

REVIEWS IN MEDICINE, ALAN SUGAR, EDITOR

The Peroxisome and the Eye

STEVE J. FOLZ, B.S., AND JONATHAN D. TROBE, M.D.

The W.K. Kellogg Eye Center, and Departments of Ophthalmology and Neurology, University of Michigan Medical Center, Ann Arbor, Michigan

Abstract. Several childhood multisystem disorders with prominent ophthalmological manifestations have been ascribed to the malfunction of the peroxisome, a subcellular organelle. The peroxisomal disorders have been divided into three groups: 1) those that result from defective biogenesis of the peroxisome (Zellweger syndrome, neonatal adrenoleukodystrophy, and infantile Refsum's disease); 2) those that result from multiple enzyme deficiencies (rhizomelic chondrodysplasia punctata); and 3) those that result from a single enzyme deficiency (X-linked adrenoleukodystrophy, primary hyperoxaluria type 1). Zellweger syndrome, the most lethal of the three peroxisomal biogenesis disorders, causes infantile hypotonia, seizures, and death within the first year. Ophthalmic manifestations include corneal opacification, cataract, glaucoma, pigmentary retinopathy and optic atrophy. Neonatal adrenoleukodystrophy and infantile Refsum's disease appear to be genetically distinct, but clinically, biochemically, and pathologically similar to Zellweger syndrome, although milder. Rhizomelic chondrodysplasia punctata, a peroxisomal disorder which results from at least two peroxisomal enzyme deficiencies, presents at birth with skeletal abnormalities and patients rarely survive past one year of age. The most prominent ocular manifestation consists of bilateral cataracts. X-linked (childhood) adrenoleukodystrophy, results from a deficiency of a single peroxisomal enzyme, presents in the latter part of the first decade with behavioral, cognitive and visual deterioration. The vision loss results from demyelination of the entire visual pathway, but the outer retina is spared. Primary hyperoxaluria type 1 manifests parafoveal subretinal pigment proliferation. Classical Refsum's disease may also be a peroxisomal disorder, but definitive evidence is lacking. Early identification of these disorders, which may depend on recognizing the ophthalmological findings, is critical for prenatal diagnosis, treatment, and genetic counselling. *Surv Ophthalmol* 35:353-368, 1991)

Key words. infantile Refsum's disease • neonatal adrenoleukodystrophy • peroxisome • peroxisomal disorders • primary hyperoxaluria type • Refsum's disease • rhizomelic chondrodysplasia punctata • Zellweger syndrome

As the result of recent developments in cellular biochemistry, a group of childhood diseases with prominent ophthalmological manifestations can now be attributed to the malfunction of a subcellular organelle called the "peroxisome." Discovered in 1954, the peroxisome is known to harbor a large number of important catabolic and anabolic reactions, among them the degradation of very-long-chain fatty acids. The build-up of these very-long-chain fatty acids and characteristic ocular abnormalities are principal markers of the peroxisomal disorders.

I. The Peroxisome

A. HISTORICAL PERSPECTIVE

While observing mouse kidney cells in 1954, Rhodin noted a single membrane-bound organelle with a granular matrix measuring about one-half micrometer which he called simply a "microbody."¹² A few years later, de Duve et al²⁷ discovered that this microbody oxidized certain substrates by utilizing molecular oxygen (O₂) and producing hydrogen peroxide (H₂O₂), leading them to designate this organelle the "peroxisome."

Branden et al,¹⁵⁵ who showed that administration of phytol, a precursor of phytanic acid, induces peroxisomal proliferation and leads to a five-fold increase in peroxisomal acyl-CoA oxidase levels. Furthermore, an elevated serum phytanic acid level is found in the peroxisomal biogenetic disorders.

D. ANABOLIC REACTIONS

Anabolic reactions that take place in the peroxisome include ether lipid synthesis (a plasmalogen precursor),⁴⁵ bile acid synthesis,⁹⁵ and possibly cholesterol synthesis.⁶⁶ Peroxisomal biogenetic disorders leave these substances in deficit or pile up excessive intermediates.

1. Ether Lipids

Peroxisomes prepare ether lipids, the major precursors for plasmalogen synthesis, from dihydroxyacetone phosphate. Plasmalogens comprise up to 20% of mammalian cell membranes¹³⁵ and 15% of myelin lipids.⁹¹ Whereas conventional phospholipids contain an ester-linked fatty acid at the first position of the glycerol backbone, plasmalogens contain a 1,2 unsaturated long-chain vinyl ether linkage at the first position. The predominant plasmalogen in most tissues is phosphatidylethanolamine, although heart and liver cell membranes contain predominantly phosphatidylcholine.⁵³ The final synthetic reactions of plasmalogen synthesis occur in the endoplasmic reticulum.⁴⁷ Defective plasmalogen synthesis may be partially responsible for some of the neurologic manifestations of peroxisomal disorders.

2. Bile Acids

Certain steps of bile acid synthesis occur in the peroxisome which accounts for the proportionally higher levels of bile acid intermediates observed in patients with peroxisome biogenesis disorders.⁹⁵ Two bile acid precursors, dihydroxycoprostanic acid and trihydroxycoprostanic acid, are detectable clinically and may aid in the diagnosis.

3. Cholesterol

Peroxisomes may possess a pathway for cholesterol synthesis¹⁴⁶ that is distinct from the better known microsomal pathway. Disruption of the peroxisomal pathway may lead to the low plasma cholesterol levels observed in some patients with peroxisomal disorders.⁹⁷

II. Peroxisomal Disorders

The peroxisomal disorders have been divided into three groups: those that result from defective biogenesis of the organelle, those resulting from more than one enzymatic abnormality but with in-

TABLE 1

Peroxisomal Disorders as Recorded at the Kennedy Institute from 1981-1988 (Adapted from Moser⁸⁷)

Disorder	No. Cases
X-linked adrenoleukodystrophy hemizygotes	575
X-linked adrenoleukodystrophy heterozygotes	504
Zellweger Syndrome	105
Neonatal adrenoleukodystrophy	54
Rhizomelic chondrodysplasia punctata	18
Infantile Refsum's disease	12
Classical Refsum's disease	4
Primary hyperoxaluria type 1	Not monitored
Insufficient information for classification	55
Others (including hyperpipecolic acidemia and isolated defects of very long chain fatty acid metabolism)	18
Total	1,345

tact peroxisome structure, and those that appear to result from one faulty enzyme.⁸⁷ The relative frequency of the various peroxisomal disorders has been reported for 1981-1988 from the Kennedy Institute⁸⁷ (Table 1).

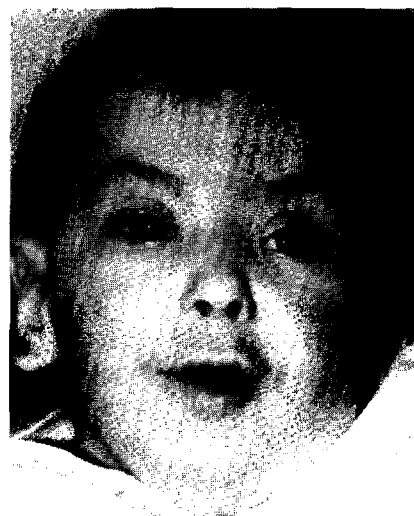A. PEROXISOME BIOGENESIS DISORDERS (TABLE 2)

The peroxisomal disorders that result from abnormal biogenesis of the organelle include Zellweger (Cerebro-hepato-renal) syndrome, neonatal adrenoleukodystrophy, and infantile Refsum's disease. Disorders of peroxisome biogenesis all share a panel of ultrastructural or biochemical abnormalities,⁸⁷ which include: 1) absent or reduced numbers of peroxisomes; 2) catalase present in the cytosol (instead of in the peroxisome); 3) reduced tissue levels of plasmalogen; 4) defective oxidation and accumulation of very long-chain fatty acids; 5) deficient oxidation and age-dependent accumulation of phytanic acid; 6) defects in certain steps of bile acid synthesis and accumulation of bile acid intermediates; 7) defective oxidation and accumulation of L-pipecolic acid; and 8) increased urinary excretion of dicarboxylic acids due to inadequate H₂O₂-based oxidation.

Genetic analysis of the peroxisomal biogenesis disorders has shown that at least five complementation groups (genes) exist.^{15,118} Alteration of any of three different genes may result in Zellweger syndrome. Likewise, there are two separate genes whose disruption will yield neonatal adrenoleukodystrophy, and one which can result in infantile Refsum's disease. Because the complementation group which encompasses infantile Refsum's dis-



Fig. 2. Left: Infant with Zellweger syndrome, showing severe craniofacial dysmorphic features: high forehead, hypertelorism, and hypoplastic supraorbital ridges (Reprinted from Smith et al¹³⁴ with permission of the authors and the CV Mosby Co.) Right: Infant with Zellweger syndrome exhibiting milder dysmorphic features: hypertelorism and hypoplastic supraorbital ridges (courtesy of James McManaway, III, MD, Hershey, PA).



ease is also one of the three complementation groups for Zellweger syndrome, the disruption of one gene may produce either Zellweger syndrome or infantile Refsum's disease. The factors which determine which of the two diseases will occur are currently unknown.

1. Zellweger Syndrome (Cerebro-hepato-renal Syndrome)

In 1964, Bowen et al¹² first described a severe neonatal disorder with distinctive craniofacial dysmorphism marked by a high forehead, epicanthal folds, hypoplastic supraorbital ridges and nasal

TABLE 2
Peroxisomal Disorders with Ocular Manifestations

	Zellweger Syndrome	Neonatal Adrenoleukodystrophy	Infantile Refsum's Disease
Inheritance	Autosomal Recessive	Autosomal Recessive	Autosomal recessive
Age at onset	Neonatal	Neonatal	First decade
Peroxisomal Defect	Imperfect biogenesis	Imperfect biogenesis	Imperfect biogenesis
Peroxisomes	Markedly reduced or absent	Markedly reduced or absent	Markedly reduced or absent
Ophthalmologic Findings	Pigmentary retinopathy and retinal arteriolar attenuation Optic atrophy Corneal clouding Glaucoma Cataract Extinguished ERG	Pigmentary retinopathy and retinal arteriolar attenuation Pigment epithelial clumping Optic atrophy Extinguished ERG	Pigmentary retinopathy and retinal arteriolar attenuation Optic atrophy Extinguished ERG
Other Clinical Findings	Craniofacial dysmorphism Seizures and hypotonia Psychomotor retardation Renal cysts	Adrenal cortical atrophy Seizures and hypotonia Psychomotor retardation	Deafness Psychomotor retardation
Biochemical Diagnostic Tests	Plasma: VLCFA Pipecolic acid Phytanic acid Bile acids RBC: Plasmalogen	Plasma: VLCFA Pipecolic acid Phytanic acid Bile acids RBC: Plasmalogen	Plasma: VLCFA Pipecolic acid Phytanic acid Bile acids RBC: Plasmalogen

*VLCFA = Very-long-chain fatty acids

bridge, micrognathia, high arched palate, and hypertelorism (Fig. 2). The externally apparent ocular abnormalities include corneal clouding,^{12,44,93,104, 105,136,144} cataracts,^{56,64,69,94,104,136,164} and glaucoma.^{12,104,105,144}

Zellweger syndrome babies also have seizures, psychomotor retardation, severe hypotonia, talipes equinovarus, limb contractures with limited finger extension (camptodactyly), hepatomegaly, severe hearing impairment, ventricular septal defects, jaundice, and hypoprothrombinemia.^{36,94,134,145} Death occurs within a few months.

As globes were inspected after death, it became evident that the posterior ocular segment is also affected, with narrowed retinal arterioles,^{35,139,157} retinal pigment clumping,¹⁰⁶ and optic disc pallor and hypoplasia.^{22,106,139} Most observers have noted that the abnormal dispersion of retinal pigment lacks the perivascular "bone spicule" pattern associated with typical retinitis pigmentosa.^{22,35} The extensive retinal abnormalities were foretold by the finding of extinguished electroretinograms in all cases.^{56,139}

The brain pathology of Zellweger syndrome consists of a failure of neuronal migration and patchy demyelination.^{28,32,93,156} The areas of demyelination

are attended by perivascular macrophages laden with inclusions which, on electron microscopy, are found to consist of two electron-dense leaflets separated by a lucent space.⁹⁴ These inclusions have been identified as cholesterol esters of very-long-chain fatty acids.

Several reports have now characterized the ophthalmic pathology. Anteriorly, corneal epithelial edema,^{22,44} posterior embryotoxon, cataract,^{44,56,69} and glaucoma have been inconsistently documented. The cause of the corneal clouding is uncertain, as no pathologic inclusions have been found in the cornea. The cataracts, of variable density, appear to be caused by vacuolations of cortical lens fibers. Although anterior chamber angle anomalies have been described,²² the pathogenesis of glaucoma is not definite.

The posterior segment abnormalities are far more severe (Fig. 3). Most striking is a loss of photoreceptors,^{35,44,69,156} but all retinal neurons are reduced in number, including retinal pigment epithelium and ganglion cells.^{44,156} Scattered through the retina and the subretinal space are numerous macrophages containing pigment and nonpigmented cytoplasmic bileaflet inclusions identical to

TABLE 2

Peroxisomal Disorders with Ocular Manifestations (continued)

Rhizomelic Chondrodysplasia Punctata	X-linked Adrenoleukodystrophy	Primary hyperoxaluria Type 1	Classical Refsum's Disease
Autosomal recessive	X-linked	Autosomal recessive	Autosomal recessive
Neonatal	First decade	First or second decades	First to fourth decades
Plasmalogen synthesis	VLCFA* oxidation	Glyoxalate metabolism	Phytanic acid oxidation
Phytanic acid oxidation	(deficient lignoceryl-CoA ligase)	(deficient alanine:glyoxalate aminotransferase)	(deficient phytanic acid alpha-hydroxylase)
Thiolase processing			
Present	Present	Present	Present
Cataract	Optic atrophy	Black parafoveal ringlets	Pigmentary retinopathy
Normal ERG	Anterior and posterior visual pathway demyelination	with or without white fibrous material deep to the lesion	and retinal arteriolar attenuation
	Normal ERG	Optic atrophy	Night blindness
			Optic atrophy
			Reduced ERG
Shortening of proximal extremities	Adrenal cortical atrophy	Renal failure	Chronic polyneuropathy
Dermatitis	Dark skin pigmentation	Osteodystrophy	Ataxia
Psychomotor retardation	Emotional lability	hydrocephalus	Hearing loss
Radiographic epiphyseal stippling	Cognitive decline		Increased CSF protein
	Hearing loss		Cardiopathy
	Incoordination and spasticity		Anosmia
Plasma: Phytanic acid	Plasma: VLCFA	Urine: Organic acids	Plasma: Phytanic acid
RBC: Plasmalogen	RBC: VLCFA	Liver: Alanine: glyoxalate aminotransferase in percutaneous biopsy	Fibroblasts: Phytanic acid
	Fibroblasts: VLCFA		

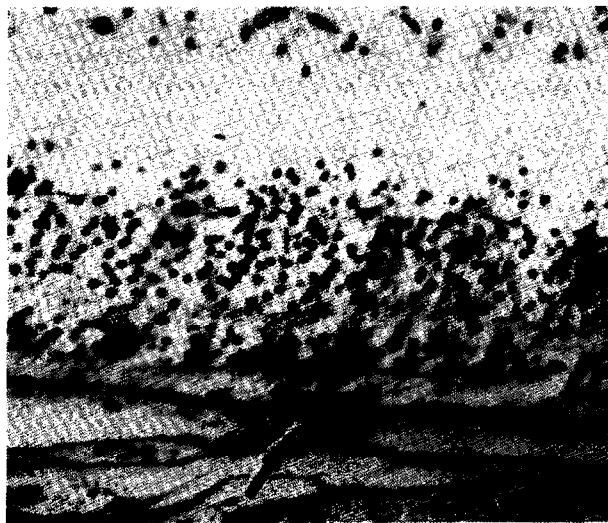


Fig. 3. Midperipheral retina in case of Zellweger syndrome, showing loss of photoreceptors and ganglion cells. An aggregate of pigmented macrophages (arrow) is present in the subretinal space (hematoxylin and eosin, by in situ hybridization in neuronal cells in a latently $\times 290$; reprinted from Cohen et al²² with permission of the authors and The Ophthalmic Publishing Co., Chicago, IL).

those seen in the brain. These inclusions are also found in the retinal pigment epithelium. The optic nerve is profoundly demyelinated, its axons interleaved with the familiar inclusion-bearing macrophages.¹³⁹ The posterior vitreous contains enough of these bileaflet-bearing macrophages to appear hazy in some cases.²² One may speculate that the accumulation of very-long-chain fatty acids kills the neurons and the myelin-forming oligodendrocytes, and that the macrophages scavenge the debris.

In 1973, Zellweger syndrome became the first human disease to be linked to the peroxisome. By utilizing histochemical staining procedures, Goldfischer et al⁹⁹ were able to show that tissues from Zellweger syndrome patients lacked catalase-containing particles (peroxisomes). Using more sophisticated techniques, Santos et al¹²¹ have recently been able to demonstrate that membrane structures similar to peroxisomes *are* present in Zellweger syndrome patients, but do not contain the normal complement of enzymes. Subsequent studies confirmed that many peroxisomal enzymes are synthesized normally in Zellweger syndrome but are not assembled into the organelle and many are therefore quickly degraded in the cytoplasm.^{25,159}

Zellweger syndrome shares the biochemical profile common to all peroxisomal biogenetic disorders, but may be biochemically distinct in having the highest very-long-chain fatty acid accumulation and lowest level of plasmalogens.

The diagnosis of Zellweger syndrome should be considered in a severely hypotonic infant with seizures, craniofacial dysmorphism, narrowed retinal arterioles, retinal pigment dispersion, and optic disc pallor. Corneal clouding and cataract are not necessary features. With these findings, Zellweger syndrome can be distinguished from intrauterine infections, Lowe's syndrome, galactosemia, and lysosomal storage abnormalities by finding elevated plasma very-long-chain fatty acids and reduced plasmalogen levels. If these tests are not normal, pipercolic acid and bile acids may be measured for confirmation. These specialized tests, which are still available only in a small number of medical centers, have now been extended to prenatal diagnosis.⁸² Because Zellweger syndrome is an autosomal recessive disorder,⁹³ genetic counseling of families that have had an affected offspring is critical. Unfortunately, there is yet no treatment available.

2. Neonatal Adrenoleukodystrophy

Neonatal adrenoleukodystrophy was first described in 1978 by Ulrich et al.¹⁵⁴ They observed a severely hypotonic infant who developed seizures at 4 days and died at 20 months. Because their patient had adrenal cortical atrophy and patchy brain demyelination reminiscent of the already well known X-linked adrenoleukodystrophy, they chose to label the disease neonatal adrenoleukodystrophy. It subsequently became clear that neonatal adrenoleukodystrophy is an autosomal recessive disorder which is clinically, pathologically, and biochemically much closer to Zellweger syndrome than to X-linked adrenoleukodystrophy.

Neonatal adrenoleukodystrophy may look exactly like Zellweger syndrome and cause death within the first year, but more commonly the disease is milder than Zellweger syndrome, with patients manifesting no dysmorphic features and living an average of four years — some even into the second decade.^{85,168} Patients typically have adrenal cortical atrophy, but rarely manifest adrenal insufficiency.⁶⁷ Anterior ocular segment abnormalities are uncommon, but retinal pigmentary degeneration and optic atrophy are disabling and diagnostically important.⁶³

We have had the opportunity to perform ophthalmological examinations on two of the longest-surviving patients with neonatal adrenoleukodystrophy — brothers aged 12 and 15. In both boys, visual acuity was 20/200 OU. The older brother had a comitant 30 prism diopter right exotropia, while the younger brother's motility examination was normal. Both patients demonstrated smooth ocular movements without nystagmus. The pupils of both patients reacted moderately, but sluggishly to light,





Fig. 4. Fundus photographs from right eye (left) and left eye (right) of a 15-year-old boy with Neonatal Adrenoleukodystrophy. Note marked retinal arteriolar attenuation, optic disc pallor, and loss of pigment epithelium especially evident in macular area.




Fig. 5. Electroretinograms (ERGs) from two boys with neonatal adrenoleukodystrophy, showing extinguished responses.

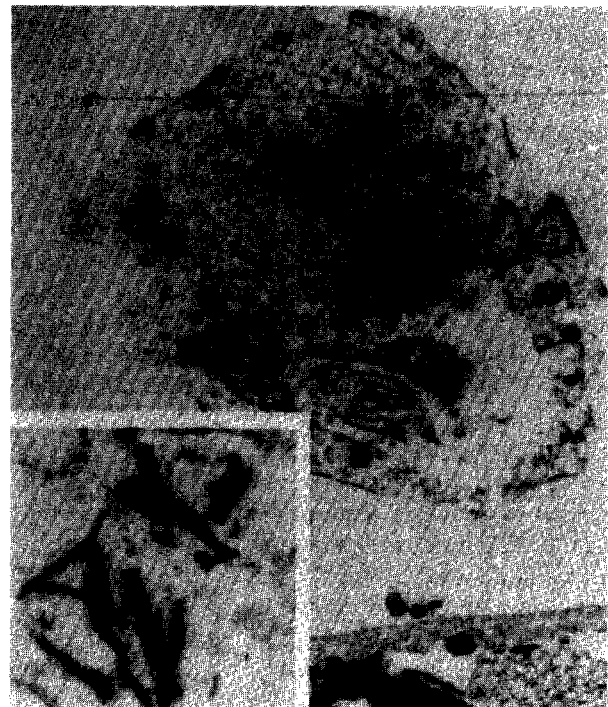


Fig. 6. Left: Retina from patient with neonatal adrenoleukodystrophy, showing loss of photoreceptor and ganglion cells, similar to that seen in Zellweger Syndrome (hematoxylin and eosin, $\times 100$). Right: Electron micrograph $\times 27,000$ of a vitreous macrophage displaying inclusion (arrow). Inset ($\times 95,000$) shows that inclusion consists of two electron-dense leaves separated by a central lucent zone. (Reprinted from Glasgow et al³⁸ with permission of the authors and *Ophthalmology*.)

Fig. 7. Retina from patient with X-linked adrenoleukodystrophy. Note loss of ganglion cells but preservation of photoreceptors. There is postmortem artifactual detachment of the photoreceptor layer (Hematoxylin and eosin, $\times 40$; Reprinted from Wray et al¹⁶⁶ with permission of the authors and the Ophthalmic Publishing Co., Chicago, IL).



and there were no other anterior segment abnormalities. The optic nerves exhibited waxy pallor with marked attenuation of the retinal vessels (Fig. 4). Pigment was clumped and scattered throughout the retinal mid-periphery; the perifoveal area was markedly depigmented. The electroretinogram showed the cone and rod responses to be decreased 95 to 98% (Fig. 5).

The pathologic findings of neonatal adrenoleukodystrophy in the central nervous system are similar to those of Zellweger syndrome.⁷ Ocular pathologic findings are confined to the posterior segment but otherwise are identical to those described in Zellweger syndrome^{22,38} (Fig. 6A). Characteristic bileaflet inclusions are present in the adrenal cortex, pigment epithelial cells, photoreceptor cells, and retinal and vitreous macrophages³⁸ (Fig. 6B).

The link to the peroxisome came first in 1982, when Brown et al¹⁴ demonstrated deficient peroxisomal very-long-chain fatty acid oxidation in tissues from neonatal adrenoleukodystrophy patients. Then in 1985, Goldfischer et al⁴⁰ discovered that peroxisomes are significantly reduced in number and size in neonatal adrenoleukodystrophy patients. It has since been learned that neonatal adrenoleukodystrophy patients share the biochemical aberrations found in Zellweger syndrome patients, except that neonatal adrenoleukodystrophy shows increased serum levels of saturated very-long-chain fatty acids,⁶³ but normal or reduced levels of mono-unsaturated very-long-chain fatty acids.⁶⁷

Neonatal adrenoleukodystrophy should be regarded clinically as a mild form of Zellweger syndrome. Patients frequently survive the years of infancy, show no dysmorphic features, and have markedly diminished vision. Because of the retinal findings, they may initially be diagnosed as having "Leber's congenital amaurosis"³⁰ or suspected of having the infantile form of neuronal ceroid lipo-

fuscinosi.^{96,150} When hearing loss is present, they may be labelled "Usher's syndrome." The correct diagnosis can now be made, as with Zellweger syndrome, by demonstrating the plasma abnormalities shared by the peroxisomal biogenetic disorders.

3. Infantile Refsum's Disease

Infantile Refsum's disease is the least severe of the peroxisome biogenesis disorders, and was first described in 1982 by Scotto et al¹²⁶ and Boltshauser et al.¹⁰ They observed patients presenting in the first year of life with pigmentary retinopathy, neurosensory deafness, growth and mental retardation, hepatomegaly, and mild facial dysmorphism consisting of epicanthal folds, flat nasal bridge, and

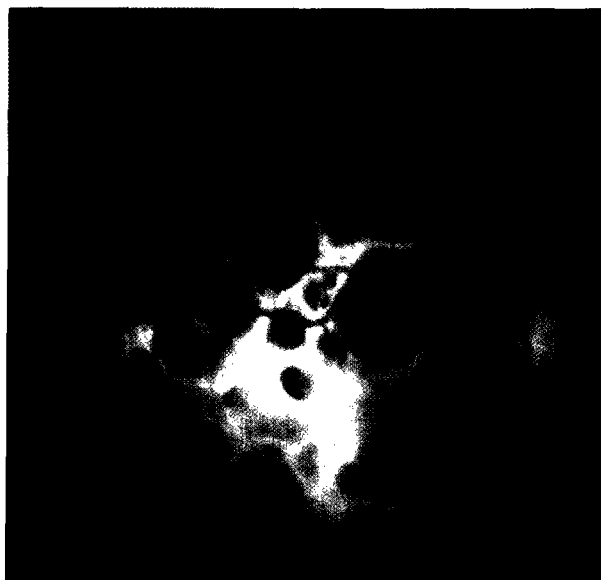

Fig. 8. Fundus photograph from a 2½ year old girl with Primary hyperoxaluria Type 1 demonstrating confluent, black, subretinal parafoveal ringlets and white fibrosis (Reprinted from Small et al¹³³ with permission of the authors and the American Medical Association).

low set ears. Increased serum levels of phytanic acid led them to surmise that these patients suffered from an infantile form of Refsum's disease, despite the fact that adult patients with Refsum's disease do not have facial dysmorphism or cognitive impairment.

Although microphthalmia, strabismus, and nystagmus have been described, the most consistent ophthalmic abnormalities are retinal arteriolar attenuation and mottled pigmentation of the retina with prominent loss of perifoveal pigment.¹⁶³ The electroretinogram demonstrates severely reduced rod and cone mediated responses.

The pathologic manifestations of infantile Refsum's disease have been documented in only one case study by Torvik et al,¹⁴⁷ who noted micronodular liver cirrhosis and hypoplastic but nonatrophic adrenal changes. The central nervous system showed severe hypoplasia of the cerebellar granular layer and reduction of axons and myelin in various areas including the optic nerves. Large numbers of perivascular macrophages with bilamellar inclusions were present in these areas, but no active demyelination process was seen. There was neuronal loss in all layers of the retina.

Shortly after infantile Refsum's disease was first described, further biochemical studies indicated that phytanic acid accumulation was not the only abnormality. Excessive tissue amounts of very-long-chain fatty acids, pipecolic acid, and bile acid intermediates were discovered,^{16,98,99} overlapping those of the biogenetic peroxisomal disorders, Zellweger syndrome and neonatal adrenoleukodystrophy, but much less severe. Several investigators have now reported a deficiency of peroxisomes in tissues from infantile Refsum's disease patients.^{6,91,115,158}

B. PEROXISOMAL DISORDERS RESULTING FROM MORE THAN ONE ENZYME DEFICIENCY

Rhizomelic chondrodysplasia punctata is currently the only disorder in this category. There is defective plasmalogen synthesis, phytanic acid oxidation, and abnormal processing of the peroxisomal enzyme thiolase. Unlike the peroxisomal biogenesis disorders, peroxisomes are present but may be abnormal.⁵²

Due to perturbed synthesis, plasmalogen levels are profoundly reduced and are lower than in Zellweger syndrome.^{52,57} Phytanic acid levels are increased and are comparable to those seen in classical Refsum's disease.⁵⁷ However, pipecolic acid, bile acid intermediates, and very long chain fatty acid levels are normal in rhizomelic chondrodysplasia punctata, indicating that some peroxisomal functions are intact.

1. Rhizomelic Chondrodysplasia Punctata

In 1914, Conradi described chondrodysplasia punctata as a condition marked by stippling foci of calcification in the epiphyses.²⁴ In 1971 Spranger et al¹³⁷ delineated the rhizomelic form of chondrodysplasia, known as rhizomelic chondrodysplasia punctata, characterized by autosomal recessive inheritance, shortening of the proximal extremities, dermatitis, psychomotor retardation, cataracts, and death usually before the end of the first year. Rhizomelic chondrodysplasia punctata was shown to be a peroxisomal disorder by Heymans et al.⁵² They noted the striking clinical similarities of rhizomelic chondrodysplasia punctata to Zellweger syndrome, then discovered a deficiency of plasmalogen synthesis and elevated levels of phytanic acid which are indicative of peroxisome dysfunction.

Rhizomelic chondrodysplasia punctata is to be distinguished from Conradi-Hunermann chondrodysplasia, which is an autosomal dominant disease with a normal life span and normal intellect. It is not a peroxisomal disorder.

Ocular findings in patients with rhizomelic chondrodysplasia punctata include alternating esotropia, lateral gaze nystagmus, and wandering eye movements.⁷⁴ However, cataracts are the most prominent and debilitating ophthalmologic manifestation.^{3,48,74,119}

A characteristic radiographic manifestation of rhizomelic chondrodysplasia punctata is irregular calcification (stippling) of the cartilage of the extremities.^{3,37,137} Primary ossification centers may be absent in the lower femur, and histologically abnormal chondrocytes are observed.¹⁰⁰ Cleaving of vertebral bodies, cerebral hypoplasia, and reduced neurons in the cerebrum, cerebellum, medulla, and spinal cord have also been reported.⁷⁴

Ocular pathologic features consist of bilateral anterior capsular cataracts containing acid mucopolysaccharides, posterior lenticonus, posterior embryotoxon, and hypoplasia of the choroid and ciliary body.⁷⁴ The cataracts are believed to be histologically similar to the usual anterior capsular cataract.^{48,74,119} Hypoplasia of retinal ganglion cells, nerve fibers, and optic nerve may also be present.⁷⁴

C. PEROXISOME DISORDERS RESULTING FROM A DEFICIENCY OF A SINGLE ENZYME

X-linked adrenoleukodystrophy and primary hyperoxaluria type 1 appear to result from a deficiency of a single peroxisomal enzyme. Although classical Refsum's disease is also frequently attributed to a single peroxisomal enzyme deficiency, definitive evidence is lacking.

The biochemical perturbation observed when the peroxisome disorder is caused by a single faulty en-

zyme is much more limited than in the peroxisome biogenesis disorders. One such example is the very-long-chain fatty acid build-up in X-linked adrenoleukodystrophy because of deficient lignoceroyl-CoA synthetase (an acyl-CoA ligase).^{50,73,129,160,162} Primary hyperoxaluria type 1 results from a deficiency of the peroxisomal enzyme alanine: glyoxylate aminotransferase and manifests increased serum levels of glyoxalate and oxalate.^{26,86} Classical Refsum's disease results from defective phytanic acid oxidation, a consequence of deficient phytanic acid alpha-hydroxylase.^{31,59} However, this reaction has not yet been localized to the peroxisome.

1. X-Linked Adrenoleukodystrophy

In 1923 Siemerling and Creutzfeldt first recognized a disorder that manifested adrenal hypofunction and cerebral demyelination.¹²⁸ Because the children appeared tanned due to adrenal dysfunction, and their post-mortem brains and spinal cords showed demyelination with gliosis, the authors called the condition "bronzed sclerosing encephalomyelitis." The condition was later named "adrenoleukodystrophy," and was found to have X-linked inheritance.^{77,85,86}

There are two predominant phenotypes associated with X-linked adrenoleukodystrophy: a *childhood form*, in which visual loss is a prominent feature, and an *adult form*, called adrenomyeloneuropathy, in which color vision deficits have been the only reported ophthalmologic disturbance.¹²⁰ In the childhood form, the first symptoms usually begin mid-way through the first decade, with emotional lability and hyperactivity. "Attention deficit disorder" is usually diagnosed, but cognitive decline soon sets in, followed by loss of sight and hearing, incoordination, and spastic quadriparesis. Adrenal hypofunction is present in nearly all cases, but may precede or follow neurologic signs.¹²³ Death usually supervenes within a decade of onset.

The visual loss in X-linked adrenoleukodystrophy appears to result from demyelination of any or all portions of the visual pathway, from optic nerve to visual cortex.^{165,166} A delayed, broad, low amplitude visual evoked response that becomes extinct with time and a normal electroretinogram^{151,165} are consistent with neural visual pathway damage that spares the outer retina.

The central nervous system pathology of X-linked adrenoleukodystrophy bears superficial resemblance to that seen in Zellweger syndrome and neonatal adrenoleukodystrophy, but there are fundamental differences.^{67,123} As in the biogenetic peroxisomal disorders, there are macrophages filled with bileaflet inclusions scattered throughout the demyelinating regions. But unlike the biogenetic peroxisomal

disorders, X-linked adrenoleukodystrophy shows very severe and focal demyelination, most marked in the parietal and occipital lobes. Perivascular lymphocytes are abundant; neurons appear normal. There are characteristic striated inclusions in Schwann cells, testis, brain, and adrenal cortex which represent cholesterol esters of very-long-chain fatty acids.^{62,101,102,103,122}

Because these changes are occurring in children who are old enough to have myelinated their cerebrum, the contrast between normal and abnormal areas is striking. It can be imaged with CT and MRI, which vividly demonstrate forward progression, from occipital to frontal lobes, of areas of low signal intensity surrounded by a "torch-like" rim of high signal intensity, reflecting breakdown of the blood-brain barrier.⁹⁶ Impressed by the intensity of this surrounding inflammatory response, observers have wondered if some other disease mechanism besides metabolic dysfunction is at work.

Ocular pathologic studies show loss of the ganglion cell layer^{151,166} (Fig. 7), and atrophy and gliosis of the nerve fiber layer and optic nerve.²³ Bileaflet-bearing macrophages have been found in the optic nerve in one case.²³ Unlike the peroxisomal biogenetic disorders, the outer retina remains histologically normal.

Although X-linked adrenoleukodystrophy is the most common peroxisomal disorder, it was not until 1976 that Igarshi et al⁶² demonstrated that there is an accumulation of very-long-chain fatty acids present as cholesterol esters in the brain and adrenal tissues from X-linked adrenoleukodystrophy patients. The definitive connection came in 1984, when Singh et al^{130,131} showed that very-long-chain fatty acid oxidation is localized to the peroxisome and that X-linked adrenoleukodystrophy results from its interruption. Since then, the specific biochemical defect has been identified as a deficiency of the peroxisomal enzyme lignoceroyl-CoA synthetase,⁵⁰ the first enzyme in the very-long-chain fatty acid oxidative pathway, and one that is embedded in the peroxisomal membrane. This leads to very-long-chain fatty acid accumulation, the only distinguishing biochemical abnormality of X-linked adrenoleukodystrophy. The pile-up of very-long-chain fatty acids, as dramatic as it is, may not be the explanation for neurologic dysfunction, since the degree of dysfunction is poorly correlated with the levels of very long chain fatty acids.⁸⁶

X-linked adrenoleukodystrophy should be suspected in boys aged under ten years who exhibit hyperactive behavior and psychomotor regression together with visual loss. Ophthalmologic findings include cortical blindness and optic atrophy. The diagnosis is made definitively by finding elevated

plasma levels of very-long-chain fatty acid.

The current treatment of childhood X-linked adrenoleukodystrophy consists of replacement of adrenal steroids and dietary restrictions of fatty acid intake. It has been shown that plasma levels of very-long-chain fatty acid can be reduced to normal levels by special dietary manipulation,^{62,113} but there is no evidence that this will induce improvement or even stabilization of the disease. Immunosuppression, used in an attempt to reduce the "inflammatory" component of X-linked adrenoleukodystrophy, has been ineffective.⁸⁸ Aubourg et al⁴ have reported reversal of neurologic deficits and brain MRI abnormalities in an eight-year-old boy treated with bone marrow transplantation. They hypothesize that the transplanted marrow cells crossed the blood-brain barrier and supplied the missing peroxisomal functions.

2. Primary hyperoxaluria Type 1

There are two types of genetically determined primary hyperoxaluria. Type 1 is an autosomal recessive disorder which results from a deficiency of the peroxisomal enzyme alanine: glyoxylate aminotransferase.^{26,89} Accumulation of glyoxylate and its conversion to oxalate result in the deposition of oxalate in various tissues, including the eye. Primary hyperoxaluria type 1 usually becomes manifest during early childhood or adulthood and patients present with renal failure or nephrolithiasis.¹³³ Infantile onset is correlated with more severe features and death due to renal failure. Primary hyperoxaluria type 2 results from a deficiency of D-glycerate dehydrogenase and is not a peroxisomal disorder.

Primary hyperoxaluria type 1 causes in a distinctive retinal pigmentary disturbance secondary to deposition of oxalate. Findings are confined to the posterior pole and are bilaterally symmetric. Mild cases show small parafoveal subretinal black ringlets with a bright white or yellow center.^{48,119,133} (Fig. 8). More advanced cases show single large, black, well-circumscribed central macular lesions with white fibrous material deep to the black area and below the sensory retina. These lesions are believed to be nonprogressive. Surprisingly, visual acuity tends to be unaffected by these lesions.¹³³

The other manifestation of primary hyperoxaluria type 1 is optic disc pallor which may be secondary to increased intracranial pressure or to retinal arteriolar occlusion.¹³³ Of 24 cases followed at a single institution, three were noted to have optic disc pallor. Two of these cases previously had enlarged ventricles, papilledema, and increased intracranial pressure.¹³³ The third had retinal arteriolar attenuation believed secondary to oxalate deposition in the vessel walls.¹³² Visual acuity was subnormal in all

TABLE 3

Pigmentary Retinopathy in Inborn Errors of Metabolism of Infancy or Childhood (Adapted from Bateman et al⁵)

<i>Lysosomal disorders</i>
Mucopolysaccharidosis
Mucopolipidosis
Fucosidosis
<i>Neuronal ceroid lipofuscinosis</i>
<i>Abetalipoproteinemia</i>
<i>Aminoacidopathies</i>
Cystinosis
Gyrate atrophy
<i>Organic acidopathies</i>
Methylmalonic acidemia
<i>Multiple sulfatase deficiency</i>
<i>Mitochondrial disorders</i>
Kearns-Sayre syndrome
<i>Peroxisomal disorders</i>
Zellweger syndrome
Neonatal adrenoleukodystrophy
Infantile Refsum's disease
Classical Refsum's disease
Primary hyperoxaluria type I

cases.

The pathologic features of primary hyperoxaluria type 1 consist primarily of renal deposition of oxalate which causes nephrolithiasis and nephrocalcinosis. Osteodystrophy has been reported and may result in pathological fractures with mild trauma.¹³ Hydrocephalus and mental retardation are also rarely seen.¹³³

Ocular pathologic findings in patients with primary hyperoxaluria type 1 consist of calcium oxalate crystal deposition in the retinal pigment epithelium, ciliary body, retina, and ocular muscles.^{33,42,76,127,167} Crystals of oxalate have also been documented in the wall of retinal vessels and all vascularized ocular tissues, including the conjunctiva, iris, inner retinal layers (especially ganglion cell layer), optic disc, choroid, and episclera.⁷⁶ The black pigmented lesions of primary hyperoxaluria type 1 are believed to represent retinal pigment epithelium hypertrophy and/or hyperplasia in response to irritation by oxalate crystal deposition.⁷⁶ The white fibrosis has been postulated to represent subretinal neovascularization. Diffuse optic atrophy secondary to papilledema may be caused by impeded cerebrospinal fluid drainage due to oxalate crystal deposition, in as much as Scowens et al¹²⁷ demonstrated elevated calcium oxalate levels in the cerebrospinal fluid of a patient with primary hyperoxaluria type 1.

In the past, patients with primary hyperoxaluria type 1 succumbed to renal failure at an early age. However, renal transplantation is prolonging sur-

vival and more patients are living long enough to demonstrate ocular lesions.

3. Classical Refsum's Disease

Classical Refsum's disease, or "heredopathia atactica polyneuritiformis" was first described in 1945 by Refsum, who noted night blindness, pigmentary retinopathy, hearing loss, peripheral neuropathy and ataxia.^{107,110} Other features are an increase in the CSF protein level with a normal cell count, cardiopathy, skeletal malformations primarily of the metatarsals and metacarpals, and skin changes resembling ichthyosis.^{41,106,107,109,111,148}

Classical Refsum's disease may have its onset from the first to the third decade, either with night blindness, extremity weakness, or ataxia.¹¹⁰ It runs an indolently progressive course with death often caused by cardiac arrhythmia. Present in all cases of classical Refsum's disease, the pigmentary retinopathy is granular rather than corpuscular, but otherwise quite like typical retinitis pigmentosa in having narrowed retinal arterioles, visual fields that show ring scotomas and progressive constriction, and electroretinography that indicates marked loss of rod and cone function.^{106,110,148}

The nervous system pathology of classical Refsum's disease involves principally the peripheral nerves, the spinal cord, and the retina.^{17,18,34,108} The rods and cones are almost entirely absent, the outer nuclear and outer plexiform layers are completely atrophic, the ganglion cells are reduced in number, the inner nuclear layer is thinned, and the nerve fiber layer is thickened due to gliosis.¹⁴⁸ Retinal vessels are narrowed and occluded, their walls swelled by lipid material. The pigment epithelium may be absent in many areas of the posterior segment. Where it is present, it is thickened and loaded with lipid. The optic nerves may show demyelination, but gliosis has not been reported. The iris sphincter and dilator muscles are also infiltrated with lipid.

Whether classical Refsum's disease is truly a peroxisomal disorder is still unsettled. An elevation of phytanic acid and reduced phytanic acid oxidation are the only biochemical markers of this disease.^{31,51,111} Although similar disturbances are found in the peroxisomal biogenesis disorders, and administration of a phytanic acid precursor leads to peroxisomal proliferation, there is yet no proof that the peroxisome is the site of phytol metabolism in humans.

Classical Refsum's disease appears to be a rare disease outside northern Europe, but its diagnosis is important because a diet free of phytol arrests and may reverse its course.^{29,65,140,141} The ophthalmologist may have the first opportunity to make the diagnosis, since the ocular signs are often the most

prominent.

III. Peroxisomal Disorders and the Ophthalmologist

The peroxisomal disorders must be added to the list of conditions with inborn errors of metabolism that present in infancy or childhood with multiorgan dysfunction and retinal abnormalities (Table 3). The three peroxisomal biogenesis disorders — Zellweger syndrome, neonatal adrenoleukodystrophy, and infantile Refsum's disease — will manifest a noncorpuscular pigmentary retinopathy and optic atrophy. The only peroxisomal disorder caused by multiple enzyme abnormalities — rhizomelic chondrodysplasia punctata — will present ophthalmologically with cataract. Of the three disorders attributable to a single enzyme defect, X-linked adrenoleukodystrophy will usually manifest optic atrophy but the retina will appear normal; primary hyperoxaluria type 1 has distinctive posterior pole retinal findings of black parafoveal ringlets surrounding yellow-white patches; classical Refsum's disease manifests a pigmentary retinopathy similar to that of Zellweger syndrome and neonatal adrenoleukodystrophy. The ophthalmologist should be aware of the genetic implications of these disorders, that biochemical tests now exist for rapid, even prenatal, diagnosis,^{19,46,72,82,84,114,116,117, 125,157,161} and that in two disorders (classical Refsum's disease, X-linked adrenoleukodystrophy) treatment is available.

References

1. Arneson DW, Tipton RE, Ward JC: Hyperpipecolic acidemia: Occurrence in an infant with clinical findings of the cerebrohepato renal (Zellweger) syndrome. *Arch Neurol* 39: 713-716, 1982
2. Arnold G, Holtzman E: Microperoxisomes in the central nervous system of the postnatal rat. *Brain Res* 155:1-17, 1978
3. Aron JJ, Aron-Rosa D, Llouquet JL: Two cases of chondrodysplasia punctate are reported. *Arch Ophthalmol* 37: 197-206, 1977
4. Aubourg P, Blanche S, Jambaque I, et al: Reversal of early neurologic and neuroradiologic manifestations of X-linked adrenoleukodystrophy by bone marrow transplantation. *N Engl J Med* 322:1860-1866, 1990
5. Bateman JB, Lang GE, Maumenee IH: Genetic metabolic disorders associated with retinal dystrophies, in Ryan SJ (ed): *Retina, Vol 3*. St Louis, CV Mosby, 1989, pp 421-444
6. Beard ME, Moser AE, Sapirstein V, et al: Peroxisomes in infantile phytanic acid storage disease: A cytochemical study of skin fibroblasts. *J Inher Metab Dis* 9:321-324, 1986
7. Benke PJ, Reyes PF, Parker JC: New form of adrenoleukodystrophy. *Hum Genet* 58:204-208, 1981
8. Bhushan A, Singh RP, Singh I: Characterization of rat brain microsomal acyl-Coenzyme A ligases: Different enzymes for the synthesis of palmitoyl-Coenzyme A and lignoceroyl-Coenzyme A. *Arch Biochem Biophys* 246:374-380, 1986
9. Bock P, Kramar R, Pavelka M: Peroxisomes and related particles in animal tissues. *Cell Biol Monogr* 7:1-239, 1980
10. Boltshauser E, Spycher MA, Steinmann B, et al: Infantile phytanic acid storage disease: a variant of Refsum's disease? *Eur J Pediatr* 139:317, 1982

11. Borst P: Animal peroxisomes (microbodies), lipid biosynthesis and the Zellweger syndrome. *Trends Biochem Sci* 8:269-272, Aug 1983
12. Bowen P, Lee CSN, Zellweger H, Lindenberg R: A familial syndrome of multiple congenital defects. *Bull Johns Hopkins Hosp* 114:402-414, 1964
13. Breed A, Chesney R, Friedman A, et al: Oxalosis-induced bone disease: a complication of transplantation and prolonged survival in primary hyperoxaluria. *J Bone Joint Surg [Am]* 63:310-316, 1981
14. Brown FR, McAdams AJ, Cummins JW, et al: Cerebro-hepato-renal (Zellweger) syndrome and neonatal adrenoleukodystrophy: Similarities in phenotype and accumulation of very long chain fatty acids. *Johns Hopkins Med J* 151:344-361, 1982
15. Brul S, Westerveld A, Strijland A, et al: Genetic heterogeneity in the cerebrohepato-renal (Zellweger) syndrome and other inherited disorders with a generalized impairment of peroxisomal functions. A study using complementation analysis. *J Clin Invest* 81:1710-1715, 1988
16. Budden SS, Kennaway NG, Phil D, et al: Dysmorphic syndrome with phytanic acid oxidase deficiency, abnormal very long chain fatty acids, and pipercolic acidemia: Studies in four children. *J Pediatr* 108:33-39, 1986
17. Cammermeyer J, Haymaker W, Refsum S: Heredopathia atactica polyneuritiformis: The neuropathological changes in three adults and one child. *Am J Pathol* 30:643-644, 1954
18. Cammermeyer J: Neuropathological changes in hereditary neuropathies: manifestation of the syndrome heredopathia atactica polyneuritiformis in the presence of interstitial hypertrophic polyneuropathy. *J Neuropath Exp Neurol* 15:340-361, 1956
19. Carey WF, Robertson EF, Van Crugten C, et al: Prenatal diagnosis of Zellweger's syndrome by chorionic villus sampling- and a caveat. *Prenatal Diagnosis* 6:227-229, 1986
20. Chang Y-F: Pipercolic acid pathway: The major lysine metabolic route in the rat brain. *Biochem Biophys Res Commun* 69:174-180, 1976
21. Chang YF: Lysine metabolism in the rat brain: Blood-brain barrier transport, formation of pipercolic acid and human hyperpipercolatemia. *J Neurochem* 30:355-360, 1978
22. Cohen SMZ, Brown FR III, Martyn L, et al: Ocular histopathologic and biochemical studies of the cerebrohepato-renal syndrome (Zellweger's syndrome) and its relationship to neonatal adrenoleukodystrophy. *Am J Ophthalmol* 96:488-501, 1983
23. Cohen SMZ, Green WR, De la Cruz ZC, et al: Ocular histopathologic studies of neonatal and childhood adrenoleukodystrophy. *Am J Ophthalmol* 95:82-96, 1983
24. Conradi E: Vorzeitiges Auftreten von Knochen- und eigenartigen Verkalkungskernen bei Chondrochystrophia foetalis Hypoplastica: Histologische und Röntgenuntersuchungen. *J Kinderheilkd* 80:86-97, 1914
25. Datta NS, Wilson GN, Hajra AK: Deficiency of enzymes catalyzing the biosynthesis of glycerol-ether lipids in Zellweger syndrome. A new category of metabolic diseases involving the absence of peroxisomes. *N Engl J Med* 311:1080-1083, 1984
26. Danpure CJ, Jennings PR: Peroxisomal alanine: glyoxalate aminotransferase deficiency in primary hyperoxaluria type 1. *FEBS Lett* 201:20-24, 1986
27. De Duve C, Baudhuin P: Peroxisomes (microbodies and related particles). *Physiol Rev* 46:323-357, 1966
28. De Leon GA, Grover WD, Huff DS, et al: Globoid cells, glial nodules, and peculiar fibrillary changes in the cerebrohepato-renal syndrome of Zellweger. *Ann Neurol* 2:473-484, 1977
29. Dickson N, Mortimer JG, Faed JM, et al: A child with Refsum's disease: Successful treatment with diet and plasma exchange. *Dev Med Child Neurol* 31:92-97, 1989
30. Ek J, Kase BF, Reith A, et al: Peroxisomal dysfunction in a boy with neurologic symptoms and amaurosis (Leber's disease): Clinical and biochemical findings similar to those observed in Zellweger syndrome. *J Pediatr* 108:19-24, 1986
31. Eldjarn L, Stokke O, Try K: Alpha-oxidation of branched chain fatty acids in man and its failure in patients with Refsum's disease showing phytanic acid accumulation. *Scand J Clin Lab Invest* 18:694-695, 1966
32. Evrard P, Caviness VS Jr, Prats-Vinas J, Lyon G: The mechanism of arrest of neuronal migration in the Zellweger malformation: An hypothesis based upon cytoarchitectonic analysis. *Acta Neuropathol (Berl)* 41:109-117, 1978
33. Fielder AR, Garner A, Chambers TL: Ophthalmic manifestations of primary oxalosis. *Br J Ophthalmol* 64:782-788, 1980
34. Flament-Durand J, Noel P, Rutsaert J, et al: A case of Refsum's disease: clinical, pathological, ultrastructural and biochemical study. *Path Eur* 6:172-191, 1971
35. Garner A, Fielder AR, Primavesi R, Stevens A: Tapetoretinal degeneration in the cerebro-hepato-renal (Zellweger's) syndrome. *Br J Ophthalmol* 66:422-431, 1982
36. Gatfield PD, Taller E, Hinton GG, et al: Hyperpipercolatemia: A new metabolic disorder associated with neuropathy and hepatomegaly: A case study. *Can Med Assoc J* 99:1215-1233, 1968
37. Gilbert EF, Opitz JM, Spranger JW, et al: Chondrodysplasia punctata: Rhizomelic form. Pathologic and radiologic studies of three infants. *Eur J Pediatr* 123:89-109, 1976
38. Glasgow BJ, Brown HH, Hannah JB, Fooks RY: Ocular pathologic findings in neonatal adrenoleukodystrophy. *Ophthalmology* 94:1054-1060, 1987
39. Goldfischer S, Moore CL, Johnson AB, et al: Peroxisomal and mitochondrial defects in the cerebro-hepato-renal syndrome. *Science* 182:62-64, 1973
40. Goldfischer S, Collins J, Rapin I, et al: Peroxisomal defects in neonatal-onset and X-linked adrenoleukodystrophies. *Science* 227:67-70, 1985
41. Gordon N, Hudson REB: Refsum's syndrome heredopathia atactica polyneuritiformis: A report of three cases, including a study of the cardiac pathology. *Brain* 82:41-55, 1959
42. Gottlieb RP, Ritter JA: Flecked retina: An association with primary hyperoxaluria. *J Pediatr* 90:939-942, 1977
43. Grove JA, Gilbertson TJ, Hammerstedt RH, Henderson LM: The metabolism of D- and L-lysine specifically labeled with ¹⁵N. *Biochim Biophys Acta* 184:329-337, 1969
44. Haddad R, Font RL, Friendly DS: Cerebro-hepato-renal syndrome of Zellweger: Ocular histopathologic findings. *Arch Ophthalmol* 94:1927-1930, 1976
45. Hajra AK, Bishop JE: Glycerolipid biosynthesis in peroxisomes via the acyl dehydroxyacetone phosphate pathway. *Ann NY Acad Sci* 386:170-182, 1982
46. Hajra AK, Datta NS, Jackson LG, et al: Prenatal diagnosis of Zellweger cerebrohepato-renal syndrome. *N Engl J Med* 312:445-446, 1985
47. Hajra AK, Ghosh MK, Webber KO, Datta NS: The peroxisomal enzymes of glycerolipid metabolism, in Freysz L, Dreyfus H, Massarelli R, Gatt S (eds). *Enzymes of Lipid Metabolism II*. New York, Plenum Press, 1986, pp 199-205
48. Hammond A: Dysplasia epiphysialis punctata with ocular anomalies. *Br J Ophthalmol* 54:1755, 1970
49. Hashimoto T: Individual peroxisomal beta-oxidation enzymes. *Ann NY Acad Sci* 386:5-12, 1982
50. Hashmi M, Stanley W, Singh I: Lignocroyl-CoASH ligase: enzyme defect in fatty acid beta oxidation system in X-linked childhood adrenoleukodystrophy. *FEBS Lett* 196:247-250, 1986
51. Herndon JH, Steinburg D, Uhlendorf BW, Fales HM: Refsum's disease: Characterization of the enzyme defect in cell culture. *J Clin Invest* 48:1017-1032, 1969
52. Heymans HSA, Oorthuys JWE, Nelck G, et al: Rhizomelic chondrodysplasia punctata: Another peroxisomal disorder. *N Engl J Med* 313:187-188, 1985
53. Heymans HSA, Schutgens RBH, Tan R, et al: Severe plasmalogen deficiency in tissues of infants without peroxisomes (Zellweger syndrome). *Nature* 306:69-70, 1983
54. Higashino K, Fujioka M, Yamamura Y: The conversion of L-lysine to saccharopine and alpha-amino adipate in mouse. *Arch Biochem Biophys* 142:606-614, 1971

55. Hijikata M, Ishii N, Kagamiyama H, et al: Structural analysis of cDNA for rat peroxisomal 3-ketoacyl-CoA thiolase. *J Biol Chem* 262:8151-8158, 1987
56. Hittner HH, Kretzer FL, Mehta RS: Zellweger syndrome. Lenticular opacities indicating carrier status and lens abnormalities characteristic of homozygotes. *Arch Ophthalmol* 99:1977-1982, 1981
57. Hoefler G, Hoefler S, Waatkins PA, et al: Biochemical abnormalities in rhizomelic chondrodysplasia punctata. *J Pediatr* 112:726-733, 1988
58. Hruban Z, Rechcigl M: Microbodies and related particles. *Int Rev Cytol (Suppl 1)*:80-94, 1969
59. Hutton D, Steinberg D: Localization of the enzymatic defect in phytanic acid storage disease (Refsum's disease). *Neurology* 23:1333-1334, 1973
60. Hutzler J, Dancis J: Conversion of lysine to saccharopine by human tissues. *Biochim Biophys Acta* 158:62-69, 1968
61. Hutzler J, Dancis J: Lysine-ketoglutarate reductase in human tissues. *Biochim Biophys Acta* 377:42-51, 1975
62. Igarashi M, Schaumburg HH, Powers J, et al: Fatty acid abnormality in adrenoleukodystrophy. *J Neurochem* 26:851-860, 1976
63. Jaffe R, Crumrine P, Hashida Y, Moser HW: Neonatal adrenoleukodystrophy. Clinical, pathological, and biochemical delineation of a syndrome affecting both males and females. *Am J Pathol* 108:100-111, 1982
64. Jan JE, Hardwick DF, Lowry RB, McCormick AQ: Cerebro-hepato-renal syndrome of Zellweger. *Am J Dis Child* 119:274-277, 1970
65. Kark RAP, Engel WK, Blass JP, et al: Heredopathia atactica polyneuritiformis (Refsum's disease): A second trial of dietary treatment in two patients. *Birth Defects* 7(1):53-55, 1971
66. Keller GA, Barton MC, Shapiro DJ, Singer SJ: 3-Hydroxy-3-methylglutaryl-coenzyme A reductase is present in peroxisomes in normal rat liver cells. *Proc Natl Acad Sci USA* 82:770-774, 1985
67. Kelley RI, Datta NS, Dobyns WB, et al: Neonatal adrenoleukodystrophy: New cases, biochemical studies, and differentiation from Zellweger and related peroxisomal polydystrophy syndromes. *Am J Med Genet* 23:869-901, 1986
68. Kindl H: The biosynthesis of microbodies (peroxisomes, glyoxysomes). *Int Rev Cytol* 80:193-229, 1982
69. Kretzer FL, Hittner HM, Mehta RS: Ocular manifestations of Conradi and Zellweger syndromes. *Metab Pediatr Ophthalmol* 5:1-11, 1981
70. Lam S, Hutzler J, Dancis J: L-pipecolaturia in Zellweger syndrome. *Biochim Biophys Acta* 882:254-257, 1986
71. Lazarow PB, Robbi M, Fujiki Y, Wong L: Biogenesis of peroxisomal proteins in vivo and in vitro. *Annu NY Acad Sci* 386:285-300, 1982
72. Lazarow PB, Small GM, Santos M, et al: Zellweger syndrome amniocytes: Morphological appearance and a simple sedimentation method for prenatal diagnosis. *Pediatr Res* 24:63-67, 1988
73. Lazo O, Contreras M, Hashmi M, et al: Peroxisomal lignoceroyl-CoA ligase deficiency in childhood adrenoleukodystrophy and adrenomyeloneuropathy. *Proc Natl Acad Sci USA* 85:7647-7651, 1988
74. Levine RE, Snyder AA, Sugarman GI: Ocular involvement in chondrodysplasia punctata. *Am J Ophthalmol* 77:851-859, 1974
75. Markwell MA, McGroarty EJ, Bieber LL, Tolbert NE: The subcellular distribution of carnitine acyltransferases in mammalian liver and kidneys. A new peroxisomal enzyme. *J Biol Chem* 248:3426-3432, 1973
76. Meredith TA, Wright JD, Gammon JA, et al: Ocular involvement in primary hyperoxaluria. *Arch Ophthalmol* 102:584-587, 1984
77. Migeon BR, Moser HW, Moser AE, et al: Adrenoleukodystrophy: evidence for X-linkage, inactivation, and selection favoring the mutant allele in heterozygous cells. *Proc Natl Acad Sci USA* 78:5066-5070, 1981
78. Mihalik SJ, Moser HW, Watkins PA, et al: Peroxisomal L-pipecolic acid oxidation is deficient in liver from Zellweger syndrome patients. *Pediatr Res* 25:548-552, 1989
79. Mihalik SJ, Rhead WJ: L-pipecolic acid oxidation in the rabbit and cynomolgus monkey. Evidence for differing organellar locations and cofactor requirements in each species. *J Biol Chem* 264:2509-2517, 1989
80. Miura S, Mori M, Takiguchi M, et al: Biosynthesis and intracellular transport of enzymes of peroxisomal beta-oxidation. *J Biol Chem* 259:6397-6402, 1984
81. Miyazawa S, Hayashi H, Hijikata M, et al: Complete nucleotide sequences of cDNA and predicted amino acid sequence of rat acyl-CoA oxidase. *J Biol Chem* 262:8131-8137, 1987
82. Moser AE, Singh I, Brown FR, et al: The cerebrohepato-renal (Zellweger) syndrome: Increased levels and impaired degradation of very-long-chain fatty acids and their use in prenatal diagnosis. *N Engl J Med* 310:1141-1145, 1984
83. Moser AE, Borel J, Odone A, et al: A new dietary therapy for adrenoleukodystrophy. Biochemical and preliminary clinical results in 36 patients. *Ann Neurol* 21:240-249, 1987
84. Moser HW, Moser AE, Powers JM, et al: The prenatal diagnosis of adrenoleukodystrophy. Demonstration of increased hexacosanoic acid in cultured amniocytes and fetal adrenal gland. *Pediatr Res* 16:172-175, 1982
85. Moser HW, Moser AE, Singh I, O'Neill BP: Adrenoleukodystrophy: Survey of 303 cases: biochemistry, diagnosis, and therapy. *Ann Neurol* 16:628-641, 1984
86. Moser HW, Naidu S, Kumar AJ, Rosenbaum AE: Adrenoleukodystrophy: toward a biochemical definition of a disease with varied presentations. *CRC Crit Rev Neurobiol* 3:29-88, 1987
87. Moser HW: Peroxisomal diseases. *Adv in Pediatr* 36:1-38, 1989
88. Naidu S, Bresnan MJ, Griffin D, et al: Childhood adrenoleukodystrophy. Failure of intensive immunosuppression to arrest neurological progression. *Arch Neurol* 45:846-848, 1988
89. Nakatani T, Kawasaki Y, Minatogawa Y, et al: Peroxisome localized human hepatic alanine-glyoxylate aminotransferase and its application to clinical diagnosis. *Clin Biochem* 18:311-316, 1985
90. Ng MC Shichi H: Peroxisomal palmitoyl CoA oxidase activity in ocular tissues and cultured ciliary epithelial cells. *J Ocul Pharm* 5:65-70, 1989
91. Norton WT: Isolation and characterization of myelin. in Morell P, (ed): *Myelin*. New York, Plenum Press, 1977, pp 161-199
92. Ogier H, Roels F, Cornelis A, et al: Absence of hepatic peroxisomes in a case of infantile Refsum's disease. *Scand J Clin Lab Invest* 45:767-768, 1985
93. Opitz JM, Zurhein GM, Vitale LV, et al: The Zellweger syndrome (cerebro-hepato-renal syndrome). *Birth Defects* 5(2):144-158, 1969
94. Passarge E, McAdams AJ: Cerebro-hepato-renal syndrome. A newly recognized disorder of multiple congenital defects, including sudanophilic leukodystrophy, cirrhosis of the liver, and polycystic kidneys. *J Pediatr* 71:691-702, 1967
95. Pedersen JI, Gustafsson J: Conversion of 3alpha, 7alpha, 12 alpha-trihydroxy-5beta-cholestanic acid into cholic acid by rat liver peroxisomes. *FEBS Lett* 121:345-348, 1980
96. Percy AK: The inherited neurodegenerative disorders of childhood: Clinical assessment. *J Child Neurol* 2:82-97, 1987
97. Poll-The BT, Saudubray JM, Ogier HAM, et al: Infantile Refsum disease: an inherited peroxisomal disorder. Comparison with Zellweger syndrome and neonatal adrenoleukodystrophy. *Eur J Pediatr* 146:477-483, 1987
98. Poulos A, Sharp P, Whiting M: Infantile Refsum's disease (phytanic acid storage disease): a variant of Zellweger syndrome? *Clin Genet* 26:579-586, 1984
99. Poulos A, Sharp P: Plasma and skin fibroblasts C₂₆ fatty acids in infantile Refsum's disease. *Neurology* 34:1606-1609, 1984
100. Poulos A, Sheffield L, Sharp P, et al: Rhizomelic chondrodysplasia punctata: Clinical pathologic, and biochemical

- findings in two patients. *J Pediatr* 113:685-690, 1988
101. Powers JM, Schaumburg HH: The adrenal cortex in adrenoleukodystrophy. *Arch Pathol* 96:305-310, 1973
 102. Powers JM, Schaumburg HH: Adrenoleukodystrophy: similar ultrastructural changes in adrenal cortical cells and Schwann cells. *Arch Neurol* 30:406-408, 1974
 103. Powers JM, Schaumburg HH: Adreno-leukodystrophy (sex-linked Schilder's disease): A pathogenetic hypothesis based on ultrastructural lesions in adrenal cortex, peripheral nerve and testis. *Am J Pathol* 76:481-500, 1974
 104. Poznanski AK, Nosanchuk JS, Baublis J, Holt JF: The cerebro-hepato-renal syndrome (CHRS) (Zellweger's syndrome). *Am J Roentgenol Radium Ther Nucl Med* 109:313-322, 1970
 105. Punnett HH, Kirkpatrick JA Jr: A syndrome of ocular abnormalities, calcification of cartilage and failure to thrive. *J Pediatr* 73:602-606, 1968
 106. Rake M, Saunders M: Refsum's disease: A disorder of lipid metabolism. *J Neurol Neurosurg Psychiatry* 29:417-422, 1966
 107. Refsum S: Heredopathia atactica polyneuritiformis. A familial syndrome not hitherto described. *Acta Psychiatr Scand Suppl* 38:1-303, 1946
 108. Refsum S: Heredopathia atactica polyneuritiformis reconsideration. *World Neurol* 1:334-347, 1960
 109. Refsum S: Heredopathia atactica polyneuritiformis: Phytanic acid storage disease (Refsum's disease), in Vinken PJ, Bruyn GW (eds): *Handbook of Clinical Neurology*. Vol 21, part 1, Amsterdam, North-Holland Publishing Co, 1975, pp 181-229
 110. Refsum S: Heredopathia atactica polyneuritiformis phytanic acid storage disease (Refsum's disease) with particular reference to ophthalmological disturbances. *Metab Ophthalmol* 1:73-79, 1977
 111. Refsum S: Heredopathia atactica polyneuritiformis. Phytanic-acid storage disease, Refsum's disease: A biochemically well-defined disease with a specific dietary treatment. *Arch Neurol* 38:605-606, 1981
 112. Rhodin J: Correlation of ultrastructural organization and function in normal and experimentally changed proximal convoluted tubule cells of the mouse kidney. PhD thesis Aktiebolaget Godvil, Stockholm, 1954
 113. Rizzo WB, Phillips MW, Dammann A, et al: Adrenoleukodystrophy: Dietary oleic acid lowers hexacosanoic (C26:0) levels. *Ann Neurol* 21:232-239, 1987
 114. Rocchiccioli F, Aubourg P, Choiset A: Immediate prenatal diagnosis of Zellweger syndrome by direct measurement of very long chain fatty acids in chorion villus cells. *Prenat Diagn* 7:349-354, 1987
 115. Roels F, Cornelis A, Poll-The BT, et al: Hepatic peroxisomes are deficient in infantile Refsum disease: A cytochemical study of 4 cases. *Am J Med Genet* 25:257-271, 1986
 116. Roels F, Verdonck V, Pauwels M, et al: Visualization of peroxisomes and plasmalogens in first trimester chorionic villus. *J Inher Metab Dis* 10 (Suppl 2):233-235, 1987
 117. Roscher A, Molzer B, Bernheimer H, et al: The cerebro-hepatorenal (Zellweger) syndrome: An improved method for the biochemical diagnosis and its potential for prenatal detection. *Ped Res* 19:930-933, 1985
 118. Rosher A, Hoefler S, Hoefler G, et al: Neonatal adrenoleukodystrophy (NALD) and cerebro-hepato-renal syndrome (CHRS): Genetic complementation analysis of impaired peroxisomal plasmalogen biosynthesis. Abstracts 24, Annual Symposium of the Society for the Study of Inborn Errors of Metabolism. Amersfoort, The Netherlands, 1987
 119. Ryan H: Cataracts of dysplasia epiphysialis punctata. *Br J Ophthalmol* 54:197, 1970
 120. Sack GH, Raven MB, Moser HW: Color vision defects in adrenomyeloneuropathy. *Am J Hum Genet* 44:794-798, 1989
 121. Santos MJ, Imanka T, Shio H, et al: Peroxisomal membrane ghosts in Zellweger syndrome-aberrant organelle assembly. *Science* 239:1536-1538, 1988
 122. Schaumburg HH, Powers JM, Suzuki K, et al: Adrenoleukodystrophy (sex-linked Schilder disease): Ultrastructural demonstration of specific cytoplasmic inclusions in the central nervous system. *Arch Neurol* 31:210-213, 1974
 123. Schaumburg HH, Powers JM, Raine CS, et al: Adrenoleukodystrophy: A clinical and pathological study of 17 cases. *Arch Neurol* 32:577-591, 1975
 124. Schram AW, Strijland A, Hashimoto T, et al: Biosynthesis and maturation of peroxisomal beta-oxidation enzymes in fibroblasts in relation to the Zellweger syndrome and infantile Refsum disease. *Proc Natl Acad Sci USA* 83:6156-6158, 1986
 125. Schutgens RBH, Schrakamp G, Wanders RJA, et al: The cerebro-hepato-renal (Zellweger) syndrome: Prenatal detection based on impaired biosynthesis of plasmalogens. *Prenat Diagn* 5:337-344, 1985
 126. Scotto JM, Hadchouel M, Odievre M, et al: Infantile phytanic acid storage disease, a possible variant of Refsum's disease: three cases, including ultrastructural studies of the liver. *J Inher Metab Dis* 5:83-90, 1982
 127. Scowen EF, Stansfeld AF, Watts RWE: Oxalosis and primary hyperoxaluria. *J Pathol* 77:195-205, 1959
 128. Siemerling E, Creutzfeldt HG: Bronzekrankheit und Sklerosierende Encephalomyelitis (diffuse sclerose). *Arch Psychiatr* 68:217-244, 1923
 129. Singh I, Moser HW, Moser AE, Kishimoto Y: Adrenoleukodystrophy: Impaired oxidation of long chain fatty acids in cultured skin fibroblasts and adrenal cortex. *Biochem Biophys Res Commun* 102:1223, 1981
 130. Singh I, Moser AE, Goldfischer S, Moser HW: Lignoceric acid is oxidized in the peroxisome: Implications for the Zellweger cerebro-hepato-renal syndrome and adrenoleukodystrophy. *Proc Natl Acad Sci USA* 81:4203-4207, 1984
 131. Singh I, Moser AE, Moser HW, Kishimoto Y: Adrenoleukodystrophy: impaired oxidation of very long chain fatty acids in white blood cells, cultured skin fibroblasts, and amniocytes. *Pediatr Res* 18:286-289, 1984
 132. Small KW, Pollock S, Scheinman J: Optic atrophy in primary oxalosis. *Am J Ophthalmol* 106:96-97, 1988
 133. Small KW, Letson R, Scheinman J: Ocular findings in primary hyperoxaluria. *Arch Ophthalmol* 108:89-93, 1990
 134. Smith DW, Opitz JM, Inhorn SL: A syndrome of multiple developmental defects including polycystic kidneys and intrahepatic biliary dysgenesis in two siblings. *J Pediatr* 67:617-624, 1965
 135. Snyder F: *Ether Lipids*. New York, Academic Press, 1972, pp 1-433
 136. Sommer A, Bradel EJ, Hamoudi AB: The cerebro-hepato-renal syndrome (Zellweger's syndrome). *Biol Neonate* 25:219-229, 1974
 137. Spranger JW, Opitz JM, Bidder U: Heterogeneity of chondrodysplasia punctata. *Hum Genet* 11:190-212, 1971
 138. Stanescu B, Dralands L: Cerebro-hepato-renal (Zellweger's) syndrome. Ocular involvement. *Arch Ophthalmol* 87:590-592, 1972
 139. Steinberg D, Mize CE, Avigan J, et al: Studies on the metabolic error in Refsum's disease. *J Clin Invest* 46:313-322, 1967
 140. Steinberg D: Elucidation of the metabolic error in Refsum's disease: strategy and tactics, in Kark RAP, Rosenberg RN, Schut LJ (eds): *Advances in Neurology*, Vol 21. New York, Raven Press, 1978, pp 113-124
 141. Steinberg D: Phytanic acid storage disease: Refsum's syndrome, in Stanbury JB, Wyngaarden JB, Fredrickson DS (eds): *The Metabolic Basis of Inherited Disease*. New York, McGraw-Hill, 1978, ed 4, pp 688-706
 142. Sternlieb I, Quintana N: The peroxisomes of human hepatocytes. *Lab Invest* 36:140-149, 1977
 143. Stokke O: Alpha-oxidation of fatty acids in various mammals, and a phytanic acid feeding experiment in an animal with a low alpha-oxidation capacity. *Scand J Clin Lab Invest* 20:305-312, 1967
 144. Taylor JC, Zellweger H, Hanson JW: A new case of the Zellweger syndrome. *Birth Defects* 5(2):159-160, 1969
 145. Thomas GH, Haslam RHA, Batshaw ML, et al: Hyperpipecolic acidemia associated with hepatomegaly, mental retardation, optic nerve dysplasia and progressive neurological disease. *Clin Genet* 8:376-382, 1975

146. Thompson SL, Burrows R, Laub RJ, Krisans SK: Cholesterol synthesis in rat liver peroxisomes. Conversion of mevalonic acid to cholesterol. *J Biol Chem* 262:17420-17425, 1987
147. Torvik A, Torp S, Kase BF, et al: Infantile Refsum's disease: a generalized peroxisomal disorder. Case report with postmortem examination. *J Neurol Sci* 85:39-53, 1988
148. Toussaint D, Danis P: An ocular pathologic study of Refsum's syndrome. *Am J Ophthalmol* 72:342-347, 1971
149. Traboulsi EI, El-Baba F, Barakat AY, Faris BM: The retinopathy of primary hyperoxaluria. *Retina* 5:151-153, 1985
150. Traboulsi EI, Green WR, Luckenbach MW, de la Cruz ZC: Neuronal ceroid lipofuscinosis. Ocular histopathologic and electron microscopic studies in the late infantile, juvenile, and adult forms. *Graefes Arch Clin Exp Ophthalmol* 225:391-402, 1987
151. Traboulsi EI, Maumenee IH: Ophthalmologic manifestations of X-linked childhood adrenoleukodystrophy. *Ophthalmology* 94:47-52, 1987
152. Trijbels JMF, Monnens LAH, Bakkeren JAJM, et al: Biochemical studies in the cerebro-hepato-renal syndrome of Zellweger: A disturbance in the metabolism of pipercolic acid. *J Inher Metab Dis* 2:39-42, 1979
153. Tsai SC, Avigan J, Steinberg D: Studies on the alpha-oxidation of phytanic acid by rat liver mitochondria. *J Biol Chem* 244:2682-2692, 1969
154. Ulrich J, Herschkowitz N, Heitz P, et al: Adrenoleukodystrophy. Preliminary report of a connatal case. Light and electron microscopical, immunohistochemical and biochemical findings. *Acta Neuropathol* 43:77-83, 1978
155. Van den Branden C, Vamecq J, Wybo I, Roels F: Phytol and peroxisome proliferation. *Pediatr Res* 20:411-415, 1986
156. Volpe JJ, Adams RD: Cerebro-hepato-renal syndrome of Zellweger. An inherited disorder of neuronal migration. *Acta Neuropathol* 20:175-198, 1972
157. Wanders RJA, Schrakamp G, Van den Bosch H, et al: A prenatal test for the cerebro-hepato-renal (Zellweger) syndrome by demonstration of the absence of catalase-containing particles (peroxisomes) in cultured amniotic fluid cells. *Eur J Pediatr* 145:136-138, 1986
158. Wanders RJA, Schutgens RBH, Schrakamp G, et al: Infantile Refsum disease: deficiency of catalase-containing particles (peroxisomes), alkylldihydroxyacetone phosphate synthase and peroxisomal beta-oxidation enzyme proteins. *Eur J Pediatr* 145:172-175, 1986
159. Wanders RJA, Schutgens RBH, Heymans HSA, et al: Biochemical analysis in peroxisomal disorders, in Fahimi HD, Sies H (eds): *Peroxisomes in Biology and Medicine*. Heidelberg, Springer-Verlag, 1987, pp 341-352
160. Wanders RJA, van Roermund CWT, van Wijland MJA, et al: X-linked adrenoleukodystrophy: defective peroxisomal oxidation of very long chain fatty acids but not of very long chain fatty acyl-CoA esters. *Clin Chim Acta* 165:321-329, 1987
161. Wanders RJA, van Wijland MJA, van Roermund CWT, Schutgens RB: Prenatal diagnosis of Zellweger syndrome by measurement of very long chain fatty acid (C26:0) beta-oxidation in cultured chorionic villous fibroblasts: implications for early diagnosis of other peroxisomal disorders. *Clin Chim Acta* 165:303-310, 1987
162. Wanders RJA, van Roermund CWT, van Wijland MJA, et al: Direct demonstration that the deficient oxidation of very long chain fatty acids in X-linked adrenoleukodystrophy is due to an impaired ability of peroxisomes to activate very long chain fatty acids. *Bioch Biophys Res Commun* 153:618-624, 1988
163. Weleber RG, Tongue AC, Kennaway NG, et al: Ophthalmologic manifestations of infantile phytanic acid storage disease. *Arch Ophthalmol* 102:1317-1321, 1984
164. Williams JP, Secrist L, Fowler GW, et al: Roentgenographic features of the cerebro-hepato-renal syndrome of Zellweger. *Am J Roentgenol Radium Ther Nucl Med* 115:607-610, 1972
165. Wilson BW: The visual system manifestations of adrenoleukodystrophy. *Neuro-ophthalmol* 1:175-183, 1981
166. Wray SH, Cogan DG, Kuwabara T, et al: Adrenoleukodystrophy with disease of the eye and optic nerve. *Am J Ophthalmol* 82:480-485, 1976
167. Zak TA, Buncic R: Primary hereditary oxalosis retinopathy. *Arch Ophthalmol* 101:78-80, 1983
168. Zellweger H: The cerebro-hepato-renal (Zellweger) syndrome and peroxisomal disorders. *Dev Med Child Neurol* 29:821-829, 1987

We wish to thank Amiya K. Hajra, Ph.D., and Pamela C. Sieving for their help in preparing this manuscript. Funded in part by The University of Michigan Student Biomedical Research Program.

Reprint address: Jonathan D. Trobe, M.D., W.K. Kellogg Eye Center, 1000 Wall St., Ann Arbor, MI 48105.