

Review Article

Evidence for dental and dental specialty treatment of obstructive sleep apnoea. Part 1: the adult OSA patient and Part 2: the paediatric and adolescent patient

R. S. CONLEY *University of Michigan School of Dentistry, Department of Orthodontics and Pediatric Dentistry, University Avenue, Ann Arbor, MI, USA*

SUMMARY Until recently, obstructive sleep apnoea was a largely unknown condition. Because of the well-publicised death of some high-profile people resulting from untreated obstructive sleep apnoea, now mostly everyone has heard of the condition. Following diagnosis, several medical treatment modalities are available to patients. However, the role that dentistry and its various specialties can play in successful treatment for obstructive sleep apnoea should not be overlooked. The common

causes for adult and paediatric obstructive sleep apnoea will be presented as well as a review of the more successful forms of dental treatment. Finally, a summary of the current evidence regarding obstructive sleep apnoea treatment will be presented.

KEYWORDS: obstructive sleep apnoea, oral sleep appliance, orthognathic surgery, sleep apnea

Accepted for publication 26 June 2010

Introduction

Chronic obstructive sleep apnoea (OSA) is a severe debilitating disorder. People of all ages are affected, but overweight middle age adult males have the highest prevalence of the disease (1). Women are affected by OSA, but to a lesser degree (2). Recently, OSA is being seen in greater numbers even within the paediatric and adolescent age range (3). Several disciplines of dentistry are well equipped to provide treatment for patients with OSA owing to their education in facial growth and development as well as craniofacial and dentofacial anomalies. Some patients may not routinely see their medical doctor and may be unaware of the condition (4). Observant dentists who typically see patients more frequently than their medical colleagues may pick up signs and symptoms of OSA during the dental visit. When seen, the dental practitioner must make a referral to the sleep team for diagnosis. With the diagnosis complete, several treatment modalities are available (5–9). Successful treatment improves the

patient's subjective and objective assessment of their daytime alertness (10–13). Forms of treatment that the dental professional already performs can be highly successful for the affected patient and provide a significant service and health benefit beyond improving the patients smile and self-esteem.

Part 1: the adult OSA patient

Diagnosis and classification of adult obstructive sleep apnoea

The classic symptom of OSA is excessive daytime sleepiness. The Epworth Sleepiness Exam is an easy, inexpensive screening tool that asks patients a series of questions (14). At the conclusion of the form, the relative sleep health and sleepiness of the patient is determined. However, this test is extremely limited; it is not able to differentiate OSA from the many other types of sleep-disordered breathing such as restless leg syndrome and other conditions.

The gold standard for proper diagnosis of obstructive sleep apnoea is an overnight polysomnography which can be performed at either a full service hospital or an independent free standing accredited sleep clinic (15). Polysomnography exams combine the results of electroencephalogram (EEG), electrocardiogram (EKG), electrooculogram (EOG), electromyography (EMG) along with respiration rate, tidal volume, inspiration and expiration volumes the severity of OSA. The primary indicator of severity is the AHI or the apnoea hypopnea index. An apnoea is defined as a cessation in breathing for 2 s or more with an arterial oxygen desaturation of two to four per cent (16). A hypopnea is a fifty per cent decrease in airflow for 10 s or more with a concomitant drop in arterial oxygen saturation (16).

Normal sleep is defined as an AHI of five or less. Mild sleep apnoea has an AHI of 5-15. Patients with moderate sleep apnoea have an AHI between 15 and 30 events per hour, while patients with severe apnoea have an AHI over 30 (16). To more critically assess sleep apnoea severity, the AHI is subdivided into an apnoea index (AI) and a hypopnea index (HI). A patient with primarily apnoeas is more severe than another patient who has the same AHI but predominantly hypopnoeas. These differences are important and may lead to significantly different treatment approaches. To put the AHI into context, a patient with an AHI of 60 stops breathing or has a significant oxygen desaturation for at least 10 s every minute. This events lead to significant reduction in oxygen perfusion to the brain causing an increased risk of stroke, myocardial infarction and other cardiac anomalies (17).

Differentiation of central apnoea from obstructive apnoea is essential (18). With obstructive apnoea, respiratory effort (documented by EMG) is present yet the patient is unable to adequately ventilate. In central apnoea patients have diminished or no respiratory effort. While certain forms of treatment are effective for both, treatment provided by the dental professional is only effective for obstructive apnoea. Providing obstructive sleep apnoea therapy for a central sleep apnoea patient can result in inadequate and inappropriate treatment.

The guidelines for successful treatment vary widely, but the primary goal is to decrease the morbidity and mortality associated with the sleep disordered breathing. The most stringent criteria for success are achieving an AHI of <10. More conservative success criteria attempt to achieve at least a 50% reduction in the AHI or an AHI of

<20. A recent report states successfully treated patients have no increased morbidity or mortality (19). For untreated individuals, there is a 37% higher 5-year morbidity and mortality (12). The morbidity and mortality statistics result from higher incidence of motor vehicle accidents, heart attack, stroke, arrhythmia and hypertension. One study concluded that the incidence of motor vehicle accidents with obstructive sleep apnoea are comparable to driving while intoxicated, which presents a major public health risk (20, 21).

Imaging modalities: lateral cephalometrics, MRI and CBCT evaluation

Dental practitioners trained in cephalometrics (commonly orthodontists, paediatric dentists and oral and maxillofacial surgeons), use these radiographs to analyse traditional skeletal and dental relationships as well as incorporate an airway analysis. Each assessment compares the patient's measures to a set of 'normative' values. Unfortunately, lateral cephalometric analysis only provides information on two dimensions; the vertical and sagittal. The third dimension (transverse) is left entirely unanalysed unless the practitioner utilises a posterior anterior cephalometric radiograph (PA film). A sample lateral cephalometric tracing that includes the common lateral cephalometric landmarks is shown in Fig. 1. Table 1 lists each lateral cephalometric landmark with its anatomical definition. Each cephalometric analysis is generally broken down into categories such as:

- 1 Cranial base measures
- 2 Horizontal maxillary and mandibular skeletal measures
- 3 Vertical maxillary and mandibular skeletal and dental measures
- 4 Intramaxillary and intramandibular measures
- 5 Dental measures
- 6 Airway measures

When individual patient measures are compared to 'ideal' standards, (the cephalometrics for orthognathic surgery analysis (COGS) was used here) (22), the patient is assigned the appropriate skeletal diagnosis. Class I, (normal), skeletal relationship patients have well-balanced faces with good position and projection of the maxilla and mandible. Patients with Class II relationships are typically more convex either from maxillary overgrowth (maxillary hyperplasia), a mandibular undergrowth (mandibular hypoplasia) or a

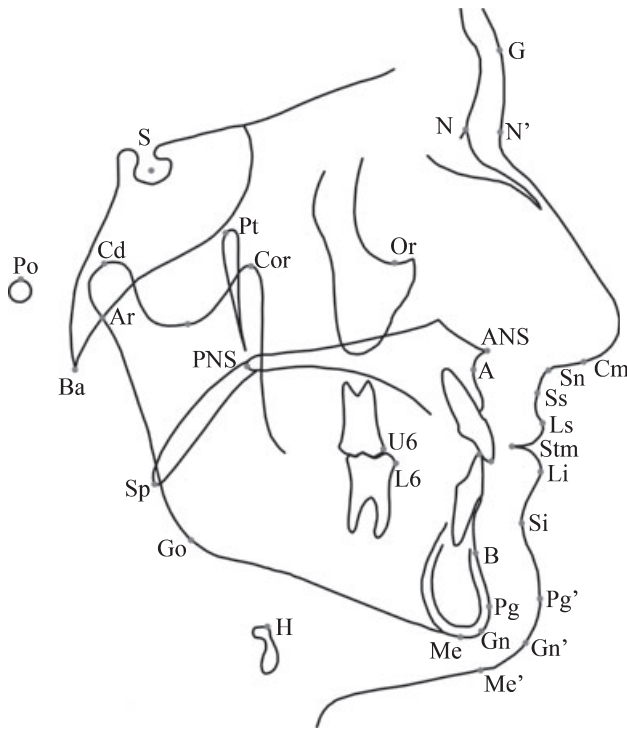


Fig. 1. A representative lateral cephalometric tracing. The individual landmarks are marked with dots. For a complete anatomical description of the landmarks, see Table 1.

combination of the two. The Class III skeletal patient demonstrates the exact opposite problem; maxillary hypoplasia, mandibular hyperplasia, or a combination of the two. Fig. 2a–c) demonstrates the lateral cephalometric tracings representative of the three different skeletal classifications.

Mild skeletal deviations from ideal generally do not constitute an increased risk of OSA. However, significant jaw abnormalities, particularly mandibular micrognathia, have been linked to OSA especially within the paediatric population (23). By examining the following cephalometric tracing (See Fig. 3), one can readily observe how this patient’s mandibular deficiency results in a functional airway deficit. This can be further impaired in craniofacial malformations such as Pierre-Robin sequence, Goldenhaar Syndrome or Marfan Syndrome (24).

While cephalometric analysis alone is insufficient to diagnose OSA, some cephalometric indicators have been reported to indicate the potential for OSA and the need for additional testing. One cephalometric measure is the linear distance from the mandibular plane to the hyoid bone (MP–H). A distance >15.4 mm

Table 1. Cephalometrics for orthognathic surgery landmarks

Skeletal (Bony) landmarks

- S: Sella; the geometric centre of the sella turcica
 - N: Nasion; the intersection of the nasal bones and the frontal bone in the midsagittal plane
 - ANS: Anterior nasal spine; the most anterior point of the bony maxilla
 - PNS: Posterior nasal spine; the most posterior point of the bony maxilla
 - A: ‘A’ point; the deepest point on the anterior surface of the bony maxilla between ANS and the upper incisor
 - U1: Upper incisor; the most inferior point on the upper central incisor
 - U6: Upper first molar; the most mesial portion of the upper first molar
 - L1: Lower incisor; the most superior point of the lower central incisor
 - L6: Lower first molar; the most mesial portion of the lower first molar
 - B: ‘B’ point; the deepest portion on the anterior contour of the mandible between the lower incisor and pogonion
 - Pg: Pogonion; the most prominent point on the anterior surface of the mandible
 - Gn: Gnathion; a constructed point midway between pogonion and menton
 - Me: Menton; the most inferior point on the bony chin
 - Go: Gonion; the most posterior-inferior point on the gonial angle of the mandible
 - Ar: Articulare; the radiographic superimposition of the ascending ramus and the cranial base
 - Cd: Condylion; the most posterior superior point on the mandibular condyle
 - Cor: Coronoid process; the most superior point on the coronoid process
 - Pt: Most posterior superior point of the pterygomaxillary fissure
 - Po: Porion; the midpoint of the superior aspect of the external auditory meatus
- Soft tissue landmarks*
- G: Glabella; the most anterior point of the forehead above the nose
 - N’: Soft tissue nasion
 - Cm: Columella
 - Sn: Subnasale; the junction of the inferior aspect of the nose and superior component of the upper lip
 - Ss: Superior sulcus; the deepest point on the curvature of the upper lip
 - Ls: Labrale superius; the most prominent point of the upper lip
 - Stm: Stomion; the intersection of the upper and lower lips. (When the lips do not contact, stomion is the midpoint between the upper and lower lip)
 - Li: Labrale inferius; the most prominent point of the lower lip
 - Si: Sulcus inferius; the deepest point on the curvature of the lower lip. Also known as soft tissue ‘B’ point or the mentolabial fold
 - Pg’: Soft tissue pogonion; the most prominent point on the anterior contour of the soft tissue chin
 - Gn’: Soft tissue gnathion; a constructed point midway between soft tissue pogonion and soft tissue menton
 - Me’: Soft tissue menton; the most inferior point of the soft tissue chin

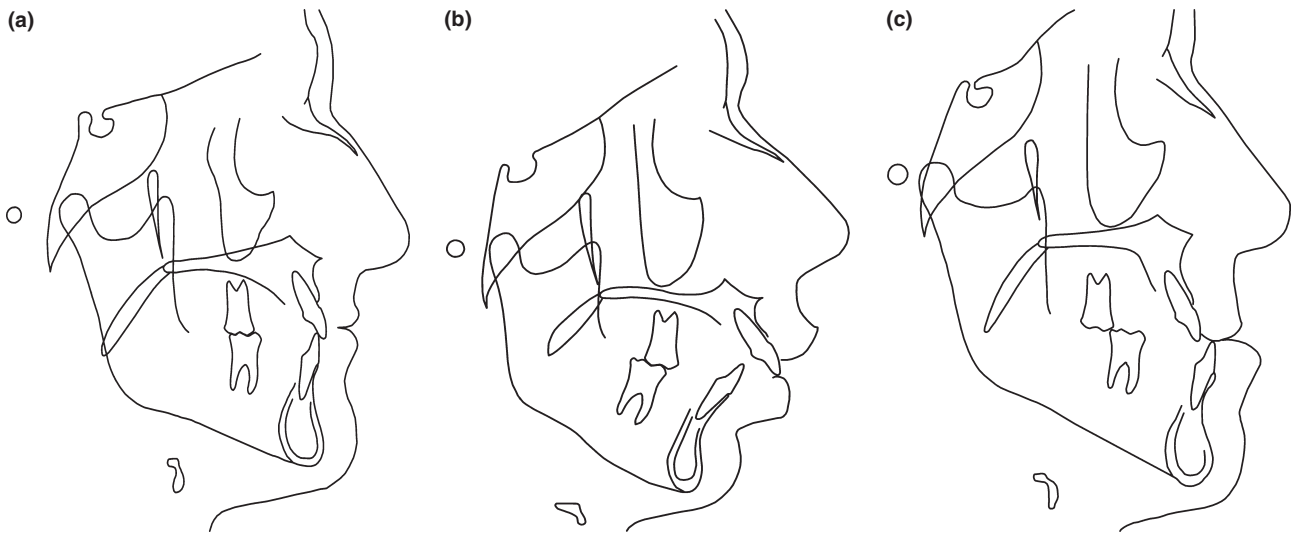


Fig. 2. Lateral cephalometric views of three distinct skeletal malocclusion. (a) depicts a patient with nearly ideal skeletal and dental balance. (b) depicts a patient with a Class II skeletal malocclusion. Note the significant mandibular deficiency, the everted lower lip, and the significant horizontal distance between the upper and lower incisors. (c) depicts the opposite, a skeletal Class III patient with mandibular hyperplasia and maxillary hypoplasia. Note the reverse overlap of the incisors, the upper incisor is behind the lower incisor.

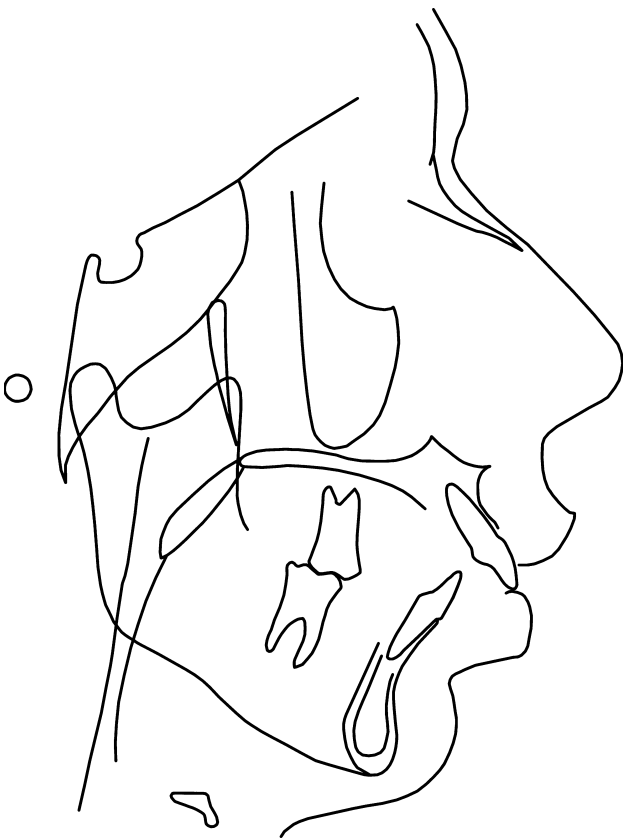


Fig. 3. In this mandibular deficient patient, the airway is also drawn. Note the significant narrowing of the airway extending from the tip of the soft palate inferiorly towards the epiglottis. This airway can become narrower in the supine position during sleep.

indicates a person at risk for OSA (25, 26). Elevated values indicate a collection of soft tissue, frequently adipose tissue, present in the submental and parapharyngeal region. This collection of tissue creates pressure, facilitating airway collapse. A collection of skeletal cephalometric measures including an increased mandibular plane angle, steep occlusal plane, over-erupted posterior dentition, large gonial angle and anterior open bite reportedly represent an increased risk for OSA (27).

Some soft tissue measures, especially those associated with soft palate dimensions, can also indicate a need for polysomnography. A longer soft palate (25, 26) and a wider soft palate can combine to reduce the posterior air space (PAS) (28–30). The combination of these factors is represented in a figure by Cistulli (30) where he presents side-by-side figures demonstrating a patient with a normal airway and a second patient with a reduced airway (See Fig. 4).

Because of its ability to accurately visualise soft tissues, several MRI studies of the airway have been conducted. Conflicting evidence is present; one study found that the volumes of the lateral pharyngeal walls, tongue and total soft tissue were larger in patients with OSA (31), while a second study found that the tongue, soft palate and lateral pharyngeal wall volume was not significantly different (32). Such lack of agreement indicates that better research with larger

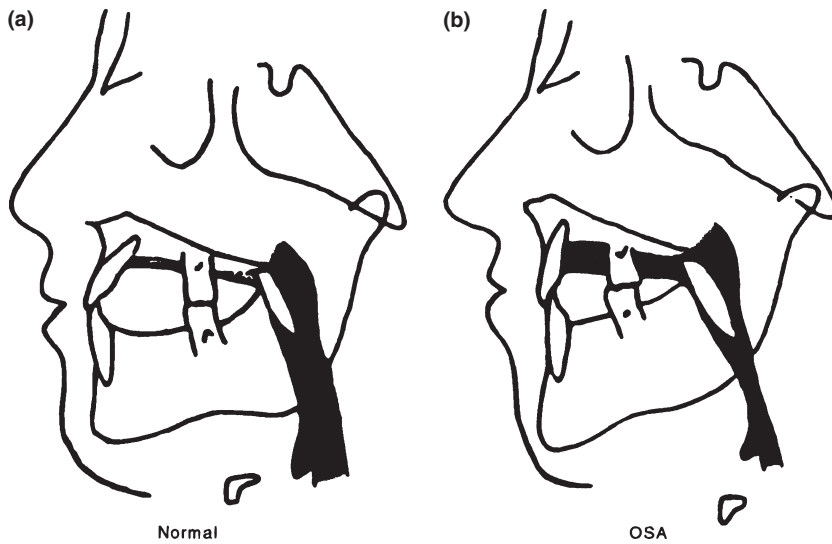


Fig. 4. (a) demonstrates a ‘normal’ airway with normal skeletal positioning of both jaws. (b) shows a patient with a longer face height, mildly deficient jaw position and narrower airway. Reprinted from Cistulli PA. Craniofacial abnormalities in OSA: implications for treatment. *Respirology* 1996;3:167.

sample sizes, more stringent inclusion and exclusion criteria and standardised evaluation parameters is needed.

Cone-beam computed tomography (CBCT) is a recently developed low-dose three-dimensional imaging technique that can generate a scan of the entire head (33). Recent publications have demonstrated that (CBCT) produces extremely accurate anatomical representations (34–36). These imaging modalities also demonstrate diminished airway prior to treatment and the significant changes that occur following successful treatment (37, 38). However, like the MRI studies described earlier, conflicting results have been reported. One study (39) (36 subjects but only 10 controls) concluded that the minimum cross-sectional airway in patients with OSA was smaller than controls. A different study (40) with 40 patients with OSA of mixed gender and 10 controls also of mixed gender found no differences.

Adult treatment modalities

The American Sleep Disorders Association (ASDA) which has been renamed the American Association of Sleep Medicine (AASM) describes eight surgical treatment options and five conservative treatment options for the patient with OSA (Table 2). Following PSG examination and diagnosis, dental professionals trained in the area of sleep medicine can perform the four of the five conservative treatment interventions listed with oral appliance therapy being the most popular and most successful. Of the surgical procedures, genioplasty, mandibular advancement, maxillomandibular

Table 2. Summary of accepted OSA treatment options. Several successful treatment options are provided by dentists or dental specialists

Surgical interventions	Conservative interventions
Tracheostomy	Weight loss
Uvulopalatopharyngeoplasty (UPPP)	Alcohol cessation
Tonsillectomy and Adenoidectomy (T & A)	Altering sleep position
Genial advancement (with or without hyoid myotomy)	Oral appliance
Laser glossectomy and lingualplasty	CPAP
Maxillomandibular advancement (MMA)	
Epiglottoplasty	
Site specific excision	

Surgical interventions in bold are procedures that may be performed by dental specialists such as oral and maxillofacial surgeons.

advancement (MMA) are most frequently performed by the oral and maxillofacial surgeon in collaboration with other dental colleagues. The success of MMA requires interdisciplinary care between orthodontics, prosthodontics, general dentistry, and oral and maxillofacial surgery to provide the best orofacial care for the patient.

Oral appliance therapy

Appliance types. Oral appliances have repeatedly been shown to be an effective form of treatment for mild to

moderate obstructive sleep apnoea and even patients with severe sleep apnoea (AHI > 30) who cannot tolerate CPAP or refuse surgical correction. For patients with severe sleep apnoea, reduction in AHI may be observed but it may not be brought into the normal range. While any decrease is beneficial, if the AHI is not brought below 20 significant long-term health risks are still present.

In the supine position, all gravity-dependent tissues including the tongue tend to fall posteriorly. The tongue base is held anteriorly by the genial tubercles. If this support is insufficient a tongue retaining device can be utilised. To fit a tongue appliance, a piece of dental floss is gently wrapped around the tongue, removed, and measured. The appliance comes in three different sizes (small, medium, and large) and two different styles, (dentate and non-dentate). The appliance bulb is moistened, compressed and the tongue is inserted. The negative pressure and the salivary adhesion act synergistically to maintain the tongue in a more forward position opening the oropharyngeal airway. This class of appliance is not utilised often as most patients find it uncomfortable and compliance is poor.

A second class of appliances actively protrudes the mandible and maintains this forward position during sleep, (See Fig. 5). Several types of appliances are available including the Kleeerway developed by orthodontists, the Tap (and its variations) developed by a prosthodontist and other variations on this theme. Each oral appliance is removable and allows patient insertion at night and removal in the morning. Because the appliance is small compared to CPAP the oral appliances are much more portable; they can even be taken on vacation or other trips away from home. Another advantage is that oral appliance therapy is relatively inexpensive and is entirely reversible. If the patient

does not obtain improvement, no permanent changes have occurred and alternative treatment options can be explored. Selection of the specific advancing appliance can be made using multiple factors including cost, convenience, durability, adjustability, and patient comfort. Because all anterior repositioning appliances function similarly, freedom exists for the patient and dental professional to individually select the appliance that will be the most comfortable. This potentially aids compliance that is essential because like CPAP, if the oral appliance is not worn, improvement cannot be obtained.

Oral appliance fabrication and treatment. To fabricate, upper and lower dental impressions are obtained. The pre-treatment range of motion including maximum opening, left and right lateral excursion, and maximum protrusion are measured. The appliance is constructed using a position approximately one-half to two-thirds of the patient's maximum protrusion and several millimetres open. Custom bite registrations in centric occlusion and the advanced position are obtained. A George gauge can be helpful in stabilizing the patient in the construction bite position. The impressions and bite registrations are either sent to a commercial laboratory for fabrication or made in house. In house appliances are typically more cost effective for the patient and can be delivered more quickly.

Prior to appliance delivery, a lateral cephalometric radiograph is taken in centric occlusion to document the baseline position. This may also be used later to assess possible bite changes as well as documenting the amount of airway opening. At the delivery appointment, appliance fit and comfort are assessed and instructions are given to the patient. Follow-up lateral cephalograph (or CBCT) and polysomnography are




Fig. 5. Sample of oral appliances. (a) Kleeerway appliance. The expansion screw is oriented in a sagittal direction to enable a custom amount of mandibular protrusion to be established for each patient. (b) A custom made mandibular protrusion appliance. The acrylic flange can be augmented or reduced to enable greater or lesser amounts of protrusion to be obtained.

taken after appropriate appliance adjustment/titration and patient adaptation periods. Using lateral cephalometric radiographs, Liu et al. (41) demonstrated a two-dimensional airway change. Haskell et al. (42) followed up with CBCT demonstrating the three-dimensional airway change following oral appliance therapy. However, to appropriately, accurately, and objectively determine the effect oral appliance treatment has on obstructive sleep apnoea it is essential to obtain a follow up sleep study with the appliance in place. Subjectively, patients will nearly universally report positive changes; however, these may not be substantiated in the follow-up polysomnography. If objective improvement is not observed, the patient must be counselled on alternate treatment options to adequately treat their sleep apnoea.

Dental practitioners who provide treatment for OSA must be aware of and comply with the AASM treatment parameters for oral appliances that were first established in 1995. At that time, on the best available evidence were a limited number of case series investigations. As patient care has continued, higher levels of evidence including prospective randomised clinical trials have become available resulting in the 2005 AASM revised practice parameters (43). The AASM's strongest parameter is a *practice standard* that is established only after well-designed prospective randomised clinical studies demonstrate that treatment is beneficial and safe. A *practice guideline* is developed from lower levels of evidence such as case series or prospective studies with high potential bias. *Practice parameters* list treatment possibilities with minimal literature support. The underlying goal of the AASM is to highlight the current evidence and illustrate future research initiatives in order to systematically and continually improve treatment outcomes (44).

Evidence regarding oral appliances. Several case series and prospective studies have been performed, but sample sizes, lack of controls, unclear randomisation methods and other factors make interpretation and application of these investigations difficult. Hoekema (45) published a meta-analysis regarding oral appliance use in 2004. Using a systematic approach with clearly stated inclusion criteria, only 13 of the possible 289 relevant papers were included. Only three mandibular repositioning appliance studies that utilised a prospective randomised design with control patients were available. Each of the three papers demonstrated a positive effect from man-

dibular repositioning appliances; however, the effect size varied (46–48). Pooling the data resulted in a small positive treatment effect. Hoekema concludes that further study including investigations regarding the possible placebo effect must be conducted.

To address these weaknesses, Blanco (49) performed a prospective randomised controlled study. The study compared a mandibular advancement appliance with a control mandibular appliance (similar design but without advancement). One significant study limitation was its small sample size; (twenty four patients started but only 15 completed the study). In addition, only a limited treatment benefit was reported. The AHI in the treatment group declined from 33 to 9.6, while the control group declined unexpectedly from 24 to 11.7. A larger effect was observed in the subjective Epworth Sleep Scale where the treatment group improved from 14.7 to 5.1 compared while the control group failed to demonstrate a significant change (16.3–13.6). Based on this study, it is unclear why the control group experienced positive changes in the AHI; it is possible there was some unintended bite opening or unanticipated change in bite position during sleep.

To improve on these limitations, Petri in 2008 improved both the study design and the study population (50). Petri et al. randomly assigned patients to a mandibular repositioning appliance group, a 'sham' appliance group, and a no treatment group. To investigate for a potential placebo effect, the 'sham' appliance group was compared to both the no treatment group and the treatment group. Ninety-three patients were initially enrolled; twelve were lost in follow-up leaving 81 patients available for analysis. The mandibular repositioning appliance demonstrated a clinically significant improvement in the AHI, the Epworth Sleep scale and the SF-36 quality of life assessment. To attempt to determine the patients most likely to improve, Petri separated the treatment group into moderate (patients with an AHI between 15 and 30) and severe (patients with AHI over 30). Nearly half of both groups experienced a 50% reduction in AHI. Fifty eight per cent of the moderate group improved to an AHI <10, while only twenty-six per cent of the severe group achieved the same goal. One-third of the moderate and one quarter of the severe group were brought into the normal (AHI < 5) range. However, while the mean patient (AHI = 39.1) significantly improved (AHI 25), they were left in the moderate sleep apnoea category. A more modest decline in the Epworth Sleep

Scale (11.7 improving to 8.4) was observed. Neither the control group nor the non-advancing appliance group experienced improvement in AHI demonstrating a lack of placebo effect. In both the Epworth Sleep Scale and SF-36 quality of life surveys, patients reported improvement demonstrating some level of subjective results from these instruments.

Several other studies investigating the effects of oral appliances have been performed. However, although prospective in nature, the studies often compare two treatment appliances that do not include a control population, have a cross-over design, have short study duration, and suffer from small sample sizes.

Because CPAP is currently the 'gold standard' treatment, the effect of mandibular repositioning appliances must be compared with CPAP. When systematic comparisons are performed, CPAP demonstrates more favourable results than oral appliances (45). The greater effect from CPAP is also supported by the 2006 Cochrane Collaboration report that only included controlled randomised studies and specifically excluded pre-post-treatment outcomes and case series publications (consecutive or non-consecutive) (51). Within the report, ten studies compared oral appliances with CPA. The Epworth scale, AHI, arousals, O₂ sat, quality of life indicators and BP were examined as well as cognitive assessment, patient preference, and withdrawals from the study. The summary supports the generally accepted conclusion that CPAP is superior to oral appliances regarding both the AHI and the Epworth Sleepiness scale.

With any type of elective treatment, compliance must be considered. Within the studies selected by the Cochrane Collaboration, larger numbers of patients withdrew from the oral appliance group than the CPAP group. This is in conflict with other surveys, case series, and anecdotal reports that generally state extremely low CPAP compliance. It is likely that this difference results from the study period. The longer the follow-up period, the fewer patients (as low as 30–40%) continue to utilise CPAP. While compliance is a factor with both treatment modalities, patients who experienced a positive treatment effect appeared to prefer the oral appliance over CPAP.

Using the best evidence currently available, it is clear that appropriately performed oral appliance therapy is a viable treatment alternative for patients with mild to moderate sleep apnoea and for patients who are unable or unwilling to comply with CPAP. However, one must also consider the limitations and potential side effects.

Published reports that include individual patient results demonstrate that some patients respond to OA and others do not (52, 53). In addition, dental changes can occur (54, 55). In one study over a 7-year period, 14.3% of oral appliance patients had no dental changes. A large number of patients experienced favourable change (41.4%), while nearly half (44.3%) experienced unfavourable changes in their bite. Favourable change was described as patients with Class II and significant overjet which improved; unfavourable change was observed in Class I patients who developed edge to edge overjet or reverse overjet.

Surgical orthodontic treatment options

While dental appliances work well in patients with mild to moderate obstructive sleep apnoea, they are not universally effective and may not be appropriate in more severe cases. For patients with severe sleep apnoea, who do not desire or cannot tolerate long-term CPAP therapy, oral and maxillofacial surgery in conjunction with orthodontic decompensation is a proven treatment alternative. Historically, a tiered surgical approach has been utilised. Given the nature of surgical therapy, well-controlled clinical studies are difficult to perform. Control subjects are difficult to obtain, subjects may be randomly assigned, but they know whether they have had surgery, and for ethical purposes, 'sham' surgical procedures are inappropriate. Finally, once surgical success is demonstrated, it is no longer ethical to withhold treatment so a patient can serve as a control. As a result, the level of evidence available for making treatment decisions is lower. There are retrospective case series, prospective case series, limited prospective randomised (with randomization of two different types of surgery) studies available. To date, there are no prospective randomised controlled studies available.

Genioplasty. The advancement genioplasty represents a first tier surgical therapy for obstructive sleep apnoea (56). The best candidates have a functional Class I occlusion, good maxillary and mandibular skeletal positioning, but deficient bony chin projection called retrogenia. When severely deficient, it is defined as microgenia. Retrogenia refers only to the size and position of the bony chin; it does not describe the size, shape, or position of the mandible itself. A retrogenic patient may have a normal mandible, a large mandible,

or a small mandible. When the patient has a small mandible and a small chin button, they can be described as retrognathic and retrogenic. Several forms of genioplasty may be performed. Each must assure that the genial tubercles are in the segment that is surgically advanced.

Evidence for genioplasty. The evidence for isolated genioplasty to improve OSA is extremely limited, largely anecdotal, and comes from case reports and limited case series (57). In a 1984 case report, a patient with OSA underwent an inferior border osteotomy to advance the genial segment (though there is no notation of how far), and the patient's OSA improved 'significantly'. Following this study, the authors initiated an investigation utilising genioplasty and hyoid suspension. Of the 239 patients enrolled, only 145 (60%) were successfully treated. While other patients improved, their improvement was insufficient to bring them into the normal range and they were left with inadequate resolution of the OSA. Another drawback is that other investigators have attempted to replicate this centre's results and the isolate genioplasty has fallen out of favour.

Mandibular advancement. Because of the limited success resulting from isolated genioplasty, Bear (58) reported on surgical mandibular advancement. With this type of surgical intervention, the entire body of the mandible is brought forward. When utilised in conjunction with a genioplasty, significantly larger advancements (measured at pogonion) are obtained. Though additional advancement is possible, this approach has limited success and multiple complicating factors. Without presurgical orthodontics, the width of the maxilla is typically too narrow to accommodate the advanced mandible. This forces the surgeon into one of three problematic scenarios. First, the surgeon may continue to advance the mandible into good a sagittal position but a posterior cross bite resulting in undesirable lateral shifts and adverse temporomandibular joint health. Alternatively, the surgeon can advance the patient into both an anterior and a posterior cross bite; i.e. create a significant post-operative malocclusion with diminished orofacial function but good airway. The final problem is the surgeon may not be able to advance the mandible enough to resolve the OSA.

Evidence for mandibular advancement. Other than the initial case report, little evidence is present for isolated

mandibular advancement. In 1990, an investigation was performed on the posterior airspace changes resulting from mandibular advancement surgery (59). In the study, the posterior airway space was measured in 25 adult patients before and after surgical mandibular advancement. The airway change 'generally increased but was variable' indicating that some patients experience greater change than others. None of these patients were diagnosed with OSA, but because of the two-dimensional airway change measured on the radiograph, the authors imply that mandibular advancement may have benefit to patients with OSA.

Maxillomandibular advancement (MMA). Following the failure of other surgical options, MMA, to advance both the maxilla and the mandible was initiated. According to some, this has now become the gold standard in surgical orthodontic care for OSA (60). Multiple case reports and controlled case series available in the literature discuss the benefits of maxillo-mandibular advancement to increase airway patency (6, 61–63).

MMA gives the surgeon the ability to maintain a functional occlusion in Class I patients or enhance the functional occlusion in Class II and Class III patients while simultaneously improving the airway and the profile. Most patients with OSA wish to pursue MMA very quickly to resolve their condition and do not desire the necessary presurgical orthodontic treatment. As a result, one of the risks associated with MMA is post-operative malocclusion. To avoid such complications, the preferred treatment approach addresses the underlying malocclusion first with presurgical orthodontic therapy to obtain complementary maxillary and mandibular dental arches. The orthodontic treatment plan determines where the teeth will be positioned in the respective jaws and the surgical plan determines where each jaw will be positioned relative to the cranial base.

For Class I skeletal and dental patients, similar amounts (typically 10 mm) of maxillary and mandibular surgical advancement are performed. Patients with a Class II malocclusion undergo larger surgical mandibular advancement in order to achieve a Class I dental and skeletal relationship. Because the mandible is advanced further, a wider portion of the mandible will articulate with a narrower portion of the maxilla following surgery. To widen the maxilla, either an initial surgical stage of surgical assist rapid maxillary expansion (SARME) or a segmental LeFort I osteotomy

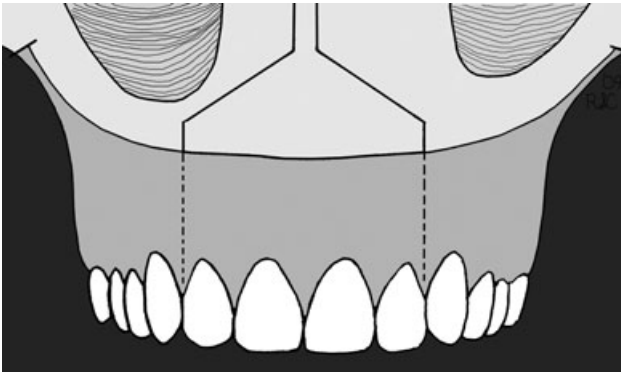


Fig. 6. A schematic drawing of a segmented LeFort I osteotomy. The osteotomy is performed between the maxillary lateral incisors and the maxillary canines in order to obtain both canine and molar expansion. Care must be taken to prevent kinking the gingival pedicle to preserve both tissue and tooth health.

can be performed at the same time as the definitive maxillomandibular advancement surgery (64, 65). When smaller amounts of maxillary widening (5-6 mm) are needed, segmental LeFort I osteotomy can be sufficient. (See Fig. 6) Where larger amounts of expansion are needed (6+ mm) SARME is preferred. (See Fig. 7) Class III patients require larger amounts of maxillary surgical advancement to achieve a Class I occlusion. While Class III patients may present with the maxillary arch completely encompassed by the mandibular arch (bilateral posterior cross bite with an anterior cross bite) following the surgical maxillary advancement, the maxilla may be too wide because a wider portion of the maxilla now articulates with a narrower portion of the mandible. These and several other considerations regarding the surgical orthodontic treatment planning necessary to achieve ideal results are covered more extensively in other publications (66).

CPAP or alternative forms of OSA treatment are used during the presurgical orthodontic phase to reduce the negative effects of OSA. Progress models are taken frequently to assess the presurgical orthodontic preparation. Once complementary arches are obtained, MMA is performed enabling both an improved airway and an improved occlusion to be obtained concurrently. After adequate post-operative healing, a follow-up polysomnography is performed to assure resolution of the OSA. For most patients, the AHI will be back in the normal to mild range (AHI < 10) and CPAP can be discontinued. An unexpected yet beneficial side effect of MMA surgery is most orthognathic surgery patients experience mild weight loss (typically 10 pounds or more) during the immediate post-operative period, which can also contribute to reducing the AHI.

Evidence for MMA. The evidence for MMA comes from case reports, retrospective controlled case series and prospective case series. While overall the evidence reported to date is positive for MMA more work remains. Future well-controlled investigations must be performed to enhance the strength of the evidence for MMA surgery. Surgical centres may have prospective clinical protocols in place for such study but these have not yet been made known.

In one of the earliest MMA case reports, Vila *et al.* (67) describes a patient with severe mandibular deficiency and an AHI of approximately 58. Prior to undergoing the MMA, the patient received a tracheostomy to bypass the airway and resolve the OSA. Following the MMA, the authors report that the patient improved dramatically. A post-operative lateral cephalogram revealed a significantly larger sagittal airway dimension. At post-operative day 15, the tracheostomy tube was removed. Similar case reports are available in

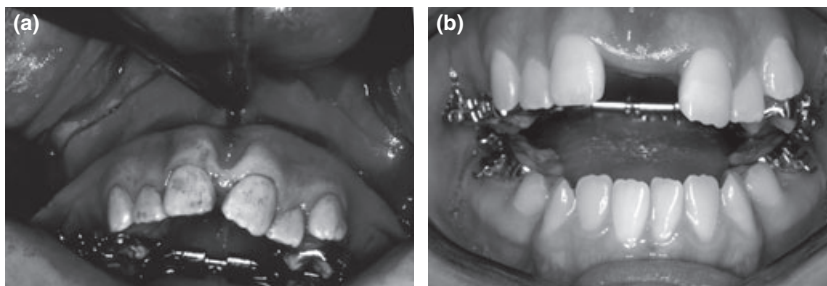


Fig. 7. (a) The intra-operative view of the surgical assist rapid palatal expansion. A circumferential cut is made above the level of the maxillary tooth roots. Finally, the osteotome is placed in the mid-sagittal region to split the suture. (b) demonstrates the significant amount of expansion that can be obtained following activation of the appliance.

the literature indicating the growing popularity of MMA surgical therapy.

One of the earliest retrospective consecutive case series publications examined patients with an AHI > 20, cephalometric evidence of maxillary and/or mandibular retrusion and a diminished posterior airway space were included (61). Each patient was intended to undergo 10 mm MMA 'to secure success,' though no reference is given and it is unclear how 10 mm was selected. In fact, even now, no clear evidence exists that a 10 mm MMA will assure success. Post-operatively, all patients improved; (AHI of 44.9–3.6). Nearly all (20 of the 21) patients improved to an AHI of <10. From these results, the authors postulated that patients should be treated with a definitive MMA rather than a genioplasty or mandibular advancement.

A subsequent case series reports on surgical patients recruited from a large initial pool of 540 patients. A small subset (210) met the cephalometric criteria for MMA; the majority (193) opted for nCPAP, while the rest (15) opted for MMA. In the surgical patients, mean AHI improved (51.4 initially, 5.0 six weeks post-operatively and 8.5 at 2 years post-operatively). Conservative nCPAP patients were treated more effectively (AHI 3.9) at the 2-year time point. Several other studies were published showing high but variable levels of success (68–70).

In a prospective study of 53 patients published in 2000, a tiered surgical approach was used (69). Of the 53 patients originally enrolled, 44 underwent Phase I genioplasty surgery which was further subdivided into two different genioplasty designs that were largely ineffective at resolving the OSA (IA: 24% success IB: 22% success). Phase II surgery (MMA) was successful in 75% of patients (15 of 20). This study illustrates many of the challenges encountered when performing prospective studies. Comparison is made difficult because of the multiple treatment protocols employed. In addition, only 13 of the original 53 patients (25%) went through the entire protocol, which makes drawing meaningful conclusions difficult. Lastly, the criteria used for success were moderate at best requiring either a greater than a 50% decrease in AHI or a post-treatment AHI < 15 which still places patients in the mild OSA category.

Sagittal maxillary and mandibular distraction osteogenesis. Distraction osteogenesis can be performed in the sagittal dimension to achieve even larger advancements

than traditional MMA. One of the advantages of distraction is the patient can undergo a polysomnography during the course of distraction. Distraction can be continued if resolution of the OSA has not occurred or discontinued as soon as success has been achieved. Currently, limited evidence has been published discussing the potential benefits of sagittal distraction osteogenesis. The first report discusses a patient who underwent mandibular distraction osteogenesis first followed by a second stage LeFort I maxillary advancement (71). Polysomnography was conducted after 6 mm of distraction with the results indicating additional advancement was needed. The process was repeated at 12 mm of mandibular distraction and the AHI was reduced to 23. Because the minimum oxygen saturation was brought into the normal range, distraction was stopped. Two months later, the maxilla was advanced to 'a harmonious position'. It is unclear why distraction was utilised in this patient as previous reports have demonstrated successful one stage surgical advancement of 12+mm. A subsequent case report discusses bimaxillary distraction osteogenesis; osteotomies were performed in the maxilla and mandible concurrently and a tracheostomy was performed to assure airway patency. The two jaws were wired together, suspension wires were placed, and distractors were positioned on the mandible bilaterally. At 18 mm of distraction, incomplete resolution of the OSA was observed during polysomnography. Distraction continued for a total of 22 mm of advancement. Follow-up sleep study indicated complete resolution with an AHI of 2.7.

Finally, one limited case series reporting on bimaxillary distraction osteogenesis is presently available. Direct comparison is difficult as different procedures were performed on the five patients. One patient underwent unilateral mandibular distraction, four patients underwent bilateral mandibular distraction, and one patient underwent combined maxillomandibular distraction. All patients improved with the minimum oxygen saturation climbing from 79% to 85% and the RDI decreasing from 49.3 to 6.6 events per hour. It is important to note, the distraction ranged from 5.5 mm to a maximum of 12.5 mm, which is within the range of standard maxillomandibular advancement. With the inherent difficulties involved in distraction osteogenesis over standard LeFort I and BSSO advancements, the advantage of the newer technique is unclear. Should patients require larger

movements, distraction may offer enhanced results. The authors correctly conclude that additional study is required.

Maxillary and mandibular transverse distraction osteogenesis. Reports conflict regarding the size, shape, and form of the dental arches and facies of the average adult obstructive sleep apnoea patient. Anecdotal evidence from case series reported in the literature appears to illustrate a component of transverse deficiency in both jaws. The magnitude of the transverse deficiency varies from patient to patient, with some patients exhibiting extreme narrowness to both jaws. With the reports from the paediatric and adolescent sleep literature demonstrating improvement in OSA resulting from palatal expansion, (see Part II), one must theorise that expansion of the adult dental arches could produce similar improvement. Unfortunately, stable non-surgical skeletal expansion of the maxilla in an adult is not possible. To obtain the necessary expansion, maxillary transverse distraction osteogenesis (previously called surgical assisted rapid maxillary expansion or SARME) is required. Historically, the amount of maxillary expansion that can be achieved has been limited by the mandibular arch because the mandible could not be stably expanded. With the advent of mandibular symphyseal distraction osteogenesis, now expansion of both arches can be considered (72–74). A useful clinical guideline is that the mandible cannot be expanded more than about 10 mm. As a result, if the patient presents with a narrow maxilla and narrow mandible but no cross bite, no more than 10 mm of expansion in both arches should be planned. If however the maxilla and mandible are narrow, and a cross bite exists, then, the mandible can be expanded 10 mm and the maxilla a greater amount. This must be assessed and examined using diagnostic models, an occlusogram, and a PA cephalograph. The PA cephalograph and a set of adolescent and adult normative values can help determine the appropriate size of the maxilla and mandible (75).

Evidence for maxillary and mandibular transverse distraction osteogenesis. A recent case report illustrates the successful incorporation of bimaxillary transverse distraction osteogenesis in combination with maxillomandibular advancement in an adult male with severe obstructive sleep apnoea (76). The pre-treatment RDI of 60 was reduced to a post-treatment RDI of 4. Unfortunately, no

interim sleep study was performed leaving the reader to speculate how much correction resulted from the transverse distraction osteogenesis and how much resulted from the maxillomandibular advancement.

Some recent work involving CBCT, acoustic rhinometry, and posterior–anterior cephalometry has evaluated the airway dimension following surgical assisted rapid palatal expansion (77–79). These reports present conflicting information. The posterior–anterior as well as lateral cephalometry report by Malkoc (78) indicates minimal to no effect on pharyngeal airway dimensions or hyoid positioning in the twenty patients examined. The CBCT evaluation of 38 patients demonstrated increased palatal area, palatal volume, inter-molar distance, and decreased nasal resistance (77). The decrease in nasal resistance was maintained over the remainder of the study period. Unfortunately, the effect of decreased nasal resistance in OSA can only be postulated as none of the study patients underwent polysomnography before or after treatment.

Conclusions

Oral appliance therapy has been investigated the most thoroughly and demonstrates one successful form of treatment that the dentist and dental specialist can provide. Surgical options that combine the care of an orthodontist and an oral and maxillofacial surgeon appear to be more successful, but the evidence levels are still low (case reports, retrospective case series, and controlled prospective case series). While the evidence appears to be good, additional stringent study is required to continue to strengthen the professions role in treating adult patients with OSA.

Part 2: the paediatric and adolescent patient

Diagnosis and classification of paediatric obstructive sleep apnoea

Patients with paediatric sleep apnoea often have more complex medical histories. Because sleep apnoea manifests differently in children, the dental professional should follow up on attention deficit disorder attention deficit and hyperactivity disorder (ADD/ADHD), cor pulmonale, failure to thrive, and mouth breathing (3). The medical history evaluation should also ask questions regarding snoring, nocturnal

gasping, and bed wetting as each are associated with OSA in children.

In the paediatric patient, dental professionals must examine the oropharynx because the primary cause of OSA is tonsillar and adenoid hypertrophy (80). Both the lingual and pharyngeal tonsils will be visible intra-orally but the adenoids will not. Tonsillar size ranges from Type 0 where the tonsils are absent to Type IV where the right and left tonsillar tissues approximate each other in the midline. In the lateral cephalometric radiograph, the tonsils are observed as a moderately radiopaque mass in the region of the mandibular gonial angle while the hypertrophic adenoids appear above the soft palate. (Fig. 8). While lymphatic tissue normally shrinks in volume after the age of six (81) the hypertrophic tonsillar and adenoid tissue may be so large that normal tissue reduction is insufficient to remove the obstruction (Fig. 9). When hypertrophic tonsils are observed clinically or radiographically, referral for endoscopic evaluation and possible surgical removal by a paediatric otolaryngologist should be made. Early removal can reduce the tendency for patients to manifest the anecdotal potential adverse

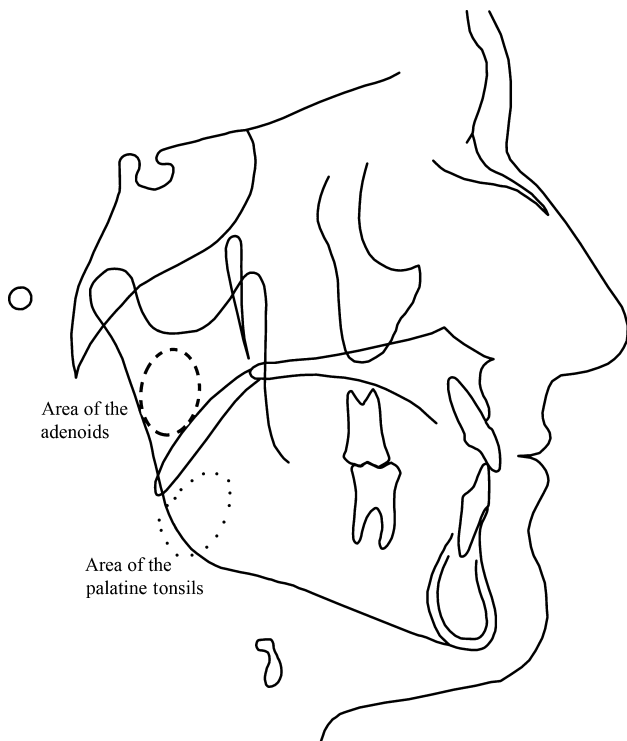


Fig. 8. Lateral cephalometric tracing that includes the adenoids (dashed line) and palatine tonsils (dotted line).

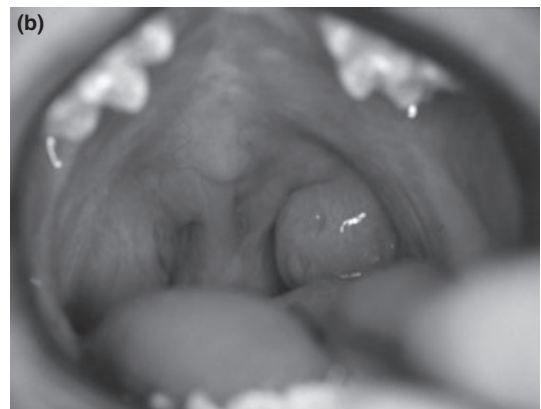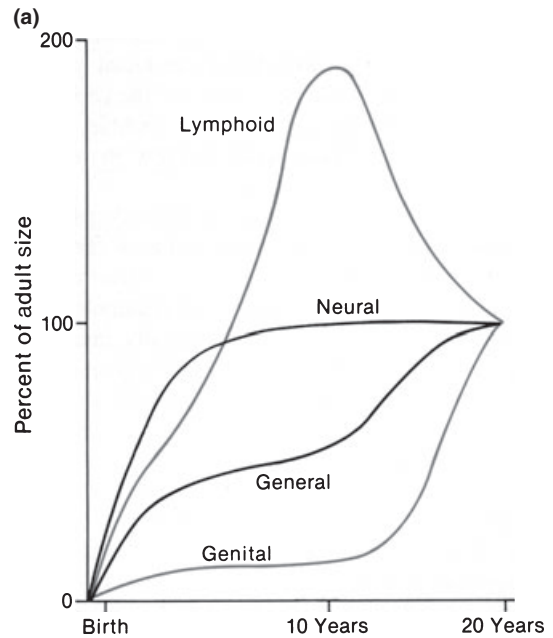


Fig. 9. (a) Scammon's curves demonstrate the different rates of growth of the different tissues in the body. Note the excessive lymphoid tissue overgrowth that shrinks as continued development occurs. It is important to note that the maxilla grows more along the neural growth curve and the mandible follows the general growth curve. Scammons curves. (b) Intra-oral view of a patient with excessive palatine tonsillar tissue. Reprinted from Proffit WR. Later stages of development. In: Proffit WR, Fields HW Jr. and Sarver DM, eds. Contemporary Orthodontics, 4th ed. St. Louis (MO): Elsevier; 2007:108.

long face growth pattern with narrow upper and lower dental arches and anterior open bite (82).

Other potential causes of OSA in the paediatric population are maxillary transverse deficiency and obesity (83, 84). Estimates of overweight and obesity prevalence ranging from one in four to one in three children have been published. This early weight

problem presents at least a two fold problem. First, children are developing OSA much earlier, leading to a lifetime treatment need. Second, the increased childhood weight increases the risk of being overweight or obese as adults.

Craniofacial anomalies can also contribute to paediatric sleep apnoea. These include both severe mandibular deficiency disorders (such as Pierre Robin sequence, Goldenhaar Syndrome), severe maxillary deficiency (Crouzon, Aperts, cleft lip \pm palate) and vertical facial anomalies (Marfans and associated 22q deletion syndromes) (24, 85).

Paediatric OSA treatment modalities

Because paediatric OSA has not been recognised as long as adult OSA, fewer treatment modalities exist. For the treatments that are available, fewer levels of evidence are present. A brief examination of the common treatment methods available to the dentist and dental specialist along with the evidence base follow.

CPAP and its potential craniofacial complications

For the severely affected adolescent patient, CPAP has been advocated. Within the adult population, craniofacial side effects of CPAP have either not been observed or not been reported. Within the paediatric and adolescent population, anecdotal reports of potential growth disturbances from long-term use of CPAP have been reported. Figure 10 shows a patient with sleep apnoea who has been undergoing treatment with CPAP for several years. Unfortunately, she was not observed clinically or radiographically by an orthodontist prior to the CPAP being administered, so it is unclear how much of the malocclusion results from CPAP and how much results from an underlying adverse growth pattern. From a biomechanical standpoint, there is potential validity; the elastic strap that maintains the mask does apply a restraining force on the maxilla not unlike the effect an orthodontic headgear. To adequately answer this question, prospective randomised clinical evaluation needs to be performed. If growth is negatively affected from CPAP, individualised assessment and treatment planning will need to be carried out in order to treat the more serious condition (i.e. the OSA or the malocclusion) and leave definitive treatment of the less serious condition for later.

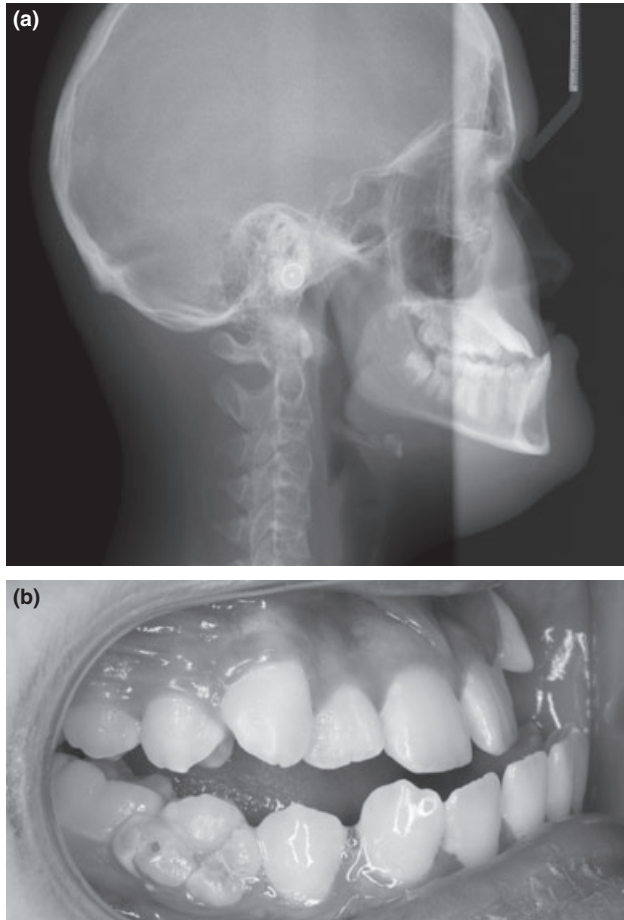


Fig. 10. (a) This lateral cephalometric image of a 12-year 3-month-old female with OSA who has received treatment with CPAP for over 3 years. Note the severe maxillary retrusion. (b) Lateral intraoral view.

Rapid maxillary expansion (RME)

When examining the paediatric or adolescent dentition, attention should be directed first towards the transverse dimension. Many patients with OSA, particularly paediatric patients demonstrate a maxillary transverse deficiency (cross bite) where the upper teeth are too narrow to occlude properly with the mandibular teeth (86, 87). This can present as a single tooth cross bite, a unilateral cross bite where the right or left side is too narrow, or a bilateral cross bite where both sides are too narrow. With the unilateral cross bite, one must determine whether this is a true unilateral cross bite (no shift) or whether the patient has a bilateral cross bite with a lateral shift. In paediatric patients, what appears to be a unilateral cross bite typically is a bilateral cross bite with a shift. To distinguish the two,

one must observe the patient opening and closing. In a bilateral cross bite with a shift, the patient starts in complete cross bite on one side with the lower dental midline deviated to that side. During opening, the lower dental midline will shift back into alignment with the maxillary midline. During closing, one often observes the patient hit prematurely on one side that deflects the jaw. The true unilateral cross bite is rare and when present, the patient bites in cross bite with the midlines off and opens without any noticeable shift. At the fully open position, the midlines will be off the same amount as when biting down.

The presence of a cross bite can be positively or negatively affected by the sagittal bite relationship. In Class II patients (maxillary molar and canine positioned more forward than the mandibular molar and canine), the patient may appear to have appropriate transverse dimension. However when the mandible is positioned more anteriorly to simulate growth or surgical correction, a cross bite can be observed. Conversely, with a Class III malocclusion, the maxilla may appear too narrow, but when the maxilla is brought forward, (or the mandible brought back), the transverse relationship may be adequate. All patients must be examined both in their initial bite position and in the anticipated final sagittal bite position.

Evidence for RME

Recently, several publications provide direct evidence of the positive effects of rapid maxillary expansion in children diagnosed with obstructive sleep apnoea (83, 86, 88–91) (See Fig. 11). Palmisano published the first piece of with Cistulli following up this work with two additional publications (86, 88, 89) Palmisano reported on 10 'young' patients (range 14–37 years old); nine of the patients improved with seven brought into the normal range. One patient had no improvement. Obvious weaknesses of the study include small sample size ($n = 10$), a variety of expansion techniques (six surgical expansion, four non-surgical), patients only had mild to moderate sleep apnoea, and the study combines adolescent and adult patients. The mean canine, premolar, and molar expansion was 5.6, 7.8, and 8.1 mm, respectively. AHI improved from 19.4 to 7 post-expansion. Pirelli (83) addressed several of these limitations by investigating expansion in 31 children. The mean age was 8.68 with a mean pre-treatment AHI of 12.2. The experimental group was stratified into

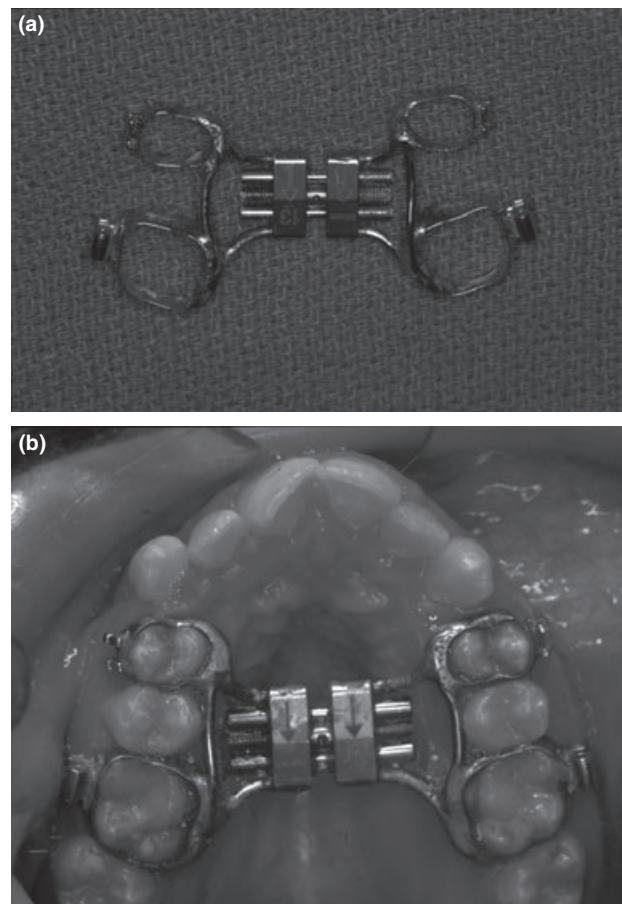


Fig. 11. (a) Rapid maxillary expansion appliance. (b) The same appliance after cementation to the maxillary first molars and first premolars bilaterally.

three categories; AHI of 5–10, 10–15 and 15+ with the largest group in the 10–15 range. Immediately following expansion (mean expansion was 4.32 mm) 29 of the 31 patients had an AHI < 5. At follow-up (6–12 months post-expansion), all patients were brought into the normal range (AHI < 1). The final improvement may have resulted from appliance removal following expansion allowing the tongue greater room. Villa (90) performed a prospective examination of 16 patients (mean age 6.9; range 4.5–10.5) 1 year following the RPE. This study not only examined the effect of expansion but also noted the size of the tonsils. While two patients were lost to follow-up, AHI improved from a mean of 5.8 ± 6.8 at the start to a mean of 2.7 ± 3.5 at 6-month follow-up and ended at 1.5 ± 1.6 at 12-month follow-up even with the presence of enlarged tonsils in 11 of the 14 patients demonstrating that expansion alone can produce significant improvement in

OSA. For the small subset of patients who were not sufficiently corrected, the residual OSA may have been better treated by tonsillectomy following expansion.

In a higher level of evidence, Miano (91) performed the first study to utilise a control group to examine the effect RPE has on the REM and non-REM portion of sleep. One limitation of the study is the small sample (only nine patients available because of 'significant artefacts' present in the polysomnography exams) and the presence of large tonsils. In the RPE group, AHI improved (17.4–5.4) total sleep time improved (393–410 min), but sleep architecture was still altered. Even though the AHI improved the percentage of REM sleep by the OSA patients declined slightly (20.3% to 17%). In addition, even though the total sleep time improved, following expansion, the patients with OSA still slept less than age matched controls (410 min versus 526 min). The likely cause of the lack of 'normalisation' is the incomplete resolution of the OSA (mean AHI post-RPE was 5.4 indicating the presence of significant OSA). The patients whose OSA was not resolved may have benefited from a post-expansion tonsillectomy as well.

The precise mechanism(s) for decreasing obstructive events via rapid maxillary expansion are not fully understood at this time. The improvement may stem from treating multiple causes and multiple sites. As reported in the cephalometric and acoustic rhinometry studies, as the maxilla expands, the palate and floor of the nasal cavity also expand which increases the volume and decreases airflow resistance within the nasal cavity. This expansion also causes statistically significant though clinically small changes in tongue size, tongue position, hyoid position, resulting from the direct expansion of the maxillary dentition (78). This larger upper arch may allow the tongue greater space and allow for more forward positioning of the tongue. Finally, the effect of widening the maxillary basal bone on the velum, the superior pharyngeal constrictors, and the surrounding orofacial musculature can not be under emphasised. Increased muscle tone is impossible to assess radiographically or clinically but could be performed with electromyography (EMG). To date, these studies have not been conducted. Although each component (increased nasal floor, increased upper arch size, and increased muscle tone) may contribute only a small amount to the correction, the combination appears to be clinically significant and tremendously

beneficial to the patient, in the publications reported to date.

Several publications give 'indirect evidence' of the benefit of RPE in the treatment of OSA (77, 78, 92–96). The second group of studies providing indirect evidence utilises various imaging modalities to provide anatomical evidence for increased airway dimensions (77, 78, 93, 96). Additional publications describe the similar effects resulting from surgical assist rapid palatal expansion performed in patients who are more skeletally mature (79, 97, 98). In these studies, lateral cephalometric evaluations, frontal (posterior-anterior) cephalometric evaluation, cone beam computed tomography, or conventional computed tomography are used to make linear and angular measures of the nasal cavity, pharyngeal airway, and the associated structures. The final pair of studies that indirectly suggest RPE may be beneficial in the treatment of OSA utilise acoustic rhinometry to evaluate the functional and volumetric airway changes (94, 95). Two major flaws with all of these 'indirect levels of evidence studies' are none of them were performed on patients with OSA and none of the utilised polysomnography.

Paediatric sagittal growth modification

Evidence for Class II growth modification therapy. It has been well documented in the adult patient with OSA that mandibular anterior repositioning appliances can be quite effective. This success leads one to presume that similar treatment could be effective in the adolescent patient as well. Given the large number of appliances commonly used to advance the mandible for orthodontic purposes (Herbst, Mara, Twin Block, Bionator, Frankel 2, etc), several treatment modalities currently employed by orthodontists could be used for children with obstructive sleep apnoea.

To date, only one study assessing sagittal growth modification in the paediatric OSA population (99). The study strengths are its randomised patient allocation and the use of an untreated control group. Unfortunately, the study has some significant weaknesses including a small sample size (19 treated and 13 controls), large number of patients lost to follow-up, (five treated and four controls) and a low threshold for success. Fortunately, the treated and control group were remarkably similar in height and weight. Some group differences were present (two experimental patients had cross bite). Interestingly, the nine patients

lost to follow-up were the heavier, taller and older patients.

Unlike adult patients, the treated adolescent patients wore the mandibular advancement appliance full time (except when eating) in an attempt to treat both the obstructive sleep apnoea and the deficient mandibular growth. All patients improved and the mean AHI dropped from a pretreatment of 7.1 to a post-treatment of 2.6. Using the low threshold for success of a 50% decrease in AHI, the majority of patients (64%) were successfully treated. Using the more stringent level of success of normalising the AHI, only 50% of patients were successfully treated. While these early results are encouraging, follow-up studies that enrol greater numbers of patients, treat for a longer period of time, and impose more stringent threshold for success must be performed. Lastly, it was not reported whether following the study period these patients would continue to be tracked. If they are not it is unclear whether the improvement gained from treatment will be sustained. In addition, one must remember that treatment with mandibular anterior repositioning appliances in non-OA patients is not 100% successful. In patients where growth modification is successful, at best, the maximum skeletal component of mandibular advancement appliances is approximately 66–75% of the total movement (100). In patients who 'relapse' both the malocclusion and the OSA may return.

One other study offering indirect evidence in Class II mandibular deficient patients presented radiographic evidence of increased airway from a Harvold activator (101). A link between the airway and OSA was presented, but none of the patients treated were known to have OSA as no polysomnography was performed. The authors conclude that because the airway dimensions increased in certain Class II patients, further study is indicated.

Evidence for Class III growth modification therapy. As mentioned earlier, both maxillary and mandibular skeletal deficiency can contribute to OSA in adults and children. One treatment strategy for the young Class III maxillary deficient orthodontic patient is protraction face mask (also known as reverse pull headgear) (102). With this form of treatment, the maxilla is typically widened first with RPE followed immediately by orthopaedic traction to bring the maxilla forward. For small maxillary deficiencies, this form of orthopaedic treatment can be quite successful.

For more severe maxillary deficiencies ($ANB > -6$), protraction is less successful.

Improvement of paediatric OSA from the RPE component of the Class III growth modification therapy has previously been demonstrated. Correction resulting from the protraction head gear is less clear and only indirect evidence is available. Five recent publications report that pharyngeal airway dimensions increase following orthopaedic protraction of the maxilla though each has significant limitations; most notably, polysomnography was not performed in any of the five papers (103–107). Additionally, one paper reports radiographic improvement in airway, though this was not demonstrated in the raw data (103). The improved airway was only observed after multiple regression analysis was performed to 'remove confounding variables' which may not have been appropriate. Finally, many papers evaluating Class III treatment are performed on patients who are relatively young and may outgrow the treatment. Kaygisiz (107) attempts to address this by performing a 4-year follow-up after maxillary protraction growth therapy. In this treatment group, both the positive skeletal and airway changes remained stable over the 4-year evaluation period. However, one must remember from previous Class III growth modifications that not all patients will experience the positive maxillary growth. If growth is not enhanced, airway changes are not likely to be obtained. Unfortunately, until Class III growth modification studies are performed utilising polysomnography the evidence for growth modification in Class III treatment will remain indirect and weak. Its potential, however, should not be discounted especially with the encouraging reports of enhanced protraction with skeletal anchorage that are being reported (108, 109).

Conclusions

OSA has gone from being a largely unknown condition to being a condition that affects multiple medical and dental disciplines. Dental professionals must screen for OSA in both their paediatric and adult new patient examinations. When signs or symptoms of OSA are observed, the dental professional must implement appropriate referrals for definitive diagnosis. Early recognition of mouth breathing and airway obstruction by the paediatric dentist, general dentist, or orthodontist can facilitate early treatment and correction of OSA in the paediatric population. Once OSA is diagnosed,

treatment protocols that have been consistently utilised for orthodontic malocclusion, (RPE, Class II and Class III growth modification), may now be used to resolve OSA. When faced with the adult patient who has signs and symptoms of obstructive sleep apnoea, dental professionals must consult more diligently with their medical colleagues. Sleep studies must be considered when making treatment decisions. Sound dental and medical treatment decisions as outlined earlier can be the 'ounce of prevention that is worth a pound of cure'.

References

- Young T, Palta M, Dempsey J, Skatrud J, Weber S, Badr S. The occurrence of sleep-disordered breathing among middle-aged adults. *N Eng J Med*. 1993;328:1230–1235.
- Strollo PJ Jr, Rogers RM. Obstructive sleep apnea. *N Eng J Med*. 1996;334:99–104.
- Marcus CL. Sleep-disordered breathing in children. *Am J Respir Crit Care Med*. 2001;164:16–30.
- Smith R, Ronald J, Delaive K, Walld R, Manfreda J, Kryger MH. What are obstructive sleep apnea patients being treated for prior to this diagnosis? *Chest*. 2002;121:164–172.
- Coleman JA Jr. Laser-assisted uvulopalatoplasty: long-term results with a treatment for snoring. *Ear Nose Throat J* 1998;77: 22–24, 6–9, 32–4.
- Prinsell JR. Maxillomandibular advancement surgery for obstructive sleep apnea syndrome. *J Am Dent Assoc* (1939). 2002;133:1489–1497.
- Sanders MH, Moore SE, Eveslage J. CPAP via nasal mask: a treatment for occlusive sleep apnea. *Chest*. 1983;83:144–145.
- Scrima L, Broudy M, Nay KN, Cohn MA. Increased severity of obstructive sleep apnea after bedtime alcohol ingestion: diagnostic potential and proposed mechanism of action. *Sleep*. 1982;5:318–328.
- Smith PL, Gold AR, Meyers DA, Haponik EF, Bleecker ER. Weight loss in mildly to moderately obese patients with obstructive sleep apnea. *Ann Intern Med*. 1985;103: 850–855.
- Campos-Rodriguez F, Pena-Grinan N, Reyes-Nunez N, De la Cruz-Moron I, Perez-Ronchel J, De la Vega-Gallardo F *et al*. Mortality in obstructive sleep apnea-hypopnea patients treated with positive airway pressure. *Chest*. 2005;128: 624–633.
- Lavie P, Lavie L, Herer P. All-cause mortality in males with sleep apnoea syndrome: declining mortality rates with age. *Eur Respir J*. 2005;25:514–520.
- Marti S, Sampol G, Munoz X, Torres F, Roca A, Lloberes P *et al*. Mortality in severe sleep apnoea/hypopnoea syndrome patients: impact of treatment. *Eur Respir J*. 2002;20: 1511–1518.
- Milleron O, Pilliere R, Foucher A, de Roquefeuil F, Aegerter P, Jondeau G *et al*. Benefits of obstructive sleep apnoea treatment in coronary artery disease: a long-term follow-up study. *Eur Heart J*. 2004;25:728–734.
- Johns MW. A new method for measuring daytime sleepiness: the Epworth sleepiness scale. *Sleep*. 1991;14: 540–545.
- Chesson AL Jr, Ferber RA, Fry JM, Grigg-Damberger M, Hartse KM, Hurwitz TD *et al*. The indications for polysomnography and related procedures. *Sleep*. 1997;20: 423–487.
- Flemmons WW, Buysse D, Redline S. Sleep-related breathing disorders in adults: recommendations for syndrome definition and measurement techniques in clinical research. The Report of an American Academy of Sleep Medicine Task Force. *Sleep*. 1999;22:667–689.
- Young T, Finn L, Peppard PE, Szklo-Coxe M, Austin D, Nieto FJ *et al*. Sleep disordered breathing and mortality: eighteen-year follow-up of the Wisconsin sleep cohort. *Sleep*. 2008;31:1071–1078.
- Abad VC, Guilleminault C. Neurological perspective on obstructive and nonobstructive sleep apnea. *Semin Neurol*. 2004;24:261–269.
- Veale D, Chailleux E, Hoorelbeke-Ramon A, Reybet-Degas O, Humeau-Chapuis MP, Alluin-Aigouy F *et al*. Mortality of sleep apnea patients treated by nasal continuous positive airway pressure registered in the ANTADIR observatory. Association Nationale pour le Traitement A Domicile de l'Insuffisance Respiratoire chronique. *Eur Respir J*. 2000;15:326–331.
- George CF. Reduction in motor vehicle collisions following treatment of sleep apnoea with nasal CPAP. *Thorax*. 2001;56:508–512.
- Horne JA, Reyner LA. Sleep related vehicle accidents. *BMJ* (Clinical research ed.). 1995;310:565–567.
- Burstone CJ, James RB, Legan H, Murphy GA, Norton LA. Cephalometrics for orthognathic surgery. *J Oral Surg*. 1978;36:269–277.
- Wittenborn W, Panchal J, Marsh JL, Sekar KC, Gurley J. Neonatal distraction surgery for micrognathia reduces obstructive apnea and the need for tracheotomy. *J Craniofac Surg*. 2004;15:623–630.
- Cistulli PA, Sullivan CE. Sleep apnea in Marfan's syndrome. Increased upper airway collapsibility during sleep. *Chest*. 1995;108:631–635.
- Riley R, Guilleminault C, Herran J, Powell N. Cephalometric analyses and flow-volume loops in obstructive sleep apnea patients. *Sleep*. 1983;6:303–311.
- Fleisher KE, Krieger AC. Current trends in the treatment of obstructive sleep apnea. *J Oral Maxillofac Surg*. 2007;65:2056–2068.
- Lowe AA, Santamaria JD, Fleetham JA, Price C. Facial morphology and obstructive sleep apnea. *Am J Orthod Dentofacial Orthop*. 1986;90:484–491.
- Tsuchiya M, Lowe AA, Pae EK, Fleetham JA. Obstructive sleep apnea subtypes by cluster analysis. *Am J Orthod Dentofacial Orthop*. 1992;101:533–542.
- Tangugorn V, Skatvedt O, Krogstad O, Lyberg T. Obstructive sleep apnoea: a cephalometric study. Part II. Uvulo-glossopharyngeal morphology. *Eur J Orthod*. 1995;17:57–67.

30. Cistulli PA. Craniofacial abnormalities in obstructive sleep apnoea: implications for treatment. *Respirology* (Carlton, Vic.). 1996;1:167–174.
31. Schwab RJ, Pasirstein M, Pierson R, Mackley A, Hachadoorian R, Arens R *et al.* Identification of upper airway anatomic risk factors for obstructive sleep apnea with volumetric magnetic resonance imaging. *Am J Respir Crit Care Med.* 2003;168:522–530.
32. Okubo M, Suzuki M, Horiuchi A, Okabe S, Ikeda K, Higano S *et al.* Morphologic analyses of mandible and upper airway soft tissue by MRI of patients with obstructive sleep apnea hypopnea syndrome. *Sleep.* 2006;29:909–915.
33. Maki K, Inou N, Takinishi A, Miller AJ. Computer-assisted simulations in orthodontic diagnosis and the application of a new cone beam X-ray computed tomography. *Orthod Craniofac Res.* 2003;6 (Suppl 1): 95–101; discussion 79–82.
34. Aboudara C, Nielsen I, Huang JC, Maki K, Miller AJ, Hatcher D. Comparison of airway space with conventional lateral headfilms and 3-dimensional reconstruction from cone-beam computed tomography. *Am J Orthod Dentofacial Orthop.* 2009;135:468–479.
35. Ludlow JB, Gubler M, Cevidanes L, Mol A Precision of cephalometric landmark identification: cone-beam computed tomography vs conventional cephalometric views. *Am J Orthod Dentofacial Orthop.* 2009;136: 312 e1–10; discussion -3.
36. Schendel SA, Hatcher D. Automated 3-dimensional airway analysis from cone-beam computed tomography data. *J Oral Maxillofac Surg.* 2010;68:696–701.
37. Fairburn SC, Waite PD, Vilos G, Harding SM, Bernreuter W, Cure J *et al.* Three-dimensional changes in upper airways of patients with obstructive sleep apnea following maxillomandibular advancement. *J Oral Maxillofac Surg.* 2007;65:6–12.
38. Ogawa T, Enciso R, Shintaku WH, Clark GT. Evaluation of cross-section airway configuration of obstructive sleep apnea. *Oral Surg Oral Med Oral Pathol Oral Radiol Endod.* 2007;103:102–108.
39. Avrahami E, Englander M. Relation between CT axial cross-sectional area of the oropharynx and obstructive sleep apnea syndrome in adults. *AJNR Am J Neuroradiol.* 1995;16: 135–140.
40. Bhattacharyya N, Blake SP, Fried MP. Assessment of the airway in obstructive sleep apnea syndrome with 3-dimensional airway computed tomography. *Otolaryngol Head Neck Surg.* 2000;123:444–449.
41. Liu Y, Zeng X, Fu M, Huang X, Lowe AA. Effects of a mandibular repositioner on obstructive sleep apnea. *Am J Orthod Dentofacial Orthop.* 2000;118:248–256.
42. Haskell JA, McCrillis J, Haskell BS, Scheetz JP, Scarfe WC, Farman AG. Effects of mandibular advancement device (MAD) on airway dimensions assessed with cone-beam computed tomography. *Semin Orthod.* 2009;15:132–158.
43. Kushida CA, Morgenthaler TI, Littner MR, Alessi CA, Bailey D, Coleman J Jr *et al.* Practice parameters for the treatment of snoring and Obstructive Sleep Apnea with oral appliances: an update for 2005. *Sleep.* 2006;29:240–243.
44. Eddy DM. A manual for assessing health practices and designing practice policies: the explicit approach. Philadelphia, PA: American College of Physicians, 1992.
45. Hoekema A, Stegenga B, De Bont LG. Efficacy and comorbidity of oral appliances in the treatment of obstructive sleep apnea-hypopnea: a systematic review. *Crit Rev Oral Biol Med.* 2004;15:137–155.
46. Mehta A, Qian J, Petocz P, Darendeliler MA, Cistulli PA. A randomized, controlled study of a mandibular advancement splint for obstructive sleep apnea. *Am J Respir Crit Care Med.* 2001;163:1457–1461.
47. Gotsopoulos H, Chen C, Qian J, Cistulli PA. Oral appliance therapy improves symptoms in obstructive sleep apnea: a randomized, controlled trial. *Am J Respir Crit Care Med.* 2002;166:743–748.
48. Johnston CD, Gleadhill IC, Cinnamon MJ, Gabbey J, Burden DJ. Mandibular advancement appliances and obstructive sleep apnoea: a randomized clinical trial. *Eur J Orthod.* 2002;24:251–262.
49. Blanco J, Zamarron C, Abeleira Pazos MT, Lamela C, Suarez Quintanilla D. Prospective evaluation of an oral appliance in the treatment of obstructive sleep apnea syndrome. *Sleep Breath.* 2005;9:20–25.
50. Petri N, Svanholt P, Solow B, Wildschiodtz G, Winkel P. Mandibular advancement appliance for obstructive sleep apnoea: results of a randomised placebo controlled trial using parallel group design. *J Sleep Res.* 2008;17:221–229.
51. Lim J, Lasserson TJ, Fleetham J, Wright J. Oral appliances for obstructive sleep apnoea. *Cochrane Database Syst Rev.* 2006; p. Art. No.: CD004435.pub3.
52. Otsuka R, Almeida FR, Lowe AA, Ryan F. A comparison of responders and nonresponders to oral appliance therapy for the treatment of obstructive sleep apnea. *Am J Orthod Dentofacial Orthop.* 2006;129:222–229.
53. Hoekema A, Doff MH, de Bont LG, van der Hoeven JH, Wijkstra PJ, Pasma HR *et al.* Predictors of obstructive sleep apnea-hypopnea treatment outcome. *J Dent Res.* 2007;86:1181–1186.
54. Almeida FR, Lowe AA, Otsuka R, Fastlicht S, Farbood M, Tsuike S. Long-term sequelae of oral appliance therapy in obstructive sleep apnea patients: Part 2. Study-model analysis. *Am J Orthod Dentofacial Orthop.* 2006;129:205–213.
55. Almeida FR, Lowe AA, Sung JO, Tsuike S, Otsuka R. Long-term sequelae of oral appliance therapy in obstructive sleep apnea patients: Part 1. Cephalometric analysis. *Am J Orthod Dentofacial Orthop.* 2006;129:195–204.
56. Riley RW, Powell NB, Guilleminault C. Obstructive sleep apnea syndrome: a review of 306 consecutively treated surgical patients. *Otolaryngol Head Neck Surg.* 1993;108: 117–125.
57. Riley R, Guilleminault C, Powell N, Derman S. Mandibular osteotomy and hyoid bone advancement for obstructive sleep apnea: a case report. *Sleep.* 1984;7:79–82.
58. Bear S, Priest J. Sleep apnoea syndrome: correction with surgical advancement of the mandible. *J Oral Surg.* 1980;38:543–549.

59. Farole A, Mundenar MJ, Braitman LE. Posterior airway changes associated with mandibular advancement surgery: implications for patients with obstructive sleep apnea. *Int J Adult Orthodon Orthognath Surg.* 1990;5:255–258.
60. Waite PD, Shettar SM. Maxillomandibular advancement: a cure for obstructive sleep apnea. *Oral Maxillofac Surg Clin North Am.* 1995;7:327.
61. Hochban W, Brandenburg U, Peter JH. Surgical treatment of obstructive sleep apnea by maxillomandibular advancement. *Sleep.* 1994;17:624–629.
62. Prinsell JR. Maxillomandibular advancement surgery for obstructive sleep apnea. *J Med Assoc Ga.* 2000;89:54–57.
63. Waite PD, Wooten V, Lachner J, Guyette RF. Maxillomandibular advancement surgery in 23 patients with obstructive sleep apnea syndrome. *J Oral Maxillofac Surg.* 1989;47:1256–1261; discussion 62.
64. Bell WH, Epker BN. Surgical-orthodontic expansion of the maxilla. *Am J Orthod.* 1976;70:517–528.
65. Jacobs JD, Bell WH, Williams CE, Kennedy JW III. Control of the transverse dimension with surgery and orthodontics. *Am J Orthod.* 1980;77:284–306.
66. Conley RS, Legan HL. Role of orthodontics in obstructive sleep apnea. In: Nanda R, Kapila SK, eds. *Current therapy in orthodontics.* St. Louis: Elsevier; 2009.
67. Vila CN, Sanz JA, Robredo JMB, Martin JJM, Rodriguez JMM, Agreda JML. Sleep Apnea Syndrome in an adult patient with mandibular hypoplasia. *Int J Oral Maxillofac Surg.* 1989;18:32–34.
68. Prinsell JR. Maxillomandibular advancement surgery in a site-specific treatment approach for obstructive sleep apnea in 50 consecutive patients. *Chest.* 1999;116:1519–1529.
69. Bettega G, Pepin JL, Veale D, Deschaux C, Raphael B, Levy P. Obstructive sleep apnea syndrome. fifty-one consecutive patients treated by maxillofacial surgery. *Am J Respir Crit Care Med.* 2000;162:641–649.
70. Dekeister C, Lacassagne L, Tiberge M, Montemayor T, Miguères M, Paoli JR. [Mandibular advancement surgery in patients with severe obstructive sleep apnea uncontrolled by continuous positive airway pressure. A retrospective review of 25 patients between 1998 and 2004]. *Rev Mal Respir.* 2006;23:430–437.
71. Paoli JR, Lauwers F, Lacassagne L, Tiberge M. Treatment of obstructive sleep apnea syndrome by mandibular elongation using osseous distraction followed by a Le Fort I advancement osteotomy: case report. *J Oral Maxillofac Surg.* 2001;59:216–219.
72. Conley R, Legan H. Mandibular symphyseal distraction osteogenesis: diagnosis and treatment planning considerations. *Angle Orthod.* 2003;73:3–11.
73. Guerrero CA, Bell WH, Contasti GI, Rodriguez AM. Mandibular widening by intraoral distraction osteogenesis. *Br J Oral Maxillofac Surg.* 1997;35:383–392.
74. Guerrero CA, Bell WH, Contasti GI, Rodriguez AM. Intraoral mandibular distraction osteogenesis. *Semin Orthod.* 1999;5:35–40.
75. Betts NJ, Vanarsdall RL, Barber HD, Higgins-Barber K, Fonseca RJ. Diagnosis and treatment of transverse maxillary deficiency. *Int J Adult Orthodon Orthognath Surg.* 1995;10:75–96.
76. Conley RS, Legan HL. Correction of severe obstructive sleep apnea with bimaxillary transverse distraction osteogenesis and maxillomandibular advancement. *Am J Orthod Dentofacial Orthop.* 2006;129:283–292.
77. Oliveira De Felipe NL, Da Silveira AC, Viana G, Kusnoto B, Smith B, Evans CA. Relationship between rapid maxillary expansion and nasal cavity size and airway resistance: short- and long-term effects. *Am J Orthod Dentofacial Orthop.* 2008;134:370–382.
78. Malkoc S, Usumez S, Iseri H. Long-term effects of symphyseal distraction and rapid maxillary expansion on pharyngeal airway dimensions, tongue, and hyoid position. *Am J Orthod Dentofacial Orthop.* 2007;132:769–775.
79. Baraldi CE, Pretto SM, Puricelli E. Evaluation of surgically assisted maxillary expansion using acoustic rhinometry and postero-anterior cephalometry. *Int J Oral Maxillofac Surg.* 2007;36:305–309.
80. Friedman M, Tanyeri H, La Rosa M, Landsberg R, Vaidyanathan K, Pieri S *et al.* Clinical predictors of obstructive sleep apnea. *Laryngoscope.* 1999;109:1901–1907.
81. Scammon R. The Measurement of the body in childhood. In: Harris J, ed. *The measurement of man.* Minneapolis: University of Minnesota Press; 1930.
82. Harvold EP, Tomer BS, Vargervik K, Chierici G. Primate experiments on oral respiration. *Am J Orthod.* 1981;79:359–372.
83. Pirelli P, Saponara M, Guilleminault C. Rapid maxillary expansion in children with obstructive sleep apnea syndrome. *Sleep.* 2004;27:761–766.
84. Hedley AA, Ogden CL, Johnson CL, Carroll MD, Curtin LR, Flegal KM. Prevalence of overweight and obesity among US children, adolescents, and adults, 1999–2002. *JAMA.* 2004;291:2847–2850.
85. Hoch B, Hochban W. Four-year-old girl with Goldenhar-sequence and severe obstructive sleep apnea, symptoms, diagnosis and therapy. *Int J Pediatr Otorhinolaryngol.* 1998;43:277–281.
86. Cistulli PA, Palmisano RG, Poole MD. Treatment of obstructive sleep apnea syndrome by rapid maxillary expansion. *Sleep.* 1998;21:831–835.
87. Cistulli PA, Richards GN, Palmisano RG, Unger G, Sullivan CE. Maxillary Morphology in obstructive sleep apnea syndrome. [abstract]. *Am J Respir Crit Care Med.* 1997;155:A418.
88. Palmisano RG, Wilcox I, Sullivan CE, Cistulli PA. Treatment of snoring and obstructive sleep apnoea by rapid maxillary expansion. *Aust N Z J Med.* 1996;26:428–429.
89. Cistulli PA. Rapid maxillary expansion in obstructive sleep apnea – hope on the horizon? *Sleep.* 2004;27:606–607.
90. Villa MP, Malagola C, Pagani J, Montesano M, Rizzoli A, Guilleminault C *et al.* Rapid maxillary expansion in children with obstructive sleep apnea syndrome: 12-month follow-up. *Sleep Med.* 2007;8:128–134.
91. Miano S, Rizzoli A, Evangelisti M, Bruni O, Ferri R, Pagani J *et al.* NREM sleep instability changes following rapid

- maxillary expansion in children with obstructive apnea sleep syndrome. *Sleep Med.* 2009;10:471–478.
92. Timms DJ. Rapid maxillary expansion in the treatment of nocturnal enuresis. *Angle Orthod.* 1990;60:229–233. discussion 34.
 93. Buccheri A, Dilella G, Stella R. Rapid palatal expansion and pharyngeal space. *Cephalometric evaluation. Prog Orthod.* 2004;5:160–171.
 94. Compadretti GC, Tasca I, Bonetti GA. Nasal airway measurements in children treated by rapid maxillary expansion. *Am J Rhinol.* 2006;20:385–393.
 95. Doruk C, Sokucu O, Bicakci AA, Yilmaz U, Tas F. Comparison of nasal volume changes during rapid maxillary expansion using acoustic rhinometry and computed tomography. *Eur J Orthod.* 2007;29:251–255.
 96. Palaisa J, Ngan P, Martin C, Razmus T. Use of conventional tomography to evaluate changes in the nasal cavity with rapid palatal expansion. *Am J Orthod Dentofacial Orthop.* 2007;132:458–466.
 97. Koudstaal MJ, Poort LJ, van der Wal KG, Wolvius EB, Prahlandersen B, Schulten AJ. Surgically assisted rapid maxillary expansion (SARME): a review of the literature. *Int J Oral Maxillofac Surg.* 2005;34:709–714.
 98. Babacan H, Sokucu O, Doruk C, Ay S. Rapid maxillary expansion and surgically assisted rapid maxillary expansion effects on nasal volume. *Angle Orthod.* 2006;76:66–71.
 99. Villa MP, Bernkopf E, Pagani J, Broia V, Montesano M, Ronchetti R. Randomized controlled study of an oral jaw-positioning appliance for the treatment of obstructive sleep apnea in children with malocclusion. *Am J Respir Crit Care Med.* 2002;165:123–127.
 100. Ruf S, Pancherz H. Dentoskeletal effects and facial profile changes in young adults treated with the Herbst appliance. *Angle Orthod.* 1999;69:239–246.
 101. Ozbek MM, Memikoglu TU, Gogen H, Lowe AA, Baspinar E. Oropharyngeal airway dimensions and functional-orthopedic treatment in skeletal Class II cases. *Angle Orthod.* 1998;68:327–336.
 102. Kapust AJ, Sinclair PM, Turley PK. Cephalometric effects of face mask/expansion therapy in Class III children: a comparison of three age groups. *Am J Orthod Dentofacial Orthop.* 1998;113:204–212.
 103. Hiyama S, Suda N, Ishii-Suzuki M, Tsuiki S, Ogawa M, Suzuki S *et al.* Effects of maxillary protraction on craniofacial structures and upper-airway dimension. *Angle Orthod.* 2002;72:43–47.
 104. Kilinc AS, Arslan SG, Kama JD, Ozer T, Dari O. Effects on the sagittal pharyngeal dimensions of protraction and rapid palatal expansion in Class III malocclusion subjects. *Eur J Orthod.* 2008;30:61–66.
 105. Oktay H, Ulukaya E. Maxillary protraction appliance effect on the size of the upper airway passage. *Angle Orthod.* 2008;78:209–214.
 106. Sayinsu K, Isik F, Arun T. Sagittal airway dimensions following maxillary protraction: a pilot study. *Eur J Orthod.* 2006;28:184–189.
 107. Kaygisiz E, Tuncer BB, Yuksel S, Tuncer C, Yildiz C. Effects of maxillary protraction and fixed appliance therapy on the pharyngeal airway. *Angle Orthod.* 2009;79:660–667.
 108. Cornelis MA, Scheffler NR, Mahy P, Siciliano S, De Clerck HJ, Tulloch JF. Modified miniplates for temporary skeletal anchorage in orthodontics: placement and removal surgeries. *J Oral Maxillofac Surg.* 2008;66:1439–1445.
 109. Heymann GC, Cevidanes L, Cornelis M, De Clerck HJ, Tulloch JF. Three-dimensional analysis of maxillary protraction with intermaxillary elastics to miniplates. *Am J Orthod Dentofacial Orthop.* 2010;137:274–284.

Correspondence: R. S. Conley, University of Michigan School of Dentistry, Department of Orthodontics and Pediatric Dentistry, 1011 N. University Avenue, Room 1510C, Ann Arbor, MI 48109-1078, USA. E-mail: rskonley@umich.edu