

Microcomputed Tomographic Analysis of the Alveolar Ridge Alteration around Extraction Sites with and without Immediate Implants Placement: In Vivo Study

Khalid Al-Hezaimi, MSc;* Munirah Saleh Al-Shabeeb, MSc;† Mansour Al-Askar, MSc;‡ Fawad Javed, PhD;§ Nasser Nooh, DSc;¶ Abdulaziz Al-Rasheed, MSc;*** Nadir Babay, MSc;†† Khalid Saleh Al-Hamdan, MSc;‡‡ Hom Lay Wang, PhD§§

ABSTRACT

Background: The aim was to assess the alveolar ridge alteration around extraction sites with and without immediate implants according to extraction socket classification (ESC) using microcomputed tomography (micro-CT).

Material and Methods: Ten beagle dogs (mean age and weight: 24 ± 0.83 months and 13.8 ± 0.49 kg, respectively) were randomly divided into three groups according to the ESC. In Group 1 (ESC-I), bilateral first and third premolars were extracted and replaced with immediate implants. In Group 2 (ESC-II), two adjacent premolars were extracted with one immediate implant placement in the mesial socket in the maxilla and in the distal socket in the mandible. In Group 3 (ESC-III), three adjacent teeth were extracted and an immediate implant was placed in the central socket. Primary closure was achieved using resorbable sutures. Buccal sites with dehiscence defects were excluded. After 4 months, subjects were sacrificed and alveolar ridge widths were measured at 1 mm interval in axial and sagittal views, using micro-CT in sites with and without immediate implants.

Results: In sites without immediate implant placement, alveolar ridge width was significantly higher in Group 1 (6.1 ± 1.35 mm) than Group 3 (4.14 ± 1.53 mm) ($p < .05$). In sites with immediate implant placement, the alveolar ridge width was higher among sites in Group 1 (6.4 ± 3.8 mm) than Group 2 (4.8 ± 0.46 mm) ($p < .05$) and Group 3 (5.02 ± 0.84 mm) ($p < .05$). Overall, between each corresponding group in both sites with and without immediate implant placement at 1 mm thickness, there was no significant difference in the alveolar ridge widths.

*Assistant Professor, Micro-CT and Biomechanics Laboratories, College of Applied Medical Sciences, King Saud University, Riyadh, Saudi Arabia; and Eng. A.B. Research Chair for Growth Factors and Bone Regeneration, Dept. of Periodontics and Community Dentistry, College of Dentistry, King Saud University, Riyadh, Saudi Arabia; †research associate, Eng. A.B. Research Chair for Growth Factors and Bone Regeneration, Dept. of Periodontics and Community Dentistry, College of Dentistry, King Saud University, Riyadh, Saudi Arabia; ‡research associate, Eng. A.B. Research Chair for Growth Factors and Bone Regeneration, Dept. of Periodontics and Community Dentistry, College of Dentistry, King Saud University, Riyadh, Saudi Arabia; §research associate, Micro-CT and Biomechanics Laboratories, College of Applied Medical Sciences, King Saud University, Riyadh, Saudi Arabia; and Eng. A.B. Research Chair for Growth Factors and Bone Regeneration, Dept. of Periodontics and Community Dentistry, College of Dentistry, King Saud University, Riyadh, Saudi Arabia; ¶associate professor, Eng. A.B. Research Chair for Growth Factors and Bone Regeneration, and Dept. of Oral and Maxillofacial Surgery, King Saud University, Riyadh, Saudi Arabia; ***associate professor, Eng. A.B. Research Chair for Growth Factors and Bone Regeneration, College of Applied Medical Sciences, King Saud University, Riyadh, Saudi Arabia; and Dept. of Periodontics and Community Dentistry, King Saud University, Riyadh, Saudi Arabia; ††Eng. A.B. Research Chair for Growth Factors and Bone Regeneration, College of Applied Medical Sciences, King Saud University, Riyadh, Saudi Arabia; and Dept. of Periodontics and Community Dentistry, King Saud University, Riyadh, Saudi Arabia; ‡‡associate professor, Eng. A.B. Research Chair for Growth Factors and Bone Regeneration, Dept. of Periodontics and Community Dentistry, College of Dentistry, King Saud University, Riyadh, Saudi Arabia; §§professor, Eng. A.B. Research Chair for Growth Factors and Bone Regeneration, Dept. of Periodontics and Community Dentistry, College of Dentistry, King Saud University, Riyadh, Saudi Arabia; and Dept. of Periodontics and Oral Medicine, School of Dentistry, University of Michigan, Ann Arbor, MI, USA

Reprint requests: Dr. Khalid Al-Hezaimi, Engineer Abdullah Bugshan Research Chair for Growth Factors and Bone Regeneration, College of Applied Medical Sciences, King Saud University, PO Box 60169, Riyadh 11545, Saudi Arabia; e-mail: hezaimik16@gmail.com

Conflict of interest and financial disclosure: The authors declare that they have no conflict of interest and there was no external source of funding for the present study.

© 2012 Wiley Periodicals, Inc.

DOI 10.1111/j.1708-8208.2012.00471.x

Conclusion: With the exception of Group 1 (ESC-I), immediate implant placement did not prevent or minimize bone remodeling in extraction sites according to ESC.

KEY WORDS: alveolar bone remodeling, extraction socket classification, immediate implants

INTRODUCTION

Tooth extraction is a traumatic procedure that jeopardizes the surrounding alveolar bone and soft tissues. Healing of the extraction socket involves several biochemical and histologic events that may alter alveolar bone architecture.¹⁻⁶ It is known that by the fourth week of extraction, the extraction socket fills with bundle bone (an immature bone that is supplied entirely and solely by ligaments and tendons).³⁻⁵ Because the buccal process of alveolar bone is entirely composed of bundle bone, it is more susceptible to undergo resorption as compared with the palatal or lingual process.³

In a recent histologic study on baboons, an extraction socket classification (ESC) was proposed.⁵ This study was based on the histologic finding that the buccal bone receives an essential share of its vascular supply from interdental blood vessels and not merely from the buccal bone.⁵ The results demonstrated that following extraction of multiple contiguous teeth, the interdental blood supply to the alveolar bone is compromised to a much larger extent as compared to when a single tooth is extracted.⁵ Other studies^{4,6} have also supported the ESC. Therefore, a compromised vascular supply to the buccal bone (that is already vulnerable to undergo resorption due to its composition) enhances bone remodeling process. These events may compromise the alveolar ridge width and complicate future oral rehabilitative procedures such as implant therapy.

To our knowledge from indexed literature, alveolar bone remodeling around immediate implants has been investigated merely in single-tooth extraction sites.⁷⁻¹³ However, alveolar bone remodeling around immediate implants placed in multiple contiguous teeth extraction sites is yet to be investigated. The present microcomputed tomographic investigation was based on the null hypothesis that immediate placement of dental implants in single and contiguous teeth extraction sites does not prevent alveolar ridge remodeling.

The aim of the present microcomputed tomography (micro-CT) analysis was to investigate the alveolar ridge width around immediate implants placed in accordance with the ESC.

MATERIALS AND METHODS

Ethical Guidelines

The study protocol was approved by the research ethics review board and the animal experimentation ethics committee of the Engineer Abdullah Bugshan Research Chair for Growth Factors and Bone Regeneration.

Study Animals and Randomization Protocol

Ten adult female beagle dogs, with a mean age and weight of 24 ± 0.83 months and 13.8 ± 0.49 kg, respectively, were used. The animals were vaccinated against rabies and infectious hepatitis. All non-surgical and surgical procedures were performed under general anesthesia using intramuscular (IM) injections of ketamine (Pfizer Limited, Sandwich, Kent, UK) (10 mg/kg body weight) and local anesthesia with xylocaine (with epinephrine 5 mg/mL) (AstraZeneca LP for DENTSPLY Pharmaceutical, York, PA, USA). All animals were kept in individual cages and on a soft diet throughout the study period.

The subjects were randomly divided into three groups by picking a paper marked 'Group 1', 'Group 2', or 'Group 3' from a brown bag. Groups 1, 2, and 3 represented ESC-I, ESC-II, and ESC-III, respectively.

Nonsurgical Protocol

In all animals, supragingival scaling was performed twice a week for 2 weeks using an ultrasonic scaler (NSK, Westborough, MA, USA). IM antibiotics (ampicillin 25 mg/kg body weight) were administered 1 day before and at the time of surgery. Periapical radiographs of the future extraction sites were taken. The animals were draped and the surgical site was swabbed with an antiseptic solution (The Purdue Frederick Company, Stamford, CT, USA).

Surgical Protocol

Using a sulcular incision (with a No. 15 blade), full thickness buccal flaps were raised and extended till the mucogingival junction. Teeth were atraumatically extracted using piezosurgery (Piezosurgery®, Mectron,

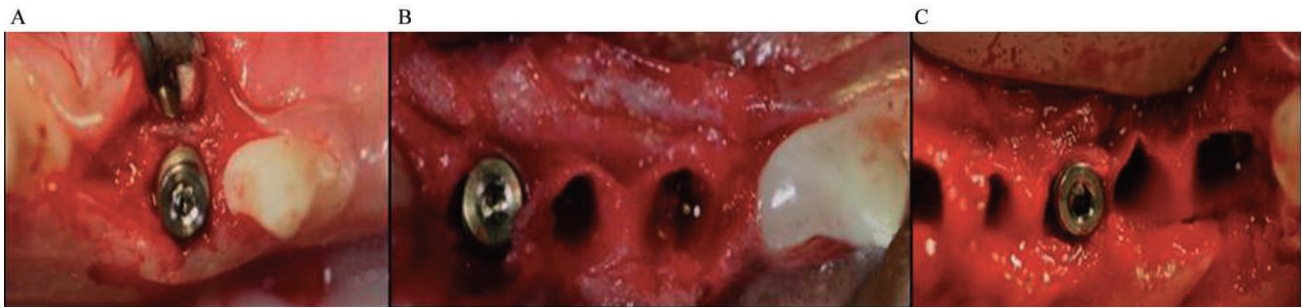


Figure 1 Immediate implant placement in fresh extraction sites in accordance with the extraction socket classification. *A*, Bilateral first and third premolars were extracted and replaced with immediate implants (Group 1). *B*, Two adjacent premolars were extracted with one immediate implant placement in the mesial socket in the maxilla and in the distal socket in the mandible (Group 2). *C*, Three teeth were extracted and an immediate implant was placement in the central socket using four dogs (Group 3). Sound buccal bone with no dehiscence is evident.

Columbus, OH, USA). All extracted teeth were devoid of dehiscence defects.

In total, 48 immediate implants (10.5 mm long and 3 mm in diameter) (Laser-Lok® microchannels, BioHorizons, Birmingham, AL, USA) were placed in the upper and lower jaws (16 implants per group) in accordance with the ESC (Figure 1).⁵ In Group 1, bilateral first and third premolars were extracted and replaced with immediate implants (see Figure 1A). In Group 2, two adjacent premolars were extracted with one immediate implant placement in the mesial socket in the maxilla and in the distal socket in the mandible (see Figure 1B). This was done to avoid contacting the root of the distally curved canine root in the lower arch using four dogs. In Group 3, three teeth were extracted and an immediate implant was placement in the central socket using four dogs (see Figure 1C). In all groups, immediate implants were submerged in bone with a lingual/palatal inclination and healing screws were placed. Immediate implants lacking primary stability at the time of placement were excluded from the study. In each group, a minimum distance of 1.5 mm was maintained between the implant and the adjacent tooth. In each group, the average gap between the implant and extraction socket was 0.75 mm. Primary closure was achieved using resorbable sutures (VICRYL Polyglactin 910, Ethicon Inc., Somerville, NJ, USA).

Postoperative Management

All subjects were administered IM injections of amoxicillin (25 mg/kg body weight once a day for 5 days) (Betamox LA, Norbrook Laboratory Limited, Newry, County Down, Northern Ireland). Plaque control procedures were executed twice weekly by topical application of 0.2% chlorhexidine digluconate solution

(GUM®, Sunstar Americas, Chicago, IL, USA), until sacrifice. Two weeks after surgery, sutures were removed and periapical radiographs were taken to assess the relationship of the implants with adjacent vital structures. IM antibiotics (Norbrook Laboratory Limited) were continued for 3 days after surgery as 25 to 50 mg/kg every 8 hours.

Euthanasia and Hard Tissue Sectioning

After 4 months, all subjects were sacrificed using an overdose of 3% sodium pentobarbital. Jaw segments containing the implants and associated mesial and distal teeth were removed *en bloc* using an electric saw (Leica SP 1600, Leica Microsystem, Bannockburn, IL, USA). The samples were fixed in 10% neutral formalin solution.

Measurement of Alveolar Ridge Width Using Micro-CT

Alveolar ridge width (buccolingual/buccopalatal width) was defined as the horizontal distance between the buccal and lingual/palatal cortical plates from the crest of ridge. Axial measurements were made at every 1 mm section up to 4 mm from the crest of bone. Alveolar ridge widths in sockets with and without immediate implants were three-dimensionally assessed using a micro-CT (SkyScan 1172, CT-Analyser version 1.11.4.2+, SkyScan, Kontich, Belgium). The x-ray generator of the micro-CT was operated at an accelerated potential of 101 kV with a beam current of 96 μ A using an aluminum filter with a resolution of 37.41 μ m pixels.

Statistical Analysis

Data analysis was performed using a statistical software (SPSS version 18.00, SPSS Inc., Chicago, IL, USA).

Differences in the alveolar bone widths in sites with and without immediate implant placement were assessed using one-way analysis of variance. For multiple comparisons, the Bonferroni post hoc test was performed. *p* Values less than .05 were considered statistically significant.

RESULTS

Alveolar Ridge Width (at 1 mm Thickness)

In sites without immediate implant placement, the mean alveolar ridge widths in Groups 1, 2, and 3 were 6.1 ± 1.35 , 4.3 ± 0.57 , and 4.14 ± 1.53 mm, respectively. Alveolar ridge width was significantly higher among sites in Group 1 (6.1 ± 1.35 mm) as compared with sites in Group 3 (4.14 ± 1.53 mm) ($p < .05$) (Table 1). There was no significant difference in the alveolar ridge width among sites in Groups 2 and 3 (Figures 2–4).

In sites with immediate implant placement, the mean alveolar ridge widths in Groups 1, 2, and 3 were 6.4 ± 3.8 , 4.8 ± 0.46 , and 5.02 ± 0.84 mm, respectively. The mean alveolar ridge width was significantly higher among sites in Group 1 (6.4 ± 3.8 mm) as compared with sites in Group 2 (4.8 ± 0.46 mm) ($p < .05$) and Group 3 (5.02 ± 0.84 mm) ($p < .05$). There was no significant difference in the alveolar ridge width among sites in Groups 2 and 3 (see Table 1 and Figures 2–4).

In general, at 1 mm thickness, there was no significant difference in the alveolar ridge widths between each corresponding group in both sites with and without immediate implant placement. In Groups 1, 2, and 3, respectively), lingual/palatal bone was present on the smooth surface of the implant with no thread exposure (see Figure 3).

TABLE 1 Alveolar Ridge Width (Mean \pm SD) of Extraction Sites with and without Immediate Implant Placement in Each Group (at 1 mm Thickness)

	Alveolar Ridge Width (in mm)	
	Extraction Site without Immediate Implant Placement (Mean \pm SD)	Extraction Site with Immediate Implant Placement (Mean \pm SD)
Group 1	6.1 ± 1.35	6.4 ± 3.8
Group 2	4.3 ± 0.57	4.8 ± 0.46
Group 3	4.14 ± 1.53	5.02 ± 0.84

* $p < .05$.

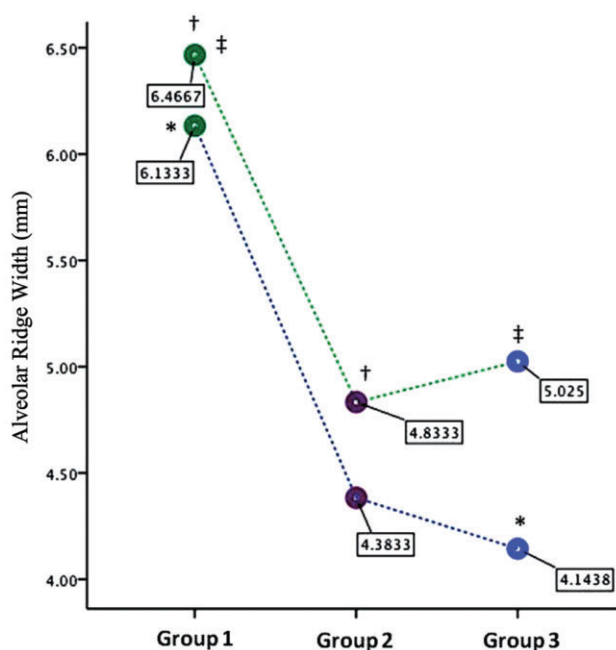


Figure 2 A graphic representation of the alveolar bone thicknesses (at 1 mm thickness) in sites with (green-dotted line) and without (blue-dotted line) immediate implant placement in Groups 1, 2, and 3. * $p < .05$, [†] $p < .05$, [‡] $p < .05$.

DISCUSSION

The present results demonstrated that the alveolar ridge width is compromised following immediate implant placement in single and contiguous teeth extraction sites. These results are in accordance with our null hypothesis. It is however noteworthy that the alveolar ridge width was compromised to a much greater extent in sites in Group 3 as compared with sites in Group 1. These results may be explained by a recent histologic study⁵ in which the authors emphasized that the interdental blood supply to the alveolus plays a pivotal role in maintaining the architecture of the alveolus. This study demonstrated that the interdental vascular supply to the alveolus is compromised following tooth extraction; however, extraction of multiple contiguous teeth compromises the interdental blood supply to the alveolus to a much greater extent as compared to when a single tooth is extracted.⁵ The present three-dimensional microcomputed tomographic results support the histologic results by Al-Hezaimi and colleagues⁵ as the alveolar ridge width was compromised around immediate implants placed in single (Group 1) as well as multiple contiguous teeth extraction sites (Group 3).

The current results are in contradiction to earlier studies,^{7–13} which demonstrated that immediate

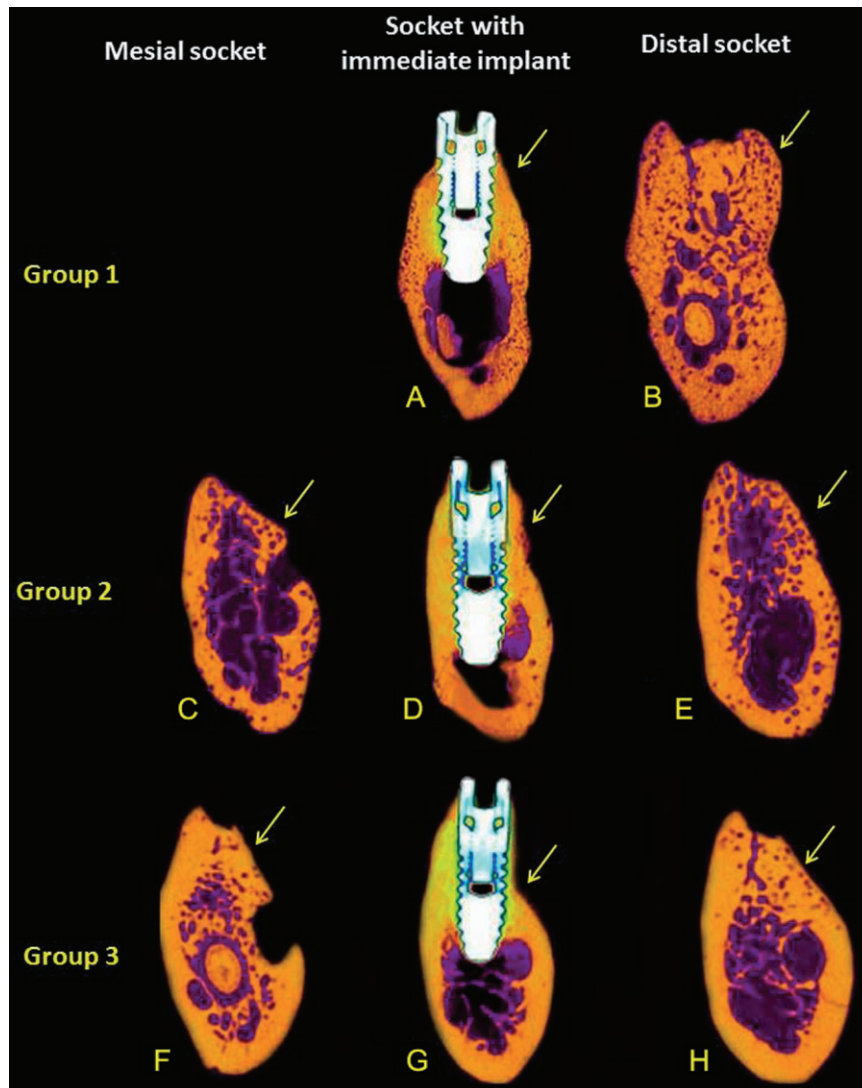


Figure 3 A series of reconstructed sagittal microcomputed tomographic images (at 1 mm thickness) illustrating the buccal bone thickness in sites with and without immediate implants placed in Groups 1, 2, and 3, respectively. *A* and *B*, Sagittal section showing the buccal bone thickness around dental implants at the crestal bone level. *C–E*, Sagittal section showing a compromised buccal bone thickness in sites with and without immediate implant placement. *F–H*, Sagittal sections showing a significant reduction in the buccal bone thickness in sites with and without immediate implant placement. Yellow arrows represent the buccal surfaces in each group.

placement of dental implants in fresh extraction sites helps prevent or minimize alveolar ridge remodeling. Our results clearly demonstrated that immediate implants placed in multiple contiguous extraction sites (Groups 2 and 3) underwent significantly more alveolar bone remodeling as compared with immediate implants in a single-tooth extraction site (Group 1). It is therefore asserted that the amount of ridge alteration following exodontia is comparative with the extent to which the interdental blood supply is compromised. An interesting finding in the present study was that the alveolar ridge width was significantly compromised on the buccal side

as compared with the lingual/palatal side of the alveolar ridge. This result may be explained by the fact that the buccal bone is entirely composed of bundle bone, which makes it more prone to resorption as compared with the lingual/palatal process of alveolar bone.^{3–5} The present canine study provides a platform for clinical scenarios where single and multiple teeth extraction sites are nominated for future implant placement. From the current study, immediate implant placement may have predictable outcomes in ESC-I and ESC-II as compared with ESC-III where significant bone remodeling occurred. However, it is also evident that simultaneous

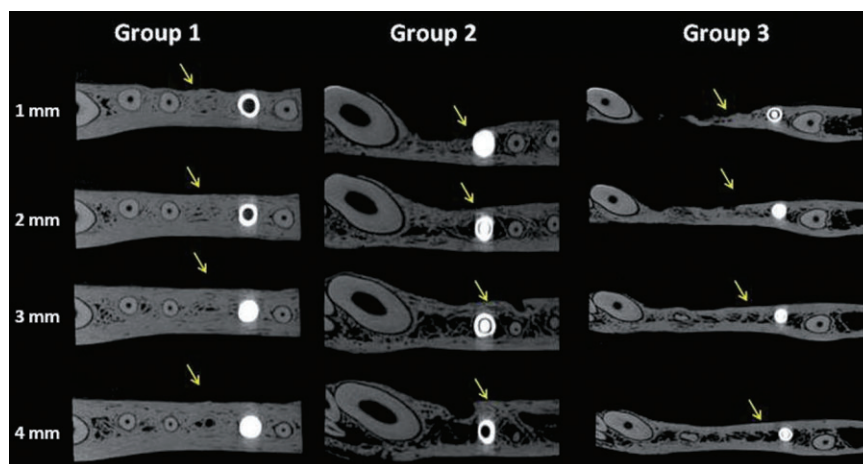


Figure 4 A series of reconstructed axial microcomputed tomographic images (from 1 mm up to 4 mm thickness) illustrating the buccal bone thickness in sites with and without immediate implants placed in Groups 1, 2, and 3, respectively. Yellow arrows represent the buccal surfaces in each group.

guided bone regeneration could be recommended in ESC-I and ESC-II due to the presence of small amount of bone thickness after 4 months of healing provided that the immediate implants were not loaded.^{3-6,14}

The present results support a recent canine study⁶ which showed that the alveolar bone thickness is significantly compromised in multiple contiguous teeth extraction sites (ESC-III, as in the present study) as compared with single-tooth extraction sites. Under such circumstances, initial bone augmentation followed by delayed placement of dental implants may be recommended for more predictable outcomes.

Studies have reported that implant system with laser micro-etched surfaces help preserve alveolar ridge width by promoting bone and soft tissue attachment along the collar of the implant and inhibiting epithelial downgrowth.¹⁵⁻¹⁷ Pecora and colleagues¹⁸ also reported that implants with laser micro-etched surfaces reduce alveolar bone loss by 70% as compared with implant surfaces without laser-etched surfaces. In the present study, 48 immediate implants with laser micro-etched collars were placed in extraction sockets; however, the present micro-CT results are in negation with the previous reports¹⁵⁻¹⁷ as all extraction sites (either with or without immediate implants) demonstrated alveolar ridge remodeling. In the current study, the lingual/palatal surface in all classes and the buccal surface in ESC-I were at the smooth surface of the implant which confirm previous reports.^{15,17}

Within the limits of the present micro-CT analysis, it is concluded that immediate implant placement does

not prevent or minimize alveolar bone remodeling in extraction sites (with the exception of ESC-I). The interdental vascular supply plays a pivotal role in maintaining the overall structural integrity of the alveolus.

ACKNOWLEDGMENT

The present research study is registered (NF#2363) at the College of Dentistry Research Center, King Saud University, Riyadh, Saudi Arabia.

REFERENCES

1. Amler MH. The time sequence of tissue regeneration in human extraction wounds. *Oral Surg Oral Med Oral Pathol* 1969; 27:309-318.
2. Cardaropoli G, Araújo M, Lindhe J. Dynamics of bone tissue formation in tooth extraction sites: an experimental study in dogs. *J Clin Periodontol* 2003; 30:809-819.
3. Araújo MG, Lindhe J. Dimensional ridge alterations following tooth extractions. An experimental study in the dog. *J Clin Periodontol* 2005; 32:212-218.
4. Al-Askar M, O'Neill R, Stark PC, Griffin T, Javed F, Al-Hezaimi K. Effect of single and contiguous teeth extractions on alveolar bone remodeling: a study in dogs. *Clin Implant Dent Relat Res* 2011. [Epub ahead of print].
5. Al-Hezaimi K, Levi P, Rudy R, Al-Jandan B, Al-Rasheed A. An extraction socket classification developed using analysis of bone type and blood supply to the buccal bone in monkeys. *Int J Periodontics Restorative Dent* 2011; 31:421-427.
6. Al-Shabeeb MS, Al-Askar M, Al-Rasheed A, et al. Alveolar bone remodeling around immediate implants placed in accordance with the extraction socket classification – a

- three-dimensional micro-computed tomography analysis. *J Periodontol* 2011. [Epub ahead of print].
7. Atieh MA, Alsabeeha NH, Duncan WJ, et al. Immediate single implant restorations in mandibular molar extraction sockets: a controlled clinical trial. *Clin Oral Implants Res* 2012. DOI: 10.1111/j.1600-0501.2011.02415.x. [Epub ahead of print].
 8. Yun JH, Jun CM, Oh NS. Secondary closure of an extraction socket using the double-membrane guided bone regeneration technique with immediate implant placement. *J Periodontol Implant Sci* 2011; 41:253–258.
 9. Caneva M, Botticelli D, Salata LA, Souza SL, Bressan E, Lang NP. Flap vs. ‘flapless’ surgical approach at immediate implants: a histomorphometric study in dogs. *Clin Oral Implants Res* 2010; 21:1314–1319.
 10. Araújo MG, Linder E, Lindhe J. Bio-Oss collagen in the buccal gap at immediate implants: a 6-month study in the dog. *Clin Oral Implants Res* 2011; 22:1–8.
 11. Barone A, Ricci M, Calvo-Guirado JL, Covani U. Bone remodelling after regenerative procedures around implants placed in fresh extraction sockets: an experimental study in Beagle dogs. *Clin Oral Implants Res* 2011. [Epub ahead of print].
 12. Kim DM, Nevins M, Camelo M, et al. The feasibility of demineralized bone matrix and cancellous bone chips in conjunction with an extracellular matrix membrane for alveolar ridge preservation: a case series. *Int J Periodontics Restorative Dent* 2011; 31:39–47.
 13. Negri B, Calvo-Guirado JL, Zamora GP, et al. Peri-implant bone reactions to immediate implants placed at different levels in relation to crestal bone. Part I: a pilot study in dogs. *Clin Oral Implants Res* 2012; 23:228–235.
 14. Araújo MG, Sukekava F, Wennström JL, Lindhe J. Ridge alterations following implant placement in fresh extraction sockets: an experimental study in the dog. *J Clin Periodontol* 2005; 32:645–652.
 15. Nevins M, Nevins ML, Camelo M, Boyesen JL, Kim DM. Human histologic evidence of a connective tissue attachment to a dental implant. *Int J Periodontics Restorative Dent* 2008; 28:111–121.
 16. Weiner S, Simon J, Ehrenberg DS, Zweig B, Ricci JL. The effects of laser microtextured collars upon crestal bone levels of dental implants. *Implant Dent* 2008; 17:217–228.
 17. Nevins M, Kim DM, Jun SH, Guze K, Schupbach P, Nevins ML. Histologic evidence of a connective tissue attachment to laser microgrooved abutments: a canine study. *Int J Periodontics Restorative Dent* 2010; 30:245–255.
 18. Pecora GE, Ceccarelli R, Bonelli M, Alexander H, Ricci JL. Clinical evaluation of laser microtexturing for soft tissue and bone attachment to dental implants. *Implant Dent* 2009; 18:57–66.