

## Assessment and Treatment of Acute Heart Failure— Case Study: Wet and Warm Profile with Concomitant Anuric Renal Failure

JIM EDWARD WEBER, D.O.

Department of Emergency Medicine, University of Michigan, Ann Arbor, Michigan, USA

### Patient Presentation and History

An 86-year-old man arrived by ambulance at the emergency department (ED) at 7:15 P.M. with shortness of breath, wheezing, and sweating. The history obtained of his present illness was brief due to the patient's extreme dyspnea. He had missed his dialysis appointment the previous day, and he complained of worsening shortness of breath that morning. En route he received nebulized albuterol and was on 100% O<sub>2</sub> by nonrebreather mask. The patient had suffered a myocardial infarction approximately 7 years previously. He had also undergone two cardiac catheterizations documenting extensive coronary artery disease (CAD), resulting in angioplasty with subsequent stent placement. In addition, he had a history of congestive heart failure (CHF) and hypertension that precipitated end-stage renal failure requiring hemodialysis. He also had chronic obstructive pulmonary disease (COPD) and was on home O<sub>2</sub> at 2 l/min. His medications were as follows: enalapril 40 mg/day, clonidine 0.1 mg t.i.d., isosorbide dinitrate 25 mg/day, atenolol 25 mg/day, salmeterol 2 puffs b.i.d., fluticasone 2 puffs b.i.d., albuterol p.r.n., lansoprazole 15 mg/day, calcium acetate 665 mg t.i.d., and Nephrocaps 1/day.

### Examination

Vital signs were temperature 37.6°C, heart rate 110 beats/min, respiratory rate 34 breaths/min, blood pressure 200/86 mmHg, SO<sub>2</sub> 91% on 100% FIO<sub>2</sub>.

The patient was a well-developed, well-nourished Caucasian male in severe respiratory distress. He was seated in a tripod position, diaphoretic, anxious, and using accessory muscles. Additional observations included the following:

- Neck: neck veins distended
- Heart: S<sub>1</sub>S<sub>2</sub>, tachycardic rate, grade II systolic murmur of greatest intensity at the left lower sternal border
- Lungs: Rapid shallow breathing, scattered wheezing, audible diffuse rales bilaterally
- Abdomen: nontender

- Extremities: warm, 2+ pitting edema
- Neurologic exam: nonfocal.

Physiologically, this patient's presentation is consistent with a warm and wet profile (Fig. 1). More than 80% of patients presenting to the ED with acutely decompensated heart failure (ADHF) have clinical congestion (i.e., are classified as being wet) and, if right heart catheterization were performed, would show elevated pulmonary capillary wedge pressure (PCWP).<sup>1</sup> These patients may have adequate (wet-warm) or reduced (wet-cold) perfusion, with the majority showing elevation in systemic vascular resistance (SVR). Clinical indicators of congestion in the assessment of patients with HF include a recent history of orthopnea and/or evidence on physical examination of jugular venous distention, hepatojugular reflux, ascites, peripheral edema, leftward radiation of the pulmonic heart sound, or a square wave blood pressure response to the Valsalva maneuver.

### Initial Emergency Department Course

Non-invasive ventilation was immediately started using bilateral positive airway pressure (BiPAP) with an inspiratory pressure of 12 mmHg and a base pressure of 5 mmHg. He was also given an intravenous (IV) nesiritide 2 mcg/kg bolus, followed by an infusion of 0.01 mcg/kg/min. Ancillary studies were as follows:

- Chest x-ray (Fig. 2): cardiomegaly, Kerley B lines, pulmonary congestion consistent with CHF
- Electrocardiogram: sinus tachycardia at 110 beats/min, bifascicular heart block, no acute ST-T wave changes
- Arterial blood gases:
  - o Initial: pH = 7.24, P<sub>a</sub>O<sub>2</sub> = 73 mmHg, P<sub>a</sub>CO<sub>2</sub> = 66 mmHg, SO<sub>2</sub> = 91.6%
  - o 10 P.M.: pH = 7.30, P<sub>a</sub>O<sub>2</sub> = 75 mmHg, P<sub>a</sub>CO<sub>2</sub> = 50 mmHg, SO<sub>2</sub> = 92.3%
- Serum laboratory values: Na = 139 mEq/l, K = 5.1 mEq/l, Cl = 98 mEq/l, HCO<sub>3</sub> = 25 mEq/l, blood urea nitro-

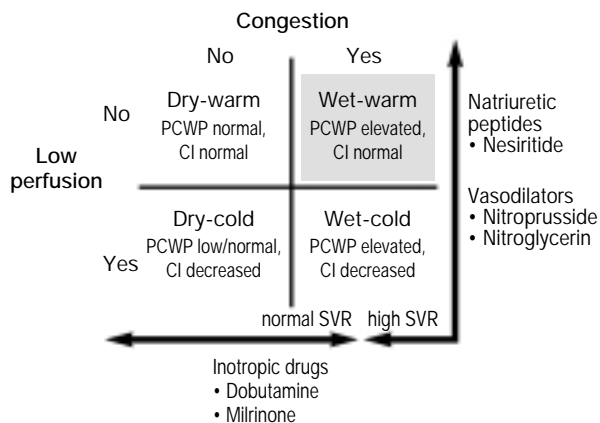


FIG. 1 Rapid clinical assessment of hemodynamic profiles (wet-warm focus). PCWP = pulmonary capillary wedge pressure, CI = cardiac index, SVR = systemic vascular resistance.

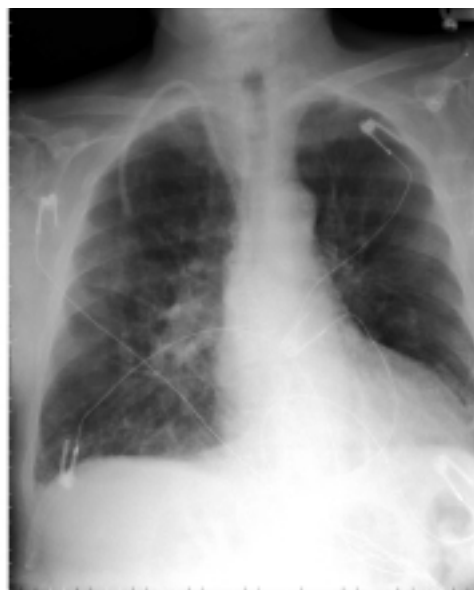

FIG. 2 Initial emergency department chest x-ray performed on this patient, who presented with signs and symptoms characteristic of a wet and warm profile. Cardiomegaly, Kerley B lines, and pulmonary congestion consistent with congestive heart failure were noted.

gen = 57 mg/dl, creatinine = 7.8 mg/dl, glucose = 340 mg/dl, troponin = 0.09 ng/ml.

**Subsequent Course**

The patient began to show signs of improvement within minutes of starting BiPAP and nesiritide therapy, as evidenced by improvement in oxygen saturation (to 98%), a decrease in respiratory rate (to 22 breaths/min), and improvement upon repeat arterial blood gas analysis. He was weaned off the BiPAP to 3 l/min of O<sub>2</sub> by nasal cannula while in the ED. After 4 h of ED management, he was transferred to the telemetry unit in stable condition. He had an uneventful evening free of dyspnea, chest pain, or arrhythmias and underwent routine dialysis the following morning.

**Discussion**

Management of CHF presents unique challenges in patients with renal failure (RF) who are dialysis dependent.<sup>2</sup> Patients with RF may have elevated B-type natriuretic peptide levels in the absence of HF; thus, the assay is less useful in this population. With patients with RF who have either a relative or absolute resistance to diuretic therapy, medication side effects of drugs used to treat CHF are of greater concern. The risk of thiocyanate toxicity with the use of nitroprusside is increased in patients with RF. In addition, there is a greater than average risk of arrhythmias with the use of inotropes and digoxin due to preexisting electrolyte disturbances. Urgent or emergent dialysis for the management of CHF is accompanied by logistical constraints as well as expense. Finally, the need for mechanical ventilation or titration of medication drips requires admission to the intensive care unit.

Natriuretic peptides such as A-type and B-type (BNP) enhance the effects of loop diuretics in patients without renal

impairment. Nesiritide, the recombinant form of BNP, does not depend on renal clearance, and the balanced vasodilatory effects of nesiritide make it useful in patients with CHF and concomitant RF. Nesiritide-treated patients with RF demonstrate reductions in PCWP and dyspnea similar to those in patients without RF.<sup>3</sup> Similarly, the incidence of hypotension or arrhythmias does not increase with nesiritide use in the presence of RF.<sup>3</sup> Data from The ADHERE<sup>®</sup> Registry show that IV

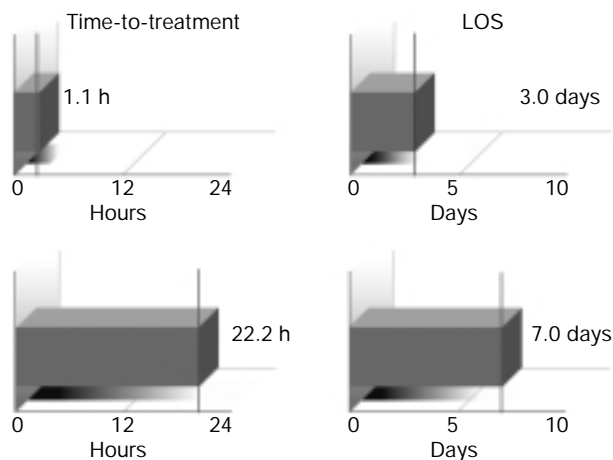


FIG. 3 The ADHERE<sup>®</sup> Registry: Time-to-treatment (left-hand column) and LOS (right-hand column) for patients started on intravenous vasoactive therapy in the emergency department (ED) and inpatient unit. The top row represents ED; the bottom row represents inpatient unit.<sup>4</sup>

vasoactives, such as nesiritide, started in the ED are associated with significantly reduced initial treatment times (1.1 h vs. 22.2 h if started in the inpatient unit,  $p < 0.0001$ , Fig. 3).<sup>4</sup> Early initiation of IV vasoactives also impacts length of stay (LOS); ADHERE<sup>®</sup> data show that those treated in the ED are associated with a significantly shorter LOS compared with those treated in the inpatient unit both in the hospital (3.0 vs. 7.0 days,  $p < 0.0001$ , Fig. 3) and in the intensive and coronary care units (ICU/CCU) (2.1 vs. 4.5 days,  $p < 0.0001$ ).<sup>4</sup>

In this case, the patient received nesiritide within 15 min of ED presentation and improved rapidly. This point is noteworthy because both the timing and choice of initial HF therapy appear to have a significant impact on a patient's hospital course, clinical outcome, and intensity of care required. A final advantage of nesiritide is its ability to prevent ICU admission (in favor of a telemetry bed) in many patients with HF who are stabilized in the ED. As nesiritide does not demonstrate tachyphylaxis, further titration and hemodynamic monitoring are typically unnecessary.

The patient's rapid and dramatic improvement suggests that ED initiation of noninvasive ventilation and IV nesiritide should be considered in patients with RF who present with decompensated heart failure.

## References

1. Nohria A, Lewis E, Stevenson LW: Medical management of advanced heart failure. *J Am Med Assoc* 2002;287:628–640
2. Stack AG, Bloembergen WE: A cross-sectional study of the prevalence and clinical correlates of congestive heart failure among incident US dialysis patients. *Am J Kid Dis* 2001;38:992–1000
3. Butler J, Peacock WF, Mathur VS, Young JB, and VMAC Study Investigators: Nesiritide (B-type natriuretic peptide) use in patients with renal insufficiency and acute decompensated heart failure: Efficacy and safety results from the VMAC trial. *Circulation* 2002; 106:II-567
4. Peacock F, Emerman CL, Costanzo MR, Berkowitz RL, Cheng M: Early initiation of intravenous vasoactive therapy improves heart failure outcomes: An analysis from The ADHERE Registry database. *Ann Emerg Med* 2003;42(4):S26