

RESEARCH LETTER

Homozygous deletion of exons 2 and 3 of NPC2 associated with Niemann-Pick Disease Type C

Malavika Hebbar^a, Harsha Prasada L^b, Aneek Das Bhowmik^c, Daniel Trujillano^d, Anju Shukla^a,
Shrijeet Chakraborti^e, Krishna Kumar Kandaswamy^d, Arndt Rolfs^{d,f}, Nutan Kamath^b, Ashwin
Dalal^c, Stephanie Bielas^g, Katta Mohan Girisha^{a,*}

^aDepartment of Medical Genetics, Kasturba Medical College, Manipal University, Manipal, India

^bDepartment of Pediatrics, Kasturba Medical College, Manipal University, Mangalore, India

^cDiagnostics Division, Centre for DNA Fingerprinting and Diagnostics, Hyderabad, India

^dCentogene AG, Rostock, Germany

^eDepartment of Pathology, Kasturba Medical College, Manipal University, Mangalore, India

^fAlbrecht-Kossel-Institute for Neuroregeneration, Medical University Rostock, Rostock, Germany

^gDepartment of Human Genetics, University of Michigan, Ann Arbor, Michigan, USA

*Corresponding author:

Dr Girisha KM
Department of Medical Genetics
Kasturba Medical College, Manipal
Manipal University, Manipal-576104
India
Email: girish.katta@manipal.edu
Phone number: +91-820-2923149

Keywords: Niemann-Pick Disease Type C; NPC2; deletion; mutation; India

TO THE EDITOR

Niemann-Pick disease type C (MIM 607625; NP-C) is an autosomal recessive, lysosomal storage disorder caused by impaired cholesterol and glycolipid trafficking due to pathogenic

variations in either *NPC1* (accounting for more than 95% of cases) or *NPC2* [Park et al., 2003]. The birth incidence ranges from 0.66 and 0.83 per 100,000 in France, the United Kingdom, and Germany. However, this disorder is observed less frequently in Australia, the Netherlands, and Northern Portugal [Vanier 2010]. Niemann-Pick disease type C is a clinically heterogeneous multisystem disorder leading to accumulation of fat and neurodegeneration. Being a neurovisceral disorder, it mainly affects liver, spleen, lungs, and nervous system [Patterson et al., 2012]. Here we report the first patient with NP-C associated with a deletion of two exons in *NPC2*.

The proband was an only child, born at term to a non-consanguineous couple of Asian origin. Her BW was 3.5 kg, normal. She was evaluated at three months of age for failure to thrive, cough, and loose stools. She was treated symptomatically for cough. However, she continued to have these symptoms requiring a hospital admission at five months of age for further evaluation. There was delay in motor development and she could not hold her neck or roll over at age 5 months.

Examination at 5 months of age showed generalized lymphadenopathy. She also had hepatosplenomegaly (spleen palpable 6 cm below the costal margin and liver 4 cm below the costal margin), consistent with abdominal ultrasonographic findings. She weighed 4.7 kg (<3rd centile), her OFC was 38 cm (more than -4 SD) and length was 68 cm (normal). Complete blood count and liver functions were unremarkable. The toxoplasma, cytomegalovirus, rubella, and herpes simplex IgM serologies were negative. The tests for hepatitis B surface antigen and human immunodeficiency virus were negative. Fat globules were absent in the stool. Lipid profile, echocardiogram, urine microscopy, and blood gases were unremarkable.

Bone marrow aspiration showed hematopoietic cells and scattered large foamy histiocytes having finely, vacuolated cytoplasm which were negative for Periodic Acid Schiff reagent, suggestive of Nieman-Pick disease (Figure 1). Several attempts to assay sphingomyelinase levels in leukocytes (for Neimann-Pick disease Type A) failed due to degraded samples. No mutations were identified on Sanger sequencing of *SMPD1*. At age of 8 months she succumbed to death due to respiratory failure. ..

Genomic DNA was extracted from the preserved whole blood of the child and parents using the standard phenol-chloroform method. Massively parallel sequencing of the exome was done using the NextSeq500 Sequencer (Illumina Inc., San Diego, CA, USA) in combination with the NextSeq™ 500 High Output Kit (2x150bp). These methods have been described in detail [Girisha et al., 2016].

To our surprise, none of the genes known to cause a storage disorder had a strong candidate variant. Based on the convincing clinical suspicion and the suggestion of a storage disease by foamy histiocytes, the genes known to cause storage disorders were analyzed on IGV. There were no reads for exon 2 and exon 3 of *NPC2* in the proband, whereas, the parents presented only half of the coverage expected for both the exons on healthy individuals (Figure 2). To validate the deletion of these two exons, multiplex ligation-dependent probe amplification (MLPA) was performed, which confirmed the homozygous deletion of exons 2 and 3 of *NPC2* in the proband and heterozygous carrier status for the same in both the parents (Figure 3). We inspected the entire exome dataset for the family and both the kinship coefficient and the homozygous variants distribution in the proband evidence that this is likely a non-consanguineous family. We have noted homozygous mutations in recessive conditions,

despite the parents denying obvious consanguinity in our earlier work [Bidchol et al., 2014; Bidchol et al., 2015; Dalal et al., 2012].

The current patient portrays the clinical course of an early infantile onset group of NP-C, classified based on the age of onset, neurological manifestations and foamy histiocytes in bone marrow. In this group, the hepatosplenomegaly is the predominant visceral sign as observed in here [Alobaidy 2015]. The cough and respiratory failure in the proband can be attributed to infiltration of the lungs with foam cells due to impaired diffusion [Patterson et al., 2012]. Pulmonary insufficiency leading to respiratory failure has been reported in infants with NP-C2 [Millat et al., 2001; Reunert et al., 2015]. Recently, a new screening approach to diagnose NP-C by detecting the elevated oxysterols was proposed by Griese *et al* [2010]. The NPC2 protein is a glycoprotein coded by the 5 exons of *NPC2* gene. Although the exact functions of *NPC1* and *NPC2* genes remain obscure, they are believed to function in a synchronized fashion in the cellular post lysosomal/late endosomal transport of cholesterol and other molecules [Sleat et al., 2004].

NPC2 gene mutations were first described in two families by Naureckiene *et al.* [2000] where they found one homozygous variant, c.58G>T and compound heterozygous variants c.58G>T and c.332delA, respectively. A study of eight unrelated families from France, Algeria, Italy, Germany, the Czech Republic, and Turkey identified two nonsense variants (p.(Glu20Ter), p.(Glu118Ter)), one missense variant (p.(Ser67Pro)), one splice site mutation (c.190+5 G>A), and one single base pair deletion (c.27delG) [Millat et al., 2001]. Thirteen more missense/nonsense variants were reported by Chikh *et al* [2005]. Currently, 25 disease-causing mutations have been reported in HGMD in *NPC2* including 19 missense/nonsense mutations,

three splice site changes and three small deletions. Deletions of an entire exon have not been reported. We could not determine the breakpoints and size of the deleted region or study the transcript in this patient. It is necessary to emphasize here that these whole exonic deletions when present in a compound heterozygous state, would not be detected by exome sequencing unless specifically tested for copy number variations.

Here we report the first patient with NPC-2 due to a homozygous deletion of two exons in the *NPC2* gene.

INTERNET RESOURCES

Human Gene Mutation Database: www.hgmd.cf.ac.uk, public version accessed on 2nd April 2016)

ACKNOWLEDGEMENTS

We thank the family who cooperated with evaluation of the child and consented for participation in this study. The National Institutes of Health funded the project titled 'Genetic Diagnosis of Heritable Neurodevelopmental Disorders in India: Investigating the Use of Whole Exome Sequencing and Genetic Counseling to Address the High Burden of Neurodevelopmental Disorders' (GRANT11808979). The authors declare no conflict of interest.

REFERENCES

Alobaidy H. 2015. Recent advances in the diagnosis and treatment of niemann-pick disease type

C in children: a guide to early diagnosis for the general pediatrician. *Int J Pediatr* 2015:816593.

Bidchol AM, Dalal A, Shah H, S S, Nampoothiri S, Kabra M, Gupta N, Danda S, Gowrishankar K, Phadke SR, Kapoor S, Kamate M, Verma IC, Puri RD, Sankar VH, Devi AR, Patil SJ, Ranganath P, Jain SJ, Agarwal M, Singh A, Mishra P, Tamhankar PM, Gopinath PM,

- Nagarajaram HA, Satyamoorthy K, Girisha KM. 2014. GALNS mutations in Indian patients with mucopolysaccharidosis IVA. *Am J Med Genet A* 164A:2793-2801.
- Bidchol AM, Dalal A, Trivedi R, Shukla A, Nampoothiri S, Sankar VH, Danda S, Gupta N, Kabra M, Hebbar SA, Bhat RY, Matta D, Ekbote AV, Puri RD, Phadke SR, Gowrishankar K, Aggarwal S, Ranganath P, Sharda S, Kamate M, Datar CA, Bhat K, Kamath N, Shah H, Krishna S, Gopinath PM, Verma IC, Nagarajaram HA, Satyamoorthy K, Girisha KM. 2015. Recurrent and novel GLB1 mutations in India. *Gene* 567:173-181.
- Chikh K, Rodriguez C, Vey S, Vanier MT, Millat G. 2005. Niemann-Pick type C disease: subcellular location and functional characterization of NPC2 proteins with naturally occurring missense mutations. *Hum Mutat* 26:20-28.
- Dalal A, Bhavani GS, Togarrati PP, Bierhals T, Nandineni MR, Danda S, Danda D, Shah H, Vijayan S, Gowrishankar K, Phadke SR, Bidchol AM, Rao AP, Nampoothiri S, Kutsche K, Girisha KM. 2012. Analysis of the WISP3 gene in Indian families with progressive pseudorheumatoid dysplasia. *Am J Med Genet A* 158A:2820-2828.
- Girisha KM, Shukla A, Trujillano D, Bhavani GS, Hebbar M, Kadavigere R, Rolfs A. 2016. A homozygous nonsense variant in IFT52 is associated with a human skeletal ciliopathy. *Clin Genet*. In press
- Griese M, Brasch F, Aldana VR, Cabrera MM, Goelnitz U, Ikonen E, Karam BJ, Liebisch G, Linder MD, Lohse P, Meyer W, Schmitz G, Pamir A, Ripper J, Rolfs A, Schams A, Lezana FJ. 2010. Respiratory disease in Niemann-Pick type C2 is caused by pulmonary alveolar proteinosis. *Clin Genet* 77:119-130.

Millat G, Chikh K, Naureckiene S, Sleat DE, Fensom AH, Higaki K, Elleder M, Lobel P, Vanier MT.

2001. Niemann-Pick disease type C: spectrum of HE1 mutations and genotype/phenotype correlations in the NPC2 group. *Am J Hum Genet* 69:1013-1021.

Naureckiene S, Sleat DE, Lackland H, Fensom A, Vanier MT, Wattiaux R, Jadot M, Lobel P. 2000.

Identification of HE1 as the second gene of Niemann-Pick C disease. *Science* 290:2298-2301.

Park WD, O'Brien JF, Lundquist PA, Kraft DL, Vockley CW, Karnes PS, Patterson MC, Snow K.

2003. Identification of 58 novel mutations in Niemann-Pick disease type C: correlation with biochemical phenotype and importance of PTC1-like domains in NPC1. *Hum Mutat* 22:313-325.

Patterson MC, Hendriksz CJ, Walterfang M, Sedel F, Vanier MT, Wijburg F. 2012.

Recommendations for the diagnosis and management of Niemann-Pick disease type C: an update. *Mol Genet Metab* 106:330-344.

Reunert J, Lotz-Havla AS, Polo G, Kannenberg F, Fobker M, Griese M, Mengel E, Muntau AC,

Schnabel P, Sommerburg O, Borggraefe I, Dardis A, Burlina AP, Mall MA, Ciana G, Bembi B, Burlina AB, Marquardt T. 2015. Niemann-Pick Type C-2 Disease: Identification by Analysis of Plasma Cholestane-3beta,5alpha,6beta-Triol and Further Insight into the Clinical Phenotype. *JIMD Rep* 23:17-26.

Sleat DE, Wiseman JA, El-Banna M, Price SM, Verot L, Shen MM, Tint GS, Vanier MT, Walkley

SU, Lobel P. 2004. Genetic evidence for nonredundant functional cooperativity between NPC1 and NPC2 in lipid transport. *Proc Natl Acad Sci U S A* 101:5886-5891.

Vanier MT. 2010. Niemann-Pick disease type C. *Orphanet J Rare Dis* 5:16.

Supplemental online Figure Legends

Supplemental Figure 1 online : A. Bone marrow aspiration shows large foamy histiocytes with vacuolated cytoplasm (Leishman stain; x40) B. A typical storage cell with finely vacuolated cytoplasm (Leishman stain; x100).

Supplemental Figure 2 online: Exome sequencing of the trio followed by alignment of paired-end reads (gray horizontal bars) to the human genome assembly 37 (hg19) showed no reads for exon 2 and exon 3 of *NPC2* gene in the proband (red arrows). Parents had reduced coverage for both the exons (proband-upper panel, mother-middle panel, father-lower panel).

Supplemental Figure 3 online: Multiplex ligation-dependent probe amplification using the SALSA MLPA probe sets P193 identified a homozygous deletion of exon 2 and 3 in the proband (blue bars: control, green bars: test) and heterozygous carrier status for the same in both the parents (proband-upper panel, mother-middle panel, father-lower panel).

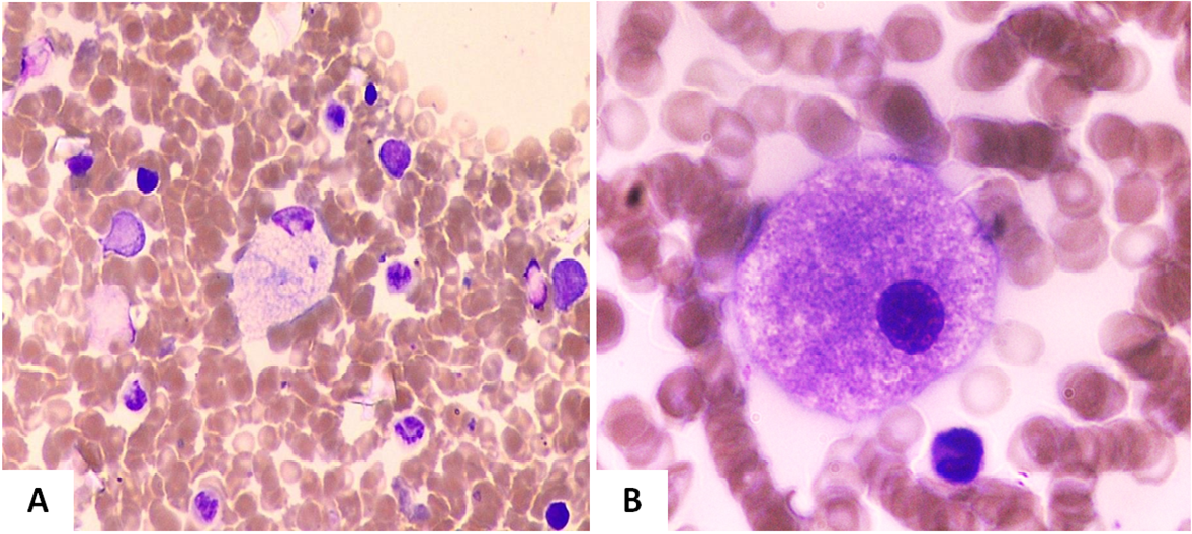


Figure 1 .

Author Manuscript




Figure 2 .

Author Manuscript

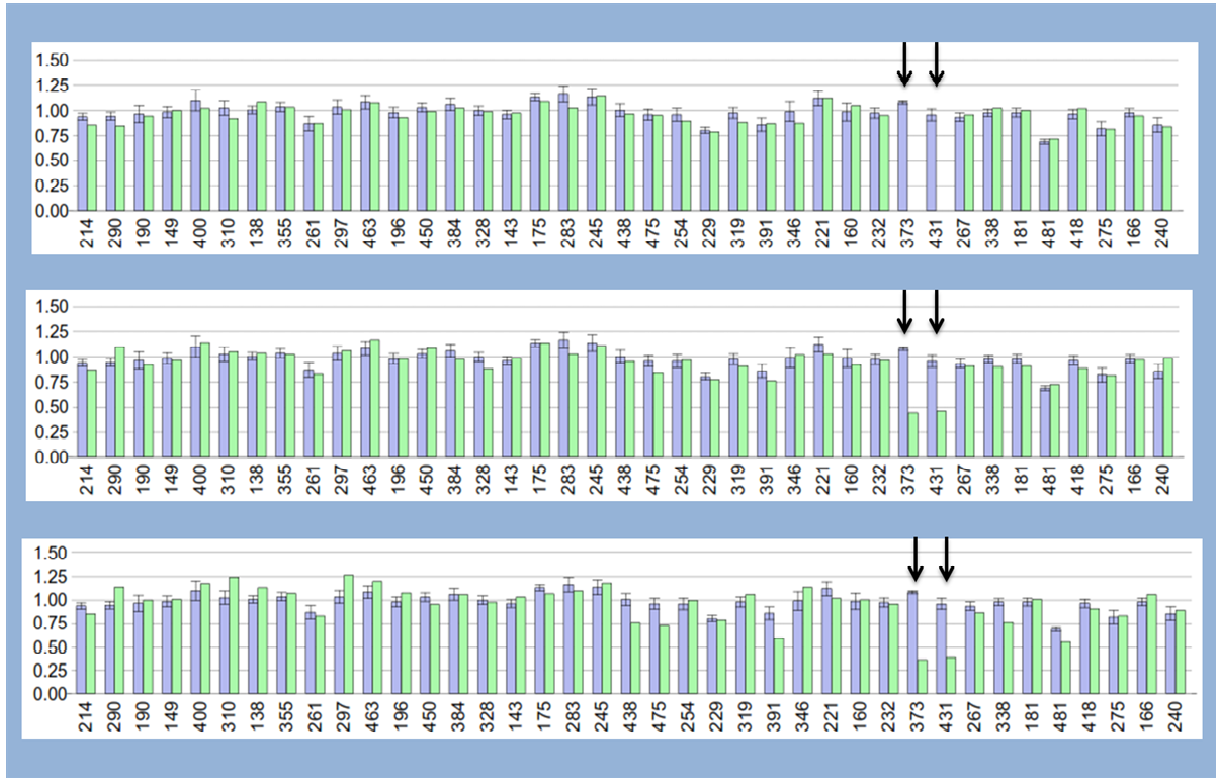


Figure 3 .

Author Manuscript