

# Sonography of Partial-Thickness Tears of the Distal Triceps Brachii Tendon

Ryan Downey, MD, Jon A. Jacobson, MD, David P. Fessell, MD, Nghi Tran, MD, Yoav Morag, MD, Sung Moon Kim, MD



Video online at [journals.ultrasoundmed.org](http://journals.ultrasoundmed.org)

**Objectives**—The purpose of this study was to retrospectively characterize the sonographic appearance of partial-thickness distal triceps brachii tendon tears.

**Methods**—After Institutional Review Board approval, sonographic records were searched for patients who had an unequivocal partial-thickness triceps tendon tear at surgery or magnetic resonance imaging. Sonograms were retrospectively characterized for tendon discontinuity of the superficial or deep layers, tendon retraction, osseous fracture fragments, and joint effusion. Imaging findings were then compared with clinical, imaging, and surgical results.

**Results**—Five patients had a partial-thickness distal triceps brachii tendon tear at surgery (n = 4) or magnetic resonance imaging (n = 1). All cases only involved the superficial tendon layer (combined long and lateral heads) with retraction of a fractured olecranon enthesophyte fragment. The deep tendon layer (medial head) was intact in all cases with no joint effusion.

**Conclusions**—Partial-thickness distal triceps brachii tendon tears have a characteristic appearance with selective superficial tendon retraction and olecranon enthesophyte avulsion fracture.

**Key Words**—sonography; trauma; triceps brachii

Elbow injuries are common athletic injuries, especially in throwing and racket sports.<sup>1</sup> Although relatively infrequent,<sup>2</sup> tears of the triceps brachii tendon can result in considerable disability.<sup>3</sup> Clinical diagnosis of this type of injury is difficult and oftentimes inaccurate, especially in the acute setting, and imaging evaluation is often necessary.<sup>4,5</sup>

Radiography is usually the first imaging modality obtained in the setting of acute elbow injury. Although it provides excellent assessment of the osseous structures and can often discern the presence of an elbow joint effusion, evaluation of soft tissue structures is limited. Magnetic resonance imaging (MRI) has been used in this setting because the exquisite soft tissue contrast and multiplanar imaging capability make MRI well suited to diagnose triceps brachii tendon tears.<sup>6</sup> Although sonography has been effectively used to image other tendinous structures in the body, little is described about the sonographic diagnosis of triceps brachii tendon tears. To our knowledge, sonographic descriptions of triceps brachii tendon tears are limited to sporadic case reports in the literature.<sup>7-9</sup>

Received March 31, 2011, from the Department of Radiology, University of Michigan, Ann Arbor, Michigan USA. Revision requested April 20, 2011. Revised manuscript accepted for publication April 29, 2011.

Address correspondence to Jon A. Jacobson, MD, Department of Radiology, University of Michigan, 1500 E Medical Center Dr, TC-2910L, Ann Arbor, MI 48109 USA.

E-mail: [jjacobsn@mich.edu](mailto:jjacobsn@mich.edu).

## Abbreviations

MRI, magnetic resonance imaging

At our institution, sonography is commonly used to evaluate tendon injuries, including the triceps brachii tendon. We have noted interesting findings in the setting of distal triceps tendon tears, particularly olecranon fracture fragments and isolated tears of the superficial aspect of the triceps tendon. The purpose of this study was to retrospectively characterize the sonographic appearance of partial-thickness distal triceps brachii tendon tears.

## Materials and Methods

### *Patients*

Institutional Review Board approval was obtained before commencing the study, and informed consent was waived. The radiology information system computer database of sonographic reports from January 2001 through September 2009 was searched using the key word “triceps,” which yielded 99 reports describing triceps brachii tendon abnormalities, 30 of which described triceps brachii tendon tears. The electronic medical records for these 30 patients were reviewed, revealing 8 patients who subsequently underwent surgical repair. The reports for other imaging studies occurring within 6 months of the original sonographic study, including MRI and conventional radiography, were also reviewed, as well as all clinical and surgical results. Patients were only included if they had unequivocal surgical confirmation of a partial-thickness distal triceps brachii tendon tear or, in the situation of an ambiguous surgical report, the presence of an unequivocal distal triceps brachii tear on correlative MRI. An exclusion criterion was the presence of elbow arthroplasty. This process resulted in a final group of 5 patients.

### *Image Evaluation*

Sonograms were retrospectively reviewed by a fellowship-trained musculoskeletal radiologist and a third-year radiology resident in consensus. The sonograms of the triceps tendon were assessed for the following: tendon discontinuity (involving the superficial, deep, or both superficial and deep layers of the triceps tendon), the length of tendon retraction if present from the distal portion of the torn tendon fibers to the olecranon, the presence or absence of an associated osseous fracture fragment (characterized as echogenic and shadowing), also noting its distance from the olecranon process and size, and finally, the presence or absence of a joint effusion. Imaging findings were then compared with clinical and surgical results as well as other imaging findings. Patients were imaged with sonography as part of routine patient care with high-resolution linear transducers (8–17 MHz) and ultrasound equipment

(iU22 and HDI 5000; Philips Healthcare, Bothell, WA; and LOGIQ 9 and E9; GE Healthcare, Milwaukee, WI) by 1 of 9 fellowship-trained musculoskeletal radiologists at our institution (range of musculoskeletal sonography experience, 2–15 years). Both static and cine images of the distal triceps brachii tendon were acquired from a posterior approach with the elbow in flexion.

## Results

The study group consisted of 5 patients (all male) with an unequivocal partial-thickness tear at surgery ( $n = 4$ ) or MRI ( $n = 1$ ). The patients had an average age of 51 years (range, 39–65 years) and a median interval from sonography to surgery of 10 days (range, 6–18 days). The times from injury to sonographic examination in the 5 patients were 1, 4, 6, 11, and 42 days, respectively (average, 13 days). The mechanism of injury was direct impact during a fall in 2 cases, injury while playing a sport in 2 cases (golf and judo), and reaching for doorknob during a fall in 1 case. Surgical findings ( $n = 4$ ) or MRI ( $n = 1$ ) revealed a partial-thickness tear of the superficial aspect of the distal triceps brachii tendon.

Retrospective review of the sonograms showed tears isolated to the superficial layer of the triceps tendon in all 5 cases with the deep layer intact (Figures 1–3). Every case was also associated with an avulsed osseous olecranon bone fragment with a mean size of 1.4 cm (range, 1.2–1.9 cm) and a mean distance of retraction of 2.9 cm (range, 2.4–3.8 cm) on sonography with the elbow in flexion. A joint effusion was absent in every case. All patients had conventional radiography after the injury, which showed the avulsed enthesophyte corresponding to the ossific fragment seen on sonography. The patient with MRI showed an isolated tear of the superficial tendon with retraction of an osseous fragment and an intact deep tendon layer, correlating with the sonographic findings. Of the 25 cases of triceps tendon abnormalities on sonography that did not go to surgery, sonography showed partial-thickness tears in 100% (25 of 25) and full-thickness tears in 0% (0 of 25).

## Discussion

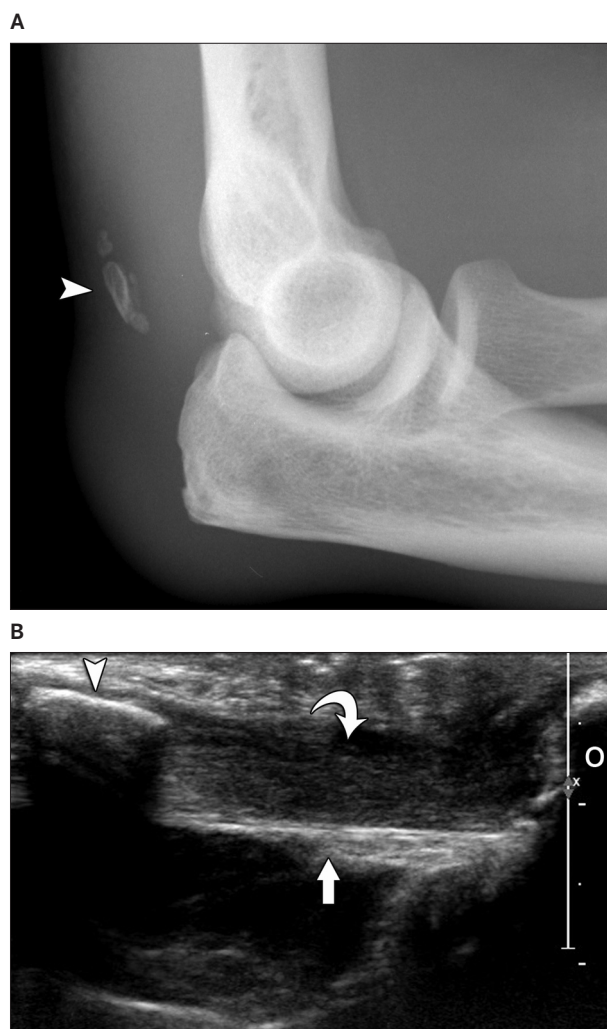
Clinical assessment of distal triceps brachii tendon tears can be challenging, and imaging is often used in the initial evaluation of suspected triceps brachii tendon injuries. The results of this study show that partial-thickness tears of the triceps brachii tendon have a characteristic appearance on sonography. In each patient, the superficial layer of the distal triceps brachii tendon was disrupted and retracted with

an avulsion fracture fragment, whereas the deep layer remained intact, representing partial-thickness tears at surgery and MRI.

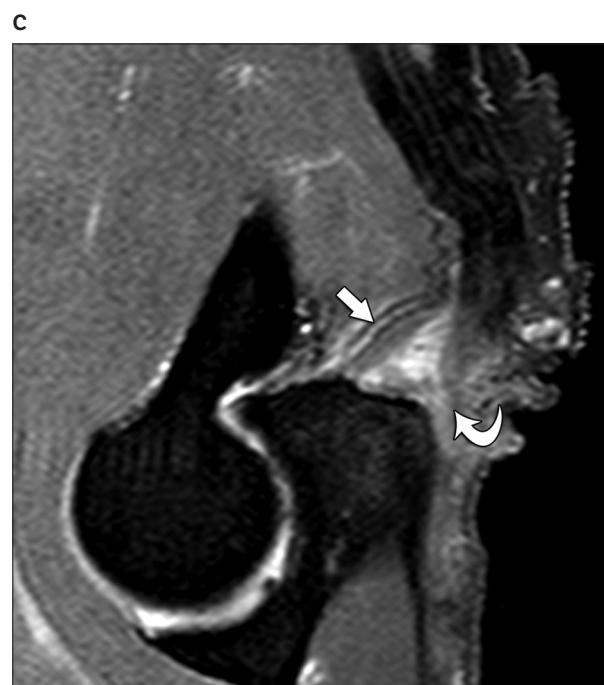The occurrence of partial-thickness triceps brachii tears selectively involving the superficial layer of the triceps may be explained by the unique anatomy of the distal tendon insertion on the olecranon. The triceps brachii is composed of 3 heads. Proximally, the long head originates from the infraglenoid tubercle of the scapula; the lateral head originates from the proximal humeral diaphysis and lateral intermuscular septum; and the medial head originates from the mid humeral diaphysis and medial intermuscular septum. Distally, the triceps brachii tendon inserts onto the olecranon with some fibers extending over the anconeus to the deep fascia of the forearm. Looking more closely at the distal triceps brachii tendon insertion, the long and lateral heads combine to form a relatively su-

perficial tendon that inserts on the olecranon process of the proximal ulna.<sup>10,11</sup> In contrast, the medial head courses deep to the combined long and lateral heads of the triceps with a very short tendon attachment onto the proximal ulna.<sup>10,11</sup> Several studies have confirmed this anatomy and showed that the medial head tendon is distinct from and deep to the common tendon of the long and lateral heads, although a common insertion exists at the distal tendon footprint on the proximal olecranon.<sup>10</sup> This combined tendon footprint is located 12 to 20 mm from the proximal tip of the olecranon process.<sup>12</sup>

The results of this study show that the partial-thickness tears of the distal triceps brachii tendon represented isolated avulsions of combined long and lateral heads seen as superficial tendon tears with avulsion fracture fragments. Indeed, the sonograms showed the normal and intact hypoechoic medial head musculature and hyperechoic tendon deep to the superficial tendon tear. In addition, the intact deep medial head tendon attachment in our cases at the proximal olecranon correlates with the location of the



**Figure 1.** Images from a 61-year-old man who injured his elbow while playing golf 1 day previously with a partial-thickness tear of the distal triceps brachii tendon. Lateral radiograph (**A**), sonogram in the long axis to the triceps brachii tendon (**B**), and T2-weighted magnetic resonance image (**C**) show an olecranon (O) avulsion fracture fragment (arrowheads) at the site of the retracted superficial tendon tear (lateral and long heads; curved arrows) with an intact deep tendon (medial head; arrows).

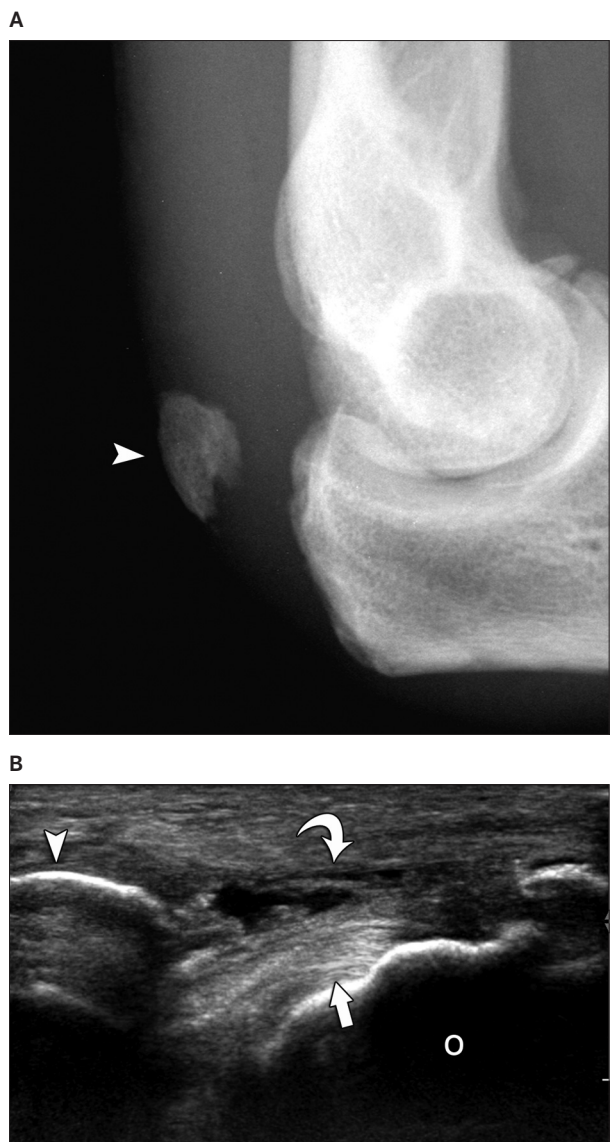


proximal aspect of the tendon footprint described in cadaveric studies.<sup>12</sup> Although partial-thickness distal triceps brachii tendon tears involving the deep aspect have been described in the literature, there are no studies to our knowledge that describe partial-thickness tears only involving the superficial tendon.<sup>11,12</sup> During sonography, dynamic evaluation during minimal passive flexion and extension showed

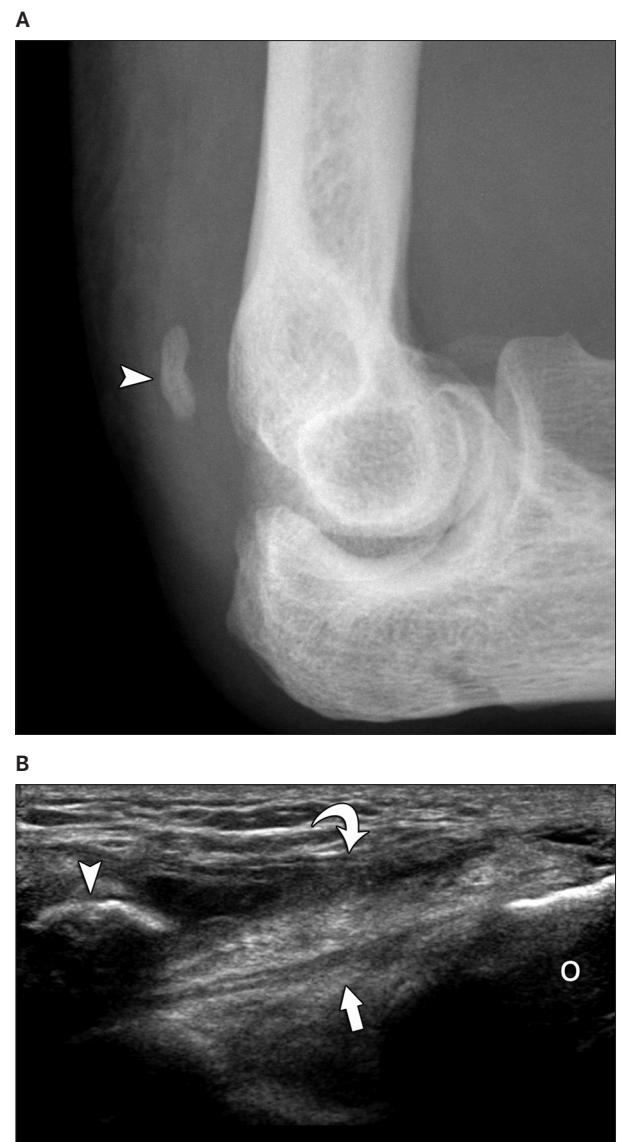
movement of the retracted superficial tendon and bone fragment away from the olecranon and intact deep tendon contiguous with the olecranon (Video 1).

Although our study consisted of 5 unequivocal cases of partial-thickness distal triceps tendon tears, available information regarding the excluded 25 cases in which tears were described on the sonographic reports deserves men-

**Figure 2.** Images from a 39-year-old man who injured his elbow during judo exercise 11 days previously with a surgically proven partial-thickness tear of the distal triceps brachii tendon. Lateral radiograph (A) and sonogram in the long axis to the triceps brachii tendon (B) show an olecranon (O) avulsion fracture fragment (arrowheads) at the site of the retracted superficial tendon tear (lateral and long heads; curved arrow) with an intact deep tendon (medial head; arrow).



**Figure 3.** Images from a 59-year-old man who injured his elbow during a fall 18 days previously with a surgically proven partial-thickness tear of the distal triceps brachii tendon. Lateral radiograph (A) and sonogram in the long axis to the triceps brachii tendon (B) show an olecranon (O) avulsion fracture fragment (arrowheads) at the site of the retracted superficial tendon tear (lateral and long heads; curved arrow) with an intact deep tendon (medial head; arrow). Note overlying olecranon bursitis in A.



tion. Three of these 25 cases did have surgery; 1 of these was excluded because of the presence of elbow arthroplasty. The other 2 cases were excluded because they had ambiguous surgical records. In these 2 cases, the surgical reports only commented on the superficial central tendon tear without mention of the deeper tissues; of interest, sonography clearly showed intact deep tendon layers in these 2 cases. Of the remaining 22 patients in whom sonography showed distal triceps brachii tendon tears but who did not have surgery, every case was a partial-thickness tear on imaging. These findings suggest that the incidence of partial-thickness tears is much higher than that of full-thickness tears if distal triceps tears are accurately characterized at imaging and surgery, although additional studies are needed for confirmation. It is possible that full-thickness tears were obvious clinically and therefore did not undergo sonographic evaluation and were not identified in our retrospective search; however, this possibility is unlikely given that no full-thickness tears were shown on sonography at our institution over approximately 8 years, with more than 3000 diagnostic musculoskeletal sonographic examinations routinely performed each year.

Another interesting observation was that every patient in our study group had an avulsed bone fragment of the proximal ulna. Radiographs showed that this bone fragment corresponded to an enthesophyte rather than an osseous fragment from the olecranon process because no underlying olecranon donor site or defect was present. In every case, the bone fragment was an average of 1.2 cm (range, 0.4–1.9 cm) in length with retraction of at least 2.4 cm proximal to the olecranon (range, 2.4–3.8 cm), as seen on sonography in elbow flexion. It is possible that the enthesophyte was the weak link in the muscle-tendon-enthesophyte-bone connection. Because enthesophytes occur in response to underlying tendon degeneration, it is possible that tendon degeneration was the primary cause of the enthesophyte avulsion. Indeed, 3 of the 5 patients had documented symptoms in the distal triceps brachii before the trauma that caused the avulsion, a condition that has also been described in the literature.<sup>3,13</sup> The average interval from injury to sonographic examination was 13 days, with 3 of 5 patients imaged within 1 week of injury. Although heterotopic ossification may be considered in the differential diagnosis, the interval between injury and sonography as well as the location of the ossification within the distal stump of the torn tendon suggests avulsion fragment.

One additional interesting clinical observation was that 4 of the 5 patients had a clinical history of bursitis. Because the elbows were not imaged before the injury, it is

unclear whether patients actually had bursitis or whether the symptoms were related to the distal tendon and clinically assumed to represent bursitis; however, bursitis was described in 60% of the patients (3 of 5) at surgery. Also of interest was that 60% of the patients (3 of 5) had blind steroid injections into the olecranon bursa before the triceps injury. Although prior steroid injections have been associated with distal triceps tendon tears, it is unclear that the steroid injections caused the tear given the presence of enthesophyte avulsion rather than a tendon tear.<sup>14</sup>

Our study was limited by its small sample size; however, the final sample size was the result of using surgery as an inclusion criterion. The use of surgery as an inclusion criterion also potentially added a selection bias because more symptomatic or substantial abnormalities were more likely to have surgical evaluation and treatment. Last, there were limitations intrinsic to retrospective studies.

In conclusion, partial-thickness tears of the triceps brachii tendon have a characteristic appearance on sonography with a retracted superficial layer attached to an enthesophyte fragment and an intact deep layer. Given the presence of an avulsed olecranon enthesophyte in every case, identification of this finding on conventional radiographs should raise concern for a partial-thickness triceps brachii tendon tear.

## References

1. Safran MR. Elbow injuries in athletes: a review. *Clin Orthop Relat Res* 1995; 310:257–277.
2. Anzel SH, Covey KW, Weiner AD, Lipscomb PR. Disruption of muscles and tendons: an analysis of 1,014 cases. *Surgery* 1959; 45:406–414.
3. Mair SD, Isbell WM, Gill TJ, Schlegel TF, Hawkins RJ. Triceps tendon ruptures in professional football players. *Am J Sports Med* 2004; 32:431–434.
4. van Riet RP, Morrey BF, Ho E, O'Driscoll SW. Surgical treatment of distal triceps ruptures. *J Bone Joint Surg Am* 2003; 85-A:1961–1967.
5. Sharma SC, Singh R, Goel T, Singh H. Missed diagnosis of triceps tendon rupture: a case report and review of literature. *J Orthop Surg (Hong Kong)* 2005; 13:307–309.
6. Tiger E, Mayer DP, Glazer R. Complete avulsion of the triceps tendon: MRI diagnosis. *Comput Med Imaging Graph* 1993; 17:51–54.
7. Kaempffe FA, Lerner RM. Ultrasound diagnosis of triceps tendon rupture: a report of 2 cases. *Clin Orthop Relat Res* 1996; 332:138–142.
8. Sisson C, Nagdev A, Tirado A, Murphy M, Suner S. Ultrasound diagnosis of traumatic partial triceps tendon tear in the emergency department. *J Emerg Med* 2011; 40:436–438.
9. Harris PC, Atkinson D, Moorehead JD. Bilateral partial rupture of triceps tendon: case report and quantitative assessment of recovery. *Am J Sports Med* 2004; 32:787–792.

10. Belentani C, Pastore D, Wangwinyuvirat M, et al. Triceps brachii tendon: anatomic-MR imaging study in cadavers with histologic correlation. *Skeletal Radiol* 2009; 38:171–175.
11. Madsen M, Marx RG, Millett PJ, Rodeo SA, Sperling JW, Warren RF. Surgical anatomy of the triceps brachii tendon: anatomical study and clinical correlation. *Am J Sports Med* 2006; 34:1839–1843.
12. Athwal GS, McGill RJ, Rispoli DM. Isolated avulsion of the medial head of the triceps tendon: an anatomic study and arthroscopic repair in 2 cases. *Arthroscopy* 2009; 25:983–988.
13. Sollender JL, Rayan GM, Barden GA. Triceps tendon rupture in weight lifters. *J Shoulder Elbow Surg* 1998; 7:151–153.
14. Yeh PC, Dodds SD, Smart LR, Mazzocca AD, Sethi PM. Distal triceps rupture. *J Am Acad Orthop Surg* 2010; 18:31–40.