

# Recurrent Hyperparathyroidism Due to a Novel *CDC73* Splice Mutation

Namita Ganesh Hattangady,<sup>1\*</sup> Tremika Le-Shan Wilson,<sup>1\*</sup> Barbra Sue Miller,<sup>2</sup> Antonio Marcondes Lerario,<sup>1</sup> Thomas James Giordano,<sup>1,3</sup> Palak Choksi,<sup>1</sup> and Tobias Else<sup>1</sup>

<sup>1</sup>Department of Internal Medicine, Division of Metabolism, Endocrinology, and Diabetes, University of Michigan, Ann Arbor, MI, USA

<sup>2</sup>Department of Surgery, Division of Endocrine Surgery, University of Michigan, Ann Arbor, MI, USA

<sup>3</sup>Department of Pathology, University of Michigan, Ann Arbor, MI, USA

## ABSTRACT

The recognition of hereditary causes of primary hyperparathyroidism (pHPT) is important because clinical care and surveillance differ significantly between sporadic and hereditary pHPT. In addition, the increasing number of genetic tests poses a challenge to classify mutations as benign or pathogenic. Functional work-up of variants remains a mainstay to provide evidence for pathogenicity. We describe a 52-year-old male patient with recurrent pHPT since age 35 years. Despite several neck surgeries with complete parathyroidectomy, he experienced persistent pHPT, necessitating repeated surgery for a forearm autotransplant, which finally resulted in unmeasurable parathyroid hormone (PTH) levels. Genetic testing revealed a new *CDC73* variant (c.238-8G>A [IVS2-8G>A]), initially classified as a variant of uncertain significance. Parathyroid tissue from the initial surgeries showed loss of heterozygosity. Using an RT-PCR approach, we show that the mutation leads to the use of a cryptic splice site in peripheral mononuclear cells. In addition, a minigene approach confirms the use of the cryptic splice site in a heterologous cell system. The novel c.238-8G>A *CDC73* variant activates a cryptic splice site, and the functional data provided justify the classification as a likely pathogenic variant. Our results underscore the importance of functional work-up for variant classification in the absence of other available data, such as presence in disease-specific databases, other syndromic clinical findings, or family history. In addition, the presented case exemplifies the importance to consider a hereditary condition in young patients with pHPT, particularly those with multi-gland involvement. © 2017 American Society for Bone and Mineral Research.

**KEY WORDS:** HYPERPARATHYROIDISM; PARAFIBROMIN; *CDC73*; SPLICE MUTATION

## Introduction

Primary hyperparathyroidism (pHPT) is a common disorder involving complications of the skeletal, renal, neurocognitive, and cardiovascular systems.<sup>(1,2)</sup> pHPT is caused by benign adenomas, multiglandular hyperplasia, and rarely, parathyroid carcinoma. pHPT is usually sporadic but also occurs as part of familial syndromes, particularly in young patients (in ~10% cases),<sup>(3)</sup> including multiple endocrine neoplasia syndromes and hyperparathyroidism-jaw tumor (HPT-JT) syndrome.<sup>(1-4)</sup>

Herein, we present a patient with pHPT and recurrent parathyroid disease, with a new germline splice site mutation in the gene Cell Division Cycle 73 (*CDC73*, accession number *NM\_024529*). The *CDC73* gene encodes the 531 amino acid parafibromin tumor suppressor protein. Missense, frameshift mutations and deletions in *CDC73* have been reported in autosomal dominant familial HPT-JT.<sup>(5-7)</sup> HPT-JT is characterized by ossifying fibromas in the jaws and pHPT but also includes

uterine fibroids, renal disease, and renal tumors. pHPT-JT also bares the risk of progressing to parathyroid cancer.

Clinical genetic testing often yields variants of uncertain significance. Pathogenicity cannot be determined only by data available in the literature, family history, epidemiological and disease-specific databases, or in silico prediction mechanisms, all of which are often uncertain. Functional evaluation of the mutation, its effect on transcription, translation, and protein function, remains a major resource for solid evidence of pathogenicity.

Our study details the effects of a novel splice site mutation in *CDC73* on parafibromin protein translation and investigates loss of heterozygosity phenomenon in a patient with recurrent pHPT.

## Clinical Case

The index case was a 52-year-old male with a longstanding history of kidney stones and diagnosed with pHPT at age

Received in original form December 14, 2016; revised form March 27, 2017; accepted April 5, 2017. Accepted manuscript online April 10, 2017.

Address correspondence to: Tobias Else, MD, Department of Internal Medicine, Division of Metabolism, Endocrinology, and Diabetes, University of Michigan, Ann Arbor, MI 48109, USA. E-mail: telse@umich.edu

\*NGH and TL-SW contributed equally to this work.

Additional Supporting Information may be found in the online version of this article.

Journal of Bone and Mineral Research, Vol. 32, No. 8, August 2017, pp 1640–1643

DOI: 10.1002/jbmr.3149

© 2017 American Society for Bone and Mineral Research

35 years. The initial surgery removed two hyperplastic parathyroid glands causing normalization of calcium levels. Seven years later, the patient had recurrent pHPT and underwent removal of two adenomatous glands and auto-transplantation to the forearm. Since then, he had recurrence of pHPT and two unsuccessful surgeries (3 and 6 years post-implantation) to reduce parathyroid tissue in the forearm. During regular surveillance, he was finally found to have several small hypoechoic areas in the proximal brachioradialis (Supplemental Fig. S1). Post-surgery, parathyroid tissue and parathyroid hormone (PTH) levels were less than the measurable range after removal. A small amount of parathyroid tissue was implanted into a subcutaneous area. He did not have a history of jaw tumors. Although the proband's family history was negative for pHPT, jaw tumors, or kidney lesions, the mother did undergo a hysterectomy presumably because of uterine fibroids. Initial genetic testing did not reveal a mutation in *MEN1* but revealed the presence of a germline intronic variant of uncertain significance (VUS) in *CDC73* c.238-8G>A (IVS2-8G>A).

## Materials and Methods

### Plasmids

Wild-type and mutant *CDC73* DNA strings were synthesized (GeneArt, Thermo Fisher, Waltham, MA, USA) and subcloned into the pDUP4-1 minigene using *Apal* and *BglII/BamHI* sites. The mutant *CDC73* string included the G>A mutation 6 bps upstream of exon 3. Primer details are provided in Supplemental Table S1.

### RNA and DNA isolation

RNA and DNA were isolated using the RNeasy Plus Mini Kit (Qiagen, Valencia, CA, USA) and Wizard Genomic DNA Purification Kit (Promega, Madison, WI, USA), respectively. Genomic DNA from formalin-fixed paraffin-embedded (FFPE) tissue was purified using the All Prep DNA/RNA FFPE Kit (Qiagen). Complementary DNA was generated from RNA using the High Capacity Reverse Transcriptase Kit (Life Technologies, Carlsbad, CA, USA).

### PCR and sequence analyses

All PCR amplifications were performed using the HotStarTaq DNA Polymerase Kit (Qiagen) and the touch-down protocol as described elsewhere.<sup>(8)</sup> Primer sequences are provided in Supplemental Table S1.

### Immunohistochemistry

Sections from formalin-fixed, paraffin-embedded normal thyroid and superior and inferior hyperparathyroid tissues were incubated with primary mouse monoclonal anti-para-fibromin antibody (Santa Cruz Biotechnology, Dallas, TX, USA) followed by secondary antibody (En Vision reagent, Dako, Carpinteria, CA, USA). Slides were visualized using 3,3'-diaminobenzidine tetrahydrochloride and H<sub>2</sub>O<sub>2</sub> and counterstained with hematoxylin.

### Human subject research

The patient consented to the Cancer Genetics Registry (IRB approval, HUM 00043430).

## Results

### Effect of the mutation on RNA splicing

Analysis of peripheral blood mRNA identified that the wild-type and mutant transcripts were both expressed (Fig. 1A), the mutant transcript being spliced 6 bp upstream to the exon. In vitro functional analysis of the splice variants was performed utilizing the pDUP4-1 minigene system (Fig. 1D, E). Cells expressing the pDUP4-1/Mutant *CDC73* displayed a splice variant of *CDC73*, which was 6 base pairs longer than the wild type *CDC73* mRNA (Fig. 1E).

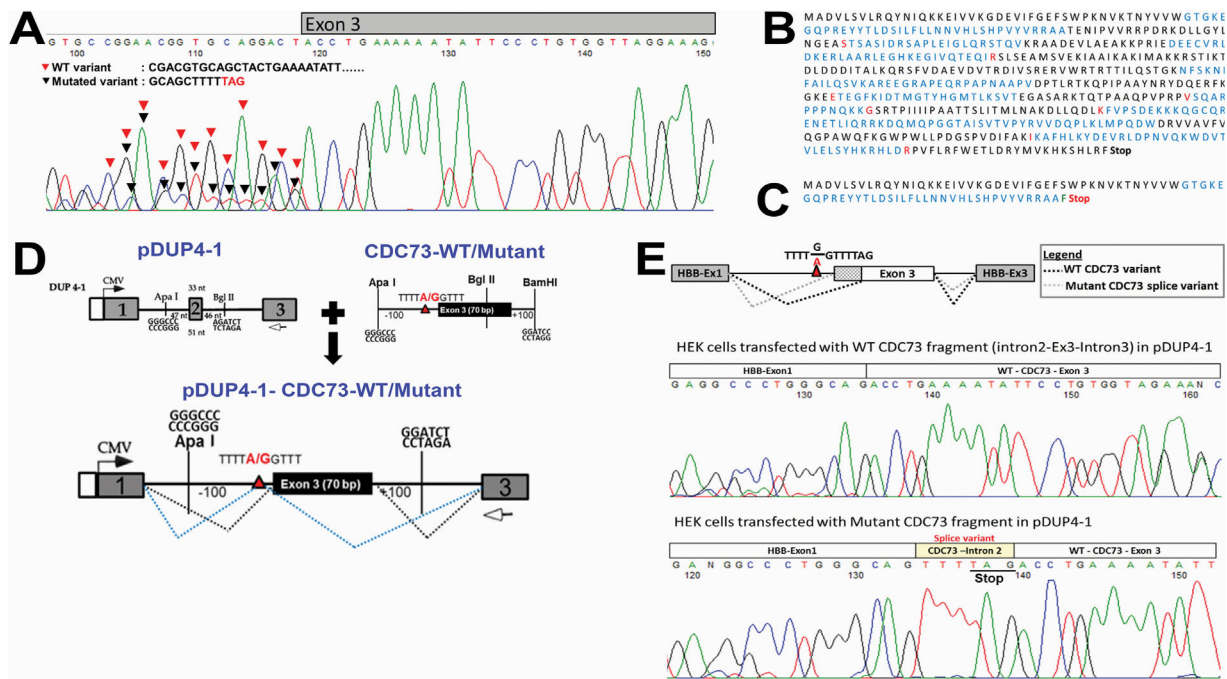
### Loss of heterozygosity (LOH)

LOH analysis was conducted in the resected hyperparathyroid tissue and in the unaffected, normal thyroid tissue. Genomic DNA sequence analysis from formalin-fixed paraffin-embedded parathyroid tumors (Fig. 2B, C) exhibited LOH, while it was preserved in control thyroid tissue (Fig. 2A). Immunostaining confirmed para-fibromin in thyroid tissue (Fig. 2E) and loss of expression in the parathyroid tissues (Fig. 2F, G).

## Discussion

Herein we identified a patient with recurrent pHPT harboring a potential splice site mutation in the tumor suppressor *CDC73* (c.238-8G>A). This mutation has not been reported in other patients, nor is it present in ExAC or 1000 genomes. Lack of functional data characterized it as a "variant of uncertain significance." Recurrent pHPT despite polyglandular resection was suggestive of a pathogenic nature of the variant. Peripheral blood analysis identified the variant as present in the germline, potentially causing a 6 bp premature splicing of exon 3, resulting in premature protein translation. The use of the cryptic splice site during post-transcriptional modification was confirmed by RT-PCR of RNA from peripheral blood as well as in an in vitro minigene approach. Finally, we show that all parathyroid tumors showed LOH and absence of para-fibromin protein. Together these data provide sufficient evidence to classify this variant as pathogenic.

The classification and interpretation of observed variants poses a significant challenge. The American College of Medical Genetics and Genomics has presented a useful system to classify germline genetic variants,<sup>(9)</sup> using clinical observations, segregation, databases, in silico prediction, and functional data. Segregation analysis is of limited value in small families or in the absence of any other clearly affected family members as in the presented case. Within our patient's pedigree there was no individual with any parathyroid abnormality, only a report on his mother, who had a hysterectomy, likely because of uterine fibroids, which are also frequent in the general population. Therefore, functional analysis proves an exceptionally useful tool to provide evidence for pathogenicity of a germline variant. Unfortunately, no other family members were available for testing of the new *CDC73* variant. However, clinical cascade testing for asymptomatic family members should always be recommended in patients diagnosed with a pathogenic germline variant. In case of pHPT associated with *MEN1* or *MEN2*, at-risk family members will benefit from surveillance for other associated manifestations, such as neuroendocrine, chromaffin, or pituitary tumors. Although there is no general surveillance protocol for *CDC73*-related disorders, yearly evaluation of



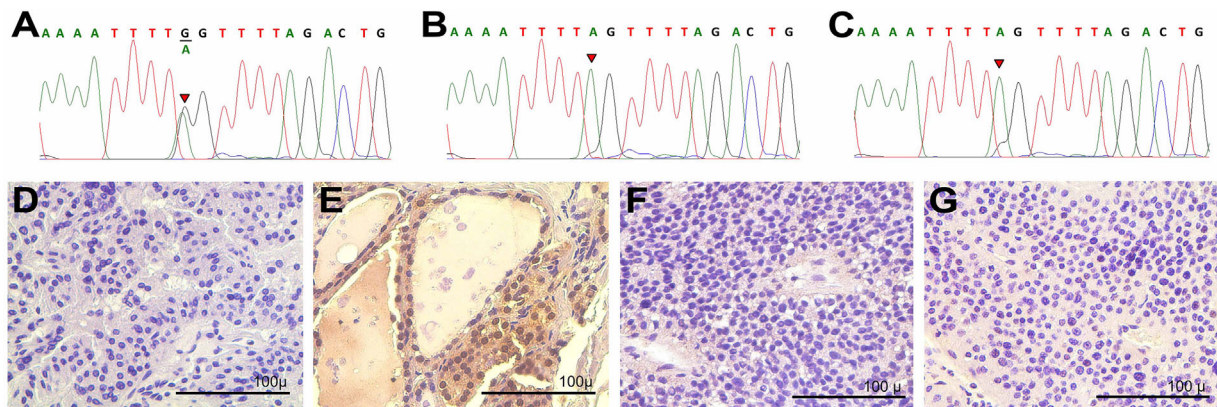
**Fig. 1.** (A) Analyses of mRNA from peripheral blood indicated that both predicted (wild-type and mutant) transcripts were expressed. (B) Wild-type and (C) predicted mutant *CDC73* transcripts. (D) Subcloning strategy to generate minigenes for WT and mutant *CDC73*. (E) In vitro characterization of the splice variants. The genetic fragment containing the wild-type and mutant intronic region and its successive exon were subcloned into the *pDUP4-1* minigene vector and transfected in human embryonic kidney cells. Cells expressing the *pDUP4-1*/Mutant *CDC73* displayed a splice variant of *CDC73*, which was 6 base pairs longer than the wild-type *CDC73* mRNA causing the inclusion of a premature “stop” codon.

parathyroid function and physical exam for jaw tumors should be considered. In addition, baseline ultrasound of the kidneys should be entertained. Furthermore, knowledge of a pathogenic *CDC73* mutation in an individual patient can lead to a lower threshold for work-up of uterine fibroids or other tumors possibly associated with the disorder, keeping in mind the likely not fully defined associated tumor risks and penetrance with *CDC73* pathogenic variants.

A recent study has shown that predisposing germline mutations can be found in up to ~10% of young patients

with pHPT.<sup>(3)</sup> Treatment of patients with hereditary predisposition to pHPT such as *MEN1* or *CDC73*-related disorders is challenging, and genetic testing can be advantageous in order to plan the right surgical procedure.<sup>(8)</sup> In hereditary pHPT, it should be considered to leave tissue in place, where it can be more easily surveilled and explored in the future.<sup>(10)</sup>

When performing surgery in patients with four-gland parathyroid disease or hereditary predisposition to pHPT, it is preferable to perform subtotal parathyroidectomy as opposed to total parathyroidectomy with autotransplantation, leaving



**Fig. 2.** Loss of heterozygosity across tissues. PCR amplification and Sanger sequencing of genomic DNA from formalin-fixed paraffin-embedded (FFPE) left superior and inferior parathyroid tumor tissues showed loss of heterozygosity (B, C), while it was preserved in control thyroid tissue (A). Immunostaining for parafibromin confirmed protein expression in thyroid tissue (E) and loss of expression in the parathyroid adenoma tissues (F, G) relative to the negative control (D).

the equivalent of a single normal parathyroid gland. This approach avoids complete hypoparathyroidism and longer periods of hypocalcemia as well as the potential implantation of autonomously functioning and potentially malignant parathyroid tissue. If necessary, parathyroid autotransplantation is best accomplished by creation of two intramuscular (eg, brachioradialis muscle) or subcutaneous pockets and placement of 20 to 30 mg of parathyroid tissue minced into 1 to 2 mm pieces into these pockets. Any remaining or autotransplanted parathyroid should be marked for future reference. Future experience will determine whether recombinant PTH will present an alternative for treatment of hypoparathyroidism in the setting of transient or permanent hypoparathyroidism.

Additionally, it remains important to define the penetrance of associated pathologies in order to streamline preventive surveillance in gene carriers. Our patient was diagnosed before the availability of routine genetic testing and after a long history of pHPT and surgical management. However, our case underscores the importance and eventual success of continuous follow-up and repeated surgery.

In summary, we show that this novel intronic *CDC73* mutation, c.238-8G>A, activates a cryptic splice site and underwent LOH in this patient's parathyroid adenomas. Together these findings provide strong in vitro evidence to reclassify this mutation as a pathogenic variant confirming our patient's diagnosis of *CDC73*-related disorder. In the future, genetic testing for young patients with pHPT will likely be beneficial in order to aid in the right treatment approaches.

## Disclosures

---

All authors state that they have no conflicts of interest.

## Acknowledgments

---

TE is supported by the NIH (1R01DK106618-01) and AHA (14SDG17990000). NGH is supported by the AHA

(6POST29900003). We thank the University of Michigan DNA Sequencing Core for performing sequencing analysis.

Authors' roles: TE, NGH, TL-SW, PC and AML designed the study, performed the research and analyzed the data. BSM, PC, TJG and TE provided clinical data. TE and NGH wrote the manuscript. All authors reviewed and contributed towards the final manuscript.

## References

---

1. Carling T. Molecular pathology of parathyroid tumors. *Trends Endocrinol Metab.* 2001;12(2):53–8.
2. Duan K, Gomez Hernandez K, Mete O. Clinicopathological correlates of hyperparathyroidism. *J Clin Pathol.* 2015;68(10):771–87.
3. Starker LF, Akerstrom T, Long WD, et al. Frequent germ-line mutations of the *MEN1*, *CASR*, and *HRPT2/CDC73* genes in young patients with clinically non-familial primary hyperparathyroidism. *Horm Cancer.* 2012;3(1–2):44–51.
4. Westin G, Bjorklund P, Akerstrom G. Molecular genetics of parathyroid disease. *World J Surg.* 2009;33(11):2224–33.
5. Rekik N, Ben Naceur B, Mnif M, et al. Hyperparathyroidism-jaw tumor syndrome: a case report. *Ann Endocrinol (Paris).* 2010;71(2):121–6.
6. Masi G, Iacobone M, Sinigaglia A, et al. Characterization of a new *CDC73* missense mutation that impairs Parafibromin expression and nucleolar localization. *PLoS One.* 2014;9(5):e97994.
7. Bricaire L, Odou MF, Cardot-Bauters C, et al. Frequent large germline *HRPT2* deletions in a French National cohort of patients with primary hyperparathyroidism. *J Clin Endocrinol Metab.* 2013;98(2):E403–8.
8. Otto EA, Ramaswami G, Janssen S, et al. Mutation analysis of 18 nephronophthisis associated ciliopathy disease genes using a DNA pooling and next generation sequencing strategy. *J Med Genet.* 2011;48(2):105–16.
9. Richards S, Aziz N, Bale S, et al. Standards and guidelines for the interpretation of sequence variants: a joint consensus recommendation of the American College of Medical Genetics and Genomics and the Association for Molecular Pathology. *Genet Med.* 2015;17(5):405–24.
10. Mehta A, Patel D, Rosenberg A, et al. Hyperparathyroidism-jaw tumor syndrome: results of operative management. *Surgery.* 2014;156(6):1315–24; discussion 24–5.