

Review article: the diagnostic approach and current management of chylous ascites

B. Lizaola¹  | A. Bonder² | H. D. Trivedi²  | E. B. Tapper³ | A. Cardenas⁴ 

¹Department of Medicine, St. Elizabeth Medical Center, Brighton, MA, USA

²Liver Center, Department of Medicine, Beth Israel Deaconess Medical Center, Harvard Medical School, Boston, MA, USA

³Department of Gastroenterology, University of Michigan, Ann Arbor, MI, USA

⁴GI/Liver Unit, Institute of Digestive Diseases and Metabolism, University of Barcelona, Hospital Clinic and Institut d'Investigacions Biomèdiques August Pi-Sunyer (IDIBAPS), Barcelona, Spain

Correspondence

Dr. A. Cardenas, Institut de Malalties Digestives i Metabòliques, University of Barcelona, Hospital Clinic, Barcelona, Spain.
Email: acardena@clinic.ub.es

Funding information

None.

Summary

Background: Chylous ascites is rare, accounting for less than 1% of cases. An appropriate and stepwise approach to its diagnosis and management is of key importance.

Aim: To review the current diagnostic approach and management of chylous ascites.

Methods: A literature search was conducted using PubMed using the key words 'chylous', 'ascites', 'cirrhosis', 'pathophysiology', 'nutritional therapy', 'paracentesis', "transjugular intrahepatic portosystemic shunt" and "TIPSS". Only articles in English were included.

Results: Chylous ascites is caused by the traumatic or obstructive disruption of the lymphatic system that leads to extravasation of thoracic or intestinal lymph into the abdominal space and the accumulation of a milky fluid rich in triglycerides. The most common causes are malignancy, cirrhosis and trauma after abdominal surgery. This condition can lead to chyle depletion, which results in nutritional, immunologic and metabolic deficiencies. An ascitic triglyceride concentration above 200 mg/dL is consistent with chylous ascites. Treatment is based on management of the underlying cause and nutritional support.

Conclusions: Chylous ascites is mostly due to malignancy and cirrhosis in adults, and congenital lymphatic disorders in children. Treatment with nutritional optimization and management of the underlying etiology are the cornerstones of therapy. When conservative measures fail, other interventions such as octreotide/somato- statin analogues, surgical ligation, embolization and transjugular intrahepatic portosystemic shunt in patients with cirrhosis can be considered.

Blanca Lizaola and Alan Bonder are the joint first authors and contributed equally to the manuscript.

The Handling Editor for this article was Professor Stephen Harrison, and this uncommissioned review was accepted for publication after full peer-review.

1 | INTRODUCTION

Chylous ascites is defined as a milky appearing, triglyceride-rich peritoneal fluid, characterised by the presence of thoracic or intestinal lymph in the abdominal cavity.¹ Abdominal malignancy, cirrhosis, lymphatic disruption after abdominal surgery, and infections represent the leading causes in adults.² In children, congenital lymphatic abnormalities and trauma are considered the most common etiologies.³ Its incidence is not well established, however, previous data from Press et al published in 1984 indicates that it accounts for 1 per 20 000 hospital admissions overall, since then no further epidemiological studies have been performed, thus the current incidence is not well known.⁴ Chylous ascites is rich in nutrients and immunoglobulins, which become no longer biologically available after accumulating in the peritoneum. This can lead to dehydration, malnutrition, electrolyte imbalance and immunosuppression.⁵ Therefore, prompt diagnosis and treatment is warranted. Herein, we review best practices for diagnosis and conservative treatment as well as emerging therapeutic options for refractory cases of chylous ascites.

2 | METHODS

A literature search was conducted using PubMed using the key words 'chylous', 'ascites', 'cirrhosis', 'pathophysiology', 'nutritional therapy', 'paracentesis' and 'TIPSS'. Only articles in English were included.

2.1 | Pathophysiology

The underlying cause of chylous ascites is the disruption of lymphatic flow. An interconnected network moves lymph—a complex mixture of proteins, lipids/chylomicra, and immune cells—from the body to the thoracic duct where it empties into the venous circulation at the union of the left internal jugular vein and the subclavian vein. Lymph is propelled through its circuit by the active, intrinsic contraction/relaxation of lymphatic vessels and passive, external compressive forces (skeletal muscles, central venous pressure variations, respiratory movement and pulsations of adjacent arteries).⁶ Approximately half of the lymph originates in the intestine. After hydrolysis and emulsification, fatty acids and monoglycerides are converted into triglycerides, which are subsequently absorbed into the lymphatic system as chylomicrons. Hence, the milky appearance of the lymph is attributed to its high triglyceride and free fatty acid content.

Browse et al⁷ proposed three pathophysiologic mechanisms by which chylous ascites occurs (Table 1): acquired lymphatic disruption, fibrosis of the lymphatic system and congenital causes. Acquired lymphatic disruption from surgery or trauma, leads to dilation of the retroperitoneal lymphatics with subsequent drainage of lymph into the abdomen through a lymphoperitoneal fistula. This dilation of lymphatic vessels also occurs as a result of the increased

lymph production and elevated hepatic venous pressure seen in patients with cirrhosis and constrictive pericarditis. Cardiac conditions such as right heart failure and dilated cardiomyopathy lead to an increased lymphatic pressure from disrupted lymphatic drainage, thereby causing lymph stasis, lymphatic dilation and chylous ascites. The caval and hepatic venous hypertension precipitates an increment in the production of hepatic lymph.⁸ The second proposed mechanism is lymph node fibrosis, most commonly due to malignancy causing lymph flow obstruction from the gut into the cisterna chyli, resulting in leakage from the dilated subserosal lymphatics into the peritoneum. The chronic effects of a persistently elevated lymphatic pressure may lead to collagen deposition at the basement membrane of the lymphatics, impairing the intestinal mucosal absorptive capacity. This process can cause protein-losing enteropathy with malabsorption, chronic steatorrhea and malnutrition. Last, congenital causes like congenital lymphangiectasia lead to exudation and leakage of lymph through a fistula into the peritoneal cavity due to the absence of lymphatic valves.

2.2 | Etiologies

Multiple etiologies have been described as causes of chylous ascites. Traditionally, the most common causes in western countries are abdominal malignancy and cirrhosis, accounting for two-thirds of atraumatic chylous ascites cases.⁴ In developing and eastern countries, infections, such as tuberculosis and filariasis, are responsible for the majority of cases. However, Steinemann et al³ performed a systematic review of 190 patients with chylous ascites where a total of 41 different etiologies were identified. The most common cause was lymphatic anomalies (32%), a condition more prevalent in the paediatric population. Malignant diseases were the second most

TABLE 1 Chylous ascites etiologies, mechanisms and causes

Etiology	Mechanism	Causes
Acquired	Thoracic duct obstruction or disruption	Trauma/surgery Infections (TB, filariasis), radiotherapy, autoimmune (SLE, sarcoidosis)
	Increased lymph production	Cirrhosis Cardiovascular disease
Fibrosis	Invasion and disruption of the normal lymph flow	Lymphomas Neuroendocrine tumors Sarcomas Leukaemia Solid organ malignancies
Congenital	Disrupted or dilated lymphatic vessels	Lymphangiectasia Waldmann's disease
		Yellow-nail syndrome
		Klippel-Trenaunay syndrome
		Lymphangioma

TB, tuberculosis, SLE, systemic lupus erythematosus.

frequent etiology (7%). Cirrhosis and mycobacterial infections were identified in 11% and 10% of the cases respectively.

2.2.1 | Malignancy

Malignancy causes chylous ascites through the invasion and disruption of the normal lymph flow.⁷ The most common malignancies reported to cause chylous ascites are lymphomas, neuroendocrine tumors, sarcomas (Kaposi sarcoma) and leukemias (chronic lymphatic leukemias) in order of prevalence.³ Among the group of the above-mentioned malignancies, lymphoma accounts for at least one-third of the cases.³ Solid malignancies can also cause chylous ascites.^{9,10}

2.2.2 | Cirrhosis

Only 0.5%–1% of all cases of cirrhosis-related ascites are chylous in nature.^{8,11} Runyon et al¹² analyzed a total of 901 ascites samples where eleven were chylous ascites; 10 of them were found to be secondary to cirrhosis and one due to malignancy. The underlying etiology is unclear but may be related to excessive hepatic and gastrointestinal lymph flow (up to 20 L/day) secondary to portal hypertension, leading to spontaneous rupture of the serosal lymphatic channels. Although data is limited, transjugular intrahepatic portosystemic shunt has proven effective for cases of refractory chylous ascites.^{13,14} The decompression of the portal vein has shown to relieve lymphatic hypertension.¹⁵

2.2.3 | Infection

Mycobacterium tuberculosis and filariasis represent the most common causes of chylous ascites in third world countries.³ Granulomatous lymphadenitis is thought to be the central cause of lymphatic obstruction and development of chylous ascites in *M. tuberculosis* infection. It is important to also consider the diagnosis of tuberculosis in patients with alcohol abuse and malnutrition due to their relative immunocompromised state. Among patients with HIV, chylous ascites can occur in association with *M. tuberculosis*, *Mycobacterium avium* Complex and Kaposi sarcoma as a complication of immune reconstitution inflammatory syndrome.^{16,17} Filariasis, an infection caused by the parasite *Wuchereria bancrofti* in third world countries, causes a severe inflammatory reaction in the lymphatics that results in lymphedema and chylous ascites.

2.2.4 | Congenital

The congenital causes of chylous ascites are more commonly seen in the paediatric population. Steinemann et al found lymphangiectasia as the most common cause of congenital anomaly in children (84%).³ Lymphangiectasia or Waldmann's disease is characterised by the presence of dilated lymph vessels due to the lack of valves in the submucosa of the small bowel resulting in leakage of lymph. Waldmann first described this disorder in 1961 as a cause of protein-losing enteropathy, lymphopenia, hypoalbuminemia and hypogammaglobulinemia.¹⁸

Lymphatic anomalies account for only 8% of atraumatic cases of chylous ascites.³

Other lymphatic anomalies exist, but constitute a smaller percentage of cases of congenital chylous ascites. For example, yellow-nail syndrome causes chylous ascites due to hypoplastic lymphatics and consists of the triad of lymphedema, pleural effusion and/or chylous ascites and yellow discoloration with nail dystrophy.¹⁹ The Klippel-Trenaunay syndrome is an inherited autosomal dominant disorder that is characterised by capillary and lymphatic hypoplastic malformations that causes chylous ascites and is associated with soft tissue and bony hypertrophy.²⁰⁻²² Lymphangiomas arise from sequestration of lymphatic tissue, which fail to communicate with the lymphatic system, and can reside in the neck, intestine, pancreas or mesentery.^{23,24}

2.2.5 | Inflammatory

Chylous ascites may occur due to radiotherapy, retroperitoneal fibrosis (Ormond's disease), and autoimmune diseases like sarcoidosis, Behçet's disease, Henoch-Schönlein purpura and systemic lupus erythematosus.^{25,26} Radiation has the same pathophysiological mechanism as retroperitoneal fibrosis; both cause fibrosis and obstruction of the lymphatics in the small bowel and mesentery with the development of chylous ascites.²⁷⁻²⁹ Sarcoidosis can produce chylous ascites by producing intrathoracic nodal fibrosis and lymphatic obstruction. Chylous ascites from systemic lupus erythematosus is more often seen in the elderly who have an insidious onset of disease, which is less commonly associated with the classic rheumatologic manifestations.^{30,31} It is proposed that the inflammation of the lymphatic vessels causes an increase in the endoluminal pressure disrupting permeability of the lymphatic walls and leading to extravasation of chyle.³²⁻³⁴

2.2.6 | Traumatic and post-operative

Any abdominal trauma that disrupts the lymphatic vessels can cause chylous ascites.³⁵ In children, battered child syndrome should be excluded in the presence of chylous ascites, as it accounts for 10% of cases in the paediatric population.^{36,37} Chylous ascites can occur early (around 1 week) after abdominal surgery due to disruption of the lymphatic vessels or late (weeks to months) due to adhesions or extrinsic compression of lymphatic vessels. Chylous ascites has been reported after many surgical procedures, including thoracic or abdominal aneurysm repair, retroperitoneal lymphadenectomy catheter placement for peritoneal dialysis, inferior vena cava resection, vagotomy, Nissen fundoplication, gastric bypass, pancreaticoduodenectomy and gynecological surgery. Liver and kidney transplants have also been associated with post-operative chylous ascites.³⁸⁻⁴⁰ Yilmaz et al⁴¹ reported a post-operative incidence of chylous ascites of 4.6% in a total of 516 liver transplant cases over a 9-year period. Low albumin, the presence of ascites before transplantation, and the use of LigaSure vessel sealing system instead of conventional suture were recognised as risk factors for developing chylous ascites.

2.2.7 | Other causes

Other less common causes include cardiac conditions, nephrotic syndrome, pancreatitis, coeliac sprue, Whipple's disease and retractile mesenteritis.⁴²⁻⁴⁷ Cardiac disease with increased right-venous pressures can lead to increased hepatic lymph production; causing impaired drainage, chyle stasis, lymphatic dilation and ultimately chylous ascites.⁴⁸⁻⁵⁰ These include right heart failure, dilated cardiomyopathy and constrictive pericarditis. Chen et al,⁵¹ reported a case of chylous ascites secondary to cardiac amyloidosis, where the contributing factor was thought to be increased left subclavian venous pressure. Both acute necrotizing pancreatitis and chronic pancreatitis are associated with chylous ascites; the underlying mechanism remains unknown but is thought to be due to direct compression of lymphatic channels.^{52,53}

2.3 | Evaluation and diagnosis

The clinical evaluation of a patient that presents with ascites should start with a thorough history and physical examination. The detailed history must include family history, recent trauma or surgery, travel, social history, and past medical history, particularly looking for

malignancy, liver or renal disease. The most common presenting symptoms in order of frequency are abdominal distension, abdominal pain, diarrhoea, dysphagia and progressive peripheral oedema.³ Other features may include nausea, vomiting, early satiety, diarrhoea, steatorrhea, malnutrition, oedema, fever and night sweats. Shortness of breath, weight gain and increased abdominal girth due to increased abdominal pressure may be present. Physical examination may reveal cachexia, temporal wasting, evidence of pleural effusions or ascites, abdominal masses and hernias, stigmata of chronic liver disease, and lower extremity oedema.

2.3.1 | Laboratory findings

Obtaining laboratory parameters in the blood and ascites is central in the diagnosis and evaluation of chylous ascites. Standard blood tests are required and should include complete blood count, basic metabolic panel, liver function tests, total protein, albumin, lactate dehydrogenase (LDH), lipid panel, amylase and lipase. A paracentesis is mandatory and is the diagnostic tool of choice in evaluating patients with ascites (Figure 1). If the appearance of the ascites is milky and chylous ascites is suspected, a triglyceride level should be measured in the ascitic fluid. A triglyceride concentration above

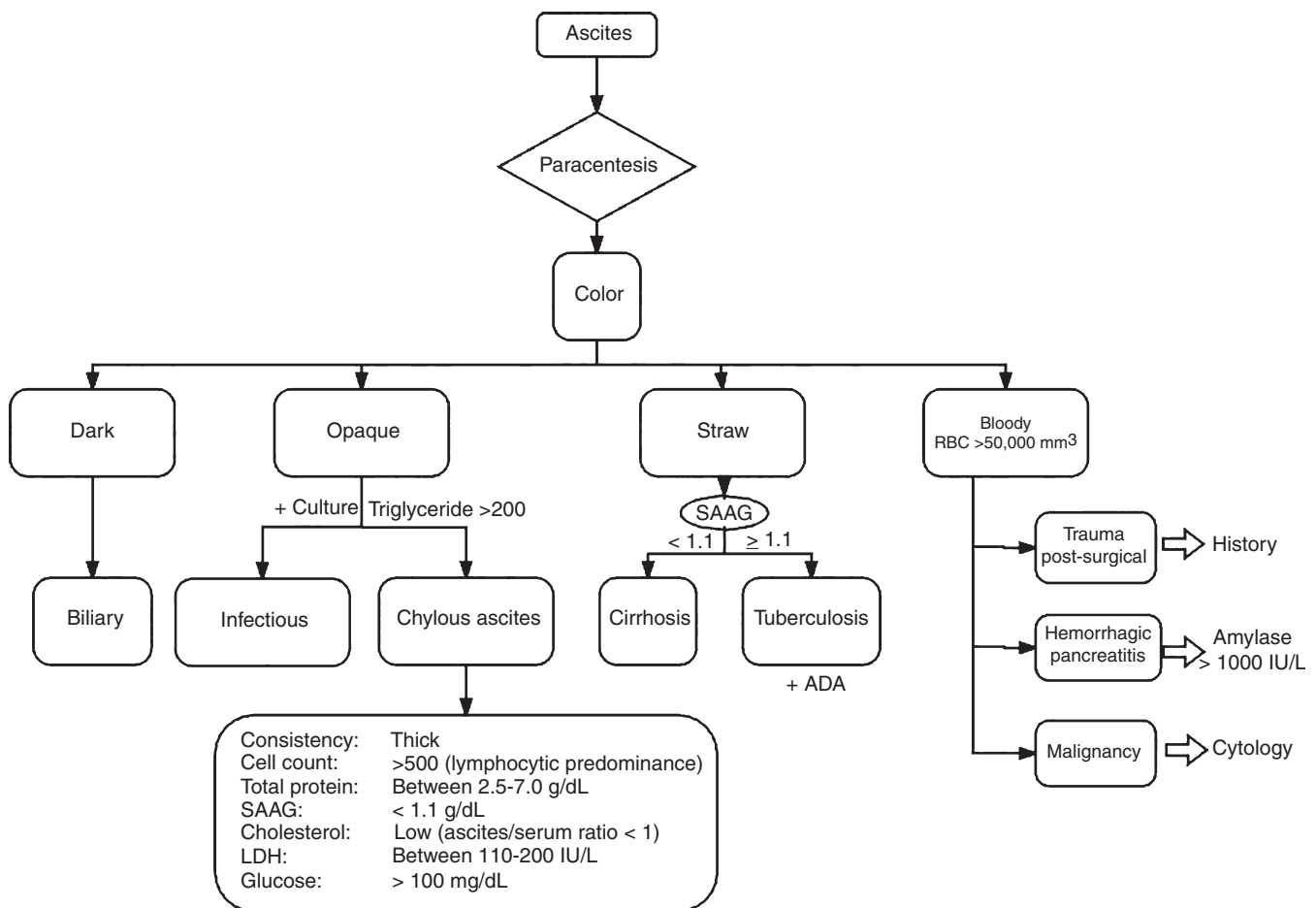


FIGURE 1 Ascites workup and chylous ascites fluid characteristics. RBC, red blood cells; SAAG, serum to ascites albumin gradient; LDH, lactate dehydrogenase; ADA, adenosine deaminase

200 mg/dL supports the diagnosis of chylous ascites, while a level less than 50 mg/dL excludes it.^{1,4} The macroscopic appearance of chylous ascites is turbid and thick compared to the straw-colored, transparent ascitic fluid seen in portal hypertension.⁵⁴ Microscopic examination of the fluid stained with Sudan III shows fat globules and leucocytes with a lymphocytic predominance. Ascitic fluid should be sent for cytology, cell count, Gram's stain, culture, total protein concentration, albumin, LDH, glucose, triglyceride and amylase.⁵⁵ If tuberculosis is suspected, tuberculosis smear, adenosine deaminase and culture should be performed. Adenosine deaminase is a sensitive (93%) and specific (94%) method to diagnose peritoneal tuberculosis, but peritoneal biopsy is required in some cases. The diagnostic accuracy of adenosine deaminase is not influenced by different study settings, adenosine deaminase cut-off or methodological quality.⁵⁶ The total protein content ranges between 2.5 and 7.0 g/dL and will vary according to the underlying etiology.¹² Typically, hepatic cirrhosis is associated with a total protein concentration in the ascites of less than 2.5 g/dL. In addition, the serum to ascites albumin gradient can be used to identify the presence of portal hypertension in the setting of liver-related disease.⁵⁷ A serum to ascites albumin gradient below 1.1 g/dL rules out portal hypertension and suggests other etiologies. In patients with chylous ascites secondary to cirrhosis, the serum to ascites albumin gradient is normally above 1.1 g/dL.^{58,59} Interestingly, CA-125 has been reported to be particularly elevated in cirrhotic patients with chylous ascites (Figure 2).⁶⁰

2.3.2 | Radiology

Radiological assessment also plays an important role in the evaluation of chylous ascites. Lymphangiography is the gold standard

diagnostic tool in cases of lymphatic obstruction. Lymphangiography and lymphoscintigraphy are useful in detecting abnormal retroperitoneal nodes, leakage, fistulization and patency of the thoracic duct. These techniques are also effective for selecting patients for surgery and assessing the effects of treatment.^{61,62} Computed tomography (CT) and magnetic resonance imaging are not specific to chylous ascites, however, they are useful in identifying intraabdominal masses, fluid collections or lymph nodes. The CT density of chylous ascites resembles that of water and is indistinguishable from urine, bile, bowel secretions or simple ascites.⁶³

2.4 | Treatment

The management of chylous ascites is a multifaceted process with limited therapeutic options available. The cornerstone of therapy revolves around correcting the underlying cause and applying conservative measures to improve patient comfort, reduce recurrence and optimise outcomes. Treatment should be individualised and adjusted for the severity of chylous ascites. Conservative measures are centered on maintaining an optimum nutritional balance and administering therapies in order to reduce the production and flow of lymph (Table 2).

The key initial step in management of chylous ascites is to optimise the patient's nutritional status. Nutritional support includes a high-protein, low fat diet supplemented with medium-chain triglycerides.⁶⁴ Medium-chain triglycerides are absorbed by the enterocytes and transported as free fatty acids and glycerol directly into the liver through the portal vein, sparing the lymphatic system. This is in contrast to long-chained triglycerides, which are converted to free fatty acids and monoglycerides that are then transported as chylomicrons

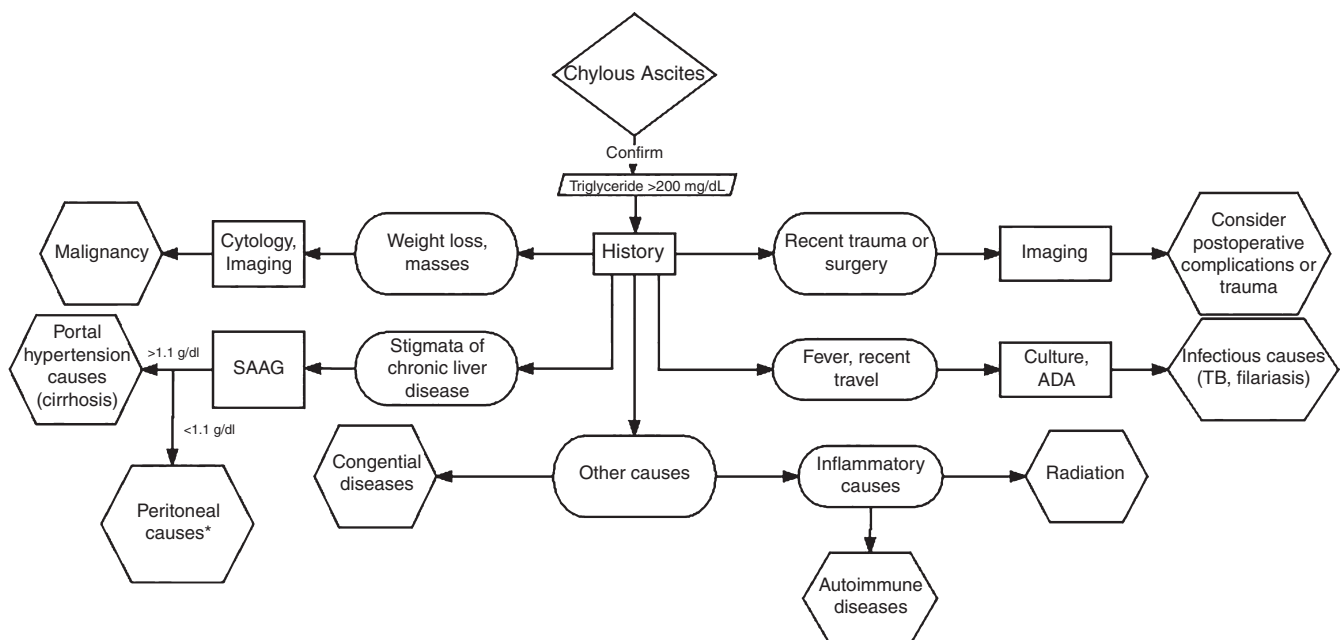


FIGURE 2 Chylous ascites differential diagnosis algorithm. *Peritoneal causes: consider malignancy, inflammatory or infectious causes. SAAG, serum to ascites albumin gradient; ADA, adenosine deaminase; TB, tuberculosis

TABLE 2 Approach to therapy in chylous ascites

Treatment	Indication	Mechanism	References
<i>First treat underlying cause</i>			
Dietary adjustments: 1. Low-fat, high protein diet 2. Medium-chain triglycerides 3. Low-salt (particularly in cirrhosis)	All causes of chylous ascites	Reduces production and flow of chyle	64,65
Therapeutic paracentesis		Temporary symptomatic relief	73
Orlistat ^a		Reversibly inhibits gastric and pancreatic lipase, reducing absorption of fats	66
Somatostatin/Ocreotide ^a		Exact mechanism unknown. Believed to decrease portal pressure and reduce intestinal fat absorption	67-70
Diuretics	Cirrhosis and cardiac related chylous ascites	Facilitate excretion of volume reducing ascites formation	64
Transjugular intrahepatic portosystemic shunt ^a	Refractory cirrhosis related chylous ascites	Reduce portal pressure	13,14,74

Other therapies such as glue embolization, spleno-renal shunt, surgical ligation and embolization of disrupted lymphatic channels are not recommended due to preliminary data. Peritoneovenous shunting is no longer used due to high morbidity from adverse effects.^{75,77,78}

^aThere is not sufficient data for these interventions.

to the intestinal lymph ducts contributing to the overall lymphatic pool. Capric, caprylic and lauric acid are medium-chain triglycerides found in coconut oil, palm kernel oil, whole milk, butter and cheese. Most oils and fats, including nuts, fish, meat, olive oil and avocado contain long-chained triglycerides and should be avoided in chylous ascites.⁶⁵ Orlistat, a gastric and pancreatic lipase inhibitor, has shown to reduce the triglyceride concentration in ascites and can be used adjunctively to a low-fat diet with medium-chain triglycerides, although data is limited.⁶⁶

Somatostatin, or its synthetic analogue, octreotide, have been used as well in the treatment of chylous ascites.⁶⁷ The exact mechanism of action of somatostatin or its analogue is not completely understood. However, it has shown to decrease portal pressure by inhibiting glucagon and other intestinal peptide-mediated splanchnic vasodilatation. It also diminishes peristalsis, intestinal absorption of fats, triglyceride concentration in the thoracic duct and attenuates the lymph flow in the major channels.⁶⁸ Somatostatin must be administered intravenously due to its short half-life of 1-3 minutes. Octreotide has a longer half-life of 2 hours and the advantage of subcutaneous administration. This somatostatin analogue has successfully been used in patients with chylous ascites secondary to pancreatitis, malignancy, post-liver transplant, portal vein thrombosis and idiopathic cases.^{69,70} Berzigotti et al,⁶⁸ utilised it as a long-term medication during 6 months in a patient with refractory chylous ascites in the setting of cirrhosis with no relapses after discontinuation. In addition to nutrition and somatostatin analogues, total parenteral nutrition (TPN) can be considered if other measures fail. However, emerging data has found enteral nutrition with medium-chain triglycerides superior to TPN.⁷¹ Recently, Pan et al⁷² in a retrospective study of 58 patients with post-operative chylous ascites evaluated the clinical effect of somatostatin, enteral medium-chain triglycerides diet and TPN. The early initiation of somatostatin

demonstrated better outcomes than its delayed initiation; and the use of enteral nutrition with medium-chain triglycerides was superior to TPN. Historically, TPN has also shown to have associated adverse effects, such as cholestasis, fatty liver and fungal infections, which may preclude its use.

Therapeutic paracentesis may be performed to provide temporary symptomatic relief. Repetitive drainage should be avoided as it can lead to electrolyte imbalance, malnutrition and infection.⁷³ Intravascular volume and albumin replacement to prevent post-paracentesis circulatory derangements is not necessary unless the patient has underlying cirrhosis.

The management of cirrhosis-related chylous ascites involves a stepwise management approach. Initially, treatment is centered on the use of diuretics and nutritional optimization with a low sodium, low fat, and high protein diet with medium-chain triglycerides. In patients who are refractory to medical therapy and maintain normal liver function, transjugular intrahepatic portosystemic shunt can be considered to help reduce portal pressures, although the data is limited.^{13,74} Even though the effects of transjugular intrahepatic portosystemic shunt on chylous ascites are still preliminary, it is believed that portal decompression reduces the flow of lymph and reduces the formation of chylous ascites.¹⁴ The recurrence of symptoms after shunt dysfunction supports this theory.¹³ Nonetheless, the benefit of transjugular intrahepatic portosystemic shunt placements should be weighed with its inherent risks.

A number of additional therapeutic strategies have been trialed for refractory chylous ascites including glue embolization, spleno-renal shunt, surgical ligation and embolization of disrupted lymphatic channels, but the data is preliminary.⁷⁵⁻⁷⁷ Peritoneovenous shunting was used in the past, however, it is rarely performed nowadays due to its high morbidity from sepsis, electrolyte imbalance, disseminated intravascular coagulopathy, small bowel obstruction and air

embolism.⁷⁸ Despite the number of potential therapeutic options available for chylous ascites, conservative treatment remains the cornerstone of therapy in these patients until further data emerges.

3 | CONCLUSIONS

Chylous ascites is an uncommon disorder characterised by the presence of a milky-appearing, triglyceride-rich fluid in the peritoneum. It is caused by the disruption of the lymphatic system with subsequent leakage of thoracic or intestinal lymph into the abdominal cavity. The most common etiologies are malignancy and cirrhosis in adults and congenital lymphatic disorders in children. Infectious causes are more prevalent in developing countries. Other pathologies associated with chylous ascites include pancreatitis, sarcoidosis, autoimmune diseases, post-surgical complications and other hereditary disorders. The diagnosis is still based on clinical history, paracentesis and ascitic fluid analysis. Perhaps the most relevant topic regarding chylous ascites is its treatment. Conservative treatment with nutritional optimization and treating the underlying etiology remains the cornerstone of therapy for chylous ascites. A high protein, low fat diet with medium-chain triglycerides has shown to be beneficial. When conservative measures fail, other interventions such as octreotide/somatostatin analogues, surgical ligation, embolization and transjugular intrahepatic portosystemic shunt in cirrhotic patients can be considered. Further investigation on the optimal therapeutic management for refractory cases of chylous ascites is warranted.

ACKNOWLEDGEMENTS

Declaration of personal interests: None.

AUTHORSHIP

Guarantor of the article: Andres Cardenas.

Author contributions: BL and AB collected, analyzed, and interpreted data from published studies; drafted the manuscript. HT and EBT analyzed and interpreted data from published studies; helped draft the manuscript. AC collected, analyzed and interpreted data from published studies; drafted and revised the manuscript.

All authors approved the final version of the manuscript.

ORCID

B. Lizaola  <http://orcid.org/0000-0003-0130-0091>

H. D. Trivedi  <http://orcid.org/0000-0002-8328-9211>

A. Cardenas  <http://orcid.org/0000-0002-0764-7873>

REFERENCES

1. Cardenas A, Chopra S. Chylous ascites. *Am J Gastroenterol*. 2002;97:1896-1900.
2. Doerr CH, Allen MS, Nichols FC III, Ryu JH. Etiology of chylothorax in 203 patients. *Mayo Clin Proc*. 2005;80:867-870.
3. Steinemann DC, Dindo D, Clavien PA, Nocito A. Atraumatic chylous ascites: systematic review on symptoms and causes. *J Am Coll Surg*. 2011;212:899-905.e891-894.
4. Press OW, Press NO, Kaufman SD. Evaluation and management of chylous ascites. *Ann Intern Med*. 1982;96:358-364.
5. Al-Busafi SA, Ghali P, Deschenes M, Wong P. Chylous ascites: evaluation and management. *ISRN Hepatol*. 2014;2014:240473.
6. Chakraborty S, Davis MJ, Muthuchamy M. Emerging trends in the pathophysiology of lymphatic contractile function. *Semin Cell Dev Biol*. 2015;38:55-66.
7. Browse NL, Wilson NM, Russo F, al-Hassan H, Allen DR. Aetiology and treatment of chylous ascites. *Br J Surg*. 1992;79:1145-1150.
8. Rector WG Jr. Spontaneous chylous ascites of cirrhosis. *J Clin Gastroenterol*. 1984;6:369-372.
9. Yau KK, Siu WT, Li MK. Chylous ascites in a patient with esophageal carcinoma. *Clin Gastroenterol Hepatol*. 2005;3:A33.
10. Wagayama H, Tanaka T, Shimomura M, Ogura K, Shiraki K. Pancreatic cancer with chylous ascites demonstrated by lymphoscintigraphy: successful treatment with peritoneovenous shunting. *Dig Dis Sci*. 2002;47:1836-1838.
11. Malagelada JR, Iber FL, Linscheer WG. Origin of fat in chylous ascites of patients with liver cirrhosis. *Gastroenterology*. 1974;67:878-886.
12. Runyon BA, Hoefs JC, Morgan TR. Ascitic fluid analysis in malignancy-related ascites. *Hepatology*. 1988;8:1104-1109.
13. Kikolski SG, Aryafar H, Rose SC, Roberts AC, Kinney TB. Transjugular intrahepatic portosystemic shunt for treatment of cirrhosis-related chylothorax and chylous ascites: single-institution retrospective experience. *Cardiovasc Intervent Radiol*. 2013;36:992-997.
14. Tsauo J, Shin JH, Han K, et al. Transjugular intrahepatic portosystemic shunt for the treatment of chylothorax and chylous ascites in cirrhosis: a case report and systematic review of the literature. *J Vasc Interv Radiol*. 2016;27:112-116.
15. Romero S, Martin C, Hernandez L, et al. Chylothorax in cirrhosis of the liver: analysis of its frequency and clinical characteristics. *Chest*. 1998;114:154-159.
16. Lin O, Scholes JV, Lustbader IJ. Chylous ascites resulting from Kaposi's sarcoma in an AIDS patient. *Am J Gastroenterol*. 1994;89:2252-2253.
17. Foschi D, Rizzi A, Corsi F, Trabucchi E, Corbellino M. Chylous ascites secondary to B-cell non Hodgkin's lymphoma in a patient with the acquired immune deficiency syndrome (AIDS). *Dig Liver Dis*. 2008;40:481-482.
18. Vignes S, Bellanger J. Primary intestinal lymphangiectasia (Waldmann's disease). *Orphanet J Rare Dis*. 2008;3:5.
19. Duhra PM, Quigley EM, Marsh MN. Chylous ascites, intestinal lymphangiectasia and the 'yellow-nail' syndrome. *Gut*. 1985;26:1266-1269.
20. Cohen MM, Jr. Klippel-Trenaunay syndrome. *Am J Med Genet*. 2000;93:171-175.
21. Scribner DR Jr, Lara-Torre E, Heineck RJ, Weiss PM. Klippel-Trenaunay syndrome complicated by ascites and vaginal lymphatic drainage in adolescence: a case report. *J Pediatr Adolesc Gynecol*. 2012;25:e139-e141.
22. Gupta N, Kabra M, Ramesh K, et al. A female with hemihypertrophy and chylous ascites - Klippel-Trenaunay syndrome or Proteus syndrome: a diagnostic dilemma. *Clin Dysmorphol*. 2006;15:229-231.
23. Nerune SM, Arakeri SU, Patil VL, Mulay HD. Bilateral cystic lymphangioma of ovary associated with chylous ascites. *J Clin Diagn Res*. 2015;9:Ed18-Ed19.
24. Iwasa T, Tani A, Miyatani Y, et al. Lymphangioma of the ovary accompanied by chylous ascites. *J Obstet Gynaecol Res*. 2009;35:812-815.

25. Abadoglu O, Osma E, Ucan ES, et al. Behcet's disease with pulmonary involvement, superior vena cava syndrome, chyloptysis and chylous ascites. *Respir Med.* 1996;90:429-431.
26. Cogar BD, Groshong TD, Turpin BK, Guajardo JR. Chylothorax in Henoch-Schonlein purpura: a case report and review of the literature. *Pediatr Pulmonol.* 2005;39:563-567.
27. Hurst PA, Edwards JM. Chylous ascites and obstructive lymphoedema of the small bowel following abdominal radiotherapy. *Br J Surg.* 1979;66:780-781.
28. Manolitsas TP, Abdessalam S, Fowler JM. Chylous ascites following treatment for gynecologic malignancies. *Gynecol Oncol.* 2002;86:370-374.
29. Gilkeson GS, Allen NB. Retroperitoneal fibrosis. A true connective tissue disease. *Rheum Dis Clin North Am.* 1996;22:23-38.
30. Lee CK, Han JM, Lee KN, et al. Concurrent occurrence of chylothorax, chylous ascites, and protein-losing enteropathy in systemic lupus erythematosus. *J Rheumatol.* 2002;29:1330-1333.
31. Chen GL, Yang DH, Hsu WH. Chylous ascites and pleural transudate: rare presentations in systemic lupus erythematosus in old age. *Case Reports Immunol.* 2012;2012:390831.
32. Manzella DJ, Dettori PN, Hertimian ML, Melero MJ. Chylous ascites and chylothorax as presentation of a systemic progression of discoid lupus. *J Clin Rheumatol.* 2013;19:87-89.
33. Cappell MS, Friedman D, Mikhail N. Chyloperitoneum associated with chronic severe sarcoidosis. *Am J Gastroenterol.* 1993;88:99-101.
34. Provenza JM, Bacon BR. Chylous ascites due to sarcoidosis. *Am J Gastroenterol.* 1991;86:92-95.
35. Maurer CA, Wildi S, Muller MF, Baer HU, Buchler MW. Blunt abdominal trauma causing chyloretroperitoneum. *J Trauma.* 1997;43:696-697.
36. Beal AL, Gormley CM, Gordon DL, Ellis CM. Chylous ascites: a manifestation of blunt abdominal trauma in an infant. *J Pediatr Surg.* 1998;33:650-652.
37. Benhaim P, Strear C, Knudson M, Neal C, Coulter K, Villarreal S. Posttraumatic chylous ascites in a child: recognition and management of an unusual condition. *J Trauma.* 1995;39:1175-1177.
38. Mukerji AN, Tseng E, Karachristos A, Maloo M, Jain A. Chylous ascites after liver transplant: case report and review of literature. *Exp Clin Transplant.* 2013;11:367-374.
39. Williams AM, Seay TM, Hundley JC, Gedaly R. Direct intranodal lymphangiography for recurrent chylous ascites following liver-kidney transplantation. *Liver Transpl.* 2014;20:1275-1276.
40. Chen JH, Chang CM, Lu MC, Wei CK, Yin WY. Delayed-onset chylous ascites after a living-donor liver transplant: first case successfully treated with conservative treatment. *Exp Clin Transplant.* 2016;14:345-348.
41. Yilmaz M, Akbulut S, Isik B, et al. Chylous ascites after liver transplantation: incidence and risk factors. *Liver Transpl.* 2012;18:1046-1052.
42. Muela Molinero A, Borrego Galan JC, Quiroga Prado L. Chylous ascites secondary to Whipple disease. *Rev Clin Esp.* 2011;211:e28-e29.
43. Kaufmann HJ. Chylous ascites and intestinal muscular hypertrophy occurring in the course of celiac sprue. *Am J Dig Dis.* 1975;20:494-497.
44. Yang AL, Baron TH, Hart PA. An uncommon cause of peripancreatic fluid. *Gastroenterology.* 2015;149:e3-e4.
45. Lippey JF, Yong TL. Chyle leak following biliary pancreatitis. *J Surg Case Rep.* 2014;2014.
46. Baban CK, Murphy M, O'Sulleabhain C, O'Hanlon D. Chylous ascites as a consequence of idiopathic pancreatitis. *BMJ Case Rep.* 2014;2014.
47. Lin WY, Lin GM, Wu CC. Coexistence of non-communicated chylothorax and chylous ascites in nephrotic syndrome. *Nephrology.* 2009;14:700.
48. Villena V, de Pablo A, Martin-Escribano P. Chylothorax and chylous ascites due to heart failure. *Eur Respir J.* 1995;8:1235-1236.
49. Riza Altiparmak M, Avsar S, Yanik S. Chylous ascites and chylothorax due to constrictive pericarditis in a patient undergoing haemodialysis. *Neth J Med.* 2004;62:59-61.
50. Hurley MK, Emiliani VJ, Comer GM, Patel A, Navarro C, Maiki CO. Dilated cardiomyopathy associated with chylous ascites. *Am J Gastroenterol.* 1989;84:1567-1569.
51. Chen JY, Li WT, Hsu CH, et al. Chylous ascites and chylothorax: an unusual manifestation of cardiac amyloidosis. *Intern Med.* 2010;49:1763-1766.
52. Andraus W, Nacif LS, Araujo RL, Buscariolli Ydos S, Salvato M, D'Albuquerque LA. Chronic pancreatitis associated with chylous ascites simulating liver cirrhosis. *Case Rep Surg.* 2013;2013:763561.
53. Santos MA, Bose PS, Maher S, Desai M. Chylous ascites: an unusual complication of necrotizing pancreatitis. *Am J Med.* 2017;130:e151-e152.
54. Gokturk HS, Demir M, Ozturk NA, et al. The role of ascitic fluid viscosity in the differential diagnosis of ascites. *Can J Gastroenterol.* 2010;24:255-259.
55. Runyon BA. Care of patients with ascites. *N Engl J Med.* 1994;330:337-342.
56. Tao L, Ning HJ, Nie HM, Guo XY, Qin SY, Jiang HX. Diagnostic value of adenosine deaminase in ascites for tuberculosis ascites: a meta-analysis. *Diagn Microbiol Infect Dis.* 2014;79:102-107.
57. Runyon BA, Montano AA, Akriviadis EA, Antillon MR, Irving MA, McHutchison JG. The serum-ascites albumin gradient is superior to the exudate-transudate concept in the differential diagnosis of ascites. *Ann Intern Med.* 1992;117:215-220.
58. Khandwalla HE, Fasakin Y, El-Serag HB. The utility of evaluating low serum albumin gradient ascites in patients with cirrhosis. *Am J Gastroenterol.* 2009;104:1401-1405.
59. Uriz J, Cardenas A, Arroyo V. Pathophysiology, diagnosis and treatment of ascites in cirrhosis. *Baillieres Best Pract Res Clin Gastroenterol.* 2000;14:927-943.
60. Kumar KS, Lee WM. Chylous ascites with marked elevation of CA-125 in cirrhosis. *Am J Gastroenterol.* 2000;95:3313-3314.
61. Pui MH, Yueh TC. Lymphoscintigraphy in chyluria, chyloperitoneum and chylothorax. *J Nucl Med.* 1998;39:1292-1296.
62. Noel AA, Gloviczki P, Bender CE, Whitley D, Stanson AW, Deschamps C. Treatment of symptomatic primary chylous disorders. *J Vasc Surg.* 2001;34:785-791.
63. Patten RM, Calkins CM, Moore EE. Isolated traumatic rupture of the cisterna chyli: CT diagnosis. *J Comput Assist Tomogr.* 1999;23:701-702.
64. Leibovitch I, Mor Y, Golomb J, Ramon J. The diagnosis and management of postoperative chylous ascites. *J Urol.* 2002;167:449-457.
65. Weinstein LD, Scanlon GT, Hersh T. Chylous ascites. Management with medium-chain triglycerides and exacerbation by lymphangiography. *Am J Dig Dis.* 1969;14:500-509.
66. Chen J, Lin RK, Hassanein T. Use of orlistat (xenical) to treat chylous ascites. *J Clin Gastroenterol.* 2005;39:831-833.
67. Ilhan E, Demir U, Alemdar A, Ureyen O, Eryavuz Y, Mihmanli M. Management of high-output chylous ascites after D2-lymphadenectomy in patients with gastric cancer: a multi-center study. *J Gastrointest Oncol.* 2016;7:420-425.
68. Berzigotti A, Magalotti D, Cocci C, Angeloni L, Pironi L, Zoli M. Octreotide in the outpatient therapy of cirrhotic chylous ascites: a case report. *Dig Liver Dis.* 2006;38:138-142.
69. Zhou DX, Zhou HB, Wang Q, Zou SS, Wang H, Hu HP. The effectiveness of the treatment of octreotide on chylous ascites after liver cirrhosis. *Dig Dis Sci.* 2009;54:1783-1788.
70. Leong RW, House AK, Jeffrey GP. Chylous ascites caused by portal vein thrombosis treated with octreotide. *J Gastroenterol Hepatol.* 2003;18:1211-1213.

71. Weniger M, D'Haese JG, Angele MK, Kleespies A, Werner J, Hartwig W. Treatment options for chylous ascites after major abdominal surgery: a systematic review. *Am J Surg*. 2016;211:206-213.
72. Pan W, Cai SY, Luo HL, et al. The application of nutrition support in conservative treatment of chylous ascites after abdominal surgery. *Ther Clin Risk Manag*. 2016;12:607-612.
73. Aalami OO, Allen DB, Organ CH Jr. Chylous ascites: a collective review. *Surgery*. 2000;128:761-778.
74. Kinney TB, Ferrara SL, Miller FJ, Roberts AC, Hassanein T. Transjugular intrahepatic portosystemic shunt creation as treatment for refractory chylous ascites and chylothorax in a patient with cirrhosis. *J Vasc Interv Radiol*. 2004;15:85-89.
75. McGrath EE, Blades Z, Anderson PB. Chylothorax: aetiology, diagnosis and therapeutic options. *Respir Med*. 2010;104:1-8.
76. Pamarthi V, Stecker MS, Schenker MP, et al. Thoracic duct embolization and disruption for treatment of chylous effusions: experience with 105 patients. *J Vasc Interv Radiol*. 2014;25:1398-1404.
77. Kong TW, Chang SJ, Kim J, et al. Risk factor analysis for massive lymphatic ascites after laparoscopic retroperitoneal lymphadenectomy in gynecologic cancers and treatment using intranodal lymphangiography with glue embolization. *J Gynecol Oncol*. 2016;27:e44.
78. Yarmohammadi H, Brody LA, Erinjeri JP, et al. Therapeutic application of percutaneous peritoneovenous (denver) shunt in treating chylous ascites in cancer patients. *J Vasc Interv Radiol*. 2016;27:665-673.

How to cite this article: Lizaola B, Bonder A, Trivedi HD, Tapper EB, Cardenas A. Review article: the diagnostic approach and current management of chylous ascites. *Aliment Pharmacol Ther*. 2017;46:816–824. <https://doi.org/10.1111/apt.14284>