

Picture of the Month

Prenatal diagnosis of hypoplastic left heart and coarctation of the aorta with color Doppler FINE

L. YEO^{1,2,3} and R. ROMERO^{1,4,5,6}

¹Perinatology Research Branch, Program for Perinatal Research and Obstetrics, Division of Intramural Research, Eunice Kennedy Shriver National Institute of Child Health and Human Development, NIH, Bethesda, MD and Detroit, MI, USA; ²Detroit Medical Center, Hutzel Women's Hospital, Detroit, MI, USA; ³Department of Obstetrics and Gynecology, Wayne State University School of Medicine, Detroit, MI, USA; ⁴Department of Obstetrics and Gynecology, University of Michigan, Ann Arbor, MI, USA; ⁵Department of Epidemiology and Biostatistics, Michigan State University, East Lansing, MI, USA; ⁶Center for Molecular Medicine and Genetics, Wayne State University, Detroit, MI, USA

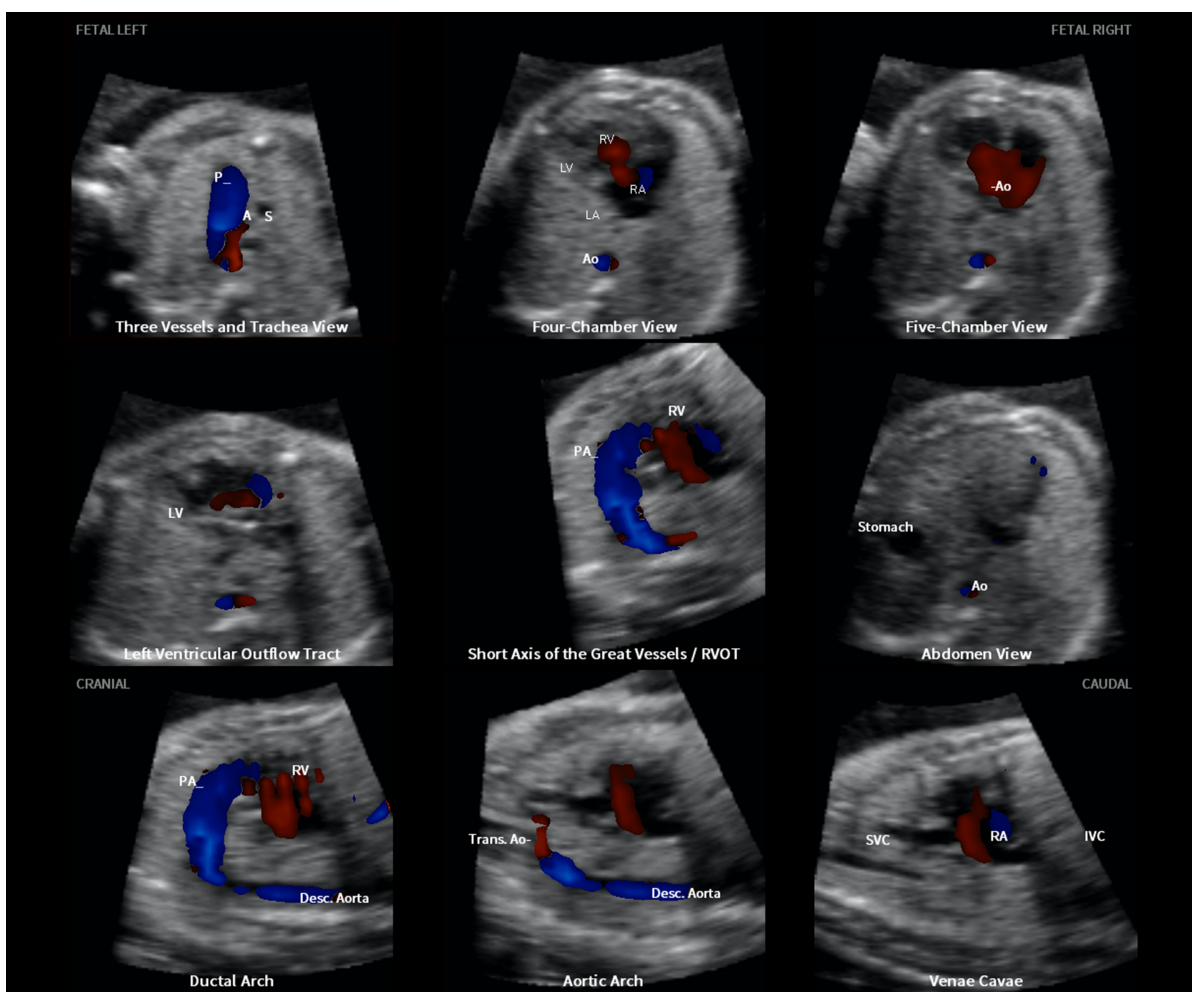


Figure 1 Color Doppler Fetal Intelligent Navigation Echocardiography method in 26-week fetus with hypoplastic left heart and coarctation of aorta (automatic labeling shown). A, transverse aortic arch; Ao, aorta; Desc., descending; IVC, inferior vena cava; LA, left atrium; LV, left ventricle; P, pulmonary artery; PA, pulmonary artery; RA, right atrium; RV, right ventricle; RVOT, right ventricular outflow tract; S, superior vena cava; SVC, superior vena cava; Trans., transverse.

Correspondence to: Dr L. Yeo and Dr R. Romero, Perinatology Research Branch, NICHD, NIH, DHHS, Hutzel Women's Hospital, 3990 John R, 4 Brush, Detroit, MI 48201, USA (e-mail: lyeo@med.wayne.edu and prbchiefstaff@med.wayne.edu)

Fetal Intelligent Navigation Echocardiography (FINE) is a method that automatically generates and displays nine standard fetal echocardiography views from volume datasets obtained with spatiotemporal image correlation^{1,2}. Color Doppler FINE or 5D Heart Color (UGEO WS80A; Samsung Healthcare, Seoul, Korea) allows the same cardiac views to be displayed with color Doppler information³. The Picture of the Month illustrates how the diagnostic planes shown by color Doppler FINE allow a precise diagnosis of hypoplastic left heart with coarctation of the aorta.

The characteristic features of this congenital heart defect were visualized in the following seven echocardiography views (Figure 1):

- The three vessels and trachea view showed a hypoplastic transverse aortic arch with retrograde flow (red color), along with a dilated pulmonary artery demonstrating antegrade flow (blue color).
- In the four-chamber view, the left side of the heart was severely hypoplastic. There was antegrade flow through the tricuspid valve during diastole, but absent flow through the atretic mitral valve.
- The five-chamber view also showed a severely hypoplastic left side, antegrade flow through the tricuspid valve and absence of a color Doppler signal in the atretic aortic root.
- The left ventricular outflow tract view confirmed absence of color Doppler flow through the mitral

valve, as well as an atretic aortic valve with absent flow. However, antegrade flow was seen through the tricuspid valve.

- In the short-axis view of the great vessels/right ventricular outflow tract, the cross-section of the aorta was small when compared with the pulmonary artery. There was systolic perfusion across the pulmonary valve and trunk.
- The ductal arch view demonstrated similar findings.
- The aortic arch view showed a very narrow transverse aortic arch (coarctation), with reversed color Doppler flow in this area, as well as in the isthmus.

The images obtained using color Doppler FINE allowed a precise diagnosis of fetal hypoplastic left heart and coarctation of the aorta at 26 weeks of gestation. More details about the case and color Doppler FINE can be found in an accompanying article in this issue of UOG³.

References

1. Yeo L, Romero R. Fetal Intelligent Navigation Echocardiography (FINE): a novel method for rapid, simple, and automatic examination of the fetal heart. *Ultrasound Obstet Gynecol* 2013; 42: 268–284.
2. Garcia M, Yeo L, Romero R, Haggerty D, Giardina I, Hassan SS, Chaiworapongsa T, Hernandez-Andrade E. Prospective evaluation of the fetal heart using Fetal Intelligent Navigation Echocardiography (FINE). *Ultrasound Obstet Gynecol* 2016; 47: 450–459.
3. Yeo L, Romero R. Color and power Doppler combined with Fetal Intelligent Navigation Echocardiography (FINE) to evaluate the fetal heart. *Ultrasound Obstet Gynecol* 2017; 50: 476–491.