

Results of surgical excision of urethral prolapse in symptomatic patients

Mary E. Hall¹ | Tola Oyesanya¹ | Anne P. Cameron²

¹ University of Michigan Medical School, Ann Arbor, Michigan

² Department of Urology, University of Michigan, Ann Arbor, Michigan

Correspondence

Anne P. Cameron, University of Michigan, Department of Urology, 2875 Taubman Center, 1500 E Medical Center Drive, Ann Arbor, MI, 48109.

Email: annepell@med.umich.edu

AIM: Here, we present the clinical presentation and surgical outcomes of women with symptomatic urethral prolapse presenting to our institution over 20 years, and seek to provide treatment recommendations for management of symptomatic urethral prolapse and caruncle.

METHODS: A retrospective review of medical records from female patients who underwent surgery for symptomatic urethral prolapse from June 1995 to August 2015 was performed. Surgical technique consisted of a four-quadrant excisional approach for repair of urethral prolapse.

RESULTS: A total of 26 patients were identified with a mean age of 38.8 years (range 3–81). The most common presentations were vaginal bleeding, hematuria, pain, and dysuria. All patients underwent surgical excision of urethral prolapse via a standard approach. Follow-up data was available in 24 patients. Six patients experienced temporary postoperative bleeding, and one patient required placement of a Foley catheter for tamponade. One patient experienced temporary postoperative urinary retention requiring Foley catheter placement. Three patients had visible recurrence of urethral prolapse, for which one later underwent re-excision.

CONCLUSION: Surgical excision of urethral prolapse is a reasonable treatment option in patients who have tried conservative management without relief, as well as in those who present with severe symptoms. Possible complications following excision include postoperative bleeding and recurrence, and patients must be counseled accordingly. In this work, we propose a treatment algorithm for symptomatic urethral prolapse.

KEYWORDS

prolapse treatment, surgical excision, urethral caruncle, urethral mass, urethral prolapse

1 | INTRODUCTION

Urethral prolapse is an often meatus-encircling mucosal protrusion typically occurring in either premenarchal girls or postmenopausal women, and urethral caruncles are small, typically asymptomatic single quadrant mucosal prolapses occurring mainly in postmenopausal women. The two can be classified as distinct entities, but are likely due to a similar underlying pathophysiology. Currently, congenital urethral prolapse is believed to occur due to an excess of urethral mucosa related to lack of support of the underlying tissue, and acquired urethral prolapse is attributable to defects in

attachment between layers of urethral smooth muscle secondary to lack of estrogen.¹ It has been postulated that factors leading to the development of acquired urethral prolapse include conditions associated with chronically increased intra-abdominal pressure, as in the case of chronic cough or constipation, combined with lack of estrogen, leading to a bimodal age distribution.²

The clinical appearance of urethral prolapse has been described as a circumferential (or donut-shaped) protrusion of mucosal tissue surrounding the urethral meatus and is often noted to be purple or red in color, edematous, and/or friable. Urethral caruncles, on the other hand, are often described as

having a polyp-like or protrusive appearance and do not encircle the entire urethra (Fig. 1). These are diseases of varying severity on the same spectrum, and may be broadly referred to under the umbrella term of “urethral prolapse” in the context of this paper.

Urethral caruncles are typically asymptomatic, but urethral prolapses can present with bothersome or distressing symptoms, such as vaginal bleeding, hematuria, pain, obstructive symptoms, and dysuria. Although various treatment strategies for urethral prolapse and caruncles have been proposed, many of the past studies supporting these approaches have been focused on patients who are asymptomatic. Few series have described large cohorts of females all presenting with symptoms, and there remains no good consensus on the optimal treatment. In patients who are symptomatic, surgical excision of the lesion is sometimes required. Here, we aim to characterize the clinical presentation and surgical outcomes of 26 female patients with very bothersome symptomatic urethral prolapse requiring surgical intervention who presented to our institution over 20 years.

2 | METHODS

A retrospective review of medical records from all female patients who underwent surgery for symptomatic urethral prolapse or caruncle from June 1995 to August 2015 at the University of Michigan was performed. Only those patients whose final diagnosis and/or pathology was confirmed to be a benign urethral prolapse or caruncle were included. Medical records were reviewed for patient demographics, comorbidities, presentation, and diagnostic workup, indications for surgery, operative procedure, and postoperative management and outcome (Table 1).

TABLE 1 Patient characteristics

	<i>n</i>	%
Age range in years (median) 3-81 (46)	–	–
Menopausal status		
Premenarchal	9	35
Postmenarchal	4	15
Peri- or postmenopausal	13	50
Comorbidities		
Chronic cough	8	31
Constipation	6	23
Prior management with estrogen cream	14	54
Presentation		
Vaginal spotting	18	69
Hematuria	8	31
Pain	7	27
Dysuria	7	27
Irritation	6	23
Thrombosis	2	8

The standard surgical technique that was most commonly employed by our center consisted of a four-quadrant excisional technique.³ This technique is demonstrated with artistic renderings and intraoperative photographs, respectively, in Figs. 2 and 3. In this approach, a cystoscopy is first performed to assess the extent of the prolapse and traction is placed on the redundant tissue with Allis clamps. Next, 3-0 Vicryl stay sutures are placed inside the urethral lumen in the four quadrants of the prolapsed mucosa to provide traction and to serve as closing sutures later. If visualization of the lumen is difficult, it can be facilitated with a small nasal speculum and the use of a narrow tip needle driver (Fig. 3, Panel B). The sutures also serve to prevent retraction of the urethral mucosa once the lesion has been excised. The

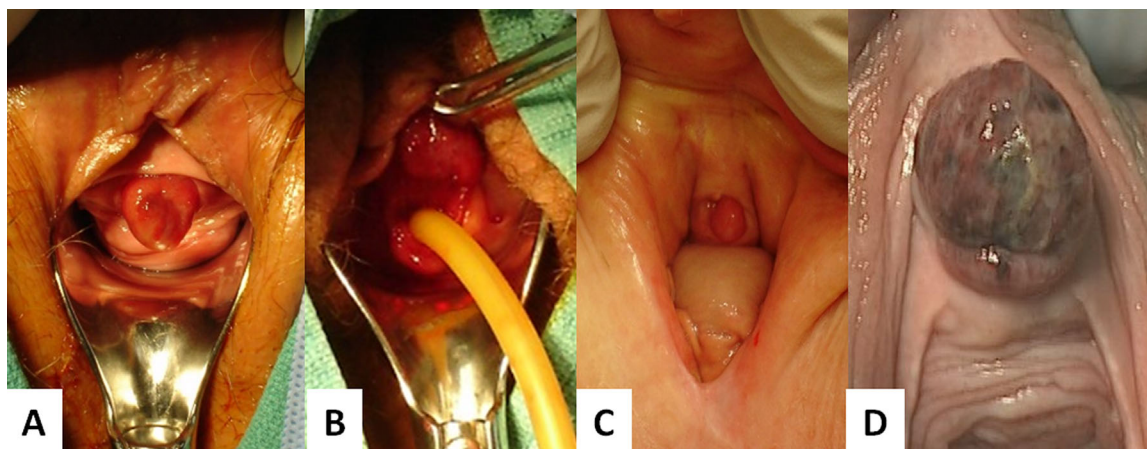


FIGURE 1 Examples of urethral prolapse and caruncle. (A) Circumferential urethral prolapse with voiding dysfunction. (B) Painful, bleeding urethral prolapse with prominence at 12 and 6 o'clock shown with Foley catheter in urethra. (C) Asymptomatic urethral caruncle that did not require excision. (D) Thrombosed urethral prolapse

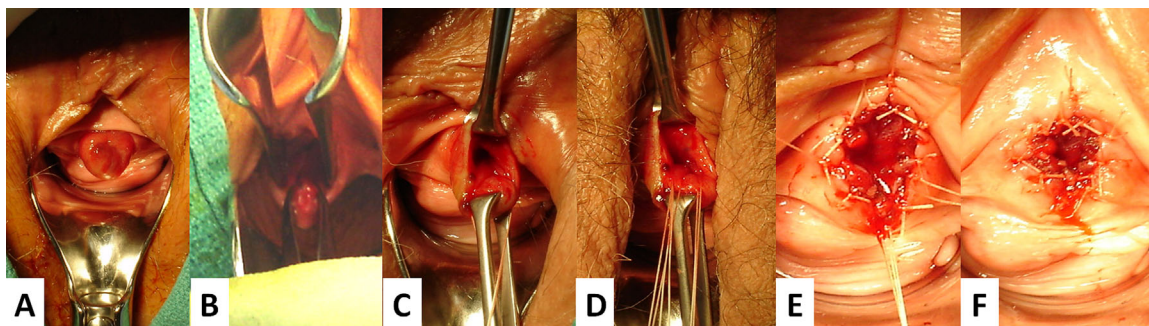


FIGURE 3 Intraoperative photographs demonstrating four-quadrant excisional technique. (A) Full-circumference urethral prolapse. (B) Nasal speculum being inserted into the urethra for greater visualization to better place intralumen sutures. (C) Edges of urethral prolapse grasped and exposed with Allis clamps. (D) Stay sutures placed along inferior aspect of prolapse inside urethral lumen. (E) Excised urethral prolapse with reapproximation of urethral mucosa with absorbable suture. (F) Completed excision with removal of stay sutures

prolapsed mucosal tissue is excised quadrant-by-quadrant by incising around the meatus and inside the urethra distal to the pre-placed sutures using a needle tip electrocautery. Only the redundant mucosal tissue is excised. The inner and outer edges of mucosa are then re-approximated using these same stay sutures. Meticulous closure with 3-0 Vicryl interrupted sutures approximating the urethral mucosa to the perimeatal mucosa between the four quadrant stitches is performed to improve healing. A Foley catheter is then placed, and if the excision was less than 50% circumference of the mucosa a trial of void is performed in the recovery room. In cases where there is more extensive excision, the catheter is left in place for 3-4 days and a trial of void is performed during a return visit in the office. Patients with atrophy are encouraged to continue applying vaginal estrogen creams in the post-operative period to facilitate healing. In our series, all patients underwent excision either with this approach or with another

related standard technique that is further described in the discussion.

3 | RESULTS

A total of 26 patients were identified, ranging in age from 3 to 81 years (bimodal distribution with median ages of each groups 6 and 61), who had received surgical treatment for urethral prolapse. Of the 26 patients, nine were premenarchal, four were postmenarchal, and 13 were peri- or postmenopausal. The most common associated comorbidities other than estrogen deficiency among the patient group were chronic cough (31%) and constipation (23%).

The most common symptoms upon presentation were vaginal spotting (69%), hematuria (31%), pain (27%), and dysuria (27%). Additional presenting symptoms included

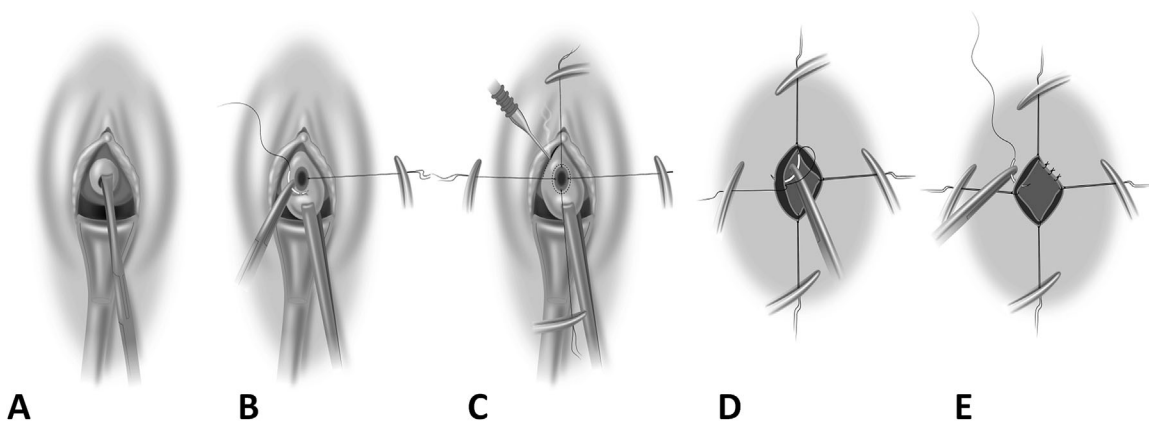


FIGURE 2 Artist renderings of four-quadrant excisional technique for treatment of urethral prolapse. (A) Urethral prolapse grasped with an Allis clamp to determine extent of prolapse. (B) With an Allis clamp on both sides of the urethra for traction, four stay sutures are placed inside the urethral lumen proximal to the planned tissue excision with the needles left attached. The purpose of these sutures is to prevent the mucosa from retracting inside the urethral lumen, as well as for eventual closure. (C) Needle-tip electrocautery is used to incise the redundant mucosa with an incision both inside and outside the prolapse as indicated by the dashed oval. (D) With the redundant mucosa removed, the already placed stay sutures are used to suture the inner and outer edges of mucosa together. Suture tails are left in place for traction to facilitate closure. (E) The mucosa between the four-quadrant sutures is approximated with interrupted sutures to complete the closure. Finally, all stay suture tails are cut and a Foley catheter is placed to complete the procedure. (Illustrations by Shayne Davidson: shaynedavidson@comcast.net)

visible thrombosis, itching, urinary retention, vaginal irritation, spraying of urine, and new development of incontinence. The patients were examined in the office, with the exception of seven pediatric patients who required anesthesia for the exam due to pain and/or discomfort. In 14 patients (54%) presenting with symptoms that could be considered relatively minor, conservative management was first attempted via treatment with topical estrogen cream. Pathology results of the excised lesion were available in 18 patients, and all revealed benign tissue. There were no cases of clinically benign-appearing lesions that were found to have malignant pathology. The typical initial follow-up appointment of patients in the series was between 4 and 6 weeks postoperatively, and patients were followed in our system for a median of 38 days after their procedure (average 259 days, range 0-1718 days). Overall, 24 of 26 patients had available follow-up data and were included in the analysis of complications.

Six of nine premenarchal girls were asymptomatic when seen within 6 weeks postoperatively with no complications reported at the initial follow-up visit, and were noted to be anatomically cured on exam. Two patients were symptomatic with minor postoperative vaginal bleeding of 1-week duration that resolved spontaneously. Three months after her surgery, one patient with successful resolution of her original lesion and symptoms later developed constipation and presented with new voiding dysfunction and spraying of the urinary stream, and was at that time noted to have recurrence of urethral prolapse on exam. Of note, re-excision was planned for this patient, but she was then lost to follow-up and when she returned 4 years later there was no longer any urethral prolapse noted.

Of the postmenarchal and postmenopausal group, 15 patients had available follow-up data. Four patients experienced minor postoperative bleeding that resolved spontaneously, and one required Foley catheter placement in the Emergency Department for tamponade of persistent bleeding. Further intervention was not required and the catheter was removed in 3 days. One patient who had initially presented with a large circumferential prolapse and had a successful voiding trial postoperatively required placement of a Foley catheter in clinic later that day for temporary postoperative urinary retention. Two of the 15 postmenarchal and postmenopausal patients had a visible recurrent mucosal prolapse when seen at their initial postoperative visit. One underwent excision of the recurrence later that year, and the other was asymptomatic and did not pursue further treatment.

Using the Clavien-Dindo classification system, overall our cohort experienced two Grade I complications (placement of Foley catheters for urinary retention and for bleeding) and one Grade IIIb complication (recurrence requiring re-excision).

4 | DISCUSSION

To summarize the results, the majority of the patients presenting to our institution with urethral prolapse or caruncle presented with one or more of the following symptoms: vaginal bleeding, hematuria, pain, and/or dysuria. Of the 24 patients who underwent surgical excision and had available follow-up data, the large majority had favorable results with few complications. Frank recurrence of urethral prolapse occurred in three patients (12.5%), and one of these patients (4.2%) required re-excision. This was the most significant complication encountered in our cohort. Other complications encountered were postoperative urinary retention requiring Foley catheter placement and persistent bleeding requiring Foley catheter placement. Six patients (25%) experienced minor postoperative bleeding which resolved spontaneously.

4.1 | Diagnosis

As we observed in our cohort, some of the more common symptomatic presentations of urethral prolapse include vaginal bleeding, hematuria, pain, and dysuria. These symptoms are non-specific and can occur with many female urethral pathologies, and the diagnosis of urethral prolapse is most often made via an examination. Patients may also present asymptotically during routine pelvic exam, or may have noted an asymptomatic mass at the meatus.

4.2 | Differential diagnosis

Visually differentiating between lesions of the meatus is not difficult. Women may present with concern for malignancy or infectious etiology, but if a careful examination is performed, benign caruncles, and prolapse are rarely mistaken for other disorders given their normal mucosal appearance. The exception is in the case of thrombosed urethral prolapses, which may have an atypical appearance (Fig. 1) due to mucosal sloughing, and in these instances resection is often necessary. Palpation of the remainder of the urethra on vaginal exam is unremarkable, as these lesions only affect the distal mucosa. A number of other disorders may present with masses at the meatus (Fig. 4), including vaginal squamous cell carcinoma and urethral carcinoma. These have atypical appearing mucosa and may present with more proximal palpable lesions along the urethra. Very distal urethral diverticula may also be confused with urethral prolapse, but do not have the same appearance on physical exam. If necessary, the diagnosis of a diverticulum may be confirmed with ultrasound or MRI. Urethral condylomas may also mimic caruncles or urethral prolapse, however, these demonstrate characteristic mucosal changes (Fig. 4). In the event of uncertainty or in the setting of a prior history of malignancy, biopsy is always advisable. Other conditions which may be included in the differential are bladder prolapse, periurethral abscesses, ureteroceles, and

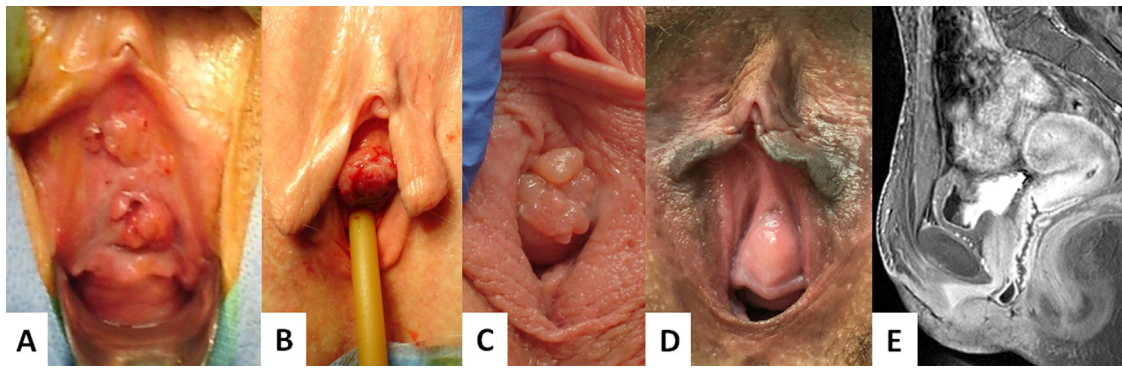


FIGURE 4 Disorders presenting with masses at the urethral meatus. (A) Vaginal squamous cell carcinoma seen above the meatus and at 3 o'clock. (B) Urethral carcinoma arising from the 12 o'clock position. (C) Urethral condylomas demonstrating characteristic mucosal changes. (D) Distal urethral diverticulum, confirmed with MRI (E)

sarcoma botryoides.⁴ As these various disorders, among others, may occasionally imitate urethral prolapse or caruncle, they must also be considered when making a final diagnosis.

4.3 | Treatment

There is no good consensus on the optimal treatment of patients with urethral prolapse or caruncle who present with symptoms. Asymptomatic patients require only reassurance and education. Current management options for symptomatic urethral prolapse or caruncle include conservative treatment with Sitz baths and topical estrogen creams along with management of the likely etiology of the prolapse if one has been identified. If this is not effective, reduction of the prolapse under general anesthesia or surgical excision of the prolapsed tissue may be required.⁵

The choice of treatment depends on the clinical situation. For example, urethral prolapse occurring postpartum during breastfeeding is likely due to estrogen deficiency and will likely respond to topical estrogen. Prolapse that occurs during an upper respiratory tract infection will likely resolve when the coughing stops. However, women who present with thrombosed, chronically bleeding, extremely painful, or obstructing lesions are unlikely to improve with conservative treatment and will require surgical management to resolve their symptoms.

Much of the literature to date is focused around small studies and case series, and many of the recommendations surrounding management are focused on series including solely premenarchal girls. Holbrook and Misra described a cohort of 21 girls ranging in age between 2 and 15 years who were diagnosed with urethral prolapse. They advocated for conservative management such as Sitz baths as the mainstay of treatment and recommended that reduction under general anesthesia be tried for cases in which there was recurrence. These authors suggested that surgery be reserved for patients with severe prolapse that was refractory to these conservative treatment measures. However, they also noted that patients

who could best be managed conservatively were those in whom urethral prolapse was incidentally found, rather than in those who presented due to symptoms.⁵ Other studies have additionally supported conservative treatment in cases of urethral prolapse, but were again focused on cohorts of premenarchal girls.^{6,7} The current series, rather, describes a cohort consisting of both premenarchal girls as well as postmenarchal and postmenopausal women, all of whom presented with bothersome symptoms. In our clinical practice, we do not offer surgical therapy for asymptomatic lesions. It should be noted, however, that one of the patients in our cohort with initial successful resolution of her lesion following surgery was demonstrated to have recurrence on exam which then resolved when she was next seen 4 years later, suggesting that there may be a place for conservative management in dealing with recurrence following surgery in premenarchal girls.

In the present series, conservative management with estrogen therapy and/or Sitz baths had already been attempted in the majority of patients without relief, so surgical excision was the logical next step. The general consensus is that Sitz baths and estrogen cream should be trialed first before moving on to surgical excision in patients with symptoms, and we agree that in many cases this is a reasonable algorithm. However, in patients who are symptomatic with severe pain, visible thrombosis, necrosis of the tissue, bleeding, or distress, we propose that surgical excision may be a first line option given the time required for estrogen to become effective, as well as the low likelihood of successful resolution. Especially in cases of clearly thrombosed or strangulated prolapse, surgical excision should be the initial step.

4.4 | Surgical techniques

Various technical approaches to excision have previously been described. A simple technique described in children involves placement of a Foley catheter with excision of the

mucosal ring over the catheter, followed by suturing of the urethral mucosa to the vestibule.⁸ Trotman et al employed various approaches of ligation, diathermy, or excision over a catheter in their series of 42 patients, however, these approaches are not currently recommended due to increasing reports of complications such as stricture following the procedure.^{5,6} Another simple approach describes simple ligation at the base with a silk suture which allows the caruncle to become ischemic and detach, although this technique has not been widely adopted.⁹ The current approach most commonly employed by our center was first described by Shurtleff and Barone and has been dubbed the “four-quadrant excisional technique.” In this technique, stay sutures are placed inside the urethral lumen in all four quadrants of the prolapsed tissue and the tissue is excised quadrant-by-quadrant with subsequent reapproximation of the mucosa with absorbable suture. This technique allows for greater visualization of the prolapse without obscuration of the view by a catheter and allows the stay sutures to generate traction on and further expose the tissues (Figs. 2 and 3).³

The large majority of our cohort underwent some iteration of the four-quadrant technique. Initial approaches in earlier patients within the series began with what is best described as a “traction and excision approach.” In this technique, the prolapsed mucosa was grasped with an Allis clamp and traction was applied. The lesion was then excised at the base, and the edges of the mucosa were reapproximated with suture. Over the years, the technique evolved to involve the use of stay sutures in order to prevent retraction of the mucosa. In cases in which the prolapse did not circumferentially encompass the meatus, a modified technique was employed, with placement of fewer stay sutures, but while maintaining the same concept of methodological excision and closure. As we reflected on these approaches, we recognized that a grading system for urethral caruncle and prolapse may in fact be very helpful for surgical planning. Considering that we refer to these disorders on a spectrum, as previously mentioned, defining the two may be helpful. We propose defining urethral caruncle as a small, single quadrant mucosal prolapse without hemorrhage or necrosis, and a urethral prolapse as a protrusion either including more than two quadrants or involving hemorrhage from venous engorgement or necrosis. When defined thus, caruncles would rarely require excision, but in the event that it was required only one or two stay sutures would be placed, and in the case of prolapse an additional stay suture for every additional quadrant requiring excision would be placed as well. Still, the same basic concept of the technique would remain the same.

Overall, we have observed very good results with this technique. Hill et al suggested that performing the procedure on well-estrogenized tissue and achieving good reapproximation is an important consideration in helping prevent urethral scarring and future development of stricture or

incontinence; these are important considerations that should be paid mind to in the peri- and intra-operative period and in part why we encourage our patients to continue using estrogen cream following the procedure.¹⁰

Given our favorable results with the four-quadrant excisional and traction and excision approaches, we suggest that this approach be considered as a first-line option during routine surgical treatment of these lesions. The method is straightforward and reproducible, and can be adapted to meet the individual characteristics of each distinct case of urethral prolapse. Our low incidence of major complications with this approach, as well as our favorable outcomes in terms of relief of symptoms, further support this method.

4.5 | Complications of excision

Previous reviews have suggested that possible complications of surgical excision include urethral stricture, voiding dysfunction, and recurrence.^{1,6,8} Overall, 3 of 24 patients with available follow-up data in our series were demonstrated to have frank recurrence, for which one underwent re-excision. In our series, we did not note any instances of development of urethral stricture. Other complications that were noted in our cohort included one patient with transient voiding dysfunction, one with temporary postoperative retention, and postoperative bleeding. Of all the complications noted, minor postoperative bleeding occurring in six patients was the most frequently encountered and self-resolved within approximately a week. Only one patient with more significant postoperative bleeding required a trip to the emergency room due to passing of large clots, and this resolved after placement of a catheter for tamponade. It is important for clinicians to be aware of these possible complications following surgical excision, so that they may be able to counsel patients accordingly and provide appropriate anticipatory guidance.

5 | LIMITATIONS

One of the major limitations of the series was limited follow-up data on patients undergoing surgical treatment of urethral prolapse or caruncles. Although all patients with the exception of two did have documented follow-up appointments and exams, these follow-up appointments occurred at varied times and were not standardized. Additionally, we are unable to account for patients pursuing additional follow-up outside our health system as records were unavailable. This series also suffered from a small sample size, however given the rarity of surgical therapy for this condition this is a relatively large series and the largest reported combined series of symptomatic peri- and postmenopausal women with urethral prolapse and caruncle. Another limitation was lack of standardization of the

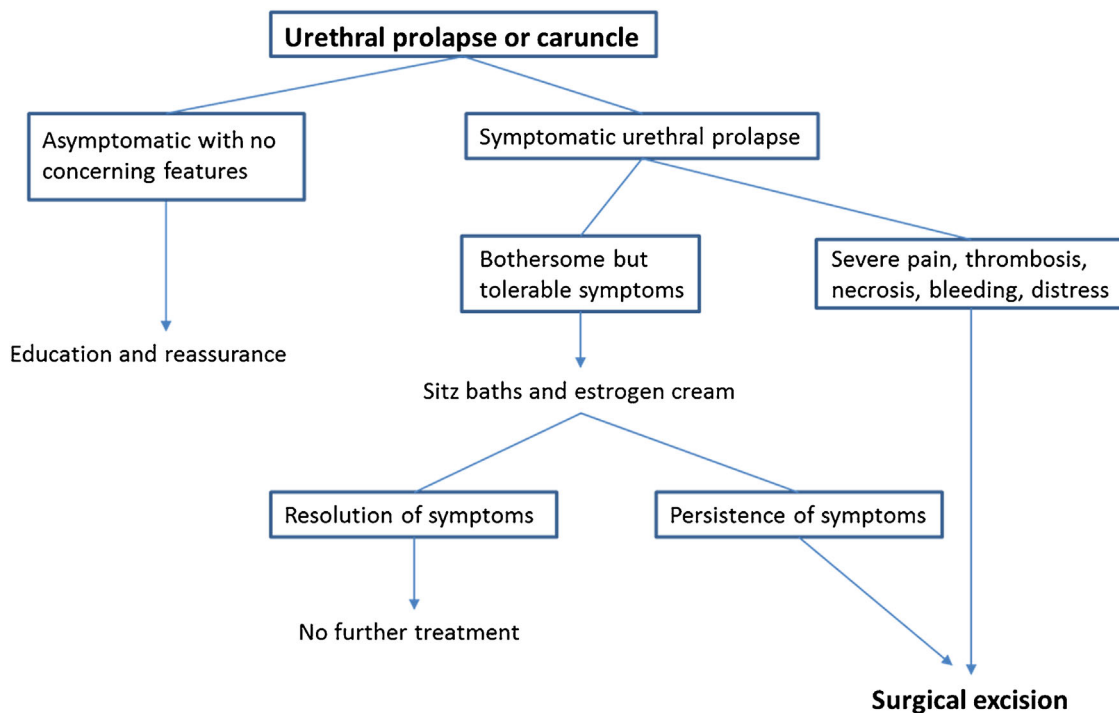


FIGURE 5 Flowchart demonstrating management of urethral prolapse

description of the prolapse or caruncle as no grading system was in existence in the past.

6 | CONCLUSION

In symptomatic patients who have tried conservative management without relief, surgical excision of urethral prolapse is a reasonable, safe, and effective procedure. Additionally, surgical management may be an appropriate first-line consideration in severely symptomatic cases (Fig. 5). The procedure should be performed via a standard approach, and with further practice and refinement of this technique, complications may be kept to a minimum. Clinicians should be made aware of possible complications that may arise postoperatively and patients should be counseled accordingly.

REFERENCES

- Schreiner L, Nygaard CC, Anschau F. Urethral prolapse in premenopausal, healthy adult woman. *Int Urogynecol J*. 2013;24:353–354.
- Hillyer S, Mooppan U, Kim H, et al. Diagnosis and treatment of urethral prolapse in children: experience with 34 cases. *Urology*. 2009;73:1008–1011.
- Shurtleff B, Barone J. Urethral prolapse: four quadrant excisional technique. *J Pediatr Adolesc Gynecol*. 2002;15:209–211.
- Fletcher S, Lemack G. Benign masses of the female periurethral tissues and anterior vaginal wall. *Curr Urol Rep*. 2008;9:389–396.
- Holbrook C, Misra D. Surgical management of urethral prolapse in girls: 13 years' experience. *BJU Int*. 2011;110:132–134.
- Trotman M, Brewster E. Prolapse of the urethral mucosa in prepubertal West Indian girls. *Br J Urol*. 1993;72:503–505.
- Rudin J, Geldt V, Alekseev E. Prolapse of urethral mucosa in white female children: experience with 58 cases. *J Pediatr Surg*. 1997;32:423–425.
- Valerie E, Gilchrist B, Frischer J, et al. Diagnosis and treatment of urethral prolapse in children. *Urology*. 1999;54:1082–1084.
- Park D, Cho T. Simple solution for urethral caruncle. *J Urol*. 2004;172:1884–1885.
- Hill A, Siff L, Vasavada S, et al. Surgical excision of urethral prolapse. *Int Urogynecol J*. 2016;22:117–117.

How to cite this article: Hall ME, Oyesanya T, Cameron AP. Results of surgical excision of urethral prolapse in symptomatic patients. *Neurourology and Urodynamics*. 2017;36:2049–2055. <https://doi.org/10.1002/nau.23232>