

Comparison of Iliofemoral Arterial Access Size between Non-Contrast 3-Tesla Magnetic Resonance Angiography and Contrast-Enhanced Computed Tomographic Angiography in Patients Referred for Transcatheter Aortic Valve Replacement

Troy M. LaBounty^{1,2}, Nicole Bhave¹, Shivraman Giri³, James Balter¹, Antonio Hernandez Conte⁴, Ravi Shah⁵, Venkatesh Murthy^{1,2}

¹Medicine and ²Radiology, University of Michigan, Ann Arbor, MI

³Siemens Healthcare; Malvern, PA

⁴Department of Anesthesia; Cedars-Sinai Medical Center, Los Angeles, CA

⁵Department of Medicine; Beth Israel Deaconess Medical Center, Boston, MA

Troy LaBounty, MD; University of Michigan, 1500 E Medical Center Dr., Ann Arbor, MI 48109;
labt@med.umich.edu

Nicole Bhave, MD; University of Michigan, 1500 E Medical Center Dr., Ann Arbor, MI 48109;
nbhave@med.umich.edu

Shivraman Giri, PhD; Siemens Healthcare, 737 North Michigan Avenue, Suite 1600
Chicago, IL 60611; shivraman.giri@siemens.com

James Balter, MD; University of Michigan, 1500 E Medical Center Dr., Ann Arbor, MI 48109;
jbalter@med.umich.edu

Antonio Conte, MD; Cedars-Sinai Medical Center, 8700 Beverly Blvd, Suite 8211
Los Angeles, California 90048; Antonio.Conte@cshs.org

This is the author manuscript accepted for publication and has undergone full peer review but has not been through the copyediting, typesetting, pagination and proofreading process, which may lead to differences between this version and the [Version record](#). Please cite this article as [doi:10.1002/jmri.25651](https://doi.org/10.1002/jmri.25651).

Ravi Shah, MD; Beth Israel Deaconess Medical Center, 330 Brookline Ave, Boston, MA 02215; rshah1@bidmc.harvard.edu

Venkatesh Murthy, MD; University of Michigan, 1500 E Medical Center Dr., Ann Arbor, MI 48109; vlmurthy@med.umich.edu

Acknowledgements: This study was funded by a University of Michigan Cardiovascular Center Inaugural Grant. Shivraman Giri is an employee of Siemens Healthcare, and provided technical support for sequence optimization. Siemens Healthcare provided an experimental sequence for use in the study, which is now commercially available. There was no other support for the study. There are no other disclosures.

Corresponding Author: Dr. Troy LaBounty, University of Michigan Medical Center, 1500 E Medical Center Dr., SPC 5853, Room 2365, Ann Arbor MI 48109-5853. Email: labt@med.umich.edu; phone: 734-764-7440; fax: 734-232-4132.

Running Title: Non-Contrast MRA for TAVR

Word Count: 999

Severe aortic stenosis is increasingly treated by transcatheter aortic valve replacement (TAVR). Given the risk of vascular injury (1), accurate measurement of arterial access size – typically by computed tomography angiography (CTA) – is critical (2). However, renal insufficiency is common in this population, and CTA contrast may cause renal injury. We hypothesized that non-contrast 3T magnetic resonance angiography (MRA) would be an accurate alternative to CTA to measure iliofemoral arterial size in patients referred for TAVR. We therefore performed both CTA and non-contrast MRA in patients with aortic stenosis referred for TAVR, and compared arterial size and image quality between these tests.

METHODS

We recruited 12 consecutive adults with aortic stenosis referred for TAVR with recent contrast-enhanced TAVR-protocol CTA, after exclusion of 2 patients unable to lay flat who were not enrolled. All enrolled patients completed both the CTA and MRA studies. All patients underwent a clinically indicated TAVR-protocol CTA. Non-contrast MRA was performed on a 3T scanner (MAGENTOM Skyra, Siemens AG, Erlangen, Germany), utilizing a prototype quiescent-inflow single-shot (QISS) technique with electrocardiogram-gating, which relies on magnetization preparation pulses to suppress background signal; after a brief quiescent interval to allow for inflow of unsuppressed arterial blood, imaging data was acquired in diastole(3). Slice thickness was 2.1 mm, and spatial resolution was 1.0 x 1.0 mm. All studies were completed in <60 minutes.

Studies were interpreted using three blinded readers by consensus. CTA and MRA studies were read in a random sequence, with at least two weeks between interpretations of paired images to minimize bias. Five arterial segments were evaluated for each patient (distal

aorta, left common iliac, left external iliac/femoral, right common iliac, and right external iliac/femoral). Measurements were performed using double-oblique short axis views in each segment, at the site with the smallest diameter. The arterial mean, minimal, and maximal diameters were measured manually on these short-axis images (Figure 1). Image quality was graded on a Likert scale of 1-4 (1, excellent; 2, good; 3, adequate; 4, nondiagnostic). Quantitative image quality was measured using the largest possible region of interest on short-axis images for each of the 5 segments, with the per-patient mean values for signal and noise compared. The degree of atherosclerosis was characterized as mild, moderate, or severe for each segment. All studies were interpreted using OsiriX version 5.8.1 for Mac OS X (OsiriX Foundation, Geneva, Switzerland).

Our primary endpoint was a comparison of the mean, minimal, and maximal arterial diameter between CTA and MRA. We also evaluated inter-test agreement for pre-specified threshold diameters of ≥ 6 mm and ≥ 7 mm, which correspond to minimal sizes for typical current and recent TAVR devices; as well as comparisons in graded and quantitative image quality. Analyses were performed using paired t-tests, Fisher exact tests, Pearson correlations, and Bland-Altman plots. Statistical analyses were performed using IBM SPSS version 22 (IBM Corporation; Armonk, NY) for Mac OS X. A $p < 0.05$ was considered significant.

Our institutional review board approved this study, and all patients provided informed consent for participation. This study is in accordance with the Declaration of Helsinki.

RESULTS

Mean age was 77.7 ± 10.3 years, and 42% were male. All studies were completed successfully, and 58/60 arterial segments were graded good or excellent. Two segments in one patient with bilateral metallic hip prostheses were graded non-evaluable on both studies due to artifact and were excluded from analysis. Atherosclerosis was graded as absent, mild, moderate, or severe in 13, 19, 20, and 6 segments, respectively. All but one patient had atherosclerosis reported.

There was no mean difference (Figures 2a, 2b, 2c) in minimal (9.8 ± 3.0 vs. 9.9 ± 3.0 mm, $p=0.87$), mean (10.5 ± 3.0 vs. 10.5 ± 3.1 mm, $p=0.75$), or maximal diameter (11.1 ± 3.2 vs. 11.1 ± 3.0 mm, $p=0.79$) between the 5 segments on CTA and MRA, with excellent correlation ($r=0.98$ for each). For individual segments, there were no differences between CTA and MRA measurements (Table 1). Agreement within 1 mm in mean diameter was observed in 88% (51/58) of segments, while all segments had agreement within 2 mm. Agreement within 1 mm in minimal diameter was observed in 90% (52/58) of segments; all segments had agreement within 2 mm. For maximal diameter, agreement within 1 mm was seen in 91% (53/58) of segments, and all segments had agreement within 2 mm. The sensitivity and specificity of MRA (vs. CTA) to identify per-artery ($n=24$) minimal diameter ≥ 6 mm were 100% (21/21) and 100% (3/3); at a threshold of ≥ 7 mm, the sensitivity and specificity were 93% (14/15) and 89% (8/9). MRA had lower image signal and noise than CTA, with comparable signal-to-noise ratio and higher mean image quality grade (Table 1).

DISCUSSION

A complete pre-TAVR evaluation also requires assessment of the aorta, aortic valve, and annulus. Our study was limited to assessment of the iliofemoral artery and distal aorta to determine the feasibility of non-contrast MRA in this region. A comprehensive non-contrast assessment could be done using our approach combined with other methods reported accurate for assessment of the aorta, aortic root, and annulus, such as other non-contrast MRA techniques (4,5) or 3-dimensional transesophageal echocardiography (6).

We examined a cohort with a high prevalence of atherosclerosis. While MRA does not typically visualize calcification, has lower spatial resolution, and only imaged the lumen (using our protocol), we observed good accuracy between tests. One advantage of MRA is the lack of calcium blooming artifact, but the lack of calcium visualization may mean that additional testing such as non-contrast computed tomography may be needed.

This study is limited by its small sample size, and larger studies are needed. MRA also may be limited in patients with prior iliofemoral stents, and some patients who are referred for TAVR may have contraindications to MRA such as the inability to lay flat due to heart failure.

This study demonstrates that non-contrast MRA may be able to accurately measure iliofemoral arterial access in patients referred for TAVR, and may represent an alternative to CTA in patients with chronic renal insufficiency. Future larger studies are needed to better assess the accuracy of this approach in a larger patient population.

REFERENCES

1. Genereux P, Webb JG, Svensson LG et al. Vascular complications after transcatheter aortic valve replacement: insights from the PARTNER (Placement of AoRTic TraNscathetER Valve) trial. *J Am Coll Cardiol* 2012;60:1043-1052.
2. Leipsic J, Gurvitch R, Labounty TM et al. Multidetector computed tomography in transcatheter aortic valve implantation. *JACC Cardiovasc Imaging* 2011;4:416-429.
3. Edelman RR, Sheehan JJ, Dunkle E, Schindler N, Carr J, Koktzoglou I. Quiescent-interval single-shot unenhanced magnetic resonance angiography of peripheral vascular disease: Technical considerations and clinical feasibility. *Magnetic resonance in medicine : official journal of the Society of Magnetic Resonance in Medicine / Society of Magnetic Resonance in Medicine* 2010;63:951-958.
4. Krishnam MS, Tomasian A, Malik S, Desphande V, Laub G, Ruehm SG. Image quality and diagnostic accuracy of unenhanced SSFP MR angiography compared with conventional contrast-enhanced MR angiography for the assessment of thoracic aortic diseases. *Eur Radiol* 2010;20:1311-1320.
5. Ruile P, Blanke P, Krauss T et al. Pre-procedural assessment of aortic annulus dimensions for transcatheter aortic valve replacement: comparison of a non-contrast 3D MRA protocol with contrast-enhanced cardiac dual-source CT angiography. *European heart journal cardiovascular Imaging* 2016;17:458-466.
6. Khaliq OK, Kodali SK, Paradis JM et al. Aortic annular sizing using a novel 3-dimensional echocardiographic method: use and comparison with cardiac computed tomography. *Circ Cardiovasc Imaging* 2014;7:155-163.

TABLES

Table 1. Comparison of Image Quality and Arterial Diameter Between CTA and MRA

	CTA	MRA	p
Distal Aorta			
Mean Diameter (mm)	15.0 ±1.8	15.2 ±1.9	0.51
Minimum Diameter (mm)	14.1 ±2.2	14.1 ±2.2	0.91
Maximal Diameter (mm)	16.1 ±1.9	15.9 ±1.7	0.09
Right Common Iliac Artery			
Mean Diameter (mm)	10.5 ±1.6	10.6 ±1.8	0.79
Minimum Diameter (mm)	9.7 ±1.8	9.9 ±2.1	0.44
Maximal Diameter (mm)	10.7 ±1.7	10.9 ±1.6	0.34
Right Femoral Artery			
Mean Diameter (mm)	8.4 ±1.3	8.4 ±1.3	1.0
Minimum Diameter (mm)	8.0 ±1.5	7.8 ±1.5	0.32
Maximal Diameter (mm)	8.7 ±1.2	8.8 ±1.2	0.48
Left Common Iliac Artery			
Mean Diameter (mm)	10.3 ±1.8	10.5 ±1.9	0.43

Minimum Diameter (mm)	9.6 ±2.3	9.8 ±2.2	0.43
Maximal Diameter (mm)	11.1 ±1.8	10.9 ±1.6	0.45
Left Femoral Artery			
Mean Diameter (mm)	8.0 ±1.4	8.0 ±1.5	0.76
Minimum Diameter (mm)	7.4 ±1.5	7.6 ±1.7	0.44
Maximal Diameter (mm)	8.5 ±1.7	8.6 ±1.6	0.89
Image Quality			
Signal	393.6 ±166.0	202.3 ±47.1	<0.001
Noise	83.3 ±78.2	43.3 ±19.4	<0.001
Signal to noise ratio	6.8 ±5.4	6.5 ±6.3	0.62
Likert Scale	3.3 ±0.6	3.8 ±0.4	0.04

CTA, computed tomographic angiography; MRA, magnetic resonance angiography.

FIGURE LEGENDS

Figure 1. Case Example. Volume-rendered images of the iliofemoral artery are demonstrated using MRA (a) and CTA (b). Using a threshold of 7 mm, this represents the single case in which MRA (c) reported an adequate minimal diameter (7.1 mm) and CTA (d) did not (6.8 mm) in the left femoral artery (arrows). Significant calcium and blooming artifact is present on CTA, which may explain this difference. Lines and traces on the short-axis images represent the minimal diameter and area, respectively. CTA, computed tomographic angiography; MRA, magnetic resonance angiography

Figure 2. Bland-Altman Plots for Comparisons of Iliofemoral Diameters between MRA and CTA. Bland-Altman Plots compare the mean (2A), minimal (2B), and maximal (2C) arterial diameters for each of the 58 arterial segments between CTA and MRA. The dashed lines demonstrate mean differences (middle) and limits of agreement (± 1.96 SD). CTA, computed tomographic angiography; MRA, magnetic resonance angiography; SD, standard deviation



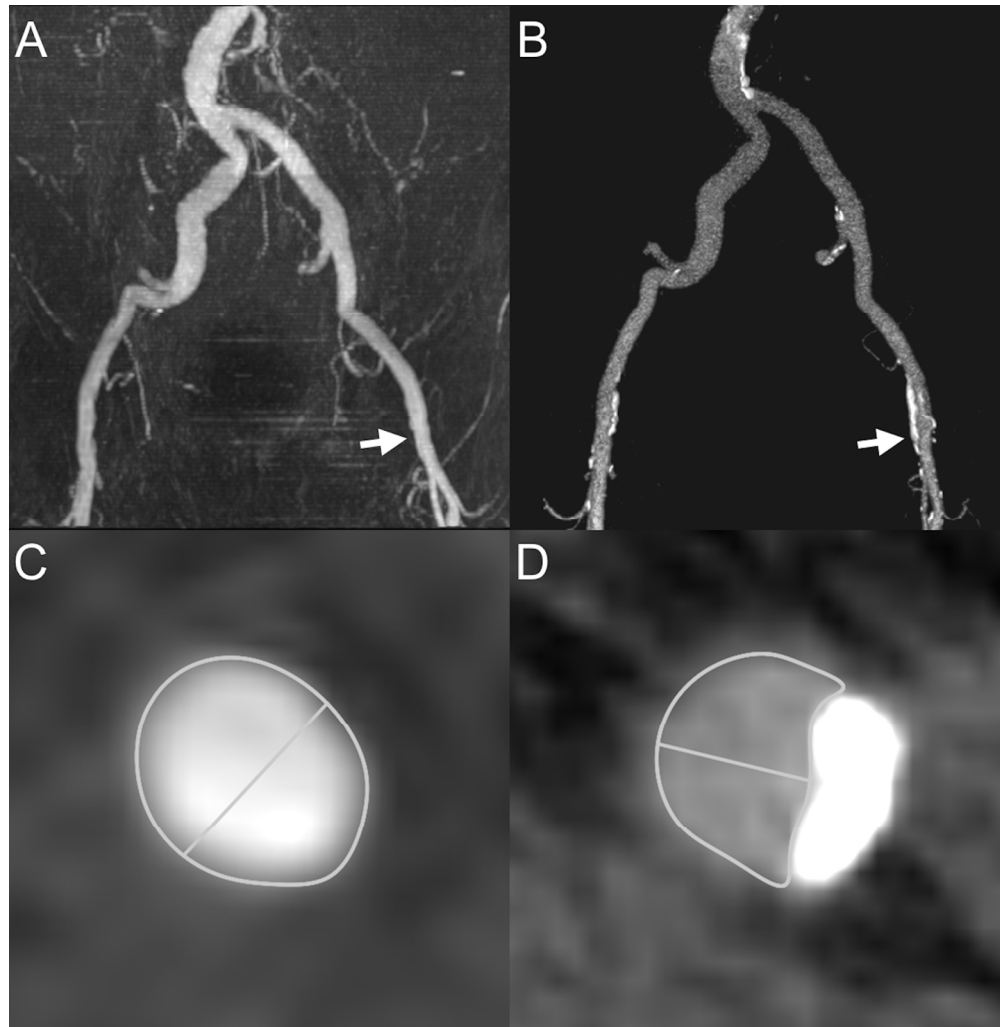


Figure 1. Case Example. Volume-rendered images of the ileofemoral artery are demonstrated using MRA (a) and CTA (b). Using a threshold of 7 mm, this represents the single case in which MRA (c) reported an adequate minimal diameter (7.1 mm) and CTA (d) did not (6.8 mm) in the left femoral artery (arrows). Significant calcium and blooming artifact is present on CTA, which may explain this difference. Lines and traces on the short-axis images represent the minimal diameter and area, respectively. CTA, computed tomographic angiography; MRA, magnetic resonance angiography.

127x130mm (300 x 300 DPI)

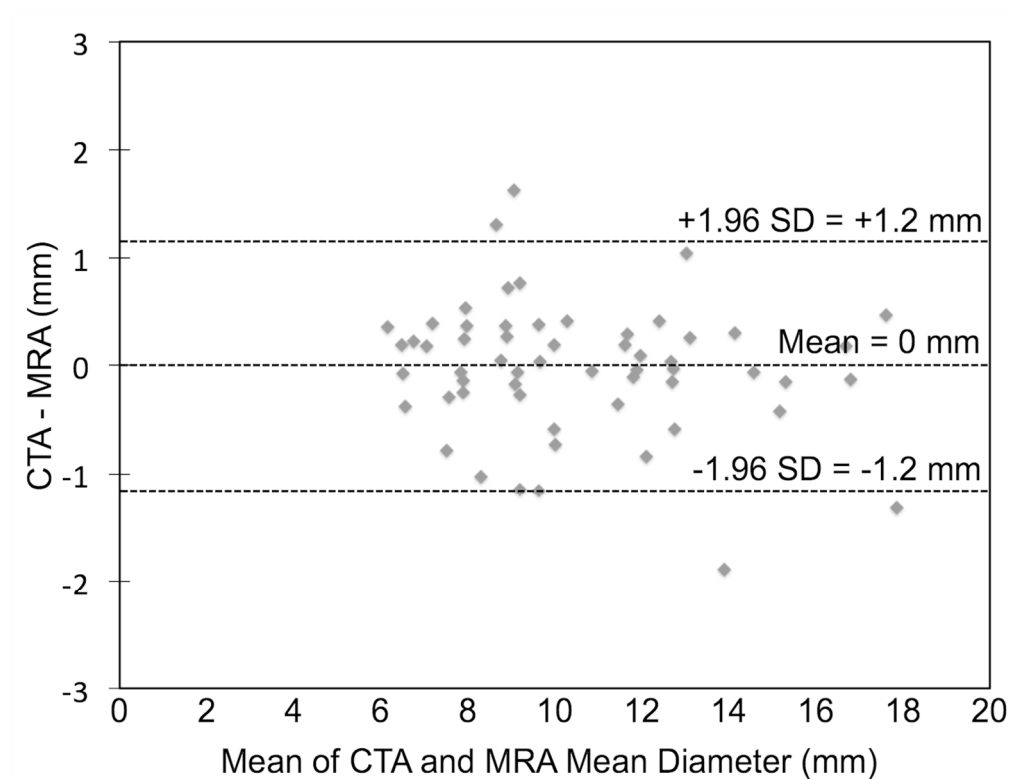


Figure 2. Bland-Altman Plots for Comparisons of Ileofoemoral Diameters between MRA and CTA. Bland-Altman Plots compare the mean (2A), minimal (2B), and maximal (2C) arterial diameters for each of the 58 arterial segments between CTA and MRA. The dashed lines demonstrate mean differences (middle) and limits of agreement (± 1.96 SD). CTA, computed tomographic angiography; MRA, magnetic resonance angiography; SD, standard deviation!! +

127x97mm (300 x 300 DPI)

ACCE

VIEW ONLY

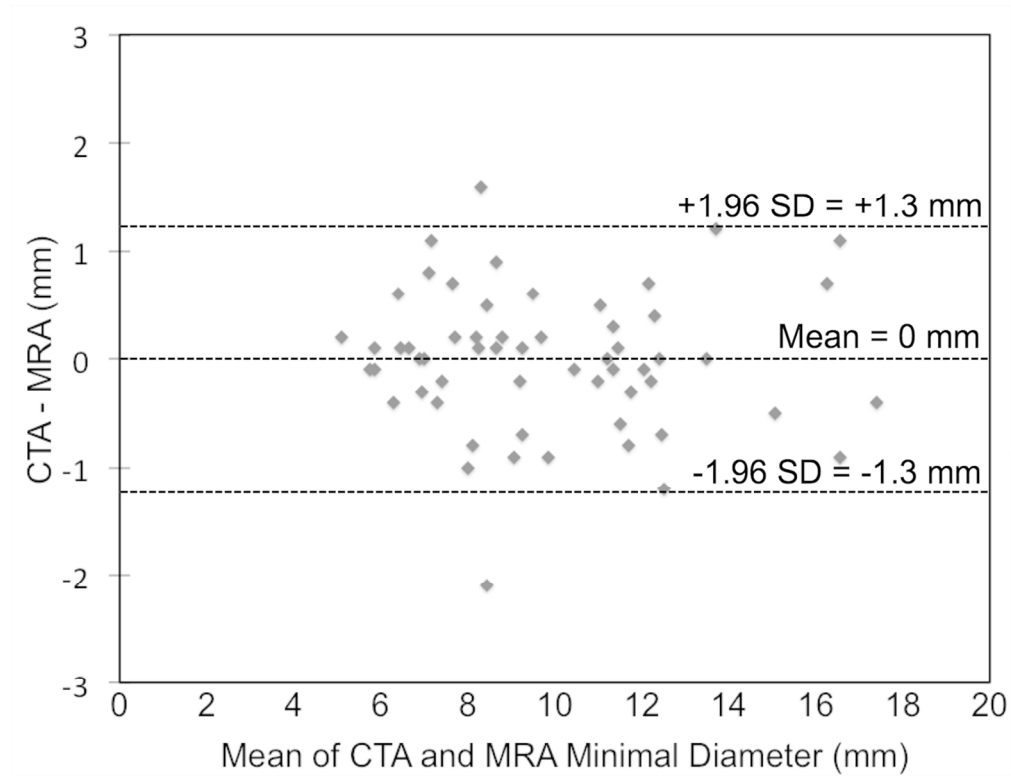


Figure 2. Bland-Altman Plots for Comparisons of Iliofemoral Diameters between MRA and CTA. Bland-Altman Plots compare the mean (2A), minimal (2B), and maximal (2C) arterial diameters for each of the 58 arterial segments between CTA and MRA. The dashed lines demonstrate mean differences (middle) and limits of agreement (± 1.96 SD). CTA, computed tomographic angiography; MRA, magnetic resonance angiography; SD, standard deviation!! +

127x97mm (300 x 300 DPI)

ACCE

VIEW ONLY

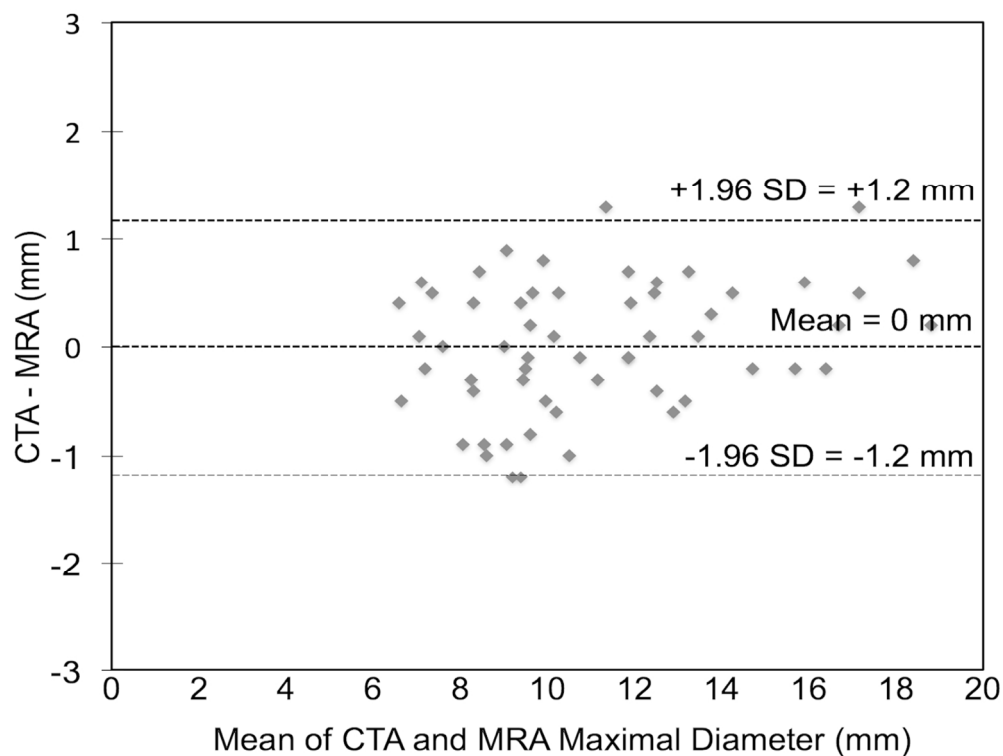


Figure 2. Bland-Altman Plots for Comparisons of Iliofemoral Diameters between MRA and CTA. Bland-Altman Plots compare the mean (2A), minimal (2B), and maximal (2C) arterial diameters for each of the 58 arterial segments between CTA and MRA. The dashed lines demonstrate mean differences (middle) and limits of agreement (± 1.96 SD). CTA, computed tomographic angiography; MRA, magnetic resonance angiography; SD, standard deviation

127x97mm (300 x 300 DPI)

Acci

ONLY