

## Case Report

# Implant Compression Necrosis: Current Understanding and Case Report

Jill D. Bashutski,\* Nisha J. D'Silva,\* and Hom-Lay Wang\*

**Background:** *Implants fail for a variety of reasons; it can be difficult to determine the exact cause of failure, especially if there are multiple contributing factors. Overcompression of the adjacent bone during implant placement is a potential contributing factor to implant failure that is not well documented in the literature.*

**Methods:** *This case report reviews the concept of bone loss induced by overcompression and presents a case of implant failure with overcompression as a potential etiology. Histology, radiographs, and clinical data are presented that document the failure of four implants placed in the posterior mandible of a 48-year-old female patient.*

**Results:** *After uneventful implant placement, one implant exfoliated 3 weeks postoperatively. The other three implants were removed because of severe bone loss up to 2 months later. Histology of the area revealed non-viable bony sequestra with bacterial colonization.*

**Conclusions:** *This case highlights unusual implant failures that likely occurred as a result of overcompression of the bone during placement. Areas involving dense bone seem to be at increased risk for compression necrosis. J Periodontol 2009;80:700-704.*

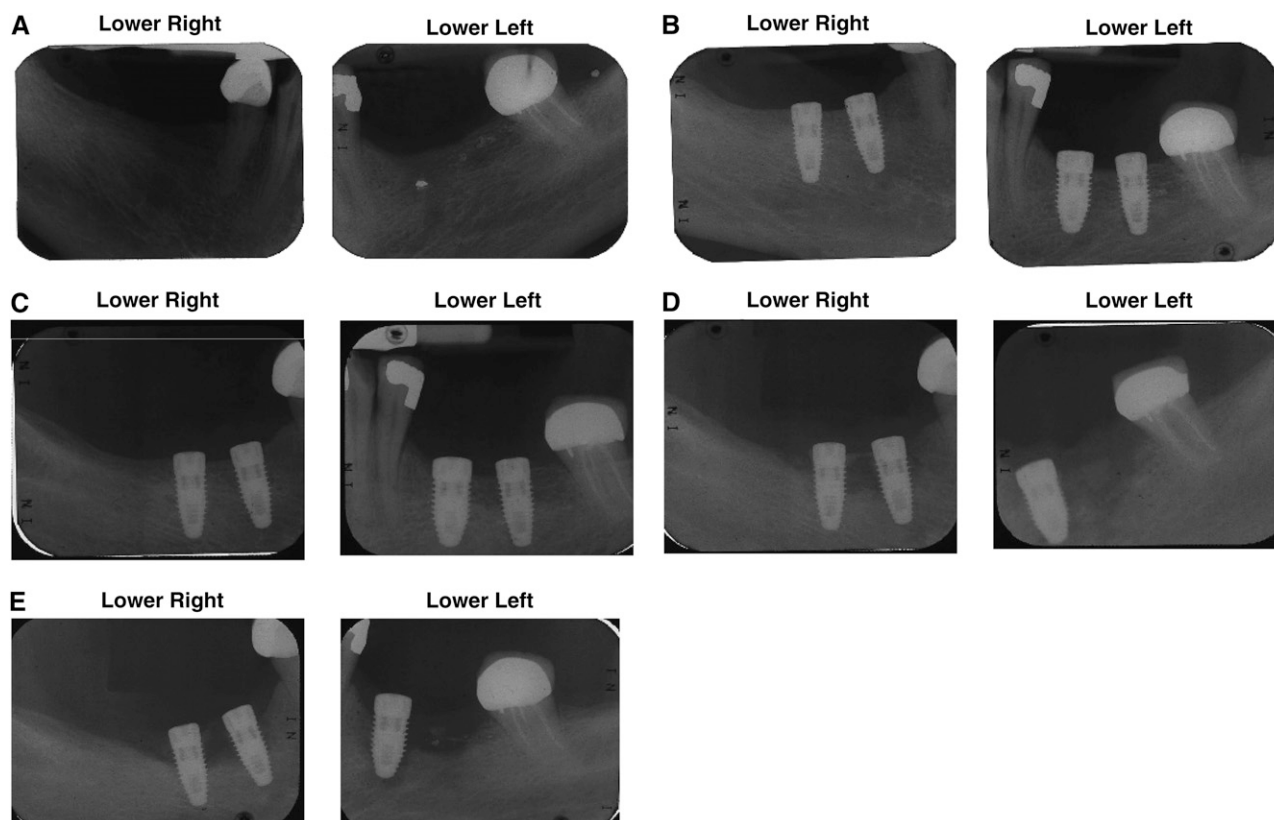
### KEY WORDS

Bone loss; case report; dental implants; necrosis.

Crestal bone loss around dental implants is most pronounced during the first year after placement and occurs for a variety of reasons. Some hypotheses for this phenomenon include surgical trauma, occlusal overload, peri-implantitis, the influence of the microgap, biologic width, reverse torque testing, and the implant crest module.<sup>1,2</sup> Severe crestal bone loss may result in implant failure. However, replacing missing teeth with dental implants is highly successful, with average success rates between 93% and 99.4%.<sup>3-6</sup> It is generally accepted that implant failures can be explained by biologic or mechanical causes. Biologic etiologies may include infection, peri-implantitis, overheating of bone, and contributing systemic factors.<sup>7-9</sup> Mechanical causes may include implant fracture, microstructure (e.g., machined surface), macrostructure (e.g., short implant length), and immediate or functional overloading resulting in bone loss.<sup>10,11</sup> However, some implant failures have unknown etiologies that cannot be explained by any of the above factors.

Compression necrosis is an emerging idea that provides an additional explanation for implant failure, resulting from inadvertent and excessive torque placed on the implant during insertion. Compression of bone beyond its physiologic tolerance may result in ischemia with subsequent necrosis or sequestrum formation, which could ultimately lead to implant failure. Furthermore, excessive torque placed on an implant can result in high levels of strain transmitted to the adjacent bone. The crestal region of an implant, often composed of dense cortical bone with a minimal blood supply, experiences maximum strain upon insertion, thereby making it more susceptible to bone necrosis when excessive pressure is applied during placement. The orthopedic literature has shown that when bone strain exceeds a certain threshold level, irreversible damage, in the form of microcracks and plastic deformation, occurs, leading to implant loosening or failure.<sup>12</sup> Similarly, the orthodontic literature demonstrated that high amounts of force transmitted to the bone during tooth movement results in a sterile,

\* Department of Periodontics and Oral Medicine, School of Dentistry, University of Michigan, Ann Arbor, MI.



### Figure 1.

**A)** Preoperative radiographs prior to implant placement. **B)** Radiographs taken immediately after implant placement. **C)** Radiographs taken 1 week after implant placement. **D)** Radiographs taken 3 weeks after implant placement showing severe horizontal bone loss and exfoliation of implant #20. **E)** Radiographs taken 2 months after implant placement showing severe horizontal bone loss in the lower right and lower left with the implant in #20 missing and nearly 100% bone loss around #19.

undermining resorption.<sup>13</sup> However, in orthopedic and orthodontic applications, the object compressing the bone is surrounded by a soft tissue component, whereas an implant is placed in direct contact with adjacent bone.

Few studies have evaluated the ability of dental implants to place sufficient pressure on adjacent bone to result in bone necrosis or implant failure. Haider<sup>14</sup> was the first to report on suspected compression necrosis of bone around a dental implant. Another case report<sup>15</sup> describing an implant failure due to suspected compression necrosis was published, in which the authors proposed a combination of bone overheating during surgery and excessive tightening of the implant with compression of bone chips at the apex of the implant as the reason for failure. Crestal bone is the least vascular and least resistant to shear forces, making it susceptible to early bone loss averaging 1.2 mm.<sup>16,17</sup> Misch<sup>18</sup> suggested that early crestal bone loss resulting in implant failure may be due to excessive forces transmitted from the implant to the bone in this area. Because overcompression during implant placement would place additional stresses on this crestal bone,

which is most susceptible to failure upon overloading, this may be an important factor to consider in the etiology of implant failure. This article presents a case of multiple implant failures due to unknown causes, in which compression necrosis may be the most likely cause of implant bone loss and failure.

### CASE REPORT

A 48-year-old female presented to the University of Michigan Graduate Periodontics clinic on October 27, 2005 for implant placement in the mandibular posterior areas. The patient was diagnosed with hepatitis B in 1976 but was no longer a carrier. Gastric-bypass surgery was performed on the patient in 2000. In addition, the patient had depression, iron-deficiency anemia, and osteoarthritis. She was taking a multivitamin; iron supplements; calcium supplements; and sertraline HCl, 150 mg, four times a day, for the above-mentioned conditions. She had quit smoking 10 years ago, but had a 13 pack-year history of cigarette smoking.

Periapical radiographs were taken prior to implant placement; they did not reveal any pathology in the lower right or left areas, with the exception of a small

radiopaque fragment in tooth #20 area (Fig. 1A). A cone-beam computed tomography<sup>†</sup> scan prior to surgery confirmed adequate bone height, with slight inadequacy in width in the mandibular posterior areas, along with the presence of an amalgam fragment in bone near #20. During one surgical visit,  $4.3 \times 10$ -mm implants<sup>‡</sup> were placed in the #19, #29, and #30 positions, and a  $5.0 \times 10$ -mm implant<sup>§</sup> was placed in the #20 position (Fig. 1B). Primary stability was achieved for all implants. Small buccal dehiscences were grafted with cortical particulate bone graft material,<sup>||</sup> and a bioabsorbable collagen membrane<sup>¶</sup> was placed over the graft. Complete and passive flap closure was achieved using non-resorbable sutures.<sup>#</sup>

At the 1-week postoperative appointment, a 3-mm incision line opening was noted on implant site #18 on the mesial side with no signs of infection or inflammation. Radiographically, there was some evidence of decreased bone density in the crestal region around the implants (Fig. 1C). Clindamycin antibiotic therapy was initiated at this time. Continued abnormal and delayed healing was noted 3 weeks postoperatively. Immediately prior to this appointment, the patient reported that the #19 implant had exfoliated. Radiographs of the remaining implants revealed severe bone loss ranging from 50% to 90% (Fig. 1D). A 1-week course of amoxicillin and metronidazole was given at this time. Because systemic influences were suspected as a potential cause of the implant failure, the patient was referred to her physician for evaluation. Blood tests, including diabetic screening, revealed no abnormalities (Table 1). After 2 months, periapical radiographs showed continued bone loss around the implants (Fig. 1E), necessitating the removal of the #20 implant. One month later, implants in the #29 and #30 positions were removed because of >70% bone loss and mobility. A biopsy of the area was taken at the time of removal. The specimen was preserved in formalin, decalcified, sectioned, stained with hematoxylin and eosin, and viewed under low-power magnification.

The bone biopsy from the lower right mandible was composed of a  $5 \times 2 \times 2$ -mm non-viable bony sequestra with bacterial colonization and subacutely inflamed granulation tissue. The bone consisted of interconnecting trabeculae of lamellar, non-viable bony sequestra with empty lacunae (Fig. 2). A minimal amount of fibrovascular connective tissue with superimposed neutrophils and lymphocytes was evident on the bone surface. However, no signs of viable bone were evident throughout the specimen or on the periphery, as evidenced by a lack of osteocytes in the lacunae.

## RESULTS AND DISCUSSION

Implant failures can occur for a variety of reasons. In the absence of an obvious cause, one can only speculate

**Table 1.**

### Laboratory Test Results Obtained Within 2 Months of Implant Placement

Laboratory Test	Results	Reference Range
White blood cell count	$7.7 \times 10^3 \mu\text{l}/\text{mm}^3$	$4.3$ to $10.8 \times 10^3 \mu\text{l}/\text{mm}^3$
Red blood cell count	$4.56 \times 10^6/\mu\text{l}/\text{mm}^3$	$4.2$ to $6.9 \times 10^6/\mu\text{l}/\text{mm}^3$
Hemoglobin	12.5 g/dl	12 to 16 g/dl
Mean corpuscular volume	$81.3 \mu\text{m}^3$	76 to $100 \mu\text{m}^3$
Platelets	$346,000 \times 10^3 \mu\text{l}/\text{mm}^3$	150,000 to $350,000 \times 10^3 \mu\text{l}/\text{mm}^3$
Fasting glucose	98 mg/dl	70 to 110 mg/dl
HbA1c (glycosylated hemoglobin)	5.42%	4.1% to 6.5%
Creatinine	0.8 mg/dl	0.6 to 1.2 mg/dl
Sodium	142 mEq/l	135 to 145 mEq/l
Potassium	3.6 mEq/l	3.5 to 5.0 mEq/l
Chloride	106 mEq/l	98 to 106 mEq/l
Calcium	8.7 mg/dl	8.5 to 10.5 mg/dl
Alkaline phosphatase	74 units/l	50 to 160 units/l
Cholesterol	170 mg/dl	<225 mg/dl
Thyroid-stimulating hormone	2.09 mU/l	0.5 to 6.0 mU/l
Ferritin	30 $\mu\text{g}/\text{dl}$ (low)	60 to 160 $\mu\text{g}/\text{dl}$
Vitamin B	127 units	100 to 600 units

as to what caused the failure. In the case report presented here, the implants failed for unknown reasons. Several potential explanations for the failure follow.

#### *Bone Overheating During Osteotomy Preparation*

Histologically, the bone specimens were necrotic with no bacterial infiltration. Consequently, it is possible that the reason for failure was non-inflammatory

<sup>†</sup> I-CAT, Imaging Sciences International, Hatfield, PA.

<sup>‡</sup> Speedy Groovy, Nobel Biocare, Gothenburg, Sweden.

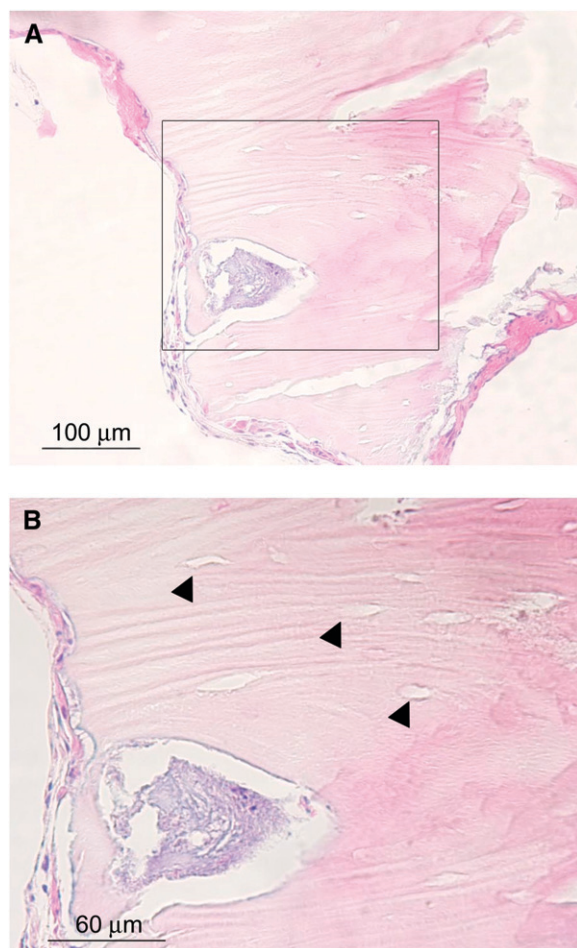
<sup>§</sup> Replace Select Tapered, Nobel Biocare.

<sup>||</sup> Puros, Zimmer Dental, Carlsbad, CA.

<sup>¶</sup> BioMend Regular, Zimmer Dental.

<sup>#</sup> 4-0 Vicryl, Ethicon, Johnson & Johnson, Somerville, NJ.





### Figure 2.

Biopsy of the lower right mandible showing non-viable bony sequestra (A and B) with bacterial colonization (B). Note the interconnecting trabeculae of lamellar, non-viable bone with empty lacunae (arrowheads). (Hematoxylin and eosin; original magnification  $\times 40$ .)

and that the subsequent superficial bacterial colonization took place after the bone necrosis had occurred.

### Overcompression of the Bone During Implant Placement Led to Localized Pressure Necrosis of the Bone

The bone was D2 quality,<sup>19</sup> and no pretapping was done prior to implant placement, which would allow sufficient pressure to be transferred to adjacent bone leading to non-inflammatory bone necrosis.

### Latent Infection Activated by Surgical Trauma in the Area

Although no obvious pathology was noted in the surgical areas, it is possible that a latent infection was activated at the time of implant placement. However, because all implants were equally affected and no overt infection was noted, it is unlikely that this was the primary cause of failure.

### Undiagnosed Systemic Disease Affected Systemic or Local Healing (e.g., osteoporosis or immunosuppression)

Low ferritin was the only abnormality noted in the blood test. Although no study has been published regarding the effect of ferritin on dental implants, a publication<sup>20</sup> in the orthopedic literature demonstrated that increased ferritin levels could induce arthritis and orthopedic prosthesis failure. Given that all implants were equally affected, it seems logical to conclude that some systemic influence may have caused the implants to fail. Impaired healing was evident immediately after implant placement. Although a physician's consult resulted in no systemic diagnosis that would affect healing, it is impossible to test for all potential conditions. Consequently, systemic disease remains a potential reason for the implant failures.

### Contamination of Implants During Surgery

It is possible that the implants were contaminated prior to placement; however, it is unlikely that all implants were contaminated or that the infection spread from one contaminated implant to the contralateral side of the mandible. Furthermore, no overt sign of infection was noted at the time of implant failure.

Although the true cause of implant failure is impossible to surmise in this case report, it is probable that the failure was due to bone overheating, undiagnosed systemic disease, or compression necrosis. A key feature of this case is that, although delayed healing was noted, there were no obvious signs of infection in the area from the time of implant placement to implant failure. Piattelli et al.<sup>15</sup> reported that aseptic necrosis is a key feature of non-infectious trauma to bone, either from overheating or overcompression. Furthermore, the biopsy revealed aseptic necrosis of the bone adjacent to the implant, lending further support to the idea that the implants failed because of physical trauma to the surrounding bone or delayed healing in the area.

Overcompression of bone leading to necrosis would most likely occur early in the healing phase (i.e., within the first month after implant placement). An additional factor that may increase the risk for overcompressing the bone includes placing implants in dense bone, such as type I or II bone in the Lekholm and Zarb<sup>21</sup> classification or D1 or D2 bone in the Misch<sup>19</sup> classification system. Crestal cortical bone is extremely dense and consequently has less vascularity, increasing the chance for necrosis when compressed during implant placement. Systemic factors that decrease vascularity or contribute to delayed wound healing, such as those seen in smokers or elderly people, may also contribute to necrosis following overcompression of the implant. Overheating of the bone could also contribute to implant failure by initiating necrosis around the implant. Eriksson et al.<sup>9</sup> showed that if

temperatures reached 47°C for ≥1 minute, bone necrosis could occur. However, Chacon et al.<sup>22</sup> demonstrated that, even after 25 uses, twist drills were unable to generate heat >47°C at a depth up to 15 mm, provided the drill design included a relief angle. Finally, if a bone graft is placed around the implant, this could prevent the graft from receiving an adequate blood supply, eventually resulting in necrosis of the graft and possible implant failure.

To prevent implant failures due to overcompression, precise surgical techniques should be used, including adequate irrigation. Care should be taken to avoid inserting the implant at torque values beyond the manufacturer's recommendations. In addition, reversing the implant by one-quarter turn after insertion may minimize stress on the adjacent bone, especially when tapered implants are used. Pretapping is essential when placing implants into dense bone, and it may prevent the need to use high torque values to place the implant.

## CONCLUSIONS

Implants may fail for a variety of unknown reasons. This case highlighted unusual implant failures that likely occurred because of physical trauma or undiagnosed systemic illness. Implants placed with excessive torque into dense bone may be at increased risk for failure due to overcompression, although the systemic factors in this case cannot be overlooked. The authors suggest that attention to good surgical technique can help to minimize trauma to adjacent bone through reversing the implant one-quarter turn after insertion, pretapping, and following the manufacturer's recommendations.

## ACKNOWLEDGMENTS

This study was supported by the Periodontal Graduate Student Research Fund, University of Michigan, Ann Arbor, Michigan. The authors report no conflicts of interest related to this case report.

## REFERENCES

- Jividen G Jr., Misch CE. Reverse torque testing and early loading failures: Help or hindrance? *J Oral Implantol* 2000;26:82-90.
- Oh TJ, Yoon J, Misch CE, Wang HL. The causes of early implant bone loss: Myth or science? *J Periodontol* 2002;73:322-333.
- Knauf M, Gerds T, Mucche R, Strub JR. Survival and success rates of 3i implants in partially edentulous patients: Results of a prospective study with up to 84-months' follow-up. *Quintessence Int* 2007;38:643-651.
- Mazzocchi A, Passi L, Moretti R. Retrospective analysis of 736 implants inserted without antibiotic therapy. *J Oral Maxillofac Surg* 2007;65:2321-2323.
- Khayat PG, Milliez SN. Prospective clinical evaluation of 835 multithreaded tapered screw-vent implants: Results after two years of functional loading. *J Oral Implantol* 2007;33:225-231.
- Wagenberg B, Froum SJ. A retrospective study of 1925 consecutively placed immediate implants from 1988 to 2004. *Int J Oral Maxillofac Implants* 2006;21:71-80.
- Paquette DW, Brodala N, Williams RC. Risk factors for endosseous dental implant failure. *Dent Clin North Am* 2006;50:361-374.
- Tonetti MS. Determination of the success and failure of root-form osseointegrated dental implants. *Adv Dent Res* 1999;13:173-180.
- Eriksson AR, Albrektsson T, Albrektsson B. Heat caused by drilling cortical bone. Temperature measured in vivo in patients and animals. *Acta Orthop Scand* 1984;55:629-631.
- Porter JA, von Fraunhofer JA. Success or failure of dental implants? A literature review with treatment considerations. *Gen Dent* 2005;53:423-432; quiz 433, 446.
- Chuang SK, Wei LJ, Douglass CW, Dodson TB. Risk factors for dental implant failure: A strategy for the analysis of clustered failure-time observations. *J Dent Res* 2002;81:572-577.
- Winwood K, Zioupos P, Currey JD, Cotton JR, Taylor M. The importance of the elastic and plastic components of strain in tensile and compressive fatigue of human cortical bone in relation to orthopaedic biomechanics. *J Musculoskelet Neuronal Interact* 2006;6:134-141.
- Meikle MC. The tissue, cellular, and molecular regulation of orthodontic tooth movement: 100 years after Carl Sandstedt. *Eur J Orthod* 2006;28:221-240.
- Haider R, Watzek G, Plenk H Jr. Histomorphometric analysis of bone healing after insertion of IMZ-1 implants independent of bone structure and drilling method (in German). *Z Stomatol* 1991;88:507-521.
- Piattelli A, Scarano A, Balleri P, Favero GA. Clinical and histologic evaluation of an active "implant periapical lesion": A case report. *Int J Oral Maxillofac Implants* 1998;13:713-716.
- Adell R, Lekholm U, Rockler B, et al. Marginal tissue reactions at osseointegrated titanium fixtures (I). A 3-year longitudinal prospective study. *Int J Oral Maxillofac Surg* 1986;15:39-52.
- Reilly DT, Burstein AH. The elastic and ultimate properties of compact bone tissue. *J Biomech* 1975;8:393-405.
- Misch CE. Factors of stress. In: Misch CE, ed. *Contemporary Implant Dentistry*. St. Louis: Mosby; 1999:122-123.
- Misch CE. Density of bone: Effect on surgical approach and healing. In: Misch CE, ed. *Contemporary Implant Dentistry*. St. Louis: C.V. Mosby; 1999:372-383.
- Fukunishi S. The bone-implant-interface: An experimental study on the effects of micro-motion (in Japanese). *Nippon Seikeigeka Gakkai Zasshi* 1995;69:53-63.
- Lekholm U, Zarb G, Albrektsson T. Patient selection and preparation. In: Brånemark PI, Zarb GA, Albrektsson T, eds. *Tissue Integrated Prostheses*. Chicago: Quintessence Publishing; 1985:199-210.
- Chacon GE, Bower DL, Larsen PE, McGlumphy EA, Beck FM. Heat production by 3 implant drill systems after repeated drilling and sterilization. *J Oral Maxillofac Surg* 2006;64:265-269.

Correspondence: Dr. Hom-Lay Wang, Department of Periodontics and Oral Medicine, School of Dentistry, University of Michigan, 1011 N. University Ave., Ann Arbor, MI 48109-1078. Fax: 734/936-0374; e-mail: homlay@umich.edu.

Submitted November 11, 2008; accepted for publication December 17, 2008.