

# Healing of Periodontal Flaps Following Use of MBR 4197 (Flucrylate) in Rhesus Monkeys

## A Clinical and Histological Evaluation\*

by

BRIAN J. LAHIFFE, B.D.S., M.S.†

RAUL G. CAFFESSE, D.D.S., M.S., DR.  
ODONT.‡

CARLOS E. NASJLETI, D.D.S.§

FLAP SURGERY for periodontal reattachment demands tight postoperative adaptation of the mature gingival connective tissue to a prepared root surface.<sup>1-3</sup> This adaptation must be maintained for a period of time sufficient to permit epithelial sealing of the dento-gingival margin. The epithelial seal in turn will permit reorganization of the connective tissues to provide a deep dento-gingival attachment, or at least close adaptation. Control of subgingival plaque seems to be the essential factor in long term maintenance of the healed periodontal wound.<sup>4</sup>

Tight adaptation of tissues following flap surgery is conventionally achieved using sutures. Many problems are associated with the use of sutures in periodontal surgery. Supplementation or replacement of sutures by a tissue adhesive for postoperative flap adaptation is possible as a result of the discovery of cyanoacrylates. Methyl-2-cyanoacrylate seems to have too great a potential for tissue irritation to recommend its use in clinical situations.<sup>5-8</sup> The higher molecular weight homologues appear to be less irritating, but even these are likely to produce a foreign body reaction on application within tissues.<sup>9-11</sup> Besides, in periodontal flap surgery, where the tightest adaptation is desired, interpolation of cyanoacrylate between the flap and the tooth surface is likely to

lead to delayed healing, and to reduce the potential for reattachment.<sup>12</sup> Superficial application of cyanoacrylate would seem not to interfere with healing after flap surgery, but care must be taken not to introduce the adhesive into the tissues.

In the late 1960's a fluoroalkyl cyanoacrylate was synthesized which was found in early animal studies to have desirable physical properties as well as low systemic and local toxicity.<sup>13</sup>

MBR 4197 (Flucrylate) has been investigated in human periodontal surgery, with promising results. No delay in healing has been seen, and in many cases, healing has been claimed to be more rapid following application of this material as a periodontal dressing.<sup>14</sup>

The purpose of this study is to test the efficacy of MBR 4197 (trifluoroisopropyl cyanoacrylate) as compared to conventional sutures in promoting tissue re-adaptation and healing after modified Widman flap surgery in monkeys.

### MATERIALS AND METHODS

Six adult Rhesus monkeys, of average weight 7 kg, housed under standard laboratory conditions, were used in this study. Each of the animals presented initially with a moderately severe chronic gingivitis, with abundant supragingival and some subgingival calculus. Gingival sulcus depth was generally 1 to 3 mm, with isolated 4 mm and rarely 5 mm pockets, when measured with a M1 periodontal probe. || Initial full mouth roentgenographs were obtained for each animal before the experimental procedures. Scaling and polishing was done in each monkey following the initial assessment, and rubber cup prophylaxis was then performed at weekly intervals up to the time of surgery, and following surgery until the time of sacrifice. A marked decrease in the level of gingival inflammation resulted from this treatment, although there was still a tendency for food debris and bacterial plaque accumulations, especially interdentially.

Two days prior to surgery, full mouth periodontal charting and clinical photographs were obtained for each animal.

The monkeys were randomly assigned to one of three experimental groups so that two monkeys would be sacrificed at 14 days, two more at 35 days, and the remaining two at 180 days postsurgically.

Anesthesia for the initial scaling, and for all surgical procedures, was obtained by using pentobarbital sodium (Nembutal).¶ For the subsequent prophylaxes, it was found sufficient to premedicate the animals with ketamine hydrochloride (Vetalar).\*\* Local injection of lidocaine HCl (Xylocaine HCl 2%) containing 1:50,000 epinephrine†† was used at surgery to reduce operative

\* This study was submitted to the Horace H. Rackham School of Graduate Studies, The University of Michigan, by the senior author in partial fulfillment of the requirements for the degree of Master of Science in Periodontics. It was partially supported by the Medical Research Division of the Veterans Administration.

† Present address: 306-805 West Broadway, Vancouver, B.C. V5Z 1K1 Canada. Formerly Department of Periodontics, The University of Michigan School of Dentistry, Ann Arbor, Michigan 48109.

‡ Professor, Department of Periodontics, The University of Michigan School of Dentistry, Ann Arbor, Michigan 48109.

§ Dental Research Section, Veterans Administration Hospital, Ann Arbor, Michigan 48105.

|| Marquis Dental Manufacturing Company, Denver, Colo.

¶ Abbot Laboratories, North Chicago, Ill. Dose 30 mg/kg body weight, IV.

\*\* Parke-Davis, Detroit, Mich. Dose 200 mg per animal, IM.

†† Astra Pharmaceutical Products, Inc., Worcester, Mass.

hemorrhage.

In each animal, the mouth was divided into three maxillary and three mandibular segments. The cuspid teeth, which were not included in the study, formed the division between segments. The third molar teeth were not included in the study.

At surgery, each segment was operated upon using a modified Widman flap technique with standard periodontal surgical instruments. The initial incision was made in the long axis of the tooth, close to the free gingival margin, and was carried down to the alveolar crest. This incision was scalloped to retain as much interproximal gingival tissue as possible. A second incision was then made intracrevicularly, leaving a thin wedge of tissue comprising crevicular and junctional epithelium with some gingival connective tissue. Vertical releasing incisions were made in the area of the cuspid teeth. Following reflection of buccal and lingual flaps, the remaining supraalveolar soft tissue was removed using Orban knives and sharp curettes. Scaling and root planing was accomplished using the same curettes. Since the monkeys did not have appreciable periodontal pockets, alveolar crestal bone was removed, mainly from the buccal aspect, to permit good flap adaptation. The bone removal was accomplished using rotary burs, and chisels. Where rotary burs were used, a sterile isotonic saline spray was used as coolant. Furcations were not opened by the osseous surgery. An attempt was made to remove an equal amount of bone in all segments. Cementum was planed in the area of surgery to leave a smooth surface.

Aspiration was used throughout surgery to avoid the inclusion of foreign material in the operated area. After washing the area of surgery with sterile isotonic saline, the flaps were readapted to the necks of the teeth.

In each monkey, both posterior segments on one side were designated for use of either sutures or cyanoacrylate. The "flip of a coin" determined which side received which mode of closure in the first monkey of each experimental group. In each experimental group, the second monkey has opposite sides used for each of the two modalities. The anterior segments received sutures in the maxilla and cyanoacrylate in the mandible for one monkey in each group, and the order was reversed for the other monkey.

Sutures employed were simple, interrupted, using Ethicon 0000 braided black silk sutures in atraumatic needles.\* No periodontal dressing was used.

MBR 4197 was supplied in liquid and aerosol forms by the manufacturer.† Initial experiences with the liquid form in dropper bottles showed some difficulty in precise application of a thin film of the material, and so the aerosol form was used throughout. For application of

this material, the flap was held in place by the operator, while another investigator applied a 1 to 2 second spray of cyanoacrylate buccally and lingually in the experimental segments. Respraying was done where deemed necessary to control hemorrhage. During application of the spray, all operating personnel wore face masks, and the monkey's oropharynx and eyes were protected by means of gauze sponges, in compliance with the manufacturer's recommendations.

Clinical photographs were taken during and after the surgical procedures. All of the surgery was performed by the same operator. Each animal was placed on a soft diet and systemic antibiotics‡ for 1 week postsurgically. A plastic collar was used during this time to prevent tearing of the sutures by the animals.

Suture removal and rubber cup polishing were done 1 week after surgery, and thereafter rubber cup prophylaxis was done at weekly intervals up to the time of sacrifice.

One monkey in the 14 day group died during the night following surgery, of postanesthetic complications which were unrelated to the material being tested. All other animals were sacrificed by exsanguination according to the experimental schedule.

After sacrifice, the maxilla and mandible with their associated soft tissues were dissected out, and placed for 3 weeks in a 10% neutral buffered formalin fixative. The jaws were then sectioned into their appropriate segments, and decalcified in 20% formic acid for 6 to 8 weeks.

Following decalcification, the segments were cut to provide both buccolingual and mesiodistal specimens in each operated segment. The specimens were embedded in paraffin, and cut at 6- $\mu$  intervals. These sections were then mounted on glass slides and prepared for histological examination with hematoxylin and eosin stain.

#### *Staining of Cyanoacrylate in Tissue Sections*

Prior to the experimental surgery, a trial was conducted to determine whether MBR 4197 could be identified in tissue sections by use of the oil red O stain, as shown with other cyanoacrylates.<sup>15</sup>

Two monkeys used in another unrelated experiment comprised the material for this trial. In the mandibular anterior region of each of these monkeys, full thickness mucoperiosteal flaps were raised buccally and lingually. The exposed bone surface was then sprayed with MBR 4197, the flaps were replaced, and the area was again sprayed with MBR 4197. The monkeys were immediately sacrificed by exsanguination, and the mandibular anterior segments were removed. These specimens were subjected to the processing as previously described, and stained with oil red O, to demonstrate the presence of cyanoacrylate within the tissues (Fig. 1).

\* Ethicon Inc., Somerville, New Jersey.

† Minnesota Mining and Manufacturing Company, St. Paul, Minnesota.

‡ Cosa Terramycin R. Department of Veterinary Medicine, Pfizer Inc. New York, New York. Daily dose 100 mg dissolved in water.

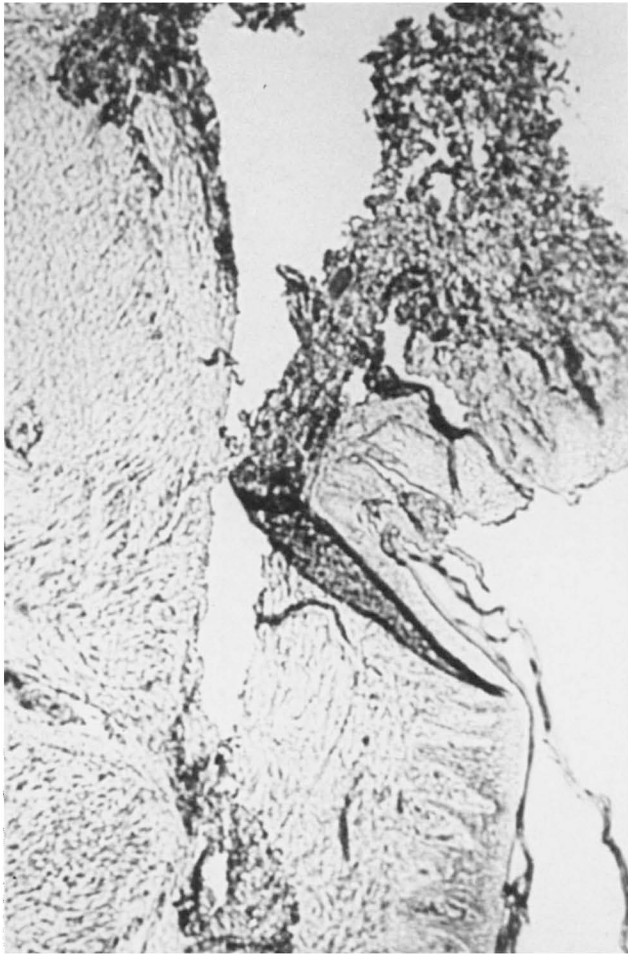

FIGURE 1. Cyanoacrylate purposely placed under the flap, stained with oil red O (original magnification,  $\times 50$ ).

## RESULTS

### Clinical Findings

Application of cyanoacrylate to an operated segment took approximately 20 seconds, as against 5 to 10 minutes to apply sutures to a comparable area.

Immediate hemostasis was obtained with a single application of cyanoacrylate in almost all cases. A second spray was applied where deemed necessary to control bleeding. All operated areas healed uneventfully (Fig. 2). In all animals, no trace of cyanoacrylate was seen at 1 week. Mild inflammation was always present around the sutures postoperatively. There was generally less clinical inflammation in the cyanoacrylate-treated segments than in those areas to which sutures had been applied up to 4 weeks postoperatively. Beyond this time, no clinical differences were apparent between the two modalities.

Tissue adaptation appeared clinically optimal in areas where the flap was not reflected beyond the mucogingival junction, and these areas exhibited most rapid clinical healing, with either modality. A tendency for marked accumulation of interdental plaque and debris was seen in all animals during postsurgical prophylaxes. A mod-

erate bleeding tendency was elicited in all interdental areas. No such bleeding was generally found on the buccal and lingual surfaces, where less plaque accumulation was seen.

## HISTOLOGIC FINDINGS

### Cyanoacrylate—Treated Flaps

In the monkey which died during the night following surgery, the flaps show complete removal of crevicular and junctional epithelium. There has been obvious separation of the flaps from the alveolar process and from the teeth.

Preparation artefact has resulted in the completed separation of many of the buccal and lingual flaps, except at their bases. Apposition of flaps in interdental areas is impossible to assess, as no attachment is seen in these areas.

The alveolar crest shows beginning surface necrosis, with empty lacunae, where the bone has been traumatized. The contour of the crest appears slightly roughened, and the normal lamellated pattern is disrupted. Cementoblasts are missing only from the area directly adjacent to the wound edges, and are elsewhere in normal arrangement. No trace of cyanoacrylate is found within the tissues on sections stained with oil red O.

### Cyanoacrylate—Treated Flaps—14 Days

An epithelial seal against the tooth has been reestablished in all sections, with a minimal histologic crevice depth (Fig. 3A). The junctional epithelium has been regenerated, and appears longer than normal in almost all areas, but is short of the apical extent of the area instrumented at surgery in all but a few cases.

Where flap adaptation has been good, a long thin junctional epithelium is found closely adapted to the tooth surface (Fig. 3A). Less good flap adaptation has resulted in healing by development of an epithelial ridge at some distance from the tooth, with an area of granulation tissue from the periodontal ligament interposed between the ridge and the tooth surface (Fig. 3B). This granulation tissue is covered by a thin epithelium, which then extends apically along the tooth surface. Close connective tissue readaptation to the root surface without cementum attachment is seen apical to the junctional epithelium and coronal to the area of fiber attachment to cementum (Fig. 3C). The orientation of fibers in these areas is parallel to the root surface (Fig. 3C). In a few areas, functionally oriented gingival fibers are seen in association with a long junctional epithelium.

A striking feature in these sections is the almost complete absence of inflammation, except where healing by third intention has taken place (Figs. 3A and 3B). Where healing by third intention has occurred, there is mild inflammation in the granulation tissue immediately subjacent to the thin epithelial covering. Interdental inflammation is more prominent than buccal or lingual inflammation, but is again confined to the most superficial part

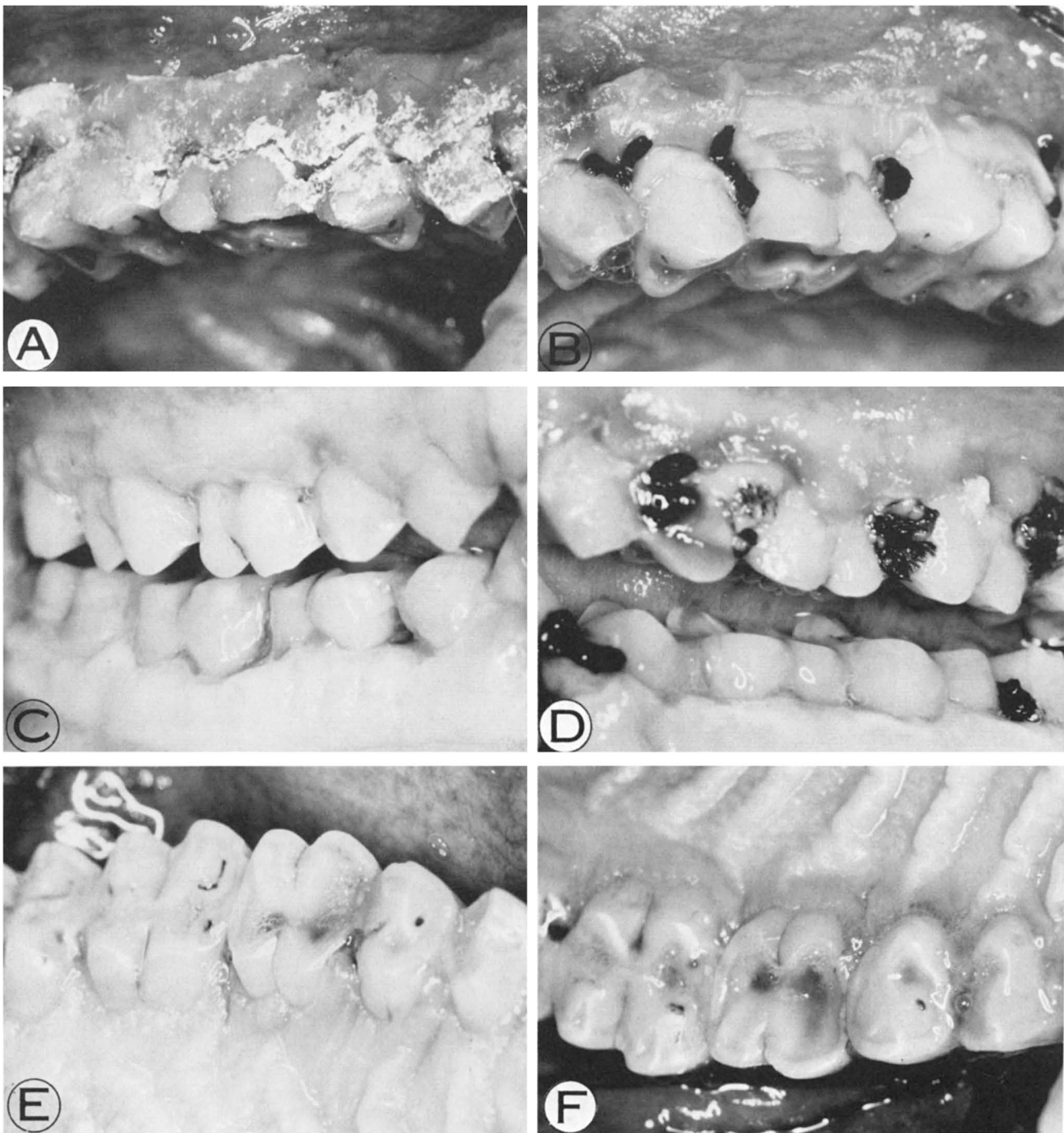


FIGURE 2A. Cyanoacrylate segment, 1 day postoperatively. B. Sutures segment, 1 day postoperatively. C. Cyanoacrylate segments, 7 days postoperatively. D. Suture segments, 7 days postoperatively. E. Cyanoacrylate segment, 4 weeks postoperatively. F. Sutured segment, 4 weeks postoperatively.

of the papillary tissues. The periodontal ligament is free of inflammation in almost all sections.

The line of incision is visible only as an area of alteration in the orientation of the gingival fiber attachment (Fig. 3C). A good union between flap and bone and tooth surface has taken place, with little preparation shrinkage.

Bone resorption has taken place at the alveolar crest, which is remodeling (Figs 3A, 3B, and 3C). Resorption of alveolar plate was present. A thicker alveolar plate is

resorbed from the periosteal side. Few osteoclasts are present at this time interval, and osteoid deposition is commonly seen in areas of previous resorption. Functional osteoblasts are found adjacent to such areas.

Cementum resorption is not prominent in the area of surgery, but is seen in many sections adjacent to the alveolar crest. This is considered unrelated directly to the surgery, since normal cementum is always seen between the area of resorption and the area of surgery. Cementum deposition is not seen at this time interval in

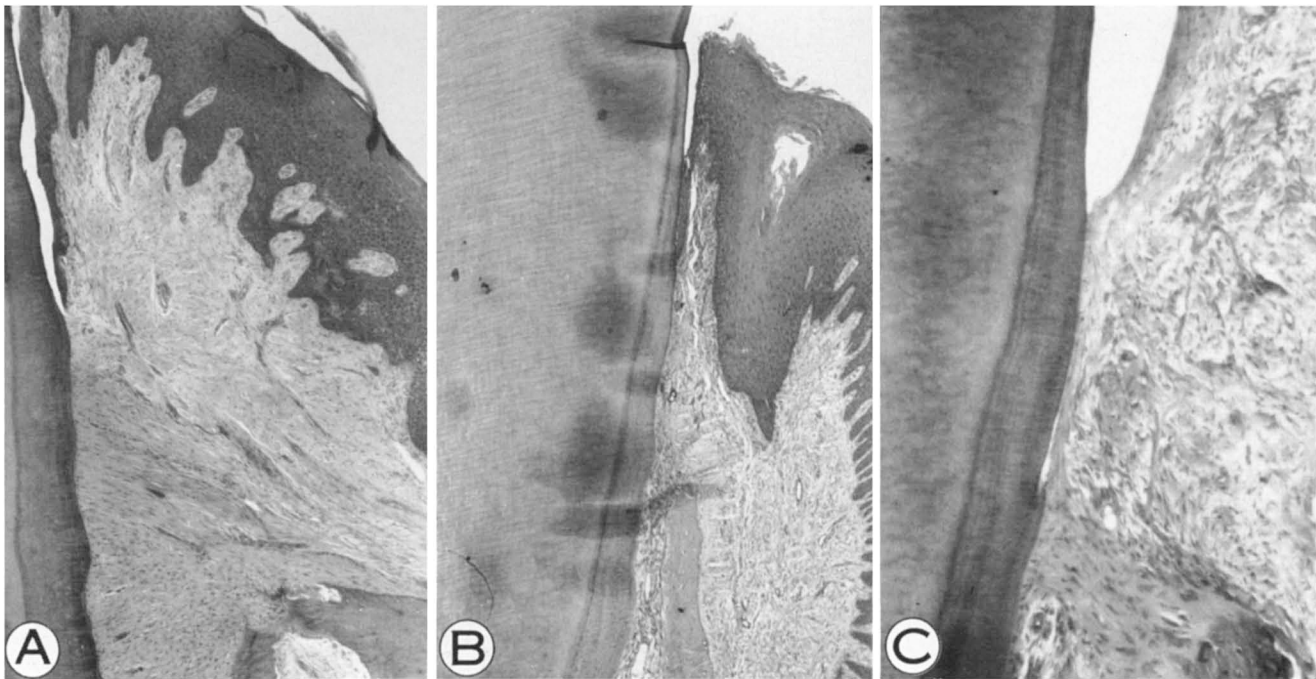


FIGURE 3A. Good flap adaptation, 35 days cyanoacrylate (original magnification  $\times 50$ ). B. Epithelial ridge, 14 days cyanoacrylate (original magnification,  $\times 50$ ). C. Fibers parallel to root surface, 14 days cyanoacrylate (original magnification,  $\times 125$ ).

the area of surgery, but is seen in those areas distant from the area of surgery where previous resorption has taken place. Secondary cementum is prominent around the apical regions.

Periodontal tissues apical to the alveolar crest are normal. No trace of cyanocrylate is found within the tissues on those sections stained with oil red O.

#### Cyanoacrylate—Treated Flaps—35 Days

A shallow histological crevice is present in all sections (Fig. 4A). The junctional epithelium is of variable length, being coronal to the apical extent of surgical instrumentation in almost all sections. In a few sections, however, the apical extent of the junctional epithelium approaches, and rarely even overlaps the edge of unoperated cementum. The junctional epithelium is uniformly thin, and is longer than normal (Fig. 4B).

Many interdental sections show healing by third intention, with a thin epithelium covering organizing granulation tissue, and extending along the root surface. Some interdental sections show a latticework of proliferating epithelial strands throughout the papillary tissue. One palatal section shows a pattern of third intention healing, with a broad epithelial ridge a considerable distance from the tooth surface (Fig. 4C). A thin epithelial covering extends over the granulation tissue to the tooth surface, where there is a short epithelial attachment.

Subepithelial inflammation is minimal beneath well adapted buccal and lingual flaps, except where deep notches have been produced in dentin at the time of the surgery. In such areas, the superficial tissues only show mild to moderate inflammation associated with accumulation of plaque under the notch, while the deeper tissues are relatively free of inflammation, and healing

normally. In a few sections where healing has been by third intention, inflammation is found to extend the full length of the junctional epithelium, which is thickened.

Inflammation is mild to moderate in interdental areas where abundant plaque is seen, but is again confined to the most superficial tissues. Fibroblasts are common in the connective tissue, and a parallel orientation of the gingival fibers with the root surface is seen where the tissues have been well adapted to the operated areas. New cementum has been laid down on old cementum and on dentin, even where distinct notches were produced at surgery (Fig. 4D). Cementoblasts are seen in such areas, and also are seen assembling along the tooth surface in some areas where connective tissue adaptation has been good but no cementum has yet been produced (Fig. 4E).

Alveolar crest remodeling has been completed, with smoothing of the previously rough crestal contours by apposition of new bone. In some areas, bone regeneration has taken place coronal to dentin notches, even where a pattern of third intention healing is observed. In such areas a concomitant deposition of cementum has taken place to line the notched dentin (Fig. 4D).

Normal cementum, periodontal ligament, and alveolar bone are seen apical to the alveolar crest. Areas of previous cementum resorption has been refilled with new cementum, and a normal functional orientation of fibers is seen. Secondary cementum is prominent in many apical areas.

No trace of cyanoacrylate is found within the tissues on any of the sections stained with oil red O.

#### Cyanoacrylate—Treated Flaps—180 Days

All sections show some connective tissue reattachment,

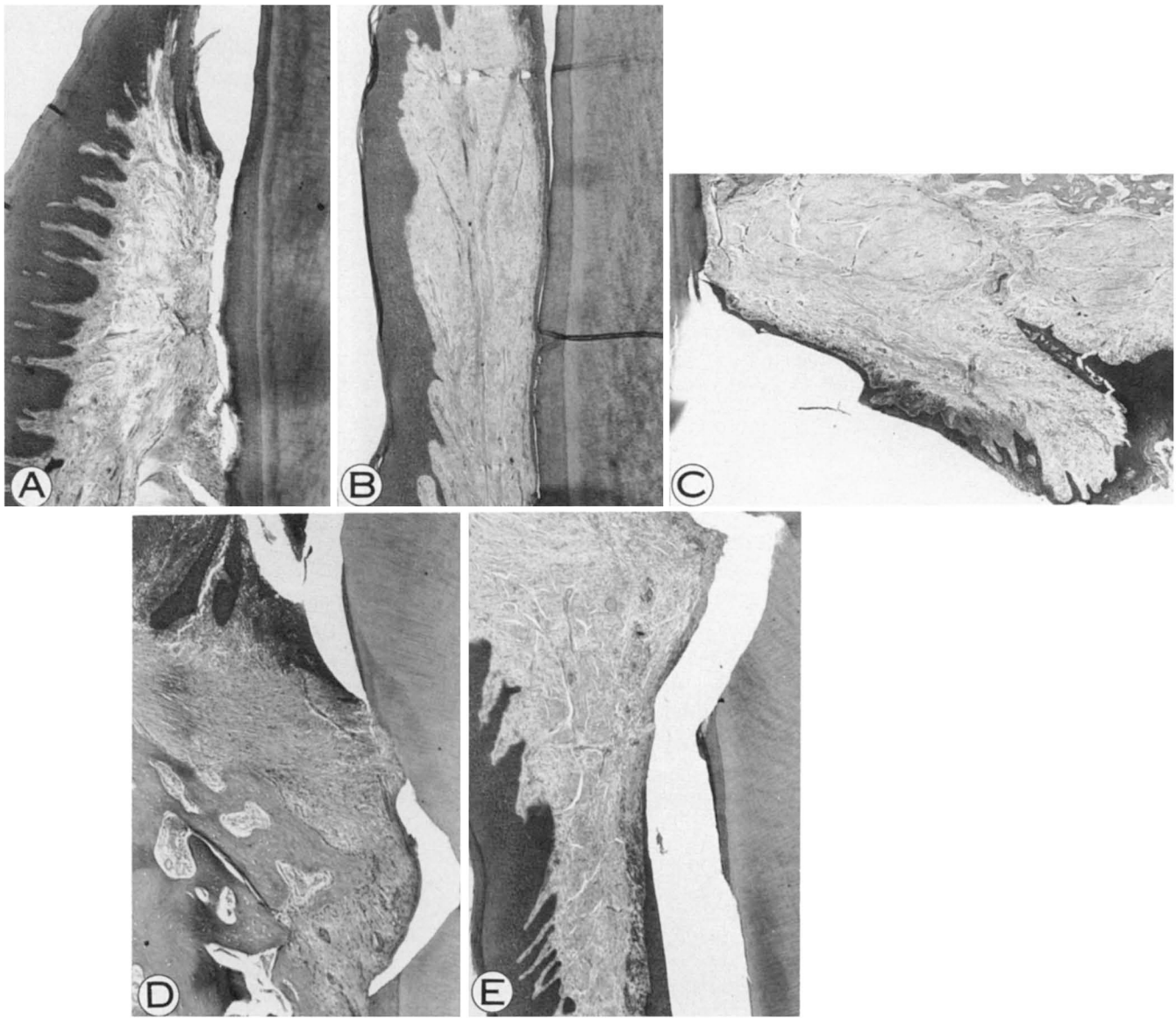


FIGURE 4A. Good flap adaptation, 35 days cyanoacrylate (original magnification,  $\times 50$ ). B. Long junctional epithelium, 35 days cyanoacrylate (original magnification,  $\times 50$ ). C. Third intention healing, 35 days cyanoacrylate (original magnification,  $\times 31.25$ ). D. Regeneration of bone and cementum coronal to notch in dentin, 35 days cyanoacrylate (original magnification,  $\times 50$ ). E. Connective tissue readaptation to notch in dentin without cementum attachment, 35 day cyanoacrylate (original magnification,  $\times 50$ ).

with a junctional epithelium of variable length, being longer than normal. A shallow gingival crevice has been reestablished. The junctional epithelium is thin, and is closely adapted to the tooth surface, even where this is very irregular. The apical extent of the junctional epithelium is in almost all cases considerably short of the apical margin of the area instrumented at surgery (Fig. 5A). In isolated areas, the junctional epithelium does reach, and rarely even overlap the unoperated cementum.

Inflammation is mild beneath buccal and lingual flaps, and where found, is associated with the crevicular epithelium. Interdental areas show mild to moderate inflammation, rarely extending into the periodontal ligament and marrow spaces. Plaque and debris are prominent in interdental areas. Budding of the junctional epithelium is seen associated with severe inflammation on one in-

terdental section (Fig. 5B). An intact fiber attachment is seen immediately apical to this area.

Foreign body giant cell reactions are seen in three areas involving both of the animals in this experimental group. Where these reactions are found, they are extremely localized, and do not disrupt the fiber pattern in the connective tissues. All three areas are within the gingival connective tissue, although one area is on the surface of the alveolar crest. In this area, there is superficial bone resorption, but the overlying transseptal fibers are undisturbed (Fig. 5C). In all such areas, an oily material which does not stain with oil red O, is found.

Good functional orientation of gingival fibers is observed in all sections at this time (Fig. 5D).

Bone remodeling has resulted in maturation of osteoid to provide smooth crestal contours in all areas (Fig. 5A).

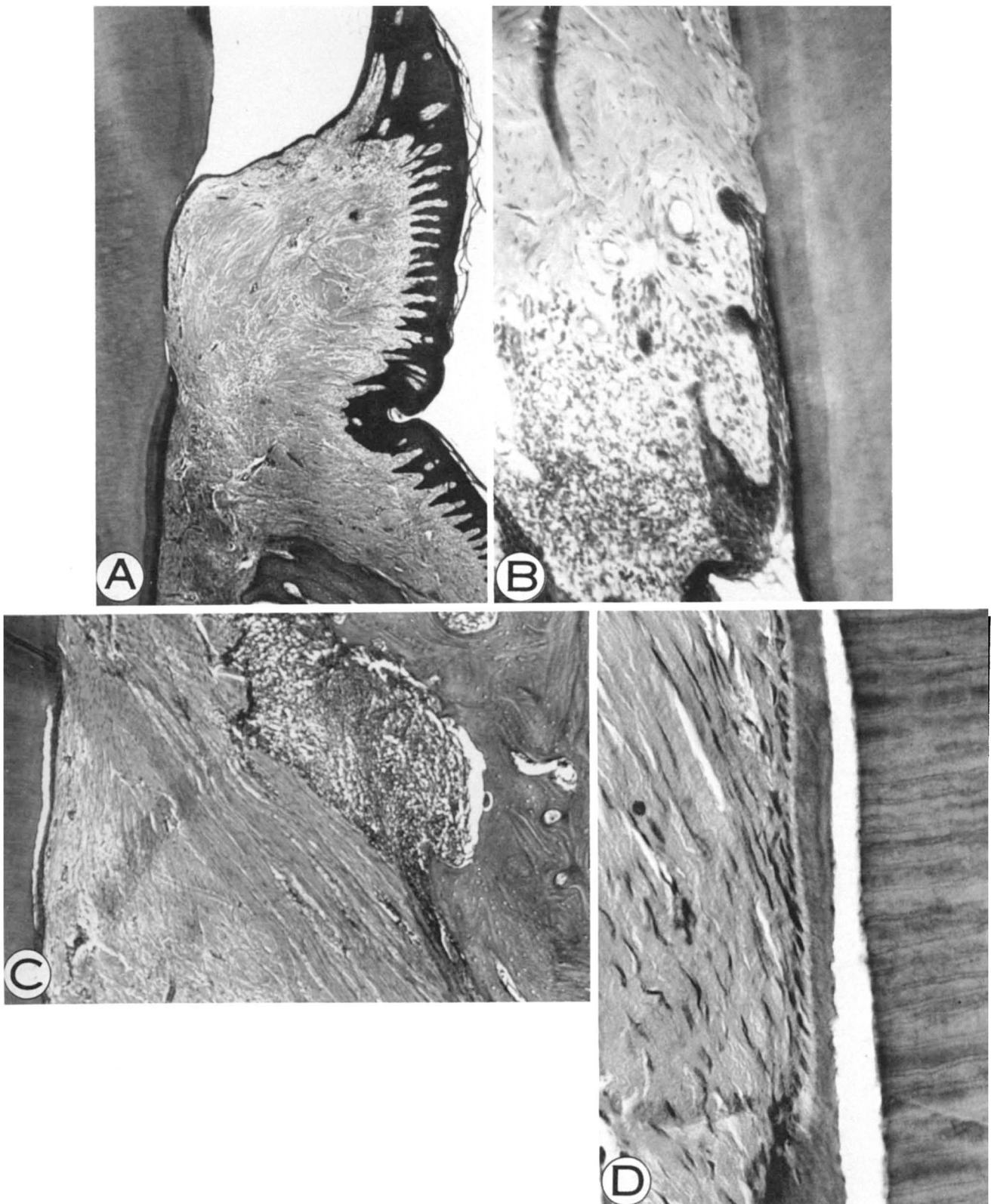


FIGURE 5A. Marginal gingiva with long junctional epithelium, 180 days cyanoacrylate (original magnification,  $\times 31.25$ ). B. Budding of junctional epithelium associated with inflammation, 180 days cyanoacrylate (original magnification,  $\times 125$ ). C. Foreign body reaction on surface of alveolar crest, 180 days cyanoacrylate. Note good fibers, and long junctional epithelium (original magnification,  $\times 50$ ). D. Fiber attachment to new cementum, 180 days cyanoacrylate (original magnification,  $\times 312.5$ ).

Cementum deposition has been thick in many sections, lining notches in dentin produced at surgery. Active cementoblasts are seen in most areas. Fiber attachment

in the dentin notches generally shows functional orientation at this time. A few areas remain where connective tissue fibers are only closely adapted to the root surface.

In such areas, the orientation of fibers is parallel to the root surface.

### *Sutured Flaps*

Distinct suture tracts were seen in the 12 hour specimens, with considerable associated debris. Interdental flap apposition at this time interval was good in suture-treated areas.

At 14 days, inflammation was greater beneath sutured flaps than beneath comparable cyanoacrylate-treated areas (Fig. 6). In all other respects, the healing patterns in areas where sutures had been applied were similar to those described for areas to which cyanoacrylate had been applied (Figs. 7, 8A, and 8B).

An area of foreign body reaction was found on one section from a 180 day sutured segment. This area was just below the crevicular epithelium, and contained an oily material which did not stain with oil red O (Fig. 8C).

### DISCUSSION

The patterns of healing observed in the present study are in basic agreement with those reported by other authors.<sup>1, 16-19</sup> A considerable reduction in surgery time was obtained in those segments to which the cyanoac-

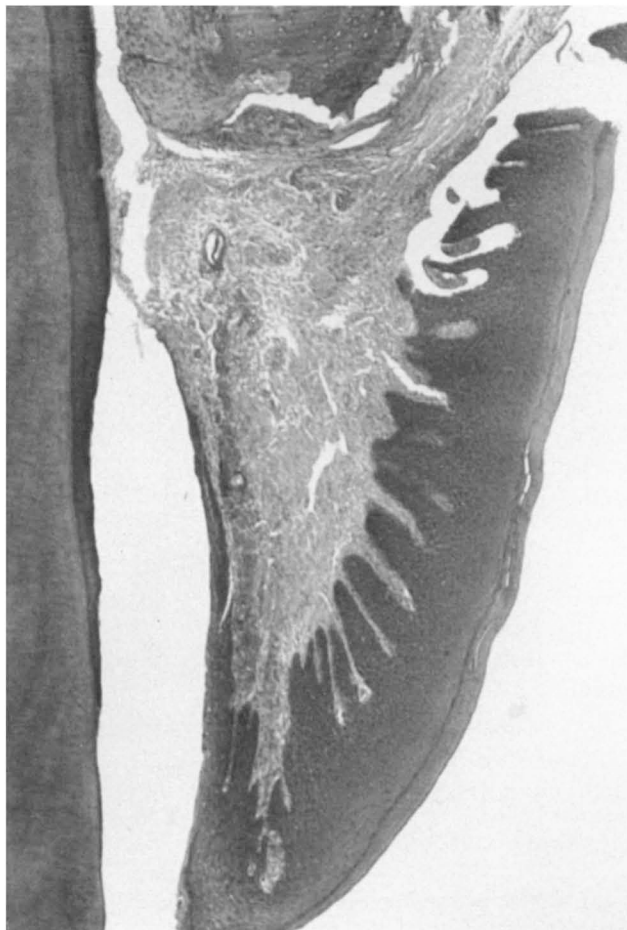


FIGURE 6. *Good flap adaptation, 14 days sutures (original magnification,  $\times 50$ ).*

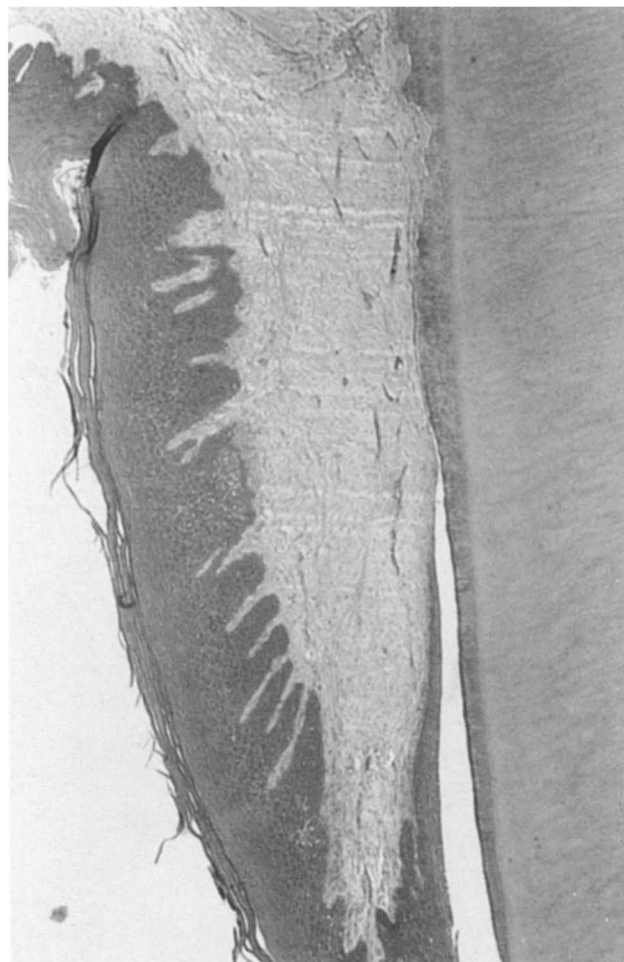


FIGURE 7. *Good flap adaptation, 35 days sutures (original magnification,  $\times 50$ ).*

rylate adhesive was applied as the means of flap immobilization. An important practical consideration with use of cyanoacrylate is to ensure that primary flap adhesion by a thin fibrin coagulum has taken place prior to application of the adhesive. Pressure applied to flap tissues after placement of the cyanoacrylate may result in cracking of this material, with loss of tissue bonding. Primary flap adhesion may be best obtained by application of the adhesive. Similar gauze pressure is generally recommended after placement of conventional sutures, to ensure that blood clot thickness is minimal between the flap and the underlying tissues. The pressure effect upon the flap tissues of tight sutures is not obtained when cyanoacrylate is the means of flap immobilization.

### *Flap Adaptation*

Interdental flap apposition in the earliest specimens observed (12 hours) was not good where cyanoacrylate had been employed, whereas, sutures did maintain good interdental flap apposition. In this animal, clinical apposition of flaps was good at the time of fixation, in all segments. It is therefore concluded that the removal of interdental flap tissues in cyanoacrylate-treated segments was an artefact of preparation. It should be noted that



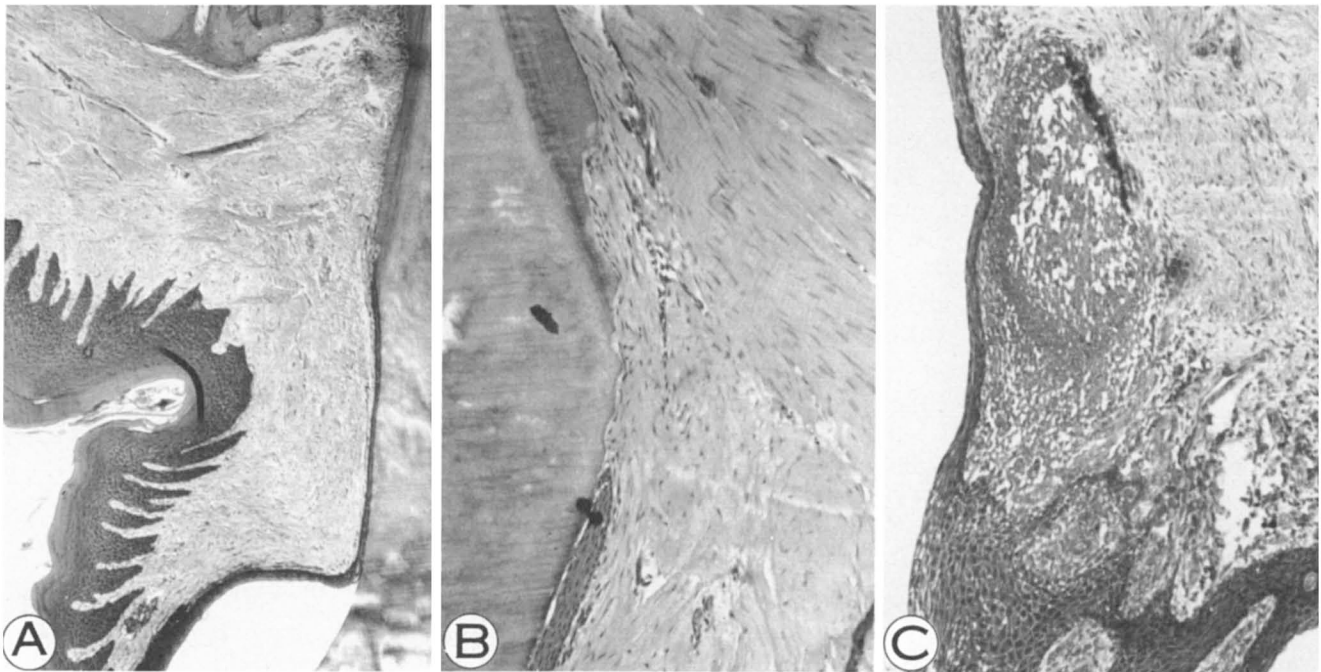


FIGURE 8A. Marginal gingiva with long junctional epithelium, 180 days sutures (original magnification,  $\times 50$ ). B. Connective tissue readapted to dentin without cementum attachment, 180 days sutures (original magnification,  $\times 125$ ). C. Foreign body reaction, 180 days sutures (original magnification,  $\times 125$ ).

sutures remained in place in sutured segments throughout the sectioning procedure, since these were present at the time of death.

Interdental flap apposition at 14 days in cyanoacrylate-treated areas was as good as, or better than, that found in sutured areas.

Buccal and lingual flap adaptation with cyanoacrylate was not different from that found with sutures at any time interval.

Interdental areas in monkeys are distinctly less amenable to periodontal surgery than the same areas in humans. Precise placement of cyanoacrylate to achieve interdental flap apposition may be easier in the wider interdental spaces in humans.

### Epithelium

The establishment of an epithelial seal against the tooth was not delayed in the present study by application of cyanoacrylate. Previously reported inhibition of epithelialization by cyanoacrylates<sup>9, 10, 20, 21</sup> may have been related to the need to expel the material from the wound edges prior to the reestablishment of an epithelial seal. In this study, the cyanoacrylate was placed only as a surface adhesive, and care was taken to ensure good epithelial adaptation to the tooth surface before and during placement of the adhesive. Thus, the material did not interfere with epithelial regeneration. Regardless of the material used to gain flap immobilization in the present study, a functional marginal gingiva had been reestablished by 180 days in all sections. Histological crevice depth was shallow, but a longer than normal junctional epithelium was present.

Inflammation was minimal buccally and lingually at

all observation times, and was usually associated with the crevicular area. Where proliferative activity was seen in the junctional epithelium, this was related to plaque-induced inflammation, and was equally likely with either modality. It seems that regular complete plaque removal will prevent loss of attachment following periodontal surgery, as also has been shown in humans. In the present study, fiber attachment was not necessary to halt apical migration of epithelium. A close connective tissue adaptation to the tooth surface was essential. Flap adaptation to ensure this tight tissue adaptation must include both connective tissue and epithelium, otherwise epithelial ridges would develop. In view of this possibility, healing by third intention is considered less desirable than other patterns of healing.

### Connective Tissue

An impression on observation of the histological specimens in the present study was that buccal and lingual inflammation was less in segments treated with cyanoacrylate than those treated with sutures at 14 days, which is in agreement with clinical observations. Increased inflammation found previously by other authors<sup>21</sup> on application of cyanoacrylates as periodontal flap dressings is presumed to occur only when the material is placed within the tissues, whether this is deliberate or inadvertent. This was not the case in the present study, since at no time was a positive reaction found within the tissues on sections stained with oil red O. In the present study, even where healing occurred by third intention, no increase in inflammation was observed in cyanoacrylate-treated areas over corresponding suture-treated areas. It seems that the particular cyanoacrylate used in

the present study formed a thin layer over such tissues, which did not become entrapped in granulation tissue as was the case in a previous study.<sup>12</sup>

Interdental inflammation was more prominent than buccal or lingual, and was about equal with both modalities. This is related to accumulation of plaque in these areas. Only rarely with either modality was inflammation observed spreading into the periodontal ligament and bone marrow spaces. Functional orientation of gingival fibers in cyanoacrylate-treated segments followed the same pattern as in sutured segments, with a parallel orientation seen where close connective tissue readaptation had been achieved. Functional orientation of fibers was seen at 35 days in some areas, and more commonly at 180 days. Most areas which healed by third intention showed mild or moderate inflammation at all time intervals. Interdental areas frequently showed such a pattern of healing with both modalities, despite the good flap apposition seen in the earliest sutured specimens. It is evident that tight interdental flap apposition leading to healing by primary intention is extremely difficult to achieve in monkeys, regardless of the method of flap immobilization. Nonetheless, there was a tendency for regeneration of periodontal attachment apparatus in interdental areas. No difference in this regard was seen with either modality tested. Flap surgery in monkeys results in alteration of the normally well-filled interdental spaces, so that food impaction and plaque accumulation are accentuated in these areas. Dental floss cannot be passed easily between the extremely tight contacts, because of sharp marginal ridges in these animals. The use of a reciprocating action interdental cleaning device in a rotary handpiece, similar to that observed in the more accessible buccal and lingual areas in the present study, might be considered appropriate to maintain a high level of plaque control in these regions.

#### *Bone Reaction*

Bone reaction beneath cyanoacrylate-treated flaps was similar to that observed with sutures. Resorption was generally completed by 14 days, with subsequent remodeling and some regeneration. Significant regeneration of alveolar bone coronal to areas of dentin notched at surgery was found with both modalities.

#### *Cementum*

Cementum resorption apical to the alveolar crest and distant from the areas of surgery is considered related to bruxism, and was found with both modalities. Bruxism may have been accentuated by the use of restraining collars in all animals during the first postoperative week. Cementoblastic activity was affected by the surgery in all segments. At 14 days, no significant new cementum deposition was observed with either modality, and by 35 days, new cementum was being deposited from the most apical part of the operated area. In cyanoacrylate-treated segments, an impression was gained of thicker new cementum deposition than in corresponding suture-treated

areas, both at 35 and 180 days. Cementum was found lining notches in dentin produced at surgery regardless of the mode of flap immobilization.

#### *Foreign Body Reactions*

Foreign body giant cell reactions were found only in four sections in the present study, all of these being in 180 day monkeys. One of these areas was in a segment to which sutures had been applied rather than cyanoacrylate. In none of the areas was found a positive reaction to oil red O stain. The foreign body introduced was therefore considered not to be cyanoacrylate in any of the specimens. No interference with marginal healing was observed in association with these areas. One potential source of foreign body irritation might have been oil from the rotary handpieces used at surgery for bone removal, and subsequent to surgery for prophylaxes.

#### *Advantages of Cyanoacrylate Adhesives*

There is no doubt that surgery time can be substantially reduced by use of cyanoacrylate adhesives for flap immobilization, since these are so rapidly applied. Immediate hemostasis is almost always achieved with a single application of the adhesive.

No deleterious effects upon healing have been found attributable to the application of cyanoacrylate in the present study. The pattern of healing is dependent upon flap adaptation, and control of inflammation.

Flap adaptation buccally and lingually was as good with cyanoacrylate as with sutures. Interdental flap apposition must be presumed equivalent also, as healing in cyanoacrylate-treated areas was not different from that seen in sutured areas.

Reduced inflammation was observed clinically and histologically with use of cyanoacrylate in the early healing stages. Where reattachment is a surgical aim, this may be an important consideration.

#### *Clinical Significance*

In the present study, the cyanoacrylate adhesive used has shown no histotoxic effects which would affect healing after flap surgery, when applied as a surface adhesive and dressing. It may be expedient in the human clinical situation to ensure good flap adaptation interdentally by use of sutures prior to precise application of MBR 4197 to form a thin adhesive layer over the apposed flap edges.

Reduced inflammation and good flap adaptation are considered to offer the best potential for reattachment. Both aims may be aided by use of MBR 4197.

#### SUMMARY

Experimental periodontal surgery was performed on six adult Rhesus monkeys, using the modified Widman flap technique. Each monkey provided four or six segments for flap surgery, and three different experimental time intervals were used.

Flaps were immobilized after surgery by conventional

sutures or by application of MBR 4197 cyanoacrylate spray. Each animal provided its own contralateral comparison, and the mode of flap immobilization was reversed in the corresponding segments in the other animal of each experimental group.

One monkey died approximately 12 hours after surgery, and the other animals were sacrificed at 14, 35 and 180 days.

Histological sections were prepared from all operated areas, and examined for the pattern of healing. A special staining technique was used to determine the presence of MBR 4197 within the tissues.

#### Findings in This Study Were

a. Clinical and histological inflammation was reduced in the early stages of healing when MBR 4197 was used as the means of flap immobilization, as compared with sutures. No differences were observed in the later stages of healing with either modality.

b. Healing was satisfactory with both modalities. The histological healing pattern is determined by the state of adaptation of the flaps, and the control of postoperative inflammation. Healing by first, second, and third intention was observed with both modalities tested. Buccal and lingual flap adaptation was generally good with either modality, while interdental flap adaptation was less good with either modality. Inflammation was more prominent in interdental areas, and was associated with continuing accumulation of plaque in these areas.

c. MBR 4197 was not introduced into the tissues by the means of application used. This compound did not interfere with the pattern of healing in any of the periodontal tissues. Healing of epithelium took place in all sections by 14 days, with subsequent maturation to reestablish a functional marginal gingiva. Functional orientation of gingival fibers was reestablished between 35 and 180 days, where there was close connective tissue adaptation without apparent fiber reattachment. In these areas, the gingival connective tissue fibers were oriented parallel to the root surface. Regeneration of cementum and alveolar bone was found coronal to operated areas even where deep notches in dentin had been produced at surgery.

#### CONCLUSIONS

Within the limitations of the present study, it may be concluded that: (a) Following modified Widman flap surgery, MBR 4197 provides flap adaptation buccally and lingually as good as that obtained with conventional sutures, and with reduced operative time, and (b) MBR 4197 does not interfere with clinical or histological healing following modified Widman flap surgery, when

placed as a superficial adhesive layer.

#### REFERENCES

1. Caffesse, R. G., Ramfjord, S. P., and Nasjleti, C. E.: Reverse bevel periodontal flaps in monkeys. *J Periodontol* **39**: 219, 1968.
2. Hiatt, W. H.: Regeneration via flap operation and the pulpal periodontal lesion. *Periodontics* **4**: 205, 1966.
3. Ramfjord, S. P., and Nissle, R. R.: The modified Widman flap. *J Periodontol* **45**: 601, 1974.
4. Rosling, B., Nyman, S., and Lindhe, J.: The effect of systematic plaque control on bone regeneration in periodontal pockets. *J Clin Periodont* **3**: 38, 1976.
5. DeRenzis, F. A., and Aleo, J. J.: An in vitro bioassay of cyanoacrylate toxicity. *Oral Surg* **30**: 803, 1970.
6. Kline, D. G., and Hayes, G. J.: An experimental evaluation of the effect of a plastic adhesive, methyl-2-cyanoacrylate, on neural tissue. *J Neurosurg* **20**: 647, 1963.
7. Raekellio, J., and Seligman, A. M.: Acute reaction to arterial adhesive in healing skin wounds. *J Surg Res* **4**: 124, 1964.
8. Woodward, S. C., Herrmann, J. B., and Cameron, J. L.: Histotoxicity of cyanoacrylate tissue adhesive in the rat. *Ann Surg* **162**: 113, 1965.
9. Eriksson, L.: Cyanoacrylate for closure of wounds in the oral mucosa in dogs. *Odontol Revy* **27**: 19, 1976.
10. Greer, R. O.: Studies concerning the histotoxicity of isobutyl-2-cyanoacrylate tissue adhesive when employed as an oral hemostat. *Oral Surg* **40**: 659, 1975.
11. Matsumoto, T., Soloway, H., and Cutright, D.: Tissue adhesive and wound healing. *Arch Surg* **98**: 266, 1969.
12. Miller, G. M., Dannenbaum, R., and Cohen, D. W.: A preliminary histologic study of the wound healing of mucogingival flaps when secured with the cyanoacrylate tissue adhesives. *J Periodontol* **45**: 608, 1974.
13. Nelson, R. A., Banitt, E., Kvan, D., Harrington, K., Robertson, J., and Buelow, J.: A new fluoroalkyl cyanoacrylate surgical adhesive. *Arch Surg* **100**: 295, 1970.
14. Medical Products Division, 3M Company, St. Paul, Minnesota. *Investigators Brochure MBR 4197*, 1974.
15. Pani, K. C., McAllister, W., Leonard, F., and Margetis, P.: Histochemical staining methods for localizing cyanoacrylate polymers in tissue sections. *Technical Report 6618*. Washington, D.C. Walter Reed Army Medical Center, December 1966.
16. Diem, C. R., Bowers, G., Ferrigno, P., and Fedi, P.: Regeneration of the attachment apparatus on pulpless teeth denuded of cementum in the Rhesus monkey. *J Periodontol* **45**: 18, 1974.
17. Listgarten, M. A.: Periodontal tissue repair over surgically exposed dentin and cementum surfaces. Abstr. No. 473. *I.A.D.R. Abstracts* 1971.
18. Listgarten, M. A.: Electron microscopic study of the junction between surgically denuded root surfaces and regenerated periodontal tissues. *J Periodont Res* **7**: 68, 1972.
19. Persson, P. A.: The marginal periodontium after flap operation. *Acta Odontol Scand* **20**: 43, 1962.
20. Hunsuck, E. E., Cutright, D. E., and Bhaskar, S. N.: Modified delayed closure of facial wounds with isobutyl cyanoacrylate. *Oral Surg* **29**: 305, 1970.
21. Ochstein, A. J., Hansen, N. M., and Swenson, H. M.: A comparative study of cyanoacrylate and other periodontal dressings on gingival surgical wound healing. *J Periodontol* **40**: 515, 1969.