

Case Series

Surgical Crown Lengthening in a Population With Human Immunodeficiency Virus: A Retrospective Analysis

Shilpa Kolhatkar,* Suzanne A. Mason,† Ana Janic,* Monish Bhola,* Shaziya Haque,‡ and James R. Winkler*

Background: Individuals with human immunodeficiency virus (HIV) have an increased risk of developing health problems, including some that are life threatening. Today, dental treatment for the population with a positive HIV diagnosis (HIV+) is comprehensive. There are limited reports on the outcomes of intraoral surgical therapy in patients with HIV, such as crown lengthening surgery (CLS) with osseous recontouring. This report investigates the outcome of CLS procedures performed at an urban dental school in a population of individuals with HIV. Specifically, this retrospective clinical analysis evaluates the healing response after CLS.

Methods: Paper and electronic records were examined from the year 2000 to the present. Twenty-one individuals with HIV and immunosuppression, ranging from insignificant to severe, underwent CLS. Pertinent details, including laboratory values, medications, smoking history/status, and postoperative outcomes, were recorded. One such surgery is described in detail with radiographs, photographs, and a videoclip.

Results: Of the 21 patients with HIV examined after CLS, none had postoperative complications, such as delayed healing, infection, or prolonged bleeding. Variations in viral load (<48 to 40,000 copies/mL), CD4 cell count (126 to 1,260 cells/mm³), smoking (6 of 21 patients), platelets (130,000 to 369,000 cells/mm³), and neutrophils (1.1 to 4.5 × 10³ /mm³) did not impact surgical healing. In addition, variations in medication regimens (highly active anti-retroviral therapy [18]; on protease inhibitors [1]; no medications [2]) did not have an impact.

Conclusions: The results of this retrospective analysis show the absence of postoperative complications after CLS in this population with HIV. Additional investigation into this area will help health care practitioners increase the range of surgical services provided to this group of patients. *J Periodontol* 2012;83:344-353.


KEY WORDS

Bone and bones; crown lengthening; facial bones; HIV; oral surgical procedures, preprosthetic.

* University of Detroit Mercy School of Dentistry, Department of Periodontics and Dental Hygiene, Detroit, MI.

† Graduate Periodontics Program at the University of Michigan, Ann Arbor, MI.

‡ Private practice, Odessa, TX.

 indicates supplementary video in the online *Journal of Periodontology*.

The introduction of highly active antiretroviral therapy (HAART) has led to reduction in the incidence of new acquired immune deficiency syndrome (AIDS) cases and the morbidity and mortality associated with human immunodeficiency virus infection (HIV).¹⁻³ In the initial stages of the HIV epidemic, dental treatment was focused on the management of HIV-associated oral lesions. Based on a survey of dental professionals' attitudes toward the treatment of the population with HIV, some suggested that this population required treatment in specialized centers.⁴ Other investigators have suspected this population to have higher complication rates after dental procedures but found no significant difference among individuals with HIV+ and HIV-negative status (HIV-).⁵

Today, the population with HIV has the potential for an increased life expectancy as a result of advances in their overall care. Routine comprehensive care is often the primary dental need for well-managed patients with HIV. This treatment may include preprosthetic surgery, such as vestibuloplasty, soft-tissue grafting, implant placement, implant-related procedures, and crown lengthening (CLS).

According to a practice profile survey in 2003, CLS is one of the most common reasons for periodontal surgery.⁶ Restoring teeth to their proper anatomic form, function, and esthetics requires preparing a well-defined restorative margin. For example, this may not be obtainable in the presence of subgingival decay, crown/root fracture, or endodontic perforation. CLS makes the margins easily accessible for accurate impressions and ultimately results in good marginal adaptation of the restoration. In addition, CLS can achieve longer clinical crowns⁷⁻¹¹ and reestablish the biologic width^{12,13} by removal of hard and soft tissues.¹⁴⁻¹⁶ The general consensus is that CLS should create ≥ 3 mm of sound tooth structure between the alveolar crest and the restorative margin.¹⁷⁻¹⁹ Therefore, surgical intervention in the form of CLS is often necessary.²⁰

Reports of intraoral surgical procedures in a population with HIV are mainly limited to extractions,²¹⁻²⁴ implant placement,²⁵⁻³² and vestibuloplasty using palatal soft-tissue grafts.³³ There are isolated reports of other periodontal surgical procedures, including the use of a lateral sliding flap and resin-modified glass ionomer for the management of an isolated recession defect.³⁴ To our knowledge, this is the first documentation that describes CLS with osseous recontouring in a population with HIV. In this retrospective analysis, only one individual had a CD4 count of < 200 cells/mm³. The remaining 20 patients had immunosuppression levels that were generally mild (< 500 cells/mm³ in eight patients) to no significant immunodeficiency (> 500 cells/mm³ in 12 patients).³⁵

MATERIALS AND METHODS

An 11-year retrospective analysis of paper and electronic records (Institutional Review Board #0910-23) at the University of Detroit Mercy School of Dentistry (UDMSOD), Detroit, MI, was conducted, and 21 individuals with HIV were identified who underwent CLS.

The HIV+ status of patients is based on self-reporting in the health history questionnaire and from the information provided by their treating physicians. Presurgical laboratory values for each patient consisted of the following: 1) CD4 cell count; 2) total white blood cell count (WBC); 3) viral load; 4) neutrophil, platelet count, hemoglobin, and hematocrit values. Other pertinent details, including medical history, medications, smoking status, and postoperative (PO) outcomes, were recorded. None of the patients required antibiotic prophylaxis, and none were prescribed antibiotics postoperatively.

All procedures were performed by periodontal faculty and periodontal residents at the UDMSOD under local anesthesia.[§] PO management included written and verbal PO instructions and prescriptions for ibuprofen (600 or 800 mg; every 6 to 8 hours as needed for pain) and 0.12% chlorhexidine gluconate mouth rinse (15 mL; twice daily). All patients were seen at $\approx 1, 2,$ and 4 weeks PO for clinical evaluation.

Different factors were analyzed and compared relative to the surgical outcome. For example, maxillary versus mandibular, anterior versus posterior surgical site, males versus females, smoking status, duration of HIV+ status, and faculty versus resident performing the procedure were compared.

A detailed description of the presurgical preparation, surgical procedure, and PO healing of one case (#17) is provided below. The other CLS were performed in a similar manner with minor changes made to the flap design and amount of the bone removal necessary based on the clinical situation. A summary of all 21 cases can be found in Table 1.

Detailed Description of the Procedure Performed in Case #17

A 62-year-old African American man was referred to the Graduate Periodontics Clinic at the UDMSOD. Recurrent subgingival decay was noted on the distal surfaces of both the first and second maxillary right premolars (Fig. 1). After caries removal and reevaluation, invasion of the biologic width was observed on teeth #4 and #5, and CLS was consequently indicated.

A review of the patient's medical history indicated that he was diagnosed with HIV in 1987 and has since been regularly monitored by his physician. His medical history stated that he was positive for hepatitis B,

§ 2% lidocaine HCL with 1:100,000 epinephrine, Benco Dental, Wilkes-Barre, PA.

Table 1.
A Summary of Medical History, Laboratory Values, Medications, Surgical Dates, and Surgical Outcomes of 21 Cases

Patient's Sex, Age (Years)	Date of HIV Diagnosis	Other Medical Conditions/Smoking	H-AART Treatment (Yes/No)	CD4 (Cells/mm ³)	Viral Load (Copies/mL)	Neutrophils (×10 ³ /mm ³)	Total WBC (×10 ³ /mm ³)	Platelets (×10 ³ /mm ³)	Hemoglobin (g/dL)	Hematocrit (%)	Tooth #	Date of Crown Lengthening	Date of Restoration	Complications*	Medications	Osseous Surgery (Yes/No)
Male, 55	1992	History of non-Hodgkin's lymphoma, hip replacement, smoker	Yes	126	3,100	3.9	6.1	165	13.4	40	5, 6, 18	Apr 2003	May 2003	None	Aptivus, Norvir, Truvada	Yes
Male, 53	2003	Penicillin allergy, non-smoker	Yes	210	400	1.4	3.4	235	15.5	45.5	32	Feb 2005	Dec 2005	None	Atripla, Kaletra, Trizivir	Yes
Male, 53	1984	Hepatitis B, non-smoker	Yes	240	40,000	2.5	5.9	202	13.1	39.1	30	Feb 2004	Mar 2004	None	Kaletra, Tenofovir	Yes
Male, 37	1993	Heart murmur, seasonal allergies, non-smoker	No	272	5,500	3.8	5.9	207	13.9	42.2	8	Feb 2004	Apr 2004	None	None	Yes
Male, 69	2007	Depression, hypertension, non-smoker	Yes	355	<48	3.8	4.3	194	12.4	36.8	3	Jan 2009	Jan 2009	None	Reyataz, Norvir, Truvada	Yes
Male, 57	2004	Hepatitis B, smoker	Yes	370	<48	2.6	5.4	189	17.8	51.2	31	Oct 2009	Jan 2010	None	Kaletra (Lopinavir/Ritonavir), Truvada	Yes
Male, 44	2003	Penicillin allergy, non-smoker	Yes	373	248	1.5	4.2	227	14.6	44.2	31	Jul 2010	Dec 2010	None	Atripla	Yes
Male, 53	1983	None, non-smoker	Yes	400	2,000	1.1	3.7	130	14.5	40.7	14	Jan 2004	March 2004	None	Atazanavir (Reyataz), Tenofovir, Ritonavir (Norvir), Didanosine (Videx)	Yes
Female, 20	1991	Non-smoker	Yes	486	1,160	1.7	3.8	256	12	37	3	Mar 2010	Jul 2010	None	Truvada, Norvir, Reyataz	Yes
Female, 57	1993	Hepatitis B and C, one pack/day smoker	Yes	536	<50	2.7	5.1	168	14.8	40.5	20	Apr 2002	Sep 2002	None	Combivir, Viralept	Yes
Male, 59	2001	Hypertension, non-smoker	Yes	574	<48	2.8	5.2	219	13.9	41.7	31	Jan 2009	Jul 2009	None	Tenofovir, Emtricitabine, Epzicom	Yes

Table 1. (continued)
A Summary of Medical History, Laboratory Values, Medications, Surgical Dates, and Surgical Outcomes of 21 Cases

Patient's Sex, Age (Years)	Date of HIV Diagnosis	Other Medical Conditions/Smoking	HAART Treatment (Yes/No)	CD4 (Cells/mm ³)	Viral Load (Copies/mL)	Neutrophils (×10 ³ /mm ³)	Total WBC (×10 ³ /mm ³)	Platelets (×10 ³ /mm ³)	Hemoglobin (g/dL)	Hematocrit (%)	Tooth #	Date of Crown Lengthening	Date of Restoration	Complications*	Medications	Osseous Surgery (Yes/No)
Female, 42	2004	Depression, non-smoker	Yes	585	3,000	1.5	3.6	212	12.1	35.9	14, 15	Feb 2009	Nov 2009	None	None	Yes
Male, 40	2006	Smoker	Yes	585	<50	6.2	6.1	351	15.4	n/a	3	Oct 2009	Dec 2009	None	Atripla	Yes
Male, 57	1991	Hepatitis B, non-smoker	Yes	612	<40	2.7	7.3	198	18.3	52.4	3	Mar 2002	Apr 2002	None	Epivir, Ziagor, Viramune	Yes
Male, 63	2005	None, non-smoker	Yes	746	<50	4.2	7.2	363	14.5	42.5	14, 15	Jun 2008	May 2009	None	Kaletra, Truvada, Sustiva (Efavirenz)	Yes
Male, 36	1999	Smoker	Yes	779	<48	1.8	5	242	14.2	44	31	Jan 2011	n/a	None	Atripla	Yes
Male, 64	1987	Latex and nickel allergy, hepatitis B, history of cocaine use, non-smoker	Yes	800	115	4.2	7.9	162	12.9	40.1	4.5	Nov 2008	Jan 2009	None	Kaletra	Yes
Male, 50	1985	Penicillin allergy, non-smoker	Yes	887	<40	2.7	6	153	15.5	44.1	14	Jan 2011	Feb 2011	None	Indinavir, Reyataz, Nevirapine, Norvir	Yes
Female, 39	2001	History of tuberculosis, asthma, smoker	Yes	1,046	<75	1.7	4.7	197	13.5	40.4	4	Dec 2008	Mar 2009	None	Efavirenz + Emtricitabine + Tenofovir (Atripla)	Yes
Male, 49	2004	Knee joint replacement, herpes simplex I, non-smoker	Yes	1,066	106	3.7	9.3	369	18.1	54.7	30	Apr 2008	Aug 2008	None	Tenofovir + Emtricitabine (Truvada), Atazanavir, Ritonavir	Yes
Male, 45	1989	Hepatitis B and C, penicillin allergy, hypertension, non-smoker	Yes	1,260	160	2.2	6.5	294	15.1	42.8	28	Sept 2007	Nov 2007	None	Tenofovir, Tribavirin, Atazanavir (Reyataz), Abacavir, Ritonavir (Norvir)	No

* Prolonged bleeding, delayed healing, and/or infection.

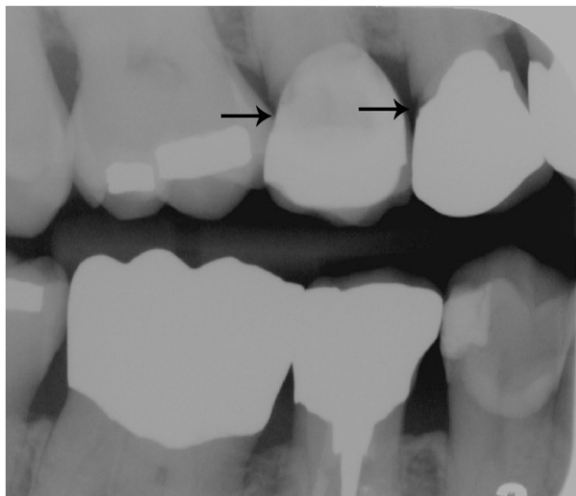

Figure 1.

Preoperative radiograph showing recurrent subgingival decay (black arrows) on the distal surfaces of both the first and second maxillary right premolars.

Table 2.

Presurgical Laboratory Values for Case #17

Variables	Values
CD4+ T lymphocyte count	800 cells/mm ³
Viral load	115 copies/mL
Neutrophil count	4.2 × 10 ³ /mm ³
WBC	7.9 × 10 ³ /mm ³
Platelet count	162 × 10 ³ cells/mm ³
Hemoglobin	12.9 g/dL
Hematocrit	40.1%

sickle cell trait, and has an allergy to latex and nickel. He also had a history of cocaine use and smoking. The patient's current medications included the protease inhibitors (lopinavir/ritonavir), an H2 receptor blocker (ranitidine), and an H1 receptor blocker (cetirizine). A review of the patient's social history indicated married status. He had been an active patient at UDMSOD since 1975 and denied any significant changes in diet during the past 5 years.

A presurgical medical consultation was sent to the patient's physician. The reported values are presented in Table 2.

Surgical Procedure

Written and oral informed consent for the surgical procedure was obtained, and the patient was educated regarding the surgical procedure and the PO healing

and care. Profound anesthesia was obtained,[§] and intrasulcular incisions were made on the facial and palatal surfaces of teeth #3 to #6. Extrasulcular incisions were made on the palatal surface of teeth #4 and #5 (Figs. 2A and 2B) (see supplementary video in the online *Journal of Periodontology*). A full-thickness flap was reflected facially and palatally. Ostectomy and osteoplasty were completed using hand and rotary instruments under copious irrigation. The presence of a bifurcation on the facial aspect of tooth #5 was noted and care was taken to minimize bone removal in the furcation area (Fig. 2C). The final topography of bone represented positive architecture with a knife-edged alveolar crest and the smooth transition of the bone level between adjacent teeth. A periodontal probe was used to confirm the presence of ≥3 mm of sound tooth structure coronal to the crest of bone on both premolars (Fig. 2D). The facial flap was apically positioned, and both flaps were sutured using 4-0 silk sutures^{||} (Figs. 2E and 2F). The provisional crowns were cemented on both premolars using temporary cement,[¶] and a periodontal dressing[#] was placed over the surgical site. The patient was advised to take ibuprofen (600 mg as needed) and prescribed chlorhexidine gluconate rinse^{**} (0.12%; twice daily for 2 weeks). The patient was asked to refrain from brushing the surgical area and chewing on the right side and was seen for PO appointments at 1, 3, and 4 weeks.

PO Healing Pattern

At the 1-week PO visit, the dressing and all remaining sutures were removed. The surgical site appeared to be healing well and the patient reported no post-surgical concerns. He was asked to clean the surgical area using an extra soft surgical toothbrush.^{††} The patient was then seen at 3 weeks PO, and the presence of slight erythema on the palatal gingiva was observed in the region of the premolars. Oral hygiene instructions were reinforced. The patient was seen again at 4 weeks PO and uneventful healing was observed (Fig. 3A). Approximately 12 weeks post-surgery, porcelain-fused-to-metal crowns were cemented on both premolars (Figs. 3B and 3C). For the next 2 years, the patient was seen regularly for routine dental care. At the 2-year follow-up, the patient exhibited pink healthy gingiva on teeth #4 and #5 with no visible signs of inflammation, bleeding on probing, or plaque accumulation. The gingival contour was firm and knife-edged (Fig. 4A). The bitewing and periapical radiograph revealed no evidence of recurrent caries,

^{||} 4-0 silk suture, Ethicon, Somerville, NJ.

[¶] Temp-Bond NE (Non-Eugenol) Accelerator, Kerr, Orange, CA.

[#] COE-PAK, GC America, Alsip, IL.

^{**} 0.12% chlorhexidine gluconate, 3M ESPE, St. Paul, MN.

^{††} GUM, Sunstar Americas, Chicago, IL.

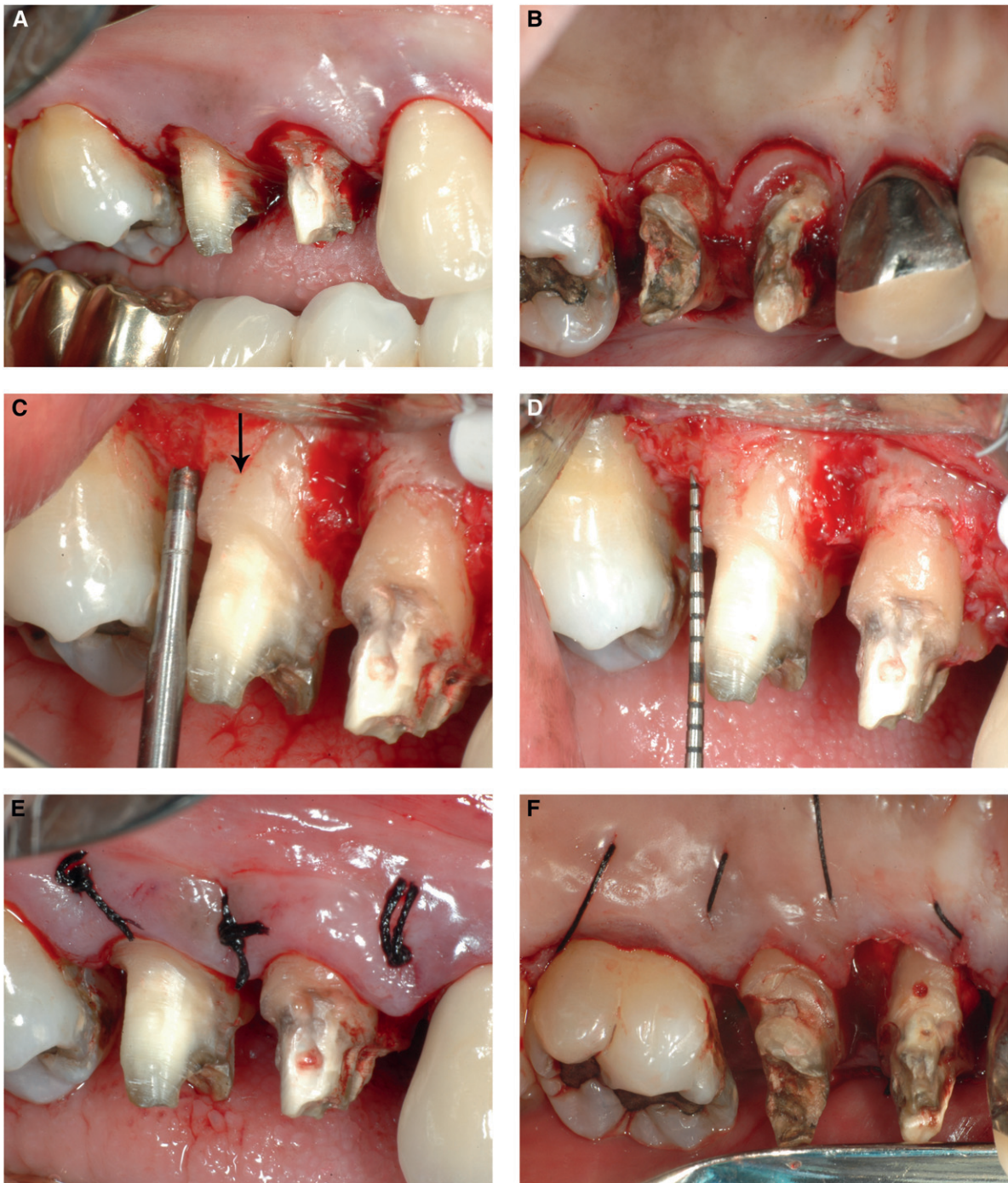

Figure 2.

A) Intrasulcular incision on the facial surfaces of teeth #3 to #6. **B)** Extrasulcular incisions were made on the palatal surface of teeth #3 and #6. **C)** The presence of a bifurcation (black arrow) on the facial aspect of #5 was observed after flap reflection. **D)** The presence of ≥ 3 mm of sound tooth structure on both premolars was confirmed. **E)** Facial view of apically positioned flap. **F)** Palatal view after sutures were placed.

marginal discrepancies, or periapical pathologies on teeth #4 and #5 (Figs. 4B and 4C).

RESULTS

The evaluation of the data from the 21 cases shows no complications with regard to delayed healing, pro-

longed bleeding, or infections. Most patients were seen at 1, 2, and 4 weeks PO, and almost all were treated by residents (19 of 21). The teeth were predominantly posterior teeth (19 of 21), with an equal distribution between the two arches (10 CLS teeth were in the mandible and 11 in the maxilla).

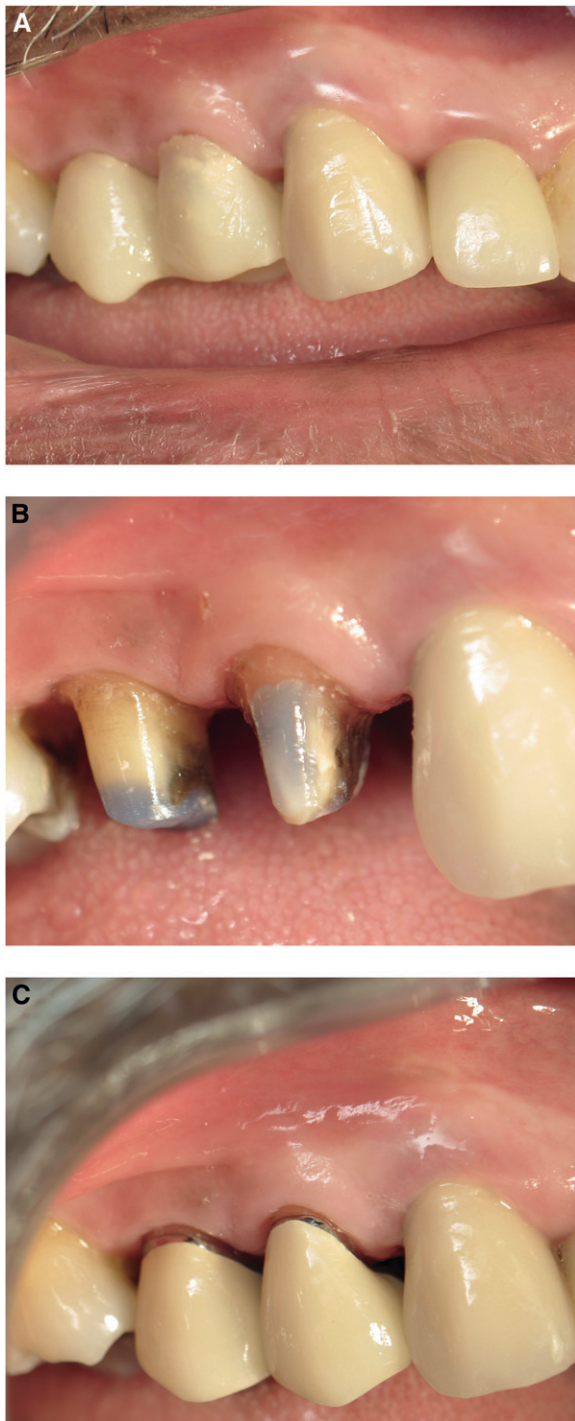

Figure 3.

A) Good oral hygiene seen around provisional crowns at the 4-week PO visit. **B)** Healthy gingiva with an absence of plaque and inflammation seen before cementation of definitive crowns. **C)** Facial view of definitive crowns cemented 12 weeks after CLS.

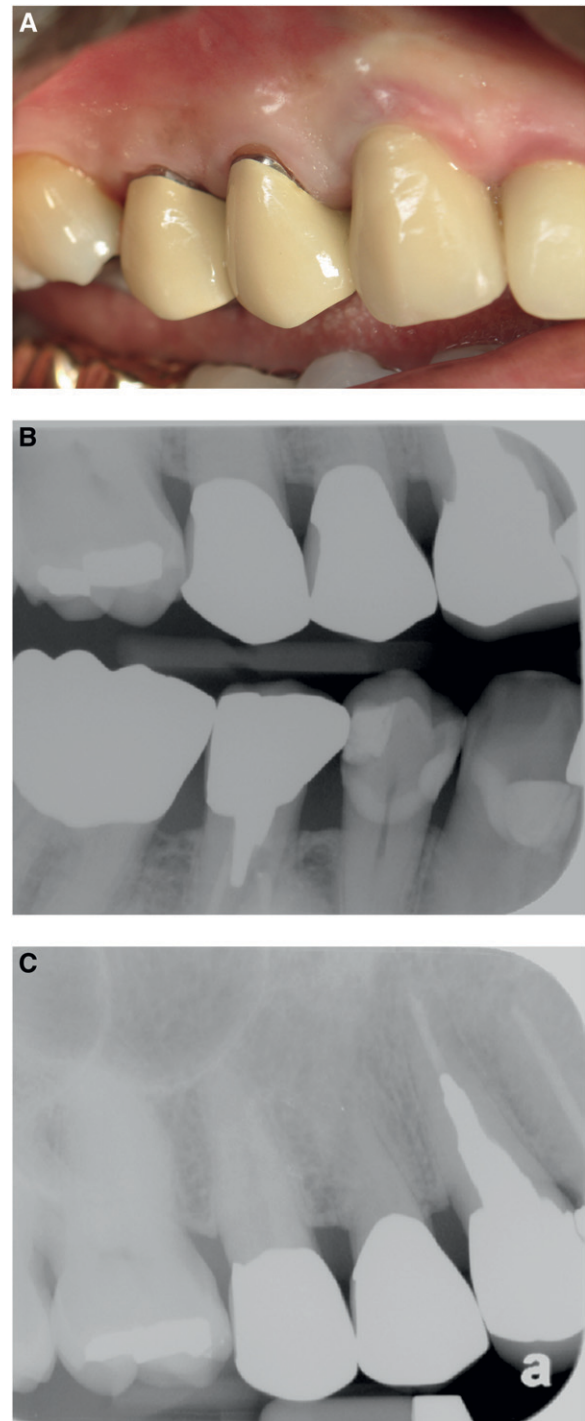


Figure 4.

A) Two-year PO facial view. **B)** Two-year bitewing radiograph showing no recurrent carious lesions. **C)** Two-year periapical radiograph showing maintenance of biologic width and crestal bone level.

The patients were predominantly male (17 of 21). At the time of surgery, the duration of HIV+ diagnosis ranged from 1 to 21 years (five were diagnosed in the 1980s, six in the 1990s, and 10 in the 2000s). Most of the patients were non-smokers (15 of 21), five were light smokers, and one was a heavy smoker. Despite the effect of smoking on periodontal wound healing, smoking did not appear to have an effect in the cases presented here.³⁶⁻³⁸

It is also important to note that the variations in viral load (<48 to 40,000 copies/mL), CD4 cell count (126 to 1,260 cells/mm³), platelets (130,000 to 369,000 cells/mm³), and neutrophils (1.1 to 4.5 × 10³/mm³) did not impact surgical healing. Based on CD4 counts, the levels of immunosuppression were insignificant in 12 individuals (>500 cells/mm³), mild in five individuals (350 to 499 cells/mm³), advanced in three individuals (200 to 349 cells/mm³), and severe in one individual (<200 cells/mm³).³⁵ Of the 21 patients, 18 were on HAART, one only on protease inhibitors, and two were taking no medications for HIV at the time of surgery. This variation in medication regimens also did not appear to have an impact on wound healing.

DISCUSSION

Oral manifestations are a classic component of the AIDS epidemic.¹ The discovery of HAART has brought substantial benefits to the population with HIV, such as improvements in their quality of life, increased life expectancy, and a dramatic decrease in oral manifestations of the disease.¹⁻³ Today, the dental needs of patients with HIV are consistent with the comprehensive dental care needs seen in the general population. Although antiretroviral medications are a mainstay in the management of HIV, they may have some adverse effects on the oral environment. A study that looked at long-term antiretroviral medication use found a reduction in salivary flow that may indirectly contribute to increased caries risk.^{39,40} The need for CLS in the presence of recurrent subgingival decay was described in Case 17.

HIV infection does not appear to be a risk factor for tooth loss according to a retrospective cross-sectional study that involved 193 HIV+ patients and 192 systemically healthy patients.²⁴ Using matched controls, comparing individuals with HIV+ to HIV- status, the results showed that age, race, and smoking status were all risk factors for tooth loss, but CD4+ cell count and viral load in the HIV+ patients did not influence tooth loss. The authors concluded that individuals with HIV treated with HAART are not at an increased risk for tooth loss when compared to systemically healthy individuals. Based on the fact that individuals with HIV are enjoying a longer lifespan and retaining their dentition for longer periods of time, we can expect this population to need treatment such as vestibuloplasty, soft-tissue grafting,

implant placement, implant-related procedures, and CLS. This case series may be beneficial because it is describing a similar procedure (CLS) in a large group of individuals with HIV.

Most studies and clinical experience show that all patients, including healthy individuals, are susceptible to post-treatment complications when undergoing surgical dental care. Comparisons of surgical complications between populations with HIV+ and HIV- status are scarce. Glick⁵ conducted a retrospective study on 331 patients with HIV, with suppressed immune systems (CD4 counts of <200 cells/mm³). These patients underwent 1,810 common invasive dental procedures, including periodontal, restorative, endodontic, prosthodontic, and surgical procedures. These procedures were performed by general dentists and had a low overall complication rate of only 0.9%. When we examined the complication rate after surgical tooth extractions, we found it to be similar for individuals with both HIV+ and HIV- status.⁵ Campo et al. evaluated post-treatment complications in 101 patients with HIV. The overall complication rate in these patients was found to be 2.2% and 4.8% after invasive dental procedures. No relationship was found among complications and virologic, immunologic, or other laboratory values.²¹ In another study, a similar percentage (3.7% versus 2.9%) of postextraction complications is seen in patients with both HIV+ and HIV- status.¹⁶ A prospective study by Dodson²² reported no differences in the complication rates between patients with HIV+ and HIV- status who underwent tooth extraction. Similarly, in our study, there were no complications noted in patients with HIV whose viral loads varied from non-detectable to 40,000 copies/mL. In our patient population, immunosuppression levels ranged from insignificant to severe and did not impact the PO wound healing. The experience of the operator did not appear to have any impact because the majority of the CLS in our series were performed by residents.

A PO complication that has been studied is the occurrence of infection in the surgical area. One of the major reasons why invasive dental procedures are not attempted on individuals with HIV is the presumption that they are more susceptible to infections and complications after such procedures.²³ Occasional reports have suggested that the patients with HIV may present a higher risk for PO infections after maxillofacial trauma surgery compared to individuals with HIV- status. A study⁴¹ showed that in the case of mandibular fractures, preoperative infection rates were statistically significant (26.4% versus 6.5% for HIV+ versus HIV-). Although PO infections were higher in cases with HIV+ than cases with HIV- status, this difference was not statistically significant.

Most of the above cited authors agree that the rate of complications in patients with HIV is similar in all stages of the disease, including those with CD4+ lymphocyte

counts of <200 cells/mm³. One of the cases presented here had a CD4+ count of 126 cells/mm³, but it did not seem to influence the outcome of CLS.

Dental surgical procedures, such as CLS, which involves manipulation of periodontal tissues, is commonly associated with transient bacteremias. It is not standard protocol to administer prophylactic antibiotics to prevent septicemia from bacteremias arising from invasive dental procedures based solely on the patient's HIV status; however, antibiotic prophylaxis is indicated for severely neutropenic patients with absolute neutrophil counts that are <500 cells/mm³. A systematic review by Patton et al.¹⁵ also concluded that HIV status alone is not an indication for the routine use of antibiotic prophylaxis before dental treatment. In the five studies that were reviewed, it was found that PO complications in the patients with HIV were minor, and treatment was done on an outpatient basis. Furthermore, none of the five studies suggested the necessity for special precautions, such as administration of antibiotic prophylaxis based solely on the patient's HIV status. Based on the available evidence, no preoperative antibiotics were prescribed in the cases presented here.

CONCLUSIONS

Currently available treatment for the population with HIV/AIDS and a longer life expectancy has resulted in the need for more comprehensive dental treatment of patients with HIV. These procedures include preprosthetic, orthodontic, and periodontal surgical procedures. The evaluation of the data from the 21 cases presented here showed that there were no complications with regard to delayed healing, prolonged bleeding, or infections after CLS in this population with HIV. Smoking status did not have an impact on the occurrence of the complications, although 25% (six of 21) of the patients were light smokers. We anticipate that this case series will help demonstrate that a commonly performed periodontal surgical procedure, such as CLS, is safe and predictable in the population with HIV.

ACKNOWLEDGMENTS

The authors thank Mr. Eric Jacobs, media specialist, School of Dentistry, University of Detroit Mercy (UDM), Detroit, MI. They also acknowledge Dr. Tanya Saour (former student at UDM), Dr. Melanie Mayberry (Clinic Director of Predoctoral Clinic Care, University Health Center), and Dr. Mary Parise (Program Director, Advanced Education in General Dentistry [AEGD] at UDM). The authors report no conflicts of interest related to this case series.

REFERENCES

- Patton LL. Sensitivity, specificity, and positive predictive value of oral opportunistic infections in adults with HIV/AIDS as markers of immune suppression and viral burden. *Oral Surg Oral Med Oral Pathol Oral Radiol Endod* 2000;90:182-188.
- Nittayananta W, Chanowanna N, Winn T. Mode of HIV transmission associated with risk of oral lesions in HIV-infected subjects in Thailand. *J Oral Pathol Med* 2010;39:195-200.
- Lederman MM. Immune restoration and CD4+ T-cell function with antiretroviral therapies. *AIDS* 2001;15(Suppl. 2):S11-S15.
- Kunzel C, Sadowsky D. Comparing dentists' attitudes and knowledge concerning AIDS: Differences and similarities by locale. *J Am Dent Assoc* 1991;122:55-61.
- Glick M. Guidelines for the evaluation and management of early HIV infection. *J Am Coll Dent* 1994;61:5-11.
- Deas DE, Moritz AJ, McDonnell HT, Powell CA, Mealey BL. Osseous surgery for crown lengthening: a 6-month clinical study. *J Periodontol* 2004;75:1288-1294.
- Palomo F, Kopczyk RA. Rationale and methods for crown lengthening. *J Am Dent Assoc* 1978;96:257-260.
- Palomo F, Peden J. Periodontal considerations of restorative procedures. *J Prosthet Dent* 1976;36:387-394.
- Lundergan W, Hughes WR Jr. Crown lengthening: A surgical flap approach. *Compend Contin Educ Dent* 1996;17:833-6, 838, 840 passim; quiz 844.
- Rosenberg ES, Garber DA, Evian CI. Tooth lengthening procedures. *Comp Contin Educ Gen Dent* 1980;1:161-172.
- Rosenberg ES, Cho SC, Garber DA. Crown lengthening revisited. *Compend Contin Educ Dent* 1999;20:527-532, 534, 536-8 passim; quiz 542.
- Oakley E, Rhyu IC, Karatzas S, Gandini-Santiago L, Nevins M, Caton J. Formation of the biologic width following crown lengthening in nonhuman primates. *Int J Periodontics Restorative Dent* 1999;19:529-541.
- van der Velden U. Regeneration of the interdental soft tissues following denudation procedures. *J Clin Periodontol* 1982;9:455-459.
- Pankhurst CL, Lewis DA, Clark DT. Prophylactic application of an intra-alveolar socket medicament to reduce postextraction complications in HIV-seropositive patients. *Oral Surg Oral Med Oral Pathol* 1994;77:331-334.
- Patton LL, Shugars DA, Bonito AJ. A systematic review of complication risks for HIV-positive patients undergoing invasive dental procedures. *J Am Dent Assoc* 2002;133:195-203.
- Porter SR, Scully C, Luker J. Complications of dental surgery in persons with HIV disease. *Oral Surg Oral Med Oral Pathol* 1993;75:165-167.
- Ingber JS, Rose LF, Coslet JG. The "biologic width" — A concept in periodontics and restorative dentistry. *Alpha Omegan* 1977;70:62-65.
- Nevins M, Skurow HM. The intracrevicular restorative margin, the biologic width, and the maintenance of the gingival margin. *Int J Periodontics Restorative Dent* 1984;4(3):30-49.
- Fugazzotto PA, Parma-Benfenati S. Preprosthetic periodontal considerations. Crown length and biologic width. *Quintessence Int Dent Dig* 1984;15:1247-1256.
- Pontoriero R, Carnevale G. Surgical crown lengthening: A 12-month clinical wound healing study. *J Periodontol* 2001;72:841-848.
- Campo J, Cano J, del Romero J, Hernando V, Rodríguez C, Bascones A. Oral complication risks after invasive and non-invasive dental procedures in HIV-positive patients. *Oral Dis* 2007;13:110-116.

22. Dodson TB. Predictors of postextraction complications in HIV-positive patients. *Oral Surg Oral Med Oral Pathol Oral Radiol Endod* 1997;84:474-479.
23. Dodson TB, Perrott DH, Gongloff RK, Kaban LB. Human immunodeficiency virus serostatus and the risk of postextraction complications. *Int J Oral Maxillofac Surg* 1994;23:100-103.
24. Engeland CG, Jang P, Alves M, Marucha PT, Califano J. HIV infection and tooth loss. *Oral Surg Oral Med Oral Pathol Oral Radiol Endod* 2008;105:321-326.
25. Glick M, Abel SN. Dental implants and human immunodeficiency virus disease. *Implant Dent* 1993;2:149-150.
26. Baron M, Gritsch F, Hansy AM, Haas R. Implants in an HIV-positive patient: A case report. *Int J Oral Maxillofac Implants* 2004;19:425-430.
27. Achong RM, Shetty K, Arribas A, Block MS. Implants in HIV-positive patients: 3 case reports. *J Oral Maxillofac Surg* 2006;64:1199-1203.
28. Kolhatkar S, Khalid S, Rolecki A, Bhola M, Winkler JR. Immediate dental implant placement in HIV-positive patients receiving highly active antiretroviral therapy: A report of two cases and a review of the literature of implants placed in HIV-positive individuals. *J Periodontol* 2011;82:505-511.
29. Shetty K, Achong R. Dental implants in the HIV-positive patient—Case report and review of the literature. *Gen Dent* 2005;53:434-7; quiz 438, 446.
30. Strietzel FP, Rothe S, Reichart PA, Schmidt-Westhausen AM. Implant-prosthetic treatment in HIV-infected patients receiving highly active antiretroviral therapy: Report of cases. *Int J Oral Maxillofac Implants* 2006;21:951-956.
31. Stevenson GC, Riano PC, Moretti AJ, Nichols CM, Engelmeier RL, Flaitz CM. Short-term success of osseointegrated dental implants in HIV-positive individuals: A prospective study. *J Contemp Dent Pract* 2007;8:1-10.
32. Rajnay ZW, Hochstetter RL. Immediate placement of an endosseous root-form implant in an HIV-positive patient: Report of a case. *J Periodontol* 1998;69:1167-1171.
33. Kolhatkar S, Mason S, Winkler JR, Bhola M. Bilateral vestibuloplasty utilizing palatal soft tissue grafts in an HIV-positive patient. *J Calif Dent Assoc* 2009;37:467-470.
34. Kolhatkar S, Haque SA, Winkler JR, Bhola M. Root coverage in an HIV-positive individual: Combined use of a lateral sliding flap and resin-modified glass ionomer for the management of an isolated severe recession defect. *J Periodontol* 2010;81:632-640.
35. World Health Organization. WHO case definitions of HIV for surveillance and revised clinical staging and immunological classification of HIV-related disease in adults and children. 2007. Available online at www.who.int/hiv/pub/guidelines/HIVstaging150307.pdf. Accessed March 30, 2009.
36. Bain CA, Moy PK. The association between the failure of dental implants and cigarette smoking. *Int J Oral Maxillofac Implants* 1993;8:609-615.
37. Bergström J. Periodontitis and smoking: An evidence-based appraisal. *J Evid Based Dent Pract* 2006;6:33-41.
38. Sloan A, Hussain I, Maqsood M, Eremin O, El-Sheemy M. The effects of smoking on fracture healing. *Surgeon* 2010;8:111-116.
39. Bretz WA, Flaitz C, Moretti A, Corby P, Schneider LG, Nichols CM. Medication usage and dental caries outcome-related variables in HIV/AIDS patients. *AIDS Patient Care STDS* 2000;14:549-554.
40. Nittayananta W, Talungchit S, Jaruratanasirikul S, et al. Effects of long-term use of HAART on oral health status of HIV-infected subjects. *J Oral Pathol Med* 2010;39:397-406.
41. Martínez-Gimeno C, Acero-Sanz J, Martín-Sastre R, Navarro-Vila C. Maxillofacial trauma: Influence of HIV infection. *J Craniomaxillofac Surg* 1992;20:297-302.

Correspondence: Dr. Shilpa Kolhatkar, 2700 Martin Luther King Jr. Blvd., Detroit, MI 48208-2576. Fax: 313/494-6666; e-mail: kolhatsh@udmercy.edu.

Submitted May 26, 2011; accepted for publication July 4, 2011.