

## IMMUNOHISTOLOGIC ANALYSIS OF SPONTANEOUS RECURRENT LARYNGEAL NERVE REINNERVATION IN A RAT MODEL

Andrew J Rosko, MD<sup>\*1</sup>; Robbi A. Kupfer, MD<sup>1\*</sup>; Sang S. Oh, DVM<sup>2</sup>, MS; Catherine T. Haring, MD<sup>1</sup>; Eva L. Feldman, MD<sup>2</sup>, PhD; Norman D. Hogikyan, MD<sup>1</sup>

\*Co-first authors

1. Department of Otolaryngology-Head and Neck Surgery, University of Michigan Health Center, Ann Arbor, Michigan, USA
2. Department of Neurology, University of Michigan Medical School, Ann Arbor, Michigan, USA

Financial Support: None

Presentation: American Laryngological Association's 2017 Annual Meeting at COSM in San Diego, California, USA. April 26, 2017

Corresponding Author:

Andrew J. Rosko, M.D.  
University of Michigan Health System  
Department of Otolaryngology-Head and Neck Surgery  
1500 E Medical Center Dr.  
1904 TC, SPC 5312  
Ann Arbor, MI 48109-5312  
734 936-3172 phone  
734 232-1007 fax  
[arosko@med.umich.edu](mailto:arosko@med.umich.edu)

Running Title: SPONTANEOUS RECURRENT LARYNGEAL NERVE REINNERVATION

Keywords: Key Words: Laryngeal reinnervation, recurrent laryngeal nerve, vocal fold

Financial Disclosures: This research was supported by the University of Michigan Program for Neurology Research and Discovery. The authors have no other funding, financial relationships, or conflicts of interest to disclose.

Conflict of Interest: None

This is the author manuscript accepted for publication and has undergone full peer review but has not been through the copyediting, typesetting, pagination and proofreading process, which may lead to differences between this version and the [Version record](#). Please cite this article as [doi:10.1002/lary.27004](https://doi.org/10.1002/lary.27004).

*Objective:* After recurrent laryngeal nerve injury (RLN), spontaneous reinnervation of the larynx occurs with input from multiple sources. The purpose of this study is to determine the timing and efficiency of reinnervation across a resected RLN segment in a rat model of RLN injury.

*Study Design:* Animal study

*Methods:* Twelve male 60-day old Sprague Dawley rats underwent resection of a 5-mm segment of the right RLN. Rats were sacrificed at 1, 2, 4, and 12 weeks after nerve injury to harvest the larynx and trachea for immunohistologic analysis. The distal RLN segment was stained with neurofilament and axons were counted and compared to the non-operated side. Thyroarytenoid (TA) muscles were stained with alpha-bungarotoxin, synaptophysin, and neurofilament to identify intact neuromuscular junctions (NMJ). The number of intact NMJ's from the denervated side was compared to the non-operated side.

*Results:* Nerve fibers regenerated across the resected RLN gap into the distal recurrent laryngeal nerve to innervate the TA muscle. The number of nerve fibers in the distal nerve segment increased over time and reached the normal number by 12 weeks post-denervation. Axons formed intact neuromuscular junctions in the TA with  $48.8 \pm 16.7\%$  of the normal number of intact NMJ's at 4 weeks and  $88.3 \pm 30.1\%$  of the normal number by 12 weeks.

*Conclusion:* Following resection of an RLN segment in a rat model, nerve fibers spontaneously regenerate through the distal segment of the transected nerve and form intact NMJ's in order to reinnervate the TA muscle.

**Key Words:** Laryngeal reinnervation, recurrent laryngeal nerve, vocal fold paralysis

Level of Evidence: NA

**Introduction:**

Laryngeal paralysis secondary to recurrent laryngeal nerve injury remains a significant cause of morbidity by impairing voice, airway, and swallowing function. While laryngeal paralysis was historically primarily related to extralaryngeal malignancies and thyroid surgery, the etiology of laryngeal paralysis has been changing in recent decades with an increase in recurrent laryngeal nerve (RLN) injury during anterior cervical spine surgery, carotid endarterectomy, and thoracic surgery.<sup>1-5</sup> Unfortunately, despite being an area of active research, there is no way to reliably restore physiological movement to the paralyzed vocal fold. The available treatment options for vocal fold paralysis consist of static geometric solutions that provide more favorable glottic closure and reinnervation procedures that provide tone to vocal fold musculature.<sup>6</sup>

Unlike most peripheral nerve injuries, clinical or experimental injury to the RLN does not typically result in progressive atrophy or fibrosis of the laryngeal musculature. This phenomenon can be attributed to a propensity of the larynx to undergo spontaneous reinnervation after RLN injury, which has been demonstrated by multiple authors.<sup>7-12</sup> Unfortunately aberrant reinnervation can lead to synkinesis, rather than physiologic motion.<sup>7</sup> Understanding spontaneous reinnervation and the sources of reinnervation have been the subject of multiple studies.<sup>13-18</sup>

Spontaneous laryngeal reinnervation was studied in previously published work using the current rat model of RLN injury. Multiple experimental conditions were employed to explore and delineate various possible reinnervation sources at 3 months post resection of an RLN segment. It was evident through retrograde brainstem neuronal labeling, EMG, and laryngoscopy that the SLN is a major source of spontaneous reinnervation, and that the RLN contributes as well although the RLN contribution was less and appeared variable.<sup>18</sup> There was also evidence for

central nervous system plasticity. Remarkably, with respect to the RLN specifically in that study, there was histologic evidence of axons in a distal nerve segment across a gap at three months post-injury in 87% of animals. It was unclear however whether the histologic staining of neurofilament in the distal RLN segment truly represented regenerated axons, or whether this was residual from native nerve. It was also unclear whether these axons contributed to functional neuromuscular junctions (NMJ).

We hypothesize that the RLN contributes to spontaneous laryngeal reinnervation by regenerating across a resected gap, and that regeneration of nerve fibers will occur in a time-dependent fashion that correlates with establishment of intact NMJ's. The purpose of this study is to evaluate this hypothesis.

Accepted Article

## Materials and Methods:

### *Animals and Procedures*

The study was performed with the approval of the University of Michigan Committee on Use and Care of Animals. Twelve male Sprague-Dawley rats, age 60 days, underwent RLN resection using procedures previously described in a rat model of chronic RLN injury.<sup>19</sup> Briefly, intraperitoneal ketamine (50 mg/kg) and xylazine (5 mg/kg) with inhaled 1.8% isoflurane were used to induce anesthesia with spontaneous respiration for microlaryngoscopy to document vocal fold mobility. The larynx, trachea, and right RLN were then exposed under an operating microscope through a midline cervical incision and 5 mm of the right RLN at the level of the cervical trachea was resected. The wound was closed and microlaryngoscopy was again performed to confirm right vocal fold paralysis. The rats were then divided into four groups of three rats each and harvested at different time points following RLN denervation. Rats were sacrificed at 1 week, 2 weeks, 4 weeks, and 12 weeks.

### *Harvest and Tissue Processing*

Rats were euthanized, followed by intracardiac perfusion of 4% paraformaldehyde. The larynx and trachea with associated RLNs were harvested and sectioned at 20  $\mu$ m. Immunohistochemistry was then performed. Sections through the trachea and RLNs were processed with anti-neurofilament antibodies (Millipore, Billerica, Massachusetts) to visualize axons within the RLN distal to the resected segment of the nerve. Sections through the resected gap were also examined to confirm that the axons were regenerating across the gap from the proximal nerve segment. A Nikon Microphot FXA microscope was used with a Spot RT slider CCD 3mp camera and a 40x objective providing a total of 400x magnification. Images were acquired using Spot Basic version 4.6.3.10 (*Diagnostic Instruments, Inc.*, Sterling Heights,

Michigan). Images imported into Metamorph version 7.7.1 (Molecular Devices Corp., Sunnyvale, CA) and axons were counted. Four sections were analyzed for each animal. The results from the injured side were compared to the non-operative side which served as an internal control. Results were reported as a ratio of the transected side over the normal non-operative side.

Sections through the thyroarytenoid (TA) muscle were processed with anti-neurofilament antibodies, anti-synaptophysin antibodies (Sigma, St. Louis, Missouri), and  $\alpha$ -bungarotoxin (Invitrogen, Carlsbad, California) to visualize the axons, presynaptic terminals, and acetylcholine receptors, respectively for identification of intact NMJ. A neuromuscular junction was counted if there was triple staining with neurofilament, synaptophysin, and  $\alpha$ -bungarotoxin (**Figure 1**).

Images were captured at 200 x power using an [Olympus Fluoview FV500 scanning laser microscope](#). The results from the injured side were compared to the non-operative side which served as an internal control. Results were reported as a ratio of the transected side over the normal non-operative side. The researchers analyzing the sections were unblinded.

## **Results:**

### *Animal procedures*

All 12 animals underwent the designated procedures, were confirmed to have right vocal fold paralysis following denervation, survived to the chosen endpoint, and were successfully harvested.

### *Axon Regeneration Across Resected Segment*

There was immunohistochemical evidence of axon regeneration into the distal RLN to innervate the TA muscle (**Figure 2**). Neurofilament was present as early as 1 week and the number of

nerve fibers in the distal nerve segment increased over time. At 1 week  $38.2 \pm 8.5\%$  of the intact nerve fibers were histologically present across the cut nerve gap. This increased to  $64.3 \pm 17.9\%$  by 2 weeks,  $88.4 \pm 2.8\%$  at 4 weeks, and normalized to  $109.4 \pm 16.7\%$  by 12 weeks post-denervation (**Figure 3**).

#### *Neuromuscular Junction Analysis from the Thyroarytenoid Muscle*

Immunohistochemical analysis of NMJ's within the TA muscles demonstrated time-dependent increase in the number of intact NMJ's following RLN resection. Early in the time course, very few intact neuromuscular junctions were noted on the injured side compared to the normal non-operated side ( $2.8 \pm 4.9\%$  at week 1 and  $4.9 \pm 3.5\%$  at week 2). By week 4, the number of intact NMJ's increased dramatically to  $48.8 \pm 10.8\%$  and nearly normalized by 12 weeks ( $88.3 \pm 32.8\%$ ) (**Figure 4**). Morphologically, the shape of the neurofilament stained fibers had a more normal appearance as time progressed, and synaptophysin stained pre-synaptic terminal increased with time (**Figure 5**). Interestingly, the number of  $\alpha$ -bungarotoxin-stained motor endplates did not differ between the different time points, but these endplates were not contacted by neurofilament-stained axonal fibers or synaptophysin-stained presynaptic terminals in the earlier time points (**Figure 5B and 5C**).

**Discussion:**

As shown in previous studies, there is spontaneous reinnervation of the larynx after RLN injury.<sup>7-12</sup> The current study supports the conclusion that the RLN itself contributes to spontaneous reinnervation. All 12 animals demonstrated regeneration of axons into the distal RLN segment across the resected gap. Interestingly, when the axons regenerated, they were able to identify the distal nerve stump across the unreconstructed nerve gap to reach the larynx. Axon counts in the distal nerve just beyond the injury demonstrated efficient neural regeneration as axonal density reached near normal numbers by week 4, and had normalized by week 12. The previously published study with this model had demonstrated that 87% of animals had neurofilament staining in the distal nerve segment, but it was unclear whether the staining was of residual native tissue or whether it was in fact staining regenerated axons. Observing the change in axon count over time in the current study answers this question, and is definitive evidence of RLN degeneration and regeneration in the distal nerve segment.

This finding is supported by previous findings. Chen et al. evaluated 29 patients with unilateral vocal fold paralysis after thyroid surgery and explored the recurrent laryngeal nerve. In their study, 5 patients had intact recurrent laryngeal nerves, while 24 had transected nerves. In patients with nerve transection, proliferative connective tissue was seen connecting the proximal and distal ends of the transected nerve. It was postulated that this may indicate spontaneous regeneration of the recurrent laryngeal nerve despite the lack of functional vocal fold movement.<sup>20</sup> Spontaneous axonal regeneration is critical in maintaining tone to the laryngeal musculature after denervation. This has been termed “subclinical reinnervation.”<sup>21</sup> The origin of the axons innervating the larynx is often aberrant, however the current study, along with the findings from Chen et al and our previous work suggest at least some axons originate within the injured recurrent laryngeal nerve.<sup>18,20,21</sup>



The current study also demonstrates the time-dependent formation of intact NMJ's in the TA muscle. By 12 weeks the number of intact NMJ's was almost equal to that of the uninjured side. While the NMJ's were very disorganized at early time points, they had a more normal morphological appearance by 12 weeks. These data alone add useful information to the collective knowledge base regarding the phenomenon of spontaneous laryngeal reinnervation, particularly with respect to possible directed reinnervation paradigms discussed below. In our study, the number of motor endplates did not change with acute denervation. This is in concordance with the understanding of acute muscle denervation. In the early stage of denervation, the muscle creates a microenvironment that is conducive for reinnervation.<sup>22</sup> This includes upregulation of muscle regulation factors, increase in nicotinic acetylcholine receptors and Schwann cell proliferation.<sup>22-27</sup> As in our study the motor end plates remain present, and are often upregulated, in the acute post denervation phase and are a key contributor to successful reinnervation.

The timing of intact NMJ formation had a logical temporal relationship to axonal regrowth in the distal RLN, which further supports the conclusion that the regenerated RLN is contributing to the functional regenerated NMJ's. This answers a second important question remaining after the previously published study regarding the functional significance of regenerated RLN axons. We do acknowledge that the current experimental paradigm does not allow for delineation of what percentage of the functional NMJ's are innervated by RLN versus SLN or other neural sources, but the temporal relationship described above supports an RLN contribution. Consideration was given to resecting the SLN on the experimental side in the current study in order to eliminate this neural regeneration source, but it was felt that this would significantly alter the denervation/reinnervation milieu and would make the study non-representative of the common clinical situation of isolated RLN injury.

While this study confirms and further characterizes a source of laryngeal reinnervation, the fundamental issue remains that spontaneous reinnervation is not physiologic and often leads to synkinesis. As such, there is much interest in both improving regenerative efficiency and in guiding axonal growth to prevent synkinesis. The concept of correct nerves reaching correct muscles is the most important goal in laryngeal reinnervation research.

Efforts to improve neural regeneration in general after a recognized nerve injury include primary coaptation, autologous nerve grafting, nerve conduits using an extracellular matrix, bone marrow derived cells to improve vascularity, supportive cells, gene therapy with growth factors, and even 3D printed scaffolds.<sup>28-34</sup> While some of these techniques hold promise in terms of promoting axonal growth, they do not address the problem of synkinesis. Selectively promoting desired reinnervation sources and targets and/or preventing undesired ones using growth factors or neurotoxins is an important current arena of investigation, and elegant work is being done in the laboratories of Halum, Paniello, Pitman and others.<sup>35-37</sup> A thorough characterization of spontaneous reinnervation sources and mechanisms is a necessary prerequisite to achieving the goals of physiologic reinnervation and improved outcomes for patients with laryngeal paralysis.

### **Conclusion:**

This study demonstrates that axons are able to spontaneously regenerate across a 5-mm gap in a rat model of RLN injury. These axons reach the larynx and contribute to intact neuromuscular junctions. The numbers of regenerated axons and neuromuscular junctions increase in a time-dependent manner and nearly normalize by 12 weeks post-injury.

Accepted Article

**References:**

1. Rosenthal LH, Benninger MS, Deeb RH. Vocal fold immobility: a longitudinal analysis of etiology over 20 years. *The Laryngoscope*. 2007;117(10):1864-1870.
2. Benninger MS, Gillen JB, Altman JS. Changing etiology of vocal fold immobility. *The Laryngoscope*. 1998;108(9):1346-1350.
3. Merati AL, Shemirani N, Smith TL, Toohill RJ. Changing trends in the nature of vocal fold motion impairment. *Am J Otolaryngol*. 2006;27(2):106-108.
4. Feehery JM, Pribitkin EA, Heffelfinger RN, et al. The evolving etiology of bilateral vocal fold immobility. *J Voice*. 2003;17(1):76-81.
5. Prasad VM, Fakhoury R, Helou D, Lawson G, Remacle M. Unilateral vocal fold immobility: a tertiary hospital's experience over 5 years. *European archives of oto-rhino-laryngology : official journal of the European Federation of Oto-Rhino-Laryngological Societies*. 2017.
6. Erman AB, Kejner AE, Hogikyan ND, Feldman EL. Disorders of cranial nerves IX and X. *Semin Neurol*. 2009;29(1):85-92.
7. Crumley RL. Laryngeal synkinesis revisited. *The Annals of otology, rhinology, and laryngology*. 2000;109(4):365-371.
8. Sahgal V, Hast MH. Effect of denervation on primate laryngeal muscles: a morphologic and morphometric study. *J Laryngol Otol*. 1986;100(5):553-560.
9. Blitzer A, Jahn AF, Keidar A. Semon's law revisited: an electromyographic analysis of laryngeal synkinesis. *Ann Otol Rhinol Laryngol*. 1996;105(10):764-769.
10. Iroto I, Hirano M, Tomita H. Electromyographic investigation of human vocal cord paralysis. *The Annals of otology, rhinology, and laryngology*. 1968;77(2):296-304.
11. Hogikyan ND, Johns MM, Kileny PR, Urbanek M, Carroll WR, Kuzon WM, Jr. Motion-specific laryngeal reinnervation using muscle-nerve-muscle neurotization. *The Annals of otology, rhinology, and laryngology*. 2001;110(9):801-810.
12. Johns MM, Urbanek M, Chepeha DB, Kuzon WM, Jr., Hogikyan ND. Thyroarytenoid muscle maintains normal contractile force in chronic vocal fold immobility. *The Laryngoscope*. 2001;111(12):2152-2156.
13. Flint PW, Downs DH, Coltrera MD. Laryngeal synkinesis following reinnervation in the rat. Neuroanatomic and physiologic study using retrograde fluorescent tracers and electromyography. *The Annals of otology, rhinology, and laryngology*. 1991;100(10):797-806.
14. Crumley RL, McCabe BF. Regeneration of the recurrent laryngeal nerve. *Otolaryngology-head and neck surgery : official journal of American Academy of Otolaryngology-Head and Neck Surgery*. 1982;90(4):442-447.
15. Nomoto M, Yoshihara T, Kanda T, Kaneko T. Synapse formation by autonomic nerves in the previously denervated neuromuscular junctions of the feline intrinsic laryngeal muscles. *Brain Res*. 1991;539(2):276-286.
16. Nomoto M, Yoshihara T, Kanda T, Konno A, Kaneko T. Misdirected reinnervation in the feline intrinsic laryngeal muscles after long-term denervation. *Acta Otolaryngol Suppl*. 1993;506:71-74.

7. Hydman J, Mattsson P. Collateral reinnervation by the superior laryngeal nerve after recurrent laryngeal nerve injury. *Muscle & nerve*. 2008;38(4):1280-1289.
8. Kupfer RA, Old MO, Oh SS, Feldman EL, Hogikyan ND. Spontaneous laryngeal reinnervation following chronic recurrent laryngeal nerve injury. *Laryngoscope*. 2013;123(9):2216-2227.
9. Old MO, Oh SS, Feldman E, Hogikyan ND. Novel model to assess laryngeal function, innervation, and reinnervation. *Ann Otol Rhinol Laryngol*. 2011;120(5):331-338.
0. Chen D, Chen S, Wang W, Zhang C, Zheng H. Spontaneous regeneration of recurrent laryngeal nerve following long-term vocal fold paralysis in humans: histologic evidence. *Laryngoscope*. 2011;121(5):1035-1039.
1. Crumley RL. Experiments in laryngeal reinnervation. *Laryngoscope*. 1982;92(9 Pt 2 Suppl 30):1-27.
2. Ma J, Shen J, Lee CA, et al. Gene expression of nAChR, SNAP-25 and GAP-43 in skeletal muscles following botulinum toxin A injection: a study in rats. *J Orthop Res*. 2005;23(2):302-309.
3. Kobayashi J, Mackinnon SE, Watanabe O, et al. The effect of duration of muscle denervation on functional recovery in the rat model. *Muscle Nerve*. 1997;20(7):858-866.
4. Lapalombella R, Kern H, Adami N, et al. Persistence of regenerative myogenesis in spite of down-regulation of activity-dependent genes in long-term denervated rat muscle. *Neurol Res*. 2008;30(2):197-206.
5. Weis J, Kaussen M, Calvo S, Buonanno A. Denervation induces a rapid nuclear accumulation of MRF4 in mature myofibers. *Dev Dyn*. 2000;218(3):438-451.
6. Zhao C, Veltri K, Li S, Bain JR, Fahnstock M. NGF, BDNF, NT-3, and GDNF mRNA expression in rat skeletal muscle following denervation and sensory protection. *J Neurotrauma*. 2004;21(10):1468-1478.
7. Wu P, Chawla A, Spinner RJ, et al. Key changes in denervated muscles and their impact on regeneration and reinnervation. *Neural Regen Res*. 2014;9(20):1796-1809.
8. Lundborg G. A 25-year perspective of peripheral nerve surgery: evolving neuroscientific concepts and clinical significance. *J Hand Surg Am*. 2000;25(3):391-414.
9. Millesi H. Techniques for nerve grafting. *Hand Clin*. 2000;16(1):73-91, viii.
0. Wang Y, Li ZW, Luo M, Li YJ, Zhang KQ. Biological conduits combining bone marrow mesenchymal stem cells and extracellular matrix to treat long-segment sciatic nerve defects. *Neural Regen Res*. 2015;10(6):965-971.
1. de Luca AC, Lacour SP, Raffoul W, di Summa PG. Extracellular matrix components in peripheral nerve repair: how to affect neural cellular response and nerve regeneration? *Neural Regen Res*. 2014;9(22):1943-1948.
2. Yamakawa T, Kakinoki R, Ikeguchi R, Nakayama K, Morimoto Y, Nakamura T. Nerve regeneration promoted in a tube with vascularity containing bone marrow-derived cells. *Cell Transplant*. 2007;16(8):811-822.
3. Wang D, Liu XL, Zhu JK, et al. Bridging small-gap peripheral nerve defects using acellular nerve allograft implanted with autologous bone marrow stromal cells in primates. *Brain Res*. 2008;1188:44-53.

4. Yurie H, Ikeguchi R, Aoyama T, et al. The efficacy of a scaffold-free Bio 3D conduit developed from human fibroblasts on peripheral nerve regeneration in a rat sciatic nerve model. *PloS one*. 2017;12(2):e0171448.
5. McRae BR, Kincaid JC, Illing EA, Hiatt KK, Hawkins JF, Halum SL. Local neurotoxins for prevention of laryngeal synkinesis after recurrent laryngeal nerve injury. *The Annals of otology, rhinology, and laryngology*. 2009;118(12):887-893.
6. Paniello RC. Vocal fold paralysis: improved adductor recovery by vincristine blockade of posterior cricoarytenoid. *The Laryngoscope*. 2015;125(3):655-660.
7. Hernandez-Morato I, Tewari I, Sharma S, Pitman MJ. Blockade of glial-derived neurotrophic factor in laryngeal muscles promotes appropriate reinnervation. *The Laryngoscope*. 2016;126(10):E337-342.

Accepted Article

**Figure 1.** Immunohistochemical analysis of intact neuromuscular junctions. Neurofilament (red) demonstrates nerve fibers, synaptophysin (green) demonstrates presynaptic terminals, and  $\alpha$ -bungarotoxin (blue) demonstrates motor end plates. The three images are merged to assess contact.

Accepted Article

**Figure 2.** Immunohistologic analysis with neurofilament stain of the recurrent laryngeal nerve (RLN) across a resected segment. Intact RLN (A), Neurofilament within RLN location one week following resection (B), two weeks following resection (C) four weeks following resection (D), and 12 weeks following resection (E).

Accepted Article



**Figure 3.** Axonal counts from the resected section of the recurrent laryngeal nerve over time following nerve injury. Axon counts are shown as a ratio of the injured to uninjured side. Error bars represent standard deviation.

Accepted Article

**Figure 4.** The number of intact neuromuscular junctions present in the thyroarytenoid muscle were compared over time following recurrent laryngeal nerve injury. The number of intact neuromuscular junctions are shown as a ratio of the injured to uninjured side. Error bars represent standard deviation.

Accepted Article

**Figure 5.** Immunohistologic analysis of neuromuscular junctions (NMJ) within the thyroarytenoid (TA) muscle. Images are merged to show nerve fibers (red neurofilament stain), presynaptic terminals (green synaptophysin stain), and motor end plates (blue  $\alpha$ -bungarotoxin stain). TA muscle with intact NMJ (A). TA muscle one week following nerve injury (B) and two weeks following nerve injury (C), showing normal number of motor end plates but no intact NMJ. TA muscle 4 weeks following nerve injury (D). TA muscle 12 weeks following nerve injury, showing intact NMJ with altered nerve fiber morphology (E).

Accepted Article

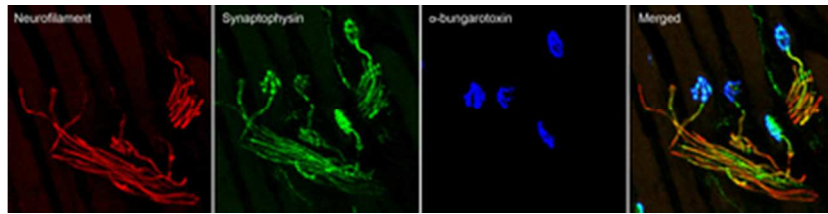


Figure 1. Immunohistochemical analysis of intact neuromuscular junctions. Neurofilament (red) demonstrates nerve fibers, synaptophysin (green) demonstrates presynaptic terminals, and  $\alpha$ -bungarotoxin (blue) demonstrates motor end plates. The three images are merged to assess contact.

34x8mm (300 x 300 DPI)

Accepted Article

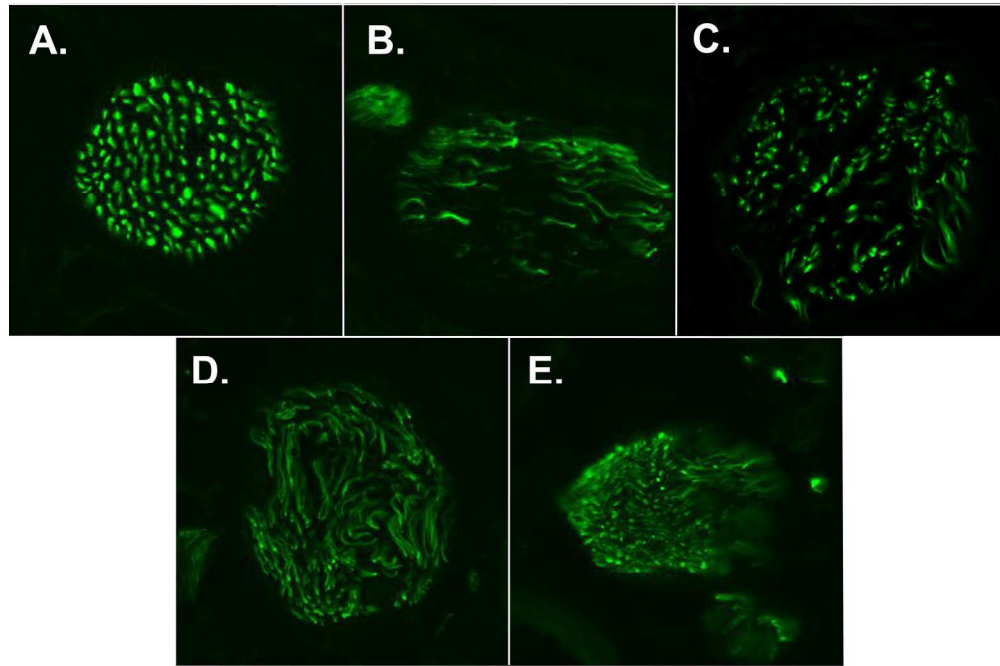


Figure 2. Immunohistologic analysis with neurofilament stain of the recurrent laryngeal nerve (RLN) across a resected segment. Intact RLN (A), Neurofilament within RLN location one week following resection (B), two weeks following resection (C) four weeks following resection (D), and 12 weeks following resection (E).

177x118mm (300 x 300 DPI)

Accepted

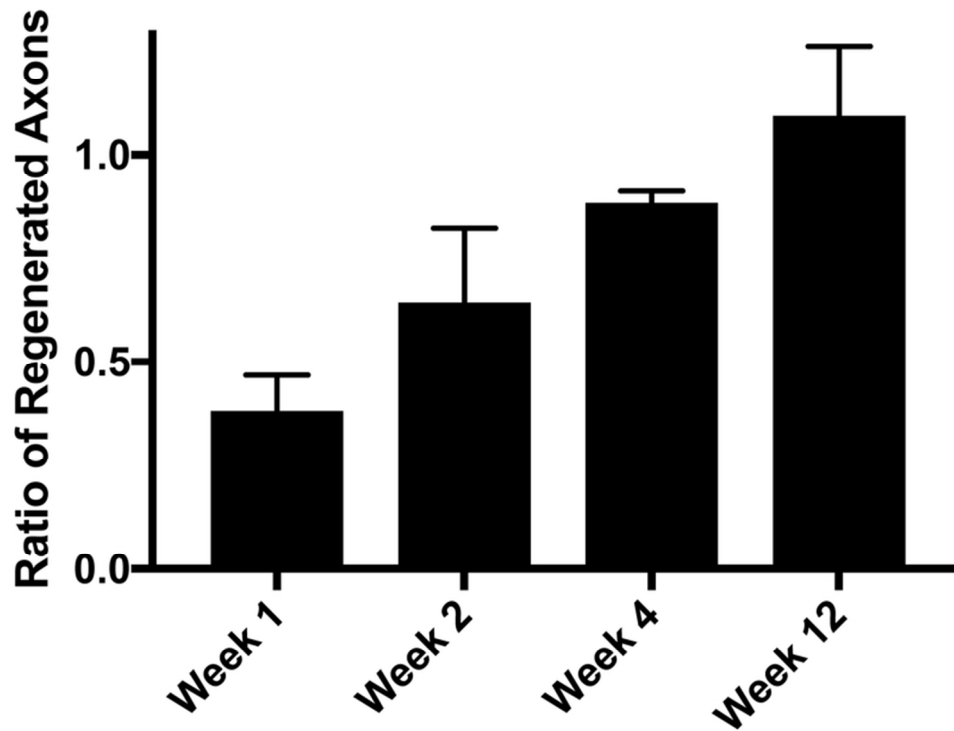


Figure 3. Axonal counts from the resected section of the recurrent laryngeal nerve over time following nerve injury. Axon counts are shown as a ratio of the injured to uninjured side. Error bars represent standard deviation.

71x54mm (300 x 300 DPI)

AcceJ

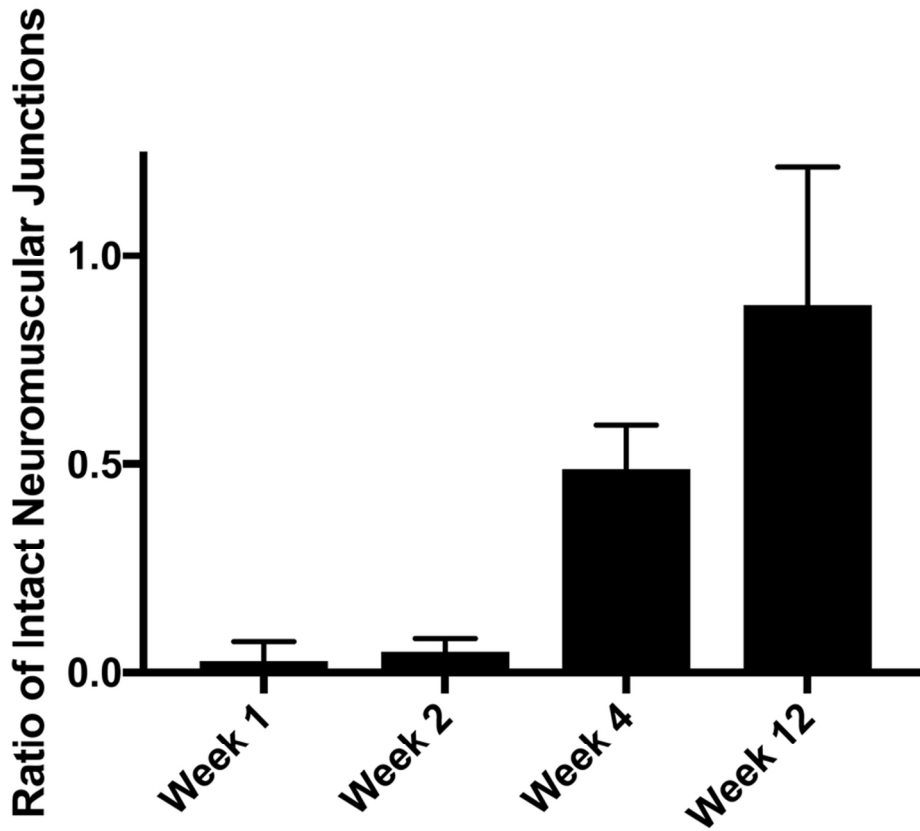


Figure 4. The number of intact neuromuscular junctions present in the thyroarytenoid muscle were compared over time following recurrent laryngeal nerve injury. The number of intact neuromuscular junctions are shown as a ratio of the injured to uninjured side. Error bars represent standard deviation.

85x74mm (300 x 300 DPI)

ACC

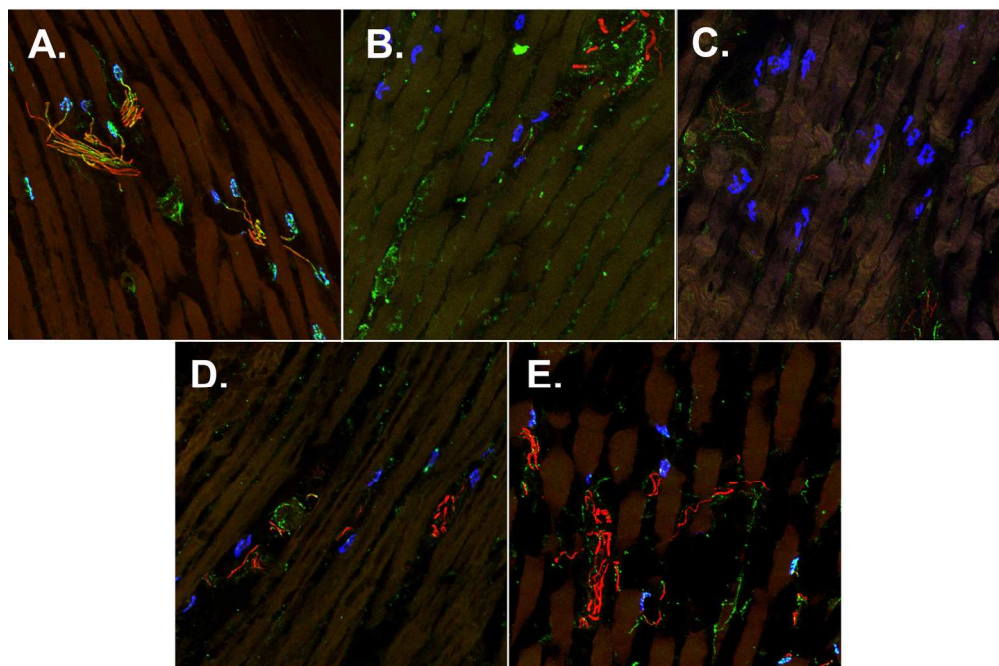


Figure 5. Immunohistologic analysis of neuromuscular junctions (NMJ) within the thyroarytenoid (TA) muscle. Images are merged to show nerve fibers (red neurofilament stain), presynaptic terminals (green synaptophysin stain), and motor end plates (blue  $\alpha$ -bungarotoxin stain). TA muscle with intact NMJ (A). TA muscle one week following nerve injury (B) and two weeks following nerve injury (C), showing normal number of motor end plates but no intact NMJ. TA muscle 4 weeks following nerve injury (D). TA muscle 12 weeks following nerve injury, showing intact NMJ with altered nerve fiber morphology (E).

177x118mm (300 x 300 DPI)

Accel