

Hamada Ryusho (Orcid ID: 0000-0002-4035-823X)

Recurrent branch of anterior interosseous artery perforator-based propeller flap for distal forearm injuries: Report of two cases

Ryusho Hamada, MD^{1,2}; Akira Shinaoka, MD, PhD^{2,3}; Narushi Sugiyama, MD, PhD²; Toshiyuki Watanabe, MD²; , MD^{1,2}; Yoshihiro Kimata, MD, PhD²

¹ Department of Plastic Surgery, Kagawa Prefectural Central Hospital, Kagawa 760-8557, Japan

² Department of Plastic and Reconstructive Surgery, Okayama University Graduate School of Medicine, Dentistry, and Pharmaceutical Science, Okayama 700-8558, Japan

³ Department of Human Morphology, Okayama University Graduate School of Medicine, Dentistry, and Pharmaceutical Science, Okayama 700-8558, Japan

Correspondence: Ryusho Hamada, MD, Department of Plastic Surgery, Kagawa Prefectural Central Hospital, 1-2-1 Asahi-cho, Takamatsu-shi, Kagawa 760-8557, Japan

Email: patapatagonia.r3@gmail.com

No grant information

This is the author manuscript accepted for publication and has undergone full peer review but has not been through the copyediting, typesetting, pagination and proofreading process, which may lead to differences between this version and the Version of Record. Please cite this article as doi: [10.1002/micr.30388](https://doi.org/10.1002/micr.30388)

Running title: Recurrent branch of anterior interosseous artery perforator-based flap

Abstract

Despite various options for the reconstruction of soft tissue defects in the distal forearm, perforator-based propeller flap is rarely used. Here, we presented two cases of distal forearm injuries that were repaired using the recurrent branch of anterior interosseous artery perforator-based propeller flap. Patients in these cases were 57 and 67 years of age. Wounds resulting from farming machine injury and pyogenic extensor tenosynovitis following cat bite wounds were localized to the distal forearm and dorsum of the hand. Defect dimensions were 5×10 cm and 5×8 cm. The 12×7 cm- and 21×4 cm- sized recurrent branch of anterior interosseous artery perforator-based propeller flap was designed adjacent to the wounds. In the latter case, the absence of the posterior interosseous artery in the distal forearm was observed. One perforator from the recurrent branch of the anterior interosseous artery emerged through the septum between the extensor digiti minimi and extensor carpi ulnaris 7.5 cm and 6.0 cm proximal to the ulnar head in cases 1 and 2, respectively. Perforators were identified using multidetector computed tomographic angiography and handheld Doppler. Extending to two

thirds or almost the full length of the forearm, the flaps were raised and rotated by 90° and 120° to cover the defect. The donor sites were closed using free skin graft. Both flaps survived. Except for minor wound dehiscence and hemarthrosis, no other postoperative complications occurred. Patients returned to work or daily activities at 3- and 4-month follow-up after surgery.

Introduction

The reconstruction of traumatic soft tissue defects in the distal forearm remains challenging for reconstructive surgeons. The primary restoration of well-vascularized tissue around the exposed vital structures such as the bone, tendons, nerves, and vessels is required to prevent infection and tendon adhesion in the distal forearm.¹ The type of flap considered the most efficacious in the management of soft tissue defects in the distal forearm remains controversial. The reverse flap is popular for distal forearm reconstruction.²⁻⁴ However, reverse flaps with retrograde radial or ulnar artery pedicle have a disadvantage in that the major vessels of the forearm have to be sacrificed, which could result in postoperative digital ischemia or cold intolerance.⁵ The reverse posterior interosseous artery flap can be applied in cases with ulnar or radial artery disruption to cover skin defects over the distal forearm without sacrificing the major vessels. However, it

requires the retrograde dissection of the vascular pedicle through the fascial septum, and there is the potential for posterior interosseous nerve injury when raising the flap⁶ and postoperative venous congestion.^{7,8} Moreover, retrospective clinical studies on the posterior interosseous artery flap reported that the posterior interosseous artery was absent or unusable in some cases.⁹⁻¹¹ Perforator-based propeller flaps can provide adequate soft tissue coverage for the distal forearm with antegrade venous drainage without sacrificing the major vessels.¹² Recently, there have been several reports focusing on the anterior interosseous artery perforator-based flap; however, reports describing perforator-based propeller flap in the distal forearm are rare.¹³⁻¹⁷ Here, we presented two cases of distal forearm defects following a farming machine injury and pyogenic extensor tenosynovitis that were repaired using the recurrent branch of anterior interosseous artery perforator-based propeller flap.

Case reports

Case 1

A 57-year-old male farm worker presented to our clinic after a farming machine injury to his right distal forearm (Fig. 1A). The complex injury comprised distal radius fracture, disruption of

the radial flexor, near complete disruption of the extensor tendons, segmental loss of the radial artery and superficial branch of the radial nerve, and a soft tissue defect measuring 5×10 cm on both the dorsal and radial aspects at the distal forearm level (Fig. 1B). The wounds were first treated with meticulous debridement, tendon repair, and vacuum-assisted closure therapy by orthopedic surgeons. Open reduction with internal plate fixation for the radius fracture was performed at 4 days after initial debridement (Fig. 1C); moreover, the recurrent branch of anterior interosseous artery perforator-based propeller flap was raised to cover the soft tissue defect. A dominant perforator from the recurrent branch of the anterior interosseous artery 7.5 cm proximal to the ulnar head was detected preoperatively using computed tomographic (CT) angiography and handheld Doppler. The recurrent branch of anterior interosseous artery perforator-based propeller flap was designed adjacent to the wound (Fig. 1D). The proximal side of the flap was first raised under the deep fascia up to the muscle tendon junction and above the paratenon distally. A healthy septocutaneous perforator emerged through the septum between the extensor digiti minimi and extensor carpi ulnaris (Fig. 1E). After fully elevating the flap (Fig. 2), it was rotated by 90° clockwise to cover the defect (Fig. 1F). The size of the flap was 12×7 cm. The donor site was closed using a free skin graft. The flap developed minor wound

dehiscence at its distal tip and required resuturing; nevertheless, the wound healed with no other major complications such as venous congestion or infection. The patient was referred to the rehabilitation department at 17 days post-injury and returned to daily activities and work at 3-month follow-up (Fig. 1G).

Case 2

A 67-year-old healthy female presented with infected cat bite wounds on the right distal forearm at 10 days post-injury (Fig. 3A). Pyogenic extensor tenosynovitis progressed from the middle third of the forearm to the third metacarpophalangeal (MCP) joint, and almost the entire extensor tendons had ruptured or degenerated at the wrist level (Fig. 3B). The patient was treated with serial debridement and vacuum-assisted closure therapy by orthopedic surgeons. There was a soft tissue defect measuring 5×8 cm in the dorsal hand with exposure of the third MCP joint and ruptured extensor tendons after multiple debridements (Fig. 3C). In this case, the use of reverse posterior interosseous artery flap was initially planned; however, the flap was not usable owing to the absence of the posterior interosseous artery in the distal forearm, which might be due to anatomic variation or previous surgical intervention. We changed the procedure

intraoperatively and adopted a sequential surgical approach based on the recurrent branch of anterior interosseous artery perforator. A dominant perforator from the recurrent branch of the anterior interosseous artery 6.0 cm proximal to the ulnar head was detected preoperatively using CT angiography and handheld Doppler (Fig. 4). The recurrent branch of anterior interosseous artery perforator-based propeller flap was designed adjacent to the previous incision (Fig. 3D). A healthy septocutaneous perforator emerged through the septum between the extensor digiti minimi and extensor carpi ulnaris (Fig. 3E). The flap was raised in the same manner as in the previous case and was rotated by 120° clockwise to cover the defect (Fig. 3F). The size of the flap was 21 × 4 cm. The donor site was closed using a free skin graft. Postoperative rehabilitation was started at 7 days after reconstruction. After the start of rehabilitation, the patient experienced hemarthrosis in the third MCP joint, which rapidly healed without infection after evacuation via a small incision. There were no other complications, and the flap completely survived. The patient was referred to the rehabilitation department at 1 month postoperatively and returned to daily activities at 4-month follow-up (Fig. 3G).

Discussion

In this paper, we presented our experience with two cases treated with the recurrent branch of anterior interosseous artery perforator-based propeller flap. Numerous similar perforator-based flaps in the distal forearm have been well described in the published literature. The anterior interosseous artery perforator-based flap is a well-known flap for distal forearm reconstruction.¹³⁻¹⁷ However, to the best of our knowledge, there has been no report describing the recurrent branch of anterior interosseous artery perforator-based propeller flap for distal forearm defects. In the case of reverse posterior interosseous artery flaps, additional procedures with wide distal flap base including perforating branches from the anterior or posterior interosseous artery have been reported to enhance the reliability of vascular supply.^{11,18} In our cases, the flaps based on only one perforator extended to two thirds or almost the full length of the forearm from the recurrent branch of the anterior interosseous artery without including other perforators from the posterior interosseous artery, and it survived completely. Although there is no definitive information about the survival area of this flap, the anatomical relationship between the recurrent branch of the anterior interosseous artery and the posterior interosseous artery has been well described in previous reports in the literature.¹⁹⁻²¹ In an extensive cadaveric study, Humber et al. performed anatomic and embryologic analysis of the anastomosis between

the anterior and posterior interosseous arteries and, based on the diameter of the posterior interosseous artery, concluded that the vascular arcade formed by the dorsal branch of the anterior interosseous artery anastomoses with the posterior interosseous artery via choke vessels in the middle forearm. Furthermore, they proposed the term “recurrent branch of the anterior interosseous artery” to describe the distal portion of the posterior interosseous artery.¹⁹ Sun et al. performed a statistical analysis of the perforator location of the posterior interosseous vascular system. They reported that two main clusters of perforators from the posterior interosseous vascular system were located at a distance of 6 ± 2 cm proximal to the head of the ulna and 10 ± 1 cm distal to the lateral epicondyle of the humerus along the axis of the ulnar head-to-lateral epicondyle.²⁰ These reports indicate that the cluster of perforators proximal to the head of the ulna is derived from the anterior interosseous vascular system, whereas the cluster of perforators distal to the lateral epicondyle of the humerus is derived from the posterior interosseous vascular system. Consequently, they connect to each other via choke anastomosis in the middle forearm. Therefore, the recurrent branch of anterior interosseous artery perforator-based flap, including additional adjacent perforator vascular territories of the posterior interosseous artery, may be harvested at a large size to provide sufficient coverage for the distal forearm in

accordance with the perforasome theory.^{22,23} Angrigiani et al. performed ink injections in fresh cadaver forearms through a catheter placed in the distal portion of the anterior interosseous artery. In their study, the distal and middle thirds of the dorsal forearm were stained, but the proximal third remained unstained despite the larger amounts of ink injected. Further, they observed that tissue loss occurred in the reverse posterior interosseous artery flap when raised in the proximal third of the forearm despite the incorporation of the large proximal cutaneous branch of the posterior interosseous artery in the pedicle.²¹ According to their studies, harvesting the recurrent branch of anterior interosseous artery perforator-based propeller flap extending to two thirds of the dorsal forearm may be safe; however, reaching a defect extending beyond the MCP joint seems difficult. The rotation arc of the skin paddle is limited by the location of the perforators. Therefore, preoperative assessment of vascular information by handheld Doppler or CT angiography is required. Although the location of the perforators can be predicted using preoperative handheld Doppler or CT angiography, the surviving area of the recurrent branch of anterior interosseous artery perforator-based flap remains uncertain. We encountered only two cases, and further study is required to clarify the vascular territory of this flap.

Although the reverse posterior interosseous artery flap is a “workhorse” for distal forearm reconstruction, it has disadvantages in that impossible cases of flap exist in minority of patients with anatomical blood vessel variation.⁹⁻¹¹ Therefore, it is important to consider an alternative procedure when planning for the reverse posterior interosseous artery flap. However, there are few salvage procedures for the impossible case of reverse posterior interosseous artery flap. Giunta et al. and Pauchot et al. described a case with absent pedicle of the posterior interosseous artery flap and the salvage procedure in this situation.^{11,24} However, their solutions require complex procedures such as conversion to a free flap or anterior interosseous artery flap with dissection of the interosseous membrane. As described above, a situation in which there are no standardized salvage techniques for the impossible case of reverse posterior interosseous artery flap is challenging. In our experience with one case, the procedure could be changed from the reverse posterior interosseous artery flap to the recurrent branch of anterior interosseous artery perforator-based propeller flap via an existing incision. The recurrent branch of anterior interosseous artery perforator-based propeller flap has duplicative vascular territory of the posterior interosseous artery flap. Therefore, it can archive only additional incision continuing the previous incision and superficial dissection around the pedicle perforator. In our case, the

recurrent branch of anterior interosseous artery perforator-based propeller flap could serve as a substitute for the reverse posterior interosseous artery flap, hence providing a simple local solution.

The anterior interosseous vascular system passes between the ulna and radius adjacent to the interosseous membrane, which may reduce the probability of damage to the vascular pedicle of the recurrent branch of anterior interosseous artery perforator-based flap. The vascular supply of the recurrent branch of anterior interosseous artery perforator-based propeller flap seems stable owing to the provision of double arterial blood supply from the anterior and posterior interosseous arteries with antegrade venous drainage. Further, a compensatory increase in anterior and posterior interosseous artery perfusion was noted after radial artery excision,²⁵ which may be beneficial to patients with ulnar or radial artery injury. However, if there is suspected disruption of the anterior interosseous artery, impairment of flap circulation could be possible, and other procedures should be considered.

Donor site morbidity and cosmetic consideration are also important when planning distal forearm reconstruction. Neuwirth et al. evaluated the donor site morbidity of posterior interosseous artery flaps and reported high satisfaction with the aesthetic appearance of donor

sites; however, there was a difference between directly closed and grafted donor sites, with acceptance and satisfaction being lower for grafted donor sites.²⁶ The recurrent branch of anterior interosseous artery perforator-based propeller flap leaves a visible scar at the donor site, and it may require free skin graft, which may be unacceptable, especially in young female patients.

We described two cases of the recurrent branch of anterior interosseous artery perforator-based propeller flap. In one case, the reverse posterior interosseous artery flap could be converted to the recurrent branch of anterior interosseous artery perforator-based propeller flap. We believe that it is a reasonable option for coverage of the distal forearm, especially in impossible cases of reverse posterior interosseous artery flap.

References

1. Shaw DT, Payne RL Jr. One stage tubed abdominal flaps; single pedicle tubes. *Surg Gynecol Obstet* 1946;83:205-9.
2. Biemer E, Stock W. Total thumb reconstruction: a one-stage reconstruction using an osteo-cutaneous forearm flap. *Br J Plast Surg* 1983;36:52-5.

3. Li ZT, Liu K, Cao YD. The reverse flow ulnar artery island flap: 42 clinical cases. *Br J Plast Surg* 1989;42:256-9.
4. Zancolli EA, Angrigiani C. Colgajo dorsal de antebrazo (en isla). *Rev Asoc Argent Ortop Traumatol* 1986;51:161-68.
5. Jones BM, O'Brien CJ. Acute ischaemia of the hand resulting from elevation of a radial forearm flap. *Br J Plast Surg* 1985;38:396-7.
6. Buchler U, Frey HP. Retrograde posterior interosseous flap. *J Hand Surg Am* 1991;16:283-92.
7. Özalp B, Elbey H, Aydin A, Özkan T. Distally based subcutaneous veins for venous insufficiency of the reverse posterior interosseous artery flap. *Microsurgery* 2016;36:384-90.
8. Akinci M, Ay S, Kamiloglu S, Erçetin O. The reverse posterior interosseous flap: a solution for flap necrosis based on a review of 87 cases. *J Plast Reconstr Aesthet Surg* 2006;59:148-52.
9. Cavadas PC. Posterior interosseous flap based on a septal perforator, in the absence of the distal artery. *Plast Reconstr Surg* 1999;104:592.
10. Dadalt Filho LG, Ulson HJ, Penteado CV. Absence of the anastomosis between the anterior and posterior interosseous arteries in a posterior interosseous flap: a case report. *J Hand Surg Am* 1994;19:22-5.

11. Giunta R, Lukas B. Impossible harvest of the posterior interosseous artery flap: a report of an individualised salvage procedure. *Br J Plast Surg* 1998;51:642-5.
12. Hyakusoku H, Yamamoto T, Fumiiri M. The propeller flap method. *Br J Plast Surg* 1991;44:53-4.
13. Akin S. V-Y advancement island flap based on the perforator of the anterior interosseous artery. *Ann Plast Surg* 2003;51:51-6.
14. Panse NS, Joshi SB, Sahasrabudhe PB, et al. The anterior interosseus artery perforator flap: anatomical dissections and clinical study. *World J Plast Surg* 2017;6:152-58.
15. Yii NW, Niranjana NS. Fascial flaps based on perforators for reconstruction of defects in the distal forearm. *Br J Plast Surg* 1999;52:534-40.
16. Syed SA, Zahir KS, Zink JR, et al. Distal dorsal forearm flap. *Ann Plast Surg* 1997;38:396-403.
17. Panse N, Sahasrabudhe P. Free style perforator based propeller flaps: simple solutions for upper extremity reconstruction! *Indian J Plast Surg* 2014;47:77-84.
18. Chen HC, Cheng MH, Schneeberger AG, et al. Posterior interosseous flap and its variations for coverage of hand wounds. *J Trauma* 1998; 45: 570-4.

19. Hubmer MG, Fasching T, Haas F, et al. The posterior interosseous artery in the distal part of the forearm. Is the term “recurrent branch of the anterior interosseous artery” justified? *Br J Plast Surg* 2004;57:638-44.
20. Sun C, Wang YL, Ding ZH, et al. Anatomical basis of a proximal fasciocutaneous extension of the distal-based posterior interosseous flap that allows exclusion of the proximal posterior interosseous artery. *J Plast Reconstr Aesthet Surg* 2015;68:17-25.
21. Angrigiani C, Grilli D, Dominikow D, Zancolli EA. Posterior interosseous reverse forearm flap: experience with 80 consecutive cases. *Plast Reconstr Surg* 1993;92:285-93.
22. Taylor GI, Corlett RJ, Ashton MW. The functional angiosome: clinical implications of the anatomical concept. *Plast Reconstr Surg* 2017;140:721-33.
23. Taylor GI, Chubb DP, Ashton MW. True and ‘choke’ anastomoses between perforator angiosomes: part i. anatomical location. *Plast Reconstr Surg* 2013;132:1447-56.
24. Pauchot J, Lepage D, Leclerc G, et al. Posterior interosseous free flap because of absence of posterior interosseous pedicle. A report of an individualised salvage procedure and of an exceptional anatomical variation. Review of the literature. *Ann Chir Plast Esthet* 2010;55:56-60.

25. Ciria-Lloréns G, Gómez-Cía T, Talegón-Meléndez A. Analysis of flow changes in forearm arteries after raising the radial forearm flap: a prospective study using colour duplex imaging. *Br J Plast Surg* 1999;52:440-4.
26. Neuwirth M, Hubmer M, Koch H. The posterior interosseous artery flap: clinical results with special emphasis on donor site morbidity. *J Plast Reconstr Aesthet Surg* 2013;66:623-8.

Figure legends

Figure 1

A, Wound on the right distal forearm. B, Distal radius fracture and disruption of the radial artery. C, After performance of repeated debridement. D, After flap elevation. E, Recurrent branch of

the anterior interosseous artery perforator (black arrow). F, After 90° of rotation. G, At 6 months after surgery.

Figure 2

Illustration of the recurrent branch of anterior interosseous artery perforator-based propeller flap.

A, Posterior interosseous artery. B, Recurrent branch of the anterior interosseous artery between the extensor digiti minimi and extensor carpi ulnaris. C, Dorsal branch of the anterior interosseous artery. The blue circle pertains to the primary vascular territory from the recurrent branch of the anterior interosseous artery, whereas the green circle indicates the adjacent vascular territory from the posterior interosseous artery. The blue arrow is the rotation arc of the recurrent branch of anterior interosseous artery perforator-based propeller flap.

Figure 3

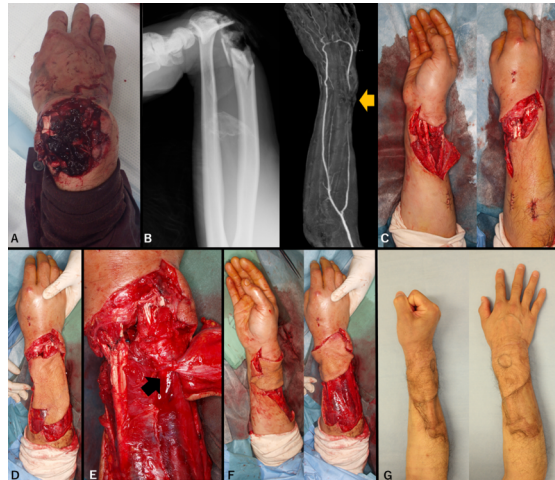
A, Wound on the right distal forearm. B, Degenerated tendons and intraoperative view of debridement. C, After performance of repeated debridement. D, Flap design. E, Recurrent

branch of the anterior interosseous artery perforator (black arrow). F, After 120° of rotation. G,

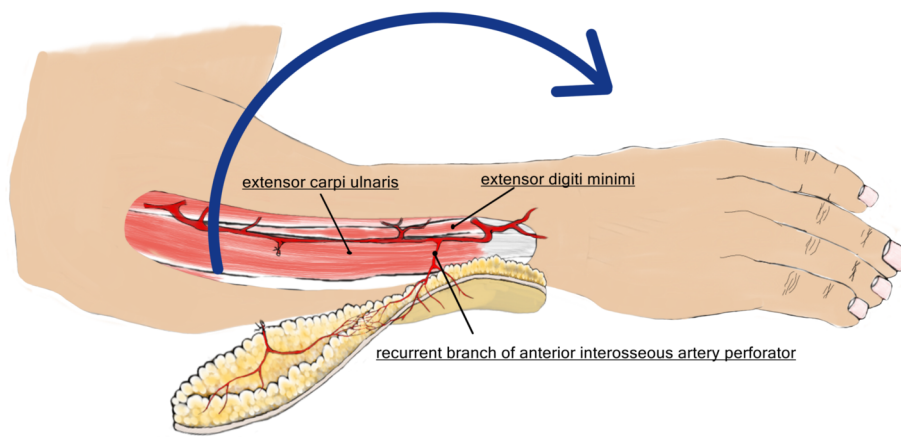
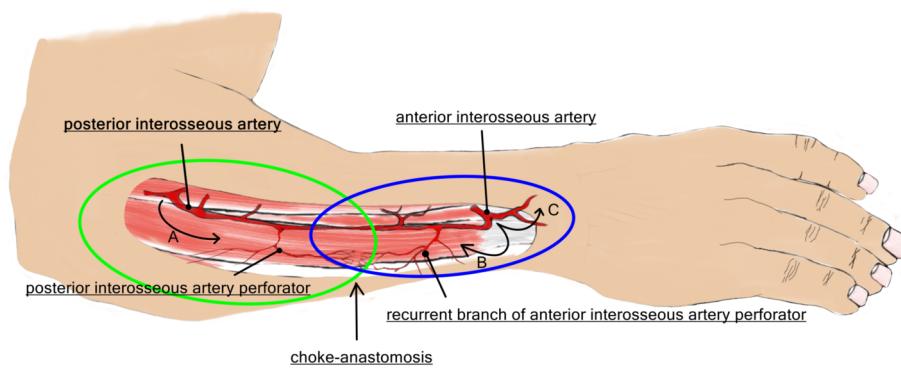
At 6 months after surgery.

Figure 4

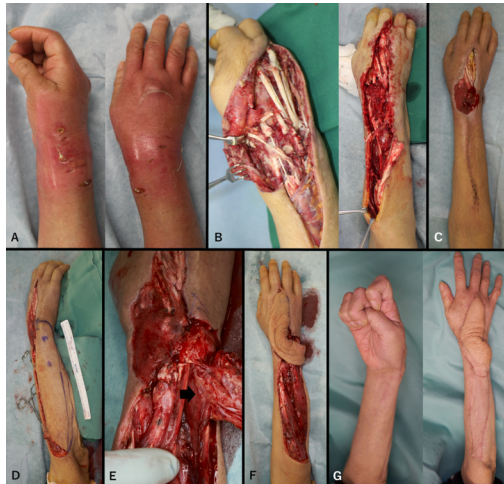Multidetector computed tomographic angiography (MDCTA) and 3D fusion images of the interosseous vascular system (blue vessel) in Case 2. A, Axial views of the MDCTA at each level (red arrows) and the recurrent branch of the anterior interosseous artery perforator (green arrows). B, Emerging point of the perforator through the septum between the extensor digiti minimi and extensor carpi ulnaris (yellow arrow).



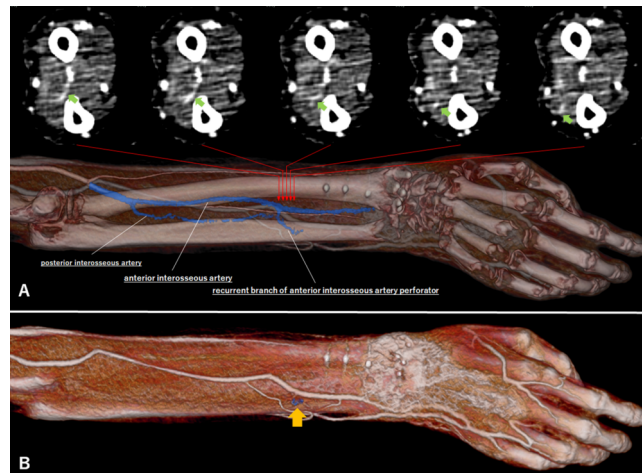
micr-18-0169-File002.tif



micr-18-0169-File003.tif



micr-18-0169-File004.tif



micr-18-0169-File005.tif