

Article type : Review

**Basal Cell Carcinoma of the Vulva: A Case Report and Systematic Review of the Literature**

Sruthi Renati, M.D.,<sup>1</sup> Christopher Henderson, M.D., M.Phil.,<sup>2</sup> Ashley Aluko, M.D.,<sup>3</sup>,  
Susan Burgin, M.D.<sup>4</sup>

<sup>1</sup> Department of Dermatology, University of Michigan, Ann Arbor, MI

<sup>2</sup> Department of Dermatology, Duke University Hospital, Durham, NC

<sup>3</sup> Department of Obstetrics and Gynecology, Beth Israel Deaconess Medical Center, Boston, MA

<sup>4</sup> Department of Dermatology, Beth Israel Deaconess Medical Center, Boston, MA

Corresponding author contact information:

Susan Burgin, M.D., [sburgin@bidmc.harvard.edu](mailto:sburgin@bidmc.harvard.edu), (T) 617-667-3753, (F) 617-975-5033

Beth Israel Deaconess Medical Center, Department of Dermatology, 330 Brookline Avenue,  
Shapiro Building; Boston, MA 02215-5400

This article has no funding source.

Conflict of Interest Disclosure: None Declared.

This research has not previously been published.

**This is the author manuscript accepted for publication and has undergone full peer review but has not been through the copyediting, typesetting, pagination and proofreading process, which may lead to differences between this version and the Version of Record. Please cite this article as doi: 10.1111/ijd.14307**

This article is protected by copyright. All rights reserved

This research did not require an IRB due to its being a systematic literature review.

Tables: 3

Figures: 2

## Abstract

**Background:** The vulva is an unusual site for basal cell carcinoma (BCC). Vulvar BCC accounts for less than 1% of all BCCs, and less than 5% of all vulvar malignancies. We report the case of an 83 year-old woman who presented with a two-month history of a tender labial growth, with histopathology confirming nodular BCC. We conducted a systematic literature review of the characteristics of reported cases of vulvar BCCs.

**Methods:** A comprehensive systematic review of articles indexed for MEDLINE and Embase yielded 96 reports describing 437 patients with 446 BCCs of the vulva.

**Results:** The mean age at presentation was 70 (range 20 to 100). Most women had no underlying vulvar disease. Approximately 60% of cases were of the nodular subtype. Treatment approach varied widely with over half of cases treated with wide local or local excision. Mohs micrographic surgery (MMS) for vulvar BCC was first reported in 1988 with seven total MMS cases reported. Twenty-three cases of recurrence have been reported; 21 of these cases after local excision, but none following MMS.

**Conclusion:** Vulvar BCC is rarely reported cancer that affects older women predominantly. MMS represents a promising treatment for BCC in this anatomic location.

## Introduction

While basal cell carcinomas (BCC) are the most common human malignancy, the vulva is an unusual location with vulvar BCCs accounting for less than 1% of all BCCs.<sup>1</sup> Additionally, BCC of the vulva accounts for less than 5% of all vulvar malignancies.<sup>2,3</sup> BCC of the vulva most

commonly affects elderly women. Presenting symptoms include pruritus, a lump, bleeding, and pain.<sup>4</sup> The proposed risk factors for BCC occurring in non sun-exposed sites such as the vulva include radiation therapy and basal cell nevus syndrome.<sup>5,6</sup> Treatment options for vulvar BCCs include radical and simple vulvectomy, wide local excision, simple surgical (local) excision and Mohs micrographic surgery (MMS). We report the case of an 83 year-old woman who presented with a BCC of the vulva. We also review the characteristics of the reported cases of vulvar BCCs in the literature, including treatment approach.

### **Case Report**

An 83 year-old woman with a 40-year history of treated lichen sclerosus presented with a tender growth in the genital area for two months. Genital examination revealed a 5mm eroded papule on the right inferolateral labium majus arising on normal skin, and a white, sclerotic appearance of the labia minora and clitoris (Figure 1). Biopsy of the papule revealed a nodular BCC. The patient underwent MMS. She has no evidence of disease recurrence at 3 years.

## Literature Review: Materials and Methods

A comprehensive systematic review of articles indexed for MEDLINE and Embase using the terms *basal cell carcinoma* or *basal cell cancer* or *basal cell epithelioma* or *basal cell tumor* or *basal cell tumour* or *BCC* and *vulva* or *vulvar* or *vulval* was performed. Rule-in criteria included anatomic localization of BCCs to the external female genitalia, English language abstract and article text, and non-duplication of cases. Exclusion criteria included lesions not confirmed as BCC by biopsy, ambiguous language regarding anatomic location, as well as review articles or opinion pieces that do not characterize a specific patient case. Two independent reviewers screened titles and abstracts for relevance. Two reviewers assessed the remaining articles for inclusion, with disagreements going to a third reviewer. Only published case reports or case series in peer-reviewed journals were included in this review, with publication years ranging from 1950 to 2015. Case series that presented case reports in aggregate form were included even if these reports did not specify lesion details beyond location and histopathology. In most case reports, lesion size, specific anatomic site, patient age, treatment, recurrence, associated metastases, and provider specialty were available. These data were noted and tabulated yielding 96 reports in the English literature describing 437 patients with BCCs of the vulva.<sup>1-96</sup> Of the 96 reports, 41 were published in the gynecology or gynecologic oncology literature, 29 in the dermatology literature, and 26 in non-gynecology, non-dermatology literature (pathology, surgery, oncology, medicine).

## Results

The mean age at presentation was 70 years (range 20 to 100). Of the 437 patients, 7 patients had more than one vulvar tumor ( 2 of whom had 3 primary tumors) resulting in a total of 446 cases of vulvar BCC.<sup>5,6,32,38,53,54</sup> Risk factors for the 7 patients with multiple BCC of the vulva included 4 patients with a previous history of multiple BCC on sun-exposed sites<sup>32,38,53,54</sup>, 2 patients with history of radiation to pelvis<sup>5,54</sup>, and 3 patients with Gorlin's syndrome.<sup>6,14</sup> Overall, most women did not have underlying vulvar disease; however, in 3 patients, BCCs arose in contiguity with extramammary Paget disease.<sup>7,44,63</sup> Two BCCs arose within an area of lichen sclerosis<sup>57,88</sup> while in a third case, a BCC arose adjacent to the area affected by lichen sclerosis<sup>34</sup>, as was seen in our patient.

### *Anatomic site*

The exact site on the vulva was documented in 212 cases. The labium majus was the site of origin in 162 cases, the clitoris in 10, labium minus in 8, perineum in 4, vagina/surrounding introitus and posterior fourchette in 3 each, and one BCC arose from the periurethral mucosa. Twenty-one further cases involved more than one anatomic location due to the larger size of tumor at presentation. Potential risk factors in these patients include underlying extramammary Paget disease in two women<sup>7,44</sup>, five patients with aggressive histology such as infiltrative, morpheaform and infundibulocystic BCC patterns<sup>7,56,61,71,92</sup>, two patients with a history of previous BCC on sun-exposed sites<sup>71,76</sup>, and seven patients with a documented late presentation, with either lesion ulceration, large size, and/or metastases.<sup>36,60,61,62,71,92</sup>

#### *Histopathologic subtype*

Specific histopathologic subtype of the BCC was documented in 199 cases (Figure 2) and included 116 (58%) cases that were nodular, 30 (15%) superficial and 27 (14%) infiltrative. There were 10 documented cases displaying more than one BCC histopathologic subtype—6 were nodular, infiltrative, and superficial; 3 were nodular and superficial; 1 was nodular and infiltrative and contiguous with a squamous cell carcinoma (SCC). Other reported histopathologic diagnoses were 4 cases of mixed BCC and SCC, 3 total cases of BCC contiguous to SCC (one mentioned above), and 10 cases of basosquamous cell carcinoma (BSC). Of the 10 cases of BSC, one case of BSC was infiltrative and metastatic to bone. This patient also had a history of basal cell nevus syndrome.<sup>14</sup>

#### *Therapeutic approach*

Surgical treatment approaches varied widely and were documented in 353 cases. The most common surgical treatment was wide local excision in 88 (25%) cases and simple surgical (local) excision in 173 (49%). Vulvectomy was also reported with 40 (11%) cases of bilateral simple vulvectomy, 23 (7%) cases of radical vulvectomy of which 17 had concomitant lymph node dissection, and 9 (3%) cases of hemi- or partial vulvectomy of which 2 cases had concomitant lymph node dissection. The indication for lymph node dissection in these 19 patients included 7 patients with palpable inguinal lymphadenopathy and 3 patients because biopsy revealed BSC histology.<sup>15,53,56</sup> Other reasons for lymph node dissection included 3 cases with initial diagnosis of SCC or adenocystic carcinoma<sup>15,55</sup> and 1 case due to large tumor size and concern for involvement of the clitoral lymphatic network.<sup>23</sup> Indications for lymph node dissection were not specified in the remaining 5 cases. Eight cases were treated with excisional

biopsy alone, 4 cases were treated with radiation therapy, and 3 cases were treated with electrocautery.

Seven (2%) total cases of MMS for the treatment of vulvar BCC have been reported. The first reported cases of vulvar BCC treated with MMS were in 1988 when 2 patients with BCC located on the perineum were successfully treated with MMS.<sup>20</sup> An additional 5 cases of vulvar BCC have since reported treatment with MMS.<sup>2,65,76</sup> A study by Gibson *et al.* found 8 cases of perianal and genital BCC successfully treated with MMS; however, this report does not specify whether these BCC were located on the vulva.<sup>1</sup> Our case documents an additional vulvar BCC successfully treated with MMS.

#### *Local recurrence*

Twenty-three cases of local recurrence have been documented in the literature (5.1% of 446 cases) (Table I). Twenty-one of these cases occurred following local excision (7 completely excised, 7 incompletely excised, 6 unspecified). The remaining cases recurred after radical vulvectomy and lymphadenectomy, x-ray therapy followed by direct radium application, and excisional biopsy with tumor-free margins. Of the 14 recurrent cases in which age was reported, patients were an average of 69 years old (range 44 to 92). The histopathological characteristics of primary BCC lesions that recurred were specified in 10 cases.<sup>10,34,61,69,77,95</sup> There was notable variation, including cases with both low<sup>34</sup> and high<sup>34,77</sup> mitotic counts. Squamous change was evident in 5 primary tumors.<sup>34,61,69,95</sup>

Recurrent lesions were most often treated with local excision. Four patients died from recurrent disease—one from local tumor invasion leading to hemorrhage and septicemia, another from local spread and infection, a third from renal failure due to pelvic and abdominal disease, and a fourth from respiratory distress secondary to lung metastases.<sup>15,34,80,95</sup> Multiple recurrences were not uncommon, occurring in four BCC cases. Of the cases involving a single recurrence, time to recurrence ranged from 6 months to 13 years. Three series of BCC cases revealed a local recurrence rate of 8.9-10.7%.<sup>15,34,82</sup> No recurrence after MMS has been reported (Table III).

#### *Metastatic BCC*

Twelve cases in this series of 446 were metastatic (2.7%). Table II presents key features of these cases. Of the 11 metastatic cases in which age was reported, patients were an average of 74 years old (range 41 to 87). BCC was metastatic to inguinal lymph nodes in 9 of the 12 cases. Palpable lymphadenopathy on the side of histologically confirmed metastases was appreciated in

only 3 of these cases. There was 1 reported case of distant nodal metastasis (supraclavicular lymph node)<sup>15</sup> and 4 cases of hematogenous spread (right thigh skin, pubic bone, femoral head, lung).<sup>61,62,77,95</sup> Metastatic BCC lesions tended to be large and deeply infiltrative. The depth of involvement was reported in 4 cases,<sup>34,62,71,86</sup> with the deepest penetration measuring 6 cm.<sup>62</sup> In 7 cases, the primary BCC invaded subcutaneous tissue or fat, and in 2 cases the tumor extended to the pubic bone.

Perrone *et al.* compared their single case of metastatic BCC to 10 cases of nonmetastatic BCC. They found that the metastatic lesion was distinguished by extensive local involvement of the urethra and vagina, clinical history of vaginal bleeding secondary to tumor infiltration, deep penetration into subcutaneous fat, and a morphea-like growth pattern.<sup>71</sup> Two cases of metastatic BCC were notable for delayed presentation—one patient noticed “something growing” on her vulva for approximately 5 years before seeking treatment, and another patient presented with a 14-year history of a lump on the mons pubis.<sup>86,92</sup>

Most patients with metastatic disease were treated with radical vulvectomy and bilateral inguinal lymphadenectomy. The patient with femoral head metastasis did not undergo inguinal node dissection because of known hematogenous spread and a primary goal of palliation.<sup>62</sup> Radiation therapy was performed on 5 patients. Winkelmann *et al.* present a case of a large and locally invasive tumor that rendered the patient an inoperable candidate. This patient was treated with pre-operative radiation that resulted in complete resolution of the tumor prior to radical vulvectomy and proctectomy with inguinal lymphadenectomy.<sup>92</sup> Four patients with metastatic BCC died from the disease.<sup>15,34,62,95</sup>

## Discussion

Although BCC is a common malignancy, the vulva is an unusual anatomic location for BCC and accounts for less than 1% of all BCC. We reviewed over 400 published cases of vulvar BCC in the literature and found that vulvar BCCs most often affect postmenopausal females over the age of 70. The most common location is the labium majus. Vulvar BCC is rarely associated with underlying vulvar disease such as extramammary Paget disease or lichen sclerosus.

Vulvar BCC is histopathologically similar to BCC occurring in other anatomic locations.<sup>19</sup> Certain histologic types such as basosquamous carcinoma, adenocystic and infiltrative types tend to be more aggressive and may explain cases of recurrence.<sup>97</sup> Lymph node involvement and hematogenous metastasis to distant sites are rare but can occur. Treatment

approaches varied widely in reported literature. Most cases were treated with wide local excision. A minority of patients underwent simple or radical vulvectomy. Seven cases treated with MMS have been well documented in the literature.

In our review of 437 patients with vulvar BCC, 23 (5.1%) recurred and 12 (2.7%) metastasized. Studies estimate a recurrence rate of 4.2% (follow up < 5 yrs) and 8.7% (follow up > 5yrs) for all BCCs<sup>98</sup> and the reported incidence of metastatic BCC for all BCCs ranges from 0.0028%-0.55%.<sup>5, 65</sup> These vulvar recurrence and metastatic rates are likely underestimated, as patient follow-up was limited in most case reports. Because of the low incidence of vulvar BCC, it remains difficult to define factors associated with increased risk of recurrent or metastatic disease. Several reported cases of local recurrence followed incomplete excision, though the presence or absence of positive surgical margins does not appear predictive of recurrence. High recurrence rates have been reported in the literature with local recurrence after complete local excision in about 10-20% of cases, possibly due to inadequate surgical margins.<sup>69</sup> Advanced vulvar BCC often involves metastasis to inguinal lymph nodes, though distant nodal metastasis and hematogenous spread are also possible. Based on our review, potential risk factors for metastatic disease include large size (including from late presentation), depth of involvement, and aggressive histologic features. Though uncommon, both recurrent and metastatic BCC can be fatal.

MMS has been associated with improved cosmetic and functional outcomes.<sup>5,65</sup> MMS may be the best chance of cure, especially with increased tumor size, aggressive histology, and when maximum uninvolved tissue preservation is desired.<sup>20</sup> The use of MMS for treatment of vulvar BCC may lead to improved rates of local recurrence. MMS represents a promising treatment for BCC in this anatomic location, however further experience with MMS for vulvar BCC is needed to confirm this observation

Questions (answers found after references)

1. In which decade do most patients experience vulvar BCC?
  - a) Fifth
  - b) Sixth
  - c) Seventh
  - d) Eighth



2. Which of the following is not a potential risk factors for BCCs developing in non sun-exposed areas?
  - a) Radiation therapy
  - b) Basal cell nevus syndrome
  - c) Recurrent infection
  - d) Lichen sclerosus
3. The majority of the articles reviewed in this manuscript come from which literature sources?
  - a) Gynecology
  - b) Gynecological oncology
  - c) Dermatology
  - D) Surgical oncology
4. What is the most common site for vulvar BCCs?
  - a) Introitus
  - b) Posterior fourchette
  - c) Periurethral
  - d) Labium majus
5. What is the most common histological subtype of vulvar BCC?
  - a) Superficial
  - b) Nodular
  - c) Infiltrative
  - d) Basosquamous
6. What is the recurrence rate of vulvar BCCs?
  - a) 1.4%
  - b) 3.5%
  - c) 5.1%
  - d) 8.5%
7. After which treatment modality did most vulvar BCC recurrences occur?
  - a) Mohs micrographic surgery
  - b) Electrodessication and curettage
  - c) Local excision
8. What percentage of vulvar BCCs result in metastasis?
  - a) 1.5%

- b) 2.7%
  - c) 5.1%
  - d) 7%
9. What is the most common location for vulvar BCC metastasis?
- a) Inguinal lymph node
  - b) Retroperitoneal lymph node
  - c) Distant site
  - d) Uterus
10. In the author's opinion, what is the preferred method for vulvar BCC treatment?
- a) Local excision
  - b) Electrodesiccation & curettage
  - c) Mohs micrographic surgery

Figure legends.

Figure 1. BCC arising from the labium majus. Changes of treated lichen sclerosus also seen.

Figure 2. Histopathologic subtypes of vulvar BCCs (n=199)

## References:

1. Gibson GE, Ahmed I. Perianal and genital basal cell carcinoma: a clinicopathologic review of 51 cases. *J Am Acad Dermatol.* 2001 Jul 1;45(1):68-71.
2. Miller ES, Fairley JA, Neuburg M. Vulvar basal cell carcinoma. *Dermatol Surg.* 1997 Mar 1;23(3):207-9.
3. Schueller EF. Basal cell cancer of the vulva. *Am J Obstet Gynecol.* 1965 Sep 15;93(2):199-208.
4. Piura B, Rabinovich A, Dgani R. Basal cell carcinoma of the vulva. *J Surg Oncol.* 1999 Mar 1;70(3):172-6.
5. Stiller M, Klein W, Dorman R, Albom M. Bilateral vulvar basal cell carcinomata. *J Am Acad Dermatol.* 1993 May 1;28(5):836-8.
6. Giuliani M, Di LS, Zoccali G, *et al.* Gorlin syndrome associated with basal cell carcinoma of the vulva: A case report. *Eur J Gynaecol Oncol.* 2006;27(5):519-22.
7. Abdelbaqi M, Shackelford RE, Quigley BC, *et al.* Concurrent Paget's disease and basal cell carcinoma of the vulva; a case report. *Int J Clin Exp Pathol.* 2012;5(6):592.
8. Abell MR. Adenocystic (pseudoadenomatous) basal cell carcinoma of vestibular glands of vulva. *Am J Obstet Gynecol.* 1963 Jun 15;86(4):470-82.
9. Aboul-Nasr AL. Malignant tumors of the female external genital organs. *J Egypt Med Assoc.* 1961;44:809.
10. Ackles RC, Pratt JP. Basal-cell carcinoma of the vulva. *Am J Obstet Gynecol.* 1956 Nov 1;72(5):1124-6.
11. Adem K, Nassar A. Pathologic quiz case: Fine-needle aspiration of lytic bone lesions in a 63-year-old woman. *Arch Pathol Lab Med.* 2004 Jul;128(7):819-20.
12. Ambrosini A, Becagli L, Resta P, *et al.* Basal cell carcinoma of the vulva. *Eur J Gynaecol Oncol.* 1980 May;1(2):126-8.
13. Asuman C, Özlem A, Burçak T, *et al.* An unusual location of basal cell carcinoma: the clitoris and the vulva *Indian J Dermatol.* 2008;53(4):192.
14. Bean SF, Becker FT. Basal cell carcinoma of the vulva: a case report and review of the literature. *Arch Dermatol.* 1968 Sep 1;98(3):284-6.
15. Benedet JL, Miller DM, Ehlen TG, *et al.* Basal cell carcinoma of the vulva: clinical features and treatment results in 28 patients. *Obstet Gynecol.* 1997 Nov 1;90(5):765-8.
16. Betti R, Brusca C, Inselvini E, *et al.* Basal cell carcinomas of covered and unusual sites of the body. *Int J Dermatol.* 1997 Jul 1;36(7):503-5.
17. Blas Ruperez BR, Margarita Riera MR, Isabel Lazaro IL, *et al.* Basal cell carcinoma of the vulva. *Int J of Gynecol Cancer.* 2013;23:1174.

18. Boyd WD. Vulval cancer, 1992-2002 - multidisciplinary care and prognostic factors. *Irish Medical Journal*. 2011;104:234-6.
19. Breen JL, Neubecker RD, Greenwald EA, *et al*. Basal cell carcinoma of the vulva. *Obstet Gynecol*. 1975 Aug;46(2):122-9.
20. Brown MD, Zachary CB, Grekin RC, *et al*. Genital tumors: their management by micrographic surgery. *J Am Acad Dermatol*. 1988 Jan 1;18(1):115-22.
21. Bukhari IA, Khalid AJ. Vulvar basal cell carcinoma misdiagnosed for 4 years. *Saudi Med J*. 2006;27(1):93-4.
22. Caucanas M, Müller G, Vanhooetghem O. Vulvar basal cell carcinoma: report of a case involving the mucosa and review of the literature. *Dermatol Reports*. 2011 Oct 5;3(3).
23. Celik H, Gurates B, Yavuz A, Dogan Z, *et al*. Vulvar basal cell carcinoma with clitoral involvement. *Acta Derm Venereol*. 2009 Mar 1;89(2):191-2.
24. Charles AH. Carcinoma of the vulva. *Br Med J*. 1972 Feb 12;1(5797):397-402.
25. Collins PS, Farber GA, Hegre AM. Basal-Cell Carcinoma of the Vulva. *Dermatol Surg*. 1981 Sep 1;7(9):711-4.
26. Copas PR, Spann JC, Majmudar B, *et al*. Basal cell carcinoma of the vulva. A report of four cases. *J Reprod Med*. 1996 Apr;41(4):283-6.
27. Cortés J, Marqués A, Torrecabota J, *et al*. Triple cancer in asymptomatic women. *Eur J Gynaecol Oncol*. 1982;3(1):24.
28. Cruz-Jimenez PR, Abell MR. Cutaneous basal cell carcinoma of vulva. *Cancer*. 1975 Nov 1;36(5):1860-8.
29. de Giorgi V, Massi D, Mannone F, *et al*. Dermoscopy in vulvar basal cell carcinoma. *Arch Dermatol*. 2007 Mar 1;143(3):423-31.
30. de Giorgi V, Salvini C, Massi D, *et al*. Vulvar basal cell carcinoma: retrospective study and review of literature. *Gynecol Oncol*. 2005 Apr 1;97(1):192-4.
31. DeAmbrosis K, Nicklin J, Yong-Gee S. Basal cell carcinoma of the vulva: a report of four cases. *Australas J Dermatol*. 2008 Nov 1;49(4):213-5.
32. Deppisch LM. Basal cell carcinoma of the vulva. *Mt Sinai J Med*. 1978;45(3):406-10.
33. Dudzinski MR, Askin FB, Fowler Jr WC. Giant basal cell carcinoma of the vulva. *Obstet Gynecol*. 1984 Mar;63(3 Suppl):57S-60S.
34. Feakins RM, Lowe DG. Basal cell carcinoma of the vulva: a clinicopathologic study of 45 cases. *Int J Gynecol Pathol*. 1997 Oct;16(4):319-24.

35. Fleury AC, Junkins-Hopkins JM, Diaz-Montes T. Vulvar basal cell carcinoma in a 20-year-old: Case report and review of the literature. *Gynecol Oncol Case Rep.* 2012 Jan;2(1):26.
36. Garg M, Sharma P, Gupta S, *et al.* Giant vulvar basal cell carcinoma. *BMJ Case Rep.* 2013;2013.
37. Gleeson NC, Ruffolo EH, Hoffman MS, *et al.* Basal cell carcinoma of the vulva with groin node metastasis. *Gynecol Oncol.* 1994 Jun 1;53(3):366-8.
38. Goldberg DJ. Multiple Basal-Cell Carcinoma of the Vulva. *Dermat Surg.* 1984 Aug 1;10(8):615-7.
39. Goldberg LH, Robins P. Basal-Cell Carcinoma on and Around the Female Genitalia. *J Dermatol Surg Oncol.* 1981 Jul 1;7(7):572-5.
40. Goldstein AI, Kent DR. All vulvar lesions should be biopsied: Basal cell carcinoma—an example of the futility of diagnosis by gross appearance. *Am J Obstet Gynecol.* 1975 Jan 15;121(2):173-4.
41. Goplerud DR, Keettel WC. Carcinoma of the vulva: A review of 156 cases from the University of Iowa Hospitals. *Am J Obstet Gynecol.* 1968 Feb 15;100(4):550-3.
42. Hoffman MS, Roberts WS, Ruffolo EH. Basal cell carcinoma of the vulva with inguinal lymph node metastases. *Gynecol Oncol.* 1988 Jan 1;29(1):113-9.
43. Ikeda S, Tanaka T, Kawada A. Ultrastructures of 2 cases of malignant vulva tumor after the long lapse of time. Paget's disease and basal cell carcinoma. *J Clin Electron Micro.* 1984;17:789.
44. Ishizawa T, Mitsuhashi Y, Sugiki H, *et al.* Basal cell carcinoma within vulvar Paget's disease. *Dermatology.* 1998;197(4):388-90.
45. Jimenez HT, Penoglio CM, Richart RM. Vulvar basal cell carcinoma with metastasis: a case report. *Am J Obstet Gynecol.* 1975 Jan 15;121(2):285-6.
46. Jurado F, Ramos A, Rivera M, *et al.* Vulvar basal cell carcinoma mimicking pigmented lichen planus. *J Am Acad Dermatol.* 2014;70:AB141.
47. Kacerovská D, Michal M, Kašpírková J, *et al.* Epidermolytic hyperkeratosis of the vulva associated with basal cell carcinoma in a patient with vaginal condyloma acuminatum and vaginal intraepithelial neoplasia harboring HPV, type 42. *Cesk Patol.* 2014 Apr;50(2):92-4.
48. Kanitakis J, Arbona-Vidal E, Faure M. Extensive pigmented vulvar basal-cell carcinoma presenting as pruritus in an elderly woman. *Dermatol Online J.* 2011 Jan 1;17(1).
49. Kara M, Colgecen E, Yildirim EN. Vulvar basal cell carcinoma. *Indian J Pathol Microbiol.* 2012 Oct 1;55(4):583.
50. Karlgren E. Vulvar malignancies treated at Sabbatsberg Hospital over 20 years. *Acta Obstet Gynecol Scand Suppl.* 1978 Jan 1;57(sup73):3-1.
51. Kelly J. Malignant disease of the vulva. *BJOG: An International Journal of Obstetrics & Gynaecology.* 1972 Mar 1;79(3):265-72.

52. Khandeparkar JMS, Dharwadkar AMP, Kamat VB. Basal cell carcinoma of vulva. A case report. *Indian Journal of Surgery*. 1982;44:265-7.
53. Kimball KJ, Straughn JM, Conner MG, *et al*. Recurrent basosquamous cell carcinoma of the vulva. *Gynecol Oncol*. 2006 Aug 1;102(2):400-2.
54. Lally A, Charnock F, Clelland C, Turner R, *et al*. Multiple vulval basal cell carcinomas. *J Eur Acad Dermatol Venereol*. 2007 Mar 1;21(3):407-8.
55. Lui PC, Fan YS, Lau PP, *et al*. Vulvar basal cell carcinoma in China: a 13-year review. *Am J Obstet Gynecol*. 2009 May 1;200(5):514-e1.
56. Marcus SL. Basal cell and basal-squamous cell carcinomas of the vulva. *Am J Obstet Gynecol*. 1960 Mar 1;79(3):461-9.
57. McAdams AJ, Kistner RW. The relationship of chronic vulvar disease, leukoplakia, and carcinoma in situ to carcinoma of the vulva. *Cancer*. 1958 Jul 1;11(4):740-57.
58. Merino MJ, LiVolsi VA, Schwartz PE, *et al*. Adenoid basal cell carcinoma of the vulva. *Int J Gynecol Pathol*. 1982;1(3):299-306.
59. Thomas RH, McGibbon DH, Munro DD. Basal cell carcinoma of the vulva in association with vulval lichen sclerosus et atrophicus. *J Royal Society Medicine*. 1985;78(Suppl 11):16.
60. Misago N, Suzuki Y, Miura Y, *et al*. Giant polypoid basal cell carcinoma with features of fibroepithelioma of Pinkus and extensive cornification. *Eur J Dermatol*. 2004;14(4):272-5.
61. Mizushima J, Ohara K. Basal cell carcinoma of the vulva with lymph node and skin metastasis. *J Dermatol*. 1995 Jan 1;22(1):36-42.
62. Mulayim N, Silver DF, Ocal IT, *et al*. Vulvar basal cell carcinoma: two unusual presentations and review of the literature. *Gynecol Oncol*. 2002 Jun 1;85(3):532-7.
63. Mulvany NJ, Rayoo M, Allen DG. Basal cell carcinoma of the vulva: a case series. *Pathology*. 2012 Oct 1;44(6):528-33.
64. Nazari Z, Omranipour R. Unusual location of vulvar basal cell carcinoma. *J Low Genit Tract Dis*. 2006 Oct 1;10(4):242-4.
65. Nehal KS, Levine VJ, Ashinoff R. Basal cell carcinoma of the genitalia. *Dermatol Surg*. 1998 Dec 1;24(12):1361-3.
66. Nel RW. Basal-cell carcinoma of the vulva-review of the literature and report of a case. *S Afr Med J*. 1957 Apr 1;31(16):381-3.
67. Nowak RJ. Basal cell carcinoma of the vulva. *Obstet Gynecol*. 1954 Oct 1;4(4):392-8.
68. Onnis A, Marchetti M, Valente S, *et al*. Surgical management of invasive vulvar carcinoma: a non mutilating technique. *Eur J Gynaecol Oncol*. 1981;2(3):85.

69. Palladino VS, Duffy JL, Bures GJ. Basal cell carcinoma of the vulva. *Cancer*. 1969 Sep 1;24(3):460-70.
70. Pengsaa P, Pothinam S, Udomthavornasuk B. Vulvar carcinoma at Srinagarind Hospital, Khon Kaen, Thailand. *Eur J Gynaecol Oncol*. 1993;14(1):56-62.
71. Perrone T, Twigg LB, Adcock LL, *et al*. Vulvar basal cell carcinoma: an infrequently metastasizing neoplasm. *Int J Gynecol Pathol*. 1987;6(2):152-65.
72. Pisani C, Poggiali S, Padova L, *et al*. Basal cell carcinoma of the vulva. *J Eur Acad Dermatol Venereol*. 2006 Apr 1;20(4):446-8.
73. Ramse OB. Carcinoma of the vulva. *Acta Obstet Gynecol Scand*. 1966 Jan 1;45(S9):127-8.
74. Regauer S, Nogales FF. Vulvar trichogenic tumors: a comparative study with vulvar basal cell carcinoma. *Am J Surg Pathol*. 2005 Apr 1;29(4):479-84.
75. Rodríguez VG, De la Fuente García A, Torres MA, *et al*. Could cryosurgery be an alternative treatment for basal cell carcinoma of the vulva *Indian Dermatol Online J*. 2014 Apr;5(2):160.
76. Saini R, Sarnoff DS. Basal cell carcinoma of the vulva presenting as unilateral pruritus. *J Drugs Dermatol*. 2008 Mar;7(3):288-90.
77. Sakai T, Goto M, Kai Y, Kato A, *et al*. Vulvar basal cell carcinoma with bone metastasis. *J Dermatol*. 2011 Jan 1;38(1):97-100.
78. Sasajima CC, Vilar E, de Brito EX, *et al*. Vulvar basal cell carcinoma: An unusual location. *J Am Acad Dermatol*. 2013 Apr 1;68(4):AB168.
79. Sherrard J, Bowen ML. Vulval carcinoma presenting as 'recurrent herpes'. *Int J STD AIDS*. 1998 Apr 1;9(4):237.
80. Siegler AM, Greene HJ. Basal-cell carcinoma of the vulva: A report of five cases and a review of the literature. *Am J Obstet Gynecol*. 1951 Dec 1;62(6):1219-24.
81. Simkin RJ, Fisher BK. Basal cell epithelioma of the vulva. *Obstet Gynecol*. 1977 May;49(5):617-9.
82. Simonsen E, Johnsson JE, Trop C, Alm P. Basal cell carcinoma of the vulva. *Acta Obstet Gynecol Scand*. 1985;64:231-4.
83. Smith BH, Daily WT. Basal cell carcinoma of the labium minus pudendi. *Arch Pathol*. 1950 Jul;50(1):132.
84. Staiano JJ, Wong L, Butler J, *et al*. Flap reconstruction following gynaecological tumour resection for advanced and recurrent disease—a 12 year experience. *J Plast Recon & Aesth Surg*. 2009 Mar 1;62(3):346-51.
85. Suda T, Kakinuma H. Erosive velvety lesion on the vulva--vulvar basal cell carcinoma. *Arch Dermatol*. 2006 Mar;142(3):385-90.

86. Sworn MJ, Hammond GT, Buchanan R. Metastatic basal cell carcinoma of the vulva case report. *BJOG: An International Journal of Obstetrics & Gynaecology*. 1979 Apr 1;86(4):332-4.
87. Takahashi H. Non-ulcerative Basal Cell Carcinoma. *J Dermatol*. 2000 Dec 1;27(12):798-801.
88. Thomas RH, McGibbon DH, Munro DD. Basal cell carcinoma of the vulva in association with vulval lichen sclerosus et atrophicus. *J R Soc Med*. 1985;78(Suppl 11):16.
89. Thurston JG. Basal-celled carcinoma of the vulva. *J Obstet Gynaecol Br Emp*. 1951 Jun 1;58(3):465-7.
90. Vakselj A, Bebar S. The role of sentinel lymph node detection in vulvar carcinoma and the experiences at the Institute of Oncology Ljubljana. *Rad Oncol*. 2007 Dec 1;41(4):167-73.
91. Ward J. Five cases of basal-cell carcinoma of the vulva. *J Obstet Gynaecol Br Emp*. 1956 Oct 1;63(5):697-705.
92. Winkelmann SE, Llorens AS. Metastatic basal cell carcinoma of the vulva. *Gynecol Oncol*. 1990 Jul 1;38(1):138-40.
93. Wright JL. Two unusual vulval tumours. *N Z Med J*. 1951 Dec;50(280):560-5.
94. Yaghoobi R, Razi T, Feily A. Clinical image: an unusual pigmented basal cell carcinoma arising from vulva. *Acta Dermatoven APA*. 2011;20(2).
95. Yamagami T, Araki S, Aiko Y, *et al*. Examination of metastatic basal cell carcinoma. *Kurume Medical J*. 1974 Nov 15;21(2-3):83-6.
96. Zerner J, Fenn ME. Basal cell carcinoma of the vulva. *Int J Gynaecol Obstet*. 1979 May 1;17(3):203-5.
97. Jacobs GH, Rippey JJ, Altini M. Prediction of aggressive behavior in basal cell carcinoma. *Cancer*. 1982 Feb 1;49(3):533-7.
98. Rowe DE, Carroll RJ, Day CL, Jr. Long-term recurrence rates in previously untreated (primary) basal cell carcinoma: Implications for patient follow-up. *J Dermatol Surg Oncol*. 1989 Mar 1;15(3):315-28.

Answers to questions:

1, c; 2, c; 3, a, b, & c; 4, d; 5, b; 6, c; 7, c; 8, b; 9, a; 10, c



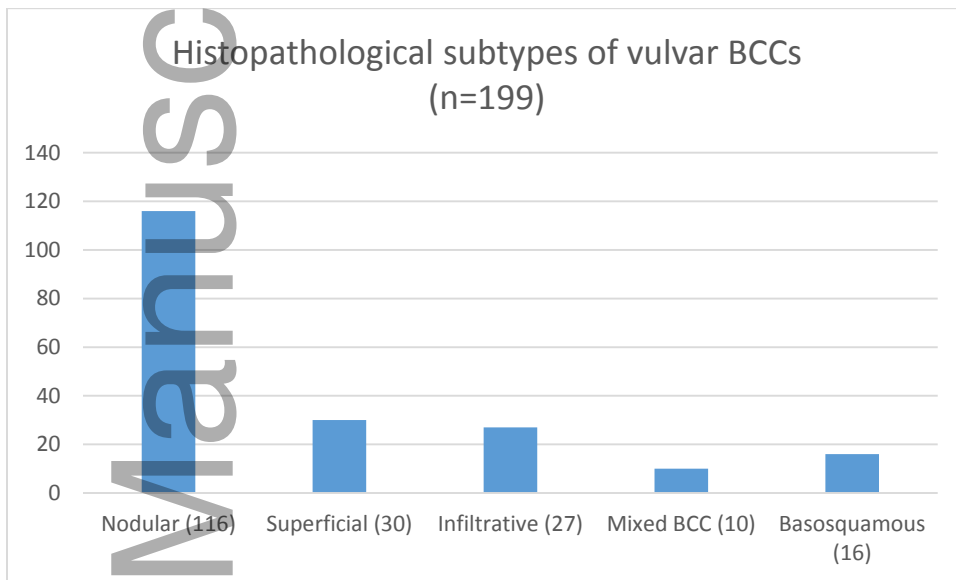
**Figure 2**

Table I: BCC Recurrences

Article	No	Notable Patient History	Primary BCC* Size (cm), Extent	Primary Treatment	Recurrence		Recurrence Treatment/ Outcome
					Months to recurrence	Features	
Siegler <i>et al.</i> , 1951	1	Age 49	Size: 3	X-ray therapy, followed by radium applied directly to the lesion	12	Local recurrence	Radical vulvectomy with removal of posterior and lateral vaginal walls, post-operative radiation. Pt died one year later of local spread and infection.
Abell <i>et al.</i> , 1963	2	Age 44	Size: 2.5	Local excision (complete)	~156	Local recurrence	Vulvectomy and bilateral inguinal lymph node dissection.
Palladino <i>et al.</i> , 1969	3	Age 39	---	Local excision	24 then 72	Local recurrence	Local re-excision both times. Pt died of squamous cell CA of lung 11 yrs after biopsy of primary BCC lesion.
	4	Age 69	Size: 1.5	Local excision	36	Local recurrence	Local re-excision. Disease-free 6 years following original excision.
Yamagami <i>et al.</i> , 1974	5	Age 53	---	Local excision	13 then 22	Local recurrence  * At the time of 3 <sup>rd</sup> recurrence, pt was diagnosed with metastatic BCC	Chemotherapy followed by local radiation. Pt's lungs deteriorated and she died of respiratory failure due to lung metastases.
Deppisch <i>et al.</i> , 1978	6	Age 56	---	Local excision	6	Local recurrence	Local re-excision. Disease-free at 5-year follow-up

<b>Zerner et al., 1979</b>	7	Age 87	---	Local excision (complete)	---	Local recurrence	---
	8	Age 92	Size 3 x 5	Local excision (complete)	---	Local recurrence	---
<b>Simonsen et al., 1985</b>	9-10	---	---	Local excision (complete)	~60	Local recurrence	Local surgical extirpation
	9.5% (2/21)						
<b>Copas et al., 1996</b>	11	Age 87	---	Local excision	60	Local recurrence (3x5cm)	Local re-excision (complete). Pt died one month later of MI
		Renal cell CA					
	12	Age 89	---	Local excision (complete)	120	Local recurrence (3 lesions, largest 4x7mm)	Local re-excision (complete). Disease-free at 6 month follow-up.
		2 BCC recurrences			*time to 3 <sup>rd</sup> recurrence		
<b>Feakins et al., 1997</b>	13	---	Size: >5, nodal metastases	Radical vulvectomy, inguinal lymphadenectomy (complete)	23	Local recurrence	Tumor eroded into inguinofemoral blood vessels causing hemorrhage and septicemia. Patient died from BCC.
	8.9% (4/45)						
	14-16	---	---	Local excision (incomplete)	---	Local recurrence	---
<b>Benedet et al., 1997</b>	17-18	---	---	Wide local excision (incomplete)	24	---	Local re-excision (complete)
	10.7% (3/28)						
	19	Age 80	Size 2 x 1	Wide local excision (incomplete), followed by immediate re-excision (complete)	72	Local recurrence	Irradiated supraclavicular nodal metastasis (apparently complete resolution). Pt died of renal failure 2 years later, due to pelvic and abdominal disease.
						*After primary treatment, prior to local recurrence, pt presented with metastatic BCC in supraclavicular node	

<b>Piura <i>et al.</i>, 1999</b>	20	Age 62	Size: 2	Wide local excision (complete)	65	Local recurrence	Local excision (complete). Disease-free at 15 month follow-up.
	21	Age 72 Breast CA	Size: 1	Excisional biopsy with tumor free margins (required repeat excisional biopsy at 6 months due to first recurrence)	16 *time to 2 <sup>nd</sup> recurrence	Local recurrence	Right hemivulvectomy (complete). Disease-free at 143 month follow-up.
<b>Gibson <i>et al.</i>, 2001</b>	22	---	---	Wide excision	84	---	---
<b>Sakai <i>et al.</i>, 2011</b>	23	Age 87	Size: 5 x 3.7	Local excision (complete)	55	Presented with ulcerated, indurated left inguinal lesion. CT showed 25mm x 22mm mass in left inguinal region (recurrence vs. lymph node metastasis) MRI showed metastasis to pubic bone	Surgical excision, then palliative treatment. Pt alive and well at 14 month follow-up

Table II: BCC metastases

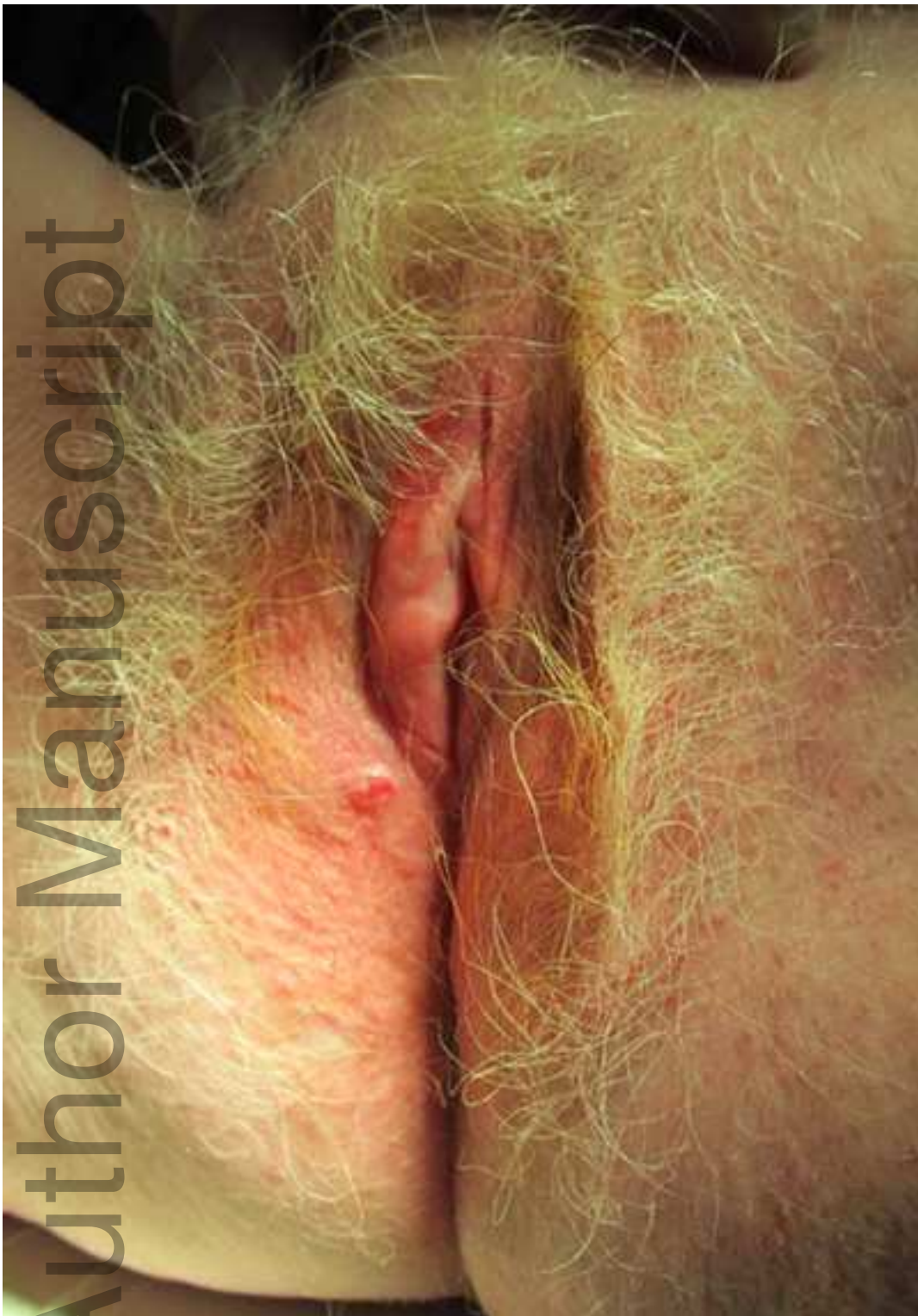Article	No	Age	Size (cm)/ Extent	Primary Histologic Features	Palpable inguinal nodes?	Site of Metastasis	Treatment/Outcome
<b>Yamagami <i>et al.</i>, 1974</b>	1	53	---	Mixed solid and adenoid type	No	Lung	Chemotherapy followed by local radiation. Pt's lungs deteriorated and she died of respiratory failure due to lung metastases.
<b>Jimenez <i>et al.</i>, 1975</b>	2	41	5 x 5 x 2.5  Infiltrated deep and lateral subcutaneous tissues	Infiltrative, small foci of squamoid cells	Yes (left)	Inguinal lymph nodes (left, both superficial and deep)	Radical vulvectomy, bilateral lymph node dissection
<b>Sworn <i>et al.</i>, 1979</b>	3	71	8 x 4.5  Extended 0.5 cm into adjacent fat.	Solid and adenoid, many mitotic figures	No	Lymph nodes in subcutaneous fat (5 total)	Lesion completely excised
<b>Perrone <i>et al.</i>, 1987</b>	4	86	"Large"  Infiltrated lateral wall of vagina, urethra, subcutaneous fat (thickness=1.2)	Adenoid, morphealike, pillar type  keratinization	No	Inguinal lymph nodes (3 right, 4 left, 1 Cloquet)	Radical vulvectomy, bilateral inguinal lymphadenectomy, post-operative radiation to pelvis and inguinal areas. Patient alive and well at 1 yr and 2 month follow-up
<b>Hoffman <i>et al.</i>, 1988</b>	5	74	6 x 4, 1 (two lesions)  Infiltrated subcutaneous fat, extended to perineal body and approaching anal skin	Solid, adenoid, areas of keratinization, infrequent mitoses	No	Inguinal lymph nodes (2/12 left, superficial)	Radical vulvectomy, bilateral inguinal lymphadenectomy
<b>Winkleman <i>n et al.</i>,</b>	6	71	6 x 15	Morpheic	Yes (bilateral)	Inguinal lymph node (1/6 right, 0/8 left)	Pre-operative radiation to vulva, symphysis pubis and perineal body (complete resolution), radical

1990			Ulceration and necrosis to the depth of the symphysis pubis				vulvectomy and proctectomy with removal of the anus with transverse colostomy, inguinal lymphadenectomy
<b>Gleeson <i>et al.</i>, 1994</b>	7	86	2.5 x 4  Shallow ulcer	Nodular, adenoid, few mitotic figures, hyperkeratotic squamous epithelium	Yes (left)	Inguinal lymph node (right)	Radical vulvectomy, bilateral inguinofemoral lymphadenectomy. Patient disease free at 1-year follow-up
<b>Mizushima <i>et al.</i>, 1995</b>	8	79	10 x 8  Infiltrated deep and lateral subcutaneous tissues	Adenoid, squamoid tumor cells, mitotic figures observed, vascular invasions, tumor embolizations	Yes (bilateral)	Inguinal lymph nodes (10/26)  Skin (right thigh)	The skin metastasis on the right thigh was slightly reduced by radiation before pt was lost to follow-up. (Pt had undergone radical excision of vulvar BCC and bilateral lymph node dissection 6 months prior). Pt's breast CA recurred, and she died the following year.
<b>Feakins <i>et al.</i>, 1997</b>	9	---	Infiltrated subcutaneous fat (depth= 1.12)	Infiltrative, compact lobular, low mitotic count, focal benign squamous change	---	Inguinal lymph node	Radical vulvectomy and inguinal lymphadenectomy (complete). Local recurrence at 23 months, tumor eroded into inguinofemoral blood vessels causing hemorrhage and septicemia. Patient died from BCC.
<b>Benedet <i>et al.</i>, 1997</b>	10	80	2 x 1  Infiltrated subcutaneous tissue, perineural invasion	---	---	Supraclavicular lymph node	Treated supraclavicular nodal met with irradiation, with apparently complete resolution. Pt developed a local recurrence 2 years after this. Pt died of renal failure 2 years later (thought 2/2 pelvic and abdominal disease)
<b>Mulayim <i>et al.</i>, 2002</b>	11	86	13 x 8  Infiltrated to pubic bone. (Max thickness= 6), involved perineal body and the lower vagina.	Solid, adenoid, mitoses common.	No	Femoral head (left)	Radical resection of the vulva bilaterally, mons anteriorly, perineum posteriorly. Radiation to the femoral head metastasis. At 6 months, she progressed with multiple bony(right femur, skull) and intraperitoneal metastases and died with disease.

<b>Sakai <i>et al.</i>, 2011</b>	12	87	5 x 3.7	Infiltrative, high mitotic figures	---	Inguinal lymph node (left, vs. local recurrence)  Pubic bone	Surgical excision then palliative treatment. Pt was alive and well at 14 mo follow-up
----------------------------------	----	----	---------	------------------------------------	-----	--	---

Table III: BCC Primary Treatment Preceding Local Recurrence

Primary treatment	Case number	Local Recurrence (n= 23)	Avg. size (cm) if recurrent
Local or wide local excision	261	21	3.0cm (n=7)
Bilateral simple vulvectomy	40	0	--
Radical vulvectomy	23	0	--
Hemi vulvectomy	9	0	--
Excisional biopsy	8	1	1cm (n=1)
Radiation therapy	4	1	3cm (n=1)
Electrocautery	3	0	--
Mohs micrographic surgery	7	0	--



ijd\_14307\_f1.jpg