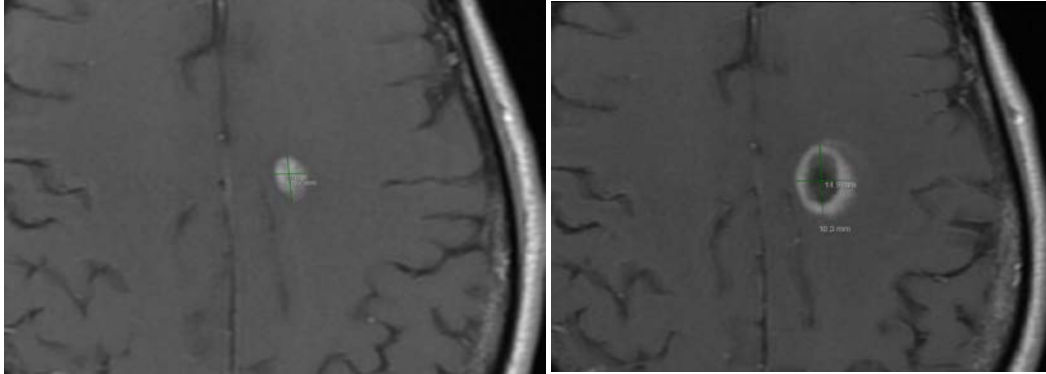


Supplemental Figure for:
Outcomes in patients treated with laser interstitial thermal therapy for primary brain cancer and brain metastases
Leigh Klaus Swartz et al.



Supplemental Figure S1
MR brain of patient with GBM prior to LITT (left) and 6 weeks after LITT (right)