

THE ENERGY-ABSORBING STEERING COLUMN

A Study of Collision Performance
in Fatal and Nonfatal Accidents

DONALD F. HUEIKE, PH.D.
Associate Professor of Anatomy

WILLIAM A. CHEWNING, B.S.
Research Associate

The University of Michigan

HIGHWAY SAFETY RESEARCH INSTITUTE
The University of Michigan • Ann Arbor
1968

HSRI Report No. Bio-7

This research was supported in part by United States Public Health Service research grant no. UI-00021 from the Injury Control Program, National Center for Urban and Industrial Health (Cincinnati, Ohio) and by the Highway Safety Research Institute of The University of Michigan (Ann Arbor). The drawing of the energy-absorbing steering column is reproduced with the permission of Paul Skeels of General Motors Proving Ground.

Introduction	1
References	3
Impact on the Energy-Absorbing Column by the Driver	5
Death From Steering Wheel-Column Impact	39
Facial Injuries From Striking the Steering Wheel	49

CONTENTS

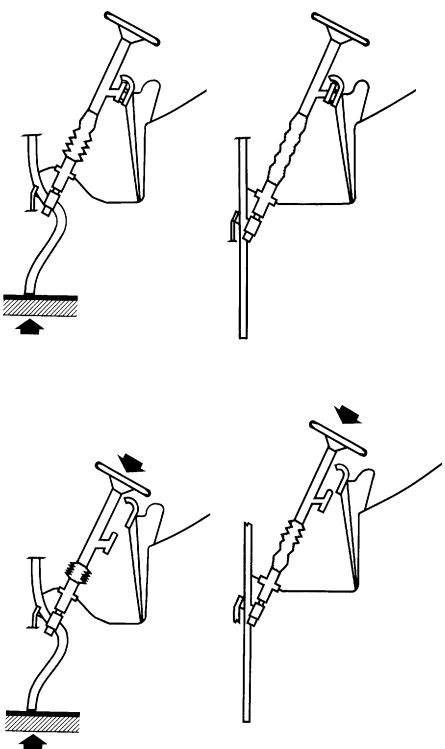


INTRODUCTION

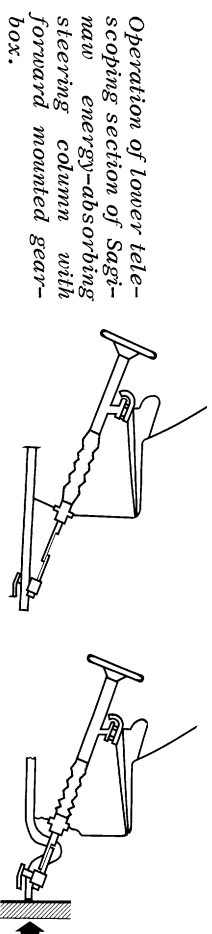
From a previous four-year study of fatal automobile accidents (1961-1965)^{1,2*} and ACIR** data,³ it has been shown that the steering assembly—the column and steering wheel rim—ranked high as one of the major causes of fatal and serious injuries to drivers in automobile crashes. In the Michigan study, only deaths resulting from ejection exceeded driver-steering assembly fatalities, and then only slightly. Most of these dangerous or fatal injuries were caused by blunt impact to the thoracic or abdominal viscera. These studies indicated that if the driver's torso would strike a nonpenetrating or energy-absorbing structure rather than a rigid one, less force would be transmitted to the vital thoracic and abdominal organs, and a reduction in the number of fatalities and a decrease in the severity of injuries sustained could be anticipated.

Energy-absorbing steering columns were incorporated in all 1967 model cars manufactured in North America by General Motors, Chrysler, and American Motors. This energy-absorbing column is firmly attached to the instrument panel by one-way breakaway mounts to resist any rearward movement of the column. There is also a clamp on the column at the toe-pan for the same purpose. Within the column, the shift tube and center steering shaft are constructed of telescoping components which are fastened together in such a manner that an axial force of approximately 150 pounds is required to push them together. The energy-absorbing steering column mesh jacket, located just above the toe-pan, can be reduced in length by loading either from above by the driver, or from below by frontal crush of the vehicle. The mesh section can compress a maximum of $8\frac{1}{4}$ inches.

In addition, those models with a forward-mounted gear box have a telescoping section inside the engine compartment which allows the steering shaft to reduce in length an additional $9\frac{1}{2}$ inches. This underhood section is not energy absorbing to the driver, but allows for more vehicle exterior front-end crush before the column is loaded rearward at the toe-pan. It, therefore, reduces the rearward movement of the steering assembly in the vehicle cabin. A detailed description of this energy absorbing system has been presented by Skeels.⁴



Operation of Saginaw energy-absorbing steering column rearward mounted gear box.



Operation of lower telescoping section of Saginaw energy-absorbing steering column with forward mounted gear box.

*Superior figures refer to references on page 3.
**Automotive Crash Injury Research, Cornell Aeronautical Laboratory.

There are no anthropomorphic dummies yet developed to indicate a realistic injury level for the internal organs and no animal experiments can accurately duplicate *adult* human internal organ injury; only field investigations of crashes involving automobiles equipped with the energy-absorbing steering column can adequately document any changes in mortality and morbidity from driver impact to such a system.

Research investigations of fatal and nonfatal automobile crashes involving "late" model cars have been conducted at The University of Michigan for the past four years. Automobiles equipped with the energy-absorbing steering column have appeared in the study and a comparison can be made with fatal accidents previously studied. In the fatal series (pre-1967 models), no automobiles were equipped with the energy-absorbing steering column system.

At the present time, only two driver fatalities have been reported from impact to the energy-absorbing steering column system in this study. One of these involved a violent head-on collision where the impact forces exceeded the limits of the energy-absorbing column; the column compressed its total distance. No driver deaths from striking the energy-absorbing column have been noted in other studies.^{5,6}

Steering column injuries sustained by drivers striking the energy-absorbing column, whether they wore a seat belt or not, at most usually consist of "a sore chest." When interviewed, the drivers frequently stated that they "ached all over," a typical statement made by many occupants after an automobile accident.

Often in low-speed accidents involving vehicles with or without the energy-absorbing column, facial injuries were sustained from wheel rim contact. These injuries were usually located near the midline of the face. Lacerations to the forehead, nasal area (usually without nasal bone fracture), lips, teeth, or chin were most frequently noted. The vertical location of these injuries on the face apparently depends on the height of the individual and the speed of the vehicle at impact. Such injuries are even noted in drivers wearing seat belts; thus, seat belts do not necessarily prevent these facial injuries. Such injuries, however, could be prevented by a shoulder belt worn in combination with a lap seat belt. In higher speed impacts, the driver's face apparently misses the steering wheel, and he strikes his torso on the wheel.

A maximum force requirement of 2500 pounds for the passenger vehicle steering assembly (wheel and column) has been set by federal regulation.⁷ This study indicates that the force required to compress the energy-absorbing steering system is neither insufficient nor excessive with respect to driver injury. Any changes in the standards should, therefore, be considered only after a careful study of field accident data.

The following case histories are divided into three groups:

The first contains accidents involving impact on the energy-absorbing column system by the driver.

The second group is of accidents wherein drivers died from steering wheel-column impact.

The third group illustrates facial injury accidents where the driver struck the steering wheel.

REFERENCES

1. Huelke, D. F. and Gikas, P. W.: "Causes of Deaths in Automobile Accidents—Final Report," Office of Research Administration, Report No. 06749-1-F, The University of Michigan, April, 1966.
2. Huelke, D. F. and Gikas, P. W.: "Ejection—The Leading Cause of Death in Fatal Automobile Accidents," *The Tenth Staph Car Crash Conference*, Society of Automotive Engineers, pp. 260-294, 1967.
3. Schwimmer, S. and Wolf, R. A.: "Leading Causes of Injury in Automobile Accidents," Automotive Crash Injury Research, Cornell Aeronautical Laboratory, Cornell University, Ithaca, New York, June, 1962.
4. Skeels, P. C.: "The General Motors Energy Absorbing Steering Column," *The Tenth Staph Car Crash Conference*, Society of Automotive Engineers, pp. 1-13, 1967.
5. Siegel, A.: Personal Communication, 1967.
6. Nelson, W. D.: "Bibliography of Accident Cases Involving the 1967 Energy Absorbing Steering Column," General Motor Proving Ground Report Nos. 23757 and 24043, 1967.
7. *Motor Vehicle Safety Standard No. 203 S4.1*, "Impact Protection for the Driver from the Steering Control System-Passenger Car," Federal Register 32, No. 23, p. 2414, February, 1967.



**Impact on the Energy-Absorbing
Column by the Driver**

1967 Chevelle (Figures 1 and 2). In this intersection collision, the Chevelle struck another car in the side at 20 mph. The underhood portion of the energy-absorbing column telescoped $3\frac{1}{8}$ inches. There were no reported injuries to the unrestrained 29-year old male driver. The in-car energy-absorbing section of the column was not collapsed.


(Case #156/10/6/66)



1




2



3


1967 Chevrolet (Figures 3 and 4). This vehicle struck a van which had turned in front of the case vehicle. The impact speed was estimated at 20-25 mph. The in-car portion of the energy-absorbing column compressed approximately $1\frac{1}{2}$ inch. The unrestrained 18-year old male driver sustained a 4 cm laceration in the left eyebrow area from steering wheel impact, a right knee abrasion (lower instrument panel), and a bruise to his right forearm (instrument panel?). (Case #182/12/8/66)



4

1967 Chevrolet (Figures 5 and 6). This vehicle was driven by a 21-year old male who was forced off the road into the ditch. The in-car mesh section compressed approximately $\frac{3}{4}$ inch. The right door glass was broken. The driver sustained a small ($\frac{1}{2}$ cm) laceration on the right side of his nose (steering wheel or window glass), a fracture of his nose, and a fracture of his maxilla from steering wheel impact or other interior components; he was not wearing a seat belt and was free to bounce about in the car.


(Case #240/8/9/67)




5



6



7




8


1967 Pontiac (Figures 7 and 8). This vehicle was driven by a 28-year old female (5 ft, 6 in., 143 lb), who was not wearing a seat belt because she was 7 months pregnant. The car had just started up from a parking space when it hit a parked car at an impact speed of approximately 15-20 mph. The driver struck the wheel and compressed the column approximately $\frac{1}{2}$ inch. She lacerated her lower lip and loosened a tooth (steering wheel) and had a right knee bruise (lower instrument panel). She also recalls hitting the steering wheel with her abdomen but did not have any bruises from this impact. Two months later, she delivered a normal, healthy baby.

(Case #235/7/19/67)


1967 Camaro (Figures 9 and 10). This is an intersection collision at an approximate impact speed of 30 mph. The 16-year old male driver (5ft, 7 in., 200 lb) sustained a 4 cm chin laceration from striking the steering wheel. The in-car portion of the energy-absorbing column was compressed 4 inches. No complaints of specific chest or abdominal injuries were indicated. The driver sustained small scratches in the hairline (windshield) and had a sore neck (rear passenger and seat back impact). He complained of a bruised, stiff left knee and stated that he was "sore all over."
(Case #227/6/11/67)



9




10




11

1967 Chevrolet (Figures 11 and 12). This vehicle, driven by a 21-year old male, went out of control and into a ditch after the unrestrained driver fell asleep. The vehicle rolled onto its left side. The left door window glass was broken. There was in-car column compression of approximately $\frac{3}{4}$ inch. The steering wheel was not deformed; no injuries to the chest or abdomen were noted from steering wheel impact. The driver sustained abrasions of both forearms (steering wheel, door?), fracture of the fourth metacarpal of the right hand (source unknown), abrasions of the left temporal area of the head (steering wheel, door?), and a 2 cm laceration of the eyelid (window glass).
(Case #239/8/4/67)



12

1967 Plymouth (Figures 13 and 14). This vehicle, driven by a 22-year old male, went off the roadway and struck two trees when the driver fell asleep. The unrestrained driver struck his chest on the steering wheel, compressing the column $\frac{1}{2}$ inch; he did not have any chest pain or injuries related to this impact. Both knees were bruised from instrument panel impact.
(Case #174/11/24/66)



13




14




15

1967 Chevelle (Figures 15 and 16). This is an intersection collision at approximately 25 mph. There was no compression of the energy-absorbing column. The 25-year old driver complained of chest pain (steering wheel), a bump on the head (rear view mirror), and a bruised left knee (lower instrument panel).
(Case #202/3/9/67)




16


1967 Barracuda (Figures 17 and 18). This vehicle went off the roadway on a curve and flipped over, damaging both the front and rear ends. The in-car energy-absorbing column compressed approximately $\frac{1}{2}$ inch. There was some slight separation of the column from its instrument panel mounting. The 40-year old male driver, who was unrestrained, sustained facial abrasions and multiple small scalp lacerations (windshield), multiple body abrasions, and a fracture of the right tibia. He had no specific injury that could be related to steering wheel-column impact.
(Case #216/4/18/67)



17




18



19

1967 Chevy II (Figures 19 and 20). This vehicle struck the rear of another car. The unrestrained 61-year old male driver had a contusion of the anterior chest wall from steering wheel impact. Two of the three wheel spokes were cracked at their attachment to the hub of the steering column. No compression of the mesh section of the column was noted.


(Case #214/4/12/67)




20

1967 Buick (Figures 21 and 22). This station wagon struck the rear of a foreign-made station wagon at approximately 60 mph. The 30-year old male driver (6 ft, 175 lb) was wearing a seat belt. He sustained a 1-inch laceration of the lower lip and gingiva, and had a sore chest. These injuries were sustained by steering wheel impact. The energy-absorbing mesh section compressed 3 inches and the underhood unit telescoped $3\frac{3}{4}$ inches. Abdominal bruising from the seat belt was noted. Right leg bruises were sustained by lower instrument panel contact.


(Case #284/12/15/67)



21




22



23

1967 Chevrolet (Figures 23 and 24). This car struck another, head-on, at 30-35 mph. The unrestrained 45-year old male driver (5 ft, 8 in., 180 lb) sustained two rib fractures, a laceration, and possible fracture of the nose from steering wheel impact. The in-car mesh section column compressed $4\frac{1}{4}$ inches. (Case #285/12/18/67)



24

1964 Oldsmobile F-85 (Figures 25 and 26). This vehicle struck the 1967 Chevrolet shown in Figures 59, 60, and 61. The 50-year old male driver was not wearing a seat belt. He sustained lacerations to the chin and neck area (steering wheel rim and/or windshield) and fractures of several ribs. In addition, he had an injury to the colon, requiring exploratory surgery, and fractured his left tibia. The imprint of the horn button was still visible on the anterior chest wall 7 months after the accident.


(Case #231/6/18/67)



25




26



27

1967 Buick (Figures 27 and 28). This was a head-on glancing collision where the subject vehicle was almost stopped (5 mph) and the other car was traveling at 50 mph at impact. The 55-year old male driver (6 ft, 1 in., 175 lb) was wearing a lap seat belt; he fractured his nasal cartilage and had upper abdominal bruising from steering wheel impact. The mesh section of the column compressed $1\frac{3}{4}$ inches. He also had seat-belt bruises on the iliac crests; both legs were bruised (lower instrument panel) and minor lacerations of his left leg were noted (instrument panel or side wall beneath panel).
(Case #248/8/25/67)




28


1967 Ambassador Station Wagon (Figures 29 and 30). This vehicle went off the right side of the road and hit a tree 50 feet off the road's edge, at an impact speed of 40 mph. The 17-year old male driver wore a seat belt but did not have belt bruises. He had chest bruises from steering wheel impact; the mesh section of the column compressed 1¾ inches; the underhood section also telescoped, but an accurate measurement could not be obtained. The driver had a small laceration near the hairline (sun visor-header), a fracture of his right patella (lower instrument panel), and a fracture of his right hand (instrument panel?).
(Case #270/11/4/67)



29




30



31

1967 Chevrolet (Figures 31 and 32). This car hit a tree at an estimated speed of 25 mph. The 30-year old female driver was not wearing a seat belt. She sustained a sore chest from steering wheel impact and also had a small laceration to her eyebrow from windshield or steering rim contact. The mesh section compressed $4\frac{3}{4}$ inches. (Case #252/8/23/67)




32


1968 Oldsmobile Cutlass (Figures 33 and 34). The driver of this car fell asleep; the vehicle went off the left side of the road and hit a tree at 35 mph. The unrestrained 27-year old male driver (5 ft, 10 in., 155 lb) struck the steering wheel (sore chest); the mesh section compressed 3 inches and the underhood section telescoped 4 inches. He also sustained a laceration above the right eye (windshield) and a left knee bruise (lower instrument panel).
(Case #264/9/24/67)



33



34



35


1967 Oldsmobile Delta 88 (Figures 35 and 36). This car struck another at an equivalent car-to-car speed of 25 mph. The 37-year old female driver (5 ft, 6 in.) was wearing her seat belt loosely at the time of impact. She sustained a sore chest from striking the steering wheel. She compressed the mesh section 2 inches; the underhood section telescoped $3\frac{1}{4}$ inches. She was unconscious for approximately 5 minutes and had a large bruise on her forehead from sun visor-header impact.

(Case #236/7/29/67)



36

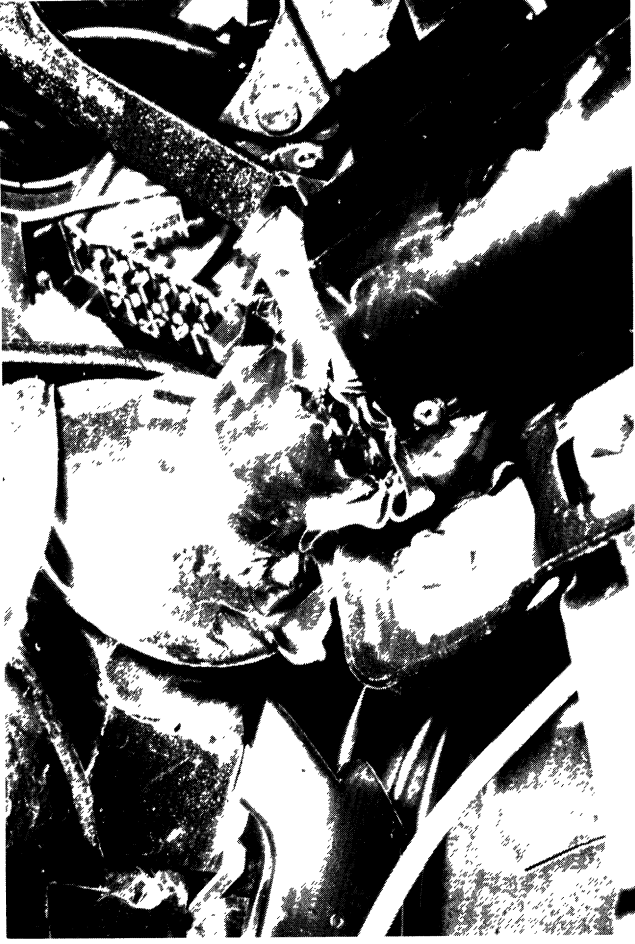1967 Camaro (Figures 37, 38, 39, and 40). On a clear afternoon on a straight road, a 20-year old male driver (5 ft, 10 in., 180 lb) swerved to avoid another vehicle headed toward him. His Camaro went off the roadway and struck a utility pole at an impact speed of 25 mph. The column compressed about 1½ inches from the impact of the occupant with the steering wheel and another 7 inches because of vehicle deformation, for a total column compression of 8½ inches. The wheel rim was bent. The lap-seat belted driver sustained forehead and nasal abrasions and right chest bruises from steering wheel impact. His lower back was sore on both sides; he had a seat-belt bruise across his lower abdominal area. Instrument panel contact produced superficial abrasions of both legs. His right ankle was sprained. (Case #UM-20-68)



37




38




40




39



41



42



43


1967 Pontiac (Figures 41, 42, and 43). This vehicle "ran out of road" and hit a clump of trees at an estimated speed of 40-45 mph. The 40-year old male driver (5 ft, 10 in., 170 lb) sustained a laceration across his forehead (steering wheel), chest bruises (steering wheel and column), and a fracture of the right leg above the ankle. He was wearing a lap seat belt. The in-car energy-absorbing mesh section compressed 8 inches. The upper half of the wheel was markedly bent forward.

(Case #247/8/25/67)

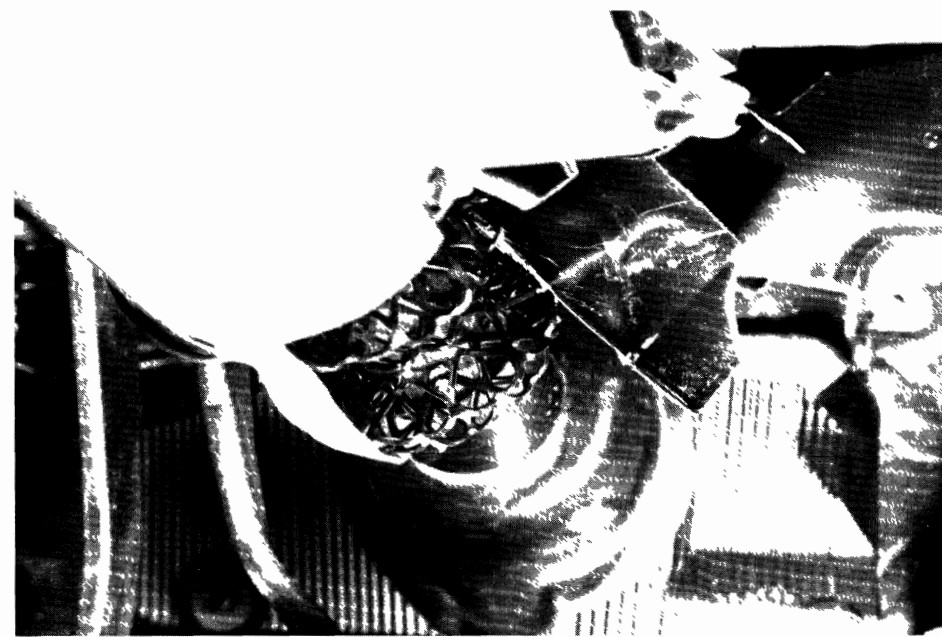
1967 Firebird (Figures 44, 45, and 46). This vehicle was struck in the front by a 1967 Oldsmobile that was sliding broadside across the centerline. The impact speed is estimated at 30 mph for both vehicles. The unrestrained driver of the Oldsmobile struck his head on the right header, side rail, and "A" pillar. He died two months later. The male driver of the Firebird (6 ft, 3 in., 170 lb) struck the steering wheel with his chest and compressed the in-car energy-absorbing column 5 inches. His chest was mildly tender. He hit the padded sun visor and dented the header and sustained a small scalp laceration from this impact. He was unconscious for about 10 minutes. Knee bruises were sustained by striking the lower instrument panel. He was wearing a lap seat belt.
(Case #234/7/13/67)



44



45




46



47

1967 Chevrolet (Figures 47, 48, and 49). This vehicle, driven by a 52-year old male, was involved in an intersection collision. The in-car energy-absorbing column compressed about 3 inches. The unrestrained driver sustained a laceration above his left eyebrow (windshield). No other injuries were reported. (Case #219/5/5/67)



48



49


1967 Pontiac GTO (Figures 50, 51, and 52). This vehicle left the roadway and struck a 32-inch diameter tree at an estimated impact speed of 45-50 mph. The 23-year old male driver (6 ft, 1 in., 150-160 lb), wearing a seat belt at the time of the accident, was killed. He compressed the in-car energy-absorbing column 6 inches. The under-hood portion of the column telescoped 8 inches. He sustained a fracture of the right fifth rib (which did not perforate the pleura) probably caused by the wheel-column impact; also, slight mediastinal hemorrhage was found. There were a few slight hemorrhagic areas in the intestinal wall due to either the seat belt or steering wheel impact. He flexed over the steering wheel and struck the instrument panel in front of, and to the left of, the steering wheel. He died of a basilar skull fracture and cerebral injury. (Case #12/8/13/67)




50



51




52



53

1967 Chevrolet (Figures 53, 54, and 55). The 19-year old male driver (5 ft, 11 in., 170 lb) lost control of this car on an expressway; the car rolled over four times in the median. The driver struck the steering column, compressing it 4 inches. No injuries were sustained from this contact. The driver was not wearing a seat belt and bounced about the interior of the car during the rollover sequence. He had chest pain, possibly from striking the steering column. He sustained a bruised left shoulder, sore posterior neck, compression fracture of L1-2 vertebrae, and a small laceration and bruise on the back of his head.

(Case #224/6/5/67)




54



55

1967 Oldsmobile F-85 (Figures 56, 57, and 58). In this car-tree impact of 45-50 mph the energy-absorbing mesh section compressed 4 inches and the underhood unit telescoped $5\frac{3}{4}$ inches. The 21-year old driver was not wearing a seat belt. He was hospitalized one day with multiple nondescript bruises and lacerations over his entire body. He did not have a chest injury from the wheel-column contact. (Case #272/10/14/67)




56



57



58



59




60




61

1967 Chevrolet (Figures 59, 60, and 61). This vehicle was involved in a head-on collision on a blind rise in the road. (See Figs. 25 and 26.) Both cars were traveling at 35-40 mph. The 24-year old male driver (5 ft, 4 in., 158 lb) was wearing a seat belt but did not have seat belt abrasions. He had a sore chest from steering wheel impact and "ached all over." The column was compressed $3\frac{3}{4}$ inches. In addition, he sustained abrasions to the face and nose (windshield), lacerations inside the mouth, a fracture of his maxilla, and a cervical sprain syndrome ("A" pillar or windshield). Both knees were bruised (lower instrument panel). He also had bruises of both arms. He was not hospitalized.
(Case #231/6/18/67)


1967 Chevrolet (Figures 62, 63, and 64). This was a head-on collision in a snow storm. The impact speed was 20-30 mph. The unrestrained male driver (6 ft, 200 lb) "ached all over," and sustained an abrasion injury of his nose from impact to the steering wheel. The mesh section of the column compressed $6\frac{1}{4}$ inches.
(Case #277/11/23/67)



62



63




64




65

1967 Camaro (Figures 65, 66, and 67). A 24-year old male driver (5 ft, 11 in., 150 lb) lost control of his car on a curve and went off the roadway. In this collision, estimated at 20 mph, the column compressed approximately 2 inches. The unrestrained driver sustained bruises to his lower ribs and a laceration to the left side of his chin (steering wheel).
(Case #279/12/16/67)




66




67


1968 Oldsmobile (Figures 68, 69, and 70). A 28-year old male driver (6 ft, 195 lb) lost control of his car on a curve, went off the road, and struck a tree at an estimated speed of 25 mph. The column compressed approximately $2\frac{3}{4}$ inches. No injuries were reported from steering column impact. The unrestrained driver sustained lacerations to his head and face from windshield contact. (Case #UM-05-68)




68



69




70



71

1968 Camaro (Figures 71, 72, and 73). On a foggy afternoon, a 1968 Camaro, driven by a 19-year old male (6 ft, 140 lb) struck an oncoming 1962 Plymouth. There was approximately a 50 percent overlap of the two cars. The driver of the Plymouth was killed by steering column impact. The energy-absorbing column in the Camaro compressed $7\frac{1}{8}$ inches from both occupant impact and vehicle frontal collapse. The steering wheel rim was bent and the column separated from the instrument panel mounts. The Camaro driver, who was not wearing a seat belt, sustained a fracture of the left twelfth rib, an abrasion to the chest, a laceration to the chin (all from steering rim impact), and knee abrasions (instrument panel impact). He had a laceration of his liver (wheel-column), but recovered after surgery. (Case #UM-14-68)



72




73

1968 Ford (Figures 74, 75, and 76). The 21-year old unrestrained driver of this vehicle struck a cement spillway after crossing an ice-covered lake at high speed. The estimated speed at impact was 25 mph. The driver sustained minor facial lacerations from impact to the windshield and rear view mirror. The column was compressed 11½ inches. No chest injuries were reported. (Case #UM-21-68)



74




75



76

1967 Toronado (Figure 77). This vehicle went out of control and struck a tree at an estimated impact speed of 15 mph. No steering-column compression was found. The 54-year old female driver (5 ft, 6½ in., 145 lb), who was not wearing a seat belt, sustained a bruise on the chin (steering wheel), a contusion of the right arm (source unknown), and a bruise beneath the left knee (lower instrument panel).

(Case #238/8/1/67)



77


Death From Steering Wheel-Column Impact



78



79



80

1967 Pontiac Firebird (Figures 78, 79, and 80). This vehicle struck a 1966 Mustang head-on, with a 40 percent left front overlap. The unrestrained 18-year old male driver of the Firebird died from multiple internal injuries. The energy-absorbing column compressed its full extent. The estimated impact speed was 40-50 mph. (Case #UM-03-68)



81


1967 Chevrolet (Figures 81 and 82). This station wagon, traveling on an expressway at a high rate of speed, hit the rear end of a tractor trailer, which was traveling at 50 mph after impact. The differential impact speed is estimated at 25 mph. The car crossed the expressway median and the opposite lanes and rotated 180 degrees to come to rest on the far shoulder of the road. The unrestrained 52-year old male driver (6 ft, 1 in., 210 lb) compressed the column a total of 1½ inches. He died 8 hours later of a laceration of the thoracic aorta; he had mediastinal hemorrhage and fractures of the right sixth and seventh ribs. These injuries are believed to have been sustained from impact with the steering wheel assembly. Facial lacerations were sustained from windshield impact.

(Case #18/11/2/67)

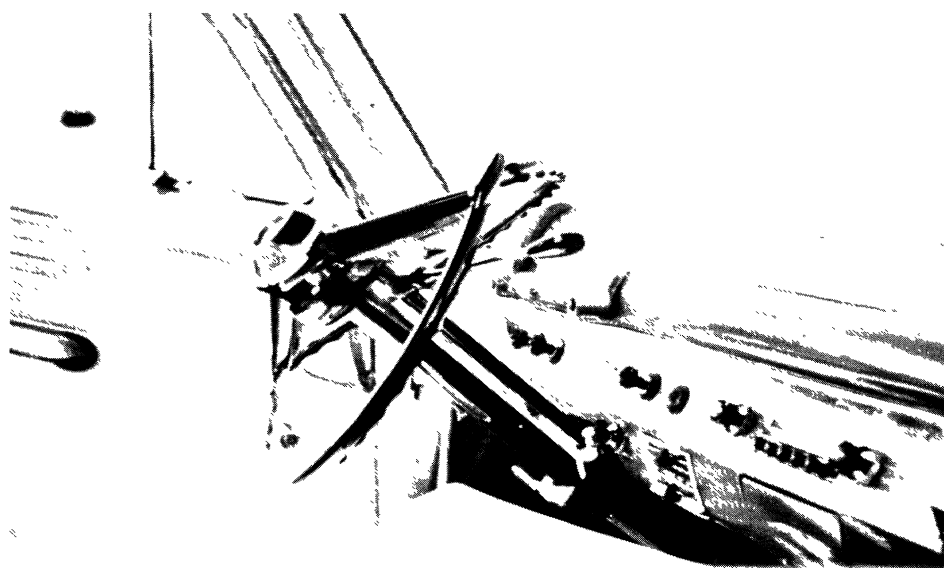


82


1954 Ford (Figures 83 and 84). This car struck an earth embankment head-on at approximately 25 mph. The 35-year old male driver impacted the steering column. He died from fractures of the chest wall, lacerations of the heart, aorta, and lungs.
(Case #5/4/16/62)



83




84




85

1956 Pontiac (Figures 85 and 86). This was a head-on collision of two vehicles of the same make, model and body style. Both drivers were unrestrained. The impact speed was approximately 35-40 mph. The 30-year old male driver (6 ft, 200 lb) of the one car died; he sustained multiple fractures of the ribs, rupture of intercostal and mediastinal blood vessels, hemothorax and hemomediastinum from wheel-column impact. The other male driver (5 ft, 7 in.) survived. He sustained multiple facial and scalp lacerations from impact to the horn ring and a fractured left femur from instrument panel impact. (Case #15/7/3/62)




86


1959 Mercury (Figures 87 and 88). This vehicle went off the road and struck a tree stump at approximately 20 mph. The 21-year old male driver (270 lb) struck the steering column and sustained rib fractures and internal thoracic injuries.
(Case #34/11/15/62)



87



88



89


1962 Ford (Figures 89 and 90). This vehicle went off the right side of the road on a curve and struck a tree at approximately 45 mph. The unrestrained 45-year old male driver sustained multiple fractures of the sternum and ribs, bilateral hemothorax, and a lacerated liver from impact to the steering wheel and column. He died four hours after the accident.

(Case #7/4/5/63)




90


1963 Oldsmobile (Figures 91 and 92). This vehicle hit the left rear dual wheels of a dump truck. The estimated speed at impact was 40 mph. The unrestrained 28-year old male driver sustained multiple internal thoracic injuries from impact to the steering wheel and spokes. He died one hour after impact.
(Case #26/6/15/64)



91


92






93

1964 Chevrolet (Figures 93 and 94). This vehicle left the roadway, went down a roadside slope, and struck a tree at an impact speed of 20-25 mph. The unrestrained 52-year old male driver sustained fractures of the fifth and seventh ribs adjacent to the sternum, a left hemothorax, and a heart injury (EKG abnormal) from steering column impact. He died two hours after the accident.
(Case #29/10/30/65)



94

1965 Chevrolet (Figures 95 and 96). This fatal head-on, car-to-car collision occurred at an estimated impact speed of 50 mph. The unrestrained 46-year old male driver (5 ft, 10 in., 210 lb) sustained multiple rib fractures, laceration of the thoracic aorta, and lacerations of the liver and mesentery with intraabdominal hemorrhage from steering wheel and column impact.
(Case #47/12/16/66)



95


96



Facial Injuries From Striking the Steering Wheel


1965 Corvair (Figures 97 and 98). This vehicle was passing a truck when it struck a 1962 Oldsmobile in the left side at approximately 15-20 mph. The unrestrained 20-year old female driver suffered a long forehead laceration and chest pain due to impact to the steering wheel. Her left knee was bruised from lower instrument panel contact.

(Case #209/3/27/67)



97


98





99

1962 Falcon (Figures 99 and 100). This vehicle struck the rear end of a stopped car at an estimated speed of approximately 10 mph. The 22-year old female driver (5 ft, 4 in., 125 lb) was wearing a seat belt; she sustained a laceration of the nose from contact with the steering wheel. No other injuries were recorded.
(Case #195/1/22/67)




100

1964 Buick (Figures 101 and 102). This vehicle went through a “T” intersection and up an embankment, hitting a tree at an estimated impact speed of 20 mph. The unrestrained 48-year old male driver fractured his nose when he hit the steering wheel, or possibly the windshield. He also had a knee abrasion (lower instrument panel). (Case #188/1/6/67)



101


102





103

1966 Mustang (Figures 103 and 104). This was an intersection collision. The vehicle, driven by an unrestrained 24-year old male, struck a 1964 school bus which made a left hand turn in front of the Mustang. The driver of the Mustang sustained a 1-inch laceration of his left scalp and a 1-inch laceration of his right eyebrow when he struck the steering wheel. Also, he had contusions and abrasions to the left knee (lower instrument panel).
(Case #269/11/1/67)




104

1965 Mustang (Figures 105 and 106). This vehicle went out of control on a curve, crossed over a curb, and struck a concrete stairway at approximately 15 mph. The unrestrained 25-year old male driver sustained a laceration to his lower lip and tongue and a bite wound of the tongue from contact with the steering wheel.
(Case #221/5/13/67)



105


106





107

1965 Pontiac (Figures 107 and 108). This vehicle drove through a stop sign and across a “T” intersection, hitting a small sign and traveling on into a field. The unrestrained 27-year old male driver (6 ft, 4 in., 215 lb) sustained a severely lacerated nose from impact to the steering wheel.
(Case #265/9/28/67)



108

