



# Clonal T-cell large granular lymphocyte proliferations in childhood and young adult immune dysregulation conditions

Süreyya Savaşan<sup>1,2</sup>  | Batool Al-Qanber<sup>1</sup>  | Steven Buck<sup>1</sup> | Erin Wakeling<sup>3</sup> | Manisha Gadgeel<sup>1</sup> 

<sup>1</sup>Division of Hematology/Oncology, Hematology/Oncology Flow Cytometry Laboratory, Children's Hospital of Michigan, Detroit, Michigan

<sup>2</sup>Pediatric Blood and Marrow Transplant Program, Children's Hospital of Michigan, Carman and Ann Adams Department of Pediatrics, Karmanos Cancer Center, Wayne State University School of Medicine, Detroit, Michigan

<sup>3</sup>Molecular Genetics Laboratory, Detroit Medical Center University Laboratories, Detroit, Michigan

## Correspondence

Süreyya Savaşan, Division of Hematology/Oncology, Hematology/Oncology Flow Cytometry Laboratory, Children's Hospital of Michigan, 3901 Beaubien Boulevard, Detroit, MI 48201.

Email: ssavasan@med.wayne.edu

## Funding information

Children's Hospital of Michigan Foundation

## Abstract

**Background:** Proliferation of large granular lymphocytes (LGL) and T-cell LGL (T-LGL) in peripheral blood along with demonstration of clonality are the hallmarks of a heterogeneous group of disorders, including T-LGL leukemia or T-LGL lymphocytosis. They are often associated with neutropenia and responsive to immunosuppression. The true nature of this entity is not well understood. Some cases are reported as reactive phenomena with very limited experience in pediatric population.

**Methods:** Hematology/Oncology Flow Cytometry Laboratory database has been reviewed retrospectively. Patients with identifiable distinct CD5-dim T-cell population and positive clonal T-cell receptor rearrangement were included in the analysis. Clinical and laboratory data were then reviewed.

**Results:** Sixteen cases of children and young adults with increased peripheral blood clonal T-LGL population characterized by dim CD5 expression with wide range of underlying immune dysregulation/stimulation disorders were reviewed. Extended follow up with repeat testing suggested the reactive nature of persistent clonal T-LGL proliferations in this group.

**Conclusions:** Our observations indicate that clonal T-LGL proliferations in children and young adults are reactive in nature and some can be persistent with an indolent course with unknown consequentiality. Clonal T-LGL cells could be targeting the most prominent immunogenic stressor(s) involved as a control mechanism.

## KEYWORDS

childhood, clonal, immune dysregulation, T-cell large granular lymphocyte proliferation

## 1 | INTRODUCTION

Clonal T-cell large granular lymphocyte (T-LGL) proliferations, also named as T-LGL leukemia or T-LGL lymphocytosis, are a heterogeneous group of disorders characterized by the presence of clonal T-LGL cells for more than 6 months, and usually but not always, a population size of minimum  $2 \times 10^9/L$  in peripheral blood (PB). Clinically, such patients frequently have immune-mediated cytopenias, particularly neutropenia in addition to increase in T-LGL cells with a clonal pattern

in PB.<sup>1</sup> Proliferating T-LGL cells are characterized by CD3, CD5-dim, predominantly CD8, and T-cell receptor (TCR)- $\alpha\beta$  expression on flow cytometry. Various T-LGL proliferations have been described in aplastic anemia, pure red cell aplasia, celiac disease, hypoplastic myelodysplastic syndrome, paroxysmal nocturnal hemoglobinuria, dasatinib therapy, lymphomas, solid organ recipients, and Felty syndrome.<sup>2-6</sup>

The pathophysiology of clonal T-LGL proliferations is yet to be explained. The distinction between reactive and malignant entities is not well defined. This proliferation, at times, was labeled as "T-cell clonopathy of undetermined significance" previously and potential unclear nature of T-LGL proliferations has been addressed recently.<sup>6,7</sup> Determination of clonality has been often seen as an indicator of a leukemic process. Thus, these cases are often

Abbreviations: CMV, cytomegalovirus; LGL, large granular lymphocyte; PB, peripheral blood; RDD, Rosai-Dorfman disease; TCR, T-cell receptor; T-LGL, T-cell LGL; UCBT, umbilical cord blood transplantation.

considered as T-LGL leukemia. Recently, acquired *STAT3* mutations are proposed as an additional evidence for malignant process in large granular lymphocyte (LGL) leukemia.<sup>8</sup> And *STAT3* mutations have been recently reported in 43% of clonal T-LGL proliferations in patients with Felty syndrome.<sup>9</sup> Successful use of immunosuppressive agents in LGL leukemia treatment without intensive chemotherapy regimens otherwise used in the treatment of various types of leukemia indicates an indolent course. The experience on this entity is much more limited in the pediatric population. In this study, we review our observations and findings in clonal T-LGL proliferations in children and young adults.

## 2 | METHODS

### 2.1 | Patients

We retrospectively reviewed Hematology/Oncology Flow Cytometry Laboratory database in an Institutional Review Board at Wayne State University approved study. Cases with the presence of identifiable separate CD5-dim T-cell populations in conjunction with positive clonal TCR rearrangement patterns were included in the analysis. In the majority of the cases, flow cytometric determination of increased CD5-dim T-cell expansion preceded the first TCR rearrangement testing. Many patients have had repeated flow cytometric analysis and TCR rearrangement testing, while four patients had just one TCR rearrangement testing. Clinical histories, complete blood count, TCR rearrangement, and lymphocyte subset analysis results were reviewed.

### 2.2 | Flow cytometric analysis and PB lymphocyte morphology

Mononuclear cells from heparinized PB samples were obtained by density gradient separation using Fico/Lite-LymphoH (Atlanta Biologicals), washed in complete medium (RPMI1640 + 10% fetal bovine serum + gentamycin) and re-suspended in phosphate-buffered saline (PBS) + 30% adult bovine serum as a blocking agent for nonspecific staining of immunoglobulins. Surface markers were assessed for three-color immunophenotyping by incubating mononuclear cells for 20 min in the dark with fluorescence-conjugated monoclonal antibodies CD3-PC5, CD19-FITC, and CD5-PE, CD3-PC5, CD57-FITC, and CD8-PE (Beckman Coulter) in two tubes respectively, followed by washing in PBS and resuspension in PBS + 0.4% formaldehyde as a fixative prior to acquisition using a Coulter XL-MCL flow cytometer (Beckman Coulter) equipped with an Argon laser.

In four recent cases, 10-color immunophenotyping was performed using a Coulter Gallios flow cytometer (Beckman Coulter). Surface markers were assessed with fluorescence-conjugated monoclonal antibodies for CD3, CD4, CD5, CD8, CD16, CD19, CD45, CD56, CD57, and TCR- $\alpha\beta$ . Mature T-lymphocytes were analyzed using Boolean gating around the CD3-bright lymphocyte population. Isotype and/or FMO controls were used to assign background staining and to allow determination of percent reactivity with tested antibodies. T-LGL populations have a distinctive dim CD5-positive profile among mature T cells. A total of 57 PB flow cytometry tests obtained for clinical

indications in those 16 cases were analyzed. Wright-Giemsa-stained PB smears were prepared from ethylenediamine tetraacetic acid anticoagulated blood and reviewed under microscope for lymphocyte morphology and detection of LGLs.

### 2.3 | TCR gene rearrangement analysis

Genomic DNA isolation and T-cell clonality testing were performed at the Detroit Medical Center University Laboratories Molecular Genetics Laboratory, a CLIA-licensed and College of American Pathologist accredited laboratory (Detroit, MI). Genomic DNA was extracted from PB white blood cells with the Genra Puregene DNA isolation kit (Qiagen) according to the manufacturer's recommendations. Two hundred fifty nanograms of genomic DNA was amplified with the TCR Beta Gene Clonality Assay and TCR Gamma Gene Rearrangement Assay 2.0 ABI Fluorescence Detection kits (Invivoscribe) targeting V, D, and J regions that flank the unique hypervariable antigen-binding region 3 (CDR3) of the TCR-beta and V and J regions of the TCR-gamma gene loci, respectively, according to manufacturer's and the Euroclonality/Biomed-2 consortium recommendations. PCR products were analyzed by capillary electrophoresis using an ABI 3130xl genetic analyzer and GeneMapper v4.0 software (Applied Biosystems). A clonal pattern was defined as the presence of one or two peaks that are at least three times the height of the polyclonal background. When a clonal pattern was detected in a single multiplex PCR reaction, testing was repeated to exclude pseudo-clonality.

## 3 | RESULTS

Sixteen cases of clonal T-LGL proliferation included in this analysis had a wide spectrum of underlying conditions, three of which were in the young adult age category. Cases have been followed up to 7 years. None of the cases had neutropenia as part of their spectrum in contrast to frequent association with T-LGL leukemia in the literature. Three patients had chronic graft versus host disease (cGvHD), two Evans syndrome (ES),<sup>10</sup> and one case for each of the following conditions: common variable immunodeficiency disorder (CVID), severe combined immunodeficiency (SCID) with maternal engraftment who developed cytomegalovirus (CMV) infection following umbilical cord blood transplantation (UCBT) and later acute Epstein-Barr virus (EBV) infection,<sup>11</sup> co-existing Langerhans cell histiocytosis (LCH), and primary hemophagocytic lymphohistiocytosis (HLH),<sup>12</sup> autoimmune hemolytic anemia, chronic idiopathic thrombocytopenic purpura (cITP), Hodgkin lymphoma (HL), X-linked lymphoproliferative disorder, Rosai-Dorfman disease (RDD), acute EBV infection, acute parvovirus B19 infection, and paroxysmal nocturnal hemoglobinuria with history of treated severe aplastic anemia (Table 1). Pathophysiological processes involved in these cases included various combinations of inherited immune deficiency in four, acquired immune deficiency in five, lymphoproliferation in six, alloimmune reaction in three, autoimmune reaction in five, infection in four, inflammation in three, and malignancy in one case.

**TABLE 1** Clinical and laboratory findings in reported cases

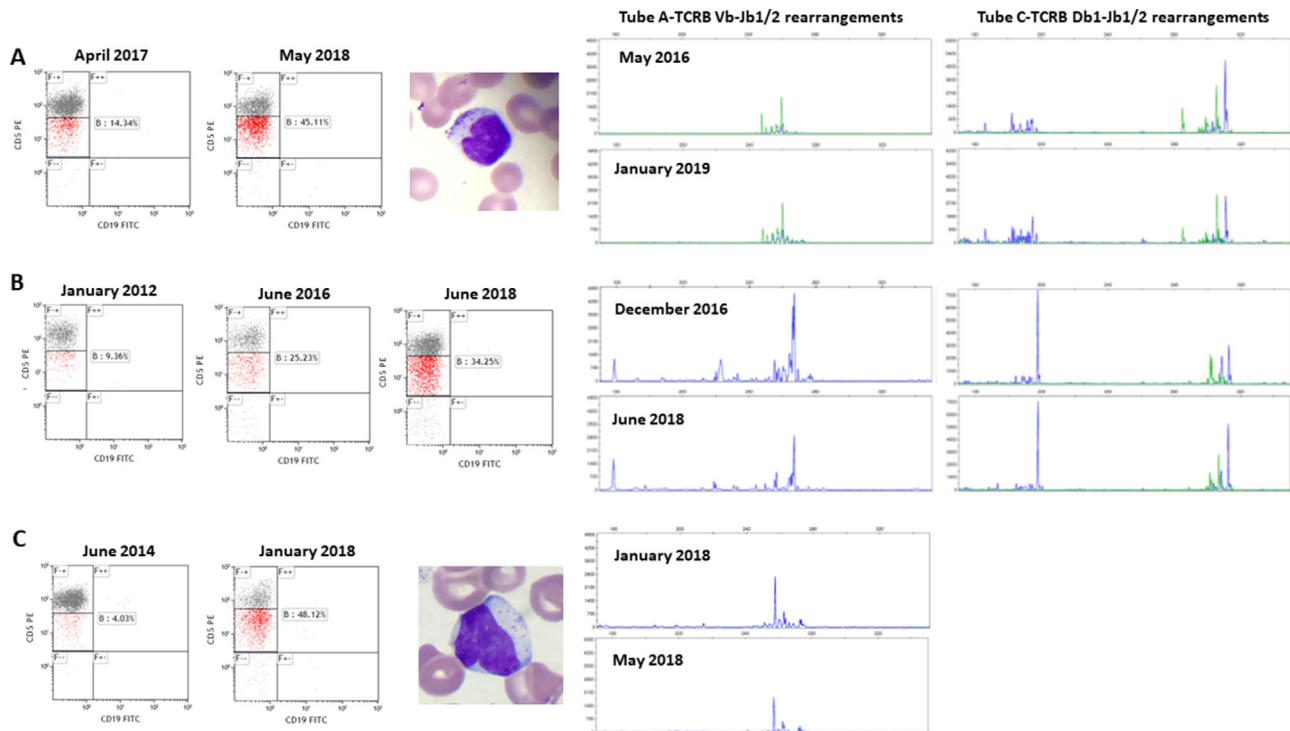
Case No.	Sex	Primary diagnosis	Process	Age-T-LGL	T-LGL (%)	PB T-LGL	T-LGL status	Age-TCR	TCR status	Treatment
1	M	CVID (TAC1 mutation)	I-ID, LP	10	10-19	0.2-0.37	0.7-I	10	Persistent	IVIg
2	F	cGvHD-BL	A-ID, ALI	20.4	26-35	0.84-0.91	1.4-F	20.4	Persistent	Steroids
3	F	SCID (JAK3 mutation)	I-ID, LP, INFEC	0.1	23 - 13	1.08-0.59	1.5-D	0.1	Persistent	UCBT, anti-CMV Tx
4	M	LCH and HLH	I-ID	1.8	22-14	0.31-0.25	7.1-D	5.5	Persistent	Chemotherapy
5	M	ES (LRBA mutation)	AI, INFLM, INFEC	10.4	18-10	0.24-0.2	4.4-F	13.9	Persistent	Steroids, anti-CMV Tx
6	M	ES	AI, LP	9.3	5-22	0.05-0.53	6.4-I	13.8	Persistent	Steroids, splenectomy
7	F	AIHA	AI	15.2	15-33	0.17-0.3	3.4-I	18.6	N/A	Steroids
8	F	cITP	AI	12.8	16-9	0.62-0.21	0.7-D	12.8	Persistent	No therapy
9	F	HL	MLGN, A-ID, INFLM	14.2	22-14	0.33-0.54	0.9-D	14.2	Persistent	Chemotherapy
10	M	XLP	I-ID, LP	28	59	1.93	N/A	28	N/A	IVIg
11	M	RDD	LP, INFLM	1.6	6-24	0.26-0.38	3.6-I	5.2	Persistent	Steroids
12	F	cGvHD-GT	A-ID, ALI	5.1	10-11	0.29-0.4	0.4-I	5.1	Persistent	Steroids
13	F	IM (EBV infection)	A-ID, INFEC, LP	14.7	18-19	0.57-0.52	0.2-S	14.7	Resolved	No therapy
14	M	cGvHD, SAA	A-ID, ALI	10.8	11-24	0.11-0.32	1.1-I	11.9	Persistent	Steroids, tacrolimus
15	M	PB19-erythroid aplasia	INFEC	15.2	9	0.15	N/A	15.2	N/A	Blood transfusions
16	F	PNH, SAA	AI	22.9	19	0.44	N/A	22.9	N/A	Eculizumab

Abbreviations: Age-TCR, age at first TCR gene rearrangement study; Age-T-LGL, age at T-LGL proliferation diagnosis in years; AI, autoimmunity; A-ID, acquired immune deficiency; AIHA, autoimmune hemolytic anemia; ALI, allo immunization; BL, Burkitt lymphoma; cGvHD, chronic graft versus host disease; cITP, chronic idiopathic thrombocytopenic purpura; CVID, common variable immune deficiency disorder; D, decreasing; EBV, Epstein-Barr virus; ES, Evans syndrome; F, female; F, fluctuating; GT, Glanzmann thrombasthenia; HL, Hodgkin lymphoma; I-ID, inherited immune deficiency; I, increasing; IM, infectious mononucleosis; INFEC, infection; INFLM, inflammation; IVIG, intravenous immunoglobulin; LCH, Langerhans cell histiocytosis; LP, lymphoproliferation; M, male; MLGN, malignancy; S, stable; SCID, severe combined immunodeficiency; PB19, parvovirus B19; PB T-LGL, peripheral blood T-LGL count ( $\times 10^9/L$ ) at diagnosis and last follow up; pHLH, primary hemophagocytic lymphohistiocytosis; PNH, paroxysmal nocturnal hemoglobinuria; Process, processes involved in the disorder pathogenesis; RDD, Rosai-Dorfman disease; SAA, severe aplastic anemia; TAC1, transmembrane activator and CAML interactor; TCR status, status of the TCR clonotype at the last testing; T-LGL (%), percent of T-LGL (CD5-dim T cells) among peripheral blood lymphocytes by flow cytometry at diagnosis and last follow up; T-LGL status, duration of T-LGL presence (in years), current status of the T-LGL proliferation by T-LGL percent; Tx, therapy; XLP, X-linked lymphoproliferative disorder.

One patient (case #3) with SCID had three different clonal peaks at different times in association with maternal engraftment, CMV infection following UCBT, and during an acute EBV infection after immune suppression withdrawal, respectively.<sup>11</sup> The patient with RDD (case #11) developed clonal T-LGL expansion when his disease flared. In three instances in two patients, clonal T-LGL proliferations disappeared with the resolution of underlying disease, acute EBV infection in case #13, maternal engraftment and CMV infection in case #3, respectively. However, the T-LGL clones persisted and were frequently associated with relative increased presence over time, if the disease process continued to be active or progressed, despite the use of therapeutic approaches including several lines of either single or combined immunosuppressive medications (Figure 1). In summary, three clonal T-LGL proliferations in two patients have resolved, were persistent in

nine with the original TCR rearrangement pattern, and four cases have not been reevaluated (Tables 1 and 2).

Among the cases with persistent clonal T-LGL proliferation lasting longer than 6 months, three patients, cases #3, #12, and #14, had active cGvHD following allogeneic hematopoietic stem cell transplantation. They were on various immunosuppressive treatment regimens and had persistent clonal T-LGL proliferations lasting 23, 18, and 21 months, respectively. Cases #5 and #6 with Evans syndrome have been followed for several years and have been on various immune suppressive regimens throughout their course and had clonal T-LGL lasting 26 and 24 months, respectively. Case #1 was referred to us for splenomegaly and was found to have panhypogammaglobulinemia and diagnosed with CVID and further investigation revealed double heterozygous *TAC1* mutation as the cause. A repeat set of tests



**FIGURE 1** Three representative cases. Flow cytometric analysis was made on the CD3-positive gated lymphocytes. A, Case #14 had significant worsening of chronic graft-versus-host disease, (B) case #6 has been treated for active Evans syndrome using several different modalities over the years, and (C) case #11 had a flare of Rosai-Dorfman disease. Giemsa-stained peripheral blood smears showed several large granular lymphocytes. All showed clonal T-cell receptor gene rearrangements (data shown are the GeneScan results of the  $V\beta$ - $J\beta$ 1/2 and  $D\beta$ 1- $J\beta$ 1/2 gene rearrangements detected with the Euroclonality/BIOMED-2 TCRB tube A and tube C, respectively)

in 8 months demonstrated continued clonal T-LGL proliferation while on intravenous immunoglobulin supplementation. Case #4 was diagnosed with concurrent primary HLH and LCH when the patient presented with fever, hepatosplenomegaly, and cytopenias and responded to chemotherapy directed to LCH. Studies performed following completion of treatment revealed clonal T-LGL proliferation, which has lasted for 56 months.

Case #8 with cITP on immunosuppressive treatment was tested twice 9 months apart with positive clonal T-LGL proliferation. Case #9 had HL and underwent successful chemotherapy and continued to have clonal T-LGL proliferation for 11 months. None of our patients had T-LGL populations greater than  $2 \times 10^9/L$ , which is debated not be a pre-requisite for diagnosis of T-LGL leukemia, despite significant percent presence in the lymphocyte population. This could be partially due to clinical symptoms, such as splenomegaly and/or treatment of the underlying disease with steroids or chemotherapy leading to lymphopenia.

The size of the CD5-dim T-cell population was variable with a median value of 18.6% and as high as 58.7% of the lymphocyte population. Presence of T-LGL population has positively correlated with CD8, CD57, and inversely with CD19 expression (all  $P = 0.001$ ). Furthermore, 10-color analysis of CD5dim+ T-cell population performed on Gallios Flow Cytometer showed predominance of CD8, TCR- $\alpha\beta$ , and CD57-positive subsets with an average of 69.6% (51.5-78.8) CD8-positive, 79.6% (60.3-94.1) TCR- $\alpha\beta$ -positive, and 45.5%

(10.8-60.6) CD8/CD57 double-positive cells, whereas CD4-positive cells constituted 13% (2.8-23.1) and CD56/CD16 double-positive cells constituted 4.1% (1.1-5.9) in four cases studied (Figure 2).

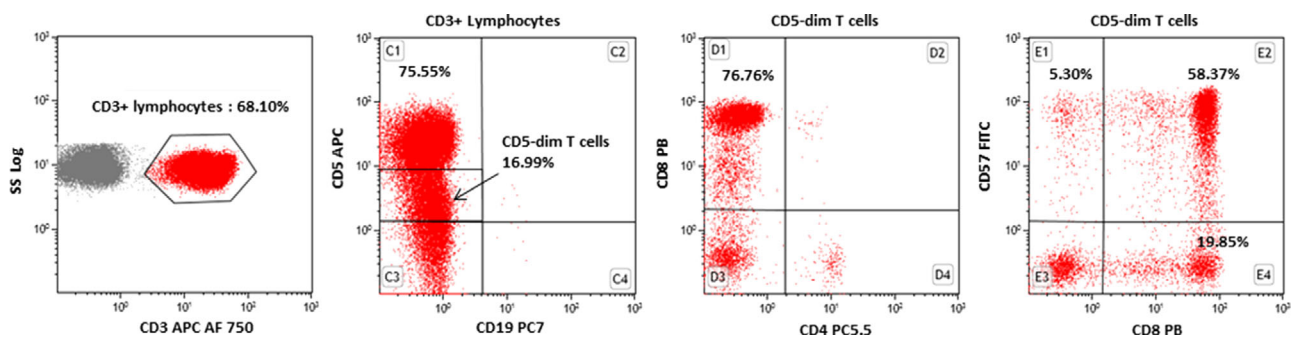
## 4 | DISCUSSION

There have been many reported cases of T-LGL leukemia associated with underlying autoimmune disorders, malignancy, bone marrow failure, solid organ transplantation, or use of certain drugs.<sup>2-6,13</sup> In general, it is reported to be an indolent type of leukemia and the therapies utilized consist of immunosuppressive drugs that target the associated disorder as well. Two main methods were used to determine clonality in T-LGL leukemia cases: TCR gene rearrangement analysis or flow cytometric TCR variable beta chain study with comparable results.<sup>14</sup> Whether all cases with increased population of PB T cells with T-LGL phenotype by flow cytometry along with determination of clonality by either method should be called as T-LGL leukemia remains a question. The required duration of the presence of clonal cells longer than 6 months and the number of circulating clonal cells, which is debated as a requirement at this time, may not be sufficient to determine the fine line between T-LGL leukemia cases and nonleukemia proliferations in our opinion. It is not clear whether neutropenia is secondary to clonal T-LGL cells. Nevertheless, mortality does not appear to be directly related to the presence of these

**TABLE 2** T-cell clonality evaluations in reported cases

Case No.	Primary diagnosis	Age-TCR	No. of TCR tests (done over months)	TCRB clonal rearrangements	TCRG clonal rearrangements
1	CVID (TACI mutation)	10	2 (8)	V $\beta$ -J $\beta$ 2	Polyclonal
2	cGvHD-BL	20.4	4 (23)	D $\beta$ 2-J $\beta$ 2	Polyclonal
3	SCID (JAK3 mutation)	0.1	12 (27)	Various V $\beta$ 1-J $\beta$ 1/2 and D $\beta$ 1/2-J $\beta$ 1/2	V $\gamma$ -J $\beta$ (once)
4	LCH and HLH	5.5	13 (56)	V $\beta$ -J $\beta$ 1, D $\beta$ 2-J $\beta$ 2, D $\beta$ 1-J $\beta$ 2	Polyclonal
5	ES (LRBA mutation)	13.9	5 (26)	V $\beta$ -J $\beta$ 2, D $\beta$ 2-J $\beta$ 2	Polyclonal
6	ES	13.8	3 (24)	V $\beta$ -J $\beta$ 1, D $\beta$ 2-J $\beta$ 2	Polyclonal
7	AIHA	18.6	1	D $\beta$ 2-J $\beta$ 2	V $\gamma$ -J $\beta$
8	cITP	12.8	2 (9)	D $\beta$ 1-J $\beta$ 2	Polyclonal
9	HL	14.2	3 (11)	V $\beta$ -J $\beta$ 2, D $\beta$ 1-J $\beta$ 2	Polyclonal
10	XLP	28	1	V $\beta$ -J $\beta$ 2, D $\beta$ 1-J $\beta$ 2	V $\gamma$ -J $\beta$
11	RDD	5.2	2 (4)	V $\beta$ -J $\beta$ 2	Polyclonal
12	cGvHD-GT	5.1	4 (18)	V $\beta$ -J $\beta$ 1, D $\beta$ 2-J $\beta$ 2	Polyclonal
13	IM (EBV infection)	14.7	2 (3)	V $\beta$ -J $\beta$ 1/2	Polyclonal
14	cGvHD, SAA	11.9	4 (21)	V $\beta$ -J $\beta$ 1, D $\beta$ 1-J $\beta$ 1, D $\beta$ 1-J $\beta$ 2	Polyclonal
15	PB19-erythroid aplasia	15.2	1	V $\beta$ -J $\beta$ 2	Polyclonal
16	PNH, SAA	22.9	1	V $\beta$ -J $\beta$ 2, D $\beta$ 1/2-J $\beta$ 1/2	Polyclonal

Abbreviations: Age-TCR, age at first T-cell receptor (TCR) gene rearrangement study in years; AIHA, autoimmune hemolytic anemia; BL, Burkitt lymphoma; cGvHD, chronic graft versus host disease; cITP, chronic idiopathic thrombocytopenic purpura; CVID, common variable immune deficiency disorder; EBV, Epstein-Barr virus; ES, Evans syndrome; F, female; GT, Glanzmann thrombasthenia; HL, Hodgkin lymphoma; M, male; IM, infectious mononucleosis; LCH, Langerhans cell histiocytosis; PB19, parvovirus B19; pHLH, primary hemophagocytic lymphohistiocytosis; PNH, paroxysmal nocturnal hemoglobinuria; RDD, Rosai-Dorfman disease; SAA, severe aplastic anemia; SCID, severe combined immunodeficiency; TACI, transmembrane activator and CAML interactor; TCRB, TCR-beta chain gene; TCRG, TCR-gamma chain gene; #TCR tests, number of TCR tests (time between the first and the last TCR tests in months); XLP: X-linked lymphoproliferative disorder.

**FIGURE 2** 10-color flow cytometric analysis of a representative case showing CD8 and CD57 staining patterns within CD5dim T cell gate, representing T-LGL population

cells.<sup>15</sup> It may be solely semantics, but not all clonal proliferations are malignant in nature, like LCH that is frequently associated with *BRAF* mutations, which is currently defined just as a neoplastic disorder.

The true mechanism of clonal T-LGL development, their target(s), and potential role(s) remain largely unknown. The real incidence may be much higher in individuals with dysregulated immune system, if routinely examined. The development of clonal T-LGL expansions in a certain group of patients with immune dysregulation or stimulation conditions, but not in all, and the existence of nonclonal T-LGL proliferations in some need further investigation. Progression in long-standing clonal T-LGL proliferations through gaining new and/or additional mutations

is a possibility. In this regard, presence of *STAT3* mutations may be taken as an indicator for progressive neoplastic state, since 43% of cases with Felty syndrome were found to have this mutation.<sup>9</sup> The question stands whether the remainder of those cases without *STAT3* mutations represent a more indolent neoplastic disease course.

The great majority of T-LGL leukemia/proliferation cases are in the adult population, less than 3% seen in individuals younger than 25 years of age with very rare reporting in children.<sup>15-17</sup> The series presented here provides additional details to this rather uncommon entity due to close and lengthy follow-up in a predominantly pediatric population. None of the cases in our series had neutropenia, which



is reported in 50% of the patients with T-LGL leukemia. The use of immunosuppression has been associated with a relative increase in the CD5-dim T-cell population size despite decreases in both absolute lymphocyte count and in T and B subset values in patients with active underlying disease, which may indicate relative resilience of these cells along with continuing immunogenic stimulation. Thus, clonal expansion of T-LGL appears to be a dynamic process in our cases reflecting the activity of the underlying disease process, including alone or a combination of immunodeficiency, autoimmune and alloimmune reactions, infection, inflammation, lymphoproliferation, and malignancy. As nicely exemplified in the severe combined immunodeficiency case, three separate clonal T-LGL proliferations were associated with maternal engraftment, CMV infection following UCBT, and acute EBV infection, respectively.<sup>11</sup>

In conclusion, the great majority of clonal T-LGL proliferations in young people are likely to be reactive in nature, associated with an existing inherited or acquired, persistent or temporary immune dysregulation or stimulation state and some may be persistent, longer than 6 months as observed in nine cases reported here. Our observations emphasize that such proliferations can be seen in children and broaden the spectrum of underlying associated conditions. Whether the treatment strategy should be modified and the expected clinical course or outcome would be affected due to presence of clonal T-LGL proliferations in young patients remain unknown. We agree with the theory that clonal T-LGL proliferations could be targeting the most prominent immunogenic stressor(s) involved as an effort by the immune system to control the process. Studies investigating the function of clonal T-LGL and their potential role in the various disease processes are underway.

## ACKNOWLEDGMENTS

This study was partially supported by funds from Children's Hospital of Michigan Foundation. Some of the findings included in this report were presented at the American Society of Hematology 2018 Annual meeting in San Diego, CA.

## CONFLICT OF INTEREST

The authors declare that there is no conflict of interest.

## ORCID

Süreyya Savaşan  <https://orcid.org/0000-0001-7138-3027>

Batool Al-Qanber  <https://orcid.org/0000-0003-0828-2471>

Manisha Gadgeel  <https://orcid.org/0000-0001-8366-9487>

## REFERENCES

- Lamy T, Moignet A. LGL leukemia: from pathogenesis to treatment. *Blood*. 2017;129(9):1082-1094.
- Sabnani I, Zucker MJ, Tsang P, Palekar S. Clonal T-large granular lymphocyte proliferation in solid organ transplant recipients. *Transplant Proc*. 2006;38(10):3437-3440.
- Prochorec-Sobieszek M, Rymkiewicz G, Makuch-Łasica H, et al. Characteristics of T-cell large granular lymphocyte proliferations associated with neutropenia and inflammatory arthropathy. *Arthritis Res Ther*. 2008;10(3):R55.
- Mustjoki S, Ekblom M, Arstila TP, et al. Clonal expansion of T/NK-cells during tyrosine kinase inhibitor dasatinib therapy. *Leukemia*. 2009;23(8):1398-1405.
- Goyal T, Thakral B, Wang SA, et al. T-cell large granular lymphocytic leukemia and coexisting B-cell lymphomas: a study from the Bone Marrow Pathology Group. *Am J Clin Pathol*. 2018;149(2):164-171.
- Langerak AW, Assmann JLC. Large granular lymphocyte cells and immune dysregulation diseases—the chicken or the egg. *Haematologica*. 2018;103(2):193-194.
- Dhodapkar MV, Li CY, Lust JA, Tefferi A, Phyllyk RL. Clinical spectrum of clonal proliferations of T-large granular lymphocytes: a T-cell clonopathy of undetermined significance. *Blood*. 1994;84(5):1620-1627.
- Andersson E, Kuusanmäki H, Bortoluzzi S, et al. Activating somatic mutations outside the SH2-domain of STAT3 in LGL leukemia. *Leukemia*. 2016;30(5):1204-1208.
- Savola P, Brück O, Olson T, et al. Somatic STAT3 mutations in Felty syndrome: an implication for a common pathogenesis with large granular lymphocyte leukemia. *Haematologica*. 2018;103(2):304-312.
- Rajpurkar M, Buck S, Lafferty J, Wakeling E, Ravindranath Y, Savaşan S. Acquired pure red cell aplasia and acquired amegakaryocytic thrombocytopenia associated with clonal expansion of T-cell large granular lymphocytes in a patient with lipopolysaccharide-responsive beige-like anchor (LRBA) protein deficiency. *J Pediatr Hematol Oncol*. 2019;41(8):e542-e545.
- Savaşan S, Wakeling E, Knight T, Buck S, Gadgeel M. Different clonal T-large granular lymphocyte proliferations in SCID. *J Clin Immunol*. 2019;39(3):245-248.
- Savaşan S, Poulik J, Gabali A. Langerhans cell histiocytosis and primary hemophagocytic lymphohistiocytosis with persistent clonal T-large granular lymphocyte proliferation. *Ann Hematol*. 2018;97(7):1295-1296.
- Moignet A, Lamy T. Latest advances in the diagnosis and treatment of large granular lymphocytic leukemia. *Am Soc Clin Oncol Educ Book*. 2018;38:616-625.
- Hsieh YC, Chang ST, Huang WT, Kuo SY, Chiang TA, Chuang SS. A comparative study of flow cytometric T cell receptor V $\beta$  repertoire and T cell receptor gene rearrangement in the diagnosis of large granular lymphocytic lymphoproliferation. *Int J Lab Hematol*. 2013;35:501-509.
- Swerdlow SH, Campo E, Harris NL, et al. WHO Classification of Tumours of Haematopoietic and Lymphoid Tissues. World Health Organization Classification of Tumours. Lyon, France: IARC; 2017.
- Boeckx N, Uyttebroeck A, Langerak AW, Brusselmans C, Goossens W, Bossuyt X. Clonal proliferation of T-cell large granular lymphocytes. *Pediatr Blood Cancer*. 2004;42(3):275-277.
- Kondoh K, Morimoto M, Keino D, et al. T-cell large granular lymphocyte leukemia in a child with anemia and Crohn's disease. *Pediatr Int*. 2013;55(1):111-114.

**How to cite this article:** Savaşan S, Al-Qanber B, Buck S, Wakeling E, Gadgeel M. Clonal T-cell large granular lymphocyte proliferations in childhood and young adult immune dysregulation conditions. *Pediatr Blood Cancer*. 2020;67:e28231. <https://doi.org/10.1002/pbc.28231>