



## ORIGINAL ARTICLE

# GARS-related disease in infantile spinal muscular atrophy: Implications for diagnosis and treatment

Rebecca Markovitz<sup>1</sup> | Rajarshi Ghosh<sup>1</sup>  | Molly E. Kuo<sup>2,3</sup> | William Hong<sup>1,12,13</sup> | Jaehyung Lim<sup>1,12,13</sup> | Saunder Bernes<sup>4</sup> | Stephanie Manberg<sup>4</sup> | Kathleen Crosby<sup>5</sup> | Pranoot Tanpaiboon<sup>5</sup> | Diana Bharucha-Goebel<sup>8,9</sup> | Carsten Bonnemann<sup>8,9</sup> | Carrie A. Mohila<sup>6,7</sup> | Elizabeth Mizerik<sup>1,13</sup> | Suzanne Woodbury<sup>13,14</sup> | Weimin Bi<sup>1</sup>  | Timothy Lotze<sup>12,13</sup> | Anthony Antonellis<sup>2,10,11</sup> | Rui Xiao<sup>1</sup> | Lorraine Potocki<sup>1,13</sup>

<sup>1</sup>Department of Molecular and Human Genetics, Baylor College of Medicine, Houston, Texas

<sup>2</sup>Cellular and Molecular Biology Program, University of Michigan, Ann Arbor, Michigan

<sup>3</sup>Medical Scientist Training Program, University of Michigan, Ann Arbor, Michigan

<sup>4</sup>Division of Child Neurology, Barrow Neurological Institute, Phoenix Children's Hospital, Phoenix, Arizona

<sup>5</sup>Division of Genetics and Metabolism, Children's National Hospital, Rare Disease Institute, Washington, District of Columbia

<sup>6</sup>Department of Pathology, Texas Children's Hospital, Houston, Texas

<sup>7</sup>Department of Pathology and Immunology, Baylor College of Medicine, Houston, Texas

<sup>8</sup>Division of Neurology, Children's National Hospital, Washington, District of Columbia

<sup>9</sup>Neuromuscular and Neurogenetic Disorders of Childhood Section, NINDS, National Institutes of Health, Bethesda, Maryland

<sup>10</sup>Department of Human Genetics, University of Michigan, Ann Arbor, Michigan

<sup>11</sup>Department of Neurology, University of Michigan, Ann Arbor, Michigan

<sup>12</sup>Department of Pediatrics, Division of Neurology and Developmental Neuroscience, Baylor College of Medicine, Houston, Texas

<sup>13</sup>Texas Children's Hospital, Houston, Texas

<sup>14</sup>Baylor College of Medicine, Department of Physical Medicine and Rehabilitation, Houston, Texas

**Correspondence**

Lorraine Potocki, Department of Molecular and Human Genetics, Baylor College of Medicine, Texas Children's Hospital, 6701 Fannin Street, Suite 1560, Houston, TX 77030, United States.  
Email: lpotocki@bcm.edu

**Funding information**

National Institute of General Medical Sciences, Grant/Award Number: GM118647; National Institute of Neurological Disorders and Stroke, Grant/Award Number: NS113515; NIH Cellular and Molecular Biology Training Grant, Grant/Award Number: GM007315; NIH Medical Scientist Training Program Training Grant, Grant/Award Number: GM007863

**Abstract**

The majority of patients with spinal muscular atrophy (SMA) identified to date harbor a biallelic exonic deletion of *SMN1*. However, there have been reports of SMA-like disorders that are independent of *SMN1*, including those due to pathogenic variants in the glycyl-tRNA synthetase gene (*GARS1*). We report three unrelated patients with *de novo* variants in *GARS1* that are associated with infantile-onset SMA (iSMA). Patients were ascertained during inpatient hospital evaluations for complications of neuropathy. Evaluations were completed as indicated for clinical care and management and informed consent for publication was obtained. One newly identified, disease-associated *GARS1* variant, identified in two out of three patients, was analyzed by functional studies in yeast complementation assays. Genomic analyses by exome and/or gene panel and *SMN1* copy number analysis of three patients identified two previously undescribed *de novo* missense variants in *GARS1* and excluded

*SMN1* as the causative gene. Functional studies in yeast revealed that one of the *de novo* *GARS1* variants results in a loss-of-function effect, consistent with other pathogenic *GARS1* alleles. In sum, the patients' clinical presentation, assessments of previously identified *GARS1* variants and functional assays in yeast suggest that the *GARS1* variants described here cause iSMA. *GARS1* variants have been previously associated with Charcot–Marie–Tooth disease (CMT2D) and distal SMA type V (dSMAV). Our findings expand the allelic heterogeneity of *GARS*-associated disease and support that severe early-onset SMA can be caused by variants in this gene. Distinguishing the SMA phenotype caused by *SMN1* variants from that due to pathogenic variants in other genes such as *GARS1* significantly alters approaches to treatment.

#### KEYWORDS

clinical genetics, CMT, *GARS*, hereditary motor and sensory neuropathy, non-*SMN1* SMA

## 1 | INTRODUCTION

Spinal muscular atrophy (SMA) and Charcot–Marie–Tooth (CMT) disease are hereditary neuromuscular disorders that lead to progressive weakness and muscle wasting. CMT disease refers to a group of disorders characterized by a progressive chronic motor and sensory polyneuropathy. CMT2, specifically Charcot–Marie–Tooth disease 2D (CMT2D), is the sub-type associated with variants in the glycyl-RNA synthetase gene, *GARS1* (also referred to as *GARS*, which we use throughout the manuscript). CMT2D typically presents with muscle weakness of the hands, characterized by distal motor and sensory neuropathy.

The SMA group of disorders are typically characterized by symmetric proximal muscle weakness and atrophy resulting from progressive degeneration and loss of anterior horn cells in the spinal cord and the brain stem nuclei. The first SMA patients (Russman, 2007) were diagnosed based on clinical and histopathological features. Unified inclusion criteria for SMA were developed by the International SMA Consortium (Munsat, 1991). Patients were stratified by severity based on criteria including clinical features, age of onset and age at death (Drew, Blair, & Nicholson, 2011).

In contrast to the extreme allelic and locus heterogeneity observed in CMT (Timmerman, Strickland, & Züchner, 2014), the vast majority of patients with SMA harbor a biallelic exonic deletion of *SMN1* mapping to the long arm of chromosome 5. There has been increasing appreciation of non-*SMN1* forms of SMA since the initial reports where it has been estimated that about 5% of SMA patients have a genetic etiology other than *SMN1* (Wirth et al., 1999). Over 15 loci have been associated with clinical presentations that mimic *SMN1*-related SMA. These non-*SMN1* SMAs are sometimes referred to as non-5q SMA and typically affect the proximal muscles. On the severe end of the spectrum within the non-5q SMA subgroup is SMA with respiratory distress (SMARD), due to biallelic pathogenic variants in *IGHMBP2* (Grohmann et al., 2001; Guenther et al., 2007). Yet

another subgroup, SMA type V distal type (dSMAV), presents with distal weakness and no sensory involvement. Both CMT2D and dSMAV are caused by heterozygosity for pathogenic variants in *GARS* gene, encoding glycyl-tRNA synthetase. In fact, recent literature suggests that dSMAV and CMT2D are on a clinical spectrum of *GARS*-associated axonal neuropathy, not distinct diseases (Antonellis, Goldfarb, & Sivakumar, 1993). In addition, multiple case reports have described patients with a pathogenic variant in *GARS* with an iSMA like phenotype (Eskuri, Stanley, Moore, & Mathews, 2012; James et al., 2006; Liao et al., 2015).

In humans, there are 37 genes encoding aminoacyl-tRNA synthetases (aaRS) (Antonellis & Green, 2008). Variants in genes encoding aaRSs have been associated with various human diseases including early onset, multi-system recessive phenotypes and dominant peripheral neuropathy (Fuchs et al., 2019; Meyer-Schuman & Antonellis, 2017). Over the past 16 years, multiple studies have associated defects in aaRS with CMT (Storkebaum, 2016) and dSMAV (Tsai et al., 2017).

The *GARS* gene was the first aaRS to be implicated in a human inherited disease (Antonellis et al., 2003, 1993). *GARS* is critical for charging glycine onto cognate tRNA molecules and is required for protein synthesis in the mitochondria and the cytosol (Chihara, Luginbuhl, & Luo, 2007; Qin et al., 2014). The human *GARS* protein consists of a N-terminal WHEP-TRS domain, a catalytic domain interspersed by three insertion domains and a C-terminal anticodon-binding domain (Antonellis et al., 2003; Qin et al., 2014). The majority of patients reported with *GARS*-associated dominant neuropathy present with later onset CMT2D or dSMAV (Antonellis et al., 2003). Here we present three patients with severe, early-onset SMA. Each patient carries a *de novo* pathogenic variant in either the catalytic or anticodon binding domain of *GARS*. Analysis of these results indicates that pathogenic variants in the anticodon binding and the catalytic domains can result in an early-onset form of SMA.

## 2 | PATIENTS AND METHODS

Patients were ascertained in the course of routine clinical care provided at three institutions. Genetic testing, imaging, neurophysiology, and histopathology studies were done on a clinical basis.

Yeast complementation assays were performed as previously described (Oprescu et al., 2017). The p.Ile334Asn GARS variant was modeled in the human wild-type GARS  $\Delta$ MTS $\Delta$ WHEP open-reading frame (Chien et al., 2014; Oprescu et al., 2017). Mutagenesis was performed using the Quickchange II XL Site-Directed Mutagenesis Kit, a sequence-validated wild-type GARS  $\Delta$ MTS $\Delta$ WHEP pDONR221 construct, and mutation-specific primers (available upon request). Reactions were transformed into *Escherichia coli*, and plasmid DNA was purified from individual colonies and sequenced to confirm the presence of the mutation and the absence of PCR-induced errors. Sequence-validated constructs for wild-type and p.Ile334Asn GARS  $\Delta$ MTS $\Delta$ WHEP were cloned into pYY1 (Chien et al., 2014) using Gateway cloning technology (Invitrogen). The resulting reactions were transformed into *E. coli*, and plasmid DNA was purified from individual colonies and digested with *Bsr*GI to confirm proper recombination. To assess the ability of wild-type and p.Ile334Asn GARS  $\Delta$ MTS $\Delta$ WHEP to support cellular growth, a previously validated haploid yeast strain with the endogenous *GRS1* locus deleted and viability maintained via a pRS316 vector bearing wild-type *GRS1* (Turner, Lovato, & Schimmel, 2000) was transformed with wild-type GARS  $\Delta$ MTS $\Delta$ WHEP, p.Ile334Asn GARS  $\Delta$ MTS $\Delta$ WHEP, or the pYY1 vector with no GARS insert. Transformed yeast cells were grown on solid media lacking leucine (pYY1 harbors the *LEU2* gene) and uracil (pRS316 harbors the *URA3* gene). Colonies were grown to saturation in 2 mL -leu-ura liquid medium at 30°C and 275 rpm for 48 hr. A 1 mL aliquot from each 2 mL culture was spun down at 10,000 rpm and re-suspended in 50  $\mu$ L UltraPure RNase/DNase-free water. Undiluted cultures and dilutions of 1:10 and 1:100 were spotted on 0.1% 5-FOA complete solid medium (Teknova, Hollister, CA) to select for cells that have spontaneously lost the *URA3*-bearing maintenance vector (Boeke, Trueheart, Natsoulis, & Fink, 1987). Yeast viability was assessed by visual inspection after 5 days of incubation at 30°C. Two colonies per transformation were assayed.

## 3 | RESULTS

### 3.1 | Clinical features of patients

We identified three patients with *de novo* variants in the GARS gene that led to very early onset neuropathy with respiratory distress, mimicking iSMA. Clinical features of these patients are summarized in Table 1.

Patient 1 is a former appropriate-for-age (AGA) 40w4d male, born by spontaneous vaginal delivery to a 29-year-old Hispanic female and a 28-year-old Hispanic male. The pregnancy was notable for oligohydramnios with no associated complications. The parents were non-consanguineous and the family history was negative for

neuropathy. At birth, the patient had subtle decreased movement in his lower extremities compared to his upper extremities, but without notable hypotonia, respiratory distress, or feeding difficulties.

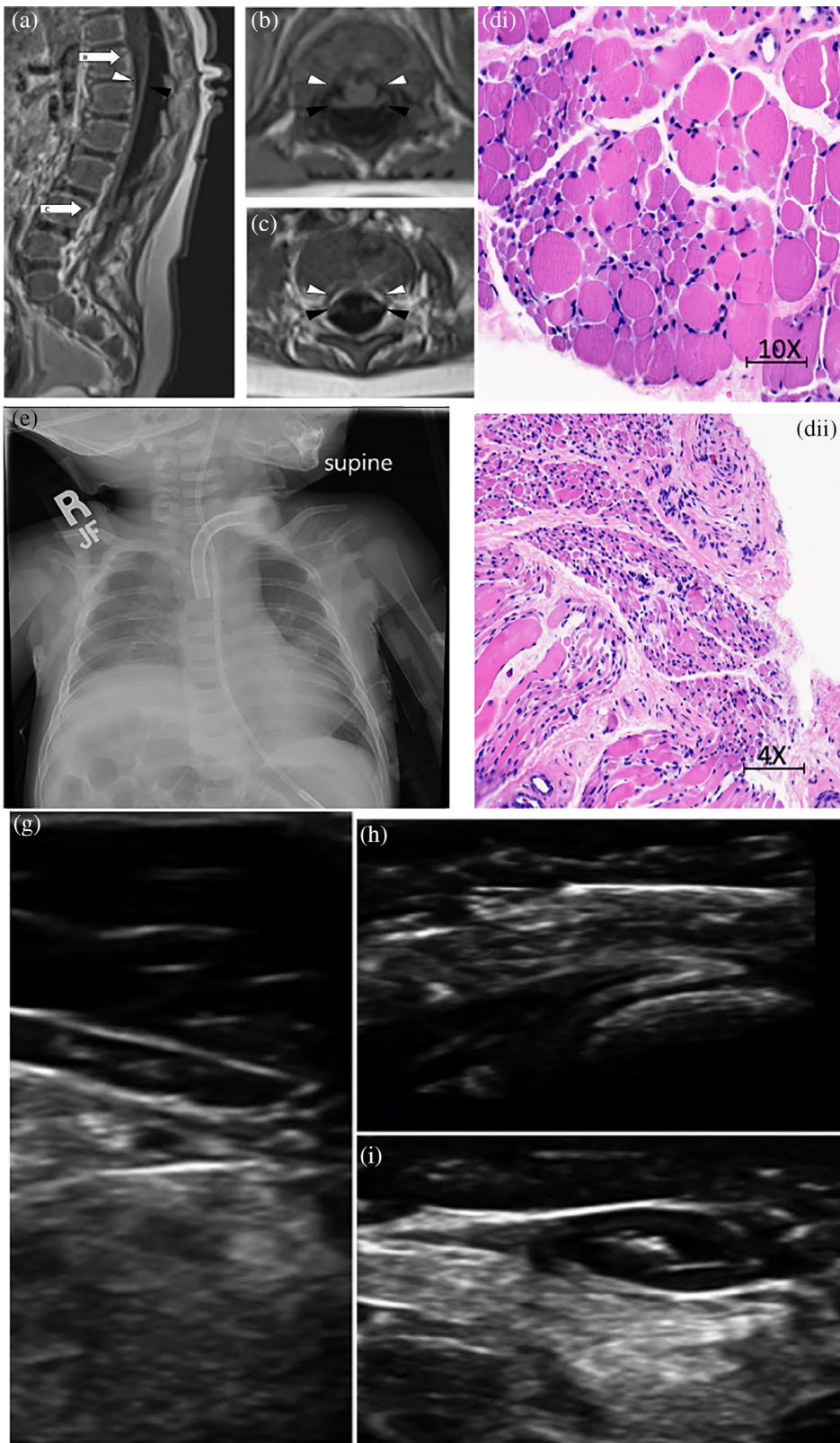
At approximately 9 weeks of age, he was hospitalized due to respiratory distress, decreased movements, and poor feeding. Initial physical exam findings were significant for an alert infant with a weak cry and associated cyanosis. He progressed to respiratory failure requiring mechanical ventilation. His motor exam was significant for generalized hypotonia with antigravity strength in the upper extremities and inability to overcome gravity in the lower extremities. Proximal muscles were weaker than distal muscles. Muscle stretch reflexes were absent. Tongue fasciculations were present. There was no obvious clinical evidence of sensory impairment, although detailed sensory exam was limited due to his young age and sedation. At 11 months of age, he remains alert, on 24-h chronic ventilation and gastrostomy tube, and requires assistance for all activities of daily living.

His diagnostic evaluation was suggestive of motor neuron involvement in many aspects. MRI of his complete spine showed marked volume loss of ventral cauda equina as well as atrophy of lower lumbar and sacral paraspinal musculature, gluteal and iliopsoas muscles, and pelvic girdle muscles (Figure 1a–c). On nerve conduction study, compound muscle action potentials had severely decreased amplitude with normal latency while some muscles were non-responsive. Sensory nerve action potentials were normal except his right sural nerve that was nonresponsive and bilateral medial plantar nerves that showed mildly prolonged latencies with the decreased amplitude on the right compared to the left. Needle EMG showed decreased insertional activity and recruitment in all tested muscles. Some muscles showed large amplitude motor unit potential, and one muscle with severely decreased recruitment showed polyphasic activity. Biopsy of his quadriceps muscle had marked variation in fiber size with small group and fascicular atrophy (Figure 1d).

Patient 2 was born to his Hispanic mother and father at 39 weeks gestation via a repeat C-section. His weight was appropriate for gestational age at 7 pounds. His mother had an uncomplicated pregnancy and he was discharged on day of life 4 without any detected medical issues. There was no consanguinity and no family history of any neuromuscular disorders.

At 6 weeks of age he began having repeated events of respiratory failure requiring multiple intubations and ultimately a tracheostomy ~2 months of age. He has remained on constant mechanical ventilation since that time. His chest X-rays consistently revealed right hemidiaphragm elevation (Figure 1e). At 4 months of age he had an ultrasound evaluation revealing minimal movement of the right hemidiaphragm representing likely diaphragmatic paralysis versus significant paresis. A subsequent ultrasound at 9 months of age revealed apparent diminished diaphragmatic motion bilaterally.

He was first evaluated by neurology at 9.5 months of age due to progressive weakness, distal greater than proximal, and respiratory failure. He had significant generalized weakness including lack of antigravity strength proximally and nearly no movement distally. At that time, he had no fixed contractures but hands had claw-like appearance suggestive of significant intrinsic muscle atrophy and bilateral



**FIGURE 1** (a) Patient 1 MRI of the spine in sagittal view. Note marked volume loss of ventral cauda equina (white arrowhead) and intact dorsal cauda equina (black arrowhead). White arrows signify the spinal level of images (b) and (c) that show marked volume loss of ventral cauda equina (white arrowhead) and intact dorsal cauda equina (black arrowhead) in axial view. (d) Patient 1, hematoxylin and eosin stain of quadriceps muscle with marked variation in fiber size with small group and fascicular atrophy typical of SMA1; (e) Patient 2, chest X-ray with elevation of Right hemi-diaaphragm; (f) Patient 2, hematoxylin and eosin stain of muscle with variation in muscle size, rare myophagocytosis, regenerating fibers (g), (h), and (i) Patient 3, muscle ultrasound with severe atrophy and neurogenic changes of distal > proximal muscles [Color figure can be viewed at [wileyonlinelibrary.com](http://wileyonlinelibrary.com)]

caval deformity of his feet. Reflexes were absent throughout. There were no overt fasciculations. There was no evidence of sensory deficits on clinical exam. He has always been very alert and with apparently normal cognitive function.

He was initially able to roll over around 3 months of age but lost this skill at 18 months of age. He attained the ability to sit at 12 months of age and maintained this at last follow up at 39 months of age but is unable to attain this posture independently.

**TABLE 1** Clinical features of three patients with *de novo* GARS variants and infantile SMA presentation with respiratory distress

	Patient 1	Patient 2	Patient 3
Pathogenic variant	c.1001T>A (p.Ile334Asn)	c.1001T>A (p.Ile334Asn)	c.1954G>C (p.Gly652Arg)
Inheritance	<i>de novo</i>	<i>de novo</i>	<i>de novo</i>
Age of presentation	9 weeks	6 weeks	Day 0
Age at most recent encounter	6 months	39 months	14 months
Initial presentation of respiratory distress, poor feeding and muscle weakness	+	+	+
<b>Neurologic</b>			
Hypotonia, lower extremities > upper extremities	+	+	+
Fasciculations	+	–	+
Hyporeflexia	+	+	+
Atrophy	–	+	+
Pes Cavus	–	+	–
Contractures	–	+	+
Sensory impairment	<sup>a</sup>	+	–
<b>Respiratory</b>			
Stridor	+	+	+
Weak cry	+	+	+
Elevated right diaphragm	+	+	<sup>b</sup>
Chronic ventilation	+	+	+
<b>Feeding/nutrition</b>			
Poor feeding	+	+	+
G-tube dependent	+	+	+

<sup>a</sup>Absence of sural nerve response.

<sup>b</sup>Poor diaphragm movement noted on ultrasound.

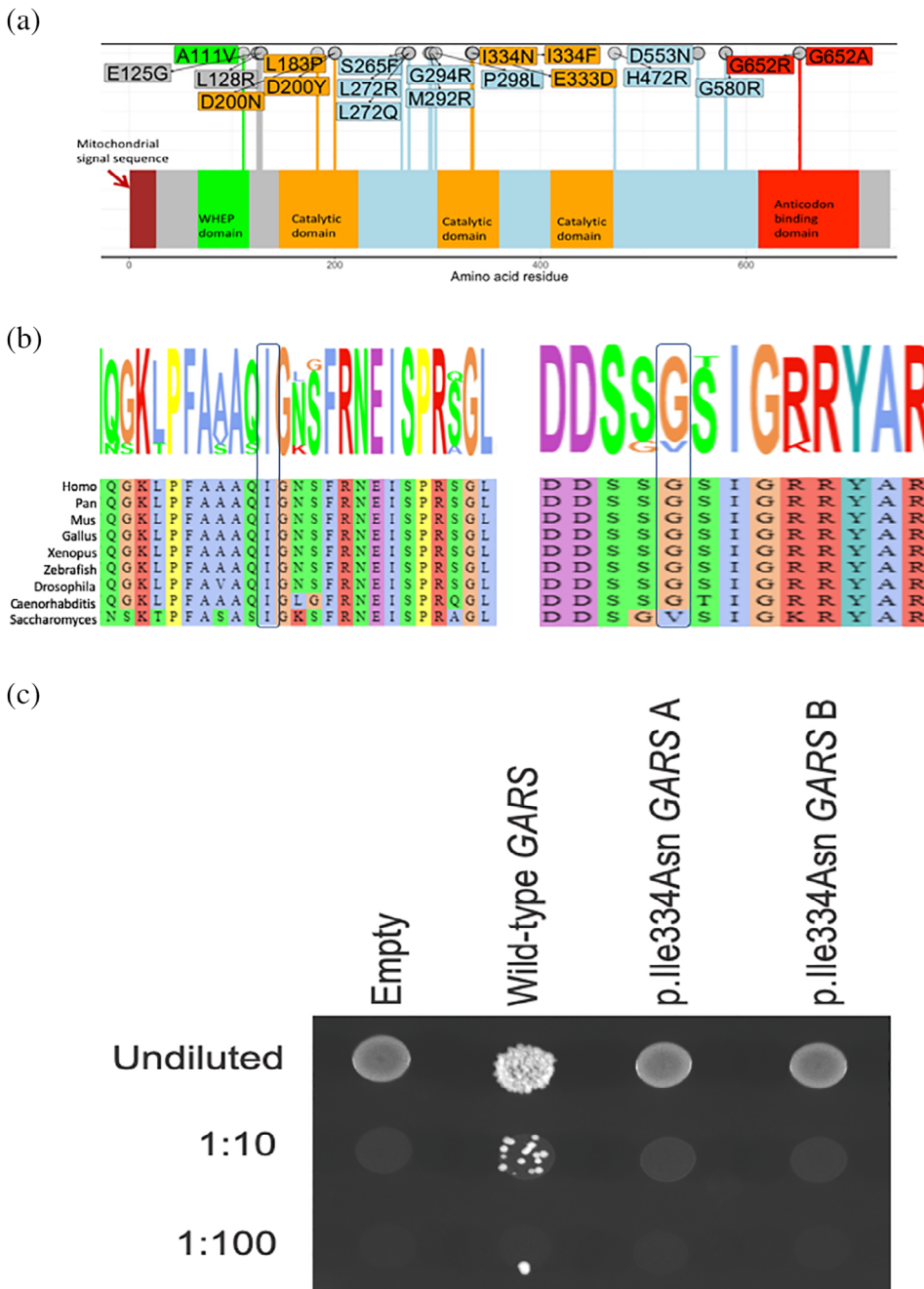
At 39 months of age he remained unable to perform antigravity movements proximally and had very little distal movements. He had significant ankle contractures and has had surgery for his progressive kyphoscoliosis.

His evaluation has included a MRI of the brain and C-spine completed at 9 months of age which revealed slightly increased prominence of the bi-frontal and temporal subarachnoid spaces and mild prominence of the lateral and third ventricles. The cervical spine MRI was normal. At 10 months of age he had a left thigh muscle biopsy with features of denervation atrophy with group atrophy with large groups of atrophic fibers (both type 1 and 2 fibers) as well as features of chronic active myopathy (variation in muscle size, rare myophagocytosis, regenerating fibers, marked endomysial fibrosis, occasional darkly stained hyalinized fibers on trichrome stain, indistinct fiber typing on ATPase pH 9.4, and co-expression of fast and slow myosin) (Figure 1f).

An EMG/NCV was performed at 3 years of age which revealed a severe, active, diffuse, axonal sensory-motor but predominantly motor peripheral neuropathy. Compound muscle action potentials were absent in all tested nerves (right peroneal, tibial, median, ulnar, and musculocutaneous nerves). Sensory nerve action potentials were normal in the median and ulnar nerves but absent in the right medial plantar and sural nerves. Needle EMG revealed numerous fibrillation potentials, complex repetitive discharges, and increased insertional activity. There were a few fasciculation potentials. Activation was

examined in a few muscles, which revealed long duration and high amplitude motor units with reduced recruitment.

Patient 3 was the AGA product of a 38-week gestation delivered by spontaneous vaginal delivery to a Caucasian father and French Canadian mother. There was no consanguinity. Pregnancy was uncomplicated and with normal perceived fetal movement. Apgar scores were 8 and 9 at 1 and 5 min, respectively. Inspiratory stridor and hypotonia were noted at birth. He was subsequently diagnosed with vocal cord paralysis. By 1 month of age, he was having difficulty maintaining weight, largely due to poor suck, swallowing difficulties and early fatigue with feeding. He developed more notable respiratory insufficiency at 10 weeks, also with bulbar weakness, including drooling. BiPAP was trialed but following an acute GI bleed he was intubated and subsequently failed multiple extubation attempts. He underwent tracheostomy at 4 months of age and remains ventilator dependent. He had progressive weakness of his extremities, initially with distal weakness that progressed to proximal involvement. At 5 months, he was able to move his legs and at 7 months of age he was still able to move his arms; however, he subsequently lost those abilities. At the time of his last examination, at 14 months of age, he was alert and attentive to his surroundings with marked weakness. He was able to move his shoulders within the plane of gravity, and facial strength was relatively preserved. Tongue movements were limited and he had notable tongue fasciculations.



**FIGURE 2** (a) The mutation spectrum of GARS. Missense mutations causing CMT2D/ dSMA are shown on the GARS primary structure. The domains are colored as indicated. (b) Conservation of the p.Ile334 and the p.Gly652 residues. (c) The p.Ile334Asn GARS variant causes a loss-of-function effect in yeast complementation assays. Yeast lacking endogenous *GRS1* (the yeast ortholog of GARS) were transformed with vectors containing wild-type GARS  $\Delta$ MTS $\Delta$ WHEP or p.Ile334Asn GARS  $\Delta$ MTS $\Delta$ WHEP, or a vector with no GARS insert ("Empty"). Resulting cultures were plated undiluted or diluted (1:10 or 1:100) on media containing 5-FOA or media lacking leucine and uracil (-leu-ura) and grown at 30°C. Two independently generated mutant constructs ("a" and "b") were tested [Color figure can be viewed at [wileyonlinelibrary.com](http://wileyonlinelibrary.com)]

His evaluation included multiple EMGs, brain MRI and muscle ultrasound. His brain MRI was largely normal. Muscle ultrasound at 13 months of age showed severe atrophy and neurogenic changes in all muscles, more pronounced distally than proximally (Figure 1g-i). In the distal lower extremity, there are dense and severely atrophic muscles with no voluntary or spontaneous activity seen. Triceps were relatively spared compared to the biceps and deltoid muscles, but all showed abnormal echogenicity. There were fasciculations seen in the proximal upper extremities, paraspinal muscles, tongue, and orbicularis oris muscle. The diaphragm muscle appeared very thin and with no spontaneous movement visualized.

Patient 3 had multiple EMGs. His initial EMG was at 2 months of age, which showed a length-dependent, severe, mixed axonal and demyelinating predominantly motor sensorimotor polyneuropathy with active denervation seen on needle EMG exam in proximal and distal muscles of the upper and lower extremities. Repeat EMG at 3 months of age showed absent sensory responses, absent motor responses in the lower extremities, markedly reduced median CMAP motor amplitude (0.6 mV), and needle EMG exam again showed abnormal spontaneous activity suggesting active denervation. Repeat EMG at 13 months of age showed absent sensory and motor responses, no voluntary motor units elicited on needle EMG distally,

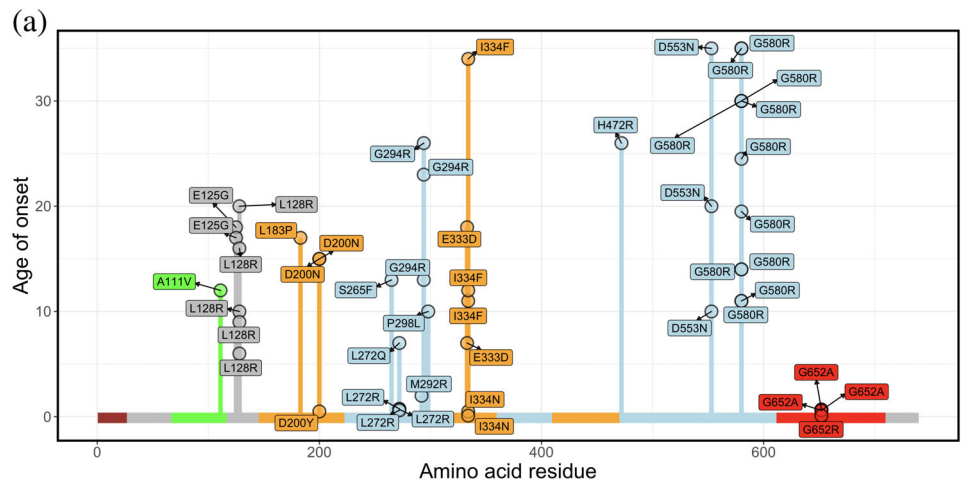
and evidence of ongoing active denervation in the proximal upper extremity (biceps brachii muscle).

### 3.2 | Variants in the catalytic and anticodon binding domain of GARS leads to early onset SMA

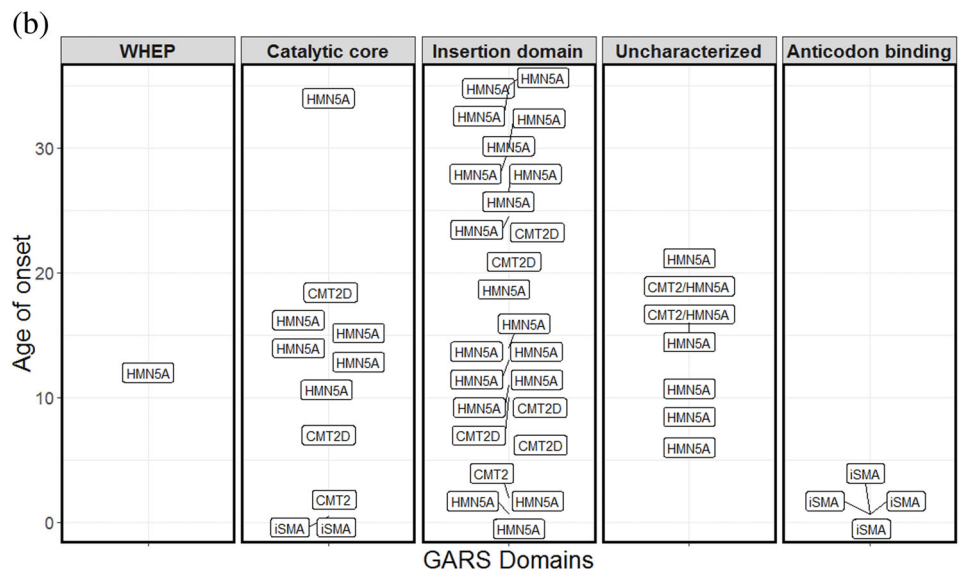
None of the three patients described above harbored the *SMN1* gene deletion. Trio exome sequencing of Patient 1 and a hereditary neuropathy gene panel testing of Patient 2 revealed heterozygosity for the same NM\_002047.2:c.1001T>A (p.Ile334Asn) missense variant in the catalytic domain of GARS (Figure 2a). This was consistent with the overlapping clinical presentation of the two patients (Table 1). This variant, absent from the gnomAD variant database (Karczewski et al., 2019), affects a highly conserved residue that is invariant from yeast to humans (Figure 2b). The variant identified in both of these patients was a *de novo* event. Consistent with the involvement of this residue of GARS in hereditary neuropathy, a different missense substitution at this codon (p.Ile334Phe, also reported as p.Ile280Phe) has been identified in patients with features of later onset dSMA (James et al.,

2006; Klein et al., 2014). Additionally experimental studies show that this residue is critical for charging tRNA with glycine *in vitro* (Antonellis et al., 2006; Griffin et al., 2014). Consistent with this we also found that the p.Ile334Asn variant failed to complement the deletion of the yeast ortholog *GRS1* in a yeast complementation assay, indicating a loss-of-function effect consistent with other neuropathy-associated GARS variants (Griffin et al., 2014) (Figure 2c).

Trio exome sequencing in Patient 3 revealed heterozygosity for a *de novo*—and previously unreported—c.1954G>C (p.Gly652Arg) GARS variant. The c.1954G>C (p.Gly652Arg) change is also not present in the gnomAD database; however a p.Gly652Glu variant is present in 1 out of 249,522 alleles. The affected Gly652 residue is conserved between the nematode *Caenorhabditis elegans* to humans (Figure 2b). Additionally, a different change of the same amino acid (p.Gly652Ala) has been previously reported to cause infantile or early childhood onset axonal CMT and distal spinal muscular atrophy type (Eskuri et al., 2012; James et al., 2006). The p.Gly652Ala change is within the anticodon-binding domain of GARS and mutations within the anticodon-binding domain have been proposed to be more damaging to enzyme function than those within other GARS domains. Taken



**FIGURE 3** (a) The majority of patients with GARS variants exhibit late-onset clinical features of neuropathy. Plot of age of onset (years) versus amino acid residue for different variants in GARS implicated in different types of neuropathy. The variants reported in this study are indicated by arrows. (b) Age of onset (years) and published diagnosis of patients with putative GARS pathogenic variants. Age of onset is on the y axis and each facet represent the domains of GARS. Each of the rectangles depicts patients and their published diagnosis. Majority of patients are diagnosed as dSMAV or CMT2D. iSMA: infantile SMA [Color figure can be viewed at wileyonlinelibrary.com]



together we identified two potentially deleterious *de novo* variants in GARS in three patients presenting with infantile onset SMA.

### 3.3 | The I334N GARS variant does not support yeast cell growth in complementation assays

Yeast complementation assays have revealed loss-of-function characteristics for the majority of CMT-associated GARS variants (Antonellis et al., 2006; Griffin et al., 2014) indicating that this model can be employed to predict pathogenicity (Oprescu et al., 2017). GARS with both the mitochondrial targeting sequence (MTS) and WHEP domain deleted ( $\Delta$ MTS $\Delta$ WHEP) has been shown to allow robust cell growth (Chien et al., 2014; Oprescu et al., 2017). We therefore compared the ability of wild-type and p.Ile334Asn human GARS  $\Delta$ MTS $\Delta$ WHEP to complement the loss of endogenous yeast *GRS1* (the yeast ortholog of GARS). Complementation studies were performed in a previously validated haploid yeast strain deleted for endogenous *GRS1* and maintained with *GRS1* on a *URA3*-bearing vector (Turner et al., 2000). Wild-type or p.Ile334Asn GARS  $\Delta$ MTS $\Delta$ WHEP expression constructs, or constructs with no GARS insert ("Empty" in Figure 2c) were transformed into the yeast strain and grown on 5-FOA, which selects for spontaneous loss of the *URA3*-bearing maintenance vector (Figure 2c). The empty plasmid did not support yeast growth, consistent with *GRS1* being an essential gene (Figure 2c). The wild-type GARS  $\Delta$ MTS $\Delta$ WHEP expression construct supported robust yeast growth, which indicates that human GARS can complement the loss of the endogenous *GRS1* locus, consistent with previous findings (Chien et al., 2014; Oprescu et al., 2017). The p.Ile334Asn GARS  $\Delta$ MTS $\Delta$ WHEP expression construct was unable to support yeast growth (Figure 2c), suggesting that p.Ile334Asn GARS represents a loss-of-function allele.

### 3.4 | *De novo* variants in the GARS anticodon binding domain leads to early-onset SMA

The observation of three patients with *de novo* variants in different functional domains of GARS and clinical features consistent with early-onset SMA suggested that depending on the nature of the amino-acid change and location of the variant in the GARS protein, the presentation of a patient may mimic infantile onset SMA rather than a later onset CMT2D or dSMAV. Among the patients with dSMA, CMT2D, or infantile SMA and GARS variants published in the literature ( $n = 45$ ), we found that seven had infantile onset of symptoms (15.5%, age of onset less than 2 years old, Figure 3a,b). The majority of patients are diagnosed with dSMA or CMT2D, particularly when the variants are not in the anticodon-binding or catalytic domain (Chung et al., 2018; Eskuri et al., 2012; James et al., 2006; Liao et al., 2015) (Figure 3b). Our identification of three patients with early-onset SMA adds to the growing appreciation of the broad spectrum of dominant phenotypes associated with GARS pathogenic variants. This includes early onset motor neuropathy that may mimic infantile SMA with respiratory distress, as seen in our patients.

The p.Ile334Asn and p.Gly652Arg GARS variants affect amino acids that are located in the catalytic and the anticodon binding domains of GARS, respectively. Both of these residues with a different amino-acid change were previously reported in patients (Antonellis et al., 2003; Eskuri et al., 2012; James et al., 2006) presenting with neuropathic clinical features. An isoleucine to phenylalanine change at position 334 has been associated with a later onset dSMA in three patients (James et al., 2006; Figure 3a). The isoleucine to asparagine amino-acid change is the first amino acid in this domain that has been associated with early-onset SMA. In contrast, the change from glycine at position 652 to another hydrophobic residue, alanine, has been reported in three patients with early-onset SMA like features. Consistent with the critical nature of this glycine residue, we found that a patient with a hydrophobic to polar amino-acid change (p.Gly652Arg) at this residue presented with early-onset SMA with respiratory distress.

## 4 | DISCUSSION

We report three patients with infantile-onset SMA due to pathogenic variants in GARS. This expands the number of patients with GARS-associated, infantile-onset SMA adding support to the idea that deleterious mutations in GARS can lead to infantile SMA. The clinical presentations of patients with pathogenic GARS variants were very similar to that observed in patients with deletion of *SMN1*. Indeed, in six out of the 10 cases of infantile-onset SMA due to GARS variants, *SMN1* testing was ordered as the first line of genetic testing. Given the overlap of clinical features we suggest that in the absence of a homozygous deletion in *SMN1*, consideration should be given for a compound heterozygous state, as approximately 5% of patients with SMA will have a deletion in one allele and a point mutation in the other. If this were not to identify an etiology, then further genetic analysis should proceed with either a comprehensive neuromuscular panel or whole exome/genome analysis. Based on currently available commercial gene panels, GARS is most often included in those tests targeted at CMT or distal hereditary neuropathies with later rather than early onset. Therefore, the diagnosis of GARS-related disease in patients with infantile onset may be missed. With the addition of *SMN1* dosage testing to newborn screening in many states, second-line testing with whole exome sequencing can be expedited in those patients in which *SMN1*-related disease has already been excluded.

Our patients' clinical presentations overlap with both SMA and SMA-related disorders. There is overlap with SMA type 1, due to early onset, and dSMAV due to distal weakness greater than proximal. In addition, our patients had varying degrees of sensory impairment, which can be found in CMT2D, a disorder known to overlap with dSMAV. Finally, due to distal greater than proximal weakness and initial presentation of respiratory distress, our patients fit a diagnosis of SMARD1. We highlight the dilemma of diagnosis for our patients that the clinically defined boundaries between these syndromes are not as impermeable as previously thought, consistent with recent literature (Darras, 2011; Peeters, Chamova, & Jordanova, 2014). As we transition



from diagnoses hinged purely on clinical features to those based on underlying genomic alterations, these classifications will likely become further refined. For example, to our knowledge *IGHMBP2* is the only gene associated with SMARD1; however, based on this report, certain *GARS* variants may lead to SMARD1-like features. This could potentially alter the current diagnostic criteria for SMARD1, which include pathogenic variants in *IGHMBP2*.

*GARS* has been associated with CMT2D and dSMA. Consistent with recent reports (Chung et al., 2018; Eskuri et al., 2012; James et al., 2006; Liao et al., 2015), our results suggest that *GARS* variants could potentially lead to early onset SMA-like features depending on the nature and location of the amino acid change. Functional studies have shown that *GARS* consists of multiple domains including the catalytic, anti-codon binding and dimerization domain, and mutations in each of these domains (Antonellis et al., 2003; Griffin et al., 2014) leads to axonal neuropathy. Several disease mechanisms have been proposed based on mice and *in vitro* studies. Indeed it was recently shown that defective sensory motor connectivity in spinal muscular atrophy results from dysregulation of *GARS* pathway. This in turn may contribute to molecular and phenotypic overlap between spinal muscular atrophy and CMT2D. (Shorrock et al., 2018). The isoleucine to asparagine variant in our patients is located in the catalytic core of *GARS*. The critical nature of this residue is evident from functional studies in yeast. An isoleucine to phenylalanine change in this residue resulted in less than 10% aminoacylation activity compared to the wild-type *GARS* but was able to maintain yeast viability when modeled in the yeast ortholog *GRS1* (Griffin et al., 2014). In contrast, the isoleucine to asparagine change that we identified in our patients with a more severe clinical presentation results in a loss-of-function effect in yeast complementation assays. It is therefore likely that the p.Ile334Asn variant in *GARS* results in reduced enzyme function, which may be particularly detrimental to neurons. The second variant we identified (p.Gly652Arg) affects an amino acid in the anticodon binding domain. Another variant affecting the same codon, p.Gly652Ala, also found in patients with severe early-onset SMA-like features did not differ from wild-type in a yeast complementation assay (Stum et al., 2011) but was shown to aberrantly interact with proteins involved in axonal transport (Mo et al., 2018). Our finding of a novel variant at the same residue in a patient with severe early-onset SMA supports the idea that depending on the affected domain, different *GARS* alleles cause axonal neuropathy through different mechanisms that are likely not captured in the yeast assays. These findings continue to expand the spectrum of clinical phenotypes of "GARS-Associated Axonal Neuropathy". Studies are needed to elucidate the precise mechanisms of how these newly identified variants in *GARS* lead to axonal neuropathy.

Despite the potential pitfalls of differentiating the different types of SMA-related diseases, due to recent development of treatment for *SMN1*-related diseases, the differentiation at the genomic level has important management implications. The recent development of antisense oligonucleotide therapy for *SMN1*-related disease has altered the outcome, especially when given to children early in the disease course. However, since the antisense oligonucleotide and more recently adenovector-based gene therapy are the only therapeutics for

*SMN1*-related disease, it is crucial to delineate *SMN1* spinal muscular atrophy from the less common, yet more genetically diverse, non-5q SMA. Specifically, it is important that physicians are aware that non-5q SMA can present as a severe, infantile phenotype, as was the case with our patients. Our results suggests tRNA ligases particularly *GARS1* as a key contributor to clinical presentations non 5q SMA. An increased awareness of these non-5q SMA-like patients will help to more rapid diagnosis and provide more optimal disease management. Additionally, this is a diagnosis that should be considered in the case of an infant with rapidly progressive bulbar, axial and appendicular weakness, adding to SMA, SMARD, and pontocerebellar hypoplasias which may have similarly aggressive patterns of weakness. By increasing awareness of these non-5q SMA-like patients, we can more rapidly diagnose and provide optimal treatment to these patients.

### ACKNOWLEDGEMENTS

We thank the patients and their families for allowing us to sharing their clinical data. All patients included have provided consent for publications. M.K. is supported by the NIH Medical Scientist Training Program Training Grant (GM007863) and the NIH Cellular and Molecular Biology Training Grant (GM007315) from the National Institute of General Medical Sciences, and an NIH National Research Service Award (F31) from the National Institute of Neurological Disorders and Stroke (NS113515). A.A. is supported by a grant from the National Institute of General Medical Sciences (GM118647).

### CONFLICT OF INTEREST

Baylor College of Medicine and Miraca Holdings Inc. have formed a joint venture with shared ownership and governance of Baylor Genetics (BG), formerly the Baylor Miraca Genetics Laboratories, which performs chromosomal microarray analysis and clinical exome sequencing. LP: The Department of Molecular and Human Genetics at Baylor College of Medicine derives revenue from molecular genetic testing offered in the Baylor Genetics Laboratories. The remaining authors did not declare any competing interests.

### AUTHOR CONTRIBUTIONS

R.M., R.G., L.P. analyzed data and co-wrote the article. M.E.K, A.A. designed and performed yeast experiments, provided valuable input in writing the article. W.H., J.L., T.L. provided figures and analyzed patient neurological data. S.B., S.W. and S.M. provided patient data and input in manuscript writing. K.C., P.T, D.B, C.B. provided patient data and input in manuscript writing. E.M. and C.M. provided relevant images. W.B., R.X. analyzed patient exome data and provided valuable input in manuscript writing.

### DATA AVAILABILITY STATEMENT

The data that support the findings of this study are available from the corresponding author upon request.

### ORCID

Rajarshi Ghosh  <https://orcid.org/0000-0001-7368-8940>

Weimin Bi  <https://orcid.org/0000-0002-1330-7031>

## REFERENCES

- Antonellis, A., Ellsworth, R. E., Sambuughin, N., Puls, I., Abel, A., Lee-Lin, S.-Q., ... Green, E. D. (2003). Glycyl tRNA synthetase mutations in Charcot-Marie-Tooth disease type 2D and distal spinal muscular atrophy type V. *American Journal of Human Genetics*, *72*, 1293–1299.
- Antonellis, A., Goldfarb, L. G., & Sivakumar, K. (1993). GARS-associated axonal neuropathy. In M. P. Adam, H. H. Ardinger, R. A. Pagon, S. E. Wallace, L. J. Bean, K. Stephens, & A. Amemiya (Eds.), *GeneReviews*<sup>®</sup>. Seattle (WA): University of Washington, Seattle.
- Antonellis, A., & Green, E. D. (2008). The role of aminoacyl-tRNA synthetases in genetic diseases. *Annual Review of Genomics and Human Genetics*, *9*, 87–107.
- Antonellis, A., Lee-Lin, S.-Q., Wasterlain, A., Leo, P., Quezado, M., Goldfarb, L. G., ... Green, E. D. (2006). Functional analyses of glycyl-tRNA synthetase mutations suggest a key role for tRNA-charging enzymes in peripheral axons. *The Journal of Neuroscience*, *26*, 10397–10406.
- Boeke, J. D., Trueheart, J., Natsoulis, G., & Fink, G. R. (1987). 5-Fluoroorotic acid as a selective agent in yeast molecular genetics. *Methods in Enzymology*, *154*, 164–175.
- Chien, C.-I., Chen, Y.-W., Wu, Y.-H., Chang, C.-Y., Wang, T.-L., & Wang, C.-C. (2014). Functional substitution of a eukaryotic glycyl-tRNA synthetase with an evolutionarily unrelated bacterial cognate enzyme. *PLoS One*, *9*, e94659.
- Chihara, T., Luginbuhl, D., & Luo, L. (2007). Cytoplasmic and mitochondrial protein translation in axonal and dendritic terminal arborization. *Nature Neuroscience*, *10*, 828–837.
- Chung, P., Northrup, H., Azmath, M., Mosquera, R. A., Moody, S., & Yadav, A. (2018). Glycyl tRNA Synthetase (GARS) gene variant causes distal hereditary motor neuropathy V. *Case Reports in Pediatrics*, *2018*, 8516285.
- Darras, B. T. (2011). Non-5q spinal muscular atrophies: The alphanumeric soup thickens. *Neurology*, *77*, 312–314.
- Drew, A. P., Blair, I. P., & Nicholson, G. A. (2011). Molecular genetics and mechanisms of disease in distal hereditary motor neuropathies: Insights directing future genetic studies. *Current Molecular Medicine*, *11*, 650–665.
- Eskuri, J. M., Stanley, C. M., Moore, S. A., & Mathews, K. D. (2012). Infantile onset CMT2D/dSMA V in monozygotic twins due to a mutation in the anticodon-binding domain of GARS. *Journal of the Peripheral Nervous System*, *17*, 132–134.
- Fuchs, S. A., Schene, I. F., Kok, G., Jansen, J. M., Nikkels, P. G. J., van Gassen, K. L. I., ... van Hasselt, P. M. (2019). Aminoacyl-tRNA synthetase deficiencies in search of common themes. *Genetics in Medicine*, *21* (2), 319–330.
- Griffin, L. B., Sakaguchi, R., McGuigan, D., Gonzalez, M. A., Searby, C., Züchner, S., ... Antonellis, A. (2014). Impaired function is a common feature of neuropathy-associated glycyl-tRNA synthetase mutations. *Human Mutation*, *35*, 1363–1371.
- Grohmann, K., Schuelke, M., Diers, A., Hoffmann, K., Lucke, B., Adams, C., ... Hübner, C. (2001). Mutations in the gene encoding immunoglobulin mu-binding protein 2 cause spinal muscular atrophy with respiratory distress type 1. *Nature Genetics*, *29*, 75–77.
- Guenther, U.-P., Varon, R., Schlicke, M., Dutranoy, V., Volk, A., Hübner, C., ... Schuelke, M. (2007). Clinical and mutational profile in spinal muscular atrophy with respiratory distress (SMARD): Defining novel phenotypes through hierarchical cluster analysis. *Human Mutation*, *28*, 808–815.
- James, P. A., Cader, M. Z., Muntoni, F., Childs, A.-M., Crow, Y. J., & Talbot, K. (2006). Severe childhood SMA and axonal CMT due to anticodon binding domain mutations in the GARS gene. *Neurology*, *67*, 1710–1712.
- Karczewski, K. J., Francioli, L. C., Tiao, G., Cummings, B. B., Alföldi, J., Wang, Q., ... MacArthur, D. G. (2019). Variation across 141,456 human exomes and genomes reveals the spectrum of loss-of-function intolerance across human protein-coding genes. Manuscript submitted for publication. <https://www.biorxiv.org/content/10.1101/531210v2>.
- Klein, C. J., Middha, S., Duan, X., Wu, Y., Litchy, W. J., Gu, W., ... Dyck, P. J. (2014). Application of whole exome sequencing in undiagnosed inherited polyneuropathies. *Journal of Neurology, Neurosurgery, and Psychiatry*, *85*, 1265–1272.
- Liao, Y.-C., Liu, Y.-T., Tsai, P.-C., Chang, C.-C., Huang, Y.-H., Soong, B.-W., & Lee, Y.-C. (2015). Two novel De novo GARS mutations cause early-onset axonal Charcot-Marie-Tooth disease. *PLoS One*, *10*, e0133423.
- Meyer-Schuman, R., & Antonellis, A. (2017). Emerging mechanisms of aminoacyl-tRNA synthetase mutations in recessive and dominant human disease. *Human Molecular Genetics*, *26*, R114–R127.
- Mo, Z., Zhao, X., Liu, H., Hu, Q., Chen, X.-Q., Pham, J., ... Yang, X.-L. (2018). Aberrant GlyRS-HDAC6 interaction linked to axonal transport deficits in Charcot-Marie-Tooth neuropathy. *Nature Communications*, *9*, 1007.
- Munsat, T. L. (1991). International SMA collaboration. *Neuromuscular Disorders*, *1*, 81.
- Opreescu, S. N., Chepa-Lotrea, X., Takase, R., Golas, G., Markello, T. C., Adams, D. R., ... Antonellis, A. (2017). Compound heterozygosity for loss-of-function GARS variants results in a multisystem developmental syndrome that includes severe growth retardation. *Human Mutation*, *38*, 1412–1420.
- Peeters, K., Chamova, T., & Jordanova, A. (2014). Clinical and genetic diversity of SMN1-negative proximal spinal muscular atrophies. *Brain*, *137*, 2879–2896.
- Qin, X., Hao, Z., Tian, Q., Zhang, Z., Zhou, C., & Xie, W. (2014). Cocrystal structures of glycyl-tRNA synthetase in complex with tRNA suggest multiple conformational states in glycylation. *The Journal of Biological Chemistry*, *289*, 20359–20369.
- Russman, B. S. (2007). Spinal muscular atrophy: Clinical classification and disease heterogeneity. *Journal of Child Neurology*, *22*, 946–951.
- Shorrock, H. K., van der Hoorn, D., Boyd, P. J., Llaverro Hurtado, M., Lamont, D. J., Wirth, B., ... Gillingwater, T. H. (2018). UBA1/GARS-dependent pathways drive sensory-motor connectivity defects in spinal muscular atrophy. *Brain*, *141*, 2878–2894.
- Storkebaum, E. (2016). Peripheral neuropathy via mutant tRNA synthetases: Inhibition of protein translation provides a possible explanation. *BioEssays*, *38*, 818–829.
- Stum, M., McLaughlin, H. M., Kleinbrink, E. L., Miers, K. E., Ackerman, S. L., Seburn, K. L., ... Burgess, R. W. (2011). An assessment of mechanisms underlying peripheral axonal degeneration caused by aminoacyl-tRNA synthetase mutations. *Molecular and Cellular Neurosciences*, *46*, 432–443.
- Timmerman, V., Strickland, A. V., & Züchner, S. (2014). Genetics of Charcot-Marie-Tooth (CMT) disease within the frame of the human genome project success. *Genes (Basel)*, *5*, 13–32.
- Tsai, P.-C., Soong, B.-W., Mademan, I., Huang, Y.-H., Liu, C.-R., Hsiao, C.-T., ... Lee, Y.-C. (2017). A recurrent WARS mutation is a novel cause of autosomal dominant distal hereditary motor neuropathy. *Brain*, *140*, 1252–1266.
- Turner, R. J., Lovato, M., & Schimmel, P. (2000). One of two genes encoding glycyl-tRNA synthetase in *Saccharomyces cerevisiae* provides mitochondrial and cytoplasmic functions. *The Journal of Biological Chemistry*, *275*, 27681–27688.
- Wirth, B., Herz, M., Wetter, A., Moskau, S., Hahnen, E., Rudnik-Schöneborn, S., Zerres, K. (1999). Quantitative analysis of survival motor neuron copies: Identification of subtle SMN1 mutations in patients with spinal muscular atrophy, genotype-phenotype correlation, and implications for genetic counseling. *American Journal of Human Genetics*, *64*, 1340–1356.

**How to cite this article:** Markovitz R, Ghosh R, Kuo ME, et al. GARS-related disease in infantile spinal muscular atrophy: Implications for diagnosis and treatment. *Am J Med Genet Part A*. 2020;182A:1167–1176. <https://doi.org/10.1002/ajmg.a.61544>