





ORIGINAL STUDIES

EDITORIAL COMMENT: Expert Article Analysis for:
[The new era of ventricular pacing during structural interventions](#)

The initial U.S. experience with the Tempo active fixation temporary pacing lead in structural heart interventions

Tamim M. Nazif MD^{1,2}  | Shmuel Chen MD PhD²  | Pablo Codner MD¹ |
Paul M. Grossman MD³ | Daniel S. Menees MD³ | Carlos E. Sanchez MD⁴  |
Steven J. Yakubov MD⁴  | Jonathan White MD⁵ | Samir Kapadia MD⁵  |
Brian K. Whisenant MD⁶ | John K. Forrest MD⁷ | Amar Krishnaswamy MD⁵  |
Arash Arshi MD⁴ | James L. Orford MD⁶ | Martin B. Leon MD^{1,2} |
José M. Dizon MD¹ | Susheel K. Kodali MD^{1,2} | Stanley J. Chetcuti MD³

¹Columbia University Irving Medical Center, New York, New York

²Clinical Trials Center, Cardiovascular Research Foundation, New York, New York

³University of Michigan Cardiovascular Center, Ann Arbor, Michigan

⁴OhioHealth/Riverside Methodist Hospital, Columbus, Ohio

⁵Cleveland Clinic Heart & Vascular Institute, Cleveland, Ohio

⁶Intermountain Medical Center Heart Institute, Salt Lake City, Utah

⁷Yale University School of Medicine, New Haven, Connecticut

Correspondence

Tamim Nazif, 177 Fort Washington Avenue
5th Floor Room 5C-501, New York, NY
10032.

Email: tnm31@cumc.columbia.edu

Abstract

Objectives: This multicenter retrospective study of the initial U.S. experience evaluated the safety and efficacy of temporary cardiac pacing with the Tempo[®] Temporary Pacing Lead.

Background: Despite increasing use of temporary cardiac pacing with the rapid growth of structural heart procedures, temporary pacing leads have not significantly improved. The Tempo lead is a new temporary pacing lead with a soft tip intended to minimize the risk of perforation and a novel active fixation mechanism designed to enhance lead stability.

Methods: Data from 269 consecutive structural heart procedures were collected. Outcomes included device safety (absence of clinically significant cardiac perforation, new pericardial effusion, or sustained ventricular arrhythmia) and efficacy (clinically acceptable pacing thresholds with successful pace capture throughout the index procedure). Postprocedure practices and sustained lead performance were also analyzed.

Results: The Tempo lead was successfully positioned in the right ventricle and achieved pacing in 264 of 269 patients (98.1%). Two patients (0.8%) experienced loss of pace capture. Procedural mean pace capture threshold (PCT) was 0.7 ± 0.8 mA. There were no clinically significant perforations, pericardial effusions, or sustained device-related arrhythmias. The Tempo lead was left in place postprocedure in 189 patients (71.6%) for mean duration of 43.3 ± 0.7 hr (range 2.5–221.3 hr) with final PCT of 0.84 ± 1.04 mA ($n = 80$). Of these patients, 84.1% mobilized out of bed with no lead dislodgment.

Conclusion: The Tempo lead is safe and effective for temporary cardiac pacing for structural heart procedures, provides stable peri and postprocedural pacing and allows mobilization of patients who require temporary pacing leads.

KEYWORDS

balloon valvuloplasty, electrophysiology, pacemaker, tamponade, temporary pacing, transcatheter aortic valve replacement

1 | INTRODUCTION

The use of temporary pacing has significantly increased as a necessary adjunct to transcatheter aortic valve replacement (TAVR) and other structural heart interventions. Many of these procedures require the precise placement of implantable devices, which can be achieved by rapid ventricular pacing with a temporary pacing lead.¹ Furthermore, approximately 5–30% of TAVR patients and 10–15% of alcohol septal ablation (ASA) patients develop periprocedural cardiac conduction disturbances requiring permanent pacemaker implantation.^{2–4} At-risk patients, such as those with preexisting right bundle branch block or new left bundle branch block after TAVR, may require retention of a temporary pacing lead for several days as a precaution against the development of complete heart block or other dangerous bradyarrhythmias.

The standard design of temporary pacing leads consists of two rigid metal electrodes mounted at and near the distal tip of an insulated electrical wire. This design has been associated with cardiac perforation and tamponade in up to 0.6–4.0% of cases^{5–9} and lead dislodgment with loss of capture in 10–37% of patients.^{7,10,11} In addition, the standard lead design does not allow patient mobilization or ambulation, which may affect patient comfort, delay mobilization, prolong intensive care unit and hospital length of stay, and impact costs. The novel

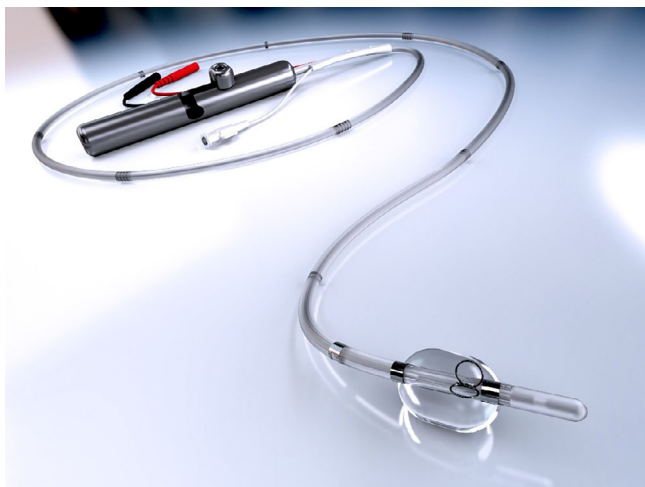


FIGURE 1 The Tempo Temporary Pacing Lead features bipolar electrodes, active fixation to ensure stable pace capture, and a soft tip to reduce the risk of right ventricle perforation [Color figure can be viewed at wileyonlinelibrary.com]

Tempo[®] Temporary Pacing Lead (BioTrace Medical, Inc., Menlo Park, CA) has a soft distal tip to reduce the risk of cardiac perforation and allows active lead fixation to ensure reliable pace capture during the index procedure and during subsequent patient mobilization.¹²

The aim of this study is to evaluate the safety and efficacy of the Tempo lead for intra- and postprocedural cardiac pacing support in a large real-world cohort of patients undergoing structural heart interventions.

2 | METHODS

2.1 | Device

The Tempo lead (Figure 1) is a radiopaque, polymeric lead that features bipolar electrodes, a novel active fixation mechanism designed to enhance pacing stability, and a soft tip to minimize the risk of right

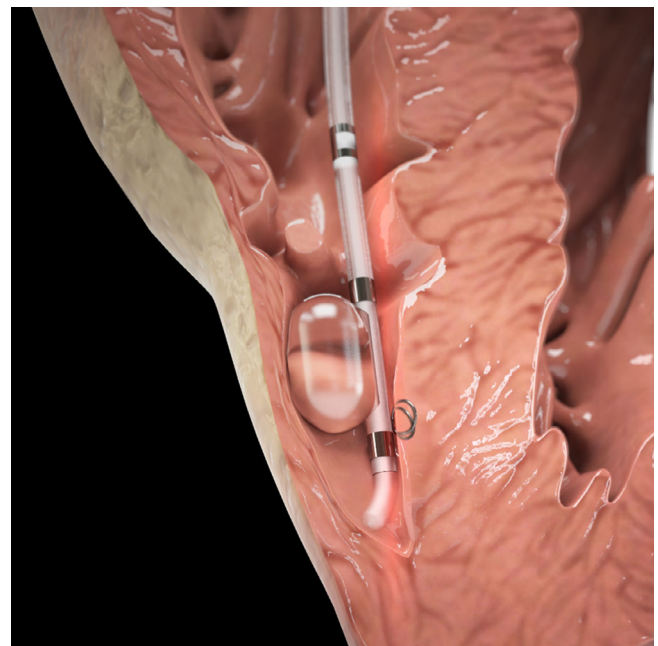


FIGURE 2 The Tempo lead's active fixation is accomplished via small retractable stabilizer loops deployed into the myocardium. An elastomeric balloon inflates to aid passage through the venous vasculature and into the right ventricle and provides apposition of the stabilizer loops to the myocardium. The balloon is deflated after the stabilizer loops are deployed [Color figure can be viewed at wileyonlinelibrary.com]

ventricular perforation. Active fixation is accomplished via small, retractable nitinol stabilizer loops that are deployed into the myocardium. An elastomeric balloon, mounted asymmetrically on the lead body between the electrodes, aids passage through the venous vasculature and provides apposition of the loops to the right ventricular myocardium (Figure 2). The lead is readily visualized by fluoroscopy, and an asymmetric orientation marker is used to orient the stabilizer loops toward the ventricular septum (Figure 3). The Tempo lead has been cleared by the U.S. Food and Drug Administration for temporary transvenous cardiac pacing for up to 7 days.

2.2 | Study design and patient population

This is a retrospective, nonrandomized, multicenter registry study. Data was collected from six high-volume, structural heart centers in the United States for consecutive patients who underwent transcatheter structural heart procedures using the Tempo lead. Subjects were included if the Tempo lead entered the vascular introducer sheath. Patient care was per institutional standard of care at the participating centers during the period of study. The study was approved by the local Institutional Review Board at each participating institution.

2.3 | Endpoints

The primary safety outcome consisted of device-related adverse events, including clinically evident cardiac perforation, new pericardial effusion,

and sustained ventricular arrhythmia. The primary efficacy endpoint was defined as successful lead placement with clinically acceptable pacing capture threshold (PCT) and stable cardiac pacing during the index procedure. Procedural success was defined as the ability to advance the Tempo lead to the right ventricle and to achieve right ventricular pacing. Pace capture thresholds and stability during the implant period were analyzed. Postprocedural practice patterns, including patient ambulation and overall and intensive care unit length of stay, were also evaluated.

2.4 | Statistical analysis

Results are depicted as mean \pm SD for numerical data and percentage for categorical data. All comparisons are descriptive in nature.

3 | RESULTS

A total of 269 patients were included from six centers in the United States. Baseline demographic, clinical, electrocardiographic, and echocardiographic patient characteristics are presented in Table 1. The mean age was 77.7 ± 10.4 years, and 64.3% of patients were male. Patients had significant medical comorbidities, including coronary artery disease (61.6%), chronic kidney disease (45.0%), and diabetes mellitus (36.4%). Prior permanent pacemaker or automated implantable cardioverter defibrillators were present in 5.6% of the patients. The mean left ventricular ejection fraction was $57.6 \pm 12\%$, and 13.3% of the patients had moderate/severe tricuspid regurgitation.

3.1 | Procedural characteristics

Procedural characteristics and the distribution of the structural heart procedures performed with the Tempo lead are presented in Table 2. The procedures included 251 (93.3%) TAVRs (57.6% self-expanding and 35.7% balloon-expandable transcatheter heart valve), 12 (4.5%) ASA, and 6 (2.2%) other transcatheter structural heart interventions. The Tempo lead was placed by jugular venous access in 58.7% of the cases and femoral venous access in the remaining 41.3%.

3.2 | Outcomes

Procedural success was achieved in 98.1% (264/269) of cases and stable capture was achieved in all but two cases such that the primary efficacy endpoint was met in 97.4% (262/269) of patients (Table 3). The five unsuccessful lead placements included two from the right femoral vein, two from the left femoral vein, and one from right internal jugular vein. In the two patients (0.8%) with lead dislodgment and loss of pacing capture (both inserted via the right internal jugular vein), repositioning of the lead led to successful pacing. The immediate post implantation PCT was collected in 92.4% (244/264) of patients in whom the Tempo lead was successfully implanted and was 0.70 ± 0.77 mA. The primary safety endpoint (absence of clinically significant cardiac perforation, new pericardial effusion, and sustained ventricular arrhythmia) was met in all patients. Lead removal was free of complications in all patients.

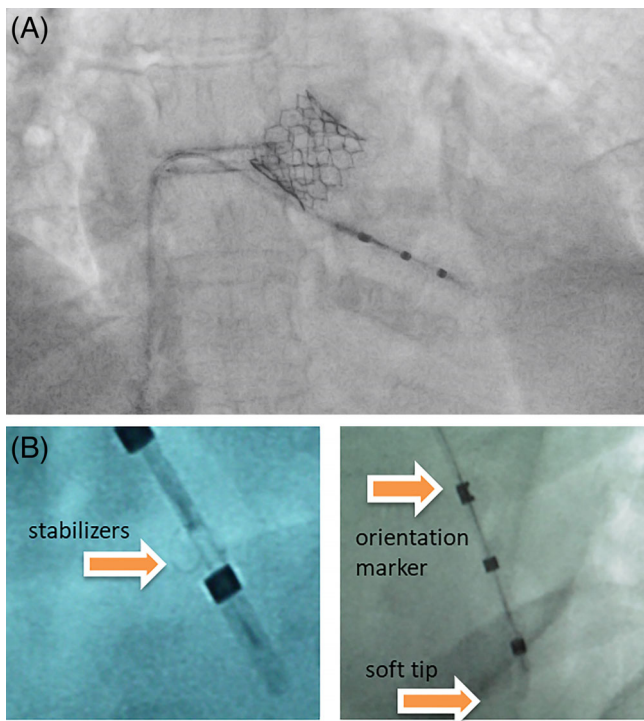


FIGURE 3 (a) Fluoroscopic view of the Tempo lead in the right ventricular apex. (b) Fluoroscopic view of the Tempo lead demonstrating the soft tip in the right ventricular apex, the orientation marker, and the deployed active fixation stabilizer loops [Color figure can be viewed at wileyonlinelibrary.com]

TABLE 1 Baseline patient characteristics

Age	77.7 ± 10.4 years (269)
Male sex	64.3% (173/269)
History of smoking	28.6% (77/269)
Hypertension	85.5% (230/269)
Diabetes mellitus	36.4% (98/269)
Coronary artery disease	60.6% (163/269)
Prior PPM or AICD	5.6% (15/269)
Chronic kidney disease	45.0% (121/269)
Pulmonary hypertension	22.3% (60/269)
COPD	20.8% (56/269)
Baseline echocardiogram	
LV ejection fraction (%)	57.6 ± 12.1 (267)
RV dilation (moderate to severe)	7.4% (19/256)
Tricuspid regurgitation (moderate to severe)	13.3% (34/256)
Baseline electrocardiogram	
Atrial fibrillation/flutter	21.9% (59/269)
Sinus bradycardia	12.2% (28/229)
First degree AVB	21.2% (57/269)
Second degree AVB	0.4% (1/269)
RBBB (complete)	13.4% (35/261)
LBBB (complete)	7.3% (19/261)

Note: Values are % (n/N) or mean ± SD (n).

Abbreviations: AICD, automatic implantable cardioverter-defibrillator; AVB, atrioventricular block; COPD, chronic obstructive pulmonary disease; LBBB, left bundle branch block; LV, left ventricular; PPM, permanent pacemaker RBBB, right bundle branch block; RV, right ventricular.

TABLE 2 Procedural characteristics

Structural heart procedure	
TAVR with self-expanding valve	57.6% (155/269)
TAVR with balloon-expandable valve	35.7% (96/269)
Alcohol septal ablation	4.5% (12/269)
Other	2.2% (6/269)
Access for Tempo lead placement	
Femoral vein	41.3% (111/269)
Internal jugular vein	58.7% (158/269)

Note: Values are % (n/N).

Abbreviation: TAVR, transcatheter aortic valve replacement.

The Tempo lead was left in place in 71.6% (189/264) of patients at the end of the index procedure (Table 4). The mean total pacing duration was recorded in 87.8% (166/189) of these patients and was 43.3 ± 0.7 hr (range 2.5–221.3 hr). With the Tempo lead in place, 159/189 patients (84.1%) mobilized at least from bed to chair, and 134/189 (70.8%) ambulated without restriction related to the pacing lead. There were no reports of lead dislodgment or loss of pace capture. The final PCT before lead removal was reported in 39.2% (74/189) and was 0.82 ± 1.07 mA.

TABLE 3 Lead safety and performance during index procedure

Procedural success (successful lead placement with right ventricular pacing)	98.1% (264/269)
Primary efficacy endpoint (procedural success and stable pacing during index procedure)	97.4% (262/269)
Primary safety endpoint (device-related adverse events)	0.0% (0/269)
Cardiac perforation and/or tamponade	0.0% (0/269)
Sustained arrhythmias	0.0% (0/269)
Immediate post implantation, procedural pace capture threshold	0.70 ± 0.77 mA (244)

Note: Values are % (n/N) or mean ± SD (n).

TABLE 4 Postprocedure lead use

Patients in whom Tempo lead was left in place at the end of the procedure	71.6% (189/264)
Lead dislodgment	0.0% (0/189)
Cardiac perforation and/or tamponade	0.0% (0/189)
Sustained arrhythmias	0.0% (0/189)
Mean implant duration (hours)	43.3 ± 0.7 (136)
Final pace capture threshold	0.84 ± 1.04 mA (80)
Mobility	
Bed to chair	84.1% (159/189)
Ambulation	70.8% (134/189)
Mean implant duration (hours)	44.5 ± 0.5 (140)
Final (before the removal of the lead) postprocedural pace capture threshold	0.82 ± 1.07 mA (74)

Note: Values are % (n/N) or mean ± SD (n).

4 | DISCUSSION

This study evaluated the safety and efficacy of the Tempo temporary pacing lead in a large real-world registry of patients undergoing transcatheter heart interventions at six high-volume centers in the United States. In this experience, the Tempo lead provided effective temporary cardiac pacing during the procedure in more than 97% of patients. PCTs were within a clinically acceptable range and pacing remained stable throughout the procedure in the vast majority. The Tempo lead was retained in situ after the procedure in more than 70% of patients and continued to function well during patient mobilization and ambulation. The primary safety endpoint was met in all patients, with no reported device-related adverse events, including clinically evident cardiac perforation, new pericardial effusion, or sustained ventricular arrhythmia.

Temporary pacing leads serve important intra and postprocedural roles in structural heart procedures. During transcatheter valve replacement procedures, temporary pacing is frequently used for TAVR device stability during deployment, and rapid pacing is mandatory in the case of balloon-expandable TAVR and transcatheter mitral valve replacement.^{13,14} Lead dislodgment or loss of pace capture in this setting can

result in valve embolization.^{15,16} Pacing support is also necessary in case of heart block and related conduction disturbances, which can occur during or after transcatheter heart valve implantation or ASA in patients with hypertrophic cardiomyopathy.^{2,4} Since conduction disturbances may be delayed in onset, pacing leads are frequently left in situ after the index procedure and may limit patient mobilization.^{17,18} This practice may also prolong length of stay especially in intensive or cardiac care unit settings.

Structural heart interventions have traditionally relied on the use of conventional temporary transvenous bipolar cardiac pacing leads consisting of two rigid metal electrodes mounted at and approximately 1 cm from the distal tip of an insulated electrical wire. This technology has not improved significantly in decades and is associated with important limitations, including instability and a risk of cardiac perforation. Because standard temporary pacing leads do not include an active myocardial fixation mechanism, they have traditionally been associated with high rates of lead dislodgment and loss of pace capture.^{6,7,9-11,19} The use of these leads during TAVR has also been associated with cardiac perforation and tamponade, ranging from 0.6 to 4.0% in different series, presumably due to the stiff distal tip of these leads.²⁰⁻²⁴ Although temporary pacing leads with a distal screw for active myocardial fixation have been used to attempt to reduce dislodgment and loss of pace capture, these leads have exhibited dislodgment rates of up to 6%. Furthermore, distal screw fixation temporary leads have been associated with cardiac perforation rates as high as 23% and are no longer available.^{25,26} Some centers have also used a permanent pacing lead that is externalized through the vascular introducer sheath and connected to an external permanent pacemaker.²⁷ However, this approach, is technically more complex, presents perforation risk, and may not be cost effective.

The Tempo lead was designed to address the limitations of conventional temporary leads. The soft distal tip is designed to be atraumatic during placement and retention in the right ventricle and is radiopaque to allow ready visualization under fluoroscopy. Two small Nitinol stabilizer loops allow for active lead fixation to ensure stable pace capture, while mitigating the risk of perforation due to their small diameter and asymmetric orientation with preferential deployment into the thicker interventricular septum. These stabilizers are readily deployed and retracted using a spring-loaded external handle-delivery system at the proximal end of the lead. (Figure 2). An asymmetric, elastomeric balloon assists in transit through the venous access and serves to oppose the lead to the interventricular septal wall during stabilizer deployment. The lead is indicated for use for up to 7 days and, given the novel active fixation mechanism, allows for early patient mobilization.

The current analysis reinforces the results of the previously described first in human experience in New Zealand using the Tempo lead in 25 patients undergoing transcatheter structural heart interventions and electrophysiology procedures.¹² As in the current study, the implantation of the Tempo temporary pacing lead was technically feasible and safe for intraprocedural and postprocedural pacing support. In the current, substantially larger registry of 269 patients, the rates of procedural success and safety endpoints remain similar, expanding the existing safety and efficacy data regarding Tempo lead utilization during various structural heart interventions.

Among patients in this analysis in whom the Tempo lead was left in place after the procedure, more than 80% were mobilized out of bed with maintenance of clinically acceptable PCTs and no reported loss of pacing capture. This is in contrast to the previously existing standard of care at the institutions included in this analysis of mandatory bed rest for patients who required temporary pacing leads. Early mobilization in critically ill patients has been shown to be associated with decreased rates of delirium, readmission or death, ventilator-assisted pneumonia, and central line and catheter infections.²⁸ The Tempo lead's active fixation mechanism may also allow some patients with postprocedure conduction disturbances to recover on general hospital wards rather than in the intensive care unit with reduced in-hospital costs. This may also allow for a greater window of time before the decision to implant a permanent pacemaker is required in patients with conduction disturbances that may ultimately resolve in a substantial proportion of cases.

5 | STUDY LIMITATIONS

The present study has several limitations. Although it is a relatively large, multicenter registry study, the use of site-reported data and the retrospective nature of the analysis are subject to the inherent limitations of this methodology. Diagnostic tests, including electrocardiograms and echocardiograms, were performed and interpreted only according to local institutional standards of care. As the current study did not include a control group (patients treated with a classic temporary transvenous pacemaker lead), direct comparisons regarding safety, efficacy, and postprocedure mobilization are also not possible. Although there were no reports of lead dislodgment or loss of pace capture during patient mobilization, the final PCT before lead removal was reported only in 39.2% and thus this data may be biased. Finally, structural heart procedures other than TAVR are underrepresented and the generalizability of the results beyond this group of patients is unknown.

6 | CONCLUSION

This multi-center, retrospective analysis of the initial real-world experience in the United States demonstrates that the Tempo lead is technically feasible, safe, and effective for temporary cardiac pacing for transcatheter structural heart interventions. The Tempo lead provides stable peri and postprocedural pacing support and allows mobilization of patients who require temporary pacing leads.

DISCLOSURE OF INTERESTS

BioTrace Medical provided funding for this research. Tamim Nazif and Susheel Kodali disclose consulting for BioTrace Medical. Tamim Nazif, Susheel Kodali, and John Forest disclose consulting or honoraria for Edwards LifeSciences, Medtronic, and Boston Scientific. Brian Whisenant discloses equity in BioTrace Medical. Carlos Sanchez discloses consulting for Edwards LifeSciences and Medtronic. Paul Michael Grossman discloses consulting for Medtronic Cardiovascular, research support from Medtronic Cardiovascular, Edwards Life Sciences, and Cardiovascular

Systems Incorporated, registry support from Blue Cross Blue Shield of Michigan, and research support from National Institutes of Health.

ORCID

Tamim M. Nazif  <https://orcid.org/0000-0003-1239-2489>

Shmuel Chen  <https://orcid.org/0000-0001-8843-1777>

Carlos E. Sanchez  <https://orcid.org/0000-0002-1818-4472>

Steven J. Yakubov  <https://orcid.org/0000-0002-0952-7509>

Samir Kapadia  <https://orcid.org/0000-0002-0026-3391>

Amar Krishnaswamy  <https://orcid.org/0000-0001-6048-7955>

REFERENCES

- Webb JG, Pasupati S, Achtem L, Thompson CR. Rapid pacing to facilitate transcatheter prosthetic heart valve implantation. *Catheter Cardiovasc Interv.* 2006;68:199-204.
- Auffret V, Puri R, Urena M, et al. Conduction disturbances after transcatheter aortic valve replacement: current status and future perspectives. *Circulation.* 2017;136:1049-1069.
- Siontis GC, Juni P, Pilgrim T, et al. Predictors of permanent pacemaker implantation in patients with severe aortic stenosis undergoing TAVR. A Meta-Anal. *J Am Coll Cardiol.* 2014;64:129-140.
- Fitzgerald P, Kusumoto F. The effects of septal myectomy and alcohol septal ablation for hypertrophic cardiomyopathy on the cardiac conduction system. *J Interv Card Electrophysiol.* 2018;52:403-408.
- Metkus TS, Schulman SP, Marine JE, Eid SM. Complications and outcomes of temporary transvenous pacing: an analysis of >360,000 patients from the National Inpatient Sample. *Chest.* 2019;155:749-757.
- Lopez Ayerbe J, Villuendas Sabate R, Garcia Garcia C, et al. Temporary pacemakers: current use and complications. *Rev Esp Cardiol.* 2004;57:1045-1052.
- Betts TR. Regional survey of temporary transvenous pacing procedures and complications. *Postgrad Med J.* 2003;79:463-465.
- Jowett NI, Thompson DR, Pohl JE. Temporary transvenous cardiac pacing: 6 years experience in one coronary care unit. *Postgrad Med J.* 1989;65:211-215.
- Austin JL, Preis LK, Crampton RS, Beller GA, Martin RP. Analysis of pacemaker malfunction and complications of temporary pacing in the coronary care unit. *Am J Cardiol.* 1982;49:301-306.
- Gammage MD. Temporary cardiac pacing. *Heart.* 2000;83:715-720.
- Lumia FJ, Rios JC. Temporary transvenous pacemaker therapy: an analysis of complications. *Chest.* 1973;64:604-608.
- Webster M, Pasupati S, Lever N, Stiles M. Safety and feasibility of a novel active fixation temporary pacing Lead. *J Invasive Cardiol.* 2018;30:163-167.
- Mauri V, Reimann A, Stern D, et al. Predictors of permanent pacemaker implantation after transcatheter aortic valve replacement with the SAPIEN 3. *JACC Cardiovasc Interv.* 2016;9:2200-2209.
- Fadahnsi OO, Olowoyeye A, Ukaigwe A, et al. Incidence, predictors, and outcomes of permanent pacemaker implantation following transcatheter aortic valve replacement: Analysis from the U.S. Society of Thoracic Surgeons/American College of Cardiology TVT Registry. *JACC Cardiovasc Interv.* 2016;9:2189-2199.
- Ibebuogu UN, Giri S, Bolorunduro O, et al. Review of reported causes of device embolization following trans-catheter aortic valve implantation. *Am J Cardiol.* 2015;115:1767-1772.
- Tay EL, Gurvitch R, Wijeyesinghe N, et al. Outcome of patients after transcatheter aortic valve embolization. *JACC Cardiovasc Interv.* 2011;4:228-234.
- Mangieri A, Lanzillo G, Bertoldi L, et al. Predictors of advanced conduction disturbances requiring a late (>=48 H) permanent pacemaker following transcatheter aortic valve replacement. *JACC Cardiovasc Interv.* 2018;11:1519-1526.
- Jorgensen TH, De Backer O, Gerds TA, Bieliauskas G, Svendsen JH, Sondergaard L. Immediate post-procedural 12-Lead electrocardiography as predictor of late conduction defects after transcatheter aortic valve replacement. *JACC Cardiovasc Interv.* 2018;11:1509-1518.
- Murphy JJ. Current practice and complications of temporary transvenous cardiac pacing. *BMJ.* 1996;312:1134.
- Bosmans JM, Kefer J, De Bruyne B, et al. Procedural, 30-day and one year outcome following CoreValve or Edwards transcatheter aortic valve implantation: results of the Belgian national registry. *Interact Cardiovasc Thorac Surg.* 2011;12:762-767.
- Grube E, Buellesfeld L, Mueller R, et al. Progress and current status of percutaneous aortic valve replacement: results of three device generations of the CoreValve Revalving system. *Circ Cardiovasc Interv.* 2008;1:167-175.
- Piazza N, Onuma Y, Jesserun E, et al. Early and persistent intraventricular conduction abnormalities and requirements for pacemaking after percutaneous replacement of the aortic valve. *JACC Cardiovasc Interv.* 2008;1:310-316.
- El Masry H, Breall JA. Alcohol septal ablation for hypertrophic obstructive cardiomyopathy. *Curr Cardiol Rev* 2008;4:193-197.
- Cribier A, Eltchaninoff H, Tron C, et al. Treatment of calcific aortic stenosis with the percutaneous heart valve: mid-term follow-up from the initial feasibility studies: the French experience. *J Am Coll Cardiol.* 2006;47:1214-1223.
- de Cock CC, Van Campen CM, In't Veld JA, Visser CA. Utility and safety of prolonged temporary transvenous pacing using an active-fixation lead: comparison with a conventional lead. *Pacing Clin Electrophysiol.* 2003;26:1245-1248.
- Chauhan A, Grace AA, Newell SA, et al. Early complications after dual chamber versus single chamber pacemaker implantation. *Pacing Clin Electrophysiol.* 1994;17:2012-2015.
- Leong D, Sovari AA, Ehdaie A, et al. Permanent-temporary pacemakers in the management of patients with conduction abnormalities after transcatheter aortic valve replacement. *J Interv Card Electrophysiol.* 2018;52:111-116.
- Hunter A, Johnson L, Coustasse A. Reduction of intensive care unit length of stay: the case of early mobilization. *Health Care Manag (Frederick).* 2014;33:128-135.

How to cite this article: Nazif TM, Chen S, Codner P, et al. The initial U.S. experience with the Tempo active fixation temporary pacing lead in structural heart interventions. *Catheter Cardiovasc Interv.* 2020;95:1051-1056. <https://doi.org/10.1002/ccd.28476>