

1

Estimating Risk for Future Intracranial, Fully Implanted, Modular Neuroprosthetic Systems: A systematic review of hardware complications in clinical deep brain stimulation and experimental human intracortical arrays

Estimating Risk for Future Intracranial Devices

Autumn. J. Bullard¹, M.S.E., Brianna C. Hutchison¹, Jiseon Lee¹, B.S., Cynthia A. Chestek^{1,2}, Ph.D., Parag G. Patil^{1,3}, M.D., Ph.D.

¹Department of Biomedical Engineering, University of Michigan, Ann Arbor, MI, USA

²Department of Electrical Engineering and Computer Science, University of Michigan, Ann Arbor, MI, USA

³Department of Neurosurgery, University of Michigan Medical School, Ann Arbor, MI, USA

Funding:

This research was supported in part by the A. Alfred Taubman Medical Research Institute.

Authors' Contributions:

Autumn. J. Bullard, Cynthia A. Chestek, Parag G. Patil were responsible for creating the protocol for the literature search and inclusion criteria, analyzing and interpreting the data, and drafting the manuscript. Autumn. J. Bullard, Brianna C. Hutchison, and Jiseon Lee were responsible for reviewing abstracts and full-length papers for inclusion and data extraction. Autumn. J. Bullard, Brianna C. Hutchison, Jiseon Lee, Cynthia A. Chestek, Parag G. Patil were responsible for reviewing and approving the final manuscript. All authors approved the final version.

Conflict of Interest:

There were no conflicts of interest.

Corresponding Author:

This is the author manuscript accepted for publication and has undergone full peer review but has not been through the copyediting, typesetting, pagination and proofreading process, which may lead to differences between this version and the [Version of Record](#). Please cite this article as doi: [10.1111/ner.13069](https://doi.org/10.1111/ner.13069)

Parag G. Patil, MD PhD
University of Michigan
1500 E. Medical Center Drive, SPC 5338
Ann Arbor, MI 48109-5338
Email: pgpatil@med.umich.edu
Phone: 734-615-1520
Fax: 734-936-9294

Abstract

Introduction: A new age of neuromodulation is emerging: one of restorative neuroengineering and neuroprosthetics. As novel device systems move towards regulatory evaluation and clinical trials, a critical need arises for evidence-based identification of potential sources of hardware-related complications to assist in clinical trial design and mitigation of potential risk.

Objective and Methods: The objective of this systematic review is to provide a detailed safety analysis for future intracranial, fully implanted, modular neuroprosthetic systems. To achieve this aim, we conducted an evidence-based analysis of hardware complications for the most established clinical intracranial modular system, deep brain stimulation (DBS), as well as the most widely used intracranial human experimental system, the silicon-based (Utah) array.

Results: Of 2,328 publications identified, 240 articles met the inclusion criteria and were reviewed for DBS hardware complications. The most reported adverse events were infection (4.57%), internal pulse generator malfunction (3.25%), hemorrhage (2.86%), lead migration (2.58%), lead fracture (2.56%), skin erosion (2.22%), and extension cable malfunction (1.63%). Of 433

publications identified, 76 articles met the inclusion criteria and were reviewed for Utah array complications. Of 48 human subjects implanted with the Utah array, 18 have chronic implants. Few specific complications are described in the literature, hence implant duration served as a lower bound for complication-free operation. The longest reported duration of a person with a Utah array implant is 1,975 days (~5.4 years).

Conclusion: Through systematic review of the clinical and human-trial literature, our study provides the most comprehensive safety review to date of DBS hardware and human neuroprosthetic research using the Utah array. The evidence-based analysis serves as an important reference for investigators seeking to identify hardware-related safety data, a necessity to meet regulatory requirements and to design clinical trials for future intracranial, fully implanted, modular neuroprosthetic systems.

Keywords: deep brain stimulation, brain machine interface, Utah array, hardware, adverse events

Introduction

A new age of neuromodulation is emerging. Established open-loop neuromodulation systems treat a broad range of neurological network disorders, including Parkinson disease, tremor, dystonia, obsessive-compulsive disorder, epilepsy and pain. A newly approved closed-loop device provides responsive neural control of epilepsy. A growing body of literature suggests promise for neuromodulation to treat intractable depression and enhance recovery from spinal-cord injury. Experimental neuroprosthetic systems incorporate intracortical silicon-based arrays and networked sensing and stimulation modules to allow real-time neuroprosthetic control. As technology advances and the number of modular systems grow, a need arises to anticipate the potential safety features and shortcomings of future neuroprosthetic systems. Such analysis, based upon all available evidence, may be of value in satisfying prerequisites of regulatory requirements, formulating clinical-trial design and oversight, and fully informing patient consent.

The primary aim of this systematic review is to provide a detailed safety analysis to inform future intracranial, fully implanted and modular neuroprosthetic systems. To accomplish this aim, we examine the safety profiles of the most widespread intracranial clinical system, deep brain stimulation, as well as the most widespread intracranial human experimental system, the silicon-based (Utah) array, to identify safety considerations inherent to emerging modular neuroprosthetic systems and to derive the most reliable safety estimates possible for likely future neuroprosthetic systems. Our comprehensive and systematic review of the safety literature for deep brain stimulation and human trials of the Utah array provides greater detail and scope than many earlier

reviews by encompassing all indications for DBS and focusing upon the structural components of the DBS system. Detailed safety evaluation of experimental systems, such as the Utah array, has been difficult due to the dearth of complications reported in the literature, which focuses upon scientific and technological advances. However, indirect indicators exist. For example, we can estimate the duration of complication-free Utah array operation from reported periods of implant longevity in the literature. As a result, in addition to evaluating the potential safety of future modular intracranial device systems, this review also achieves an additional secondary goal of providing the most comprehensive safety and longevity review to date of human neuroprosthetic research using the Utah array.

Currently FDA-approved chronically implanted intracranial neuromodulation systems include deep brain stimulation (DBS) and responsive neurostimulation (RNS). DBS has been used for decades to treat movement disorders¹⁻³ and, more recently, to treat neuropsychiatric disorders and epilepsy⁴⁻⁶. DBS systems are modular, consisting of a multi-contact lead, an internal pulse generator (IPG), and an extension cable. The multi-contact lead is a depth electrode, typically 28 or 40 cm long, inserted into an intracranial target structure through a burr hole in the skull. The lead is secured at the skull entry point via a burr hole cover. The IPG is typically placed subcutaneously in the chest region. The extension cable connects the two via subcutaneous tunneling along the neck. As a related example, however relatively new and not as widely used, the responsive neurostimulation system for epilepsy (RNS, NeuroPace Inc.) is similarly modular,

consisting of cortical strip or depth leads connected to a cranially-implantable neurostimulator unit⁷.

To monitor and record brain electrical activity for neuroprosthetic applications, the commercially available Utah array (NeuroPort, Blackrock Microsystems, Inc.) is FDA approved for human implantation up to 30 days, or longer with an investigational device exemption. The NeuroPort Array consists of a 4.0 mm x 4.0 mm silicon-based microelectrode (Utah) array with 96 electrodes, extending 1.0 to 1.5 mm, and a wire bundle connecting the array to a pedestal (Figure 1). The pedestal penetrates the skin to provide electrical connectivity. A cable carries signals from the pedestal to front-end amplifiers and, ultimately, to a computer-based signal acquisition system for recording and decoding^{8,9}. Currently, the major limitation of the NeuroPort system is that tethering the pedestal to external hardware impedes mobility, constraining array use to laboratory settings. In addition, the transcutaneous pedestal violates the barrier integrity of the skin, potentially raising the risk of infection. Any clinically adopted neuroprosthetic system will require the Utah array to be connected to a fully implanted modular actuator system with the ability to record and respond to stimuli, similar to closed-loop DBS or RNS.

An example of such a system is the Networked Neural Prosthesis (NNP). The NNP is a fully implantable, modular functional electrical stimulation (FES) system which, in conjunction with implanted Utah arrays, could form a fully-implanted future neuroprosthetic system. The current NNP consists of multiple interconnected modules each with their own functionality responsible for recording myoelectric activity, providing intramuscular stimulation, and power.

Combinations of these modules can be distributed around the body to assist in a variety of functions lost by individuals due to spinal cord injury^{10,11}. The current-version NNP only records residual myoelectric activity, but it may be possible to add a neural recording module to record directly from the brain and facilitate cortical-controlled FES. Hence, a combined Utah Array-NNP system becomes a useful exemplar system for safety analysis. An overview of the exemplar, prototypical fully implantable, modular, neuromodulation system is shown in Figure 1B.

To understand potential hardware complications for such emerging systems, we have performed a systematic review focused on the hardware mechanisms of DBS failure as well as longevity or safety of the Utah array in humans. DBS is a well-established, fully implantable system that is similarly modular to our exemplar prototypical neuroprosthetic system. However, the electrode lead used in DBS is not directly comparable. Hence, major safety concerns and potential failure modes of the Utah Array-NNP system are hypothesized to be similar to those documented in both DBS systems and the Utah Array.

Materials and Methods

Search Strategy

A systematic review was conducted to identify the relevant literature on hardware complications of DBS, by searching the electronic databases: Pubmed, Embase, ClinicalTrials.gov, Scopus, and Cochrane's Library. The search was broken down into two concepts; device and risks. A comprehensive list of keywords was generated to capture all synonyms of DBS and risks, including both general terms and potential risks specific to DBS. This list was then optimized by

removing additional keywords that resulted in search results captured by the larger umbrella of another keyword. All device related keywords were grouped together by an OR operator and the same was done for the risk keywords. The device and risk groups were then merged with the AND operator to identify all articles with mention of DBS and some form of risk or complication in the title or abstract (Table 1).

A similar approach was taken to identify all articles including the use of the Utah array in humans in the title or abstract. The search was again separated into two concepts: device and patient, where a comprehensive list of all synonyms describing Utah arrays and humans was generated. Each separate concept group was combined through the OR operator and then together with the AND operator. In addition, a list of known principal investigators who have conducted experiments with humans implanted with Utah arrays were identified. This was incorporated at the end with the AND operator to help refine the search results (Table 2).

Study Selection

The search results were critiqued through a two-reviewer process. Each reviewer independently read the title and abstract of articles to screen for relevance. They were classified as either possibly relevant or clearly irrelevant. Articles deemed as clearly irrelevant by both reviewers were immediately excluded, and articles classified as possibly relevant by both reviewers were immediately included. The articles where the reviewers disagreed were reviewed again, discussed, and then resolved.

Predefined inclusion and exclusion criteria were created to further refine our search results to include only the papers within the scope of the review, shown in Figure 2. Selected articles were required to have clinical data from a primary study, report on bleeding, infection, or hardware complications related to DBS, and include a quantification of risk. Articles not reporting data on hardware complications, and articles reporting data solely on revision procedures were excluded, as well as case studies, review articles, and editorial letters. Only full-length articles available in English or easily translatable that met all criteria were eligible for inclusion. Two reviewers (AB and JL) independently read the full-length articles and assessed against the inclusion criteria. Articles that met all criteria according to both reviewers were included in this review. Articles that both reviewers agreed did not meet one or more of the criteria were excluded. The remaining articles where the reviewers disagreed were reviewed again, discussed, and then resolved.

Data Extraction

To avoid extraction errors, two reviewers independently extracted data from the eligible articles and any discrepancies were discussed and resolved. Infection, hemorrhage, skin erosion, and hardware failures related to malfunctions of the extension cable and IPG, and fracture or migration of the DBS electrode were the primary complications focused on in this review. For each eligible article the following data were extracted about the adverse event: incidence rate, location, the time of occurrence post initial surgery, if additional surgery was required, and if it resulted in a total explant of the system. Because there are relatively few centers hosting these clinical trials, publications often have studies with overlapping patients and multiple complications

occurring in the same patient. Articles with overlapping patients were identified and these patients were only counted once. Per patient data was extracted for each complication, therefore if one patient experienced more than one complication (i.e. infection and hemorrhage) both were accounted for. However, we did not use multiple occurrences of the same complication in one patient (i.e. reoccurring infections).

Results

DBS Search Results and Study Characteristics

Our initial database search yielded 2,328 DBS publications that contained our keywords and MeSH terms in either the title or abstract. After screening titles and abstracts, 479 potentially relevant articles were identified, and the full text was assessed against the inclusion criteria. Finally, 240 articles were chosen to be included in this meta-analysis^{12–124,124–249} (Figure 2). The remaining 239 articles were excluded for the following reasons: not DBS or related (n= 47), no quantification of risk (n=15), secondary revision procedures (n= 16), case studies, review articles, or editorial letters (n=145), not published in English (n= 5), full-length article unavailable (n=21). A total of 34,089 patients across articles were included in this analysis. Notably, only 7 hardware related deaths occurred within these patients. The per patient incidence rates of all complications and subgroups of their locations are reported in Table 3. Unfortunately, due to the lack of a comprehensive or standardized reporting system for complications there is missing information within the literature. All papers that reported complications did not also report details on the

location. In addition, complications experienced at multiple locations per patient have been accounted for. The results presented in Table 3 are a reflection of this mentioned.

Hemorrhage

Bleeding is always a major concern when implanting electrodes into the brain. Hemorrhage during and after surgery can lead to neurological damage and even death in severe cases. Of all the articles included in the study, 133 consisting of 19,389 patients reported on hemorrhage. The overall incidence rate was 2.86%. Out of all the papers in the literature that reported information on the location of hemorrhages, 86.9% of those were intracerebral hemorrhages (ICH), the most common during the duration of the implanted system. While hemorrhage is most likely to occur in the brain for these procedures, it also occurred in other areas throughout the body as well: at the site of the IPG (8.13 %) and along the extension cable (1.62 %). When a bleed occurs, it is usually reported to happen intraoperatively or within a few days of the surgery. Bleeding should always be taken seriously, however the risk posed by the reported hemorrhage ranged in severity and the action taken to resolve it. Some hemorrhages resolve on their own without any external intervention, while others are more serious and may require additional surgeries or other procedures. For the purpose of this review, any adverse events that required an additional surgery were deemed as serious adverse events. In serious cases, the device is normally explanted. Usually bleeds that occur outside of the brain can be resolved and then hardware can be re-implanted. In all the studies, there were only 6 reported deaths due to ICH (0.02%).

Infection

Second to bleeding, infection is often considered the next most dangerous adverse event to be cautious of in any surgical procedure, especially when there are foreign objects introduced inside the body, particularly the brain. With future modular systems expected to incorporate multiple implantable devices around the body, this is of major concern. There were 174 articles consisting of 27,072 patients that reported data on infection. It was the most frequently occurring adverse event, with an incidence rate 3.79% and was the main reason for ultimate device explanation. This is on par with other implantable devices such as the heart pacemaker. According to a systematic review by Persson et al., infections of cardiac implanted electrical devices range from 0.2 to 3.7%²⁵⁰. However, this incidence rate varies largely across studies making the true incidence rate hard to establish due to the lack of standard methods for reporting incidences. Additionally, there was only one reported death related to an untreated infection. The infections observed varied widely in their location, time of incidence relative to the initial surgery, and severity. Of the 104 papers that reported the location of where infections occurred, 44.2% were located at the site of the IPG, followed by the scalp or burr hole (17.8%), the connector and extension cable (13.6 %), and in the brain along the electrode lead (11.1 %). Of the 49 studies who reported time, infections are observed within the first 30 days of surgery (10.2%), however it can also occur months thereafter. Most cases of infections in the brain were reported early, within days, whereas infections that occurred around hardware outside of the brain took longer to appear. The majority of the reported infections were classified as severe, meaning they resulted in the patient

having additional surgery. However, although additional surgery was required, in 35.9% of cases the infection was resolved, and the hardware was ultimately re-implanted allowing DBS therapy to continue. Depending on the location of the infection only a subset of the system would be explanted and re-implanted. It was rare that the entire system had to be explanted and then re-implanted. However, if the infection was extremely severe and widespread the entire system would be permanently explanted (20.7%). This was typically seen in instances of infection that had tracked along the DBS electrode.

Skin Erosion

Skin erosion is defined here as any place where there was a breakage of the skin due to implanted hardware nearby. Erosion of the skin is most commonly seen over the IPG and on the scalp at the site of the burr hole or the connector where the extension cable and electrode meet. This was reported in a total of 2.46% of cases and was very commonly associated with infection. In 62.6% of cases where skin erosion was reported there was also a case of infection reported near the site of erosion. An additional surgery or procedure was required in 25 % of cases with skin erosion. Typically, wound debridement or surgical closure was used to repair skin erosion, however some instances required revisions and re-implantation of hardware. The more severe cases stemmed from erosion around the burr hole or the connector site and, where the electrode lead or extension cable was replaced. There were only 18 cases of skin erosion (9%) that led to the permanent explant of the entire system.

Other Hardware Failures

In addition to the previously mentioned hardware failures, there were also malfunctions of the extension cable and IPG, and fracture or migration of the DBS electrode. This includes most of the complications due to DBS hardware that are potentially relevant to future chronic tethered devices. Overall, IPG malfunction occurred 2.33% of the time, extension cable malfunction occurred 1.95% of the time, lead fracture occurred 2.53% of the time, and lead migration occurred 3.49% of the time. These are typically not dangerous in and of themselves, though in a single case, a patient was electrically shocked due to the malfunction of the IPG¹²³. In most cases however, these are complications that usually require additional routine surgeries, which do have their own associated risks. In 22.6 % of reported cases (including the electrical shock incident), they were able to revise and fix. In only 2 cases was a complete explantation necessary.

Utah Array Search Results and Study Characteristics

Our initial search identified 433 articles, which resulted in 76 articles after screening where humans had been implanted with the Utah array (Figure 3). The Utah array, a 96-channel microelectrode array (Blackrock Microsystems), has been implanted intracortically in a total of 48 subjects as of September 2018. This consists of patients implanted for epilepsy and other intraoperative opportunities where tissue would have been ablated, and patients with paralysis. The demographic of Utah array implants is dominated by acute cases, usually to study epilepsy, anesthesia, or cognition, memory or language. A smaller subset of the cases are chronic implants, used to study brain machine interfaces for motor control of prosthesis and stimulation for sensory

mapping. Of the 48 people implanted with the Utah array, 30 were implanted for less than 30 days and 18 people were implanted chronically for more than 30 days^{8,9,251–295}. We have identified all the senior authors and the sites, to our knowledge, involved in studies with human implants in Table 4.

The longest reported duration of a person with a Utah array implant is at least 1,975 days (~5.4 years), shown in Figure 4 and Table 5. S3, a participant in the BrainGate2 pilot clinical trial, was first implanted November 30, 2005, and while it has not been reported that her array has actually been explanted, it was documented that she completed her enrollment in the BrainGate2 clinical trial²⁵⁹. Of the chronic cases, there was only one report of an explanted Utah array in the literature. Participant S1 at the University of Pittsburgh was implanted for 987 days and then explanted due to skin retraction around the pedestals. However, it was reported that there was no sign of infection. The only other mention of the safety of the Utah array implant was with participant EGS at California Institute of Technology. They reported that there was no device related adverse events to occur throughout their study^{278,296}. Table 5 shows the breakdown of chronic patients across different studies and the lengths of reported implantation. The end of the reported duration of the implant does not mean that the Utah array has failed, however just the last reported published date for that participant. There have been a reported 9,254 of total published implant days.

Discussion

The safety surrounding neuromodulation technology is a critical question for both established and emerging systems. Hardware-related complications can result in potential injury to the patient, repeated surgical procedures, and reduced clinical efficacy. In this comprehensive, systematic review we found that DBS had an incidence rate of 19.04% for total hardware related complications. The most common adverse events were infection, followed by lead migration, lead fracture or failure, hemorrhage, skin erosion, IPG malfunction, and malfunction of the extension cable. The rates of complications reported here are similar to those found in prior studies and other notable systematic reviews^{290,297-301}. The most recent and closely related DBS review of hardware complications by Jitkriksadakul et al., investigated the differences in incidence rates across indications for DBS. They used this information to identify patients more at risk based on their indication in order to inform them prior to surgery²⁹⁰. While we have similar rates of complications, our review did not focus on specific indications. As a result, our search structure consisted of different keywords and more databases. Therefore, we were able to include many more papers in our analyses, which offered more data points for a more comprehensive review. Another recent review of DBS complications done by the Neurostimulation Appropriateness Consensus Committee (NACC), developed recommendations to improve patient safety and reduce the risk of injury associated with neuromodulation devices²⁹⁷. This review focused on DBS as a subset of many other neurostimulation therapies. Although we experienced slightly higher

incidence rates than reported here, according to this review we are still within accepted rates of invasive brain procedures. It is also unclear how many patients were included in this review.

Using the information about DBS hardware complications, we are able to infer potential safety challenges that future intracranial, fully implanted and modular neuroprosthetic systems may face and begin the discussion on how to plan for and mitigate these risks when developing a clinical trial. We have identified the following adverse events to be potentially most salient to emerging systems: hemorrhage, infections, skin erosions, and malfunctions of the extension cable.

Hemorrhage

Based on this review, bleeding in the brain during or immediately after the surgery is the most critical adverse event that can risk the safety of the patient. In the DBS cases reporting ICH, the clot most often tracked along the lead and extended into the brain. Bleeding was not typically seen on the surface of the brain. The biggest difference between DBS and future neural implants is the type of electrode used. Since the Utah array is currently the only device used chronically in humans, and one of the arrays most likely to be incorporated into future modular devices, we will focus on this array. While a DBS lead extends several centimeters into the brain, the Utah array is much shallower, inserting only 1.5 mm into the brain. Therefore, if most of the bleeds that occur in DBS are not on the surface, it is likely that the DBS lead is perturbing blood vessels deeper in the brain that the Utah array would miss³⁰². It is possible that the incidence rate of ICH experienced in DBS could be an overestimate of what we would see in future intracranial, modular neuroprosthetic systems. In the case of both DBS and the Utah array for future devices, additional

action can be taken to help possibly reduce the incidence rate. Studies that experienced lower ICH rates attributed it to physicians' cautious and proper use of the equipment and insertion of electrodes, avoiding major vasculature on the brains' surface. Imaging can also be performed post-surgery as a means of proactive monitoring to detect any small or asymptomatic ICHs³⁰³. While bleeds can be very serious, they are expected, and protocols have been established to manage them.

Infection

Infections pose the highest risk for terminal explantation of the DBS entire system (20.7%). Reported infections were predominantly found at the site of the IPG, followed by the burr hole, and then the extension cable. While in DBS there is only one IPG, in the case of the NNP and other future modular systems, there will be many more "IPGs" and extension cables routed throughout the body. This has the potential to increase the rate at which infections arise and possibly affect their ability to spread throughout the body. Infections in DBS are typically managed with antibiotics, or portions of the system may be explanted while antibiotics is administered and then successfully re-implanted. Re-implantation is the main treatment for infection in such systems. While they are categorized as serious adverse events, they are very common. Future modular systems may have the potential for increased incidence of infection due to the rise in the amount of modular devices that can be implanted in a single system. However, while some infections may be inevitable, it is important to note that this does not necessarily have to be a failure of the system. As seen in DBS, revision procedures occur frequently without ultimately ending the therapy. Understanding where the infections are most likely to occur and a potential time frame in which

they occur more frequently relative to the initial surgery allows for management protocols to be developed within a clinical trial. Physicians can anticipate these complications and monitor patients more closely in areas more predisposed to infection as well as search for symptoms more deliberately time periods where infections typically spike. While this may not necessarily reduce the overall infections rate, being proactive may reduce the rate at which infection leads to system explant or a more severe complication. Studies have also been performed to investigate different antibiotics and the administration of them at different time points throughout the lifetime of the implant to reduce the infection rate³⁰⁴⁻³⁰⁶.

Skin Erosion

Skin erosion, while occurring less frequently, commonly occurs with infection. When there is erosion or breakage of the skin the area becomes susceptible and leads to infection of the area. Since skin erosion was most likely to occur over the IPG, a modular system with multiple IPGs, as proposed with the NNP and potential future devices, may experience an increased incidence rate than reported in DBS. Knowing this we can begin to investigate surgical procedures for the best placement of these IPGs or modular devices throughout the body and how to implant them deeper as to reduce the risk of erosion. Similar to infection, cases of skin erosion are also categorized as serious, requiring a surgical revision. This may be treated with wound debridement but is most likely to lead to explantation of a portion or the whole system.

Extension Cable Malfunctions

Although there was a low incidence rate of extension cable malfunctions in comparison to the other adverse events in DBS, this is vital information. The addition of a wire to connect the Utah array to an implantable module is where most of the uncertainty lies with the safety of future intracranial, modular devices. Malfunctions of the extension cable usually involve Twiddler's syndrome or bowstringing which can lead to fracture of the cable or displacement of the electrode. One of the biggest risks with future Utah array tethered devices is that tension on the extension cable has the potential to dislodge the implanted array. However, of all the reported extension cable malfunctions, none led to the displacement of a DBS electrode, likely due to anchoring at the burr hole. All complications were due to breakage of the cable, which were then replaced. Most of the complications with the extension cable occur in the neck, however with future Utah array tethered devices the module directly connected to the Utah array will be secured to the skull. This smaller device may decrease the risk for potential electrode array dislodgement.

Utah Array Safety and Longevity

Utah arrays have been implanted in substantially fewer individuals, for shorter duration, and the literature does not contain much about the safety of these implants as compared to DBS, which has a sufficiently large population to reveal rare safety events. Since there has been no publication to date that explicitly discusses the risks or adverse events that occur in chronic human implants, we systematically reviewed all the published literature to address this topic. We identified 48 individuals implanted with a Utah array and determined the duration of implantation

at the time of the study. This represents a starting point for a safety dataset of all FDA monitored studies. Acute studies are more common and have been the dominant contributor to the population of subjects with Utah arrays. While long-term effects are not observed in these subjects, observations from short term studies help to estimate intracerebral hemorrhage, although not explicitly mentioned or discussed in any papers we reviewed. Infection typically prompts explantation of the array, so array longevity provides a lower bound on the period of time without serious infection or other adverse event. The mean number of days of Utah array implantation across all participants was 578. This underestimates implant time. With the exception of one paper, no study reported array explantation. In the absence of complication, participants typically remain implanted following the conclusion of the study.

Because DBS systems are clinically available and have been implanted in many patients, incidence rates of DBS adverse events serve as a risk profile benchmark for future Utah array modular systems. Understanding the potential risks and failure modes of a device and how many people must be observed to witness such risks could be useful information when designing a clinical trial. For example, we conducted a power analysis to estimate the number of patients implanted with the Utah array needed to see similar incidence rates as DBS. We found that it would take a very large amount of people within a clinical trial before we would begin to see complications with similar incidence rates as DBS systems. By contrast, if Utah array tethered devices introduced 5x the risk of DBS we would be able to see it much earlier and with fewer people (Table 6). Given the low incidence rate of infection in DBS, we would not have expected

to see any complications in cases with as few as 18 chronically implanted Utah arrays. It is also notable that these Utah arrays were all percutaneous and would likely have a higher infection rate than a fully implanted system.

The large number of people needed to do a true safety study is far off. However, few individuals are required to demonstrate the efficacy of neuroprosthetic systems. Efficacy may therefore have to be established before safety studies can begin. Early feasibility human trials would be beneficial in not only moving the needle in technology surrounding the future of implantable intracortical devices, but also helping to increase the population of people with these devices for a comprehensive understanding of safety over time.

Study Limitations

This review focused primarily on the Utah array, using the existing intracranial DBS system as a benchmark for safety data of future implantable neuroprostheses systems that will employ the Utah array for BMI applications. However, reviews of other existing intracranial neuromodulation devices such as the responsive neurostimulation (RNS) system may add value as well. In addition, there is currently no standardized method for reporting adverse events related to DBS hardware or Utah array safety, thus this review is incomplete. There were some DBS articles that contained data on hardware-related complications that were excluded because either the information was too general (i.e. grouping infections and skin erosions and other skin complications together) or the data was per electrode lead and not per patient. Papers also generally lacked the time in which adverse events took place. In addition, papers discussing human research

with the Utah array did not disclose any adverse events and some lacked important details such as the implantation date. Due to the lack of data reported in literature discussing human research using the Utah array, we determined in order to continue to establish a database of safety data for future and emerging neuromodulation technologies we need to be gathering detailed information about the implantations during experiments such as implant and explant dates, detailed per patient adverse events, the time frame in which adverse events occurred, as well as the responsive action. Access to a detailed database of adverse events involving intracranial, modular systems will not only influence the design of future devices, but also serve as a reliable reference for investigators seeking to successfully advance their device through the regulatory process towards a clinical trial.

As a result of the poor structure and overall lack of reported complications across the field, we focused on the hardware-related complications that could provide the most data in order to produce a reliable review and serve as a benchmark to infer the most about future intracranial, modular devices. We identified hemorrhage, infection, skin erosion, and other malfunctions, however these are certainly not the only safety risks future devices have the potential to face. Safety of future devices cannot be fully assessed by looking at the incidence rate of these categories alone, yet this is a quantifiable starting point.

When implanting electrodes in the brain there is always a risk of neurological damage or neurobehavioral effects experienced by the patient. Neurobehavioral effects reported with DBS are most often linked to the stimulation, therefore not directly comparable to the Utah array, which would be used for recording. However, these risks persist with the Utah array as well. Implanted

Utah arrays are known to result in reactive tissue responses including inflammation, glial scarring, and neuronal death or migration near the site of the electrode, seen in the histological data^{307–312}. It is possible that this histological response could potentially result in functional deficits, however, because current chronic studies with these arrays include patients already with severe loss of motor functions, we are unable to measure any unintended damage to physiological functions in these patients. There has been very little research done to investigate the potential motor deficits caused by the implantation of chronic intracortical electrodes in motor cortex. In a study done by Goss-Varley et al., it was shown that healthy rats implanted with chronic microelectrodes in the motor cortex resulted in deficits effecting fine motor function³¹³. Implanted animals performed the ladder task significantly slower with an increased number of paw slips than the non-implanted control animals. It was reported that while graphically significant, visually watching the animals yielded less conclusive results. Contrarily, many able-bodied rhesus macaques have been implanted for research and shown no signs of any motor deficits. This behavioral response has also been shown in studies investigating neuronal death from moderate traumatic brain injury and resection in rats and similarly in humans, where moderate motor deficits recovered over time or were unnoticeable^{314–316}. There are considerable complexities of the brain, therefore ultimately, safety questions will be best addressed in a sufficiently powered, prospective clinical trial. In the meantime, pilot studies will continue to contribute valuable data points over time by including implant and explant dates, the time frame of experiments as well as any physiological and neurobehavioral effects.

Conclusion

We identify and quantitatively summarize the hardware-related complications of deep brain stimulation that can be used to estimate potential safety risks of future modular, implantable neuroprosthetic systems. In addition, we collect longevity data for human Utah array implants. The evidence-based analysis serves as an important benchmark for investigators seeking safety data on intracranial, modular systems. As new devices are developed this information can be used to identify and assess potential hardware failures in advance. These complications can ultimately compromise the safety of the patient, therefore anticipating future risks allows physicians and engineers to develop specific surgical and risk mitigation protocols within their clinical trials. In addition, this safety data is essential to the FDA and should be included to develop a strong portfolio to meet regulatory requirements and help progress towards clinical trials.

References

1. Weaver FM, Follett K, Stern M, et al. Bilateral deep brain stimulation vs best medical therapy for patients with advanced Parkinson disease: a randomized controlled trial. *JAMA*. 2009;301(1):63-73. doi:10.1001/jama.2008.929.
2. Rodríguez Cruz PM, Vargas A, Fernández-Carballal C, Garbizu J, De La Casa-Fages B, Grandas F. Long-term Thalamic Deep Brain Stimulation for Essential Tremor: Clinical Outcome and Stimulation Parameters. *Mov Disord Clin Pract*. 2016;3(6):567-572. doi:10.1002/mdc3.12337.
3. Ackermans L, Duits A, van der Linden C, et al. Double-blind clinical trial of thalamic stimulation in patients with Tourette syndrome. *Brain*. 2011;134(3):832-844. doi:10.1093/brain/awq380.
4. Abreu V, Vaz R, Rebelo V, et al. Thalamic Deep Brain Stimulation for Neuropathic Pain: Efficacy at Three Years' Follow-Up. *Neuromodulation Technol Neural Interface*. 2017;20(5):504-513. doi:10.1111/ner.12620.
5. Ooms P, Mantione M, Figeo M, Schuurman PR, van den Munckhof P, Denys D. Deep brain stimulation for obsessive-compulsive disorders: long-term analysis of quality of life. *J Neurol Neurosurg Psychiatry*. 2014;85(2):153-158. doi:10.1136/jnnp-2012-302550.
6. Kim SH, Lim SC, Kim J, Son B-C, Lee KJ, Shon Y-M. Long-term follow-up of anterior thalamic deep brain stimulation in epilepsy: A 11-year, single center experience. *Seizure*. 2017;52:154-161. doi:10.1016/j.seizure.2017.10.009.
7. Heck CN, King-Stephens D, Massey AD, et al. Two-year seizure reduction in adults with medically intractable partial onset epilepsy treated with responsive neurostimulation: final results of the RNS System Pivotal trial. *Epilepsia*. 2014;55(3):432-441. doi:10.1111/epi.12534.
8. Hochberg LR, Serruya MD, Friehs GM, et al. Neuronal ensemble control of prosthetic devices by a human with tetraplegia. *Nature*. 2006;442(7099):164-171. doi:10.1038/nature04970.
9. Truccolo W, Friehs GM, Donoghue JP, Hochberg LR. Primary motor cortex tuning to intended movement kinematics in humans with tetraplegia. *J Neurosci*. 2008;28(5):1163-1178. doi:10.1523/JNEUROSCI.4415-07.2008.
10. Kilgore KL, Peckham PH, Crish TJ, Smith B. United States Patent. 2007;1(12):0-3. doi:10.1016/j.(73).
11. Smith B, Crish TJ, Buckett JR, Kilgore KL, Peckham PH. Development of an implantable networked neuroprosthesis. *2nd Int IEEE EMBS Conf Neural Eng*. 2005;2005:454-457. doi:10.1109/CNE.2005.1419657.

12. Hilliard JD, Bona A, Vaziri S, Walz R, Okun MS, Foote KD. 138 Delayed Scalp Erosion After Deep Brain Stimulation Surgery. *Neurosurgery*. 2016;63(CN_suppl_1):156. doi:10.1227/01.neu.0000489708.21831.66.
13. Sixel-Döring F, Trenkwalder C, Kappus C, Hellwig D. Skin complications in deep brain stimulation for Parkinson's disease: frequency, time course, and risk factors. *Acta Neurochir (Wien)*. 2010;152(2):195-200. doi:10.1007/s00701-009-0490-3.
14. Kochanski RB, Nazari P, Sani S. The Utility of Vancomycin Powder in Reducing Surgical Site Infections in Deep Brain Stimulation Surgery. *Oper Neurosurg (Hagerstown, Md)*. February 2018. doi:10.1093/ons/ox293.
15. Messina G, Rizzi M, Dones I, Franzini A. Cosmetic posterior implant of internal pulse generators in deep brain stimulation procedures: technical report. *Neuromodulation*. 2014;17(8):729-730. doi:10.1111/ner.12156.
16. Motlagh MG, Smith ME, Landeros-Weisenberger A, et al. Lessons Learned from Open-label Deep Brain Stimulation for Tourette Syndrome: Eight Cases over 7 Years. *Tremor Other Hyperkinet Mov (N Y)*. 2013;3. <http://www.ncbi.nlm.nih.gov/pubmed/24255802>. Accessed October 1, 2018.
17. Fenoy AJ, Simpson RK. Risks of common complications in deep brain stimulation surgery: management and avoidance. *J Neurosurg*. 2014;120(1):132-139. doi:10.3171/2013.10.JNS131225.
18. Baizabal-Carvallo JF, Kagnoff MN, Jimenez-Shahed J, Fekete R, Jankovic J. The safety and efficacy of thalamic deep brain stimulation in essential tremor: 10 years and beyond. *J Neurol Neurosurg Psychiatry*. 2014;85(5):567-572. doi:10.1136/jnnp-2013-304943.
19. Panov F, Gologorsky Y, Connors G, Tagliati M, Miravite J, Alterman RL. Deep brain stimulation in DYT1 dystonia: a 10-year experience. *Neurosurgery*. 2013;73(1):86-93; discussion 93. doi:10.1227/01.neu.0000429841.84083.c8.
20. Petrossian MT, Paul LR, Multhaupt-Buell TJ, et al. Pallidal deep brain stimulation for dystonia: a case series. *J Neurosurg Pediatr*. 2013;12(6):582-587. doi:10.3171/2013.8.PEDS13134.
21. Pepper J, Zrinzo L, Mirza B, Foltynie T, Limousin P, Hariz M. The risk of hardware infection in deep brain stimulation surgery is greater at impulse generator replacement than at the primary procedure. *Stereotact Funct Neurosurg*. 2013;91(1):56-65. doi:10.1159/000343202.
22. Odekerken VJJ, van Laar T, Staal MJ, et al. Subthalamic nucleus versus globus pallidus bilateral deep brain stimulation for advanced Parkinson's disease (NSTAPS study): a randomised controlled trial. *Lancet Neurol*. 2013;12(1):37-44. doi:10.1016/S1474-4422(12)70264-8.

23. Leone M, Franzini A, Proietti Cecchini A, Bussone G. Success, failure, and putative mechanisms in hypothalamic stimulation for drug-resistant chronic cluster headache. *Pain*. 2013;154(1):89-94. doi:10.1016/j.pain.2012.09.011.
24. Ostrem JL, Galifianakis NB, Markun LC, et al. Clinical outcomes of PD patients having bilateral STN DBS using high-field interventional MR-imaging for lead placement. *Clin Neurol Neurosurg*. 2013;115(6):708-712. doi:10.1016/j.clineuro.2012.08.019.
25. Zhang J, Wang T, Zhang C-C, et al. The safety issues and hardware-related complications of deep brain stimulation therapy: a single-center retrospective analysis of 478 patients with Parkinson's disease. *Clin Interv Aging*. 2017;12:923-928. doi:10.2147/CIA.S130882.
26. Dlouhy BJ, Reddy A, Dahdaleh NS, Greenlee JDW. Antibiotic impregnated catheter coverage of deep brain stimulation leads facilitates lead preservation after hardware infection. *J Clin Neurosci*. 2012;19(10):1369-1375. doi:10.1016/j.jocn.2012.02.008.
27. Guridi J, Rodriguez-Oroz MC, Alegre M, Obeso JA. Hardware complications in deep brain stimulation: electrode impedance and loss of clinical benefit. *Parkinsonism Relat Disord*. 2012;18(6):765-769. doi:10.1016/j.parkreldis.2012.03.014.
28. Mendes Martins V, Coste J, Derost P, et al. [Surgical complications of deep brain stimulation: clinical experience of 184 cases]. *Neurochirurgie*. 2012;58(4):219-224. doi:10.1016/j.neuchi.2012.02.004.
29. Bourne SK, Conrad A, Konrad PE, Neimat JS, Davis TL. Ventricular width and complicated recovery following deep brain stimulation surgery. *Stereotact Funct Neurosurg*. 2012;90(3):167-172. doi:10.1159/000338094.
30. Fenoy AJ, Simpson RK. Management of device-related wound complications in deep brain stimulation surgery. *J Neurosurg*. 2012;116(6):1324-1332. doi:10.3171/2012.1.JNS111798.
31. Son B, Han S, Choi Y, et al. Transaxillary subpectoral implantation of implantable pulse generator for deep brain stimulation. *Neuromodulation*. 2012;15(3):260-6; discussion 266. doi:10.1111/j.1525-1403.2011.00420.x.
32. Charles PD, Dolhun RM, Gill CE, et al. Deep brain stimulation in early Parkinson's disease: enrollment experience from a pilot trial. *Parkinsonism Relat Disord*. 2012;18(3):268-273. doi:10.1016/j.parkreldis.2011.11.001.
33. Harries AM, Kausar J, Roberts SAG, et al. Deep brain stimulation of the subthalamic nucleus for advanced Parkinson disease using general anesthesia: long-term results. *J Neurosurg*. 2012;116(1):107-113. doi:10.3171/2011.7.JNS11319.
34. Piacentino M, Pilleri M, Bartolomei L. Hardware-related infections after deep brain stimulation surgery: review of incidence, severity and management in 212 single-center procedures in the first year after implantation. *Acta Neurochir (Wien)*. 2011;153(12):2337-

2341. doi:10.1007/s00701-011-1130-2.
35. Bhatia R, Dalton A, Richards M, Hopkins C, Aziz T, Nandi D. The incidence of deep brain stimulator hardware infection: the effect of change in antibiotic prophylaxis regimen and review of the literature. *Br J Neurosurg*. 2011;25(5):625-631. doi:10.3109/02688697.2011.566384.
 36. Levy RM, Lamb S, Adams JE. Treatment of chronic pain by deep brain stimulation: long term follow-up and review of the literature. *Neurosurgery*. 1987;21(6):885-893. <http://www.ncbi.nlm.nih.gov/pubmed/3325851>. Accessed September 28, 2018.
 37. Oyama G, Okun MS, Zesiewicz TA, et al. Delayed clinical improvement after deep brain stimulation-related subdural hematoma. Report of 4 cases. *J Neurosurg*. 2011;115(2):289-294. doi:10.3171/2011.3.JNS101424.
 38. Park JH, Chung SJ, Lee CS, Jeon SR. Analysis of hemorrhagic risk factors during deep brain stimulation surgery for movement disorders: comparison of the circumferential paired and multiple electrode insertion methods. *Acta Neurochir (Wien)*. 2011;153(8):1573-1578. doi:10.1007/s00701-011-0997-2.
 39. Fily F, Haegelen C, Tattevin P, et al. Deep brain stimulation hardware-related infections: a report of 12 cases and review of the literature. *Clin Infect Dis*. 2011;52(8):1020-1023. doi:10.1093/cid/cir065.
 40. Ostrem JL, Racine CA, Glass GA, et al. Subthalamic nucleus deep brain stimulation in primary cervical dystonia. *Neurology*. 2011;76(10):870-878. doi:10.1212/WNL.0b013e31820f2e4f.
 41. Chang WS, Kim HY, Kim JP, Park YS, Chung SS, Chang JW. Bilateral subthalamic deep brain stimulation using single track microelectrode recording. *Acta Neurochir (Wien)*. 2011;153(5):1087-1095. doi:10.1007/s00701-011-0953-1.
 42. Ackermans L, Duits A, van der Linden C, et al. Double-blind clinical trial of thalamic stimulation in patients with Tourette syndrome. *Brain*. 2011;134(Pt 3):832-844. doi:10.1093/brain/awq380.
 43. Doshi PK. Long-term surgical and hardware-related complications of deep brain stimulation. *Stereotact Funct Neurosurg*. 2011;89(2):89-95. doi:10.1159/000323372.
 44. Nazzaro JM, Lyons KE, Honea RA, et al. Head positioning and risk of pneumocephalus, air embolism, and hemorrhage during subthalamic deep brain stimulation surgery. *Acta Neurochir (Wien)*. 2010;152(12):2047-2052. doi:10.1007/s00701-010-0776-5.
 45. Follett KA, Weaver FM, Stern M, et al. Pallidal versus subthalamic deep-brain stimulation for Parkinson's disease. *N Engl J Med*. 2010;362(22):2077-2091. doi:10.1056/NEJMoa0907083.

46. Burdick AP, Fernandez HH, Okun MS, Chi Y-Y, Jacobson C, Foote KD. Relationship between higher rates of adverse events in deep brain stimulation using standardized prospective recording and patient outcomes. *Neurosurg Focus*. 2010;29(2):E4. doi:10.3171/2010.4.FOCUS10100.
47. Sydow O, Thobois S, Alesch F, Speelman JD. Multicentre European study of thalamic stimulation in essential tremor: a six year follow up. *J Neurol Neurosurg Psychiatry*. 2003;74(10):1387-1391. <http://www.ncbi.nlm.nih.gov/pubmed/14570831>. Accessed September 27, 2018.
48. Moro E, Lozano AM, Pollak P, et al. Long-term results of a multicenter study on subthalamic and pallidal stimulation in Parkinson's disease. *Mov Disord*. 2010;25(5):578-586. doi:10.1002/mds.22735.
49. Nunta-Aree S, Sitthinamsuwan B, Boonyapisit K, Pisarnpong A. SW2-year outcomes of subthalamic deep brain stimulation for idiopathic Parkinson's disease. *J Med Assoc Thai*. 2010;93(5):529-540. <http://www.ncbi.nlm.nih.gov/pubmed/20524438>. Accessed October 2, 2018.
50. Bhatia S, Zhang K, Oh M, Angle C, Whiting D. Infections and hardware salvage after deep brain stimulation surgery: a single-center study and review of the literature. *Stereotact Funct Neurosurg*. 2010;88(3):147-155. doi:10.1159/000303528.
51. Maldonado IL, Roujeau T, Cif L, et al. Magnetic resonance-based deep brain stimulation technique: a series of 478 consecutive implanted electrodes with no perioperative intracerebral hemorrhage. *Neurosurgery*. 2009;65(6 Suppl):196-201; discussion 201-2. doi:10.1227/01.NEU.0000342404.14347.FB.
52. Chan DTM, Zhu XL, Yeung JHM, et al. Complications of deep brain stimulation: a collective review. *Asian J Surg*. 2009;32(4):258-263. doi:10.1016/S1015-9584(09)60404-8.
53. Nahas Z, Anderson BS, Borckardt J, et al. Bilateral epidural prefrontal cortical stimulation for treatment-resistant depression. *Biol Psychiatry*. 2010;67(2):101-109. doi:10.1016/j.biopsych.2009.08.021.
54. Ben-Haim S, Asaad WF, Gale JT, Eskandar EN. Risk factors for hemorrhage during microelectrode-guided deep brain stimulation and the introduction of an improved microelectrode design. *Neurosurgery*. 2009;64(4):754-62; discussion 762-3. doi:10.1227/01.NEU.0000339173.77240.34.
55. Xiaowu H, Xiufeng J, Xiaoping Z, et al. Risks of intracranial hemorrhage in patients with Parkinson's disease receiving deep brain stimulation and ablation. *Parkinsonism Relat Disord*. 2010;16(2):96-100. doi:10.1016/j.parkreldis.2009.07.013.
56. Miller JP, Acar F, Burchiel KJ. Significant reduction in stereotactic and functional

- neurosurgical hardware infection after local neomycin/polymyxin application. *J Neurosurg.* 2009;110(2):247-250. <http://www.ncbi.nlm.nih.gov/pubmed/19263587>. Accessed October 2, 2018.
57. Gervais-Bernard H, Xie-Brustolin J, Mertens P, et al. Bilateral subthalamic nucleus stimulation in advanced Parkinson's disease: five year follow-up. *J Neurol.* 2009;256(2):225-233. doi:10.1007/s00415-009-0076-2.
 58. Allert N, Jusciute E, Weirich O, Daryaeitabar M, Nolden BM, Karbe H. Long-Term Stability of Short Circuits in Deep Brain Stimulation. *Neuromodulation.* 2018;21(6):562-567. doi:10.1111/ner.12709.
 59. Bhatia S, Oh M, Whiting T, Quigley M, Whiting D. Surgical complications of deep brain stimulation. A longitudinal single surgeon, single institution study. *Stereotact Funct Neurosurg.* 2008;86(6):367-372. doi:10.1159/000175799.
 60. Gorgulho A, Juillard C, Uslan DZ, et al. Infection following deep brain stimulator implantation performed in the conventional versus magnetic resonance imaging–equipped operating room. *J Neurosurg.* 2009;110(2):239-246. doi:10.3171/2008.6.17603.
 61. O'Sullivan D, Pell M. Long-term follow-up of DBS of thalamus for tremor and STN for Parkinson's disease. *Brain Res Bull.* 2009;78(2-3):119-121. doi:10.1016/j.brainresbull.2008.09.001.
 62. Delavallée M, Abu-Serieh B, de Tournaninoff M, Raftopoulos C. Subdural motor cortex stimulation for central and peripheral neuropathic pain: a long-term follow-up study in a series of eight patients. *Neurosurgery.* 2008;63(1):101-108. doi:10.1227/01.NEU.0000335076.24481.B6.
 63. Sillay KA, Larson PS, Starr PA. Deep brain stimulator hardware-related infections: incidence and management in a large series. *Neurosurgery.* 2008;62(2):360-367. doi:10.1227/01.neu.0000316002.03765.33.
 64. Cersosimo MG, Raina GB, Piedimonte F, Antico J, Graff P, Micheli FE. Pallidal surgery for the treatment of primary generalized dystonia: Long-term follow-up. *Clin Neurol Neurosurg.* 2008;110(2):145-150. doi:10.1016/j.clineuro.2007.10.003.
 65. Sansur CA, Frysinger RC, Pouratian N, et al. Incidence of symptomatic hemorrhage after stereotactic electrode placement. *J Neurosurg.* 2007;107(5):998-1003. doi:10.3171/JNS-07/11/0998.
 66. Alterman RL, Miravite J, Weisz D, Shils JL, Bressman SB, Tagliati M. Sixty hertz pallidal deep brain stimulation for primary torsion dystonia. *Neurology.* 2007;69(7):681-688. doi:10.1212/01.wnl.0000267430.95106.ff.
 67. Seijo FJ, Alvarez-Vega MA, Gutierrez JC, Fdez-Glez F, Lozano B. Complications in subthalamic nucleus stimulation surgery for treatment of Parkinson's disease. Review of

- 272 procedures. *Acta Neurochir (Wien)*. 2007;149(9):867-876. doi:10.1007/s00701-007-1267-1.
68. Chou Y-C, Lin S-Z, Hsieh WA, et al. Surgical and hardware complications in subthalamic nucleus deep brain stimulation. *J Clin Neurosci*. 2007;14(7):643-649. doi:10.1016/j.jocn.2006.02.016.
69. Zsigmond P, Hemm-Ode S, Wårdell K. Optical Measurements during Deep Brain Stimulation Lead Implantation: Safety Aspects. *Stereotact Funct Neurosurg*. 2017;95(6):392-399. doi:10.1159/000484944.
70. Voges J, Hilker R, Bötzel K, et al. Thirty days complication rate following surgery performed for deep-brain-stimulation. *Mov Disord*. 2007;22(10):1486-1489. doi:10.1002/mds.21481.
71. Vesper J, Haak S, Ostertag C, Nikkhah G. Subthalamic nucleus deep brain stimulation in elderly patients – analysis of outcome and complications. *BMC Neurol*. 2007;7(1):7. doi:10.1186/1471-2377-7-7.
72. Paluzzi A, Belli A, Bain P, Liu X, Aziz TM. Operative and hardware complications of deep brain stimulation for movement disorders. *Br J Neurosurg*. 2006;20(5):290-295. doi:10.1080/02688690601012175.
73. Kupsch A, Benecke R, Müller J, et al. Pallidal Deep-Brain Stimulation in Primary Generalized or Segmental Dystonia. *N Engl J Med*. 2006;355(19):1978-1990. doi:10.1056/NEJMoa063618.
74. Greenberg BD, Malone DA, Friehs GM, et al. Three-Year Outcomes in Deep Brain Stimulation for Highly Resistant Obsessive–Compulsive Disorder. *Neuropsychopharmacology*. 2006;31(11):2384-2393. doi:10.1038/sj.npp.1301165.
75. Amirnovin R, Williams ZM, Cosgrove GR, Eskandar EN. Experience with Microelectrode Guided Subthalamic Nucleus Deep Brain Stimulation. *Oper Neurosurg*. 2006;58(1 Suppl):ONS-96-ONS-102. doi:10.1227/01.NEU.0000192690.45680.C2.
76. Lee JYK, Kondziolka D. Thalamic deep brain stimulation for management of essential tremor. *J Neurosurg*. 2005;103(3):400-403. doi:10.3171/jns.2005.103.3.0400.
77. Kawakami N, Jessen H, Bordini B, Gallagher C, Klootwyk J, Garell CP. Deep brain stimulation of the subthalamic nucleus in Parkinson's disease. *WMJ*. 2005;104(6):35-38. <http://www.ncbi.nlm.nih.gov/pubmed/16218314>. Accessed October 2, 2018.
78. Gorgulho A, De Salles AAF, Frighetto L, Behnke E. Incidence of hemorrhage associated with electrophysiological studies performed using macroelectrodes and microelectrodes in functional neurosurgery. *J Neurosurg*. 2005;102(5):888-896. doi:10.3171/jns.2005.102.5.0888.

79. Binder DK, Rau GM, Starr PA. Risk factors for hemorrhage during microelectrode-guided deep brain stimulator implantation for movement disorders. *Neurosurgery*. 2005;56(4):722-32; discussion 722-32. <http://www.ncbi.nlm.nih.gov/pubmed/15792511>. Accessed October 2, 2018.
80. Oh MY, Abosch A, Kim SH, Lang AE, Lozano AM. Long-term hardware-related complications of deep brain stimulation. *Neurosurgery*. 2002;50(6):1268-74; discussion 1274-6. <http://www.ncbi.nlm.nih.gov/pubmed/12015845>. Accessed September 28, 2018.
81. Vesper J, Klostermann F, Wille C, Funk T, Brock M. Long-Term Suppression of Extrapyraxidal Motor Symptoms with Deep Brain Stimulation (DBS). *Zentralbl Neurochir*. 2004;65(3):117-122. doi:10.1055/s-2004-822789.
82. Yianni J, Nandi D, Shad A, Bain P, Gregory R, Aziz T. Increased risk of lead fracture and migration in dystonia compared with other movement disorders following deep brain stimulation. *J Clin Neurosci*. 2004;11(3):243-245. doi:10.1016/j.jocn.2003.10.003.
83. Binder DK, Rau G, Starr PA. Hemorrhagic Complications of Microelectrode-Guided Deep Brain Stimulation. *Stereotact Funct Neurosurg*. 2003;80(1-4):28-31. doi:10.1159/000075156.
84. Putzke JD, Wharen RE, Wszolek ZK, Turk MF, Strongosky AJ, Uitti RJ. Thalamic deep brain stimulation for tremor-predominant Parkinson's disease. *Parkinsonism Relat Disord*. 2003;10(2):81-88. <http://www.ncbi.nlm.nih.gov/pubmed/14643997>. Accessed October 2, 2018.
85. Kondziolka D, Whiting D, Germanwala A, Oh M. Hardware-Related Complications after Placement of Thalamic Deep Brain Stimulator Systems. *Stereotact Funct Neurosurg*. 2002;79(3-4):228-233. doi:10.1159/000070836.
86. Terao T, Takahashi H, Yokochi F, Taniguchi M, Okiyama R, Hamada I. Hemorrhagic complication of stereotactic surgery in patients with movement disorders. *J Neurosurg*. 2003;98(6):1241-1246. doi:10.3171/jns.2003.98.6.1241.
87. Landi A, Parolin M, Piolti R, et al. Deep brain stimulation for the treatment of Parkinson's disease: the experience of the Neurosurgical Department in Monza. *Neurol Sci*. 2003;24(0):s43-s44. doi:10.1007/s100720300039.
88. Vesper J, Klostermann F, Stockhammer F, Funk T, Brock M. Results of chronic subthalamic nucleus stimulation for Parkinson's disease: a 1-year follow-up study. *Surg Neurol*. 2002;57(5):306-11; discussion 311-3. <http://www.ncbi.nlm.nih.gov/pubmed/12128300>. Accessed October 2, 2018.
89. Loher TJ, Burgunder J-M, Pohle T, Weber S, Sommerhalder R, Krauss JK. Long-term pallidal deep brain stimulation in patients with advanced Parkinson disease: 1-year follow-up study. *J Neurosurg*. 2002;96(5):844-853. doi:10.3171/jns.2002.96.5.0844.

90. Joint C, Nandi D, Parkin S, Gregory R, Aziz T. Hardware-related problems of deep brain stimulation. *Mov Disord.* 2002;17 Suppl 3:S175-80. <http://www.ncbi.nlm.nih.gov/pubmed/11948774>. Accessed October 2, 2018.
91. Kim SH, Lim SC, Kim J, Son B-C, Lee KJ, Shon Y-M. Long-term follow-up of anterior thalamic deep brain stimulation in epilepsy: A 11-year, single center experience. *Seizure.* 2017;52:154-161. doi:10.1016/j.seizure.2017.10.009.
92. Kumar R, Lang AE, Rodriguez-Oroz MC, et al. Deep brain stimulation of the globus pallidus pars interna in advanced Parkinson's disease. *Neurology.* 2000;55(12 Suppl 6):S34-9. <http://www.ncbi.nlm.nih.gov/pubmed/11188973>. Accessed October 2, 2018.
93. Pahwa R, Lyons KL, Wilkinson SB, et al. Bilateral thalamic stimulation for the treatment of essential tremor. *Neurology.* 1999;53(7):1447-1450. <http://www.ncbi.nlm.nih.gov/pubmed/10534249>. Accessed October 2, 2018.
94. Staudt MD, Pourtaheri N, Lakin GE, Soltanian HT, Miller JP. Surgical Management of Deep Brain Stimulator Scalp Erosion without Hardware Removal. *Stereotact Funct Neurosurg.* 2017;95(6):385-391. doi:10.1159/000484323.
95. Li D, Zhang C, Gault J, et al. Remotely Programmed Deep Brain Stimulation of the Bilateral Subthalamic Nucleus for the Treatment of Primary Parkinson Disease: A Randomized Controlled Trial Investigating the Safety and Efficacy of a Novel Deep Brain Stimulation System. *Stereotact Funct Neurosurg.* 2017;95(3):174-182. doi:10.1159/000475765.
96. Lipsman N, Lam E, Volpini M, et al. Deep brain stimulation of the subcallosal cingulate for treatment-refractory anorexia nervosa: 1 year follow-up of an open-label trial. *The Lancet Psychiatry.* 2017;4(4):285-294. doi:10.1016/S2215-0366(17)30076-7.
97. Lozano AM, Fosdick L, Chakravarty MM, et al. A Phase II Study of Fornix Deep Brain Stimulation in Mild Alzheimer's Disease. *J Alzheimer's Dis.* 2016;54(2):777-787. doi:10.3233/JAD-160017.
98. Bergfeld IO, Mantione M, Hoogendoorn MLC, et al. Deep Brain Stimulation of the Ventral Anterior Limb of the Internal Capsule for Treatment-Resistant Depression. *JAMA Psychiatry.* 2016;73(5):456. doi:10.1001/jamapsychiatry.2016.0152.
99. Lezcano E, Gómez-Esteban JC, Tijero B, et al. Long-term impact on quality of life of subthalamic nucleus stimulation in Parkinson's disease. *J Neurol.* 2016;263(5):895-905. doi:10.1007/s00415-016-8077-4.
100. Petraglia FW, Farber SH, Han JL, et al. Comparison of Bilateral vs. Staged Unilateral Deep Brain Stimulation (DBS) in Parkinson's Disease in Patients Under 70 Years of Age. *Neuromodulation Technol Neural Interface.* 2016;19(1):31-37. doi:10.1111/ner.12351.
101. Wojtecki L, Groiss SJ, Ferrea S, et al. A Prospective Pilot Trial for Pallidal Deep Brain

- Stimulation in Huntington's Disease. *Front Neurol.* 2015;6:177.
doi:10.3389/fneur.2015.00177.
102. Henssen DJHA, Kurt E, van Cappellen van Walsum A-M, et al. Long-term effect of motor cortex stimulation in patients suffering from chronic neuropathic pain: An observational study. Fonoff ET, ed. *PLoS One.* 2018;13(1):e0191774.
doi:10.1371/journal.pone.0191774.
 103. Aviles-Olmos I, Kefalopoulou Z, Tripoliti E, et al. Long-term outcome of subthalamic nucleus deep brain stimulation for Parkinson's disease using an MRI-guided and MRI-verified approach. *J Neurol Neurosurg Psychiatry.* 2014;85(12):1419-1425.
doi:10.1136/jnnp-2013-306907.
 104. Kramer DR, Halpern CH, Danish SF, Jaggi JL, Baltuch GH. The Effect of Intraventricular Trajectory on Brain Shift in Deep Brain Stimulation. *Stereotact Funct Neurosurg.* 2012;90(1):20-24. doi:10.1159/000332056.
 105. Gologorsky Y, Ben-Haim S, Moshier EL, et al. Transgressing the Ventricular Wall During Subthalamic Deep Brain Stimulation Surgery for Parkinson Disease Increases the Risk of Adverse Neurological Sequelae. *Neurosurgery.* 2011;69(2):294-300.
doi:10.1227/NEU.0b013e318214abda.
 106. Burdick AP, Okun MS, Haq IU, et al. Prevalence of Twiddler's Syndrome as a Cause of Deep Brain Stimulation Hardware Failure. *Stereotact Funct Neurosurg.* 2010;88(6):353-359. doi:10.1159/000319039.
 107. Tanei T, Kajita Y, Kaneoke Y, Takebayashi S, Nakatsubo D, Wakabayashi T. Staged bilateral deep brain stimulation of the subthalamic nucleus for the treatment of Parkinson's disease. *Acta Neurochir (Wien).* 2009;151(6):589-594. doi:10.1007/s00701-009-0293-6.
 108. Egidi M, Franzini A, Marras C, et al. A survey of Italian cases of dystonia treated by deep brain stimulation. *J Neurosurg Sci.* 2007;51(4):153-158.
<http://www.ncbi.nlm.nih.gov/pubmed/18176524>. Accessed October 2, 2018.
 109. Khatib R, Ebrahim Z, Rezai A, et al. Perioperative Events During Deep Brain Stimulation: The Experience at Cleveland Clinic. *J Neurosurg Anesthesiol.* 2008;20(1):36-40.
doi:10.1097/ANA.0b013e318157a15a.
 110. Esselink RAJ, de Bie RMA, de Haan RJ, et al. Unilateral pallidotomy versus bilateral subthalamic nucleus stimulation in PD: a randomized trial. *Neurology.* 2004;62(2):201-207. <http://www.ncbi.nlm.nih.gov/pubmed/14745054>. Accessed October 2, 2018.
 111. Ianssek R, Rosenfeld J V, Huxham FE. Deep brain stimulation of the subthalamic nucleus in Parkinson's disease. *Med J Aust.* 2002;177(3):142-146.
<http://www.ncbi.nlm.nih.gov/pubmed/12149083>. Accessed October 2, 2018.

112. Servello D, Sassi M, Gaeta M, Ricci C, Porta M. Tourette syndrome (TS) bears a higher rate of inflammatory complications at the implanted hardware in deep brain stimulation (DBS). *Acta Neurochir (Wien)*. 2011;153(3):629-632. doi:10.1007/s00701-010-0851-y.
113. Fernández FS, Alvarez Vega MA, Antuña Ramos A, Fernández González F, Lozano Aragonese B. Lead Fractures in Deep Brain Stimulation during Long-Term Follow-Up. *Parkinsons Dis*. 2010;2010:409356. doi:10.4061/2010/409356.
114. Vergani F, Landi A, Pirillo D, Cilia R, Antonini A, Sganzerla EP. Surgical, medical, and hardware adverse events in a series of 141 patients undergoing subthalamic deep brain stimulation for Parkinson disease. *World Neurosurg*. 2010;73(4):338-344. doi:10.1016/j.wneu.2010.01.017.
115. Meoni S, Fraix V, Castrioto A, et al. Pallidal deep brain stimulation for dystonia: a long term study. *J Neurol Neurosurg Psychiatry*. 2017;88(11):960-967. doi:10.1136/jnnp-2016-315504.
116. Oliveria SF, Rodriguez RL, Bowers D, et al. Safety and efficacy of dual-lead thalamic deep brain stimulation for patients with treatment-refractory multiple sclerosis tremor: a single-centre, randomised, single-blind, pilot trial. *Lancet Neurol*. 2017;16(9):691-700. doi:10.1016/S1474-4422(17)30166-7.
117. Dowd RS, Pourfar M, Mogilner AY. Deep brain stimulation for Tourette syndrome: a single-center series. *J Neurosurg*. 2018;128(2):596-604. doi:10.3171/2016.10.JNS161573.
118. Volkmann J, Wolters A, Kupsch A, et al. Pallidal deep brain stimulation in patients with primary generalised or segmental dystonia: 5-year follow-up of a randomised trial. *Lancet Neurol*. 2012;11(12):1029-1038. doi:10.1016/S1474-4422(12)70257-0.
119. Air EL, Ostrem JL, Sanger TD, Starr PA. Deep brain stimulation in children: experience and technical pearls. *J Neurosurg Pediatr*. 2011;8(6):566-574. doi:10.3171/2011.8.PEDS11153.
120. Cif L, Gonzalez-Martinez V, Vasques X, et al. Staged implantation of multiple electrodes in the internal globus pallidus in the treatment of primary generalized dystonia. *J Neurosurg*. 2012;116(5):1144-1152. doi:10.3171/2012.1.JNS102045.
121. Mehrkens JH, Borggraefe I, Feddersen B, Heinen F, Bötzel K. Early globus pallidus internus stimulation in pediatric patients with generalized primary dystonia: long-term efficacy and safety. *J Child Neurol*. 2010;25(11):1355-1361. doi:10.1177/0883073810365369.
122. Mehrkens JH, Bötzel K, Steude U, et al. Long-term efficacy and safety of chronic globus pallidus internus stimulation in different types of primary dystonia. *Stereotact Funct Neurosurg*. 2009;87(1):8-17. doi:10.1159/000177623.
123. Lyons KE, Koller WC, Wilkinson SB, Pahwa R. Long term safety and efficacy of

- unilateral deep brain stimulation of the thalamus for parkinsonian tremor. *J Neurol Neurosurg Psychiatry*. 2001;71(5):682-684.
<http://www.ncbi.nlm.nih.gov/pubmed/11606685>. Accessed September 27, 2018.
124. Falowski SM, Bakay RAE. Revision Surgery of Deep Brain Stimulation Leads. *Neuromodulation*. 2016;19(5):443-450. doi:10.1111/ner.12404.
 125. Chen T, Mirzadeh Z, Chapple KM, et al. Intraoperative test stimulation versus stereotactic accuracy as a surgical end point: a comparison of essential tremor outcomes after ventral intermediate nucleus deep brain stimulation. *J Neurosurg*. 2018;129(2):290-298. doi:10.3171/2017.3.JNS162487.
 126. Koller W, Pahwa R, Busenbark K, et al. High-frequency unilateral thalamic stimulation in the treatment of essential and parkinsonian tremor. *Ann Neurol*. 1997;42(3):292-299. doi:10.1002/ana.410420304.
 127. Isaias IU, Alterman RL, Tagliati M. Deep brain stimulation for primary generalized dystonia: long-term outcomes. *Arch Neurol*. 2009;66(4):465-470. doi:10.1001/archneurol.2009.20.
 128. Lyons KE, Wilkinson SB, Overman J, Pahwa R. Surgical and hardware complications of subthalamic stimulation: a series of 160 procedures. *Neurology*. 2004;63(4):612-616. <http://www.ncbi.nlm.nih.gov/pubmed/15326230>. Accessed September 27, 2018.
 129. Constantoyannis C, Berk C, Honey CR, Mendez I, Brownstone RM. Reducing hardware-related complications of deep brain stimulation. *Can J Neurol Sci*. 2005;32(2):194-200. <http://www.ncbi.nlm.nih.gov/pubmed/16018154>. Accessed September 27, 2018.
 130. Blomstedt P, Hariz MI. Hardware-related complications of deep brain stimulation: a ten year experience. *Acta Neurochir (Wien)*. 2005;147(10):1061-4; discussion 1064. doi:10.1007/s00701-005-0576-5.
 131. Boviatsis EJ, Stavrinou LC, Themistocleous M, Kouyialis AT, Sakas DE. Surgical and hardware complications of deep brain stimulation. A seven-year experience and review of the literature. *Acta Neurochir (Wien)*. 2010;152(12):2053-2062. doi:10.1007/s00701-010-0749-8.
 132. Fytagoridis A, Blomstedt P. Complications and side effects of deep brain stimulation in the posterior subthalamic area. *Stereotact Funct Neurosurg*. 2010;88(2):88-93. doi:10.1159/000271824.
 133. Morishita T, Hilliard JD, Okun MS, et al. Postoperative lead migration in deep brain stimulation surgery: Incidence, risk factors, and clinical impact. Toft M, ed. *PLoS One*. 2017;12(9):e0183711. doi:10.1371/journal.pone.0183711.
 134. Beric A, Kelly PJ, Rezai A, et al. Complications of deep brain stimulation surgery. *Stereotact Funct Neurosurg*. 2001;77(1-4):73-78. doi:10.1159/000064600.

135. Sobstyl MR, Ząbek M, Brzuszkiewicz-Kuźmicka G, Pasterski T. Dual Anchor Internal Pulse Generator Technique May Lower Risk of Twiddler's Syndrome: A Case Series and Literature Review. *Neuromodulation*. 2017;20(6):606-612. doi:10.1111/ner.12581.
136. Gubler FS, Ackermans L, Kubben PL, et al. Infections in deep brain stimulation: Shaving versus not shaving. *Surg Neurol Int*. 2017;8(1):249. doi:10.4103/sni.sni_172_17.
137. Falowski S, Ooi YC, Smith A, Verhagen Metman L, Bakay RAE. An evaluation of hardware and surgical complications with deep brain stimulation based on diagnosis and lead location. *Stereotact Funct Neurosurg*. 2012;90(3):173-180. doi:10.1159/000338254.
138. Kaminska M, Perides S, Lumsden DE, et al. Complications of Deep Brain Stimulation (DBS) for dystonia in children – The challenges and 10 year experience in a large paediatric cohort. *Eur J Paediatr Neurol*. 2017;21(1):168-175. doi:10.1016/j.ejpn.2016.07.024.
139. Miller PM, Gross RE. Wire tethering or “bowstringing” as a long-term hardware-related complication of deep brain stimulation. *Stereotact Funct Neurosurg*. 2009;87(6):353-359. doi:10.1159/000236369.
140. Alex Mohit A, Samii A, Slimp JC, Grady MS, Goodkin R. Mechanical failure of the electrode wire in deep brain stimulation. *Parkinsonism Relat Disord*. 2004;10(3):153-156. doi:10.1016/j.parkreldis.2003.11.001.
141. Janson C, Maxwell R, Gupte AA, Abosch A. Bowstringing as a complication of deep brain stimulation: case report. *Neurosurgery*. 2010;66(6):E1205; discussion E1205. doi:10.1227/01.NEU.0000369199.72783.F9.
142. Wharen RE, Okun MS, Guthrie BL, et al. Thalamic DBS with a constant-current device in essential tremor: A controlled clinical trial. *Parkinsonism Relat Disord*. 2017;40:18-26. doi:10.1016/j.parkreldis.2017.03.017.
143. Holtzheimer PE, Husain MM, Lisanby SH, et al. Subcallosal cingulate deep brain stimulation for treatment-resistant depression: a multisite, randomised, sham-controlled trial. *The lancet Psychiatry*. 2017;4(11):839-849. doi:10.1016/S2215-0366(17)30371-1.
144. Kahn E, D'Haese P-F, Dawant B, et al. Deep brain stimulation in early stage Parkinson's disease: operative experience from a prospective randomised clinical trial. *J Neurol Neurosurg Psychiatry*. 2012;83(2):164-170. doi:10.1136/jnnp-2011-300008.
145. Linhares P, Carvalho B, Vaz R. One-step tunneling of DBS extensions--a technical note. *Acta Neurochir (Wien)*. 2013;155(5):837-40; discussion 840. doi:10.1007/s00701-013-1667-3.
146. Kaminska M, Lumsden DE, Ashkan K, Malik I, Selway R, Lin J-P. Rechargeable deep brain stimulators in the management of paediatric dystonia: well tolerated with a low complication rate. *Stereotact Funct Neurosurg*. 2012;90(4):233-239.

doi:10.1159/000337768.

147. Kim MS, Jeong JS, Ryu H-S, Choi S-H, Chung SJ. Infection related to deep brain stimulation in patients with Parkinson disease: Clinical characteristics and risk factors. *J Neurol Sci.* 2017;383:135-141. doi:10.1016/j.jns.2017.10.031.
148. Sobstyl M, Ząbek M, Dzierżęcki S, Koziara H, Mossakowski Z. Chronic bilateral pallidal stimulation in patients with generalized primary dystonia - multi-contact cathodal stimulation is superior to bipolar stimulation mode. Preliminary results. *Neurol Neurochir Pol.* 45(3):252-259. <http://www.ncbi.nlm.nih.gov/pubmed/21866482>. Accessed September 27, 2018.
149. Okun MS, Gallo B V, Mandybur G, et al. Subthalamic deep brain stimulation with a constant-current device in Parkinson's disease: an open-label randomised controlled trial. *Lancet Neurol.* 2012;11(2):140-149. doi:10.1016/S1474-4422(11)70308-8.
150. Zrinzo L, Foltynie T, Limousin P, Hariz MI. Reducing hemorrhagic complications in functional neurosurgery: a large case series and systematic literature review. *J Neurosurg.* 2012;116(1):84-94. doi:10.3171/2011.8.JNS101407.
151. Lim S-N, Lee S-T, Tsai Y-T, et al. Long-term anterior thalamus stimulation for intractable epilepsy. *Chang Gung Med J.* 31(3):287-296. <http://www.ncbi.nlm.nih.gov/pubmed/18782952>. Accessed September 27, 2018.
152. Voges J, Waerzeggers Y, Maarouf M, et al. Deep-brain stimulation: long-term analysis of complications caused by hardware and surgery--experiences from a single centre. *J Neurol Neurosurg Psychiatry.* 2006;77(7):868-872. doi:10.1136/jnnp.2005.081232.
153. Lim S-N, Lee S-T, Tsai Y-T, et al. Electrical stimulation of the anterior nucleus of the thalamus for intractable epilepsy: a long-term follow-up study. *Epilepsia.* 2007;48(2):342-347. doi:10.1111/j.1528-1167.2006.00898.x.
154. Diamond A, Shahed J, Azher S, Dat-Vuong K, Jankovic J. Globus pallidus deep brain stimulation in dystonia. *Mov Disord.* 2006;21(5):692-695. doi:10.1002/mds.20767.
155. Vidailhet M, Vercueil L, Houeto J-L, et al. Bilateral deep-brain stimulation of the globus pallidus in primary generalized dystonia. *N Engl J Med.* 2005;352(5):459-467. doi:10.1056/NEJMoa042187.
156. Temel Y, Ackermans L, Celik H, et al. Management of hardware infections following deep brain stimulation. *Acta Neurochir (Wien).* 2004;146(4):355-61; discussion 361. doi:10.1007/s00701-004-0219-2.
157. Coubes P, Vayssiere N, El Fertit H, et al. Deep brain stimulation for dystonia. Surgical technique. *Stereotact Funct Neurosurg.* 2002;78(3-4):183-191. doi:10.1159/000068962.
158. Chowdhury T, Wilkinson M, Cappellani RB. Hemodynamic Perturbations in Deep Brain

- Stimulation Surgery: First Detailed Description. *Front Neurosci.* 2017;11:477. doi:10.3389/fnins.2017.00477.
159. Umemura A, Jaggi JL, Hurtig HI, et al. Deep brain stimulation for movement disorders: morbidity and mortality in 109 patients. *J Neurosurg.* 2003;98(4):779-784. doi:10.3171/jns.2003.98.4.0779.
 160. Deep-Brain Stimulation for Parkinson's Disease Study Group, Obeso JA, Olanow CW, et al. Deep-brain stimulation of the subthalamic nucleus or the pars interna of the globus pallidus in Parkinson's disease. *N Engl J Med.* 2001;345(13):956-963. doi:10.1056/NEJMoa000827.
 161. Li D, Cao C, Zhang J, Zhan S, Chen S, Sun B. Subthalamic nucleus deep brain stimulation for Parkinson's disease: 8 years of follow-up. *Transl Neurodegener.* 2013;2(1):11. doi:10.1186/2047-9158-2-11.
 162. Limousin P, Speelman JD, Gielen F, Janssens M. Multicentre European study of thalamic stimulation in parkinsonian and essential tremor. *J Neurol Neurosurg Psychiatry.* 1999;66(3):289-296. <http://www.ncbi.nlm.nih.gov/pubmed/10084526>. Accessed September 27, 2018.
 163. Schuurman PR, Bosch DA, Merkus MP, Speelman JD. Long-term follow-up of thalamic stimulation versus thalamotomy for tremor suppression. *Mov Disord.* 2008;23(8):1146-1153. doi:10.1002/mds.22059.
 164. Zhang K, Bhatia S, Oh MY, Cohen D, Angle C, Whiting D. Long-term results of thalamic deep brain stimulation for essential tremor. *J Neurosurg.* 2010;112(6):1271-1276. doi:10.3171/2009.10.JNS09371.
 165. Tir M, Devos D, Blond S, et al. Exhaustive, one-year follow-up of subthalamic nucleus deep brain stimulation in a large, single-center cohort of parkinsonian patients. *Neurosurgery.* 2007;61(2):297-304; discussion 304-5. doi:10.1227/01.NEU.0000285347.50028.B9.
 166. Hu X, Jiang X, Zhou X, et al. Avoidance and management of surgical and hardware-related complications of deep brain stimulation. *Stereotact Funct Neurosurg.* 2010;88(5):296-303. doi:10.1159/000316762.
 167. Goodman RR. Operative techniques and morbidity with subthalamic nucleus deep brain stimulation in 100 consecutive patients with advanced Parkinson's disease. *J Neurol Neurosurg Psychiatry.* 2006;77(1):12-17. doi:10.1136/jnnp.2005.069161.
 168. Martinez-Ramirez D, Jimenez-Shahed J, Leckman JF, et al. Efficacy and Safety of Deep Brain Stimulation in Tourette Syndrome: The International Tourette Syndrome Deep Brain Stimulation Public Database and Registry. *JAMA Neurol.* 2018;75(3):353-359. doi:10.1001/jamaneurol.2017.4317.

169. Velasco AL, Velasco F, Velasco M, Trejo D, Castro G, Carrillo-Ruiz JD. Electrical stimulation of the hippocampal epileptic foci for seizure control: a double-blind, long-term follow-up study. *Epilepsia*. 2007;48(10):1895-1903. doi:10.1111/j.1528-1167.2007.01181.x.
170. Vesper J, Chabardes S, Fraix V, Sunde N, Østergaard K, Kinetra Study Group. Dual channel deep brain stimulation system (Kinetra) for Parkinson's disease and essential tremor: a prospective multicentre open label clinical study. *J Neurol Neurosurg Psychiatry*. 2002;73(3):275-280. <http://www.ncbi.nlm.nih.gov/pubmed/12185158>. Accessed September 28, 2018.
171. Fernández-Pajarín G, Sesar A, Ares B, et al. Delayed complications of deep brain stimulation: 16-year experience in 249 patients. *Acta Neurochir (Wien)*. 2017;159(9):1713-1719. doi:10.1007/s00701-017-3252-7.
172. Abode-Iyamah KO, Chiang H-Y, Woodroffe RW, et al. Deep brain stimulation hardware-related infections: 10-year experience at a single institution. *J Neurosurg*. March 2018:1-10. doi:10.3171/2017.9.JNS1780.
173. Baizabal Carvallo JF, Mostile G, Almaguer M, Davidson A, Simpson R, Jankovic J. Deep brain stimulation hardware complications in patients with movement disorders: risk factors and clinical correlations. *Stereotact Funct Neurosurg*. 2012;90(5):300-306. doi:10.1159/000338222.
174. Hardaway FA, Raslan AM, Burchiel KJ. Deep Brain Stimulation-Related Infections: Analysis of Rates, Timing, and Seasonality. *Neurosurgery*. 2018;83(3):540-547. doi:10.1093/neuros/nyx505.
175. Holslag JAH, Neef N, Beudel M, et al. Deep Brain Stimulation for Essential Tremor: A Comparison of Targets. *World Neurosurg*. 2018;110:e580-e584. doi:10.1016/j.wneu.2017.11.064.
176. Umemura A, Oka Y, Yamamoto K, Okita K, Matsukawa N, Yamada K. Complications of subthalamic nucleus stimulation in Parkinson's disease. *Neurol Med Chir (Tokyo)*. 2011;51(11):749-755. <http://www.ncbi.nlm.nih.gov/pubmed/22123476>. Accessed September 28, 2018.
177. Pahwa R, Lyons KE, Wilkinson SB, et al. Comparison of thalamotomy to deep brain stimulation of the thalamus in essential tremor. *Mov Disord*. 2001;16(1):140-143. <http://www.ncbi.nlm.nih.gov/pubmed/11215575>. Accessed September 27, 2018.
178. Kim M, Jung NY, Park CK, Chang WS, Jung HH, Chang JW. Comparative Evaluation of Magnetic Resonance-Guided Focused Ultrasound Surgery for Essential Tremor. *Stereotact Funct Neurosurg*. 2017;95(4):279-286. doi:10.1159/000478866.
179. Vidailhet M, Vercueil L, Houeto J-L, et al. Bilateral, pallidal, deep-brain stimulation in

- primary generalised dystonia: a prospective 3 year follow-up study. *Lancet Neurol.* 2007;6(3):223-229. doi:10.1016/S1474-4422(07)70035-2.
180. Blomstedt P, Hariz MI. Are complications less common in deep brain stimulation than in ablative procedures for movement disorders? *Stereotact Funct Neurosurg.* 2006;84(2-3):72-81. doi:10.1159/000094035.
 181. Stroop R, Holms F, Nakamura M, Lehrke R. A Submammarian Approach for Cosmetically Improved Implantation of Deep Brain Stimulation Generators. *World Neurosurg.* 2018;109:e699-e706. doi:10.1016/j.wneu.2017.10.057.
 182. Deuschl G, Schade-Brittinger C, Krack P, et al. A randomized trial of deep-brain stimulation for Parkinson's disease. *N Engl J Med.* 2006;355(9):896-908. doi:10.1056/NEJMoa060281.
 183. Park YS, Kang J-H, Kim HY, et al. A combination procedure with double C-shaped skin incision and dual-floor burr hole method to prevent skin erosion on the scalp and reduce postoperative skin complications in deep brain stimulation. *Stereotact Funct Neurosurg.* 2011;89(3):178-184. doi:10.1159/000324903.
 184. Peña E, Pastor J, Hernando V, et al. Skin erosion over implants in deep brain stimulation patients. *Stereotact Funct Neurosurg.* 2008;86(2):120-126. doi:10.1159/000116216.
 185. Welter M-L, Houeto J-L, Thobois S, et al. Anterior pallidal deep brain stimulation for Tourette's syndrome: a randomised, double-blind, controlled trial. *Lancet Neurol.* 2017;16(8):610-619. doi:10.1016/S1474-4422(17)30160-6.
 186. Merola A, Fasano A, Hassan A, et al. Thalamic deep brain stimulation for orthostatic tremor: A multicenter international registry. *Mov Disord.* 2017;32(8):1240-1244. doi:10.1002/mds.27082.
 187. Abreu V, Vaz R, Rebelo V, et al. Thalamic Deep Brain Stimulation for Neuropathic Pain: Efficacy at Three Years' Follow-Up. *Neuromodulation.* 2017;20(5):504-513. doi:10.1111/ner.12620.
 188. Alomar S, Mullin JP, Smithason S, Gonzalez-Martinez J. Indications, technique, and safety profile of insular stereoelectroencephalography electrode implantation in medically intractable epilepsy. *J Neurosurg.* 2018;128(4):1147-1157. doi:10.3171/2017.1.JNS161070.
 189. Klein J, Buntjen L, Jacobi G, et al. Bilateral thalamic deep brain stimulation for essential tremor in elderly patients. *J Neural Transm.* 2017;124(9):1093-1096. doi:10.1007/s00702-017-1741-8.
 190. Zhan S, Sun F, Pan Y, et al. Bilateral deep brain stimulation of the subthalamic nucleus in primary Meige syndrome. *J Neurosurg.* 2018;128(3):897-902. doi:10.3171/2016.12.JNS16383.

191. Ryu H-S, Kim M-S, You S, et al. Comparison of Pallidal and Subthalamic Deep Brain Stimulation in Parkinson's Disease: Therapeutic and Adverse Effects. *J Mov Disord*. 2017;10(2):80-86. doi:10.14802/jmd.17001.
192. Park CK, Jung NY, Kim M, Chang JW. Analysis of Delayed Intracerebral Hemorrhage Associated with Deep Brain Stimulation Surgery. *World Neurosurg*. 2017;104:537-544. doi:10.1016/j.wneu.2017.05.075.
193. Frizon LA, Hogue O, Wathen C, et al. Subsequent Pulse Generator Replacement Surgery Does Not Increase the Infection Rate in Patients With Deep Brain Stimulator Systems: A Review of 1537 Unique Implants at a Single Center. *Neuromodulation*. 2017;20(5):444-449. doi:10.1111/ner.12605.
194. Geller EB, Skarpaas TL, Gross RE, et al. Brain-responsive neurostimulation in patients with medically intractable mesial temporal lobe epilepsy. *Epilepsia*. 2017;58(6):994-1004. doi:10.1111/epi.13740.
195. White-Dzuro GA, Lake W, Neimat JS. Subpectoral Implantation of Internal Pulse Generators for Deep Brain Stimulation: Technical Note for Improved Cosmetic Outcomes. *Oper Neurosurg (Hagerstown, Md)*. 2017;13(4):529-534. doi:10.1093/ons/oxp018.
196. Chen T, Mirzadeh Z, Lambert M, et al. Cost of Deep Brain Stimulation Infection Resulting in Explantation. *Stereotact Funct Neurosurg*. 2017;95(2):117-124. doi:10.1159/000457964.
197. Themistocleous MS, Sakas DE, Boviatsis E, et al. The Insertion of Electrodes in the Brain for Electrophysiological Recording or Chronic Stimulation Is Not Associated With Any Biochemically Detectable Neuronal Injury. *Neuromodulation*. 2017;20(5):424-428. doi:10.1111/ner.12598.
198. Jobst BC, Kapur R, Barkley GL, et al. Brain-responsive neurostimulation in patients with medically intractable seizures arising from eloquent and other neocortical areas. *Epilepsia*. 2017;58(6):1005-1014. doi:10.1111/epi.13739.
199. Lempka SF, Malone DA, Hu B, et al. Randomized clinical trial of deep brain stimulation for poststroke pain. *Ann Neurol*. 2017;81(5):653-663. doi:10.1002/ana.24927.
200. Ramayya AG, Abdullah KG, Mallela AN, et al. Thirty-Day Readmission Rates Following Deep Brain Stimulation Surgery. *Neurosurgery*. 2017;81(2):259-267. doi:10.1093/neuros/nyx019.
201. Lefebvre J, Buffet-Bataillon S, Henaux PL, Riffaud L, Morandi X, Haegelen C. Staphylococcus aureus screening and decolonization reduces the risk of surgical site infections in patients undergoing deep brain stimulation surgery. *J Hosp Infect*. 2017;95(2):144-147. doi:10.1016/j.jhin.2016.11.019.

202. Ostrem JL, San Luciano M, Dodenhoff KA, et al. Subthalamic nucleus deep brain stimulation in isolated dystonia: A 3-year follow-up study. *Neurology*. 2017;88(1):25-35. doi:10.1212/WNL.0000000000003451.
203. Downes AE, Pezeshkian P, Behnke E, et al. Acute Ischemic Stroke During Deep Brain Stimulation Surgery of Globus Pallidus Internus: Report of 5 Cases. *Oper Neurosurg (Hagerstown, Md)*. 2016;12(4):383-390. doi:10.1227/NEU.0000000000001359.
204. Wang X, Wang J, Zhao H, et al. Clinical analysis and treatment of symptomatic intracranial hemorrhage after deep brain stimulation surgery. *Br J Neurosurg*. 2017;31(2):217-222. doi:10.1080/02688697.2016.1244252.
205. Rosa M, Scelzo E, Locatelli M, et al. Risk of Infection After Local Field Potential Recording from Externalized Deep Brain Stimulation Leads in Parkinson's Disease. *World Neurosurg*. 2017;97:64-69. doi:10.1016/j.wneu.2016.09.069.
206. Mandat T, Tykocki T, Koziara H, et al. Subthalamic deep brain stimulation for the treatment of Parkinson disease. *Neurol Neurochir Pol*. 45(1):32-36. <http://www.ncbi.nlm.nih.gov/pubmed/21384291>. Accessed September 28, 2018.
207. Hu K, Moses ZB, Hutter MM, Williams Z. Short-Term Adverse Outcomes After Deep Brain Stimulation Treatment in Patients with Parkinson Disease. *World Neurosurg*. 2017;98:365-374. doi:10.1016/j.wneu.2016.10.138.
208. Krause P, Lauritsch K, Lipp A, et al. Long-term results of deep brain stimulation in a cohort of eight children with isolated dystonia. *J Neurol*. 2016;263(11):2319-2326. doi:10.1007/s00415-016-8253-6.
209. Chen T, Mirzadeh Z, Chapple K, Lambert M, Ponce FA. Complication rates, lengths of stay, and readmission rates in "awake" and "asleep" deep brain stimulation. *J Neurosurg*. 2017;127(2):360-369. doi:10.3171/2016.6.JNS152946.
210. Miller S, Akram H, Lagrata S, Hariz M, Zrinzo L, Matharu M. Ventral tegmental area deep brain stimulation in refractory short-lasting unilateral neuralgiform headache attacks. *Brain*. 2016;139(Pt 10):2631-2640. doi:10.1093/brain/aww204.
211. Martin AJ, Larson PS, Ziman N, et al. Deep brain stimulator implantation in a diagnostic MRI suite: infection history over a 10-year period. *J Neurosurg*. 2017;126(1):108-113. doi:10.3171/2015.7.JNS15750.
212. Chiou S-M. Benefits of subthalamic stimulation for elderly parkinsonian patients aged 70 years or older. *Clin Neurol Neurosurg*. 2016;149:81-86. doi:10.1016/j.clineuro.2016.07.028.
213. Williams NR, Short EB, Hopkins T, et al. Five-Year Follow-Up of Bilateral Epidural Prefrontal Cortical Stimulation for Treatment-Resistant Depression. *Brain Stimul*. 2016;9(6):897-904. doi:10.1016/j.brs.2016.06.054.

214. Rasouli JJ, Kopell BH. The Adjunctive Use of Vancomycin Powder Appears Safe and May Reduce the Incidence of Surgical-Site Infections After Deep Brain Stimulation Surgery. *World Neurosurg.* 2016;95:9-13. doi:10.1016/j.wneu.2016.07.063.
215. Koy A, Weinsheimer M, Pauls KAM, et al. German registry of paediatric deep brain stimulation in patients with childhood-onset dystonia (GEPESTIM). *Eur J Paediatr Neurol.* 2017;21(1):136-146. doi:10.1016/j.ejpn.2016.05.023.
216. Testini P, Zhao CZ, Stead M, Duffy PS, Klassen BT, Lee KH. Centromedian-Parafascicular Complex Deep Brain Stimulation for Tourette Syndrome: A Retrospective Study. *Mayo Clin Proc.* 2016;91(2):218-225. doi:10.1016/j.mayocp.2015.11.016.
217. Dafsari HS, Reker P, Silverdale M, et al. Subthalamic Stimulation Improves Quality of Life of Patients Aged 61 Years or Older With Short Duration of Parkinson's Disease. *Neuromodulation.* 2018;21(6):532-540. doi:10.1111/ner.12740.
218. White-Dzuro GA, Lake W, Eli IM, Neimat JS. Novel Approach to Securing Deep Brain Stimulation Leads: Technique and Analysis of Lead Migration, Breakage, and Surgical Infection. *Stereotact Funct Neurosurg.* 2016;94(1):18-23. doi:10.1159/000442893.
219. Delavallée M, Delaunois J, Ruwet J, Jeanjean A, Raftopoulos C. STN DBS for Parkinson's disease: results from a series of ten consecutive patients implanted under general anaesthesia with intraoperative use of 3D fluoroscopy to control lead placement. *Acta Neurochir (Wien).* 2016;158(9):1783-1788. doi:10.1007/s00701-016-2889-y.
220. Higuchi M-A, Martinez-Ramirez D, Morita H, et al. Interdisciplinary Parkinson's Disease Deep Brain Stimulation Screening and the Relationship to Unintended Hospitalizations and Quality of Life. Abulseoud OA, ed. *PLoS One.* 2016;11(5):e0153785. doi:10.1371/journal.pone.0153785.
221. Ponce FA, Asaad WF, Foote KD, et al. Bilateral deep brain stimulation of the fornix for Alzheimer's disease: surgical safety in the ADvance trial. *J Neurosurg.* 2016;125(1):75-84. doi:10.3171/2015.6.JNS15716.
222. Ashkan K, Alamri A, Ughratdar I. Anti-Coagulation and Deep Brain Stimulation: Never the Twain Shall Meet. *Stereotact Funct Neurosurg.* 2015;93(6):373-377. doi:10.1159/000441232.
223. Tonge M, Ackermans L, Kocabicak E, et al. A detailed analysis of intracerebral hemorrhages in DBS surgeries. *Clin Neurol Neurosurg.* 2015;139:183-187. doi:10.1016/j.clineuro.2015.10.017.
224. Ostrem JL, Ziman N, Galifianakis NB, et al. Clinical outcomes using ClearPoint interventional MRI for deep brain stimulation lead placement in Parkinson's disease. *J Neurosurg.* 2016;124(4):908-916. doi:10.3171/2015.4.JNS15173.
225. Levi V, Carrabba G, Rampini P, Locatelli M. "Short term surgical complications

- after subthalamic deep brain stimulation for Parkinson's disease: does old age matter?". *BMC Geriatr.* 2015;15(1):116. doi:10.1186/s12877-015-0112-2.
226. Falowski SM, Ooi YC, Bakay RAE. Long-Term Evaluation of Changes in Operative Technique and Hardware-Related Complications With Deep Brain Stimulation. *Neuromodulation.* 2015;18(8):670-677. doi:10.1111/ner.12335.
 227. Akram H, Limousin P, Hyam J, Hariz MI, Zrinzo L. Aim for the Suprasternal Notch: Technical Note to Avoid Bowstringing after Deep Brain Stimulation. *Stereotact Funct Neurosurg.* 2015;93(4):227-230. doi:10.1159/000381680.
 228. Cury RG, Fraix V, Castrioto A, et al. Thalamic deep brain stimulation for tremor in Parkinson disease, essential tremor, and dystonia. *Neurology.* 2017;89(13):1416-1423. doi:10.1212/WNL.0000000000004295.
 229. Reuter S, Deuschl G, Falk D, Mehdorn M, Witt K. Uncoupling of dopaminergic and subthalamic stimulation: Life-threatening DBS withdrawal syndrome. *Mov Disord.* 2015;30(10):1407-1413. doi:10.1002/mds.26324.
 230. Kefalopoulou Z, Zrinzo L, Jahanshahi M, et al. Bilateral globus pallidus stimulation for severe Tourette's syndrome: a double-blind, randomised crossover trial. *Lancet Neurol.* 2015;14(6):595-605. doi:10.1016/S1474-4422(15)00008-3.
 231. Verla T, Marky A, Farber H, et al. Impact of advancing age on post-operative complications of deep brain stimulation surgery for essential tremor. *J Clin Neurosci.* 2015;22(5):872-876. doi:10.1016/j.jocn.2014.11.005.
 232. Salanova V, Witt T, Worth R, et al. Long-term efficacy and safety of thalamic stimulation for drug-resistant partial epilepsy. *Neurology.* 2015;84(10):1017-1025. doi:10.1212/WNL.0000000000001334.
 233. Bergey GK, Morrell MJ, Mizrahi EM, et al. Long-term treatment with responsive brain stimulation in adults with refractory partial seizures. *Neurology.* 2015;84(8):810-817. doi:10.1212/WNL.0000000000001280.
 234. Patel DM, Walker HC, Brooks R, Omar N, Ditty B, Guthrie BL. Adverse events associated with deep brain stimulation for movement disorders: analysis of 510 consecutive cases. *Neurosurgery.* 2015;11 Suppl 2:190-199. doi:10.1227/NEU.0000000000000659.
 235. Movement Disorder Group, Chan AYY, Yeung JHM, et al. Subthalamic nucleus deep brain stimulation for Parkinson's disease: evidence for effectiveness and limitations from 12 years' experience. *Hong Kong Med J = Xianggang yi xue za zhi.* 2014;20(6):474-480. doi:10.12809/hkmj144242.
 236. Keen JR, Przekop A, Olaya JE, Zouros A, Hsu FPK. Deep brain stimulation for the treatment of childhood dystonic cerebral palsy. *J Neurosurg Pediatr.* 2014;14(6):585-593.

- doi:10.3171/2014.8.PEDS141.
237. Lee S-W, Lee M-K, Seo I, Kim H-S, Kim J-H, Kim Y-S. A groove technique for securing an electrode connector on the cranial bone: case analysis of efficacy. *J Korean Neurosurg Soc.* 2014;56(2):130-134. doi:10.3340/jkns.2014.56.2.130.
 238. Sobstyl M, Kmiec T, Zabek M, Szczaluba K, Mossakowski Z. Long-term outcomes of bilateral pallidal stimulation for primary generalised dystonia. *Clin Neurol Neurosurg.* 2014;126:82-87. doi:10.1016/j.clineuro.2014.08.027.
 239. Chui J, Alimiri R, Parrent A, Craen RA. The Effects of Intraoperative Sedation on Surgical Outcomes of Deep Brain Stimulation Surgery. *Can J Neurol Sci.* 2018;45(2):168-175. doi:10.1017/cjn.2017.269.
 240. DeLong MR, Huang KT, Gallis J, et al. Effect of advancing age on outcomes of deep brain stimulation for Parkinson disease. *JAMA Neurol.* 2014;71(10):1290-1295. doi:10.1001/jamaneurol.2014.1272.
 241. Volkmann J, Mueller J, Deuschl G, et al. Pallidal neurostimulation in patients with medication-refractory cervical dystonia: a randomised, sham-controlled trial. *Lancet Neurol.* 2014;13(9):875-884. doi:10.1016/S1474-4422(14)70143-7.
 242. Sachdev PS, Mohan A, Cannon E, et al. Deep brain stimulation of the antero-medial globus pallidus interna for Tourette syndrome. Bankiewicz K, ed. *PLoS One.* 2014;9(8):e104926. doi:10.1371/journal.pone.0104926.
 243. Bjerknes S, Skogseid IM, Sæhle T, Dietrichs E, Toft M. Surgical site infections after deep brain stimulation surgery: frequency, characteristics and management in a 10-year period. Gross RE, ed. *PLoS One.* 2014;9(8):e105288. doi:10.1371/journal.pone.0105288.
 244. Tolleson C, Stroh J, Ehrenfeld J, Neimat J, Konrad P, Phibbs F. The factors involved in deep brain stimulation infection: a large case series. *Stereotact Funct Neurosurg.* 2014;92(4):227-233. doi:10.1159/000362934.
 245. de Quintana-Schmidt C, Pascual-Sedano B, Alvarez-Holzapfel MJ, et al. [Complications related with implanted devices in patients with Parkinson's disease treated with deep brain stimulation. A study of a series of 124 patients over a period of 16 years]. *Rev Neurol.* 2014;59(2):49-56. <http://www.ncbi.nlm.nih.gov/pubmed/25005315>. Accessed October 1, 2018.
 246. Solmaz B, Tatarli N, Ceylan D, Bayri Y, Ziyal MI, Şeker A. A sine-wave-shaped skin incision for inserting deep-brain stimulators. *Acta Neurochir (Wien).* 2014;156(8):1523-1525. doi:10.1007/s00701-014-2123-8.
 247. Gocmen S, Celiker O, Topcu A, Panteli A, Acar G, Acar F. Reuse of internal pulse generator in cases of infection after deep brain stimulation surgery. *Stereotact Funct Neurosurg.* 2014;92(3):140-144. doi:10.1159/000360585.

248. Charles D, Konrad PE, Neimat JS, et al. Subthalamic nucleus deep brain stimulation in early stage Parkinson's disease. *Parkinsonism Relat Disord*. 2014;20(7):731-737. doi:10.1016/j.parkreldis.2014.03.019.
249. Seijo F, Alvarez de Eulate Beramendi S, Santamarta Liébana E, et al. Surgical adverse events of deep brain stimulation in the subthalamic nucleus of patients with Parkinson's disease. The learning curve and the pitfalls. *Acta Neurochir (Wien)*. 2014;156(8):1505-12; discussion 1512. doi:10.1007/s00701-014-2082-0.
250. Persson R, Earley A, Garlitski AC, Balk EM, Uhlig K. Adverse events following implantable cardioverter defibrillator implantation: a systematic review. *J Interv Card Electrophysiol*. 2014;40(2):191-205. doi:10.1007/s10840-014-9913-z.
251. Willett FR, Pandarinath C, Jarosiewicz B, et al. Feedback control policies employed by people using intracortical brain-computer interfaces. *J Neural Eng*. 2017;14(1):016001. doi:10.1088/1741-2560/14/1/016001.
252. Ajiboye AB, Willett FR, Young DR, et al. Restoration of reaching and grasping movements through brain-controlled muscle stimulation in a person with tetraplegia: a proof-of-concept demonstration. *Lancet*. 2017;389(10081):1821-1830. doi:10.1016/S0140-6736(17)30601-3.
253. Ajiboye AB, Simeral JD, Donoghue JP, Hochberg LR, Kirsch RF. Prediction of imagined single-joint movements in a person with high-level tetraplegia. *IEEE Trans Biomed Eng*. 2012;59(10):2755-2765. doi:10.1109/TBME.2012.2209882.
254. Chadwick EK, Blana D, Simeral JD, et al. Continuous neuronal ensemble control of simulated arm reaching by a human with tetraplegia. *J Neural Eng*. 2011;8(3):034003. doi:10.1088/1741-2560/8/3/034003.
255. Kim S-P, Simeral JD, Hochberg LR, Donoghue JP, Friehs GM, Black MJ. Point-and-click cursor control with an intracortical neural interface system by humans with tetraplegia. *IEEE Trans Neural Syst Rehabil Eng*. 2011;19(2):193-203. doi:10.1109/TNSRE.2011.2107750.
256. Even-Chen N, Stavisky SD, Pandarinath C, et al. Feasibility of Automatic Error Detect-and-Undo System in Human Intracortical Brain-Computer Interfaces. *IEEE Trans Biomed Eng*. 2018;65(8):1771-1784. doi:10.1109/TBME.2017.2776204.
257. Pandarinath C, Gilja V, Blabe CH, et al. Neural population dynamics in human motor cortex during movements in people with ALS. *Elife*. 2015;4:e07436. doi:10.7554/eLife.07436.
258. Malik WQ, Hochberg LR, Donoghue JP, Brown EN. Modulation depth estimation and variable selection in state-space models for neural interfaces. *IEEE Trans Biomed Eng*. 2015;62(2):570-581. doi:10.1109/TBME.2014.2360393.

259. Masse NY, Jarosiewicz B, Simeral JD, et al. Non-causal spike filtering improves decoding of movement intention for intracortical BCIs. *J Neurosci Methods*. 2014;236:58-67. doi:10.1016/j.jneumeth.2014.08.004.
260. Hochberg LR, Bacher D, Jarosiewicz B, et al. Reach and grasp by people with tetraplegia using a neurally controlled robotic arm. *Nature*. 2012;485(7398):372-375. doi:10.1038/nature11076.
261. Annetta N, Friend J, Schimmoeller A, et al. A High Definition Non-invasive Neuromuscular Electrical Stimulation System for Cortical Control of Combinatorial Rotary Hand Movements in a Human with Tetraplegia. *IEEE Trans Biomed Eng*. August 2018:1-1. doi:10.1109/TBME.2018.2864104.
262. Truccolo W, Hochberg LR, Donoghue JP. Collective dynamics in human and monkey sensorimotor cortex: predicting single neuron spikes. *Nat Neurosci*. 2010;13(1):105-111. doi:10.1038/nn.2455.
263. Milekovic T, Sarma AA, Bacher D, et al. Stable long-term BCI-enabled communication in ALS and locked-in syndrome using LFP signals. *J Neurophysiol*. 2018;120(1):343-360. doi:10.1152/jn.00493.2017.
264. Jarosiewicz B, Sarma AA, Bacher D, et al. Virtual typing by people with tetraplegia using a self-calibrating intracortical brain-computer interface. *Sci Transl Med*. 2015;7(313):313ra179-313ra179. doi:10.1126/scitranslmed.aac7328.
265. Brandman DM, Hosman T, Saab J, et al. Rapid calibration of an intracortical brain-computer interface for people with tetraplegia. *J Neural Eng*. 2018;15(2):026007. doi:10.1088/1741-2552/aa9ee7.
266. Bacher D, Jarosiewicz B, Masse NY, et al. Neural Point-and-Click Communication by a Person With Incomplete Locked-In Syndrome. *Neurorehabil Neural Repair*. 2015;29(5):462-471. doi:10.1177/1545968314554624.
267. Perge JA, Zhang S, Malik WQ, et al. Reliability of directional information in unsorted spikes and local field potentials recorded in human motor cortex. *J Neural Eng*. 2014;11(4):046007. doi:10.1088/1741-2560/11/4/046007.
268. Homer ML, Perge JA, Black MJ, Harrison MT, Cash SS, Hochberg LR. Adaptive offset correction for intracortical brain-computer interfaces. *IEEE Trans Neural Syst Rehabil Eng*. 2014;22(2):239-248. doi:10.1109/TNSRE.2013.2287768.
269. Jarosiewicz B, Masse NY, Bacher D, et al. Advantages of closed-loop calibration in intracortical brain-computer interfaces for people with tetraplegia. *J Neural Eng*. 2013;10(4):046012. doi:10.1088/1741-2560/10/4/046012.
270. Shaikhouni A, Donoghue JP, Hochberg LR. Somatosensory responses in a human motor cortex. *J Neurophysiol*. 2013;109(8):2192-2204. doi:10.1152/jn.00368.2012.

271. Perge JA, Homer ML, Malik WQ, et al. Intra-day signal instabilities affect decoding performance in an intracortical neural interface system. *J Neural Eng.* 2013;10(3):036004. doi:10.1088/1741-2560/10/3/036004.
272. Colachis SC, Bockbrader MA, Zhang M, et al. Dexterous Control of Seven Functional Hand Movements Using Cortically-Controlled Transcutaneous Muscle Stimulation in a Person With Tetraplegia. *Front Neurosci.* 2018;12:208. doi:10.3389/fnins.2018.00208.
273. Simeral JD, Kim S-P, Black MJ, Donoghue JP, Hochberg LR. Neural control of cursor trajectory and click by a human with tetraplegia 1000 days after implant of an intracortical microelectrode array. *J Neural Eng.* 2011;8(2):025027. doi:10.1088/1741-2560/8/2/025027.
274. Kim S-P, Simeral JD, Hochberg LR, Donoghue JP, Black MJ. Neural control of computer cursor velocity by decoding motor cortical spiking activity in humans with tetraplegia. *J Neural Eng.* 2008;5(4):455-476. doi:10.1088/1741-2560/5/4/010.
275. Pandarinath C, Nuyujukian P, Blabe CH, et al. High performance communication by people with paralysis using an intracortical brain-computer interface. *Elife.* 2017;6. doi:10.7554/eLife.18554.
276. Gilja V, Pandarinath C, Blabe CH, et al. Clinical translation of a high-performance neural prosthesis. *Nat Med.* 2015;21(10):1142-1145. doi:10.1038/nm.3953.
277. Aflalo T, Kellis S, Klaes C, et al. Neurophysiology. Decoding motor imagery from the posterior parietal cortex of a tetraplegic human. *Science.* 2015;348(6237):906-910. doi:10.1126/science.aaa5417.
278. Klaes C, Kellis S, Aflalo T, et al. Hand Shape Representations in the Human Posterior Parietal Cortex. *J Neurosci.* 2015;35(46):15466-15476. doi:10.1523/JNEUROSCI.2747-15.2015.
279. Armenta Salas M, Bashford L, Kellis S, et al. Proprioceptive and cutaneous sensations in humans elicited by intracortical microstimulation. *Elife.* 2018;7. doi:10.7554/eLife.32904.
280. Zhang CY, Aflalo T, Revechkis B, et al. Partially Mixed Selectivity in Human Posterior Parietal Association Cortex. *Neuron.* 2017;95(3):697-708.e4. doi:10.1016/j.neuron.2017.06.040.
281. Rutishauser U, Aflalo T, Rosario ER, Pouratian N, Andersen RA. Single-Neuron Representation of Memory Strength and Recognition Confidence in Left Human Posterior Parietal Cortex. *Neuron.* 2018;97(1):209-220.e3. doi:10.1016/j.neuron.2017.11.029.
282. Downey JE, Schwed N, Chase SM, Schwartz AB, Collinger JL. Intracortical recording stability in human brain-computer interface users. *J Neural Eng.* 2018;15(4):046016. doi:10.1088/1741-2552/aab7a0.

283. FriedenberG DA, Schwemmer MA, Landgraf AJ, et al. Neuroprosthetic-enabled control of graded arm muscle contraction in a paralyzed human. *Sci Rep*. 2017;7(1):8386. doi:10.1038/s41598-017-08120-9.
284. Yang Y, Dickey MW, Fiez J, et al. Sensorimotor experience and verb-category mapping in human sensory, motor and parietal neurons. *Cortex*. 2017;92:304-319. doi:10.1016/j.cortex.2017.04.021.
285. Flesher SN, Collinger JL, Foldes ST, et al. Intracortical microstimulation of human somatosensory cortex. *Sci Transl Med*. 2016;8(361):361ra141. doi:10.1126/scitranslmed.aaf8083.
286. Downey JE, Weiss JM, Muelling K, et al. Blending of brain-machine interface and vision-guided autonomous robotics improves neuroprosthetic arm performance during grasping. *J Neuroeng Rehabil*. 2016;13(1):28. doi:10.1186/s12984-016-0134-9.
287. Downey JE, Brane L, Gaunt RA, Tyler-Kabara EC, Boninger ML, Collinger JL. Motor cortical activity changes during neuroprosthetic-controlled object interaction. *Sci Rep*. 2017;7(1):16947. doi:10.1038/s41598-017-17222-3.
288. Wodlinger B, Downey JE, Tyler-Kabara EC, Schwartz AB, Boninger ML, Collinger JL. Ten-dimensional anthropomorphic arm control in a human brain-machine interface: difficulties, solutions, and limitations. *J Neural Eng*. 2015;12(1):016011. doi:10.1088/1741-2560/12/1/016011.
289. Collinger JL, Wodlinger B, Downey JE, et al. High-performance neuroprosthetic control by an individual with tetraplegia. *Lancet (London, England)*. 2013;381(9866):557-564. doi:10.1016/S0140-6736(12)61816-9.
290. Jitkrisadakul O, Bhidayasiri R, Kalia SK, Hodaie M, Lozano AM, Fasano A. Systematic review of hardware-related complications of Deep Brain Stimulation: Do new indications pose an increased risk? *Brain Stimul*. 2017;10(5):967-976. doi:10.1016/j.brs.2017.07.003.
291. Bouton CE, Shaikhouni A, Annetta N V., et al. Restoring cortical control of functional movement in a human with quadriplegia. *Nature*. 2016;533(7602):247-250. doi:10.1038/nature17435.
292. Pandarinath C, O'Shea DJ, Collins J, et al. Inferring single-trial neural population dynamics using sequential auto-encoders. *Nat Methods*. 2018;15(10):805-815. doi:10.1038/s41592-018-0109-9.
293. Young D, Willett F, Memberg WD, et al. Signal processing methods for reducing artifacts in microelectrode brain recordings caused by functional electrical stimulation. *J Neural Eng*. 2018;15(2):026014. doi:10.1088/1741-2552/aa9ee8.
294. Willett FR, Murphy BA, Young DR, et al. A Comparison of Intention Estimation Methods for Decoder Calibration in Intracortical Brain-Computer Interfaces. *IEEE Trans Biomed*

- Eng.* 2017;65(9):2066-2078. doi:10.1109/TBME.2017.2783358.
295. Willett FR, Murphy BA, Memberg WD, et al. Signal-independent noise in intracortical brain-computer interfaces causes movement time properties inconsistent with Fitts' law. *J Neural Eng.* 2017;14(2):026010. doi:10.1088/1741-2552/aa5990.
296. Aflalo T, Kellis S, Klaes C, et al. Decoding motor imagery from the posterior parietal cortex of a tetraplegic human. *Science (80-)*. 2015;348(6237):906-910. doi:10.7910/DVN/GJDUTV.
297. Deer TR, Lamer TJ, Pope JE, et al. The Neurostimulation Appropriateness Consensus Committee (NACC) Safety Guidelines for the Reduction of Severe Neurological Injury. *Neuromodulation Technol Neural Interface.* 2017;20(1):15-30. doi:10.1111/ner.12564.
298. Chan DTM, Zhu XL, Yeung JHM, et al. Complications of Deep Brain Stimulation: A Collective Review. *Asian J Surg.* 2009;32(4):258-263. doi:10.1016/S1015-9584(09)60404-8.
299. Piacentino M, Pilleri M, Bartolomei L. Hardware-related infections after deep brain stimulation surgery: review of incidence, severity and management in 212 single-center procedures in the first year after implantation. *Acta Neurochir (Wien)*. 2011;153(12):2337-2341. doi:10.1007/s00701-011-1130-2.
300. Farris S, Giroux M. Deep brain stimulation: a review of the procedure and the complications. *JAAPA.* 2011;24(2):39-40, 42-45. <http://www.ncbi.nlm.nih.gov/pubmed/21387969>. Accessed May 10, 2019.
301. Boviatsis EJ, Stavrinou LC, Themistocleous M, Kouyialis AT, Sakas DE. Surgical and hardware complications of deep brain stimulation. A seven-year experience and review of the literature. *Acta Neurochir (Wien)*. 2010;152(12):2053-2062. doi:10.1007/s00701-010-0749-8.
302. Kozai TDY, Marzullo TC, Hooi F, et al. Reduction of neurovascular damage resulting from microelectrode insertion into the cerebral cortex using *in vivo* two-photon mapping. *J Neural Eng.* 2010;7(4):046011. doi:10.1088/1741-2560/7/4/046011.
303. Xiaowu H, Xiufeng J, Xiaoping Z, et al. Risks of intracranial hemorrhage in patients with Parkinson's disease receiving deep brain stimulation and ablation. *Parkinsonism Relat Disord.* 2010;16(2):96-100. doi:10.1016/j.parkreldis.2009.07.013.
304. Kochanski RB, Nazari P, Sani S. The Utility of Vancomycin Powder in Reducing Surgical Site Infections in Deep Brain Stimulation Surgery. *Oper Neurosurg.* 2018;15(5):584-588. doi:10.1093/ons/opx293.
305. Hardaway FA, Raslan AM, Burchiel KJ. Deep Brain Stimulation-Related Infections: Analysis of Rates, Timing, and Seasonality. *Neurosurgery.* 2018;83(3):540-547. doi:10.1093/neuros/nyx505.

306. Satyarthee GD. Optimal Strategy to Control Surgical Site Infection Following Deep Brain Stimulation Surgery: Adequate Management of Risk Factors, Topical Application of Vancomycin Powder in the Surgical Wound, and Preoperative Antibiotic Prophylaxis. *World Neurosurg.* 2017;101:789-790. doi:10.1016/j.wneu.2017.01.108.
307. Barrese JC, Aceros J, Donoghue JP. Scanning electron microscopy of chronically implanted intracortical microelectrode arrays in non-human primates. *J Neural Eng.* 2016;13(2):26003. doi:10.1088/1741-2560/13/2/026003.
308. Biran R, Martin DC, Tresco PA. The brain tissue response to implanted silicon microelectrode arrays is increased when the device is tethered to the skull. *J Biomed Mater Res Part A.* 2007;82A(1):169-178. doi:10.1002/jbm.a.31138.
309. Black BJ, Kanneganti A, Joshi-Imre A, et al. Chronic recording and electrochemical performance of Utah microelectrode arrays implanted in rat motor cortex. *J Neurophysiol.* 2018;120(4):2083-2090. doi:10.1152/jn.00181.2018.
310. Nolta NF, Christensen MB, Crane PD, Skousen JL, Tresco PA. BBB leakage, astrogliosis, and tissue loss correlate with silicon microelectrode array recording performance. *Biomaterials.* 2015;53:753-762. doi:10.1016/J.BIOMATERIALS.2015.02.081.
311. Stiller AM, Usoro J, Frewin CL, et al. Chronic intracortical recording and electrochemical stability of thiol-ene/acrylate shape memory polymer electrode arrays. *Micromachines.* 2018;9(10):1-14. doi:10.3390/mi9100500.
312. Szarowski DH, Andersen MD, Retterer S, et al. Brain responses to micro-machined silicon devices. *Brain Res.* 2003;983(1-2):23-35. <http://www.ncbi.nlm.nih.gov/pubmed/12914963>. Accessed February 27, 2019.
313. Goss-Varley M, Dona KR, McMahan JA, et al. Microelectrode implantation in motor cortex causes fine motor deficit: Implications on potential considerations to Brain Computer Interfacing and Human Augmentation. doi:10.1038/s41598-017-15623-y.
314. Feeney DM, Gonzalez A, Law WA. Amphetamine, haloperidol, and experience interact to affect rate of recovery after motor cortex injury. *Science.* 1982;217(4562):855-857. <http://www.ncbi.nlm.nih.gov/pubmed/7100929>. Accessed February 28, 2019.
315. Magill ST, Han SJ, Li J, Berger MS. Resection of primary motor cortex tumors: feasibility and surgical outcomes. *J Neurosurg.* 2018;129:961-972. <https://thejns.org/view/journals/j-neurosurg/129/4/article-p961.xml>. Accessed February 28, 2019.
316. Ouyang W, Yan Q, Zhang Y, Fan Z. Moderate injury in motor-sensory cortex causes behavioral deficits accompanied by electrophysiological changes in mice adulthood. *PLoS One.* 2017;12(2):e0171976. doi:10.1371/journal.pone.0171976.
317. Ajiboye AB, Willett FR, Young DR, et al. Restoration of reaching and grasping movements through brain-controlled muscle stimulation in a person with tetraplegia: a

proof-of-concept demonstration. *Lancet*. 2017. doi:10.1016/S0140-6736(17)30601-3.

Author Manuscript

TABLES

Table 1: Keywords and search structure for hardware complications in DBS

DBS Synonyms	Risk Synonyms
Deep brain stimulation, Thalamic stimulation	Hematoma, bleed*, “short circuit”, fracture, breakage, migration, infection, erosion, revision, risk, safety, adverse event*, “adverse effects”, complication*, hardware failure
[DBS OR DBS synonym...] AND [risk OR risk synonym...]	

(*) symbol at the end of a word to include other terms that begin with the root word (i.e. –ing, -s).

Table 2: Keywords and search structure for Utah arrays in humans

Utah Array Synonyms	Human Synonyms	Senior Authors
96 channel microelectrode array*, 96 channels electrode array*, microelectrode array*, intracortical microelectrode array*, intracortical brain computerinterface*, Neuroport array*	Human, subject*, patient*, tetraplegic*, quadriplegic*, person, people	Donoghue, Hochberg, Kirsh, Henderson, Shenoy, Greger, Normann, House, Cash, Jang, Zaghoul, Salas, Andersen, Schwartz, Rezai, Collinger, Scheon, Truccolo
[Utah array OR Utah array synonym...] AND [human OR human synonyms...] AND [senior author OR senior author...]		

(*) symbol at the end of a word to include other terms that begin with the root word (i.e. –ing, -s).

Table 3: DBS Hardware Related Adverse Events

Complication	Incidence (%)	No. of patients reported
Infection	3.79	1028 (27072)
IPG	44.2	265 (599)
scalp/burr hole	17.8	107 (599)
extension cable	13.6	82 (599)
lead	11.1	67 (599)
Lead migration	3.49	139 (3977)
Lead fracture or failure	2.53	208 (8214)
Hemorrhage	2.49	483 (19389)
intracerebral (ICH)	86.9	374 (430)

IPG	8.13	35 (430)
extension cable	1.62	7 (430)
Skin erosion	2.46	206 (8347)
IPG malfunction	2.33	101 (4320)
Tethering of extension cable	1.95	103 (5279)
Total Overall Complication	7.68	2098 (27299)

Table 4: Human Utah Array Implantation Sites and Senior Author Involvement

Chronic/Acute	Site	Senior Authors	No. of Implants
Chronic	University of Pittsburgh	Collinger JL	2
		Schwartz AB	
		Gaunt RA	
	California Institute of Technology, Rancho Los Amigos National Rehabilitation Hospital (RLA)	Andersen RA	3
	Brown University, Massachusetts General Hospital	Donoghue JP	12
		Hochberg LR	
		Henderson JM	
	Stanford University	Shenoy KV	12
		Kirsch RF	
	Case Western Reserve University	Ajiboye AB	1
Rezai AR			
Ohio State University	Sharma G	1	
Total Chronic Implants			18
Acute	University of Utah Health Sciences Center	House PA	2
		Greger B	
	Columbia University Medical Center	Normann RA	6
		Schevon CA	

Massachusetts General Hospital	Cash SS	3
	Truccolo W	7
National Institute of Health		6
	Zaghloul KA	
Total Acute Implants		30
Total Human Utah Array Implants		48

Table 5: Reported Duration of Chronic Human Implanted Utah Arrays

Location	Participant	Implantation Date	Reported Duration*	Adverse Events
University of Pittsburgh	S1	Feb 10,2012	987	S1 explanted due to skin retraction around the pedestals, no sign of infection
	S2	-	673	
California Institute of Technology	EGS	-	630	
	NS	-	-	
	FG	-	56	
BrainGate2	S1	-	90	T7 death unrelated to research
	S3	Nov 30, 2005	1975	
	A1	Feb 2006	239	
	T1	-	270	
	T2	Jun 2011	474	
	T5	Aug 2016	70	
	T6	Dec 7, 2012	837	
	T7	Jul 30, 2013	548	
	T8	Dec 1, 2014	928	
	T9	-	-	
	T10	-	33	
MN	Jun 2004	300		
Ohio State University	S1	-	1144	

*Reported duration is not equivalent to Utah array failure

Table 6: Example Power Analysis

Complication	Sample size needed to reject Null			Power (1- β)	α
	1.5x	2x	5x		
Infection	602	167	15	.80	.05
Skin erosion	692	193	18	.80	.05
Hemorrhage	956	267	25	.80	.05
Extension cable malfunctions	1555	435	41	.80	.05

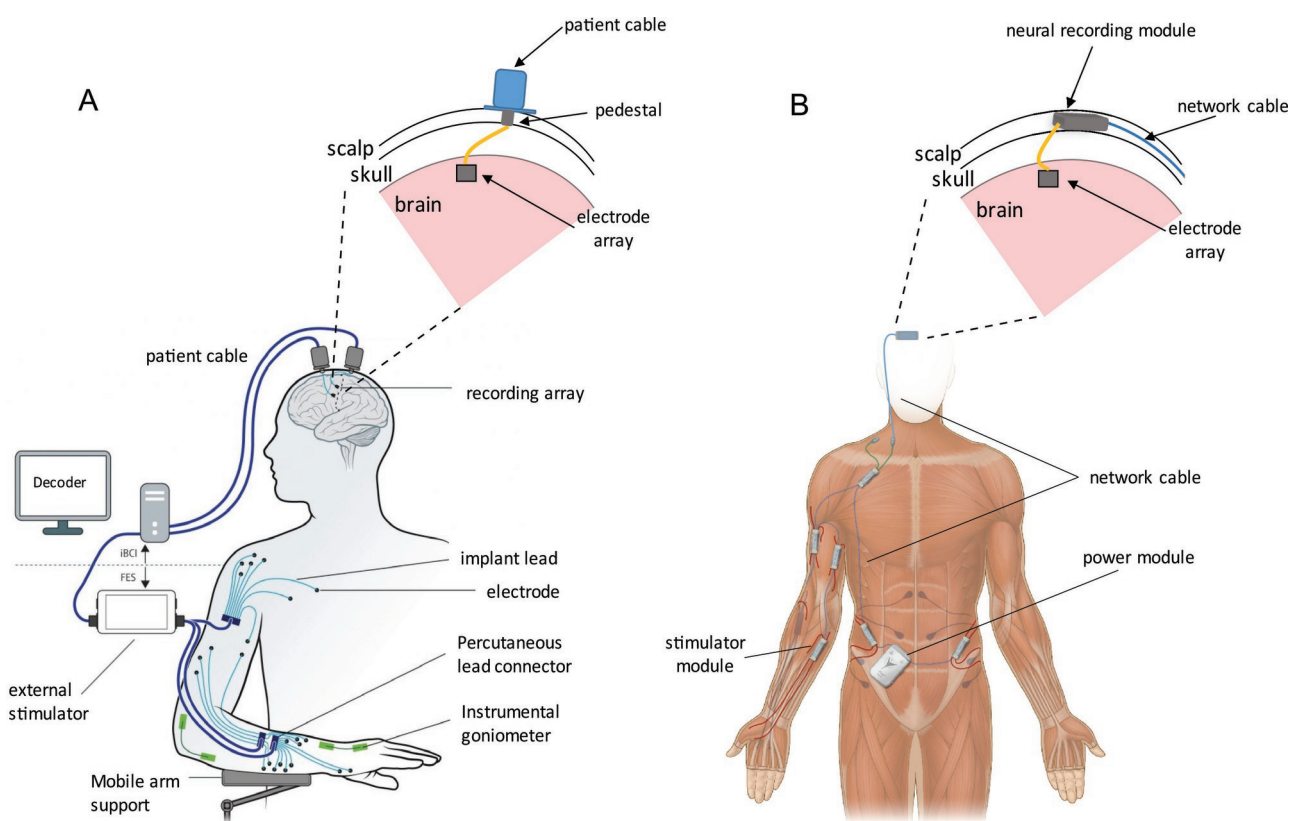
Figure Legends

Figure 1. Intracranial Neuroprosthetic Systems. A) An overview of the standard brain machine interfaces set up. An electrode is implanted in the brain and percutaneous connections are made between the patient and a series of computers. This particular example is of brain-controlled FES³¹⁷. B) An example of a potential future brain machine interface set up using a modular network. An electrode is implanted in the brain and connected to an implantable module for processing instead of a series of computers. This portrays the potential for a fully implantable brain-controlled FES system using the NNP.

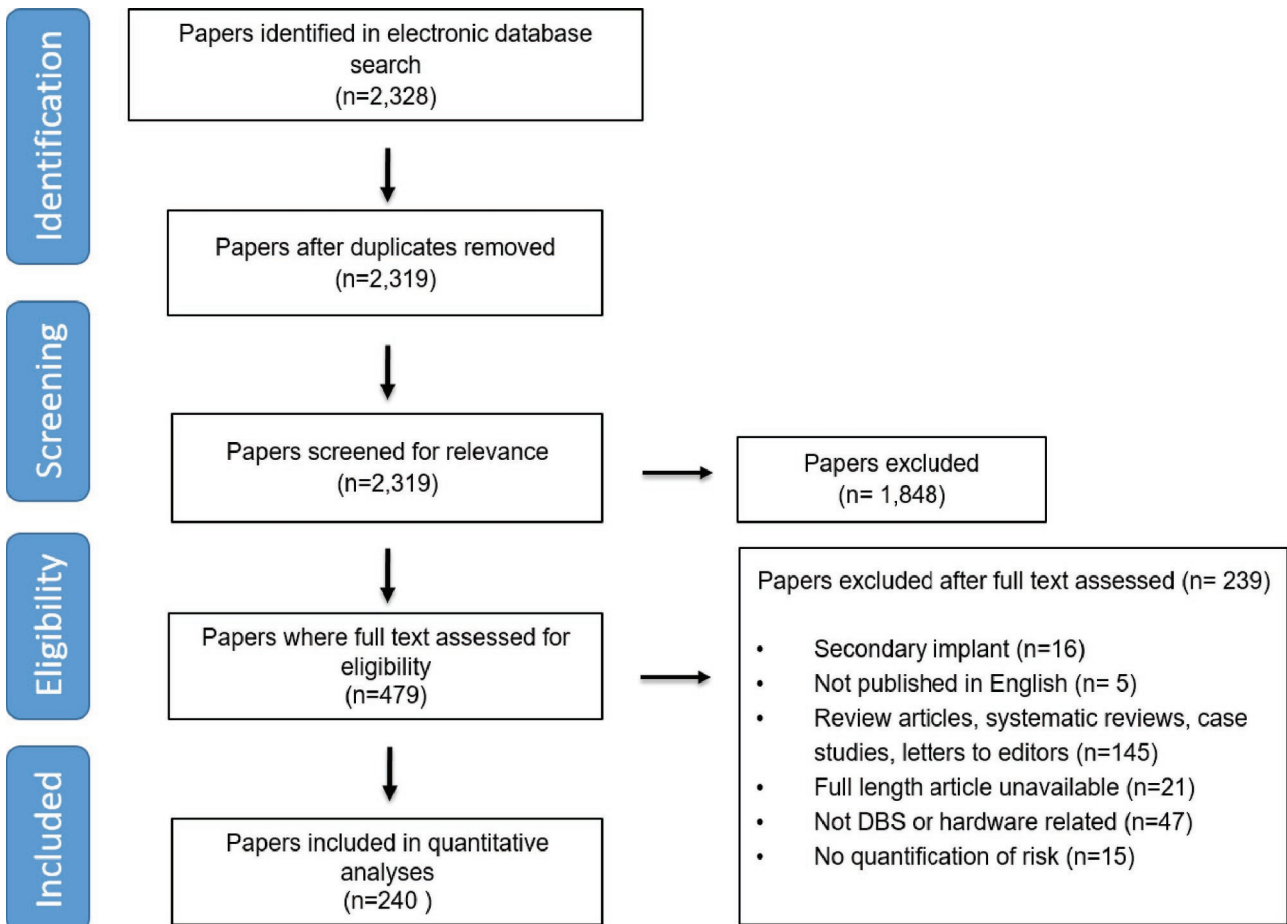
Figure 2. Flow diagram of the study selection for DBS hardware complications based on inclusion and exclusion criteria.

Figure 3. Flow diagram of the study selection for Utah arrays based on inclusion and exclusion criteria.

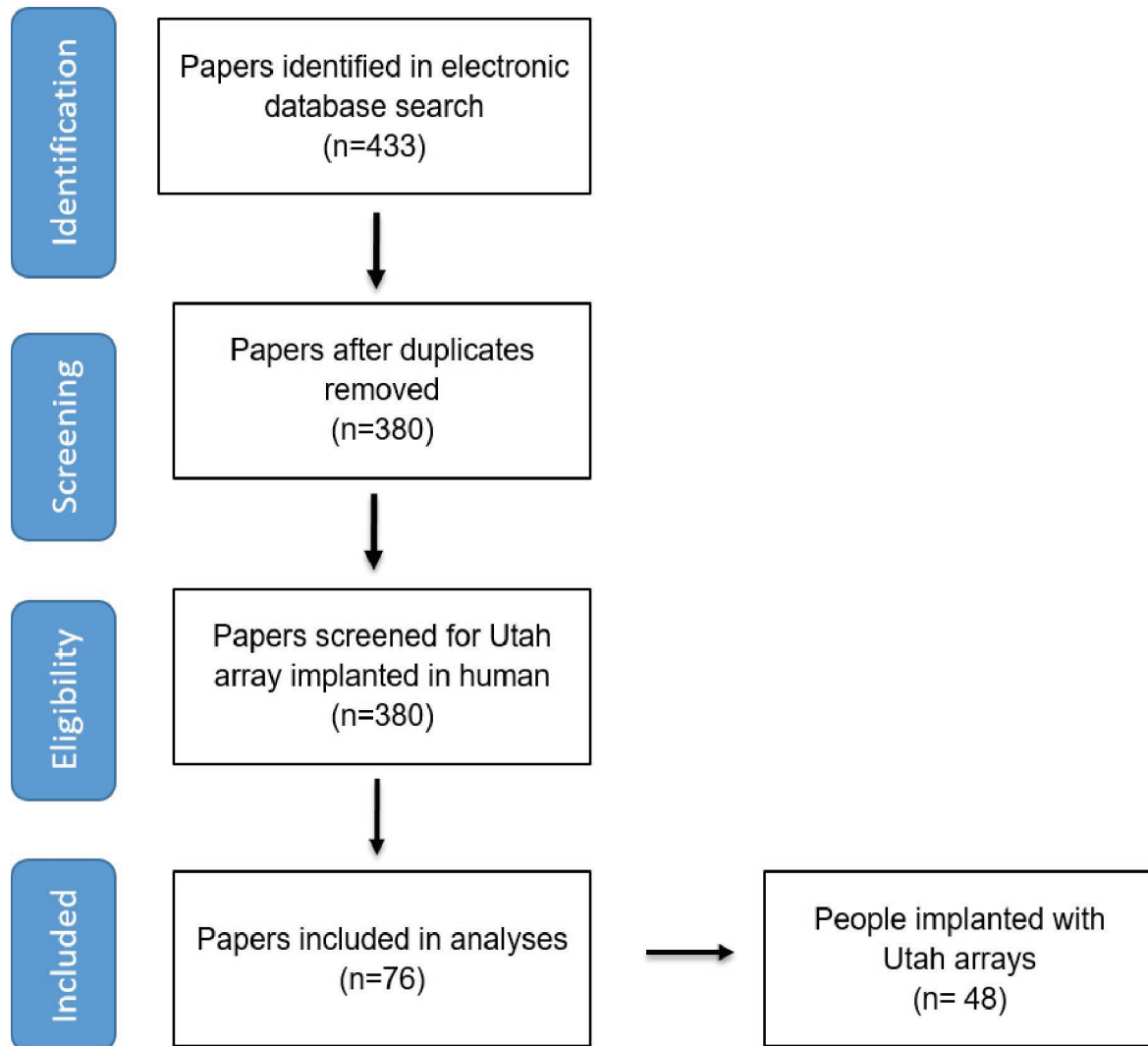
Figure 4: Length of chronic human implants reported in literature across clinical study sites.



ner_13069_figure 1.eps

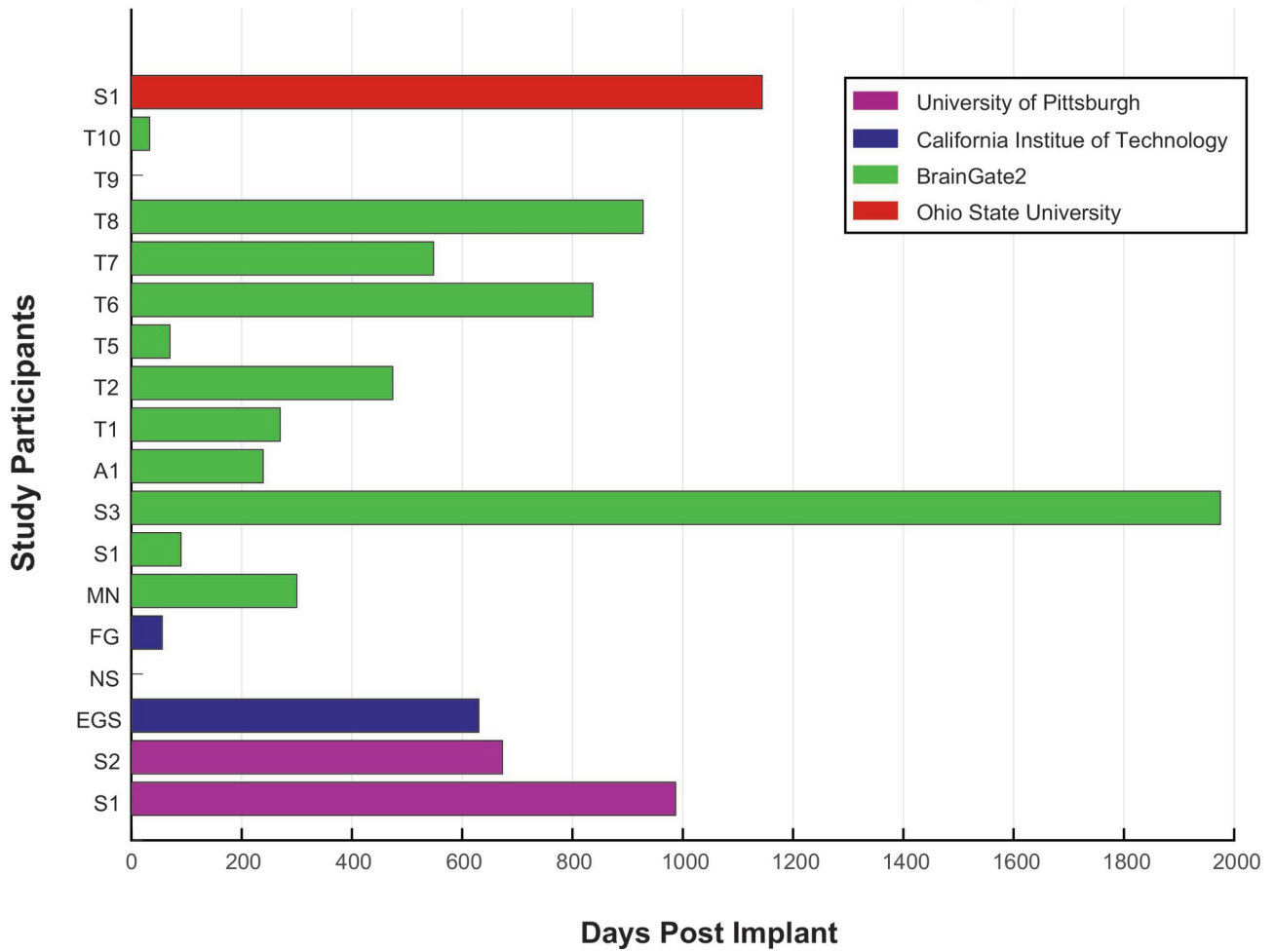


ner_13069_figure 2.eps



ner_13069_figure 3.eps

Chronic Human Utah Array Implants



ner_13069_figure 4.eps

Neuromodulation Authorship and Contributorship Form

Manuscript Title: Estimating Risk for Future Intracranial, Fully Implanted, Modular Neuroprosthetic Systems

1) Please confirm the following:

- Confirm the accuracy of the content and that the content of the manuscript represents the authors' work/opinions and not those of the sponsoring agent(s), if any.
- Confirm that the corresponding author agrees to communicate with all other authors and will obtain their approval for the final version to be published.
- Confirm that all authors are listed and have made substantial contributions to:
 - the research design, or the acquisition, analysis or interpretation of data; and to
 - drafting the paper or reviewing it critically;
 - and that all authors have approved the submitted version

2) Give a short description of each individual's contribution to the research and its publication (e.g. designed study, analyzed data, drafted paper).

Sample authorship description and acknowledgement:

Drs. A, B and C designed and conducted the study, including patient recruitment, data collection, and data analysis. Dr. A prepared the manuscript draft with important intellectual input from Drs. B and C. All authors approved the final manuscript. [Insert name of organization] provided funding for the study, statistical support in analyzing the data with input from Drs. A, B and C, and also provided funding for editorial support. Drs. A, B and C had complete access to the study data. We would like to thank Dr. D for her editorial support during preparation of this manuscript

AB, CC, PGP were responsible for creating the protocol for the literature search and inclusion criteria, analyzing and interpreting the data, and drafting the manuscript. AB, BH, and JL were responsible for reviewing abstracts and full-length papers for inclusion and data extraction. AB, BH, JL, CC, PGP were responsible for reviewing and approving the final manuscript.

3) Was this research or its publication assisted by any non-financial or 'in-kind' contributions? (e.g. provision of study design, data collection, data analysis, writing assistance, literature searching, administrative support, supply of materials).

YES NO

If yes, state the identity of the individuals who provided this assistance and disclose the source of any material or financial support:

Corresponding Author: *Peter* Date: 1/27/2019



Statement on Real or Perceived Conflicts of Interest for Authors

Information pertaining to *all* authors must be entered on this form

Neuromodulation: Technology at the Neural Interface has a primary responsibility to its readers and to the public to provide in its pages clear and unbiased scientific results and analyses. Although we rely on the expertise of our Editors, Editorial Board members and our peer reviewers to help us accomplish this, we believe that our readers should be informed of additional relationships of our authors that could pose a conflict of interest. Thus, for readers to evaluate the data and opinions presented in *Neuromodulation: Technology at the Neural Interface*, they must be informed of financial and other interests of our authors that may be at odds with unbiased presentation of data or analysis.

Therefore, *Neuromodulation: Technology at the Neural Interface* believes that all manuscripts should be accompanied by clear disclosures from all authors of their affiliations, funding sources, or financial holdings that might raise questions about possible sources of bias. Disclosure is accomplished in three ways:

First, by a complete listing of the current institutional affiliations of the authors.

This list must include academic as well as corporate and other industrial affiliations. As the editors deem appropriate, items in this list will be included in the author affiliations printed in the manuscript. Please indicate below:

- All affiliations of all authors are listed on the title page of the paper.
- Additional affiliations not on the title page are:

Second, through the acknowledgment of all financial contributions to the work being reported, including contributions “in kind.”

All funding sources will be listed in the published manuscript. Please indicate below:

- All funding sources for this study are listed in the acknowledgement section of the paper.
- Additional funding sources not noted in the manuscript are:

Third, through the execution of a statement disclosing to the Editors all financial holdings, professional affiliations, advisory positions, board memberships, patent holdings and the like that might bear a relationship to the subject matter of the contribution.

The Editors will determine whether the material disclosed to them should be published as part of the article. Please check the appropriate items below:

The following are declarable relationships:

Financial: Significant financial interest (equity holdings or stock options) in any corporate entity dealing with the material or the subject matter of this contribution. Please disclose the entity and the nature of the holding.

None

One or more authors has a financial relationship, as described below:

Management/Advisory Affiliations: Within the last 3 years, status as an officer, a member of the Board, or a member of an Advisory Committee of any entity engaged in activity related to the subject matter of this contribution. Please disclose the nature of these relationships and the financial arrangements.

None

One or more authors has a management/advisory relationship, as described below:

Paid Consulting: Within the last 3 years, receipt of consulting fees, honoraria, speaking fees, travel fees or expert testimony fees from entities that have a financial interest in the results and materials of this study. Please enumerate.

None

One or more authors has a paid consulting relationship, as described below:

Patents: A planned, pending, or awarded patent on this work by any of the authors or their institutions. Please explain.

None


One or more authors or the authors' institutions has a patent related to this work, as described below:

x All authors declare that we have read *Neuromodulation: Technology at the Neural Interface's* full Conflict of Interest Policy and have disclosed all declarable relationships as defined therein, if any.

Manuscript Number: NER-2709-01-2019.R2

Title: Estimating Risk for Future Intracranial, Fully Implanted, Modular Neuroprosthetic Systems: A systematic review of hardware complications in clinical deep brain stimulation and experimental human intracortical arrays

First Author: A Bullard

Signature:  **Date: 10/2/19**

This form must be completed and submitted to the **Neuromodulation Editorial Office** prior to your manuscript's publication. Submit form to:

Neuromodulation, 2000 Van Ness Avenue, Suite 414
San Francisco, CA 94109 USA
Fax: +1.415.683.3218 Email: INS@neuromodulation.com

DBS	Risks
1. Deep brain stimulation [Title/Abstract] 2. Deep brain stimulation [MeSH] 3. Thalamic stimulation	Hematoma, bleed*, "short circuit", fracture, breakage, migration, infection, erosion, revision, risk, safety, adverse event*, "adverse effects", complication*, hardware failure

[DBS **OR** DBS synonym...] **AND** [risk **OR** risk synonym...]

ner_13069_table 1.eps

Utah Array	Human	Senior Authors
96 channel microelectrode array*, 96 channel electrode array*, microelectrode array*, intracortical microelectrode array*, intracortical brain computer interface*, Neuroport array*	Human, subject*, patient*, tetraplegic*, quadraplegic*, person, people	Donoghue, Hochberg, Kirsch, Henderson, Shenoy, Greger, Normann, House, Cash, Jang, Zaghloul, Salas, Andersen, Shwartz, Rezai, Collinger, Schevon, Truccolo, Zaghloul

[Utah array **OR** Utah array synonym...] **AND** [human **OR** human synonym...] **AND** [Senior Author **OR** Senior Author...]

ner_13069_table 2.eps

Table 3: DBS Hardware Related Adverse Events

Complication	Incidence (%)	No. of patients reported
Infection	4.57	951 (20805)
IPG	20.4	2957 (14495)
scalp/burr hole	9.70	1406 (14495)
extension cable	8.24	1194 (14495)
lead	1.03	149 (14495)
IPG malfunction	3.25	141 (4331)
Hemorrhage	2.86	425 (14831)
intracerebral (ICH)	52.9	6340 (11963)
IPG	22.1	2655 (11963)
Extension cable	2.35	281 (11963)
Lead migration	2.58	121 (4677)
Lead fracture or failure	2.56	178 (6940)
Skin erosion	2.22	198 (8924)
Tethering of extension cable	1.63	84 (5145)
Total Overall Complication	7.68	2098 (27299)

ner_13069_table 3.eps

Table 4: Human Utah Array Implantation Sites and Senior Author Involvement

Chronic/Acute	Site	Senior Authors	No. of Implants
Chronic	University of Pittsburgh	Collinger JL	2
		Schwartz AB	
		Gaunt RA	
	California Institute of Technology, Rancho Los Amigos National Rehabilitation Hospital (RLA)	Andersen RA	3
	Brown University, Massachusetts General Hospital	Donoghue JP	11
		Hochberg LR	
	Stanford University	Henderson JM	11
	Case Western Reserve University	Shenoy KV	
		Ohio State University	Kirsch RF
	Ajiboye AB		
Total Chronic Implants			18
Acute	University of Utah Health Sciences Center	House PA	2
		Greger B	
		Normann RA	
	Columbia University Medical Center	Schevon CA	6
	Massachusetts General Hospital	Cash SS	3
		Truccolo W	
	National Institute of Health	Zaghloul KA	6
Total Acute Implants			30
Total Human Utah Array Implants			48

ner_13069_table 4.eps

Table 5: Reported Duration of Chronic Human Implanted Utah Arrays

Location	Participant	Implantation Date	Reported Duration*	Adverse Events
University of Pittsburgh	S1	Feb 10,2012	987	S1 explanted due to skin retraction around the pedestals, no sign of infection
	S2	-	673	
California Institute of Technology	EGS	-	630	
	NS	-	-	
	FG	-	56	
BrainGate2	S1	-	90	T7 death unrelated to research
	S3	Nov 30, 2005	1975	
	A1	Feb 2006	239	
	T1	-	270	
	T2	Jun 2011	474	
	T5	Aug 2016	70	
	T6	Dec 7, 2012	837	
	T7	Jul 30, 2013	548	
	T8	Dec 1, 2014	928	
	T9	-	-	
	T10	-	33	
MN	Jun 2004	300		
Ohio State University	S1	-	1144	

*Reported duration is not equivalent to Utah array failure

ner_13069_table 5.eps

Table 6: Example Power Analysis

Complication	Sample size needed to reject Null			Power (1- β)	α
	1.5x	2x	5x		
Infection	602	167	15	.80	.05
Skin erosion	692	193	18	.80	.05
Hemorrhage	956	267	25	.80	.05
Extension cable malfunctions	1555	435	41	.80	.05

ner_13069_table 6.eps