

Title

Registering Maxillomandibular Relation to Create a Virtual Patient Integrated with a Virtual Articulator for Complex Implant Rehabilitation: A Clinical Report

Running Title

Dynamic Virtual Patient

Authors (First[Given name] Middle Last[Family name])

Junying Li, DDS, MS PhD,¹ Zhaozhao Chen, DDS, MS, PhD,² Bo Dong, BDT,³ Hom-Lay Wang, DDS, MSC, PhD,⁴ Tim Joda, DMD, MSc, PhD,⁵ and Haiyang Yu, DDS, PhD⁶

Institutions

¹ Graduate Student, State Key Laboratory of Oral Diseases, National Clinical Research Center for Oral Disease, West China Hospital of Stomatology, Sichuan University, Chengdu, PR China.

Research fellow, Department of Periodontics and Oral Medicine, University of Michigan School of Dentistry, Ann Arbor, MI.

² Graduate Student, Department of Periodontics and Oral Medicine, University of Michigan School of Dentistry, Ann Arbor, MI.

³ Technician, Department of Dental Technology, West China Hospital of Stomatology, Sichuan University, Chengdu, PR China.

⁴ Professor, Department of Periodontics and Oral Medicine, University of Michigan School of Dentistry, Ann Arbor, MI.

This is the author manuscript accepted for publication and has undergone full peer review but has not been through the copyediting, typesetting, pagination and proofreading process, which may lead to differences between this version and the [Version of Record](#). Please cite this article as [doi: 10.1111/jopr.13204](https://doi.org/10.1111/jopr.13204).

This article is protected by copyright. All rights reserved.

⁵ Professor, Department of Reconstructive Dentistry, University Center for Dental Medicine Basel,
University of Basel, Basel, Switzerland

⁶ Professor, State Key Laboratory of Oral Diseases, National Clinical Research Center for Oral
Disease, West China Hospital of Stomatology, Sichuan University, Chengdu, PR China.

Conflict of interest: The authors declare no conflicts of interest, either directly or indirectly, in the
information or products listed in the paper.

Funding: Supported by the National Natural Science Foundation of China (81571006).

Corresponding author:

Dr. Haiyang Yu

Department of Prosthodontics

West China Hospital of Stomatology

Sichuan University

14 Renmin South Road, 3rd section

Chengdu, Sichuan 610041

PR CHINA

Email: yhyang6812@scu.edu.cn

Accepted May 12, 2020

ABSTRACT

The virtual patient, a unique computer simulation of the patient's face, teeth, oral mucosa, and bone, provides an extraordinary mechanism for digital dental implant surgery planning and prosthetic design. However, the seamless registration of digital scans with functional information in the context of a virtual articulator remains a challenge. This report describes the treatment of a 47-year-old male with full-mouth guided immediate implant placement and immediate loading of CAD/CAM interim prostheses. Utilizing a novel digital workflow, a multifactorial registration of the vertical dimension of occlusion, centric occlusion, and facebow record were completed digitally and paired within a digital articulator. Utilizing this innovative approach, a complex treatment plan and procedure was executed smoothly with a successful prosthetic outcome demonstrating good fit, occlusion, esthetics, and patient reported satisfaction.

Recent technological developments have increased the use of digital tools in the field of dentistry.^{1,2} Three dimensional (3D) imaging techniques, such as cone beam computed tomography (CBCT), intraoral scanners (IOS), and extraoral scanners (EOS) are now fluidly integrated within modern diagnostics and treatment simulation/execution of clinical practice.³ Computer-aided design and computer-aided manufacturing (CAD/CAM) techniques enable dentists to fabricate surgical implant templates and prostheses (both interim and definitive) in a highly accurate and efficient manner.⁴⁻⁷ Using varied digital technologies a virtual patient can be created and utilized to aid in dental diagnosis and advanced treatment simulations.⁷

A virtual patient is created by superimposing varied 3D images from an actual patient. The simulation provides a 3D surface as a volume rendering of the face, teeth, oral soft tissue and bony structures.⁹⁻¹⁰ Thus, in this platform, information needed for dental diagnosis and treatment planning can be completed even when the actual patient is absent. As a result, appointment numbers can be minimized, while maximizing clinical care.⁷ In cases that require implant surgery and rehabilitation, the virtual patient can be utilized to both design esthetic/functional prostheses and plan prosthetic-driven, computer-assisted implant surgeries.⁶

In the 3D reconstruction of hard and soft tissue, functional data (i.e. hinge axis position, centric relation (CR), and vertical dimension of occlusion (VDO)) are essential to the dental rehabilitation procedure.¹¹⁻¹⁵ The correct CR and VDO is the starting point for prosthetic design. Furthermore, the correct location of the hinge axis is the basis for the dynamic simulation of mandibular movement on a virtual articulator.^{13,16} Recently, several articles reported use of a virtual patient for full-arch implant surgery and restoration.^{6,17,18} However, the authors failed to include registration of CR, VDO, and hinge axis position and transfer of this data to their dynamic bite simulation, even in the presence of unstable occlusion. Therefore, this clinical report aims to provide a description of dynamic virtual patient simulations that also incorporate a workflow with proper CR, VDO, and location of hinge axis for complex implant rehabilitation cases.

Clinical report

A 47-year-old male suffered from partial edentulism was referred to our clinic. Clinical and radiographic examinations illuminated poor oral hygiene, stage IV and Grade C periodontitis according to the 2017 world workshop,¹⁹ and Miller grade II to III mobility among the remaining dentition. Tooth migration and shifting were present. An increased horizontal overlap of 12 mm, vertical overlap of 8 mm, as well as the loss of VDO was also observed (Fig 1 A, B, C, D). After discussion of risks and benefits provided by our different treatment options, the patient chose full-mouth implant-supported fixed prosthesis via immediate implant placement and loading. As such, accurate functional data became an essential first step in order to initiate treatment planning and surgical simulation.

In the first visit, intraoral scans were obtained using an intraoral scanner (TRIOS; 3Shape, Copenhagen, Denmark) after the initial consultation. To align the scans in approximate CR and VDO, a wax rim was made and used to support the occlusion and an optical occlusal scan was made. From the scans, custom bases for a gothic arch tracer (Gnathometer "M"; Ivoclar, Schaan, Liechtenstein) were designed using the bite splint module of a dental CAD software (Exocad version 2.2; exocad

GmbH, Darmstadt, Germany) and free CAD software (Meshmixer; Autodesk, San Rafael, CA). Two sets of bases and one set of jaw models were 3D-printed (Fig 2 A, B, C).

In the second visit, a gothic arch tracing was performed to determine the accurate VDO and CR. The VDO was estimated at 3 mm less than vertical dimension of rest. Then, the record was registered by injecting bite registration silicon material between the tracer rims (Fig 3A-C). The jaw models were then arbitrarily mounted on an articulator using the record (Fig 3D). Subsequently, a metal-free occlusal record was made by duplicating using another set of tracer base (Fig 3E). The new record was fitted to the patient's mouth, sustaining VDO and CR (Fig 3F) and a CBCT scan (field of view: 10 x 14 cm) was performed with a scanner (3D Accuitomo 170; J. Morita, Osaka, Japan) at the same time. Therefore, the CR and VDO records were transferred to the CBCT images. Digital Imaging and Communications in Medicine (DICOM) files were exported. In the CBCT image, the maxilla, mandible, infraorbital point, and external acoustic meatus area were captured for virtual articulator mounting. A 3D scanner (3dMDtrio System; 3dMD) was used to capture the patient's face during a smile and the scan was subsequently exported in a stereolithography (STL) file format.

DICOM files were converted into 3D models of the skeletal maxilla and mandible. Three-dimensional reconstruction of the face was completed using an implant planning software (Blue Sky Plan; Blue Sky Bio, Libertyville, IL). Arbitrary hinge-axis was located using Bergstrom's points (10 mm anterior to the Porion and 7 mm below the Frankfort horizontal plane) and marked with a long 3D shaft in Meshmixer (Fig 4A).^{20,21} The 3D images of the face scan, intraoral scans, and skull reconstruction were superimposed within the dental CAD software to create a virtual patient. This virtual patient was mounted on a virtual articulator by matching the arbitrary hinge-axis and face (Fig 4B).²⁰ With the digital articulator, the mandibular movement of the patient could be simulated according to the individualized TMJ-jaw relationship (Video 1). Average sagittal condylar inclination and Bennett angle were set on the virtual articulator.

Based on the virtual patient, prostheses for immediate loading were designed, and the occlusal scheme was tested (Fig 4C). The virtual prostheses were imported into the implant planning software.

According to the restorative dimensions, ridge reduction and 3D position of implants were planned (Fig 4D). Given that the soft tissue shape after surgery would be quite unpredictable, a 4 mm space between the reduced ridge and interim prosthesis bottom was designed. Two-piece surgical templates were designed by combining implant planning software and free CAD software (Meshmixer). The templates were then fabricated by stereolithography, and the restorations were milled from polymethylmethacrylate (PMMA) blocks (Fig 5).

The implant surgery was performed on the third visit (Fig 6). A tooth-supported template was used to prepare anchor pin beds under local anesthesia. After tooth extraction and flap elevation, the bone reduction guide was fitted over the alveolar ridge and fixed by anchor pins. Following ridge reduction, 14 implants (Straumann Bone Level, Roxolid SLActive; Straumann) were placed (8 in the maxilla, 6 in the mandible) in a fully guided approach with an insertion torque of 35 to 45 Ncm. Abutments (RC screw-retained abutments; Straumann) were placed under the torque of 35 Ncm, and interim copings (Coping for Screw-retained Abutments; Straumann) were attached with a torque of 15 Ncm. The interim restoration was then assembled on the bone reduction guide to secure its 3D position. Then, the interim restoration was connected with the interim coping using an autopolymerizing acrylic resin (CHAIRSIDE® Attachment Processing Material; Zest Dental). The interim prostheses were finished and polished in the lab. Following flap closure, the prostheses were delivered with good fit and esthetics (Fig 7A, B). A few adjustments were made in the posterior area to adjust occlusion. The adjusted interim prostheses showed even bilateral symmetrical contacts in maximum intercuspation and group function contacts in lateral movements. Five months later, impressions were made and superimposed to the same virtual patient. The definitive prostheses were based on the interim restorations. The original design of midline, position of maxillary incisor edge, VDO, and CR were satisfying so they remained the same. What were modified were the inclination of maxillary anterior teeth and the intaglio surface. The modifications were made to accommodate the change of alveolar ridge and soft tissue after healing. The definitive implant-supported fixed prostheses with milled metal framework, monolithic zirconia crowns, and layered composite resin gingiva were delivered at the sixth month after the surgery (Fig 7C,D, Fig 8).

Discussion

The virtual patient exhibits incredible potential for use in complex implant surgery with rehabilitation treatment. Both the surgical planning and prosthesis design can be facilitated by having detailed bone, intraoral soft tissue, and facial reconstructions. Patients facing complete loss of dentition generally also have an unstable occlusion. Hence, it is difficult to obtain accurate VDO and CR measurements from existing MIP alone. To this end, a new workflow to create virtual patients with functionally correct information is imperative for such complex clinical scenarios.

In the described workflow, a maxillomandibular relationship record device was applied when obtaining CBCT images to maintain maxilla and mandible position. Furthermore, the virtual patient helped integrate VDO, CR, mandibular movement simulation, and facial soft tissue data. These data allowed the digital design and occlusal adjustment of the prostheses prior to the surgery and reduced occlusal adjustments during prosthetic delivery. When connecting the prostheses with temporary abutments during the procedure, maintenance of their 3D position is important. To ensure this, prostheses were designed based on maxilla and mandible bone, and they could be assembled as a bone-supported guide during the intraoral conversion procedure. Similar procedures have been reported previously.^{6,17} Instead of the use of a polyvinyl siloxane carrier to fit the prosthesis on a guide, a ball-rod structure was used which allows a space between the ridge and prosthesis for the rubber-dam and soft tissue.

Despite the positive aspects of this workflow, there remain limitations. When the patient has remaining teeth, obtaining an occlusal record with increased VDO using the gothic arch tracer is difficult. In this situation, the VDO should be reduced on the virtual articulator before designing the prostheses. This problem may be avoided altogether through the use of smaller-sized gothic arch tracer components. Moreover, it is suggested to also prepare immediate denture before the surgery just in case the primary stability was not enough for immediate loading of fixed interim restorations.

Summary

This clinical report describes a digital workflow using an occlusal registration device, CBCT images, and a facial scan to create a virtual patient integrated with a virtual articulator. Use of these data for digital treatment planning, computer-assisted immediate implant surgery, and immediate delivery of CAD/CAM interim complete dental prostheses has potentially very useful applications to the advancement of dental clinical care.

Acknowledgement

We would like to offer our special thanks to Ann Decker for furnishing the language of this article.

We also thank Jiayi Yu for her assistance in the 3D printing of surgical templates and models.

Supported by the National Natural Science Foundation of China (81571006).

REFERENCES

1. Eaton KA, Reynolds PA, Grayden SK, et al: A vision of dental education in the third millennium. *Br Dent J* 2008;205:261-271
2. Schoenbaum TR: Dentistry in the digital age: an update. *Dent Today* 2012;31:108, 110, 112-113
3. Joda T, Zarone F, Ferrari M: The complete digital workflow in fixed prosthodontics: a systematic review. *BMC Oral Health* 2017;17:124
4. Chen Z, Li J, Sinjab K, et al: Accuracy of flapless immediate implant placement in anterior maxilla using computer-assisted versus freehand surgery: A cadaver study. *Clin Oral Implants Res* 2018;29:1186-1194
5. Li J, Chen Z, Chan H-L, et al: Does flap opening or not influence the accuracy of semi-guided implant placement in partially edentulous sites? *Clin Implant Dent Relat Res*;21: 1253-1261
6. Harris BT, Montero D, Grant GT, et al: Creation of a 3-dimensional virtual dental patient for computer-guided surgery and CAD-CAM interim complete removable and fixed dental prostheses: A clinical report. *J Prosthet Dent* 2017;117:197-204
7. Joda T, Gallucci GO: The virtual patient in dental medicine. *Clin Oral Implants Res* 2015;26:725-726
8. Lee CYS, Ganz SD, Wong N, et al: Use of cone beam computed tomography and a laser intraoral scanner in virtual dental implant surgery: part 1. *Implant Dent* 2012;21:265-271
9. Lin H-H, Chiang W-C, Lo L-J, et al: Artifact-resistant superimposition of digital dental models and cone-beam computed tomography images. *J Oral Maxillofac Surg* 2013;71:1933-1947
10. Plooij JM, Maal TJJ, Haers P, et al: Digital three-dimensional image fusion processes for planning and evaluating orthodontics and orthognathic surgery. A systematic review. *Int J Oral Maxillofac Surg* 2011;40:341-352
11. Pitchford JH: A reevaluation of the axis-orbital plane and the use of orbitale in a facebow transfer record. *J Prosthet Dent* 1991;66:349-355

12. Bailey J, Nowlin T: Evaluation of the third point of reference for mounting maxillary casts on the Hanau articulator. *J Prosthet Dent* 1984;51:199-201
13. Squier RS: Jaw relation records for fixed prosthodontics. *Dent Clin North Am* 2004;48:vii, 471-486
14. Nagy WW, Goldstein GR: Facebook use in clinical prosthodontic practice. *J Prosthodont*. 2019;28:772-774
15. Yu H, Zhao Y, Li J, et al: Minimal invasive microscopic tooth preparation in esthetic restoration: a specialist consensus. *Int J Oral Sci* 2019;11:1-11
16. Kordass B, Gärtner C, Söhnel A, et al: The virtual articulator in dentistry: concept and development. *Dent Clin North Am* 2002;46:493-506
17. Lewis RC, Harris BT, Sarno R, et al: Maxillary and mandibular immediately loaded implant-supported interim complete fixed dental prostheses on immediately placed dental implants with a digital approach: A clinical report. *J Prosthet Dent* 2015;114:315-322
18. Shao J, Xue C, Zhang H, et al: Full-Arch Implant-Supported Rehabilitation Guided by a Predicted Lateral Profile of Soft Tissue. *J Prosthodont* 2019;28:731-736
19. Papapanou PN, Sanz M, Buduneli N, et al: Periodontitis: Consensus report of workgroup 2 of the 2017 World Workshop on the Classification of Periodontal and Peri-Implant Diseases and Conditions. *J Periodontol* 2018;89 Suppl 1:S173-182
20. Lepidi L, Chen Z, Ravidá A, et al: A Full-Digital Technique to Mount a Maxillary Arch Scan on a Virtual Articulator. *J Prosthodont* 2019;28:335-338
21. Bergstrom G: On the reproduction of dental articulation by means of articulators: A kinematic investigation. *Acta Odontol Scand* 1950;9:3-149

Figure 1 Pretreatment condition. A, Facial photo at smile. B, Panoramic radiograph. C, Occlusal view of upper jaw. D, Occlusal view of lower jaw.

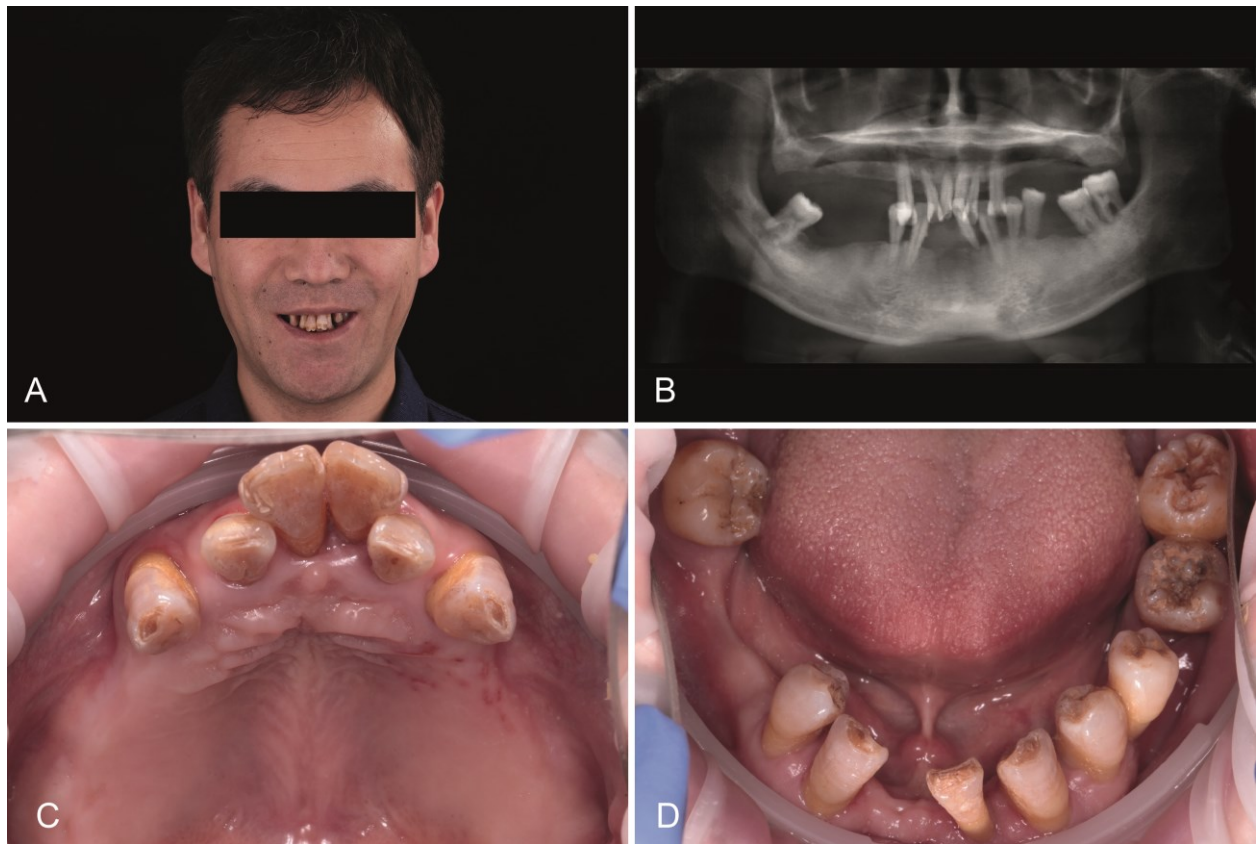
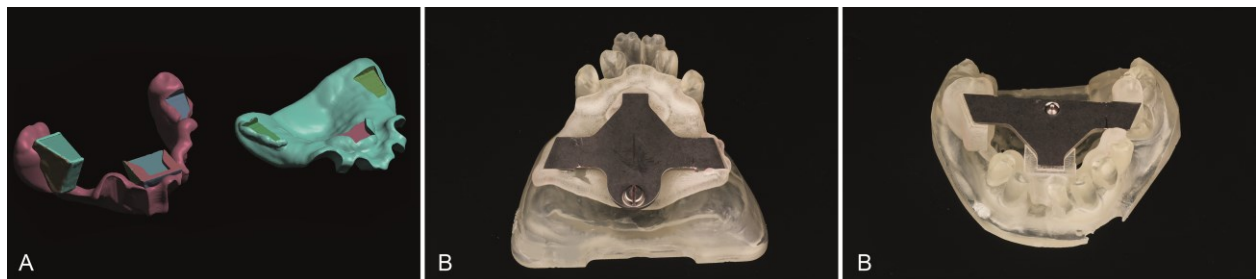

Figure 2 A, Digital design of bases for gothic arch tracer. B, Printed maxillary jaw model and gothic arch tracer. C, Printed mandibular jaw model and gothic arch tracer.



Auti

Figure 3 A, Gothic arch tracer fitted in mouth. B, Mandibular movement racing. C, Fixed bite record. D, Jaw models arbitrarily mounted on an articulator. E, Duplicated metal-free bite record. F, New record fitted in mouth.

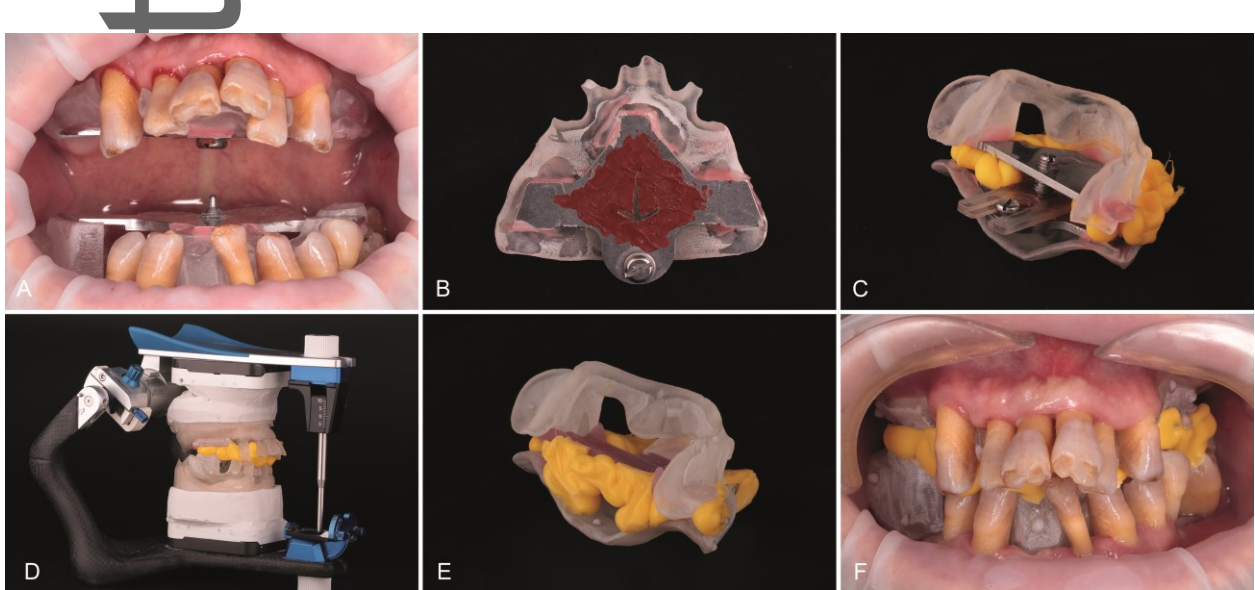


Figure 4 A, CBCT reconstruction with shafts passing through hinge axis and Porion. B, The location of hinge axis (Passing through Bergstrom's point). C, Virtual patient integrated with digital articulator. D, Prosthetic-driven digital implant planning.

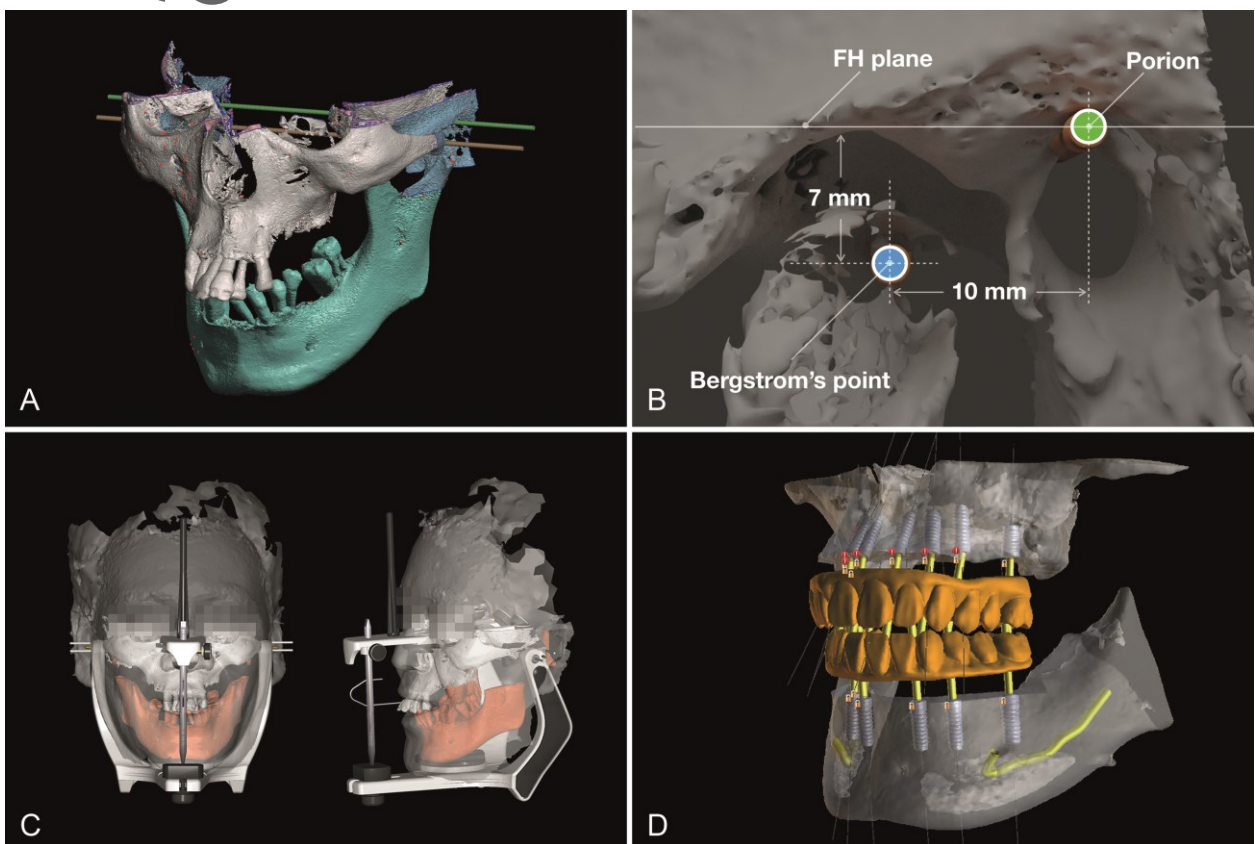


Figure 5 A, Mandibular two-piece surgical templates and interim restoration. B, Maxillary two-piece surgical templates and interim restoration. C, Digital design of interim prostheses connected with bone reduction guide. D, CAD/CAM interim prostheses assembled with surgical templates on 3D-printed bone models.

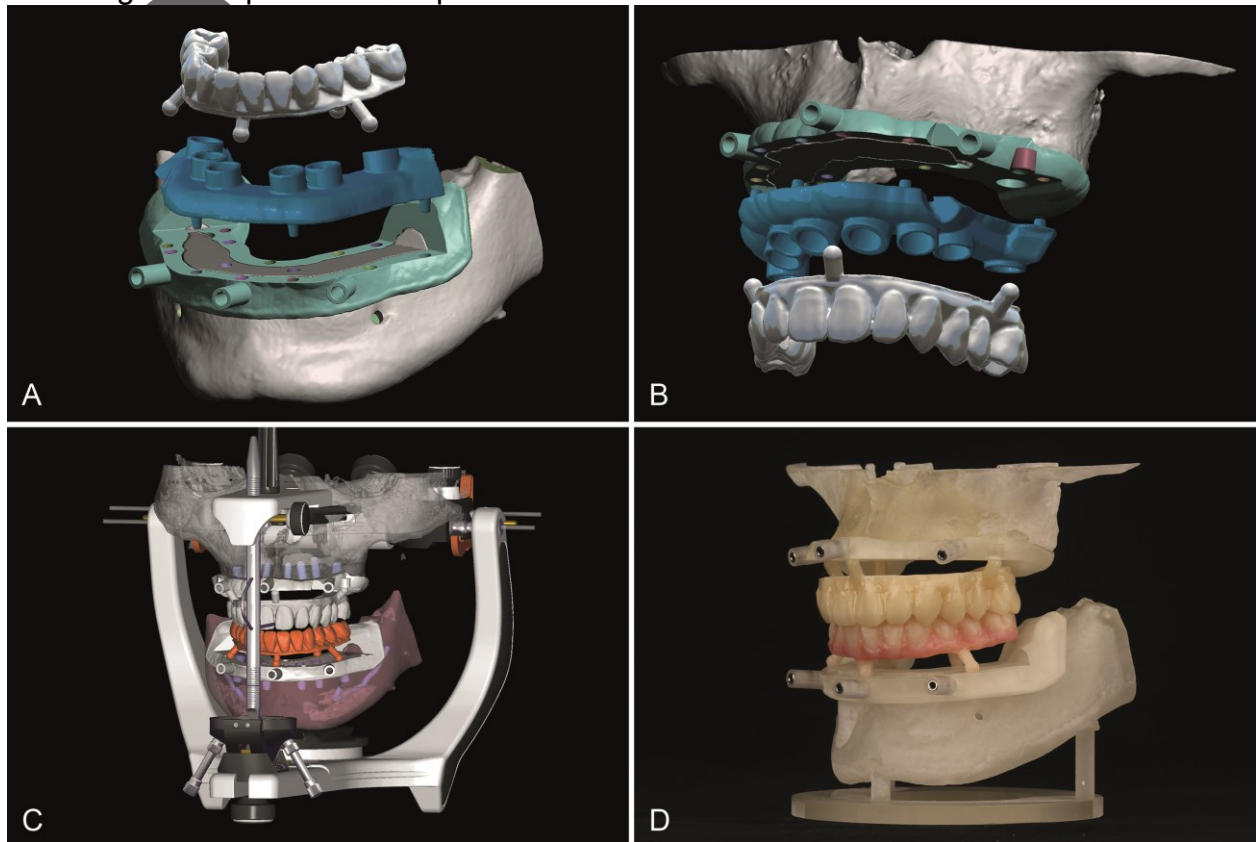


Figure 6 Immediate guided implant surgery and intraoral conversion of interim prosthesis

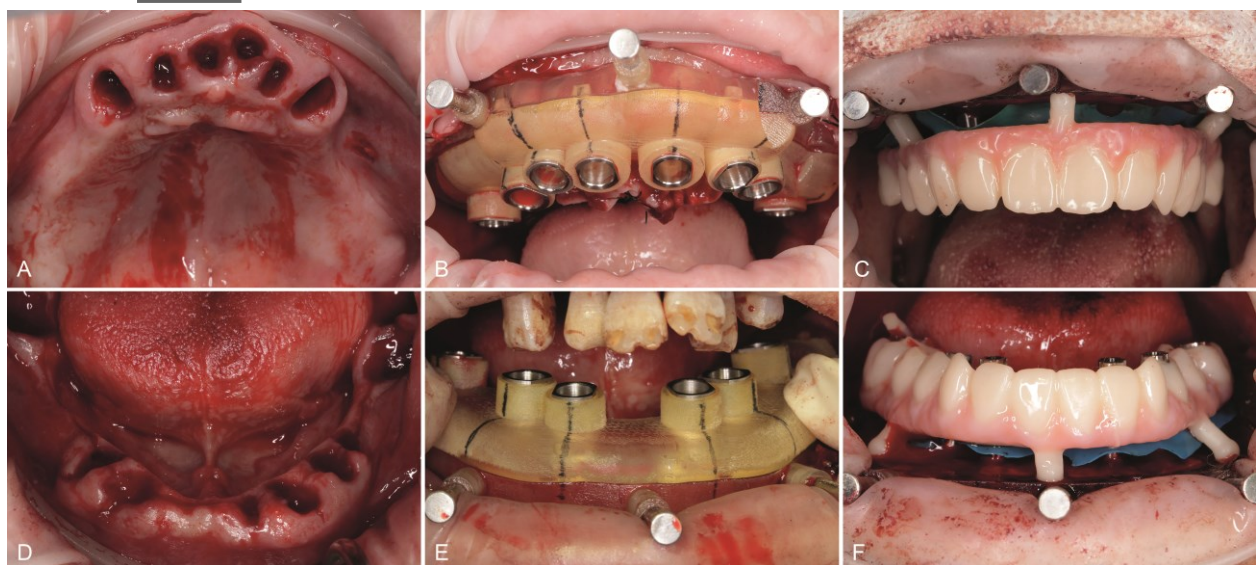


Figure 7 A, Delivered full-mouth interim prostheses. B, Smile presentation of interim prostheses. C, Intraoral view of definitive implant-supported fixed complete prostheses. D, Smile presentation of definitive prostheses.

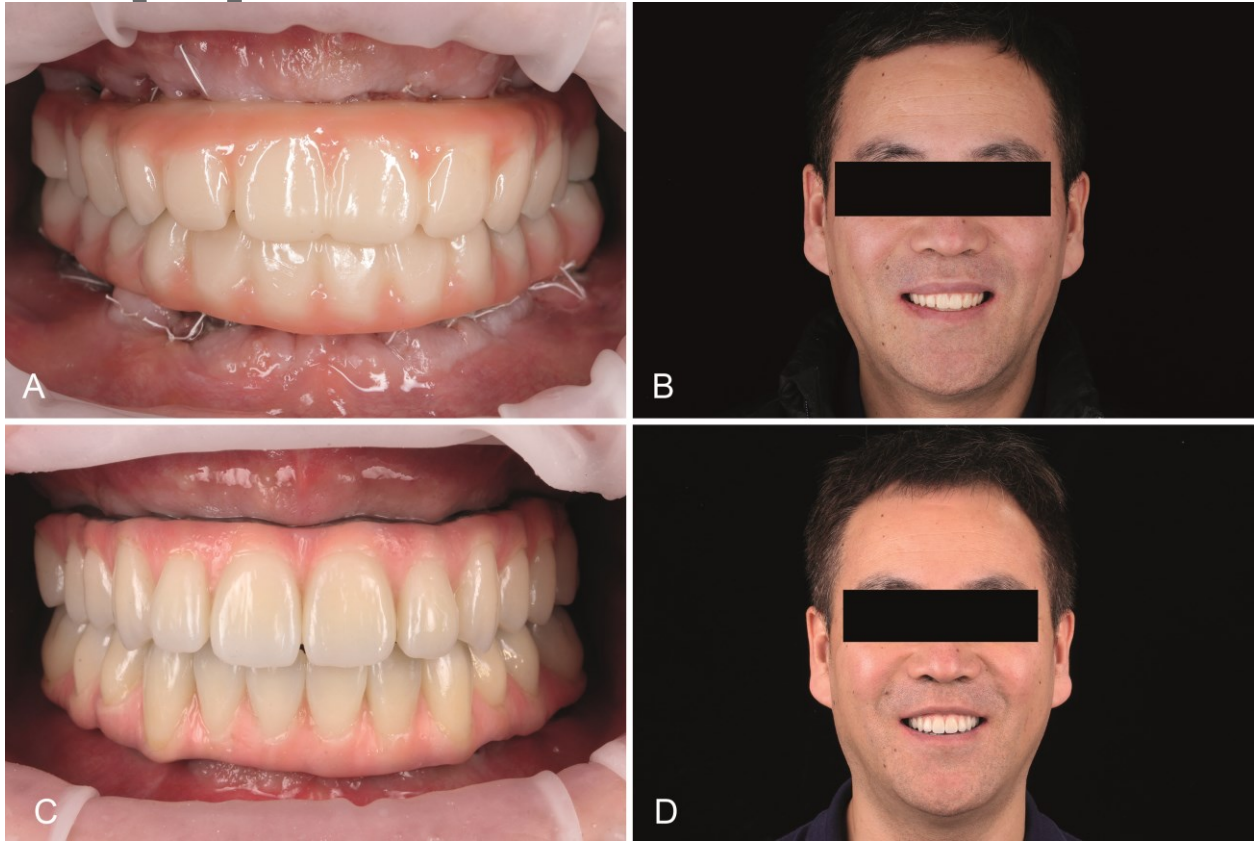


Figure 8 Panoramic radiograph after definitive restoration delivery

