

Management of Eosinophilic Esophagitis: Dietary and Nondietary Approaches

Nutrition in Clinical Practice
Volume 35 Number 5
October 2020 835–847
© 2020 American Society for
Parenteral and Enteral Nutrition
DOI: 10.1002/ncp.10571
wileyonlinelibrary.com

WILEY

Joan W. Chen, MD, MS 

Abstract

Eosinophilic esophagitis (EoE) is an allergen-driven chronic inflammatory condition, characterized by symptoms related to esophageal dysfunction and confirmed histologically by esophageal mucosal eosinophilia. Since its first description in the 1990s, the incidence and prevalence of EoE have been on the rise. It is known to affect all ages of various ethnic backgrounds and both sexes; however, it is most seen in White males. Children with EoE often present with abdominal pain, nausea, vomiting, and failure to thrive, whereas adults with EoE typically present with dysphagia and food impaction. Diagnosis of EoE requires histologic confirmation of elevated esophageal eosinophils in a symptomatic patient, and only after secondary causes have been excluded. Because EoE is a chronic and progressively fibrostenotic disease, treatment goals include resolution of symptoms, induction and maintenance of disease remission, and prevention and possibly reversal of fibrostenotic complications, while minimizing treatment-related adverse effects and improving quality of life. Treatment strategies include the “3 D’s”—drugs, diet, and dilation. Standard drug therapies include proton-pump inhibitors and topical corticosteroids. Dietary therapies include elemental diet, allergy testing–directed elimination diet, and empiric elimination diets. Endoscopic esophageal dilation for EoE strictures can alleviate esophageal symptoms but has no effect on mucosal inflammation. Recent progress in EoE research has made possible evidence-based clinical guidelines. Ongoing pharmacologic trials show promise for novel biologic agents in the treatment of refractory EoE. (*Nutr Clin Pract.* 2020;35:835–847)

Keywords

allergy; dietary elimination; elemental diet; eosinophilic esophagitis; esophageal dilation; nutrition assessment; nutrition support; proton pump inhibitor; topical corticosteroid

Introduction

Eosinophilic esophagitis (EoE) is a chronic inflammatory condition of the esophagus that has been increasingly recognized as a major cause of digestive symptoms in children and adults.¹ Since it was initially described in cases series by Attwood² and Straumann³ in 1993 and 1994, EoE has evolved into a widely recognized cause of esophageal morbidity, commonly encountered in the gastrointestinal (GI) clinic, hospital emergency rooms, and endoscopy suites.^{4,5} The key role of food allergens as the main antigenic trigger in EoE was demonstrated in a landmark study in 1995 in which a pediatric cohort with GI symptoms and histologic features of esophageal eosinophilia showed symptomatic and histologic resolution after a 6-week course of an amino acid–based formula.⁶ The differences in clinical presentation between children and adults with EoE are thought to be related to the progressive remodeling of the esophageal wall that occurs over the course of the disease. Although EoE has not been associated with increased mortality or malignancy risks, it has been shown to negatively impact patients’ quality of life (QOL).⁷ In 2007, the first EoE management guideline on the diagno-

sis and therapy of EoE was published by an international expert panel.⁸ Since that time, research effort in EoE has accelerated in both disease pathogenesis and management outcomes. A clinical guideline by the American College of Gastroenterology (ACG) was published in 2013,⁷ and an updated International Consensus Diagnostic criteria for EoE was released in 2018.⁸ In 2020, the American Gastroenterological Association (AGA) and the Joint Task Force (JTF) on Allergy-Immunology Practice Parameters issued clinical guidelines focusing on evidence-based recommendations on management of EoE.⁹ However, many areas of controversies and management dilemma still exist.

From the Division of Gastroenterology and Hepatology, Department of Internal Medicine, University of Michigan, Ann Arbor, Michigan, USA.

Financial disclosure: None declared.

Conflicts of interest: None declared.

This article originally appeared online on August 21, 2020.

Corresponding Author:

Joan W. Chen, MD, MS, 3912 Taubman Center, 1500 E. Medical Center Drive, SPC 5362, Ann Arbor, MI 48109-5362, USA.
Email: chenjoan@med.umich.edu

In this Review, we summarize the known epidemiologic pattern, pathogenesis, natural history, clinical presentation, diagnosis, and management strategies for EoE. We briefly discuss promising novel pharmacologic agents currently under investigation, and we propose future research directions.

Incidence/Prevalence

According to a population-based study to assess the epidemiology of EoE in Olmsted County, MN, over 3 decades, the incidence of EoE increased from 0.35 to 9.5 cases per 100,000 person-years over a 15-year period.⁵ This drastic increase in incidence and prevalence of EoE has been seen across the US^{1,5,10–12} and internationally.^{4,13,14} The reasons for this increase are poorly understood and are likely not solely attributed to increased recognition and surveillance.^{4,5} Studies examining changes in rates of endoscopic biopsy have found that the increase in EoE incidence outpaces the relatively modest increase in rates of biopsy.

Using population-based data, incidence estimates range from 5 to 10 cases per 100,000 and prevalence estimates range from 0.5 to 1 case per 1000.^{13–15} However, studies report higher prevalence among patients presenting with dysphagia, ranging from 12% to 23%, in patients undergoing endoscopy for dysphagia, and even higher (50% or above) in patients presenting with an esophageal food bolus impaction.^{16–18} Males are more commonly affected than females by 3–4 times, and it is more commonly seen in White patients compared with other ethnic groups.^{19–21} Patients with EoE are also more likely to be younger and have coexisting atopic conditions.²²

Pathogenesis

Understanding the pathophysiology of a disease is crucial for the development of treatment. Unfortunately, our current understanding of the pathogenesis of EoE remains incomplete. It is generally accepted that EoE results from a complex interplay between genetic predisposition, environmental, and host immune factors, and an allergen-mediated inflammatory process is a key mechanism in EoE pathogenesis. Fifty percent to 80% of EoE patients have concurrent allergic conditions such as atopic dermatitis or asthma,^{12,20,23–27} however, unlike the other common immune-mediated conditions, EoE does not appear to follow a classic immunoglobulin E (IgE)-mediated immune response. Rather, the pathogenesis of EoE involves a T-helper 2 lymphocyte (T_H2) inflammatory process, triggered most commonly by food allergens.^{28–30} This leads to a production of a combination of cytokines and chemokines, including interleukin (IL)-5, IL-4, and IL-13; thymic stromal lymphopoietin; CCL26/eotaxin-3; and transforming growth factor- β 1 (TGF- β 1).³¹ These cytokines promote T-cell differentiation and recruitment and activation of

eosinophils. The protein eotaxin-3 is strongly expressed by the esophageal epithelium and recruits eosinophils from the peripheral blood into the tissue. The production of TGF- β influences remodeling with subsequent fibrosis in the lamina propria.³² Figure 1 depicts the proposed pathogenesis of EoE.

Clinical Presentation

The diagnosis of EoE requires the presence of foregut symptoms; however, clinical presentation can vary and are often different between adults and children.^{24–27,33–36} Whereas common presenting symptoms in children include abdominal pain, nausea/vomiting, and failure to thrive, adults with EoE typically present with dysphagia, food impaction, chest pain, or reflux complaints.^{19,33,37} The difference in clinical presentation may be related to esophageal fibrostenotic remodeling over time due to chronic unabated inflammation in untreated EoE.^{38–41} An inflammatory phenotype, seen more commonly in children, demonstrates endoscopic esophageal mucosal features of edema, exudates, and linear furrows. A fibrostenotic phenotype, more commonly seen in adults, demonstrates endoscopic features of rings, strictures, and small-caliber esophagus.^{38,42,43}

Natural History

As EoE remains a young disease, the natural history of EoE has not been well described. Although long-term data are lacking, some intermediate-term data are available. In a study by Straumann et al, 30 adult patients with EoE were followed for up to a mean of 7.2 years in the absence of medical therapy.¹⁹ Dysphagia and esophageal eosinophilia persisted in nearly all patients. Importantly, subepithelial fibrosis increased on follow-up in 86% of the patients, highlighting the process of esophageal remodeling. No patient developed generalized eosinophilia or eosinophilic infiltration outside of the esophagus or esophageal neoplasm. The progression of fibrostenosis in EoE was also demonstrated by studies that show increasing prevalence of esophageal strictures with longer durations of untreated disease.⁴³ On the other hand, patients with prominent endoscopic inflammatory features were significantly younger than those with fibrostenotic features. In an analysis by Dellon et al, the risk of developing a fibrostenotic phenotype doubled for every decade of life, and odds of developing a stricture increased 5% for each year of symptoms before diagnosis.³⁸ The natural history of untreated EoE is characterized by not only morphologic alternations and subepithelial fibrosis but also functional abnormalities of esophageal motility.⁴⁴ These chronic progressive changes represent a key risk factor for food impactions and strengthens the argument for therapies to reduce mucosal inflammation even in early, uncomplicated disease.

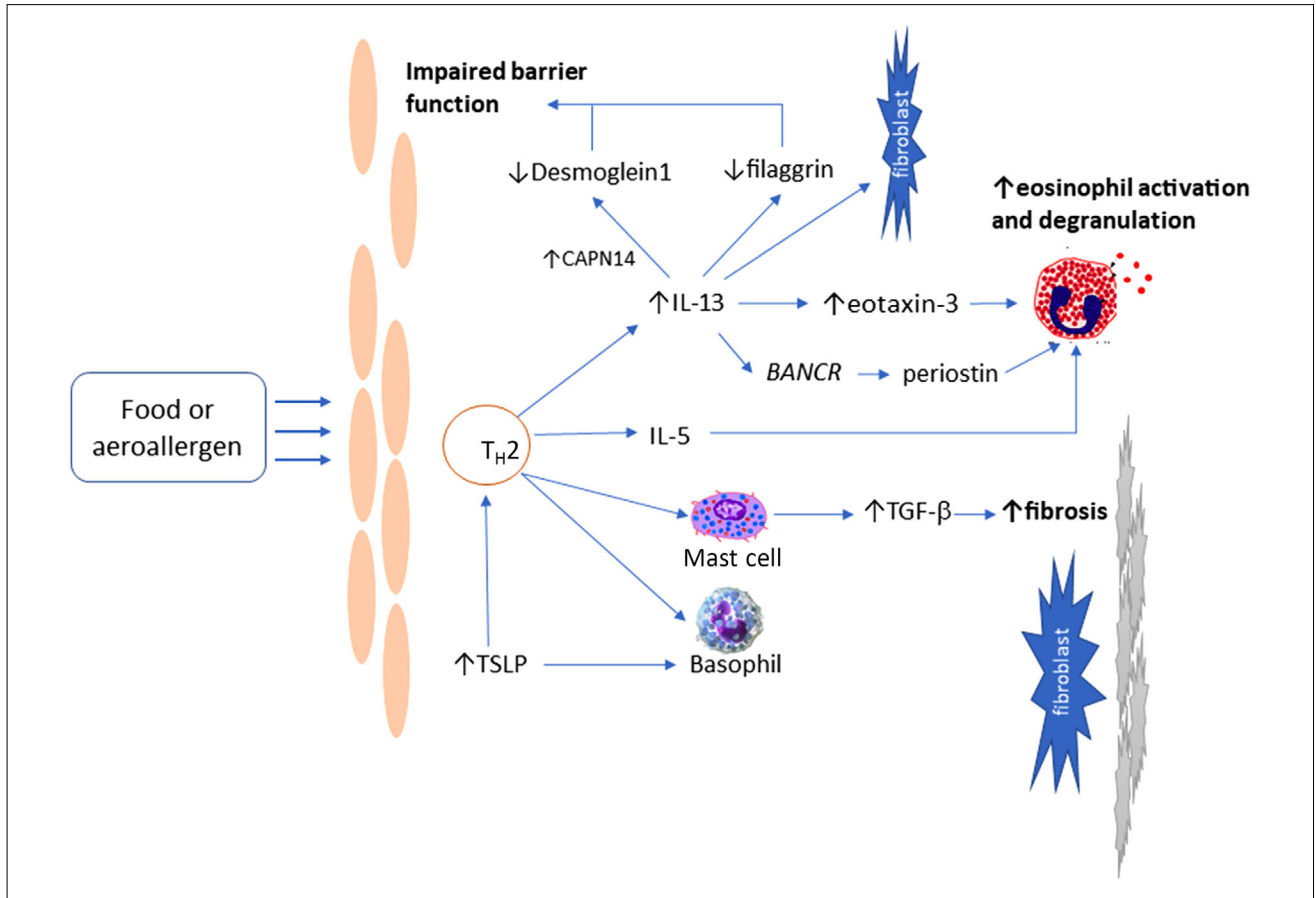


Figure 1. A summary of the pathogenesis of eosinophilic esophagitis. Food or aeroallergens trigger a T-helper 2 lymphocyte (T_H2) cell inflammatory cascade that involves secretion of interleukin (IL)-4, IL-5, and IL-13. IL-4 and IL-13 are responsible for secretion of eotaxin-3 and upregulation of periostin epithelial cells and fibroblasts. IL-13 has multiple effects including disruption of the epithelial barrier via actions on calpain 14 (CAPN14), desmoglein, and filaggrin. IL-5 is a key cytokine involved in eosinophil recruitment into the esophagus and effect on mast cells. Thymic stromal lymphopoietin (TSLP) induced by T_H2 response results in basophil mobilization into the esophageal tissue. Transforming growth factor- β (TGF- β) influences remodeling with subsequent fibrosis in the lamina propria. \uparrow , increased.

Diagnosis and Monitoring of Disease Activity

Diagnosis

Besides clinical symptoms, histologic confirmation of esophageal eosinophilia and exclusion of secondary causes are required for diagnosis. Histologic confirmation of EoE requires endoscopic biopsies showing maximum subepithelial eosinophilia ≥ 15 eosinophils per high-power field (eos/hpf).⁸ A list of alternative primary and secondary causes of esophageal eosinophilia is included in Table 1. Differentiating gastroesophageal reflux disease (GERD) from EoE can be challenging because of a similarity in symptoms and esophageal eosinophilic inflammation. And although esophageal eosinophilia involving only the distal esophagus is often associated with distal acid exposure in GERD, this pattern of esophageal eosinophilia can also

be seen in EoE. Endoscopic findings—absence of reflux complications such as reflux esophagitis, peptic stricture, or Barrett’s esophagus, and presence of EoE features—as well as response following a trial of proton-pump inhibitors (PPIs) can be used to differentiate the 2 disease entities. In more difficult cases, confirmation can be achieved using ambulatory reflux monitoring or the novel mucosal impedance testing.⁴⁵

Response to PPI as a Diagnostic Criterion

At least one-third of patients with esophageal eosinophilia achieve histologic remission on PPI alone.⁴⁶⁻⁵³ However, PPI responsiveness is not predictable by pH monitoring, revealing an alternative therapeutic mechanism of PPI apart from acid suppression.⁵⁰ The significance of the PPI-responsive

Table 1. Alternative Causes of Esophageal Eosinophilia.

Primary causes
Eosinophilic gastritis, gastroenteritis, colitis, with esophageal involvement
Hypereosinophilic syndrome with gastrointestinal involvement
Secondary causes
Gastroesophageal reflux disease
Pill esophagitis
Esophageal dysmotility syndromes
Infections
Celiac disease
Drug hypersensitivity reactions
Inflammatory bowel disease
Connective tissue disease
Pemphigus
Vasculitis
Graft-vs-host disease
Hypermobility syndromes

population was uncertain, and the term PPI-responsive esophageal eosinophilia (PPI-REE) was coined. Until the 2018 international consensus statement, a 2-month trial of twice-daily PPI therapy to rule out PPI-REE was required before a diagnosis of EoE could be made.^{1,51} However, the use of PPIs as a diagnostic strategy in EoE remained controversial.

Several recent studies have suggested that PPI-REE and EoE share similar immunohistochemistry, tissue molecular markers, and genetic alterations. In addition, patients with PPI-REE responded to dietary and topical corticosteroid treatments similarly to EoE patients in small series.⁵⁴⁻⁵⁷ The diagnosis of PPI-REE was thus abolished in the updated international consensus diagnostic criteria, and the requirement of a PPI trial was removed from the diagnostic algorithm, reflecting the finding that PPI-REE likely shares the same pathogenic inflammatory mechanism as EoE.⁸

Monitor of Disease Activity and Treatment End Points

Potential markers for assessing EoE disease activity and treatment response include clinical symptoms, endoscopic features, and histologic eosinophilic inflammation. Considerable variability is seen in the literature in reported therapeutic end points, and this inconsistency limits the interpretability and comparability of EoE therapeutic trials.⁵⁸ Most commonly, studies have relied on histology to assess therapeutic response because of the ease and consistency in assessing esophageal eosinophilia. Recent trials, with the help of newly available patient-reported outcome (PRO) and QOL questionnaires, as well as a standardized endoscopic scoring system, have also begun reporting changes in symptom and endoscopic severity. For the purpose of the

pooled analysis and comparison between clinical trials, the AGA/JTF clinical guidelines have based their recommendation on using the histologic cutoff of 15 eos/hpf to define treatment effect.⁹

Patients with EoE often have difficulties objectively reporting their symptoms. Because of chronic progressive symptoms, patients often develop adaptive behaviors such as slow eating, excessive chewing or drinking, and avoidance of specific foods, to prevent food impaction. To help standardize patient symptom reporting, PROs for EoE have recently been developed, including the EoE Activity Index (EEsAI) and Dysphagia Symptom Questionnaire.⁵⁹ The EEsAI includes a 7-day recall of 7 PRO items that takes into account these adaptive behaviors.⁶⁰ A disease-specific QOL survey, the EoE-QOL-A, was also recently developed and validated in adult EoE patients.⁶¹ These symptom assessment tools and QOL surveys may complement parameters of biologic activity in the assessment of overall EoE disease burden.

Endoscopic findings, including edema, rings, white exudates, linear furrows, and strictures, are seen in over 90% of patients with EoE.⁶² However, until recently, there was no standardization in endoscopic description of these features. A classification and grading system to describe endoscopic findings in EoE including numeric grading in severity of edema, rings, exudates, furrows, and strictures—the Endoscopic Reference Score (EREFS)—was published in 2013 to help standardize endoscopic assessment (Figure 2).⁶³ The EREFS system has since been used in recent prospective trials. Nevertheless, histologic examination remain indispensable for the assessment of EoE disease activity.⁶⁴

Treatment: The 3 D's—Drugs, Diet, and Dilation

Drugs

Proton-pump inhibitors. As PPI trials are no longer required prior to making a diagnosis of EoE, PPIs are now considered an effective primary treatment option. Based on 23 observational studies reporting 42% histopathologic response rate, compared with 13% of placebo (relative risk [RR], 0.66; 95% CI, 0.61–0.72), the AGA/JTF clinical guidelines have recommended PPI over no treatment for certain patients with EoE.⁹ This recommendation is conditional because of the very low-quality of evidence from a number of small studies using retrospective study designs with variable PPI dosing. Based on the available data, an “adequate” PPI trial to induce remission of severe EoE includes a twice-daily dosing (1 mg/kg in children) schedule for at least 8 weeks.

The therapeutic mechanism of PPI in EoE remain poorly understood; however, it has been postulated that PPI may have anti-inflammatory properties, as demonstrated by *in vitro* and *in vivo* models.^{56,65} Another potential mechanism

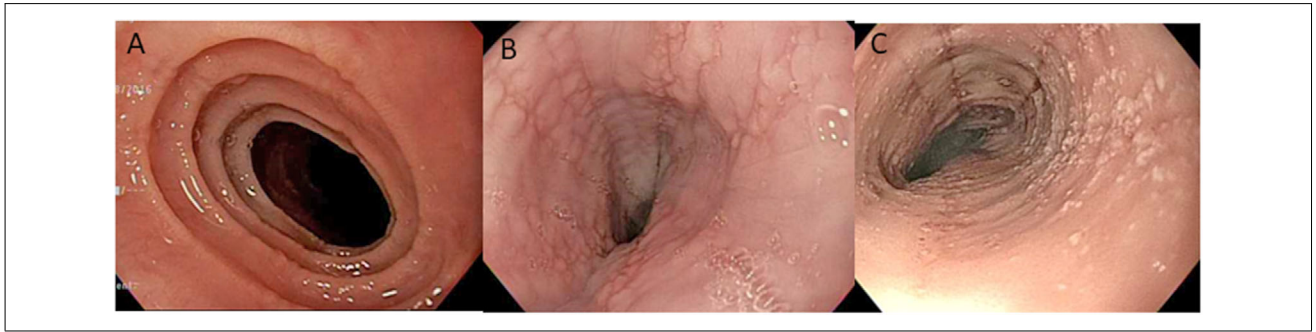


Figure 2. Examples of endoscopic features of eosinophilic esophagitis. Distinct mucosal rings are seen in (A). Longitudinal furrows are present along the length of the esophagus in (B). Diffuse white exudates/plaques can be seen intraluminally in (C). Edema, evident by the loss of vascular markings on the esophageal wall, is seen in all 3 panels. A color version of the figure can be accessed online: <https://onlinelibrary.wiley.com/doi/10.1002/ncp.10571>

involves restoration of esophageal mucosal integrity and improvement of barrier function, thereby reducing allergen influx through the mucosa.⁶⁶ Yet another potential mechanism involves blockage of T_H2 cytokine-stimulated esophageal secretion of eotaxin-3.^{67,68}

Topical Corticosteroids. Corticosteroids, delivered as a topical preparation to the esophagus, has been shown to be an effective form of treatment for EoE. Swallowed corticosteroids provide an anti-inflammatory effect by downregulating the T_H2 response and improve esophageal mucosal integrity.⁶⁹ The 2 most widely used corticosteroids are budesonide and fluticasone propionate formulations that are designed for the treatment of asthma. Earlier trials using liquid budesonide have mixed the aqueous budesonide with artificial sweetener (sucralose) to create a viscous “slurry,” which coats the esophagus when swallowed. Recently, formulations of budesonide specifically designed for EoE, including effervescent or orodispersible tablets and oral suspension, have also been investigated. Fluticasone propionate is delivered through an inhaler (without spacer), and instead of inhaling the medication, patients are instructed to swallow the aerosol. The efficacies of topical corticosteroids have been shown in reducing clinical symptoms as well as improving endoscopic findings and esophageal eosinophilia in multiple randomized trials and meta-analysis. Summary estimates by the AGA/JTF including 8 double-blind placebo-controlled randomized controlled trials indicate that 35.1% of patients treated with glucocorticosteroids failed to achieve histologic remission, compared with 86.7% of patients treated with placebo (RR, 0.39; 95% CI, 0.26–0.58), leading to their recommendation of topical glucocorticosteroids use over no treatment in EoE.⁹ However, no medications have been approved at this time for the specific treatment of EoE by the US Food and Drug Administration, although a budesonide tablet formulation for EoE has been approved by the European Medications Agency in 2018.

Overall, swallowed corticosteroids appear safe. By delivering corticosteroids topically, systemic side effects are generally avoided because of limited absorption and a high rate of first-pass metabolism by the liver. Esophageal candidiasis can occur in 5%–30% of patients receiving treatment; however, this is typically an incidental finding during endoscopy, as most patients are asymptomatic.⁷⁰ Another potential side effect of adrenal suppression due to chronic corticosteroid use is inconsistent in the literature.^{71,72} There are no reports of deleterious effects on linear growth or bone mineral density in the pediatric population; however, long-term data are still needed.

Emerging pharmacologic therapies. Although most patients will respond with clinical, endoscopic, and histologic improvement to PPIs, topical corticosteroids, or dietary therapy, a subset of patients will be refractory to standard therapy. Antiallergic medications have been explored, including a leukotriene receptor antagonist (montelukast), mast cell stabilizer (cromolyn sodium), and antihistamine, which have shown limited benefits.^{73,74} An antagonist to CRTH2 (chemoattractant receptor homologous molecule expressed on Th-2 cells) demonstrated only modest histologic and symptomatic improvement in refractory EoE adults.⁷⁵ Immunosuppressive medications azathioprine and 6-mercaptopurine have been shown to be effective in case series involving steroid-dependent EoE;⁷⁶ however, potential side effects have rendered these medications experimental therapies and are not currently recommended for EoE.

Biologic therapies. A variety of biologic therapies, offering novel targeted therapies for EoE, have been investigated, several of which are current late-phase clinical trials. These include monoclonal antibodies targeting IL-13, IL-4, and the α subunit of the IL-5 receptor (IL5R α) and Siglec-8 blockers.

Past trials have investigated the use of an anti-IgE, omalizumab, in EoE^{77,78} that did not show clinical or

histologic disease remission with the medication, likely because EoE is not a primarily IgE-mediated disease. Antibodies against IL-5, including mepolizumab and reslizumab, have been shown to reduce esophageal eosinophilia but did not lead to histologic remission nor clinical improvement.⁷⁹⁻⁸³ QAX576, an anti-IL-13 monoclonal antibody, was used in a randomized, placebo-controlled trial that showed no histologic remission. However, a recent randomized controlled trial using RPC4046, an IL-13R α 1 and IL-13R α 2 blocker, and placebo showed that RPC4046 significantly reduced esophageal mean eosinophil count and improved endoscopic severity.⁸⁴

Dupilumab, a monoclonal antibody directed against the IL-4R α subunit, which simultaneously blocks the signaling pathways of IL-4 and IL-13, is currently in a phase 3 trial assessing efficacy against EoE. In the phase 2, double-blind, placebo-controlled trial, nearly 83% of patients treated with dupilumab achieved reductions in peak eosinophil counts below 15 eos/hpf. There was also improvement in endoscopic and histologic activity scores.⁸⁵

Siglec-8, found on the membrane of human eosinophils and other immune cells, play an important role in cell signaling and immune system regulation. Anti-Siglec-8 monoclonal antibody, antolimab (AK002), was recently used in the ENIGMA trial—a randomized, phase 2, placebo-controlled study—to assess the efficacy of the medication in adult patients with eosinophilic gastritis and gastroenteritis that showed an overall 95% mean reduction of tissue eosinophilia, and overall 69% of treated patients experiencing clinic-histological response, compared with 5% of placebo patients.⁸⁶ The efficacy and safety of AK002 in EoE is currently being investigated in a multicenter trial.

Diet

The concept of food allergens as the main trigger of eosinophilic inflammation and the efficacy of dietary avoidance for treatment of EoE was demonstrated by Kelly et al in 1995 when 10 children with EoE achieved normalization of the esophageal histology and clinical remission after 6 weeks of an amino acid–based elemental diet.⁶ Numerous studies have since replicated the finding of food triggers for EoE in adult and pediatric population, and dietary avoidance therapy has been accepted as a first-line treatment for EoE. Dietary treatment strategies, including targeted (allergy testing–directed elimination diet), empiric elimination diets, or elemental diets, are often preferred because of their high efficacy, relative low cost, and safety profile.

Elemental Diet

Using an amino acid–based formula devoid of protein, elemental diet has demonstrated excellent efficacy in inducing clinical and histologic improvement in EoE.^{87,88} Overall, the effectiveness of an elemental diet in EoE is

~ 90% in both pediatrics and adults in a recent meta-analysis.⁸⁹ However, there are many practical limitations with elemental diet, including its poor palatability, high cost, and its negative impact on QOL, as well as the overall length of the food reintroduction period. The AGA/JTF thus recommends clinicians to consider patient age and preferences for alternative medical and dietary management options when considering elemental diets.⁹

Allergy Testing–Directed Elimination Diet

Ideally, a noninvasive, rapid food allergy test that can accurately predict food triggers in EoE would obviate the need for long-term medication and the laborious and lengthy process during food reintroduction. However, the inconsistency and overall futility of the available in-office food allergy tests, including skin-prick test (SPT), atopy patch test (APT), and serum antigen-specific IgE testing, in identifying EoE food triggers have been demonstrated in several studies. Spergel et al reported positive predictive values (PPVs) and negative predictive values (NPVs) for SPT, APT, and combined SPT/APT in patients with EoE.⁹⁰ The PPVs for SPT varied among food types, with an average of 47%, whereas NPVs were >90% for most foods tested except milk (30%). APT alone also showed variable PPV with average of 44% and NPV of 90% for most foods except milk (31%). Combining SPT and APT increased the NPVs to 93% for all foods except for wheat (88%) and milk (44%). This early study demonstrated potential usefulness of a negative, but not positive, allergy test. Philpott et al reported only 1 in an EoE cohort of 20 that had food triggers correctly identified by SPT,⁹¹ and Gonsalves et al similarly demonstrated that SPT performed poorly with a PPV of 13% for identification of EoE food triggers.⁹² Lucendo et al showed that positive SPT showed poor concordance with confirmed food triggers, and patients with positive or negative SPT for a given food are equally likely to relapse on subsequent food reintroduction.⁹³ The inadequacy of allergy testing–directed elimination diet is most likely attributable to the delayed-type, non–IgE-mediated hypersensitivity reaction, localized in the esophagus in EoE.

Combining the results of 12 single-arm studies, the efficacy of allergy testing–based targeted elimination diet failed to achieve histopathologic remission in ~50% (49.2%) of patients, suggesting that current allergic testing methods are not reliable tools to guide dietary intervention in EoE. As such, the AGA/JTF suggest EoE patients consider medical therapy or an alternative dietary therapy due to the limited accuracy of available allergy-based testing for the identification of EoE food triggers.⁹

Empiric Elimination Diets

With the practical limitations of elemental diet and unreliability of allergy testing–directed elimination diet, an empiric

food-elimination diet (FED) was tested in pediatric EoE patients in 2006.⁹⁴ The 6-FED consists of the elimination of the top 6 food allergens, including cow's milk, wheat, eggs, soy, peanuts/tree nuts, and fish/shellfish, with subsequent sequential reintroduction and monitor of histologic response. The 6-FED led to both clinical and histologic remission in 74% of children.⁸⁹ 6-FED appears to be effective in all ages with EoE. A meta-analysis showed a pooled histologic remission rate of 72% (95% CI, 66%–78%) in both children and adults with EoE.⁸⁹ The AGA/JTF, using 10 single-arm observational studies that reported the effectiveness of an empiric 6-FED, reported an overall, unweighted histologic response rate of 68%, with an RR for failure to achieve histologic remission relative to placebo of 0.38 (95% CI, 0.32–0.43).⁹

The level of dietary restriction in 6-FED is likely unnecessary in most EoE patients, as only 1 or 2 food triggers are typically identified, and a less restrictive 4-FED has been proposed.⁹⁵ Pooled data from 3 single-arm studies suggested that 43.1% of patients on a 4-FED failed to achieve histopathologic remission compared with 86.7% of a placebo comparison group (RR, 0.46; 95% CI, 0.42–0.57). Similarly, few observational studies have reported modest efficacy of 2-FED or single-FED. However, the quality of evidence is very low owing to noncomparative single-arm study designs and low information size.^{96–99}

A step-up approach with upfront elimination of only the top 1 or 2 foods (milk and wheat), followed by top 4 and then top 6 in nonresponders, was recently proposed.^{98,100} A 2-FED achieved remission in 43% of patients, whereas remission rates increased to previously known rates with subsequent step-up elimination in nonresponders (60% in 4-FED and 79% in 6-FED). Overall, 92% of the responders to 2- or 4-FED had 1 or 2 food triggers, demonstrating that broader elimination practice with 6-FED is likely unnecessary. Compared with the standard 6-FED, this step-up strategy allowed a reduction of procedural and diagnostic time by 20% and reduced unnecessary dietary restriction.

Barriers to Dietary Therapy and Long-Term Elimination Diet

The success of dietary therapy relies on the patient's engagement in the process, motivation to adhere to the diet, understanding of how to avoid specific food groups, and the financial means to remain on a specialized diet. This often requires a multidisciplinary treatment approach, with the collaboration of an experienced gastroenterologist and registered dietitian or nutritionist. Patient education is required for label reading, avoidance of cross-contamination, and nutrition planning.

The issue of cross-contamination is currently an area of controversy. For example, the definition of wheat avoidance in many European trials included the elimination of wheat,

barley, and rye, whereas in most US centers, trials included elimination of only wheat. Cross-reactivity to barley and rye can occur in food allergy to wheat, but it is unclear whether this cross-reactivity is clinically relevant in EoE. Additionally, the amount of contaminated allergen needed to induce EoE remains unknown and may be individualized. Future studies are needed to address the issue of cross-reactivity/contamination in EoE.

Once the food trigger(s) for EoE is identified, long-term avoidance is recommended to maintain drug-free EoE remission. A maintenance avoidance diet has been shown to be effective in keeping patients in clinical and histologic remission for a period of at least 3 years,^{92,93,101} and rechallenging patients after effective avoidance for up to 4 years showed recurrence of EoE in most cases.¹⁰¹

Despite the recommendation, there are challenges and barriers to long-term elimination diet, and patient long-term adherence has been found to be modest. A recent study found a 57% compliance rate with maintenance diet in EoE patients who have successfully completed the 6-FED to identify food triggers. Incomplete symptom relief on maintenance diet, social challenges, and diet-related anxiety were cited as factors influencing adherence to the diet.¹⁰²

Although eliminating the long-term need for pharmacologic therapy, chronic dietary therapy in EoE is not without potential adverse effects. Some of the side effects include potential nutrition deficiency, decreased QOL, psychological impact of a limited diet, risk of development of eating disorders, and increased cost and complexity of food sourcing. Patients may therefore benefit from periodic referral to a dietitian well-versed in management of EoE diet to maximize food options and avoid nutrition imbalances. Children and adolescents should be monitored closely to ensure they are meeting their growth parameters and that no abnormal feeding behaviors arise.

Dilation

Increased production of the cytokine TGF- β by eosinophils and mast cells results in recruitment of fibroblasts, promotion of epithelial-mesenchymal transition, and increased smooth muscle contractility—all of which contribute to esophageal wall remodeling in EoE.^{103–105} The ongoing fibrostenotic remodeling manifests endoscopically as strictures, rings, and narrow-caliber esophagus as previously described.^{19,106–110} Pharmacologic agents may play a minor role in reversing fibrosis; however, in most patients with advanced esophageal fibrostenosis resulting in frequent dysphagia or food impaction, dilation is key to providing symptomatic relief.

Early case series have described deep esophageal tear, severe pain, and perforation in EoE patients after esophageal dilation, resulting in consensus recommendation

Table 2. Pros and Cons of Treatment Options in Eosinophilic Esophagitis.

EoE treatment	Pros	Cons
Drugs:	Histological efficacy seen in at least one-third of treated	“Band-Aid” approach
Proton-pump inhibitors	Ease of therapy initiation Low cost No dietary restrictions Few endoscopies needed	Nuisance of taking a medication Long-term safety data available but controversial
Topical corticosteroids	Histological and clinical efficacy proven Ease of therapy initiation No dietary restrictions Few endoscopies needed	Cost of medication “Band-Aid” approach Nuisance of taking a medication Long-term medication safety unclear
Diet: Empiric elimination	Getting to the “source” (food trigger) of the issue Minimal side effects Low maintenance cost No need for long-term medication	Multiple endoscopies needed Impact on QOL Difficulty maintaining adequate nutrition
Dilation of esophageal strictures	Most effective strategy for treating fibrostenotic remodeling Sustained effect for symptom improvement Good safety profile in EoE	No effect on esophageal inflammation Chest discomfort frequent post procedure

EoE, eosinophilic esophagitis; QOL, quality of life.

that “whenever possible medical or dietary therapy for EoE should be attempted before performing esophageal dilation.”¹⁰ However, multiple recent large-scale studies have reported low rates of complication from esophageal dilation in EoE,¹¹¹⁻¹¹⁸ and esophageal dilation has since been included as a potential treatment in symptomatic patients in recent guidelines.¹ Review by the AGA/JTF reported symptomatic improvement in 87% of patients after esophageal dilation (but no change in esophageal eosinophil counts). No mortality associated with dilation was reported, and the pooled perforation rate was found to be 0.4%. Although the quality of evidence remains low because of the observational nature of studies and the lack of control groups, the AGA/JTF recommends endoscopic dilation in adults with dysphagia from a stricture associated with EoE as an acute and adjuvant rather than an isolated chronic management strategy.⁹

Medical vs Dietary Avoidance Therapy

As the literature supports use of medical or dietary therapy as first-line treatment in EoE, the choice of initial therapy is oftentimes dependent on individual patient situations and patient preferences. Table 2 lists the pros and cons of each therapeutic approach that can be useful for patient counseling during discussion of therapeutic options.

Management Algorithm

Because of the progress made in EoE-related research in the last 2 decades, evidence-based clinical guidelines are

available to assist in management of EoE. A proposed management algorithm, based on recent guidelines and expert consensus recommendations, is shown in Figure 3. The algorithm outlines the requirement of clinical symptoms and histologic esophageal eosinophilia, as well as exclusion of secondary causes of esophageal eosinophilia, prior to a diagnosis of EoE. Once an EoE diagnosis is made, standard first-line treatment options should be discussed and counseling regarding the benefits and risks of each therapy should be provided to the patient. The treatment plan may be individualized, and the choice of treatment should involve shared decision making. Esophageal dilation should be considered if suspicion for EoE-related esophageal stricture is high, although this should be done in conjunction with treatment for eosinophilic inflammation. In patients with persistent obstructive symptoms despite resolution of eosinophilia, esophageal dilation should be considered for treatment of subtle esophageal strictures. Finally, maintenance therapy should be suggested in patients demonstrating treatment response, and alternative therapy or experimental trials should be considered in those refractory to standard treatment. Because there are limited long-term treatment data available, patients with EoE should be offered regular clinical follow-up even after achieving clinical and histologic remission. There is currently no evidence to support routine endoscopic assessment in asymptomatic patients once they are in remission on a maintenance therapy; however, repeat endoscopic exam should be considered in the setting of symptom recurrence.

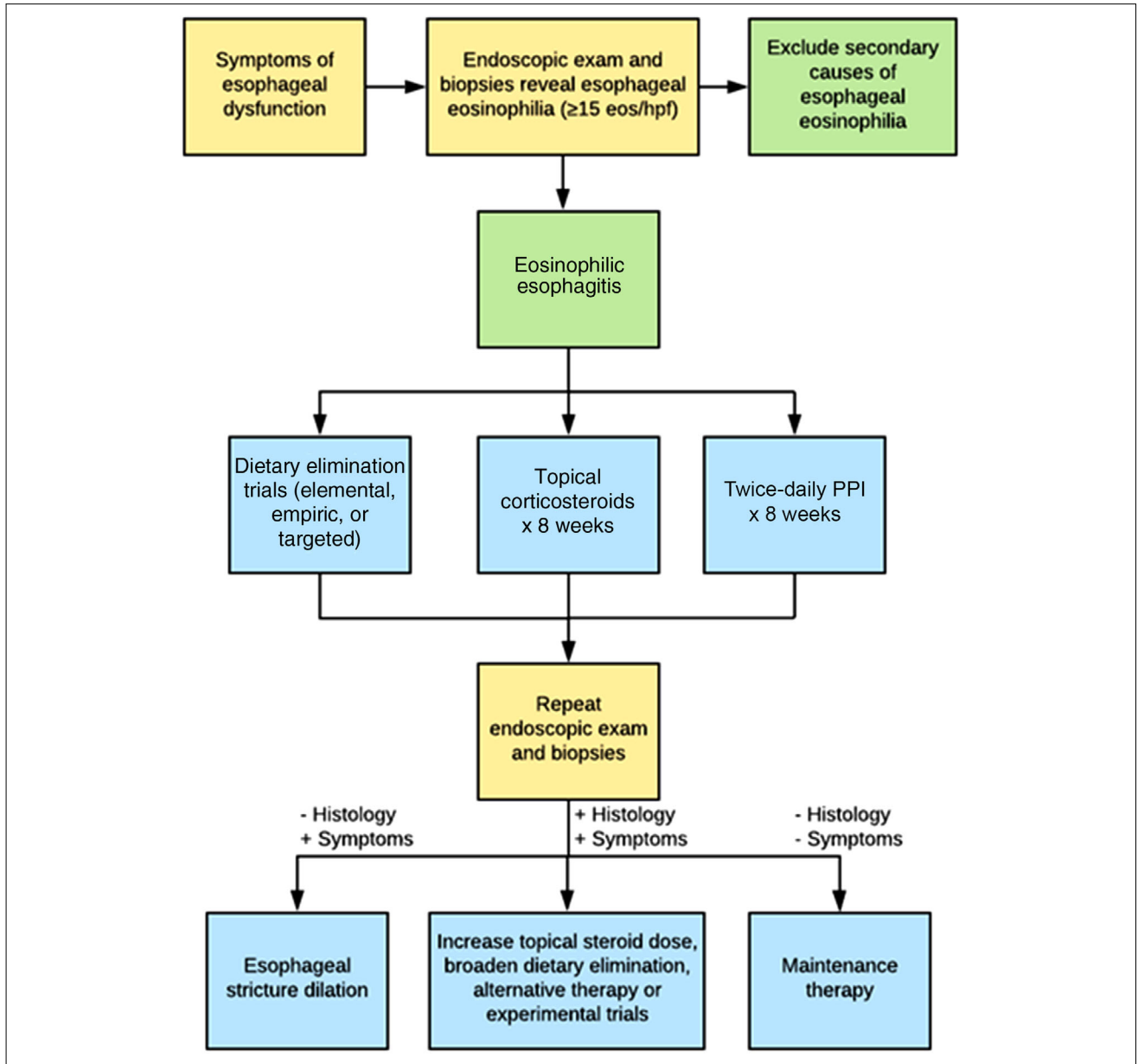


Figure 3. A proposed eosinophilic esophagitis management algorithm based on available guidelines and expert recommendations. -, absent; +, present; eos/hpf, eosinophils per high-power field; PPI, proton-pump inhibitor.

Conclusion

EoE is a recently defined disease entity that has transformed from a rare condition to an emerging cause of esophageal symptoms in children and adults. Since its initial description, there has been immense interest in the disease in both the research and clinical settings. It has been shown to be a T_H2 -predominant inflammatory process triggered most commonly by food allergens. Empiric dietary elimination with exclusion of the most common food triggers and subsequent serial reintroduction has been shown to be the

most feasible while effective dietary treatment approach; on the other hand, pharmacologic therapies using PPIs and/or topical corticosteroids have also been proven effective in reducing EoE inflammation. As no head-to-head comparison studies have been conducted to date, the decision on therapy should be shared between the practitioner and the patients after a thorough discussion of the pros and cons of each approach. Future research involving direct comparisons between treatment modalities is needed. Maintenance therapy in EoE after initial disease remission is generally recommended; however, long-term outcome data are

needed to identify the lowest effective medication dose and to confirm benefits of chronic avoidance diet. Future research should also explore combination therapy, which can potentially provide a tailored approach to maximize treatment benefits and avoid unwanted side effects. Several biologic agents have shown potential to improve clinical and histologic outcomes in early-phase clinical trials and offer promise as alternative or salvage therapy in EoE.

Statement of Authorship

J. W. Chen contributed to the conception and design of the research; J. W. Chen contributed to the acquisition and analysis of the data; J. W. Chen contributed to the interpretation of the data; and J. W. Chen drafted the article. All authors critically revised the article, agree to be fully accountable for ensuring the integrity and accuracy of the work, and read and approved the final article.

References

1. Liacouras CA, Furuta GT, Hirano I, et al. Eosinophilic esophagitis: updated consensus recommendations for children and adults. *J Allergy Clin Immunol*. 2011;128(1):3-20 e6; quiz 1-2.
2. Attwood SE, Smyrk TC, Demeester TR, Jones JB. Esophageal eosinophilia with dysphagia. A distinct clinicopathologic syndrome. *Dig Dis Sci*. 1993;38(1):109-116.
3. Straumann A, Spichtin HP, Bernoulli R, Loosli J, Vogtlin J. Idiopathic eosinophilic esophagitis: a frequently overlooked disease with typical clinical aspects and discrete endoscopic findings. *Schweiz Med Wochenschr*. 1994;124(33):1419-1429.
4. Hruz P, Straumann A, Bussmann C, et al. Escalating incidence of eosinophilic esophagitis: a 20-year prospective, population-based study in Olten County, Switzerland. *J Allergy Clin Immunol*. 2011;128(6):1349-1350.
5. Prasad GA, Alexander JA, Schleck CD, et al. Epidemiology of eosinophilic esophagitis over three decades in Olmsted County, Minnesota. *Clin Gastroenterol Hepatol*. 2009;7(10):1055-1061.
6. Kelly KJ, Lazenby AJ, Rowe PC, Yardley JH, Perman JA, Sampson HA. Eosinophilic esophagitis attributed to gastroesophageal reflux: improvement with an amino acid-based formula. *Gastroenterology*. 1995;109(5):1503-1512.
7. Safroneeva E, Coslovsky M, Kuehni CE, et al. Eosinophilic oesophagitis: relationship of quality of life with clinical, endoscopic and histological activity. *Aliment Pharmacol Ther*. 2015;42(8):1000-1010.
8. Dellon ES, Liacouras CA, Molina-Infante J, et al. Updated International consensus diagnostic criteria for eosinophilic esophagitis: proceedings of the agree conference. *Gastroenterology*. 2018;155(4):1022-1033 e10.
9. Hirano I, Chan ES, Rank MA, et al. AGA Institute and the joint task force on allergy-immunology practice parameters clinical guidelines for the management of eosinophilic esophagitis. *Gastroenterology*. 2020;158(6):1776-1786.
10. Furuta GT, Liacouras CA, Collins MH, et al. Eosinophilic esophagitis in children and adults: a systematic review and consensus recommendations for diagnosis and treatment. *Gastroenterology*. 2007;133(4):1342-1363.
11. Noel RJ, Putnam PE, Rothenberg ME. Eosinophilic esophagitis. *N Engl J Med*. 2004;351(9):940-941.
12. Straumann A, Simon HU. Eosinophilic esophagitis: escalating epidemiology? *J Allergy Clin Immunol*. 2005;115(2):418-419.
13. van Rhijn BD, Verheij J, Smout AJ, Bredenoord AJ. Rapidly increasing incidence of eosinophilic esophagitis in a large cohort. *Neurogastroenterol Motil*. 2013;25(1):47-52 e5.
14. Dellon ES, Erichsen R, Baron JA, et al. The increasing incidence and prevalence of eosinophilic oesophagitis outpaces changes in endoscopic and biopsy practice: National population-based estimates from Denmark. *Aliment Pharmacol Ther*. 2015;41(7):662-670.
15. Dellon ES, Hirano I. Epidemiology and natural history of eosinophilic esophagitis. *Gastroenterology*. 2018;154(2):319-32 e3.
16. Prasad GA, Talley NJ, Romero Y, et al. Prevalence and predictive factors of eosinophilic esophagitis in patients presenting with dysphagia: a Prospective Study. *Am J Gastroenterol*. 2007;102(12):2627-2632.
17. Sperry SL, Crockett SD, Miller CB, Shaheen NJ, Dellon ES. Esophageal foreign-body impactions: epidemiology, time trends, and the impact of the increasing prevalence of eosinophilic esophagitis. *Gastrointest Endosc*. 2011;74(5):985-991.
18. Kidambi T, Toto E, Ho N, Taft T, Hirano I. Temporal trends in the relative prevalence of dysphagia etiologies from 1999-2009. *World J Gastroenterol*. 2012;18(32):4335-4341.
19. Straumann A, Spichtin HP, Grize L, Bucher KA, Beglinger C, Simon HU. Natural history of primary eosinophilic esophagitis: a follow-up of 30 adult patients for up to 11.5 years. *Gastroenterology*. 2003;125(6):1660-1669.
20. Spergel JM, Brown-Whitehorn TF, Beausoleil JL, et al. 14 years of eosinophilic esophagitis: clinical features and prognosis. *J Pediatric Gastroenterol Nutr*. 2009;48(1):30-36.
21. Sperry SL, Woosley JT, Shaheen NJ, Dellon ES. Influence of race and gender on the presentation of eosinophilic esophagitis. *Am J Gastroenterol*. 2012;107(2):215-221.
22. Mackenzie SH, Go M, Chadwick B, et al. Eosinophilic oesophagitis in patients presenting with dysphagia—a prospective analysis. *Aliment Pharmacol Ther*. 2008;28(9):1140-1146.
23. Veerappan GR, Perry JL, Duncan TJ, et al. Prevalence of eosinophilic esophagitis in an adult population undergoing upper endoscopy: a Prospective Study. *Clin Gastroenterol Hepatol*. 2009;7(4):420-426, 6 e1-2.
24. Simon D, Marti H, Heer P, Simon HU, Braathen LR, Straumann A. Eosinophilic esophagitis is frequently associated with IgE-mediated allergic airway diseases. *J Allergy Clin Immunol*. 2005;115(5):1090-1092.
25. Jyonouchi S, Brown-Whitehorn TA, Spergel JM. Association of eosinophilic gastrointestinal disorders with other atopic disorders. *Immunol Allergy Clin North Am*. 2009;29(1):85-97.
26. Assa'ad A. Eosinophilic esophagitis: association with allergic disorders. *Gastrointest Endosc Clin North Am*. 2008;18(1):119-132.
27. Roy-Ghanta S, Larosa DF, Katzka DA. Atopic characteristics of adult patients with eosinophilic esophagitis. *Clin Gastroenterol Hepatol*. 2008;6(5):531-535.
28. Aceves SS. Eosinophilic esophagitis. *Immunol Allergy Clin North Am*. 2015;35(1):145-159.
29. Rothenberg ME. Biology and treatment of eosinophilic esophagitis. *Gastroenterology*. 2009;137(4):1238-1249.
30. Dellon ES. The pathogenesis of eosinophilic esophagitis: beyond the eosinophil. *Dig Dis Sci*. 2013;58(6):1445-1448.
31. Zhang Z, Sferra TJ, Eroglu Y. T cell co-stimulatory molecules: a co-conspirator in the pathogenesis of eosinophilic esophagitis? *Dig Dis Sci*. 2013;58(6):1497-1506.
32. Clayton F, Peterson K. Eosinophilic esophagitis: pathophysiology and definition. *Gastrointest Endosc Clin N Am*. 2018;28(1):1-14.
33. Liacouras CA, Spergel JM, Ruchelli E, et al. Eosinophilic esophagitis: a 10-year experience in 381 children. *Clin Gastroenterol Hepatol*. 2005;3(12):1198-206.

34. Gonsalves N. Distinct features in the clinical presentations of eosinophilic esophagitis in children and adults: is this the same disease? *Dig Dis*. 2014;32(1-2):89-92.
35. Straumann A, Aceves SS, Blanchard C, et al. Pediatric and adult eosinophilic esophagitis: similarities and differences. *Allergy*. 2012;67(4):477-490.
36. Lucendo AJ, Sanchez-Cazalilla M. Adult versus pediatric eosinophilic esophagitis: important differences and similarities for the clinician to understand. *Expert Rev Clin Immunol*. 2012;8(8):733-745.
37. Baxi S, Gupta SK, Swigonski N, Fitzgerald JF. Clinical presentation of patients with eosinophilic inflammation of the esophagus. *Gastrointest Endosc*. 2006;64(4):473-478.
38. Dellon ES, Kim HP, Sperry SL, Rybnicek DA, Woosley JT, Shaheen NJ. A phenotypic analysis shows that eosinophilic esophagitis is a progressive fibrostenotic disease. *Gastrointest Endosc*. 2014;79(4):577-585 e4.
39. Aceves SS, Ackerman SJ. Relationships between eosinophilic inflammation, tissue remodeling, and fibrosis in eosinophilic esophagitis. *Immunol Allergy Clin North Am*. 2009;29(1):197-211, xiii-xiv.
40. Hirano I, Aceves SS. Clinical implications and pathogenesis of esophageal remodeling in eosinophilic esophagitis. *Gastroenterol Clin North Am*. 2014;43(2):297-316.
41. Schoepfer AM, Safroneeva E, Bussmann C, et al. Delay in diagnosis of eosinophilic esophagitis increases risk for stricture formation in a time-dependent manner. *Gastroenterology*. 2013;145(6):1230-1236 e1-2.
42. Straumann A. The natural history and complications of eosinophilic esophagitis. *Thoracic Surg Clin*. 2011;21(4):575-587.
43. Menard-Katcher P, Marks KL, Liacouras CA, Spergel JM, Yang YX, Falk GW. The natural history of eosinophilic oesophagitis in the transition from childhood to adulthood. *Aliment Pharmacol Ther*. 2013;37(1):114-121.
44. van Rhijn BD, Oors JM, Smout AJ, Bredenoord AJ. Prevalence of esophageal motility abnormalities increases with longer disease duration in adult patients with eosinophilic esophagitis. *Neurogastroenterol Motil*. 2014;26(9):1349-1355.
45. Choksi Y, Lal P, Slaughter JC, et al. Esophageal mucosal impedance patterns discriminate patients with eosinophilic esophagitis from patients with GERD. *Clin Gastroenterol Hepatol*. 2018;16(5):664-671 e1.
46. Dranove JE, Horn DS, Davis MA, Kernek KM, Gupta SK. Predictors of response to proton pump inhibitor therapy among children with significant esophageal eosinophilia. *J Pediatr*. 2009;154(1):96-100.
47. Sayej WN, Patel R, Baker RD, Tron E, Baker SS. Treatment with high-dose proton pump inhibitors helps distinguish eosinophilic esophagitis from noneosinophilic esophagitis. *J Pediatr Gastroenterol Nutr*. 2009;49(4):393-399.
48. Peterson KA, Thomas KL, Hilden K, Emerson LL, Wills JC, Fang JC. Comparison of esomeprazole to aerosolized, swallowed fluticasone for eosinophilic esophagitis. *Dig Dis Sci*. 2010;55(5):1313-1319.
49. Molina-Infante J, Ferrando-Lamana L, Ripoll C, et al. Esophageal eosinophilic infiltration responds to proton pump inhibition in most adults. *Clin Gastroenterol Hepatol*. 2011;9(2):110-117.
50. Francis DL, Foxx-Orenstein A, Arora AS, et al. Results of ambulatory pH monitoring do not reliably predict response to therapy in patients with eosinophilic oesophagitis. *Aliment Pharmacol Ther*. 2012;35(2):300-307.
51. Dellon ES, Gonsalves N, Hirano I, et al. ACG clinical guideline: evidenced based approach to the diagnosis and management of esophageal eosinophilia and eosinophilic esophagitis (EoE). *Am J Gastroenterol*. 2013;108(5):679-692; quiz 93.
52. Schroeder S, Robinson ZD, Masterson JC, et al. Esophageal human beta-defensin expression in eosinophilic esophagitis. *Pediatr Res*. 2013;73(5):647-654.
53. Vazquez-Elizondo G, Ngamruengphong S, Khrisna M, Devault KR, Talley NJ, Achem SR. The outcome of patients with oesophageal eosinophilic infiltration after an eight-week trial of a proton pump inhibitor. *Aliment Pharmacol Ther*. 2013;38(10):1312-1319.
54. Dellon ES, Speck O, Woodward K, et al. Markers of eosinophilic inflammation for diagnosis of eosinophilic esophagitis and proton pump inhibitor-responsive esophageal eosinophilia: a prospective study. *Clin Gastroenterol Hepatol*. 2014;12(12):2015-2022.
55. Moawad FJ. Letter: distinguishing PPI-responsive oesophageal eosinophilia from eosinophilic esophagitis – still a long way to go; authors' reply. *Aliment Pharmacol Ther*. 2014;39(10):1249-1250.
56. Wen T, Dellon ES, Moawad FJ, Furuta GT, Aceves SS, Rothenberg ME. Transcriptome analysis of proton pump inhibitor-responsive esophageal eosinophilia reveals proton pump inhibitor-reversible allergic inflammation. *J Allergy Clin Immunol*. 2015;135(1):187-197.
57. Shoda T, Matsuda A, Nomura I, et al. Eosinophilic esophagitis versus proton pump inhibitor-responsive esophageal eosinophilia: transcriptome analysis. *J Allergy Clin Immunol*. 2017;139(6):2010-2013.
58. Sodikoff J, Hirano I. Therapeutic strategies in eosinophilic esophagitis: induction, maintenance and refractory disease. *Best Pract Res Clin Gastroenterol*. 2015;29(5):829-839.
59. Dellon ES, Irani AM, Hill MR, Hirano I. Development and field testing of a novel patient-reported outcome measure of dysphagia in patients with eosinophilic esophagitis. *Aliment Pharmacol Ther*. 2013;38(6):634-642.
60. Schoepfer AM, Straumann A, Panczak R, et al. Development and validation of a symptom-based activity index for adults with eosinophilic esophagitis. *Gastroenterology*. 2014;147(6):1255-1266 e21.
61. Stern E, Taft T, Zalewski A, Gonsalves N, Hirano I. Prospective assessment of disease-specific quality of life in adults with eosinophilic esophagitis. *Dis Esophagus*. 2018;31(4).
62. Kim HP, Vance RB, Shaheen NJ, Dellon ES. The prevalence and diagnostic utility of endoscopic features of eosinophilic esophagitis: a meta-analysis. *Clin Gastroenterol Hepatol*. 2012;10(9):988-996 e5.
63. Hirano I, Moy N, Heckman MG, Thomas CS, Gonsalves N, Achem SR. Endoscopic assessment of the oesophageal features of eosinophilic oesophagitis: validation of a novel classification and grading system. *Gut*. 2013;62(4):489-495.
64. van Rhijn BD, Verheij J, Smout AJ, Bredenoord AJ. The endoscopic reference score shows modest accuracy to predict histologic remission in adult patients with eosinophilic esophagitis. *Neurogastroenterol Motil*. 2016;28(11):1714-1722.
65. Kedika RR, Souza RF, Spechler SJ. Potential anti-inflammatory effects of proton pump inhibitors: a review and discussion of the clinical implications. *Dig Dis Sci*. 2009;54(11):2312-2317.
66. van Rhijn BD, Weijenberg PW, Verheij J, et al. Proton pump inhibitors partially restore mucosal integrity in patients with proton pump inhibitor-responsive esophageal eosinophilia but not eosinophilic esophagitis. *Clin Gastroenterol Hepatol*. 2014;12(11):1815-1823 e2.
67. Cheng E, Zhang X, Huo X, et al. Omeprazole blocks cotaxin-3 expression by oesophageal squamous cells from patients with eosinophilic oesophagitis and GORD. *Gut*. 2013;62(6):824-832.

68. Zhang X, Cheng E, Huo X, et al. Omeprazole blocks STAT6 binding to the eotaxin-3 promoter in eosinophilic esophagitis cells. *PLoS one*. 2012;7(11):e50037.
69. van Rhijn BD, Verheij J, van den Bergh Weerman MA, et al. Histological response to fluticasone propionate in patients with eosinophilic esophagitis is associated with improved functional esophageal mucosal integrity. *Am J Gastroenterol*. 2015;110(9):1289-1297.
70. Chuang MY, Chinnaratha MA, Hancock DG, et al. Topical steroid therapy for the treatment of Eosinophilic Esophagitis (EoE): a systematic review and meta-analysis. *Clin Transl Gastroenterol*. 2015;6:e82.
71. Philla KQ, Min SB, Hefner JN, et al. Swallowed glucocorticoid therapy for eosinophilic esophagitis in children does not suppress adrenal function. *J Pediatr Endocrinol Metab*. 2015;28(9-10):1101-1106.
72. Golekoh MC, Hornung LN, Mukkada VA, Khoury JC, Putnam PE, Backeljauw PF. Adrenal insufficiency after chronic swallowed glucocorticoid therapy for eosinophilic esophagitis. *J Pediatr*. 2016;170:240-245.
73. Attwood SE, Lewis CJ, Bronder CS, Morris CD, Armstrong GR, Whittam J. Eosinophilic oesophagitis: a novel treatment using Montelukast. *Gut*. 2003;52(2):181-185.
74. Lucendo AJ, De Rezende LC, Jimenez-Contreras S, et al. Montelukast was inefficient in maintaining steroid-induced remission in adult eosinophilic esophagitis. *Dig Dis Sci*. 2011;56(12):3551-3558.
75. Straumann A, Hoesli S, Bussmann C, et al. Anti-eosinophil activity and clinical efficacy of the CRTH2 antagonist OC000459 in eosinophilic esophagitis. *Allergy*. 2013;68(3):375-385.
76. Netzer P, Gschossmann JM, Straumann A, Sendensky A, Weimann R, Schoepfer AM. Corticosteroid-dependent eosinophilic oesophagitis: azathioprine and 6-mercaptopurine can induce and maintain long-term remission. *Eur J Gastroenterol Hepatol*. 2007;19(10):865-869.
77. Clayton F, Fang JC, Gleich GJ, et al. Eosinophilic esophagitis in adults is associated with IgG4 and not mediated by IgE. *Gastroenterology*. 2014;147(3):602-609.
78. Loizou D, Enav B, Komlodi-Pasztor E, et al. A pilot study of omalizumab in eosinophilic esophagitis. *PLoS one*. 2015;10(3):e0113483.
79. Stein ML, Collins MH, Villanueva JM, et al. Anti-IL-5 (mepolizumab) therapy for eosinophilic esophagitis. *J Allergy Clin Immunol*. 2006;118(6):1312-1319.
80. Stein ML, Villanueva JM, Buckmeier BK, et al. Anti-IL-5 (mepolizumab) therapy reduces eosinophil activation ex vivo and increases IL-5 and IL-5 receptor levels. *J Allergy Clin Immunol*. 2008;121(6):1473-1483, 83 e1-4.
81. Straumann A, Conus S, Grzonka P, et al. Anti-interleukin-5 antibody treatment (mepolizumab) in active eosinophilic oesophagitis: a randomised, placebo-controlled, double-blind trial. *Gut*. 2010;59(1):21-30.
82. Assa'ad AH, Gupta SK, Collins MH, et al. An antibody against IL-5 reduces numbers of esophageal intraepithelial eosinophils in children with eosinophilic esophagitis. *Gastroenterology*. 2011;141(5):1593-604.
83. Spergel JM, Rothenberg ME, Collins MH, et al. Reslizumab in children and adolescents with eosinophilic esophagitis: results of a double-blind, randomized, placebo-controlled trial. *J Allergy Clin Immunol*. 2012;129(2):456-463, 463 e1-3.
84. Rothenberg ME, Wen T, Greenberg A, et al. Intravenous anti-IL-13 mAb QAX576 for the treatment of eosinophilic esophagitis. *J Allergy Clin Immunol*. 2015;135(2):500-507.
85. Hirano I, Dellon ES, Hamilton JD, et al. Efficacy of Dupilumab in a phase 2 randomized trial of adults with active eosinophilic esophagitis. *Gastroenterology*. 2020;158(1):111-122 e10.
86. Dellon E, Peterson K, Murray J. Efficacy and safety of AK002 in adult patients with active eosinophilic gastritis and/or gastroenteritis: primary results from a randomized, double-blind, placebo-controlled phase 2 trial (ENIGMA Study). *United Eur Gastroenterol J*. 2019;8:1419-1420.
87. Markowitz JE, Spergel JM, Ruchelli E, Liacouras CA. Elemental diet is an effective treatment for eosinophilic esophagitis in children and adolescents. *Am J Gastroenterol*. 2003;98(4):777-782.
88. Peterson KA, Byrne KR, Vinson LA, et al. Elemental diet induces histologic response in adult eosinophilic esophagitis. *Am J Gastroenterol*. 2013;108(5):759-766.
89. Arias A, Gonzalez-Cervera J, Tenias JM, Lucendo AJ. Efficacy of dietary interventions for inducing histologic remission in patients with eosinophilic esophagitis: a systematic review and meta-analysis. *Gastroenterology*. 2014;146(7):1639-1648.
90. Spergel JM, Brown-Whitehorn T, Beausoleil JL, Shuker M, Liacouras CA. Predictive values for skin prick test and atopy patch test for eosinophilic esophagitis. *J Allergy Clin Immunol*. 2007;119(2):509-511.
91. Philpott H, Nandurkar S, Royce SG, Thien F, Gibson PR. Allergy tests do not predict food triggers in adult patients with eosinophilic oesophagitis. A comprehensive prospective study using five modalities. *Aliment Pharmacol Ther*. 2016;44(3):223-233.
92. Gonsalves N, Yang GY, Doerfler B, Ritz S, Ditto AM, Hirano I. Elimination diet effectively treats eosinophilic esophagitis in adults; food reintroduction identifies causative factors. *Gastroenterology*. 2012;142(7):1451-1419 e1; quiz e14-5.
93. Lucendo AJ, Arias A, Gonzalez-Cervera J, et al. Empiric 6-food elimination diet induced and maintained prolonged remission in patients with adult eosinophilic esophagitis: a prospective study on the food cause of the disease. *J Allergy Clin Immunol*. 2013;131(3):797-804.
94. Kagalwalla AF, Sentongo TA, Ritz S, et al. Effect of six-food elimination diet on clinical and histologic outcomes in eosinophilic esophagitis. *Clin Gastroenterol Hepatol*. 2006;4(9):1097-1102.
95. Kagalwalla AF, Shah A, Li BU, et al. Identification of specific foods responsible for inflammation in children with eosinophilic esophagitis successfully treated with empiric elimination diet. *J Pediatr Gastroenterol Nutr*. 2011;53(2):145-149.
96. Kagalwalla AF, Amsden K, Shah A, et al. Cow's milk elimination: a novel dietary approach to treat eosinophilic esophagitis. *J Pediatr Gastroenterol Nutr*. 2012;55(6):711-716.
97. Kruszewski PG, Russo JM, Franciosi JP, Varni JW, Platts-Mills TA, Erwin EA. Prospective, comparative effectiveness trial of cow's milk elimination and swallowed fluticasone for pediatric eosinophilic esophagitis. *Dis Esophagus*. 2016;29(4):377-84.
98. Molina-Infante J, Arias A, Alcedo J, et al. Step-up empiric elimination diet for pediatric and adult eosinophilic esophagitis: the 2-4-6 study. *J Allergy Clin Immunol*. 2018;141(4):1365-1372.
99. Spergel JM, Brown-Whitehorn TF, Cianferoni A, et al. Identification of causative foods in children with eosinophilic esophagitis treated with an elimination diet. *J Allergy Clin Immunol*. 2012;130(2):461-467 e5.
100. Molina-Infante J MI, Alcedo J, Garcia-Romero R, et al. Step-up empiric elimination diet for pediatric and adult eosinophilic esophagitis: the 2-4-6 study. *UEG Week Abstract*. 2016.

101. Molina-Infante J, Arias A, Barrio J, Rodriguez-Sanchez J, Sanchez-Cazalilla M, Lucendo AJ. Four-food group elimination diet for adult eosinophilic esophagitis: a Prospective Multicenter Study. *J Allergy Clin Immunol*. 2014;134(5):1093-1099 e1.
102. Wang R, Hirano I, Doerfler B, Zalewski A, Gonsalves N, Taft T. Assessing adherence and barriers to long-term elimination diet therapy in adults with eosinophilic esophagitis. *Dig Dis Sci*. 2018;63(7):1756-17562.
103. Aceves SS, Newbury RO, Dohil R, Bastian JF, Broide DH. Esophageal remodeling in pediatric eosinophilic esophagitis. *J Allergy Clin Immunol*. 2007;119(1):206-212.
104. Aceves SS, Chen D, Newbury RO, Dohil R, Bastian JF, Broide DH. Mast cells infiltrate the esophageal smooth muscle in patients with eosinophilic esophagitis, express TGF-beta1, and increase esophageal smooth muscle contraction. *J Allergy Clin Immunol*. 2010;126(6):1198-1204 e4.
105. Cheng E, Souza RF, Spechler SJ. Tissue remodeling in eosinophilic esophagitis. *Am J Physiol Gastrointest Liver Physiol*. 2012;303(11):G1175-G1187.
106. Bohm ME, Richter JE. Review article: oesophageal dilation in adults with eosinophilic oesophagitis. *Aliment Pharmacol Ther*. 2011;33(7):748-757.
107. Mishra A, Wang M, Pemmaraju VR, et al. Esophageal remodeling develops as a consequence of tissue specific IL-5-induced eosinophilia. *Gastroenterology*. 2008;134(1):204-214.
108. Aceves SS. Tissue remodeling in patients with eosinophilic esophagitis: what lies beneath the surface? *J Allergy Clin Immunol*. 2011;128(5):1047-1049.
109. Kagalwalla AF, Akhtar N, Woodruff SA, et al. Eosinophilic esophagitis: epithelial mesenchymal transition contributes to esophageal remodeling and reverses with treatment. *J Allergy Clin Immunol*. 2012;129(5):1387-1396 e7.
110. Rieder F, Nonevski I, Ma J, et al. T-helper 2 cytokines, transforming growth factor beta1, and eosinophil products induce fibrogenesis and alter muscle motility in patients with eosinophilic esophagitis. *Gastroenterology*. 2014;146(5):1266-1277 e1-9.
111. Dellon ES. Diagnosis and management of eosinophilic esophagitis. *Clin Gastroenterol Hepatol*. 2012;10(10):1066-1078.
112. Schoepfer AM, Gonsalves N, Bussmann C, et al. Esophageal dilation in eosinophilic esophagitis: effectiveness, safety, and impact on the underlying inflammation. *Am J Gastroenterol*. 2010;105(5):1062-1070.
113. Bohm M, Richter JE, Kelsen S, Thomas R. Esophageal dilation: simple and effective treatment for adults with eosinophilic esophagitis and esophageal rings and narrowing. *Dis Esophagus*. 2010;23(5):377-385.
114. Dellon ES, Gibbs WB, Rubinas TC, et al. Esophageal dilation in eosinophilic esophagitis: safety and predictors of clinical response and complications. *Gastrointest Endosc*. 2010;71(4):706-712.
115. Kaplan M, Mutlu EA, Jakate S, et al. Endoscopy in eosinophilic esophagitis: "feline" esophagus and perforation risk. *Clin Gastroenterol Hepatol*. 2003;1(6):433-437.
116. Cohen MS, Kaufman AB, Palazzo JP, Nevin D, Dimarino AJ, Jr, Cohen S. An audit of endoscopic complications in adult eosinophilic esophagitis. *Clin Gastroenterol Hepatol*. 2007;5(10):1149-1153.
117. Kavitt RT, Penson DF, Vaezi MF. Eosinophilic esophagitis: dilate or medicate? A cost analysis model of the choice of initial therapy. *Dis Esophagus*. 2014;27(5):418-423.
118. Runge TM, Eluri S, Cotton CC, et al. Outcomes of esophageal dilation in eosinophilic esophagitis: safety, efficacy, and persistence of the fibrostenotic phenotype. *Am J Gastroenterol*. 2016;111(2):206-213.