





**CORE CURRICULUM****SCAI guidelines on device selection in Aorto-iliac arterial interventions**

Dmitriy N. Feldman MD, FSCAI<sup>1</sup> | Ehrin J. Armstrong MD, FSCAI<sup>2</sup>  |  
 Herbert D. Aronow MD, MPH, FSCAI<sup>3</sup> | Subhash Banerjee MD, FSCAI<sup>4</sup> |  
 Larry J. Díaz-Sandoval MD, FSCAI<sup>5</sup> | Michael R. Jaff DO, FSCAI<sup>6</sup> |  
 Sasanka Jayasuriya MD, FSCAI<sup>7</sup> | Safi U. Khan MD, MS<sup>8</sup>  |  
 Andrew J. Klein MD, FSCAI<sup>9</sup> | Sahil A. Parikh MD, FSCAI<sup>10</sup> |  
 Kenneth Rosenfield MD, MSCAI<sup>11</sup> | Mehdi H. Shishehbor DO, MPH, PhD, FSCAI<sup>12</sup>  |  
 Rajesh V. Swaminathan MD, FSCAI<sup>13</sup> | Christopher J. White MD, MSCAI<sup>14</sup> 

<sup>1</sup>Weill Cornell Medical College, New York, New York

<sup>2</sup>University of Colorado School of Medicine, Aurora, Colorado

<sup>3</sup>The Warren Alpert Medical School of Brown University, Providence, Rhode Island

<sup>4</sup>Dallas Veterans Affairs Medical Center, Dallas, Texas

<sup>5</sup>Metro Health-University of Michigan Health, Wyoming, Michigan

<sup>6</sup>Newton-Wellesley Hospital, Newton, MA

<sup>7</sup>Ascension - Columbia St. Mary's Hospital, Milwaukee, Wisconsin

<sup>8</sup>West Virginia University, Morgantown, West Virginia

<sup>9</sup>Piedmont Heart Institute, Atlanta, Georgia

<sup>10</sup>Columbia University Medical Center, New York, New York

<sup>11</sup>Massachusetts General Hospital, Boston, Massachusetts

<sup>12</sup>Univeristy Hospitals Cleveland Medical Center and Case Western Reserve, University School of Medicine, Cleveland, Ohio

<sup>13</sup>Duke University Medical Center, Duke Clinical Research Institute, Durham, North Carolina

<sup>14</sup>Ochsner Clinical School, University of Queensland, AU, Ochsner Health System, New Orleans, Louisiana

**Correspondence**

Dmitriy N. Feldman, Weill Cornell Medical College, New York Presbyterian Hospital, Department of Medicine, Greenberg Division of Cardiology, 520 East 70 Street, Starr-434 Pavilion, New York, NY 10021.

Email: dnf9001@med.cornell.edu

**1 | INTRODUCTION**

Aorto-iliac (Ao-I) disease is quite prevalent and leads to significant limitation in functional status and quality of life. Advances in endovascular

therapy (EVT) techniques in the last 25 years, low risk of peri-procedural complications and excellent long-term patency have made it possible to treat most symptomatic patients with Ao-I disease using an endovascular-first rather than a surgical approach in addition to guidelines-directed medical therapy. The approach to intra-procedural assessment of Ao-I lesions has evolved over time to include pressure gradient measurement and intravascular imaging. In 2017, the Society for Cardiovascular Angiography and Interventions (SCAI) published an update to the Appropriate Use Criteria (AUC) for EVT in the Ao-I, femoral-popliteal (FP), infra-popliteal and renal arterial circulations.<sup>1</sup> In 2018, a multi-societal AUC document for EVT was released by the American College of Cardiology (ACC)/American Heart Association

**Abbreviations:** ABL, ankle-brachial index; Ao-I, aorto-iliac; AUC, appropriate use criteria; BES, balloon expandable stent; BMS, bare metal stent; CIA, common iliac artery; CLI, critical limb ischemia; COR, class of recommendation; CTO, chronic total occlusion; DCB, drug-coated balloon; DES, drug-eluting stent; DUS, duplex ultrasonography; EIA, external iliac artery; EVT, endovascular therapy; FP, femoral-popliteal; ISR, in stent restenosis; LOE, level of evidence; PTA, percutaneous transluminal angioplasty; QoL, quality of life; RCT, randomized clinical trial; SCAI, Society for Cardiovascular Angiography and Interventions; SES, self-expanding stent; SFA, superficial femoral artery; TLR, target lesion revascularization; TVR, target vessel revascularization.

**TABLE 1** Author relevant relationships with industry and other entities

Group member	Date	Consultant	Speaker's bureau	Ownership/ Stock/ Shareholder	Grant or research support	Institutional or organizational relationship	Expert witness	Advisory board
Dmitriy N. Feldman, MD, FSCAI (chair)	September 27, 2018				Medtronic (SPYRAL HTN-ON MED trial)			
Christopher J. White, MD, MSCAI (co-chair)	September 14, 2018							
Ehrin J. Armstrong, MD, FSCAI	September 14, 2018	Abbott, Cardiovascular Systems, Gore, Medtronic, Philips						Abbott, Cardiovascular Systems, Gore, Medtronic, Philips
Herbert D. Aronow, MD, MPH, FSCAI	September 14, 2018	Philips (DSMB ILLUMENATE trial)						
Subhash Banerjee, MD, FSCAI	September 14, 2018	Medtronic, AstraZeneca			Boston Scientific, Abbott, Aralez	Boston Scientific, Abbott, Aralez		
Larry J. Diaz, MD, FSCAI	September 15, 2018							
Michael R. Jaff, DO, FSCAI	September 17, 2018, updated 12/10/2019			Embolitech, PQ Bypass, Gemini, Vascular Therapies, Sano V		Effective January 2020: part-time employment with Boston Scientific		Abbott, Boston Scientific, Medtronic, American Orthotics and Prosthetics Association, Vactronix, Venarum, Philips
Sasanka Jayasuriya, MD, FSCAI	September 28, 2018							
Andrew J. Klein, MD, FSCAI	September 14, 2018							
Sahil A. Parikh, MD, FSCAI	September 15, 2018	Boston Scientific, Terumo, Asahi, Merril Lifesciences	Heartflow		Boston Scientific, Shockwave Medical, TriReme Medical, Sumodics, Silk Road Medical			Abbott, Medtronic, Boston Scientific, Philips, CSI
Kenneth Rosenfield, MD, MSCAI	September 17, 2018	Abbott, Cardinal Health, Cook, Thromborex, Surmodics, Volcano/ Philips, Amgen		Capture Vascular, Contego, CRUZAR Systems, Embolitech, Endospan, Eximo, Micell, PQ Bypass, Primacea, Shockwave,	NIH, BSCI			Abbott, Angiodynamics, BSCI, Thromborex, Surmodics, Volcano/Philips,

**TABLE 1** (Continued)

Group member	Date	Consultant	Speaker's bureau	Ownership/ Stock/ Shareholder	Grant or research support	Institutional or organizational relationship	Expert witness	Advisory board
				Silk Road Medical, Summa Therapeutics, Valcare, Thrombolex				
Mehdi Shishehbor, DO, FSCAI	September 27, 2018							Abbott, Boston Scientific, Medtronic, Philips/ Spectranetics, Terumo
Rajesh V. Swaminathan, MD, FSCAI	September 14, 2018				ACIST Medical			

(AHA)/SCAI/Society of Interventional Radiology (SIR)/Society for Vascular Medicine (SVM).<sup>2</sup> However, these documents did not address the selection of specific devices when EVT is indicated. Given the wide spectrum of available endovascular devices and paucity of comparative effectiveness data, SCAI developed the first consensus-based guidelines document for device selection in *femoral-popliteal* arterial interventions in 2018.<sup>3</sup> The purpose of this device-focused consensus document is to provide a comprehensive review of comparative effectiveness data in *aorto-iliac* arterial interventions, including safety and efficacy of devices, and to provide clinicians with guidance (class of recommendation and level of evidence) for device selection, when these devices are intended as definitive therapy.

## 2 | METHODOLOGY

This document has been developed according to SCAI Publications Committee policies for writing group composition, disclosure and management of relationships with industry (RWI), internal and external review, and organizational approval. The writing group has been organized to ensure diversity of perspectives and demographics, multi-stakeholder representation, and appropriate balance of RWI. The author disclosures are included in Table 1. Before appointment, members of the writing group were asked to disclose all relevant financial relationships with industry from the 12 months prior to their nomination. A majority of the writing group disclosed no relevant financial relationships. Disclosures were periodically reviewed during document development and updated as appropriate. SCAI policy requires that writing group members with a current financial interest be recused from participating in discussions or voting on relevant recommendations. In December 2019, one group member (MRJ) disclosed a new role involving employment by an industry stakeholder; this member was recused from further participation in document development (including voting on recommendations and editing document) on the effective date of the new role, January 1, 2020. The

work of the writing committee was supported exclusively by SCAI, a nonprofit medical specialty society, without any commercial support. Writing group members contributed to this effort on a volunteer basis and did not receive payment from SCAI.

An evidence review panel developed a protocol and conducted a systematic review of PubMed, Embase, and CENTRAL datasets using key search terms (Data S1) according to established PRISMA (preferred reporting items for systematic reviews and meta-analyses) guidelines. Prespecified inclusion criteria for the studies were (1) randomized controlled trials, meta-analyses, registries, nonrandomized comparative studies, case series and cohort studies; (2) studies comparing efficacy and/or safety of endovascular interventions for Ao-I occlusive disease. The search criteria excluded review articles, editorials, interventions for other arterial beds (ie, femoral-popliteal), articles solely studying surgical interventions, or those evaluating interventions for Ao-I aneurysms. Initially, 3,587 articles were identified. After removal of duplicates and screening of titles and abstracts, 397 full text articles were shortlisted. Further screening was conducted based on specific questionnaire and ultimately 131 articles were examined in this document (Figure 1) (Data S2).

The writing group composed of expert clinicians used a modified Delphi panel methodology to form and rate recommendations based on the data extracted during the systematic review. The panel participated in three rounds of voting, with discussions among the panelists after the first two anonymized rounds. Each panelist had equal weight in determining the final rating. Agreement among panelists was achieved when >80% of the recommendations ratings for the scenarios were concordant (Table 2).

The class (strength) of recommendation (COR) represents the anticipated magnitude of comparative benefit for a group of devices (ie, symptom improvement, patency, functional status and/or quality of life) against the risks and cost of the device use based on the SCAI (modified ACC/AHA guideline recommendation) classification (Table 2).<sup>3</sup> The Level of Evidence (LOE) represents the quality and certainty of evidence supporting the effect of the devices on the

basis of the type, quality, quantity, and consistency of data. The COR and LOE are determined independently; any COR may be paired with any LOE.

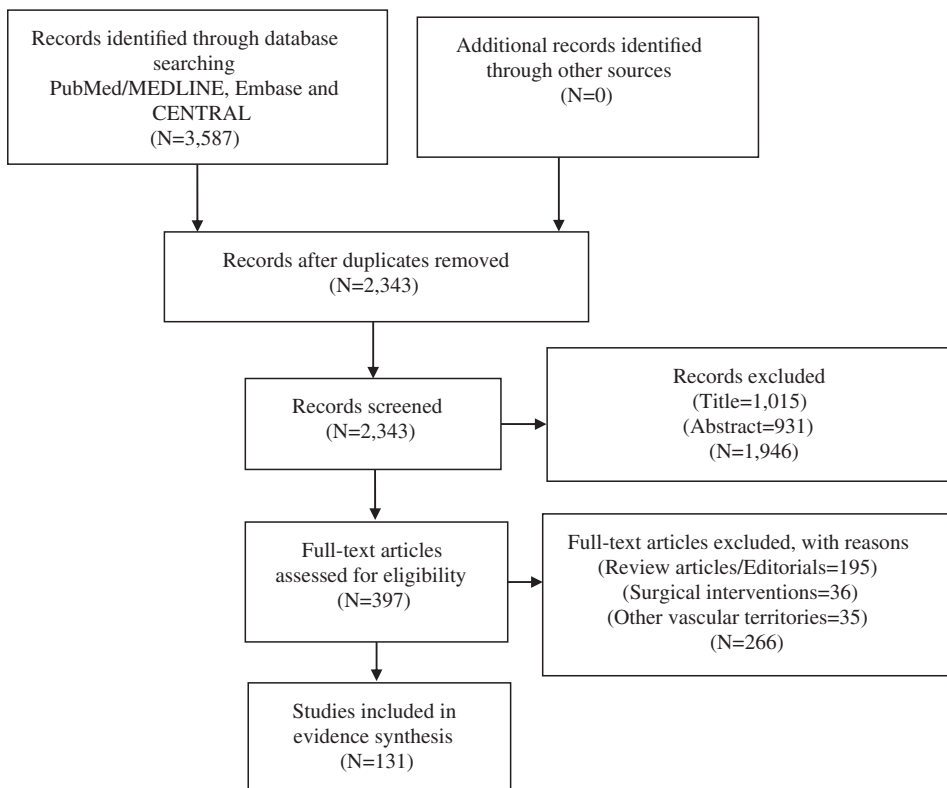
The draft manuscript was peer reviewed in February 2020 and the document was revised to address pertinent comments. The writing group unanimously approved the final version of the document. The SCAI Publications Committee and Executive Committee endorsed the document as official society guidance in April 2020. SCAI guidelines are primarily intended to help clinicians make decisions about treatment alternatives. SCAI guidelines do not necessarily follow the Food and Drug Administration's (FDA) device labeling or the Instructions for Use (IFUs). Clinicians must consider the clinical and anatomic presentation, setting, and preferences of individual patients to make judgements about the optimal approach.

### 3 | DEFINITIONS AND ASSUMPTIONS

- 1 The scenarios chosen in this document are largely based upon the anatomical features of the lesions and presence of hemodynamically significant Ao-I disease rather than clinical presentation and are not intended to be all-inclusive.
- 2 *Location*. The common iliac arteries (CIA) arise from the distal abdominal aorta and bifurcate to form the external (EIA) and internal (or hypogastric) iliac arteries. The external iliac artery becomes the common femoral artery at the inguinal canal while the internal iliac artery supplies the pelvis, buttocks, genitals, and is a source of collateral circulation to the intestines. The diameter of the

common iliac arteries ranges from 7 to 12 mm, while the external iliac artery ranges from 6 to 10 mm. The most recently updated TASC-IIIB document, describes the anatomic characteristics of Ao-I atherosclerotic disease (Figure 2).<sup>4</sup>

- 3 *Severity*. The significance of Ao-I lesions angiographically determined by diameter stenosis has been defined as mild (<50%), significant ( $\geq 50\%$ ), severe ( $\geq 70\text{--}99\%$ ), and occluded (100% diameter stenosis).
- 4 *Lesion length*. Categorized into focal ( $\leq 4$  cm) and diffuse ( $> 4$  cm), which is consistent with the definitions used for the peripheral vascular interventions SCAI AUC document.<sup>1</sup>
- 5 *Calcification*. The assessment of lesion calcification is highly subjective in published trials and registries. The Peripheral Academic Research Consortium (PARC) document definition was adopted in this document, which describes degrees of lesion calcification as (1) focal with  $< 180^\circ$  of the vessel wall and less than half the lesion length; (2) mild with  $< 180^\circ$  and greater than half the total lesion length; (3) moderate with  $\geq 180^\circ$  of the vessel wall and less than half the lesion length; and (4) severe with  $\geq 180^\circ$  and greater than half the total lesion length.<sup>5</sup>
- 6 *In stent restenosis (ISR)*. ISR is defined as a stenosis or occlusion within a previously placed stent, regardless of whether the original stent was bare metal, drug eluting, or covered; caused by inflammatory, fibrotic or atherosclerotic process rather than by a thrombotic occlusion of the stent.
- 7 For all device scenarios, COR/LOE (Table 2) are provided for groups or categories of devices and not intended to compare individual devices and/or manufacturers.
- 8 The COR/LOE for a category of the devices were assigned according to the best comparative data from published trials/



**FIGURE 1** Selection study process

**TABLE 2** Applying class of recommendation and level of evidence to device strategies [Color table can be viewed at wileyonlinelibrary.com]

Class (Strength) of Recommendation	Level (Quality) of Evidence
<b>Class I (Strong)</b> Benefit >>> Risk (&Cost) <ul style="list-style-type: none"> <li>• Device is recommended</li> <li>• Device is indicated/useful/beneficial/cost-effective</li> </ul>	<b>Level A</b> <ul style="list-style-type: none"> <li>• High-quality evidence from &gt;1 RCT</li> <li>• Meta-analyses of high-quality RCTs</li> <li>• One or more RCTs corroborated by high-quality registry studies</li> </ul>
<b>Class IIa (Moderate)</b> Benefit >> Risk (&Cost) <ul style="list-style-type: none"> <li>• Device is reasonable</li> <li>• Device can be useful/beneficial/cost-effective</li> </ul>	<b>Level B-R (Randomized)</b> <ul style="list-style-type: none"> <li>• Moderate-quality evidence from 1 or more RCTs</li> <li>• Meta-analyses of moderate-quality RCTs</li> </ul>
<b>Class IIb (Weak)</b> Benefit ≥ Risk (&Cost) <ul style="list-style-type: none"> <li>• Device may/might be useful</li> <li>• Device may/might be considered</li> <li>• Device usefulness/cost-effectiveness is unknown/unclear/uncertain or not well established</li> </ul>	<b>Level B-NR (Nonrandomized)</b> <ul style="list-style-type: none"> <li>• Moderate-quality evidence from 1 or more well-designed, well-executed nonrandomized, observational or registry studies</li> <li>• Meta-analyses of such studies</li> </ul>
<b>Class III: No Benefit (Moderate)</b> Benefit = Risk (&Cost) <ul style="list-style-type: none"> <li>• Device is not recommended</li> <li>• Device is not indicated/useful/beneficial/cost-effective</li> </ul>	<b>Level C-LD (Limited Data)</b> <ul style="list-style-type: none"> <li>• Randomized or nonrandomized observational or registry studies with limitations of design or execution</li> <li>• Meta-analyses of such studies</li> <li>• Physiological or mechanistic studies in human subjects</li> </ul>
<b>Class III: Harm (Strong)</b> Risk > Benefit (&Cost) <ul style="list-style-type: none"> <li>• Device is potentially harmful</li> <li>• Device can cause harm</li> <li>• Device is associated with excess morbidity/mortality</li> </ul>	<b>Level C-EO (Expert Opinion)</b> <ul style="list-style-type: none"> <li>• Consensus of expert opinion based on clinical experience</li> </ul>


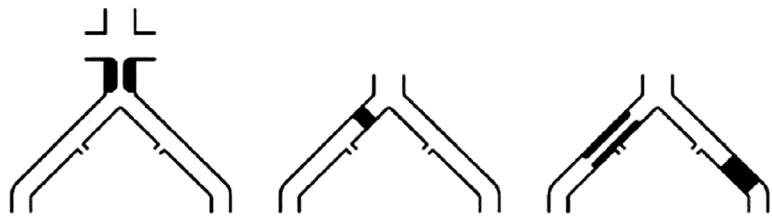

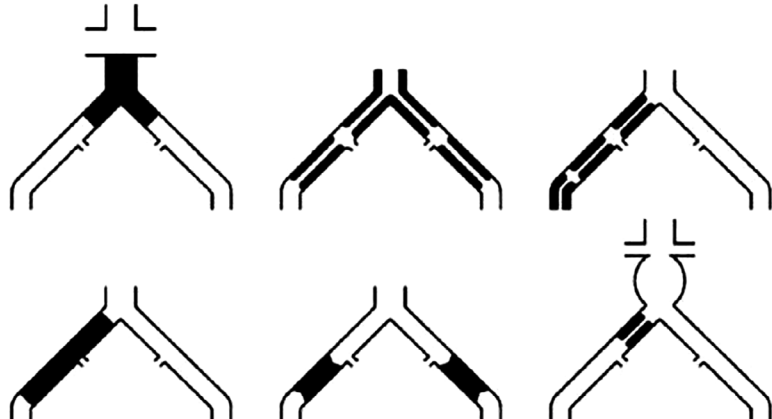
registries, with conventional uncoated balloon PTA frequently being the comparator. For instance, *Class III: No Benefit* recommendation implies that there is no benefit relative to the comparator (eg, conventional uncoated balloon PTA), rather than no benefit at all from the examined category of devices.

- 9 For device scenarios, this document focuses on the devices when utilized as the definitive (Table 3), and not necessarily the final device therapy. BMS may be chosen as the intended definitive treatment with planned pre-dilation with PTA. Uncoated PTA may be chosen as the intended definitive treatment, even if it may be necessary to use “bail-out” stenting to preserve vessel patency.
- 10 The use of adjunctive devices for lesion preparation is not addressed in this document.
- 11 The use of branched and fenestrated stent-grafts (ie, endovascular aneurysm repair devices) is beyond the scope of this document.
- 12 The cost of the devices was considered secondary to examining efficacy and safety data when determining COR/LOE, particularly for devices with limited comparative clinical data that could justify their additional cost.

- 13 Provisional stenting implies PTA with stent placement intended only for “bail-out” (ie, for significant dissection or >50% residual stenosis).
- 14 Primary stenting implies the intention to place a stent regardless of the outcome of any predilation or pretreatment.

#### 4 | CLINICAL OUTCOMES AND ENDPOINTS, ASSESSING THE EFFICACY OF REVASCULARIZATION

The primary goal of Ao-I arterial revascularization is relief of intermittent claudication leading to improvement in functional status and quality of life (QoL), less commonly to relieve the symptoms or signs of critical limb ischemia (CLI), and occasionally to relieve Ao-I obstruction to facilitate placement of large bore devices (eg, intra-aortic balloon pump, percutaneous left ventricular assist device, transcatheter aortic valve replacement, endovascular aortic repair). Claudication symptoms often manifest as exertional limb discomfort in the proximal limb

<p><b>TASC A lesions</b></p> <ul style="list-style-type: none"> <li>• Unilateral or bilateral CIA stenoses</li> <li>• Unilateral or bilateral single short (<math>\leq 3</math> cm) EIA stenosis</li> </ul>	
<p><b>TASC B lesions</b></p> <ul style="list-style-type: none"> <li>• Short (<math>\leq 3</math> cm) stenosis of the infrarenal aorta</li> <li>• Unilateral CIA occlusion</li> <li>• Single or multiple stenosis totaling 3 to 10 cm involving the EIA not extending into the CFA</li> <li>• Unilateral EIA occlusion not involving the origins of the internal iliac or CFA</li> </ul>	
<p><b>TASC C lesions</b></p> <ul style="list-style-type: none"> <li>• Bilateral CIA occlusions</li> <li>• Bilateral EIA stenoses 3 to 10 cm long not extending into the CFA</li> <li>• Unilateral EIA stenosis extending into the CFA</li> <li>• Unilateral EIA occlusion involving the origins of the internal iliac and/or CFA</li> <li>• Heavily calcified unilateral EIA occlusion with or without involvement of the origins of the internal iliac and/or CFA</li> </ul>	
<p><b>TASC D lesions</b></p> <ul style="list-style-type: none"> <li>• Infrarenal aortoiliac occlusion</li> <li>• Diffuse disease involving the aorta and both iliac arteries</li> <li>• Diffuse multiple stenoses involving the unilateral CIA, EIA, and CFA</li> <li>• Unilateral occlusions of both CIA and EIA</li> <li>• Bilateral EIA occlusions</li> <li>• Iliac stenoses in patients with AAA not amenable to endograft placement</li> </ul>	

**FIGURE 2** Inter-society consensus for the management of peripheral arterial disease (TASC) classification of aorto-iliac lesions. AAA, abdominal aortic aneurysm; CFA, common femoral artery; CIA, common iliac artery; EIA, external iliac artery

musculature (ie, buttocks, hips and thighs), suggesting “inflow” arterial obstruction. The desired outcome is to ameliorate the patient’s walking ability or to reduce symptoms so that they are no longer lifestyle limiting with improvement of arterial perfusion as demonstrated by improvement in ankle-brachial index (ABI) following treadmill exercise testing.<sup>6</sup>

The efficacy of revascularization can be gaged using physiologic and anatomic parameters. Physiologic efficacy is examined with exercise testing following revascularization, demonstrating relief of claudication using a standardized protocol and/or by improvement on measures of functional status and QoL (ie, peripheral artery questionnaire). Anatomic

efficacy is most often proven by arterial duplex ultrasonography (DUS) of the treated segment (including segments proximal and distal to the treated segment), given its low risk, cost, and accuracy. However, expert consensus panels are uncertain of the use of serial DUS in asymptomatic patients following Ao-I revascularization.<sup>7</sup>

This consensus document recommends adopting the PARC definitions for acute procedural and technical success of EVT, short- and long-term surrogate endpoints of procedural success (using imaging and physiologic measures), and functional/clinical outcome definitions.<sup>5</sup> In patients with claudication, graded treadmill testing or the standardized 6-min walk test may be used.<sup>8</sup> In this document, when

**TABLE 3** Class of recommendation (COR)<sup>a</sup> and level of evidence (LOE) for device selection as the intended definitive therapy in the aorto-iliac arterial intervention<sup>b</sup> [Color table can be viewed at [wileyonlinelibrary.com](http://wileyonlinelibrary.com)]

	PTA	Specialty balloons	DCB	BMS (Self-expanding)	BMS (Balloon expandable)	Covered stents (Self-expanding)	Covered stents (Balloon expandable)	DES	Atherectomy
<b>Aorto-iliac bifurcation</b>	IIb (weak) B-R	III (no benefit) C-EO	III (no benefit) C-EO	IIa (moderate) B-R	I (strong) B-R	IIb (weak) C-LD	I (strong) B-R	III (no benefit) C-EO	III (harm) C-EO
<b>Focal CIA lesion</b>	IIa (moderate) B-R	III (no benefit) C-EO	III (no benefit) C-EO	IIa (moderate) B-R	I (strong) B-R	IIb (weak) C-LD	I (strong) B-R	III (no benefit) C-EO	III (harm) C-EO
<b>Diffuse CIA lesion</b>	IIb (weak) B-NR	III (no benefit) C-EO	III (no benefit) C-EO	I (strong) B-NR	I (strong) B-NR	IIb (weak) C-LD	I (strong) B-NR	III (no benefit) C-EO	III (harm) C-EO
<b>Focal EIA lesion</b>	IIa (moderate) B-R	III (no benefit) C-EO	III (no benefit) C-EO	I (strong) B-R	IIa (moderate) B-R	IIb (weak) C-LD	IIa (moderate) B-NR	III (no benefit) C-EO	III (harm) C-EO
<b>Diffuse EIA lesion</b>	IIb (weak) B-NR	III (no benefit) C-EO	III (no benefit) C-EO	I (strong) B-NR	IIa (moderate) B-NR	IIa (moderate) C-LD	IIa (moderate) C-LD	III (no benefit) C-EO	III (harm) C-EO
<b>Moderate to severe calcified, focal lesion</b>	IIb (weak) B-NR	III (no benefit) C-LD	III (no benefit) C-EO	IIa (moderate) C-LD	IIa (moderate) C-LD	IIa (moderate) C-LD	I (strong) B-R	III (no benefit) C-EO	III (no benefit) C-EO
<b>Moderate to severe calcified, diffuse lesion</b>	IIb (weak) B-NR	III (no benefit) C-LD	III (no benefit) C-EO	IIa (moderate) B-NR	IIa (moderate) B-NR	IIa (moderate) C-LD	I (strong) C-LD	III (no benefit) C-EO	III (no benefit) C-EO
<b>Chronic total occlusion, focal lesion</b>	IIb (weak) C-LD	III (no benefit) C-EO	III (no benefit) C-EO	IIa (moderate) B-R	IIa (moderate) B-R	IIa (moderate) C-LD	IIa (moderate) B-R	III (no benefit) C-EO	III (harm) C-EO
<b>Chronic total occlusion, diffuse lesion</b>	IIb (weak) C-LD	III (no benefit) C-EO	III (no benefit) C-EO	IIa (moderate) B-R	IIa (moderate) B-NR	IIa (moderate) C-EO	IIa (moderate) B-R	III (no benefit) C-EO	III (harm) C-EO
<b>ISR, focal lesion</b>	IIa (moderate) C-LD	III (no benefit) C-EO	IIb (weak) C-EO	IIb (weak) C-LD	IIb (weak) C-LD	IIa (moderate) C-LD	IIa (moderate) C-LD	III (no benefit) C-EO	III (no benefit) C-EO
<b>ISR, diffuse lesion</b>	IIa (moderate) C-LD	III (no benefit) C-EO	IIb (weak) C-EO	IIb (weak) C-LD	IIb (weak) C-LD	IIa (moderate) C-LD	IIa (moderate) C-LD	III (no benefit) C-EO	III (no benefit) C-EO

BMS = bare metal stent; CFA = common femoral artery; DCB = drug coated balloon  
 DES = drug eluting stent; ISR = in-stent restenosis; PTA = percutaneous transluminal angioplasty; SFA = superficial femoral artery.  
<sup>a</sup>Colors were assigned based on Class of Recommendation.  
<sup>b</sup>Lesion length is defined as focal when ≤4 cm and as diffuse when >4 cm.

Abbreviations: BMS, bare metal stent; CFA, common femoral artery; DCB, drug-coated balloon; DES, drug-eluting stent; ISR, in-stent restenosis; PTA, percutaneous transluminal angioplasty; SFA, superficial femoral artery.

<sup>a</sup>Colors were assigned based on class of recommendation.

<sup>b</sup>Lesion length is defined as focal when ≤4 cm and as diffuse when >4 cm.



evaluating comparative effectiveness, clinical and physiologic outcomes are given greater emphasis than surrogate endpoints (eg, DUS-derived restenosis), which in turn are weighted more heavily than procedural success endpoints. When available, cost effectiveness studies were taken into consideration in the recommendations.

## 5 | DEVICES

### 5.1 | Uncoated balloons for percutaneous transluminal angioplasty (PTA)

PTA therapy in Ao-I arteries includes the use of conventional uncoated balloons. Historically, an “uncoated PTA-first” strategy that reserves stent placement for “bail-out” was the common initial treatment approach. This strategy can still be utilized in simple lesions (ie, TASC A or B lesions) given evidence from RCTs. Uncoated PTA still remains an important adjunctive treatment modality for lesion preparation in primary stenting.

Outcomes of “uncoated PTA-first” strategy have been compared against supervised exercise and best medical therapy in the randomized, multicenter MIMIC (Adjuvant benefit of angioplasty in patients with Mild to Moderate Intermittent Claudication) trial, showing significant improvements in absolute walking distance among patients treated with PTA.<sup>9</sup> A single-center, prospective

registry of 984 consecutive patients has demonstrated that PTA was associated with successful outcomes, particularly in those with claudication due to stenosis of the common iliac artery and good runoff.<sup>10</sup> An analysis of two consecutive periods examined outcomes of PTA versus PTA plus provisional stenting in 250 patients that underwent 287 procedures (94% had either common or external iliac stenoses).<sup>11</sup> Overall, there were no statistically significant differences in the cumulative primary and secondary patency at 4 years. More recently, a strategy of primary stenting for Ao-I disease has been compared to “uncoated PTA-first” plus provisional stenting strategy.<sup>12-14</sup> The Dutch iliac stent trial demonstrated that PTA with provisional stenting (for lesions with a residual gradient of >10 mm Hg after PTA) had similar clinical outcomes to primary stenting at 2 years.<sup>15</sup> However, this trial excluded patients with more complex anatomy (lesion length > 10 cm or CTOs > 5 cm). By employing a provisional stenting strategy in the iliac artery, stent placement was avoided in 63% of lesions, resulting in a more cost-effective strategy. After 5-years of follow-up there were no significant differences in patency rates, ABI, and quality of life metrics.<sup>16</sup> Both strategies appear to provide similar technical success, symptomatic improvement, quality of life and long-term patency for TASC A and B lesions.<sup>17</sup> Based upon comparative data for PTA with uncoated balloons versus other devices (see further sections), recommendations for stand-alone uncoated balloon PTA as the intended definitive therapy in Ao-I disease have been derived (Table 3 and 4).

**TABLE 4** Recommendations for Percutaneous Transluminal Angioplasty with Uncoated Balloons as the Intended Definitive Therapy in the Aorto-Iliac Arterial Interventions [Color table can be viewed at [wileyonlinelibrary.com](http://wileyonlinelibrary.com)]

Uncoated PTA	COR	LOE
1. Aorto-iliac bifurcation	IIb (weak)	B-R
2. Focal CIA lesion	IIa (moderate)	B-R
3. Diffuse CIA lesion	IIb (weak)	B-NR
4. Focal EIA lesion	IIa (moderate)	B-R
5. Diffuse EIA lesion	IIb (weak)	B-NR
6. Moderate to severe calcified, focal lesion	IIb (weak)	B-NR
7. Moderate to severe calcified, diffuse lesion	IIb (weak)	B-NR
8. Chronic total occlusion, focal lesion	IIb (weak)	C-LD
9. Chronic total occlusion, diffuse lesion	IIb (weak)	C-LD
10. ISR, focal lesion	IIa (moderate)	C-LD
11. ISR, diffuse lesion	IIa (moderate)	C-LD

### 5.2 | Specialty balloons for PTA

Specialty balloons have emerged given a potential advantage for treatment of severely calcified and undilatable lesions. In the coronary arteries the occurrence of balloon slippage, a phenomenon known as “watermelon seeding,” has been described in ~10% of patients during treatment of patients with ISR; this phenomenon has also been observed in clinical practice during Ao-I interventions. Design features include balloons with microtomes (peripheral cutting balloon [Boston Scientific, Inc., Marlborough, MA]) and those with external wire or scaffold to permit plaque scoring (ie, Angiosculpt scoring balloon [Royal Philips, Amsterdam, The Netherlands], Chocolate PTA balloon [TriReme Medical, LLC, Pleasanton, CA]). Despite a lack of RCT data and comparative studies, particularly in Ao-I vessels, specialty balloon usage has dramatically increased over time in lower extremity EVT. In the Blue Cross Blue Shield of Michigan Cardiovascular Consortium PVI Registry of 44,650 prospectively enrolled patients, specialty balloon (namely cutting balloon) utilization increased from 1.8% in 2006 to 15.1% in 2013 ( $p_{\text{trend}} < .001$ ).<sup>18</sup> Available outcomes data are observational and focus on immediate technical success and patency. In the setting of iliac ISR, limited data exist regarding outcomes after cutting balloon angioplasty as a primary treatment modality as well as after conventional PTA failure.<sup>19</sup> The use of specialty balloons as adjunctive devices for lesion preparation is not addressed in this document. Consensus recommendations for specialty balloons utilization as the intended definitive therapy in Ao-I disease



**TABLE 5** Recommendations for Percutaneous Transluminal Angioplasty with Specialty Balloons as the Intended Definitive Therapy in the Aorto-Iliac Arterial Interventions [Color table can be viewed at wileyonlinelibrary.com]

Specialty balloons	COR	LOE
1. Aorto-iliac bifurcation	III (no benefit)	C-EO
2. Focal CIA lesion	III (no benefit)	C-EO
3. Diffuse CIA lesion	III (no benefit)	C-EO
4. Focal EIA lesion	III (no benefit)	C-EO
5. Diffuse EIA lesion	III (no benefit)	C-EO
6. Moderate to severe calcified, focal lesion	III (no benefit)	C-LD
7. Moderate to severe calcified, diffuse lesion	III (no benefit)	C-LD
8. Chronic total occlusion, focal lesion	III (no benefit)	C-EO
9. Chronic total occlusion, diffuse lesion	III (no benefit)	C-EO
10. ISR, focal lesion	III (no benefit)	C-EO
11. ISR, diffuse lesion	III (no benefit)	C-EO

have been derived below and are based on absence of comparative effectiveness data and cost (Table 5).

### 5.3 | Bare metal stents (BMS): Balloon expandable stents (BES) and self-expanding stents (SES)

A primary stenting strategy for symptomatic Ao-I disease has been adopted as the preferred clinical practice based on several trials. In the Dutch iliac stent trial, though there was no difference between a primary stent strategy versus PTA with provisional stenting with respect to 5-year patency rates, complex lesions (CTOs > 5 cm and lesions > 10 cm) were excluded.<sup>15</sup> Primary stenting against PTA for iliac lesions ≤8 cm (mean 5.4 cm) was examined in the STents versus AnGioplasty (STAG) trial and showed improved technical success and lower rates of complications with stenting, with similar 2-year patency rates.<sup>14</sup> A meta-analysis of >2,000 patients demonstrated a 43% reduction in 4-year failure with stenting compared to PTA alone.<sup>20</sup>

There are two types of BMS available for Ao-I EVT: balloon expandable (typically composed of stainless steel or cobalt chromium) stents (BES) and self-expanding stents (SES) composed of nitinol or stainless steel. BES can be placed more precisely, may be expanded further post deployment and have greater radial strength.<sup>21</sup> These characteristics may make BES better suited for aorto-ostial common iliac lesions (ie, Ao-I bifurcation kissing stents), calcific lesions, or lesions with greater recoil.<sup>22</sup> However, BES may create artificial vessel straightening due to enhanced shear force, perhaps promoting more

**TABLE 6** Recommendations for Bare Metal Balloon Expandable Stents as the Intended Definitive Therapy in the Aorto-Iliac Arterial Interventions [Color table can be viewed at wileyonlinelibrary.com]

BMS (Balloon expandable stents)	COR	LOE
1. Aorto-iliac bifurcation	I (strong)	B-R
2. Focal CIA lesion	I (strong)	B-R
3. Diffuse CIA lesion	I (strong)	B-NR
4. Focal EIA lesion	IIa (moderate)	B-R
5. Diffuse EIA lesion	IIa (moderate)	B-NR
6. Moderate to severe calcified, focal lesion	IIa (moderate)	B-NR
7. Moderate to severe calcified, diffuse lesion	IIa (moderate)	B-NR
8. Chronic total occlusion, focal lesion	IIa (moderate)	B-R
9. Chronic total occlusion, diffuse lesion	IIa (moderate)	B-NR
10. ISR, focal lesion	IIb (weak)	C-LD
11. ISR, diffuse lesion	IIb (weak)	C-LD

neointimal hyperplasia, especially when used in the EIA.<sup>23</sup> SES are available in longer lengths, are more flexible, conform to varying vessel diameters permitting placement within iliac vessels of various diameters.

Numerous studies have compared BES and SES with varying results.<sup>24-27</sup> A large multicenter retrospective study of 2,147 patients (one-third BES and two-thirds SES) demonstrated similar primary patency rates at 5 years between BES (79%) and SES (75%).<sup>27</sup> Similar results were shown in the Japanese Retrospective Analysis of Aorto-Iliac stenting (REAL-AI) registry.<sup>24</sup> In 190 patients who underwent AI bifurcation stenting between 2005 and 2009, the only predictors of restenosis and need for TLR were female gender and residual diameter stenosis, stent type (BES or SES) did not predict patency. Similar results have been reported from the BRAVISSIMO registry, where stent type was not predictive of 2-year primary patency in 325 patients who underwent Ao-I stenting.<sup>25</sup> Interestingly, only kissing stents configuration and obesity predicted restenosis in this registry.

The Cordis-supported CRISP-US trial compared two SES by randomizing 203 patients with claudication or rest pain to either the Shape Memory Allow Recoverable Technology (SMART) nitinol SES or stainless steel SES (Wallstent) after suboptimal PTA. Acute procedural success was higher in patients assigned to the SMART stent (98.2 vs. 87.5%, respectively), but incidence of the primary composite endpoint (30-day death or 9-month restenosis or target vessel revascularization) was similar (6.9 vs. 5.9%),  $p_{\text{equivalence}} = .04$ .<sup>28</sup>

**TABLE 7** Recommendations for Bare Metal Self-Expanding Stents as the Intended Definitive Therapy in the Aorto-Iliac Arterial Interventions [Color table can be viewed at wileyonlinelibrary.com]

BMS (Self-expanding stents)	COR	LOE
1. Aorto-iliac bifurcation	IIa (moderate)	B-R
2. Focal CIA lesion	IIa (moderate)	B-R
3. Diffuse CIA lesion	I (strong)	B-NR
4. Focal EIA lesion	I (strong)	B-NR
5. Diffuse EIA lesion	I (strong)	B-NR
6. Moderate to severe calcified, focal lesion	IIa (moderate)	B-NR
7. Moderate to severe calcified, diffuse lesion	IIa (moderate)	B-NR
8. Chronic total occlusion, focal lesion	IIa (moderate)	B-R
9. Chronic total occlusion, diffuse lesion	IIa (moderate)	B-R
10. ISR, focal lesion	IIb (weak)	C-LD
11. ISR, diffuse lesion	IIb (weak)	C-LD

The only randomized controlled trial to compare BES and SES is the ICE trial (iliac artery stents for common or external iliac artery occlusive disease).<sup>26</sup> In this trial, 660 patients with CIA or EIA disease and Rutherford class II–IV symptoms were randomized to either BES or SES. Pre-dilation was used in 38% of SES and in 26% of BES implantation and post-dilation was also more common with SES than BES (93 vs. 22%). SES had lower binary restenosis compared to BES (6.1 vs. 14.9%,  $p = .006$ ) and lower rates of TLR (6.9 vs. 3%,  $p = .041$ ) at 12 months. In a multivariable analysis, BES remained a significant predictor of restenosis. A significant interaction was observed with respect to heavy calcification, where SES performed less well in heavily calcified lesions than in those with lesser degrees of calcification; there was no interaction between lesion type (de novo stenosis, restenosis, or occlusion), lesion length or lesion location. No differences were observed for walking impairment and no difference in the rates of death or amputation were observed between devices. Regardless of type of stent, the excellent 1-year patency rates of both groups (93.6% for BES and 97.2% for SES) highlight that endovascular revascularization with BMS should be considered as first-line for most Ao-I lesions.

Recommendations for BES and SES in Ao-I ISR lesions are primarily based on limited data from small retrospective studies and expert consensus. In a retrospective study of 41 lesions (in 24 patients) with Ao-I ISR treated with an uncoated balloon PTA in all patients, adjunctive stenting was performed in 66% of the lesions.<sup>29</sup> The 6- and

**TABLE 8** Recommendations for Drug-Eluting Stents as the Intended Definitive Therapy in the Aorto-Iliac Arterial Interventions [Color table can be viewed at wileyonlinelibrary.com]

Drug-eluting stents	COR	LOE
1. Aorto-iliac bifurcation	III (no benefit)	C-EO
2. Focal CIA lesion	III (no benefit)	C-EO
3. Diffuse CIA lesion	III (no benefit)	C-EO
4. Focal EIA lesion	III (no benefit)	C-EO
5. Diffuse EIA lesion	III (no benefit)	C-EO
6. Moderate to severe calcified, focal lesion	III (no benefit)	C-EO
7. Moderate to severe calcified, diffuse lesion	III (no benefit)	C-EO
8. Chronic total occlusion, focal lesion	III (no benefit)	C-EO
9. Chronic total occlusion, diffuse lesion	III (no benefit)	C-EO
10. ISR, focal lesion	III (no benefit)	C-EO
11. ISR, diffuse lesion	III (no benefit)	C-EO

12-month primary patency rates were 96% and 82%, respectively. Consensus recommendations for BES and SES in Ao-I lesions are listed below (Table 6 and 7).

## 5.4 | Drug-eluting stents (DES)

DES could theoretically have benefit in the treatment of symptomatic Ao-I occlusive disease; however, currently available devices have not been systematically studied in iliac artery occlusive disease. Limited sizes of DES are available for iliac arteries, with the largest available DES in US to date being 8.0 mm in diameter. DES have shown improved patency and reduction in TLR compared to uncoated balloon angioplasty or BMS implantation in FP lesions.<sup>30,31</sup> One small study examining Eluvia DES implantation in the external iliac and FP arteries reported 6-month primary patency and freedom from TLR of 92%.<sup>32</sup> Given the findings of a recent meta-analysis<sup>33</sup> and concerns about late mortality with paclitaxel-eluting technologies, consideration should be given regarding the risks and benefits of DES (or DCB) prior to their use in Ao-I arteries.<sup>34</sup> Potential risks of late mortality and benefits of reduced restenosis should be discussed with patients.

**TABLE 9** Recommendations for Drug Coated Balloons as the Intended Definitive Therapy in the Aorto-Iliac Arterial Interventions [Color table can be viewed at wileyonlinelibrary.com]

Drug coated balloons	COR	LOE
1. Aorto-iliac bifurcation	III (no benefit)	C-EO
2. Focal CIA lesion	III (no benefit)	C-EO
3. Diffuse CIA lesion	III (no benefit)	C-EO
4. Focal EIA lesion	III (no benefit)	C-EO
5. Diffuse EIA lesion	III (no benefit)	C-EO
6. Moderate to severe calcified, focal lesion	III (no benefit)	C-EO
7. Moderate to severe calcified, diffuse lesion	III (no benefit)	C-EO
8. Chronic total occlusion, focal lesion	III (no benefit)	C-EO
9. Chronic total occlusion, diffuse lesion	III (no benefit)	C-EO
10. ISR, focal lesion	IIb (weak)	C-EO
11. ISR, diffuse lesion	IIb (weak)	C-EO

Furthermore, clinicians should perform diligent monitoring of patients who have been treated with DES or DCB devices (Table 8).

### 5.5 | Drug-coated balloons (DCB)

Similar to DES, there are no randomized or prospective studies that have evaluated the role of DCB for the treatment of Ao-I disease. Theoretically, these devices may have a role for Ao-I in-stent restenosis or occlusion. However, given the lack of safety and efficacy data addressing the use of DCBs in Ao-I segment, and extensive long-term data in support of BMS or covered stents, DCB use should be very limited at this time. Furthermore, limited sizes of DCBs are available for iliac arteries, with the largest available DCB in US to date being 7.0 mm in diameter. If DCB are to be used, FDA recommendations should be taken into consideration (as discussed in Section 4.3.1)<sup>34</sup> (Table 9).

### 5.6 | Covered (endovascular grafts) stents: Balloon expandable and self-expanding

Covered stents comprise a metallic scaffold lined with polytetrafluoroethylene (PTFE) or Dacron material. These stents are used

**TABLE 10** Recommendations for Covered Balloon Expandable Stents as the Intended Definitive Therapy in the Aorto-Iliac Arterial Interventions [Color table can be viewed at wileyonlinelibrary.com]

Covered stents (balloon expandable stents)	COR	LOE
1. Aorto-iliac bifurcation	I (strong)	B-R
2. Focal CIA lesion	I (strong)	B-R
3. Diffuse CIA lesion	I (strong)	B-NR
4. Focal EIA lesion	IIa (moderate)	B-NR
5. Diffuse EIA lesion	IIa (moderate)	C-LD
6. Moderate to severe calcified, focal lesion	I (strong)	B-R
7. Moderate to severe calcified, diffuse lesion	I (strong)	C-LD
8. Chronic total occlusion, focal lesion	IIa (moderate)	B-R
9. Chronic total occlusion, diffuse lesion	IIa (moderate)	B-R
10. ISR, focal lesion	IIa (moderate)	C-LD
11. ISR, diffuse lesion	IIa (moderate)	C-LD

during percutaneous Ao-I artery revascularization either as an endovascular prosthesis for treatment of atherosclerotic disease or for bailout treatment of arterial perforation, exclusion of thrombus, and exclusion of aneurysms. By excluding underlying plaque from the lumen, covered stents limit encroachment of the arterial lumen by neointimal hyperplasia and thereby potentially reduce restenosis compared with uncovered BMS. Covered stents are commonly used in the treatment of calcified or ectatic common iliac vessels, where they may provide a safety margin due to risk of arterial rupture. There are two types of covered stents for Ao-I interventions: balloon expandable and self-expanding. Similar to uncovered BES and SES, covered BES provide greater radial strength and allow precise stent placement, whereas covered SES offer greater flexibility. Covered stents can migrate, thrombose, develop edge restenosis, result in loss of side branches (ie, internal iliac artery), and may require longer treatment with antiplatelet agents. In contemporary US clinical practice four types of covered stents are available: the iCAST™ (Atrium Medical Corp, Hudson, NH), VBX Stent Graft (W.L. Gore & Associates, Inc, Flagstaff, AZ), Viabahn® endoprosthesis (W.L. Gore & Associates, Inc, Flagstaff, AZ) and Lifestream stent (Bard, Tempe, AZ).

The iCAST™ is a balloon-expandable stent with an inner and an outer layer of PTFE material. It is FDA approved for treatment of tracheobronchial structures, however, it is frequently used off-label during endovascular Ao-I artery revascularization. This off-label use is supported

**TABLE 11** Recommendations for Covered Self-Expanding Stents as the Intended Definitive Therapy in the Aorto-Iliac Arterial Interventions [Color table can be viewed at [wileyonlinelibrary.com](http://wileyonlinelibrary.com)]

Covered stents (self-expanding stents)	COR	LOE
1. Aorto-iliac bifurcation	IIb (weak)	C-LD
2. Focal CIA lesion	IIb (weak)	C-LD
3. Diffuse CIA lesion	IIb (weak)	C-LD
4. Focal EIA lesion	IIb (weak)	C-LD
5. Diffuse EIA lesion	IIa (moderate)	C-LD
6. Moderate to severe calcified, focal lesion	IIa (moderate)	C-LD
7. Moderate to severe calcified, diffuse lesion	IIa (moderate)	C-LD
8. Chronic total occlusion, focal lesion	IIa (moderate)	C-LD
9. Chronic total occlusion, diffuse lesion	IIa (moderate)	C-EO
10. ISR, focal lesion	IIa (moderate)	C-LD
11. ISR, diffuse lesion	IIa (moderate)	C-LD

by the Covered Versus Balloon-Expandable Stent Trial (COBEST); the only published multicenter randomized clinical trial utilizing covered stents.<sup>35</sup> The trial included 168 TASC B to D lesions in 125 participants randomized to either iCAST stent versus uncovered balloon-expandable BMS. Lesions treated with a covered stent were significantly more likely to remain free from binary restenosis at 18 months (HR: 0.35,  $p < .02$ ). Post hoc subgroup analysis demonstrated a significantly lower binary restenosis in TASC C and D lesions with covered stents versus BMS (HR: 0.14, 95% CI 0.04–0.44), however, there was no difference for TASC B lesions (HR: 0.75, 95% CI 0.24–2.39). Most re-interventions occurred between 12–18 months, with fewer in the covered stent group. The improved patency with the iCAST stent was sustained at 5 years.<sup>36</sup> Observational evidence comparing the iCAST stent to a group of balloon-expandable BMS found significantly better primary, assisted and secondary patency with BMS; the TASC classification did not predict reintervention.<sup>37</sup> Dual antiplatelet therapy was predictive of long-term patency on multivariate analysis. The use of multiple iCAST stents has also been described for treatment of complex Ao-I bifurcations using a technique termed CERAB (covered endovascular reconstruction of the aortic bifurcation).<sup>38</sup>

The VBX Stent Graft, balloon expandable covered stent, was FDA approved in 2017 for the treatment of de novo or restenotic Ao-I lesions, including Ao-I bifurcation. This stent consists of

**TABLE 12** Recommendations for Atherectomy as the Intended Definitive Therapy in the Aorto-Iliac Arterial Interventions [Color table can be viewed at [wileyonlinelibrary.com](http://wileyonlinelibrary.com)]

Atherectomy	COR	LOE
1. Aorto-iliac bifurcation	III (harm)	C-EO
2. Focal CIA lesion	III (harm)	C-EO
3. Diffuse CIA lesion	III (harm)	C-EO
4. Focal EIA lesion	III (harm)	C-EO
5. Diffuse EIA lesion	III (harm)	C-EO
6. Moderate to severe calcified, focal lesion	III (no benefit)	C-EO
7. Moderate to severe calcified, diffuse lesion	III (no benefit)	C-EO
8. Chronic total occlusion, focal lesion	III (harm)	C-EO
9. Chronic total occlusion, diffuse lesion	III (harm)	C-EO
10. ISR, focal lesion	III (no benefit)	C-EO
11. ISR, diffuse lesion	III (no benefit)	C-EO

discrete stainless steel rings that are fully encapsulated in fluoropolymer and coated with heparin. In the first-in-man study 30 symptomatic patients were enrolled in a single arm prospective single center study.<sup>39</sup> The primary safety endpoint, a composite of device or procedure-related death, MI, or amputation in the treated leg within 30 days of the procedure was 0%. Primary patency, freedom from TLR, and freedom from TVR were 100% at 1 and 6 months and 96.6% at 12 months. The VBX Flex multicenter single arm study results (134 patients, 213 iliac lesions) affirm 100% technical success and 97% 9-month patency with this stent in “real-world” iliac artery lesions involving tortuosity, severe calcification, total occlusion, and direct stenting and/or kissing stent treatment at the Ao-I bifurcation.<sup>40</sup> In TASC C and D lesions, that comprised over a third of cases, 9-month patency was 95%.

The Viabahn endoprosthesis is a self-expanding stent with nitinol support extending along its entire length and an expanded PTFE lining. It is highly flexible and FDA approved for the treatment of patients with symptomatic iliac artery lesions. There are no randomized trials comparing the efficacy and safety of the Viabahn endoprosthesis to other covered or balloon-expandable stents in the iliac artery. A prospective study of 61 iliac arteries reported primary patency rate of 98% at 6 months and 91% at 12 months.<sup>41</sup> Two cases of embolization of the endoprosthesis to distal arteries were observed in the study. The Viabahn stents in EIA have been used in combination with iCAST or other balloon expandable stents in the aorta and common iliac

segments to treat complex Ao-I occlusive disease involving EIAs. A recent retrospective study of Ao-I cases observed similar mid-term patency with the Viabahn and balloon expandable BMS.<sup>42</sup> The Viabahn stent performed better in TASC D lesions, occlusive lesions with a total lesion length > 6 cm, occlusion length > 3.5 cm and in heavily calcified lesions.

The Lifestream balloon expandable covered stent is the most recently US approved iliac stent. The results of a multicenter single arm trial of 155 patients, balloon expandable vascular covered stent in the treatment of iliac artery occlusive disease (BOLSTER), evaluated the performance of this stainless steel stent encapsulated between two stretched PTFE layers.<sup>43</sup> At 9 months, primary patency was 89.1% and freedom from TLR was 96.1% by Kaplan–Meier estimate. These results were accompanied by improvements in Rutherford category from baseline and QoL scores.

Overall, there is limited high-quality comparative evidence for the routine use of covered stents in the Ao-I artery distribution. A meta-analysis of covered stents in Ao-I and FP arteries concluded that primary patency was improved with the covered stents in the FP distribution, but not Ao-I.<sup>44</sup> Currently, covered stents are selectively used to treat iliac artery perforations and excluding thrombus or arterial aneurysms. However, there are data to support the clinical efficacy of covered stents, especially balloon expandable, in treatment of TASC C and D Ao-I artery lesions. Consensus recommendations for covered BES and SES in Ao-I lesions are listed below (Table 10 and 11).

## 5.7 | Atherectomy

While use of many devices including directional atherectomy and laser atherectomy has been reported in the treatment of Ao-I disease, rotational atherectomy is the only treatment modality with available data. The CONFIRM I, II, and III registries prospectively enrolled 3,135 patients with PAD in different segments and 4,766 lesions at over 200 U.S. centers. Demographic data, lesion characteristics, and procedure outcomes for the CONFIRM patients with at least one iliac artery lesion treated with orbital atherectomy (62 patients; 68 lesions) were compared to patients with at least one SFA lesion treated with orbital atherectomy (1,570 patients; 1,809 lesions).<sup>45</sup> The procedural complication rates, defined as the composite of flow limiting dissection, perforation, slow flow, vessel closure, spasm, embolism, or thrombosis, were compared in iliac lesions versus SFA lesions. The iliac group had one reported perforation and one reported vessel closure; the rates of slow flow, spasm, embolism, thrombus, and flow limiting dissection were 0%. The overall procedural complication rate was significantly lower in the iliac group (2.9 vs. 11.2%,  $p = .03$ ). Potential risks of different atherectomy devices in Ao-I location include distal embolization, dissection and perforation; in Ao-I ISR lesions atherectomy devices can lead to stent strut damage and excision of stent fragments. Further data regarding adjunctive use of atherectomy devices in Ao-I locations are needed (Table 12).

## 5.8 | Adjunctive therapies

In addition to atherectomy, alternate approaches for lesion preparation of the Ao-I arteries have been investigated. Notably, cryoplasty and intravascular lithotripsy have been FDA approved for angioplasty and treatment of calcified arteries in 2002 and 2018, respectively. Initial experience with cryoplasty in the FP arteries suggested modest success with respect to early patency, however, longer term follow-up demonstrated no benefit compared to conventional PTA.<sup>46–49</sup> Subsequent studies confirmed this lack of benefit, and thus cryoplasty has been largely abandoned for adjunctive treatment in the Ao-I and FP segments.

Intravascular lithotripsy (Shockwave Medical, Santa Clara, CA) functions by incorporating lithotripsy emitters within an angioplasty balloon, such that sonic pressure waves drive through surrounding tissue selectively fracturing vascular calcium within the vessel wall, thus purportedly altering vessel compliance and permitting vessel dilatation at relatively low pressures. Early studies with intravascular lithotripsy have demonstrated feasibility for the management of severely calcified arterial stenoses in coronary and peripheral arteries.<sup>50–54</sup> With respect to Ao-I artery revascularization, several case reports have demonstrated potential value in the management of Ao-I occlusive disease,<sup>55</sup> particularly when large bore catheter access is required,<sup>56</sup> however, RCTs for an Ao-I application are yet to be performed.

## 6 | FUTURE RESEARCH DIRECTIONS

Ao-I endovascular intervention has evolved rapidly over the past several decades. Early sources of complications (ie, perforations) have been addressed with novel lesion preparation approaches and covered stent grafts. However, there remain numerous challenges to the management of this lesion subset. The development of integrated Ao-I prostheses for occlusive disease continues to expand our options for treating these complex patients. Moreover, alternate, “small bore” approaches to treating Ao-I occlusive disease continue to evolve. In addition, while drug-eluting technologies have emerged as clearly superior in terms of preventing restenosis in other vascular territories, the development of DES or DCB for Ao-I indications remains an unmet need. Large RCTs and post-market registries for both coronary and FP applications of intravascular lithotripsy are currently ongoing. Long-term data on lithotripsy in Ao-I lesions are needed. Comparative effectiveness trials are needed to provide the only scientifically valid approach to identify the relative value of these techniques.

## 7 | CONCLUSION

The SCAI writing committee conducted a comprehensive, systematic review and analysis of the scientific evidence and developed concise, focused, unbiased device-specific recommendations for Ao-I EVT.



These recommendations are designed to assist clinicians with relevant anatomical scenarios and to guide device selection in Ao-I location based on strength and quality of evidence for comparative effectiveness, durability and expert opinion.

## ACKNOWLEDGMENT

Muhammad Shahzeb Khan, MD, MS, Shahul Valavoor, MD and Swapna Talluri, MD for their contribution to conducting literature search and data abstraction.

## ORCID

Ehrin J. Armstrong  <https://orcid.org/0000-0002-5682-8363>

Safi U. Khan  <https://orcid.org/0000-0003-1559-6911>

Mehdi H. Shishehbor  <https://orcid.org/0000-0002-4888-2431>

Christopher J. White  <https://orcid.org/0000-0001-8618-7539>

## REFERENCES

- Klein AJ, Jaff MR, Gray BH, et al. SCAI appropriate use criteria for peripheral arterial interventions: an update. *Catheter Cardiovasc Interv.* 2017;90:E90-E110.
- Bailey SR, Beckman JA, Dao TD, Misra S, Sobieszczyk PS, White CJ. ACC/AHA/SCAI/SIR/SVM 2018 appropriate use criteria for peripheral artery intervention: a report of the American College of Cardiology Appropriate Use Criteria Task Force, American Heart Association, Society for Cardiovascular Angiography and Interventions, Society of Interventional Radiology, and Society for Vascular Medicine. *J Am Coll Cardiol.* 2019;73:214-237.
- Feldman DN, Armstrong EJ, Aronow HD, et al. SCAI consensus guidelines for device selection in femoral-popliteal arterial interventions. *Catheter Cardiovasc Interv.* 2018;92:124-140.
- Jaff MR, White CJ, Hiatt WR, et al. An update on methods for revascularization and expansion of the TASC lesion classification to include below-the-knee arteries: a supplement to the inter-society consensus for the management of peripheral arterial disease (TASC II): the TASC steering committee. *Catheter Cardiovasc Interv.* 2015;86:611-625.
- Patel MR, Conte MS, Cutlip DE, et al. Evaluation and treatment of patients with lower extremity peripheral artery disease: consensus definitions from Peripheral Academic Research Consortium (PARC). *J Am Coll Cardiol.* 2015;65:931-941.
- Aboyans V, Criqui MH, Abraham P, et al. Measurement and interpretation of the ankle-brachial index: a scientific statement from the American Heart Association. *Circulation.* 2012;126:2890-2899.
- Mohler ER III, Gornik HL, Gerhard-Herman M, Misra S, Olin JW, Zierler RE. ACCF/ACR/AIUM/ASE/ASN/ICAVL/SCAI/SCCT/SIR/SVM/SVS 2012 appropriate use criteria for peripheral vascular ultrasound and physiologic testing part 1: arterial ultrasound and physiologic testing. *J Am Coll Cardiol.* 2012;60:242-276.
- FernDermott MM, Guralnik JM, Criqui MH, Liu K, Kibbe MR, Ferrucci L. Six-minute walk is a better outcome measure than treadmill walking tests in therapeutic trials of patients with peripheral artery disease. *Circulation.* 2014;130:61-68.
- Greenhalgh RM, Belch JJ, Brown LC, et al. The adjuvant benefit of angioplasty in patients with mild to moderate intermittent claudication (MIMIC) managed by supervised exercise, smoking cessation advice and best medical therapy: results from two randomized trials for stenotic femoropopliteal and aortoiliac arterial disease. *Eur J Vasc Endovasc Surg.* 2008;36(6):680-688.
- Johnston KW, Rae M, Hogg-Johnston SA, et al. 5-year results of a prospective study of percutaneous transluminal angioplasty. *Ann Surg.* 1987;206(4):403-413.
- Hassen-Khodja R, Sala F, Declémy SI, Bouillanne PJ, Batt M, Staccini P. Value of stent placement during percutaneous transluminal angioplasty of the iliac arteries. *J Cardiovasc Surg (Torino).* 2001;42(3):369-374.
- Blankensteijn JD, van Vroonhoven TJ, Lampmann L. Role of percutaneous transluminal angioplasty in aorto-iliac reconstruction. *J Cardiovasc Surg.* 1986;27:466-468.
- Colapinto RF, Stronell RD, Johnston WK. Transluminal angioplasty of complete iliac obstructions. *AJR Am J Roentgenol.* 1986;146:859-862.
- Goode SD, Cleveland TJ, Gaines PA, STAG Trial Collaborators. Randomized clinical trial of stents versus angioplasty for the treatment of iliac artery occlusions (STAG trial). *Br J Surg.* 2013;100:1148-1153.
- Tetteroo E, van der Graaf Y, Bosch JL, et al. Randomised comparison of primary stent placement versus primary angioplasty followed by selective stent placement in patients with iliacartery occlusive disease. Dutch Iliac Stent Trial Study Group. *Lancet.* 1998;351:1153-1159.
- Klein WM, van der Graaf Y, Seegers J, et al. Dutch iliac stent trial. Long term results in patients randomized for primary or selective stent placement. *Radiology.* 2006;238:734-744.
- Bekken J, Jongsma H, Ayez N, Hoogewerf CJ, Van Well V, Fioule B. Angioplasty versus stenting for iliac artery lesions. *Cochrane Database Syst Rev.* 2015;5:CD007561.
- Thomas MP, Park YJ, Grey S, et al. Temporal trends in peripheral arterial interventions: observations from the blue cross blue shield of Michigan cardiovascular consortium (BMC2 PVI). *Catheter Cardiovasc Interv.* 2017;89(4):728-734.
- Tsetis D, Belli AM, Morgan R, et al. Preliminary experience with cutting balloon angioplasty for iliac artery in-stent restenosis. *J Endovasc Ther.* 2008;15:193-202.
- Bosch JL, Hunink MG. Meta-analysis of the results of percutaneous transluminal angioplasty and stent placement for aortoiliac occlusive disease. *Radiology.* 1997;204:87-96.
- Klein AJ, Feldman DN, Aronow HD, et al. SCAI expert consensus statement for aorto-iliac arterial intervention appropriate use. *Catheter Cardiovasc Interv.* 2014;84:520-528.
- Dyet JF, Watts WG, Ettles DF, Nicholson AA. Mechanical properties of metallic stents: how do these properties influence the choice of stent for specific lesions? *Cardiovasc Intervent Radiol.* 2000;23:47-54.
- Feldman DN, Klein AJP. Stent selection in the iliac arteries: don't fall through the ICE! *JACC Cardiovasc Interv.* 2017;10:1705-1707.
- Aihara H, Soga Y, Iida O, et al. Long-term outcomes of endovascular therapy for aortoiliac bifurcation lesions in the real-AI registry. *J Endovasc Ther.* 2014;21:25-33.
- de Donato G, Bosiers M, Setacci F, et al. 24-month data from the BRAVISSIMO: a large-scale prospective registry on iliac stenting for TASC A & B and TASC C & D Lesions. *Ann Vasc Surg.* 2015;29:738-750.
- KrankenberG H, Zeller T, Ingwersen M, et al. Self-expanding versus balloon-expandable stents for iliac artery occlusive disease the randomized ICE trial (iliac artery stents for common or external iliac artery occlusive disease). *JACC Cardiovasc Interv.* 2017;10:1694-1704.
- Soga Y, Iida O, Kawasaki D, et al. Contemporary outcomes after endovascular treatment for aorto-iliac artery disease. *Circ J.* 2012;76:2697-2704.
- Ponec D, Jaff MR, Swischuk J, et al. The nitinol SMART stent vs Wallstent for suboptimal iliac artery angioplasty: CRISP-US trial results. *J Vasc Interv Radiol.* 2004;15:911-918.
- Javed U, Balwanz CR, Armstrong EJ, et al. Mid-term outcomes following endovascular re-intervention for iliac artery in-stent restenosis. *Catheter Cardiovasc Interv.* 2013;82:1176-1184.



30. Dake MD, Ansel GM, Jaff MR, et al. Paclitaxel-eluting stents show superiority to balloon angioplasty and bare metal stents in femoropopliteal disease: twelve-month Zilver PTX randomized study results. *Circ Cardiovasc Interv.* 2011;4:495-504.
31. Gray WA, Keirse K, Soga Y, et al. A polymer-coated, paclitaxel-eluting stent (Eluvia) versus a polymer-free, paclitaxel-coated stent (Zilver PTX) for endovascular femoropopliteal intervention (IMPERIAL): a randomized, non-inferiority trial. *Lancet.* 2018;392:1541-1551.
32. Elens M, Verhelst R, Possoz J, Mastrobuoni S, Lacroix V, Astarci P. Short-term results of eluvia paclitaxel-eluting stent in external iliac and femoropopliteal lesions. *Surg Technol Int.* 2017;31:162-167.
33. Katsanos K, Spiliopoulos S, Kitrou P, Krokidis M, Karnabatidis D. Risk of death following application of paclitaxel-coated balloons and stents in the femoropopliteal artery of the leg: a systematic review and meta-analysis of randomized controlled trials. *J Am Heart Assoc.* 2018;7:e011245.
34. *Treatment of peripheral arterial disease with Paclitaxel-coated balloons and paclitaxel-eluting stents potentially associated with increased mortality - letter to health care providers* [Internet]. U.S. Food and Drug Administration; August 2019 [cited August 27, 2019]. <https://www.fda.gov/medical-devices/letters-health-care-providers/august-7-2019-update-treatment-peripheral-arterial-disease-paclitaxel-coated-balloons-and-paclitaxel>.
35. Mwiapatayi BP, Thomas S, Wong J, et al. A comparison of covered vs bare expandable stents for the treatment of aortoiliac occlusive disease. *J Vasc Surg.* 2011;54(6):1561-1570.
36. Mwiapatayi BP, Sharma S, Daneshmand A, et al. Durability of the balloon-expandable covered versus bare-metal stents in the covered versus balloon expandable stent Trial (COBEST) for the treatment of aortoiliac occlusive disease. *J Vasc Surg.* 2016;64(1):83-94.e1.
37. Humphries MD, Armstrong E, Laird J, Paz J, Pevco W. Outcomes of covered versus bare-metal balloon-expandable stents for aortoiliac occlusive disease. *J Vasc Surg.* 2014;60(2):337-343.
38. Taeymans K, Groot Jebbink E, Holewijn S, et al. Three-year outcome of the covered endovascular reconstruction of the aortic bifurcation technique for aortoiliac occlusive disease. *J Vasc Surg.* 2018;67(5):1438-1447.
39. Holden A, Merrilees S, Buckley B, Connor B, Colgan F, Hill A. First-in-human experience with the Gore balloon-expandable covered Endoprosthesis in iliac artery occlusive disease. *J Endovasc Ther.* 2017;24(1):11-18.
40. Bismuth J, Gray BH, Holden A, Metzger C, Panneton J, VBX FLEX Study Investigators. Pivotal study of a next-generation balloon-expandable stent-graft for treatment of iliac occlusive disease. *J Endovasc Ther.* 2017;24(5):629-637.
41. Lammer J, Dake MD, Bleyen J, et al. Peripheral arterial obstruction: prospective study of treatment with a transluminally placed self-expanding stent-graft. *Int Trial Study Group Radiol.* 2000;217(1):95-104.
42. Piazza M, Squizzato F, Dall'Antonia A, et al. Editor's choice - outcomes of self expanding PTFE covered stent versus bare metal stent for chronic iliac artery occlusion in matched cohorts using propensity score modelling. *Eur J Vasc Endovasc Surg.* 2017;54(2):177-185.
43. Laird JR, Zeller T, Holden A, et al. Balloon-expandable vascular covered stent in the treatment of iliac artery occlusive disease: 9-month results from the BOLSTER multicenter study. *J Vasc Interv Radiol.* 2019;30(6):836-844.e1.
44. Hajibandeh S, Hajibandeh S, Antoniou SA, Torella F, Antoniou GA. Covered vs uncovered stents for aortoiliac and femoropopliteal arterial disease: a systematic review and meta-analysis. *J Endovasc Ther.* 2016;23(3):442-452.
45. Lee MS, Martinsen BJ. Acute procedural outcomes of orbital atherectomy for the treatment of iliac artery disease: sub-analysis of the CONFIRM registries. *Cardiovasc Revasc med.* 2018;19:503-505.
46. Fava M, Loyola S, Polydorou A, et al. Cryoplasty for femoropopliteal arterial disease: late angiographic results of initial human experience. *J Vasc Interv Radiol.* 2004;15:1239-1243.
47. Laird J, Jaff MR, Biamino G, et al. Cryoplasty for the treatment of femoropopliteal arterial disease: results of a prospective, multicenter registry. *J Vasc Interv Radiol.* 2005;16:1067-1073.
48. Laird JR, Biamino G, McNamara T, et al. Cryoplasty for the treatment of femoropopliteal arterial disease: extended follow-up results. *J Endovasc Ther.* 2006;13(Suppl 2):II52-II59.
49. McCaslin JE, Andras A, Stansby G. Cryoplasty for peripheral arterial disease. *Cochrane Database Syst Rev.* 2013;8:CD005507.
50. Aksoy A, Salazar C, Becher MU, et al. Intravascular lithotripsy in calcified coronary lesions: a prospective, observational, multicenter registry. *Circ Cardiovasc Interv.* 2019;12:e008154.
51. Brinton TJ, Ali ZA, Hill JM, et al. Feasibility of shockwave coronary intravascular lithotripsy for the treatment of calcified coronary stenoses. *Circulation.* 2019;139:834-836.
52. Ali ZA, Nef H, Escaned J, et al. Safety and effectiveness of coronary intravascular lithotripsy for treatment of severely calcified coronary stenoses: the disrupt CAD II study. *Circ Cardiovasc Interv.* 2019;12:e008434.
53. Brodmann M, Werner M, Holden A, et al. Primary outcomes and mechanism of action of intravascular lithotripsy in calcified, femoropopliteal lesions: results of disrupt PAD II. *Catheter Cardiovasc Interv.* 2019;93:335-342.
54. Brodmann M, Holden A, Zeller T. Safety and feasibility of intravascular lithotripsy for treatment of below-the-knee arterial stenoses. *J Endovasc Ther.* 2018;25:499-503.
55. Radaideh Q, Shammass NW, Shammass GA, Shammass J. Safety and efficacy of lithoplasty in treating severely calcified iliac arterial disease: a single center experience. *Vasc. Dis. Manag.* 2019;16:E76-E78.
56. Ristalli F, Dini CS, Stolcova M, et al. Role of lithotripsy for small calcified iliacs in the era of big devices. *Curr Cardiol Rep.* 2019;21:143.

## SUPPORTING INFORMATION

Additional supporting information may be found online in the Supporting Information section at the end of this article.

**How to cite this article:** Feldman DN, Armstrong EJ, Aronow HD, et al. SCAI guidelines on device selection in Aorto-Iliac arterial interventions. *Catheter Cardiovasc Interv.* 2020;96:915–929. <https://doi.org/10.1002/ccd.28947>