

Surgically Facilitated Orthodontic Therapy (SFOT): Diagnosis and Indications in Interdisciplinary Dentofacial Therapy Involving Tooth Movement

George A. Mandelaris,^{*†‡} Iwei Huang,[§] Robert Relle,^{||¶} Brian S. Vence[#] and Bradley S. DeGroot^{*}

Focused Clinical Question: What are the key considerations for the interdisciplinary dentofacial therapy (IDT) team in the diagnostic process to evaluate a patient for surgically facilitated orthodontic therapy (SFOT)?

Summary: SFOT creates a demineralized bone matrix and augments dentoalveolar deficiencies in the management of dentofacial disharmony malocclusion. Numerous indications and contraindications exist which are essential to the periodontal surgeon for proper case selection. A collaboratively focused workup by an IDT team is equally essential. Cone beam computed tomography (CBCT) and orthodontic simulation software which identifies changes in the dentoalveolar complex influenced by tooth movement are critical in providing transparency to the patient and IDT team during the treatment planning process. Such transparency can aid the team in assessing goals and outcomes that consider and respect foundational dentoalveolar parameters while contributing to sustainable outcomes.

Conclusions: The SFOT IDT decision making process is complex, yet full of opportunities. Embracing SFOT IDT with innovative and novel 3D technology can optimize conditions leading to long-term outcomes that align with periodontal stability as well as patient goals and preferences which permeate beyond the achievement of “straightening teeth”. Transparency of complex IDT through 3D CBCT and orthodontic simulation software engenders “collaborative accountability” and can improve patient communication which is critical to developing meaningful and essential treatment plans. *Clin Adv Periodontics* 2020;10:204–212.

Key Words: Cone beam computed tomography; diagnosis; interdisciplinary dentofacial therapy; orthodontics; orthognathic surgery; surgically facilitated orthodontic therapy.

Background

Surgically facilitated orthodontic therapy (SFOT) (i.e., periodontally accelerated osteogenic orthodontics [PAOO] and/or corticotomy-assisted orthodontics [CAO]) is most identified with Wilcko et al. who described

the physiologic response to corticotomy surgery as a coupled demineralization-rem mineralization post-surgical bone matrix phenomena.¹ Recently, systematic and other reviews have reported a consistent track record of safety and confirmed the acceleration of tooth movement.²⁻⁵ In addition, expanded opportunities afforded by SFOT have been published for the profession to consider as a part of a broader context of interdisciplinary dentofacial therapy (IDT).⁶ Mandelaris and DeGroot (2019) have summarized SFOT techniques and provided clinical guidance in the interdisciplinary setting.⁷ The impact of cone beam computed tomography (CBCT) on regional anatomy understanding and subsequent treatment possibilities to manage diagnoses is a paradigm shift to conventional thinking. Most notably in this call for change is the well-published understanding that facial bone thickness in the human skeleton is, on average, <1mm⁸⁻¹² and that ≈66% to 75% of adult patients have some level of malocclusion.¹³

SFOT can optimize dentoalveolar and alveoloskeletal relationships in patients with dental and/or skeletal malocclusions. Dentoalveolar refers to the alveolar bone volume in relation to the tooth root and is usually described in terms of deficiencies (clinically known as dehiscences or fenestrations). Alveoloskeletal refers to the relationship between the dentoalveolar complex and the skeletal base.⁶ It is described in terms of discrepancies.

*Private Practice, Periodontics and Dental Implant Surgery, Periodontal Medicine & Surgical Specialists, LLC, Oakbrook Terrace, IL

†Department of Graduate Periodontics, College of Dentistry, University of Illinois, Chicago, IL

‡Department of Periodontics & Oral Medicine, School of Dentistry, University of Michigan, Ann Arbor, MI

§Private Practice, Orthodontics and Dentofacial Orthopaedics, Chicago, IL

||Private Practice, Oral and Maxillofacial Surgery, Los Angeles, CA

¶Department of Oral and Maxillofacial Surgery, School of Dentistry, University of California-Los Angeles, Los Angeles, CA

#Private practice, Restorative Dentistry, Oakbrook Terrace, IL

Received October 25, 2019; accepted February 3, 2020

doi: 10.1002/cap.10102

Skeletal malocclusions are well-known as discrepancies between the jaws as measured from craniofacial landmarks such as sella-nasion-A point (SNA) or sella-nasion-B point (SNB) from which analyses are made based on numeric cephalometric or CBCT data/tracing (i.e., Steiner analysis).¹⁴⁻¹⁹ Although the traditional 2D cephalometric numbers are still important, today's IDT planning is more predicated on where the teeth and jaws need to be placed in relation to the face and airway. This soft-tissue driven paradigm is often described as management of dentofacial disharmony malocclusion and seeks to create balance and harmony of hard and soft tissue structures.

In the management of malocclusion, many clinical dental signs and symptoms are compensatory mechanisms arising from deficiencies in alveolar bone volume, which are often inadequate to accommodate a normal adult dentition. Alveoloskeletal and skeletal discrepancies in the maxilla and mandible may compound such deficiencies. Dental crowding is perhaps the most obvious clinical manifestation of dentoalveolar and arch length deficiencies to which dental compensations (or tooth migration) occur to accommodate such conditions.²⁰⁻²² Because these deficiencies are pathologically compensatory, addressing them in orthodontic terms is often referred to as decompensation and whereby tooth movement must remain within the alveolar housing, commonly known as the "orthodontic boundary conditions" or the "orthodontic walls".^{23,24}

These anatomic limitations inherent in normal human anatomy underscores the difficulty, complexity, and skill involved in engineering and executing orthodontia to limit or avoid iatrogenic problems. For instance, decompensation options to correct moderate to severe crowding in a Class II malocclusion have historically involved expansion orthodontics or extraction-retraction therapy (commonly leading orthognathic surgery [OGS]), of which preventative, interceptive or corrective mucogingival surgery may or may not be required. Today, the era of digital dentistry is helping to address historical 2D treatment planning limitations and may afford expanded opportunities for the IDT team.

Effective assessment of how and when to use SFOT requires a diverse and collaborative array of specialized clinical expertise. This evolving cultural dynamic is a clarion call for individual clinicians to form IDT teams which prioritize, assign and execute therapies by the team member who is best-suited to achieve the outcomes needed to manage the core problems of the patient. This article focuses on how collaborative IDT-based treatment planning assesses individual SFOT indications, timing and implementation.

Decision Process

The American Academy of Periodontology has issued best-evidence consensus guidelines that classify the use of

CBCT imaging as essential for IDT treatment planning involving tooth movement, especially in the skeletally mature patient (Mandelaris et al., 2017^{25,26}). **Figure 1** presents an overview of clinical examination and CBCT imaging steps needed in the diagnostic inquiry of IDT cases.

Figure 2 presents a workflow/decision tree for SFOT treatment planning, with each key IDT member domain highlighting the use of each disciplines unique knowledge, training and skillset to offer the highest level of care while working in a contemporary team context.

Table 1 presents patterns of dentofacial disharmony/skeletal malocclusion, the defining characteristics of each, the treatment planning challenges and opportunities offered by SFOT, and the role of SFOT in decompensation management where OGS is required.

CBCT three-dimensional (3D) imaging of craniofacial tissues is the foundation of any SFOT IDT diagnostic evaluation and an emerging standard of care for complex cases involving skeletally mature patients requiring tooth movement. Precise visualization of key structures can identify skeletal asymmetries as well as the condition and position of the temporomandibular joint in the seated condylar position. Relationships of the natural dentition to and within the jaws can be precisely visualized and evaluated. A CBCT imaging-based crestal and radicular dentoalveolar bone-phenotype classification system has been proposed by Mandelaris et al.²⁷ which offers useful IDT-based risk-assessment benchmarks for cases involving tooth movement. The radiographic-supporting bone index proposed by Richman²⁸ offers additional guidance that correlates gingival recession and dentoalveolar dehiscences. In addition, CBCT imaging provides critical data regarding airway space volume and patency in nasopharyngeal and retroglottal regions, soft palate dimensions, hyoid bone position, as well as the location and extent of impact of adenoids and tonsils on the airway. This data set is not necessarily as easily garnered or appreciated with traditional panoramic and/or cephalometric 2D imaging and may not allow the IDT team to treatment plan as effectively.

SFOT should be considered when dentoalveolar bone augmentation is required to correct dentoalveolar deficiencies during decompensation orthodontia. Because SFOT can be considered a periodontal regenerative and dentoalveolar bone constructive surgery,^{29,30} it conceivably can be performed as a part of phenotype modification therapy involving bone grafting (PhMT-b)³¹ post-orthodontia. This would be likely considered in cases where camouflage orthodontia (defined as tooth movement to mask an underlying skeletal discrepancy) was carried out and periodontal tissue deterioration resulted. Primary determinants for SFOT surgery must include (1) an understanding of dentoalveolar bone volume to justify and support safe planned tooth movement; and (2) the skeletal relationship to that dentoalveolar bone volume. Any discrepancy between dentoalveolar and alveoloskeletal relationships must be quantitatively assessed to avoid

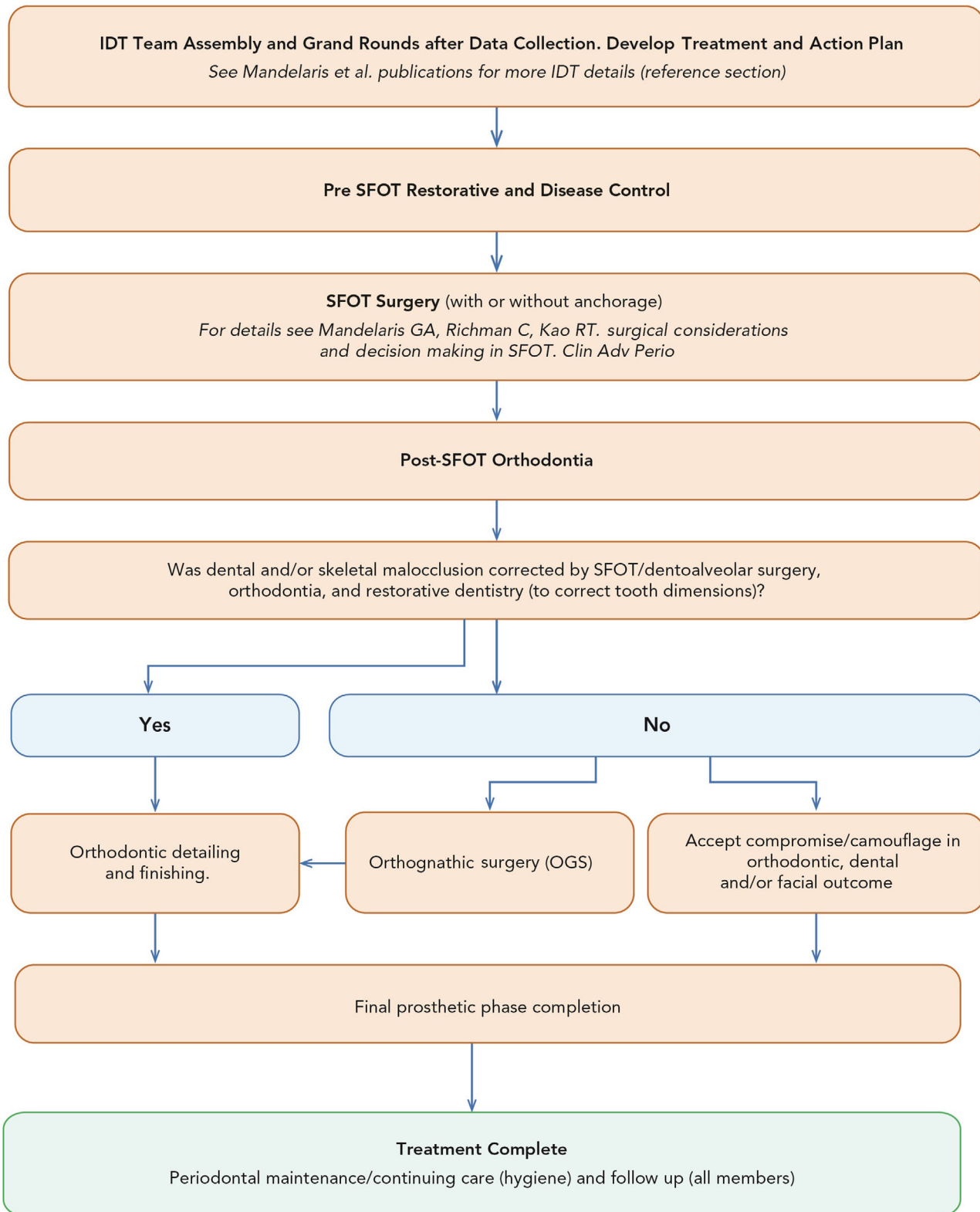


FIGURE 1 Workflow/decision tree for SFOT treatment planning.

moving teeth off the skeletal base or outside orthodontic boundary conditions during decompensation tooth movement which will subsequently cause iatrogenic periodontal problems. If such a concern is identified, PhMT-b will be required during SFOT to enhance the dentoalveolar

complex (a dynamic bone structure) to the deficient skeletal base (a static bone structure). This is often observed when decompensating the transverse maxillary deficiency and/or the Class II division I dentofacial disharmony with proclined lower incisors. (Table 1). In general, once the

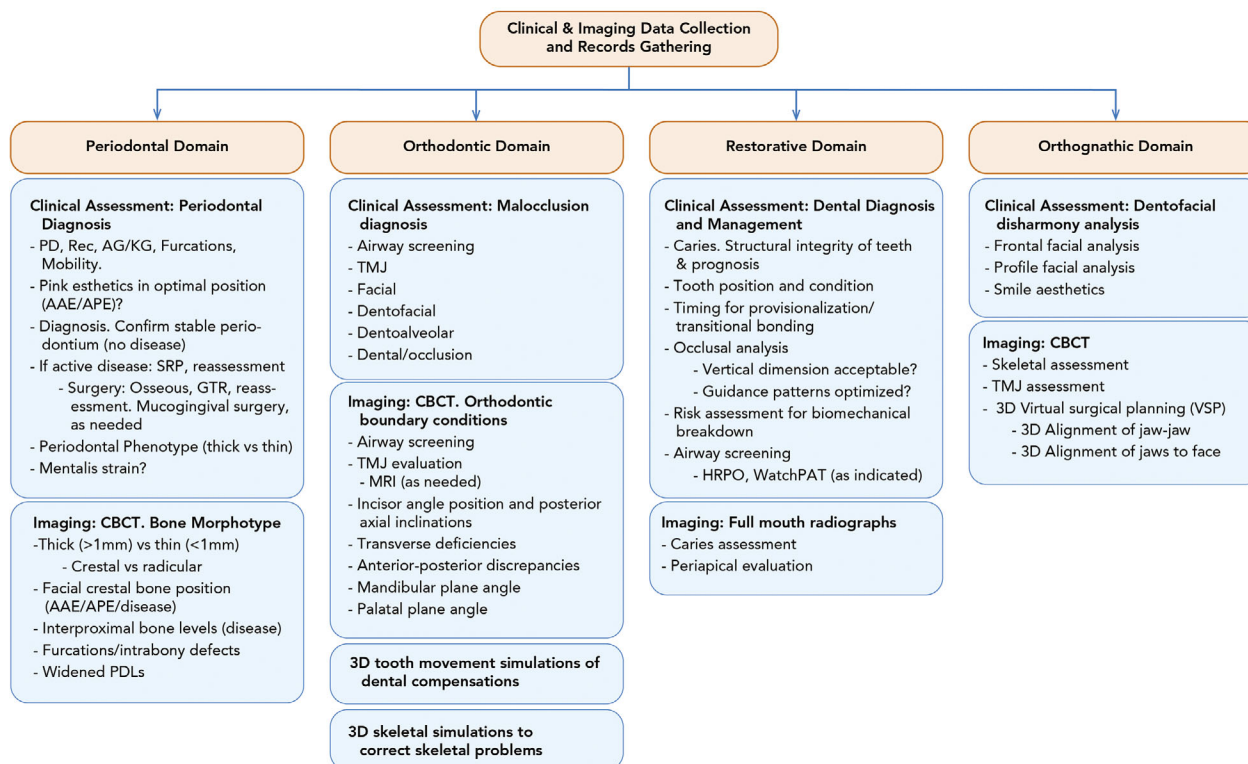


FIGURE 2 An overview of clinical examination and CBCT imaging steps needed in the diagnostic inquiry of IDT cases.

archform is expanded/decompensated and coordinated as best possible with (or without) SFOT, the resulting skeletal asymmetry or discrepancy should be managed by OGS.⁷

One of the misunderstandings of SFOT is that it can correct skeletal problems or is used primarily to move teeth fast. SFOT is a first and foremost a dentoalveolar bone surgery aimed to correct and augment dentoalveolar deficiencies. A by-product of SFOT surgery is accelerated tooth movement resulting from a demineralized bone matrix produced from bone injury. Although not the primary objective, this opportunity should not be marginalized, especially when setting up cases for patients who have severe obstructive sleep apnea and require life altering OGS. In select circumstances, the bone grafting involved may be capable of managing minor alveoloskeletal or true skeletal discrepancies by augmenting skeletal landmarks used to analyze discrepancies as well as create more bone volume with which teeth can be moved into. However, in general, once decompensation is corrected (teeth are aligned/arches coordinated) and the phenotype augmented for optimal dentoalveolar bone/periodontal health (when and where indicated), the collaboration of an OGS surgeon is required to correct more complex disharmonies and achieve more ideal jaw-jaw and jaws-face harmony.⁷

Another poorly studied and misunderstood subject is the ability of alveolar bone to adapt to forces, especially expansion. Studies have demonstrated that slow expansion is actually more detrimental to alveolar bone dimensions compared to rapid expansion,³² and in cases

leading to OGS, significant bone loss may result from decompensation movements that can only be appreciated using CBCT imaging analysis.³³ Profit's envelope of discrepancy provides perhaps the most well-accepted guidelines to answer the question: "How far teeth can be moved safely?". These guidelines speak to conventional orthodontia vs. that of growth modification therapy vs. that of OGS capabilities. They do not include guidance related to SFOT opportunities or consider published CBCT imaging regional anatomy measurements in their guidelines.^{34,35} Ferguson et al. published on the scope of treatment with PAOO and reported that certain tooth movements can be 2× to 3× greater when compared to conventional orthodontics.³⁶ However, the published tooth movement parameters involving PAOO question biologic reality with dentoalveolar surgery involving particulate bone grafting. The extent of tooth movement and need for dentoalveolar bone augmentation should be jointly agreed upon by the IDT team and is best evaluated with 3D tooth movement simulation technology that allows the dentoalveolar bone complex to be scrutinized as to the influence of tooth movement on those structures.

Just as important as identifying clear indications for SFOT is clarity of circumstances under which SFOT is contraindicated or not required. These include situations when systemic health risk assessment is not conducive to elective dentoalveolar surgery, patients demonstrating poor plaque control and/or poor patient compliance, when hypoxic conditions exist (such as heavy smoking) which negatively influence blood supply, when patients

TABLE 1 Patterns of facial disharmony/skeletal malocclusion and benefit from periodontal-orthodontic therapy involving corticotomy and dentoalveolar bone augmentation (i.e., SFOT/PAOO)

Malocclusion anatomic description	Defining characteristics	Treatment planning challenges and opportunities	Treatment options using SFOT prior to OGS
Transverse maxillary deficiency	Highly prevalent malocclusion case type. Usually presents with excess curve of Wilson. Typical correction involves SARPE, which decreases buccal alveolar bone.	SFOT/PAOO allows more optimal decompensation & correction of excess curve of Wilson as well as idealizes axial inclination of teeth by augmenting buccal alveolar bone. Skeletal movement needed with OGS may become purely expansion with improved decompensation (if possible).	SFOT/PAOO to expand & increase buccal alveolar boundary conditions (i.e., orthodontic walls) laterally, allowing decompensation to occur through buccal root torque. LeFort I osteotomy OGS may reduce the need for tipping to optimize posterior articulation.
Skeletal Class II, division 2 dentofacial disharmony malocclusion with severely upright or retroclined maxillary incisors	Notoriously difficult cases to decompensate because of thick crestal bone. May require 20° of torque, exceeding orthodontic capabilities.	The use of SFOT/PAOO induces RAP, which can help achieve more ideal decompensation for the orthodontist because the teeth move in a demineralized bone matrix, which facilitates movement, may improve the predictability of tooth movement, & decreases treatment time.	SFOT/PAOO to induce RAP & allow decompensation to occur in a demineralized bone matrix while augmenting the dentoalveolar bone complex. OGS thereafter to align skeletal discrepancies once decompensation is corrected & inter/intra-arch dimensions are aligned for such correction.
Skeletal Class II or III dentofacial disharmony malocclusion with maxillary incisor proclination requiring labial root torque	Crown is in a relatively good position. Root position is unfavorable & requires movement. Dentoalveolar bone volume is limited to accomplish ideal decompensation.	Proclination requires labial root torque while holding incisor crown position. Risk is pushing roots out of the alveolar bone and exceeding the alveolar boundary conditions (i.e., orthodontic walls). Conventional correction may include extraction and/or skeletal anchorage for maximum space closure. Conventional correction necessitates increasing a negative overjet and a larger skeletal correction. If OGS is needed, one-jaw surgery may now become a double-jaw procedure.	SFOT/PAOO to develop dentoalveolar bone & augment/enhance alveolar boundary conditions (i.e., orthodontic walls), facilitating tooth movement & expanding tooth movement capabilities.
Skeletal Class III dentofacial disharmony malocclusion cases with protrusive and retroclined mandibular incisors	Very limited alveolar bone to move teeth safely. "Teeth on a pedestal" presentation on CBCT cross section/sagittal view.	Decompensation of mandibular incisor position is impossible with labial crown torque as it can create dehiscences & periodontal problems. Conventional OGS therapy includes anteroposterior reduction genioplasty, which may not look favorable & does not correct the dentoalveolar bone deficiency/volume etiologic problem.	SFOT/PAOO to provide dentoalveolar bone & alveoloskeletal bone augmentation & to allow proclination of mandibular incisors to occur.
Skeletal Class II dentofacial disharmony malocclusions with mandibular incisor proclination needing labial root torque	Severely proclined mandibular incisors requiring decompensation for future OGS. Limited dentoalveolar bone to accomplish labial root torque movement while allowing roots of teeth to be placed in bone.	Typical plan: extract and decompensate for OGS. Not an ideal plan when patient has an ideal Holdaway ratio or no additional overjet is needed for desired skeletal correction. If the patient has obstructive sleep apnea, this condition might become worse before becoming better.	SFOT/PAOO to enhance orthodontic decompensation & apply labial root torque and place roots in bone for decompensation. OGS thereafter to correct skeletal discrepancy.

From Mandelaris GA, Neiva R, Chambrone L. American Academy of Periodontology Best Evidence Consensus on Cone Beam Computed Tomography and Interdisciplinary Dentofacial Therapy. A Systematic Review Focusing on Risk Assessment of the Dentoalveolar Bone Changes Influenced by Tooth Movement. *J Periodontol* 2017;88:960-977.

TABLE 2 Indications/rationale and contraindications for SFOT surgery

SFOT rationale and indications	SFOT contraindications
<ul style="list-style-type: none"> - To enable planned orthodontic tooth movements for ideal facially-generated tooth positioning - To enhance orthodontic boundary conditions within which safe, timely and predictable tooth movement can occur - To enhance periodontal phenotypes through phenotype conversion surgery involving bone augmentation - To reduce the risk of post orthodontic relapse - To optimize oral cavity volume conditions with expansion of the dental arches - To enhance dentoalveolar bone volume & expand decompensation capabilities - To optimize non-extraction orthodontic conditions, when appropriate 	<ul style="list-style-type: none"> - When the CBCT imaging analysis and orthodontic soft tissue simulation to correct the malocclusion do not exceed inherent dentoalveolar boundary conditions detrimental to the periodontium - When accepting any compromise is acceptable to the patient and IDT team - When the patient is a poor candidate for elective dentoalveolar surgery

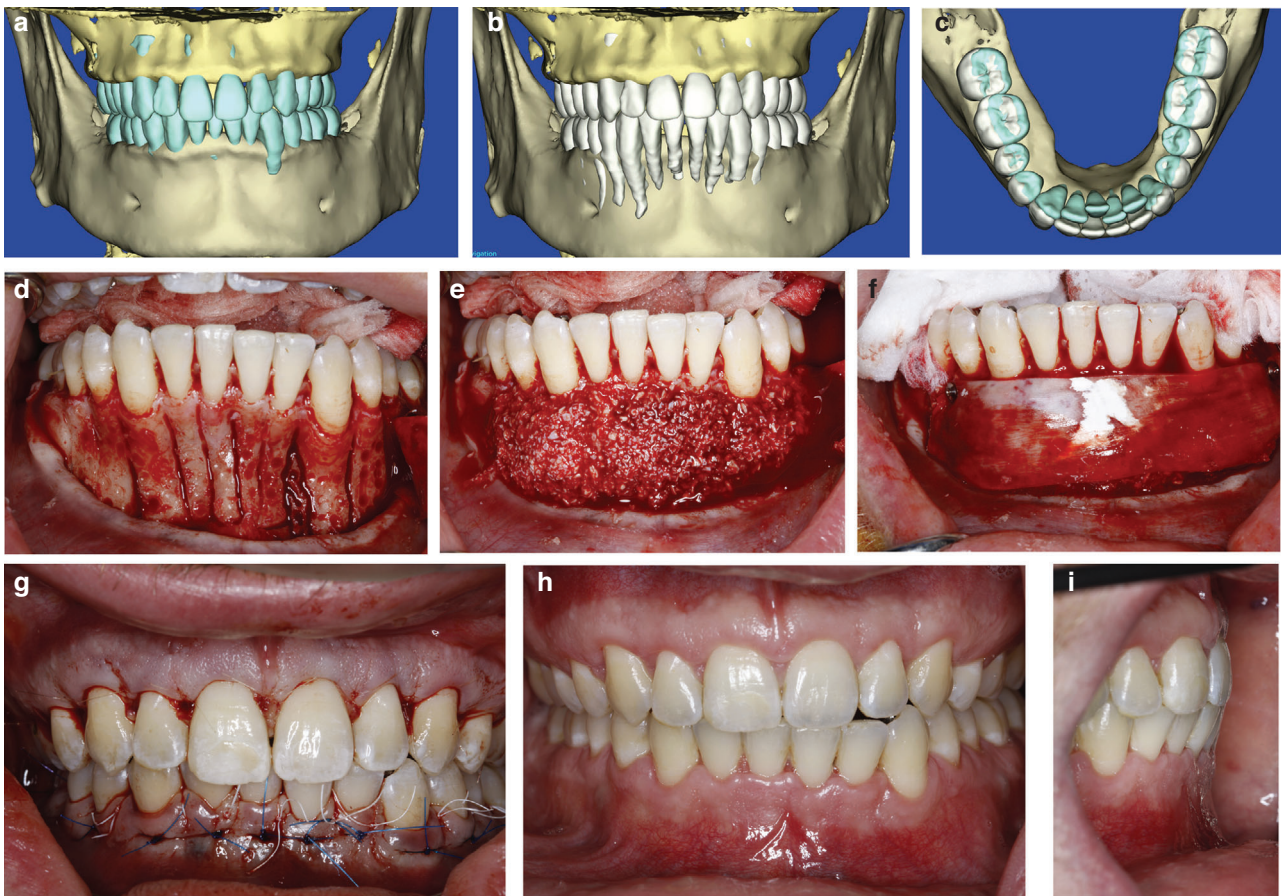

FIGURE 3 **3a** Case 1 Class II malocclusion with severe crowding and dentoalveolar deficiencies. Pre Op 3D CBCT regional anatomy presentation. **3b** Orthodontic simulation of malocclusion correction by dental arch expansion. Note dentoalveolar deficiencies that do not allow conventional orthodontia to place teeth in such a position outside the orthodontic walls. **3c** Orthodontic simulation of before and after arch forms planned to correct malocclusion. **3d** Flap surgery with corticotomies and dentoalveolar decortication performed. **3e** Particulate bone grafting to accommodate dental arch expansion and enhance orthodontic boundary conditions. **3f** Stabilized collagen membrane placement for wound stabilization and graft containment. **3g** Sutures. Esthetic crown enhancement performed in the maxillary arch. **3h** and **3i** 2 months post SFOT. Note intercincisal angle relationship produced through buccal root torque. Tooth movement is occurring through lingual orthodontia (Incognito™).

are taking anti-resorptive drug therapies predisposing to delayed healing or bisphosphonate related osteonecrosis of the jaw, when patient expectations are unreasonable (psychologic parameters not conducive to elective surgery), or if boundary conditions are adequate and sufficient for safe tooth movement to meet decompensation goals. **Table 2** summarizes indications/rationale and contraindications for SFOT surgery.

Clinical Scenarios

Case 1 (**Fig. 3a-3i**) demonstrates a Class II dentofacial disharmony malocclusion with severe lower crowding who underwent mandibular SFOT surgery to accommodate dental arch correction and expansion. Orthodontic therapy by Iwei Huang, DMD, MS (Chicago, IL)

Case 2 (**Fig. 4a-4k**) demonstrates a Class I dentofacial disharmony malocclusion with severe lower crowding

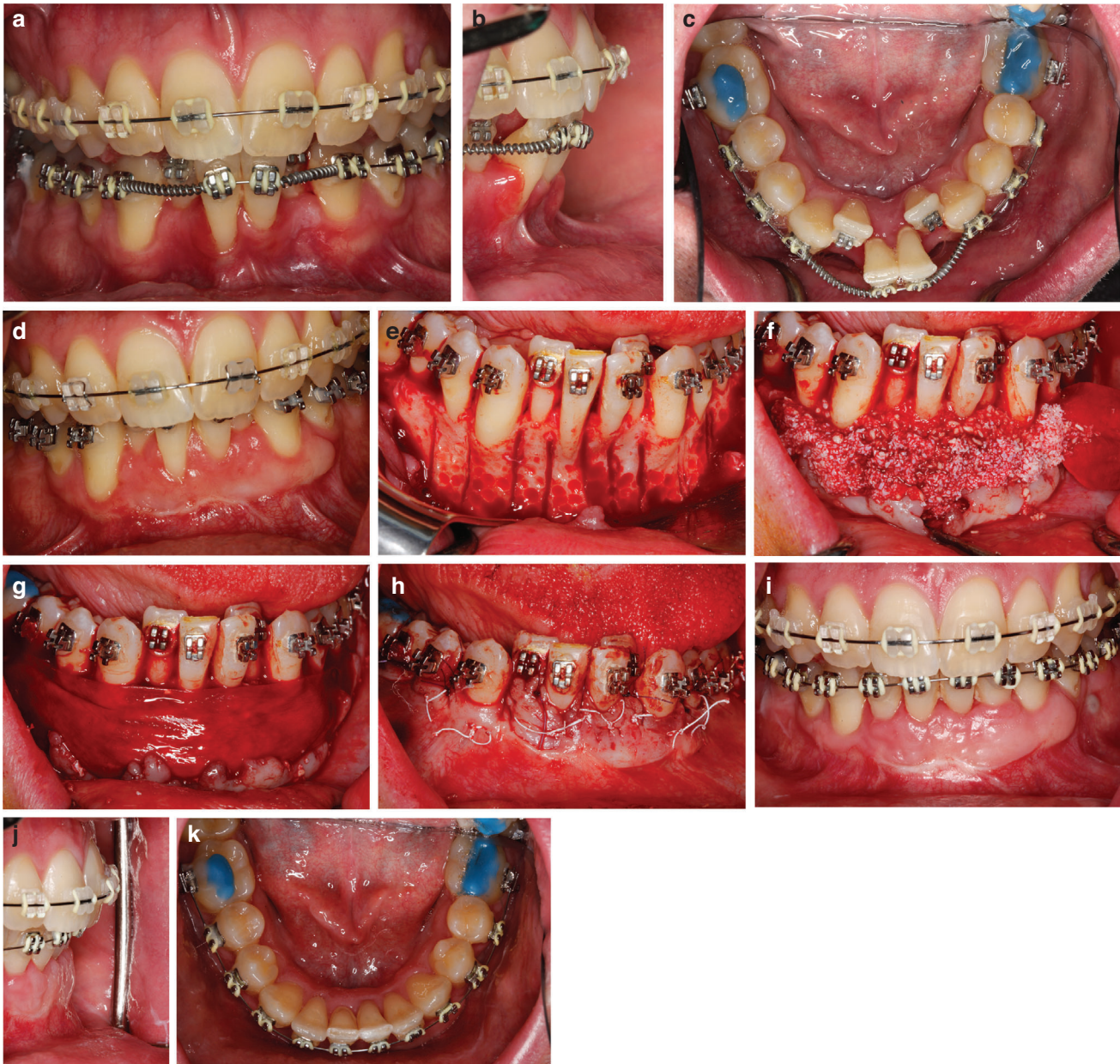

FIGURE 4 4a-c Class I malocclusion with severe crowding and dentoalveolar deficiencies. Initial exam Frontal, Lateral aspect demonstrating iatrogenic attachment loss secondary to tooth movement, occlusal view. Expansion is attempted but exceeding anatomic boundary conditions and risking tooth loss. 4d 12 weeks following cessation of orthodontic tooth movement and PhMT-soft tissue via autogenous free gingival graft (FGG) surgery to set up environment to support SFOT. 4e SFOT surgery 2 weeks post Botox of mentalis muscle to relieve strain and optimize flap closure. Corticotomies and dentoalveolar decortication performed. Note dehiscences remain and dentoalveolar deficiencies despite impression soft tissue outcome as a result of FGG surgery. 4f Particulate bone grafting to accommodate dental arch expansion and enhance orthodontic boundary conditions. 4g Stabilized collagen membrane for wound stabilization and graft containment. 4h Sutures and passive wound closure. 4i-4k 4 months post SFOT. Non extraction orthodontia nearly complete. Note significant phenotype modification through soft and hard tissue surgery. Expansion orthodontia is accommodated and tooth prognosis is now excellent.

and dentoalveolar deficiencies. PhMT-soft tissue was performed to convert and prepare the mucoingival environment 12 weeks prior to SFOT. Two weeks prior to SFOT surgery, botox was administered to the mentalis muscle to paralyze strain and optimize flap stabilization during initial wound healing. Orthodontic treatment by Jinjuan Hao, DDS, PhD (Chicago, IL).

Oral informed consent was granted by the patients for the procedures here and photography taken.

Discussion

The eagerness to achieve enhanced patient outcomes through complex and demanding SFOT IDT must be balanced by our biologic compass and periodontal conscience. With the availability of 3-D imaging technology and orthodontic simulation software programs that include the dentoalveolar complex in the treatment-planning process, CBCT becomes a foundational pillar for collaborative decision making, especially for clinicians

providing IDT in the skeletally mature patient. Similarly, decision making for orthodontic patients in regard to IDT that is more complex, and includes SFOT and/or OGS, can be significantly impaired without 3D CBCT data and orthodontic simulation planning software. Thus, these diagnostic tools are an emerging standard of care for IDT involving tooth movement.²⁵ That said, CBCT analysis is not without its risks. Notably that of ionizing radiation exposure, despite the low-dose outputs of newer CBCT units. Risk-benefit assessment of CBCT-based planning underscores the pivotal need for the interpretive expertise of clinicians with the necessary skillsets to interpret a diagnostic mix of 3-D and 2-D data proficiently.²⁵

There has never been a more exciting time to be involved in IDT. The future will continue to expand with innovative, technology-driven advances that will include artificial intelligence, deep learning, block chain cryptography to aid in decision making. The importance of an accurate diagnosis will not change. However, the treatment options with which we will respond to that diagnosis may. SFOT offers patients numerous benefits and opportunities, yet has not accumulated the long-term data most clinicians need to make reliable conclusions within an individual—and variable—"comfort zone". On the other hand, the inability—or unwillingness—to embrace measured and cautious change with an open mind may prevent the profession from serving our patients to the best of our abilities.

Conclusions

The SFOT IDT decision making process is complex, yet full of opportunities. Embracing SFOT IDT with innovative and novel 3D technology can optimize conditions leading to long-term outcomes that align with periodontal stability as well as patient goals and preferences which permeate beyond the achievement of "straightening teeth." Transparency of complex IDT through 3D CBCT and orthodontic simulation software engenders "collaborative accountability" and can improve patient communication which is critical to developing meaningful and essential treatment plans. ■

Acknowledgments

Dr. Mandelaris reports receiving lecture fees from Carestream Dental and Geistlich Pharma. Drs. Huang, Relle, Vence, and DeGroot report no conflicts of interest related to this report.

CORRESPONDENCE

Dr. George A. Mandelaris, Periodontal Medicine and Surgical Specialists, 1s224 Summit Avenue, Suite 205, Oakbrook Terrace, IL, 60181.
E-mail: GMandelaris@PeriodontalMedicine.org

References

1. Wilcko WM, Wilcko T, Bouquot JE, et al. Rapid orthodontics with alveolar reshaping: two case reports of decrowding. *Int J Periodontics Restorative Dent* [Case Reports]. 2001;21(1):9-19.
2. Zimmo N, Saleh MH, Mandelaris GA, et al. Corticotomy-accelerated orthodontics: a comprehensive review and update. *Compend Contin Educ Dent* 2017;38(1):17-25.
3. Zimmo N, Sal MHA, Sinjab K, et al. Corticotomy-Assisted orthodontics for canine distalization: a systematic review and meta-analysis of clinical controlled trials. *J Int Acad Periodontol* 2018 20(4):153-162.
4. Hoogveen EJ, Jansma J, Ren Y. Surgically facilitated orthodontic treatment: a systematic review. *Am J Orthod Dentofacial Orthop* 2014;145(4 Suppl):S51-64.
5. Liem AM, Hoogveen EJ, Jansma J, et al. Surgically facilitated experimental movement of teeth: systematic review. *Br J Oral Maxillofac Surg* 2015;53(6):491-506.
6. Mandelaris GA, DeGroot BS, Relle R, et al. Surgically facilitated orthodontic therapy: optimizing dentoalveolar bone and space appropriation for facially prioritized interdisciplinary dentofacial therapy. *Compend Contin Educ Dent* 2018;39(3):146-56.
7. Mandelaris GA, DeGroot BS. Surgically Facilitated Orthodontic Therapy (SFOT). In: Nares S. *Advances in Periodontal Surgery: A Clinical Guide to Techniques and Interdisciplinary Approaches*. Switzerland: Cham, Springer; 2019:223-226.
8. Braut V, Bornstein MM, Lauber R, et al. Bone dimensions in the posterior mandible: a retrospective radiographic study using cone beam computed tomography. Part 1—analysis of dentate sites. *Int J Periodontics Restorative Dent* 2012;32(2):175-184.
9. Braut V, Bornstein MM, Belser U, et al. Thickness of the anterior maxillary facial bone wall—a retrospective radiographic study using cone beam computed tomography. *Int J Periodontics Restorative Dent* 2011;31(2):125-131.
10. Farahamnd A, Sarlati F, Eslami S, et al. Evaluation of Impacting Factors on Facial Bone Thickness in the Anterior Maxillary Region. *J Craniofac Surg* 2017;28(3):700-705.
11. Buser D, Martin W, Belser UC. Optimizing esthetics for implant restorations in the anterior maxilla: anatomic and surgical considerations. *Int J Oral Maxillofac Implants* 2004;19(Suppl):43-61.
12. Nowzari H, Molayem S, Chiu CH, et al. Cone beam computed tomographic measurement of maxillary central incisors to determine prevalence of facial alveolar bone width ≥ 2 mm. *Clin Implant Dent Relat Res* 2012;14(4):595-602.
13. Buttkie TM, Proffit WR. Referring adult patients for orthodontic treatment. *J Am Dent Assoc* 1999;130(1):73-79.
14. Buschang PH, Fretty K, Campbell PM. Can commonly used profile planes be used to evaluate changes in lower lip position? *Angle Orthod* 2011;81(4):557-563.
15. Cao Y, Zhou Y, Song Y, et al. Cephalometric study of slow maxillary expansion in adults. *Am J Orthod Dentofacial Orthop* 2009;136(3):348-354.
16. Alves PV, Mazucheli J, Vogel CJ, et al. A protocol for cranial base reference in cephalometric studies. *J Craniofac Surg* 2008;19(1):211-215.
17. Kim SJ, Kim KH, Yu HS, et al. Dentoalveolar compensation according to skeletal discrepancy and overjet in skeletal Class III patients. *Am J Orthod Dentofacial Orthop* 2014;145(3):317-324.
18. Kim YJ, Hong JS, Hwang YI, et al. Three-dimensional analysis of pharyngeal airway in preadolescent children with different anteroposterior skeletal patterns. *Am J Orthod Dentofacial Orthop* 2010;137(3):306-311.
19. Neelapu BC, Kharbanda OP, Sardana HK, et al. Craniofacial and upper airway morphology in adult obstructive sleep apnea patients: a systematic review and meta-analysis of cephalometric studies. *Sleep Med Rev* 2017;31:79-90.
20. Kim HJ, Hong M, Park HS. Analysis of dental compensation in patients with facial asymmetry using cone-beam computed tomography. *Am J Orthod Dentofacial Orthop* 2019;156(4):493-501.
21. AlHammadi HA, Wilcko MT, Ferguson DJ. Severe mandibular crowding treated with nonextraction periodontally accelerated osteogenic orthodontics. *Int J Periodontics Restorative Dent* 2019;39(5):188-194.
22. Alhammadi MS. Dentoalveolar compensation in different anteroposterior and vertical skeletal malocclusions. *J Clin Exp Dent* 2019;11(8):745-753.
23. Kapila SD, Nervina JM. Alveolar boundary conditions in orthodontic diagnosis and treatment planning. In: Kapila SD. *Cone Beam Tomography in Orthodontics Indications, Insights, and Innovations*. Ames, IA: Wiley-Blackwell; 2014;293-316.

24. Handelman CS. The anterior alveolus: its importance in limiting orthodontic treatment and its influence on the occurrence of iatrogenic sequelae. *Angle Orthodont* 1996;66(2):95-109.
25. Mandelaris GA, Scheyer ET, Evans M, et al. American Academy of Periodontology best evidence consensus statement on selected oral applications for cone-beam computed tomography. *J Periodontol* 2017;88(10):939-945.
26. Mandelaris GA, Neiva R, Chambrone L. Cone-beam computed tomography and interdisciplinary dentofacial therapy: An American Academy of Periodontology best evidence review focusing on risk assessment of the dentoalveolar bone changes influenced by tooth movement. *J Periodontol* 2017;88(10):960-977.
27. Mandelaris GA, Vence BS, Rosenfeld AL, et al. A classification system for crestal and radicular dentoalveolar bone phenotypes. *Int J Periodontics Restorative Dent* 2013;33(3):289-296.
28. Richman C. Is gingival recession a consequence of an orthodontic tooth size and/or tooth position discrepancy? "A paradigm shift". *Compend Contin Educ Dent* 2011;32(4):e73-9.
29. Chin M. Establishing and maintaining osseointegration within the functional matrix. *Int J Periodontics Restorative Dent* 2016;36(1):29-37.
30. Chin M. Establishing and maintaining osseointegration within the functional matrix. In: Chin M. *Introduction to Surgical Design Using Embryologic Processes. Surgical Design for Dental Reconstruction with Implants: A New Paradigm*. Hanover Park, IL: Quintessence Books; 2015;13-20.
31. Kao RT, Curtis D, Kim DM, et al. American Academy of Periodontology best evidence consensus statement on modifying gingival phenotype in preparation for orthodontic and restorative treatment. *J Periodontol* In press.
32. Brunetto M, Andriani Jda S, Ribeiro GL, et al. Three-dimensional assessment of buccal alveolar bone after rapid and slow maxillary expansion: a clinical trial study. *Am J Orthod Dentofacial Orthop* 2013;143(5):633-644.
33. Gauthier C, Voyer R, Paquette M, et al. Periodontal effects of surgically assisted rapid palatal expansion evaluated clinically and with cone-beam computerized tomography: 6-month preliminary results. *Am J Orthod Dentofacial Orthop* 2011;139(4 Suppl):S117-28.
34. Proffit WR, White RP Jr. Who needs surgical-orthodontic treatment? *Int J Adult Orthodon Orthognath Surg* 1990;5(2):81-89.
35. Proffit WR, White RP Jr. Combined surgical-orthodontic treatment: how did it evolve and what are the best practices now? *Am J Orthod Dentofacial Orthop* 2015;147(5 Suppl):S205-15.
36. Ferguson DJ, Makki L, Stapelberg R, et al. Stability of the mandibular dental arch following periodontally accelerated osteogenic orthodontics therapy: Preliminary studies. *Semin Orthod* 2014;20(3):239-246.