

<PE-AT>Diagnosis of Peri-implant Status After Peri-implantitis Treatment: Proposal of a New Classification

Andrea Ravida\* DDS, MS, Matthew Galli\* DDS, Rafael Siqueira\* DDS, MS, PhD, Muhammad H.A. Saleh\*† BDS, MS, Pablo Galindo Moreno‡ DDS, MS, PhD, Hom-Lay Wang\* DDS, MS, PhD.

\*Graduate Periodontics, Department of Periodontics and Oral Medicine, University of Michigan School of Dentistry, Ann Arbor, MI, USA.

†Department of Periodontics, University of Louisville School of Dentistry, Louisville, KY, USA.

‡Oral Surgery and Implant Dentistry Department, School of Dentistry. University of Granada, Spain.

**Corresponding author:**

Hom-Lay Wang, DDS, MS, PhD

Department of Periodontics and Oral Medicine

University of Michigan School of Dentistry

1011 North University Avenue

Ann Arbor, Michigan 48109-1078, USA.

TEL: +1 (734) 763-3383

E-mail address: [homlay@umich.edu](mailto:homlay@umich.edu)

**Running title:** Diagnosis of peri-implant status after peri-implantitis treatment

**Word count:** 3075 words

**Tables and figures:** 4 Figures, 1 Table

This is the author manuscript accepted for publication and has undergone full peer review but has not been through the copyediting, typesetting, pagination and proofreading process, which may lead to differences between this version and the [Version of Record](#). Please cite this article as [doi: 10.1002/JPER.20-0124](#).

This article is protected by copyright. All rights reserved.

**Number of references:** 50

**Key words:** Dental implants, peri implantitis, disease management, diagnosis, classification

**One sentence summary:** This article proposes a classification system for diagnosis of peri-implant status after resective or regenerative surgical treatment of peri-implantitis.

**Conflict of interest and source of funding:** The authors do not have any financial interests, either directly or indirectly, in the products or information listed in the paper. This paper was partially supported by the University of Michigan Periodontal Graduate Student Research Fund.

#### *Abstract*

**Background:** The 2017 World Workshop classified peri-implant diseases into health, peri-implant mucositis, and peri-implantitis. The aim of this article is to build upon this recent classification and propose a framework for the diagnosis of peri-implant status after resective or regenerative surgical treatment for peri-implantitis.

**Methods:** A literature review was conducted to discuss the relevant diagnostic clinical and radiographic parameters, including probing depth (PD), bleeding on probing (BOP), visual inspection, and radiographic bone loss. Case definitions of possible treatment outcomes were discussed, and a flowchart was constructed to guide post-treatment diagnosis according to all the possible clinical scenarios which can be encountered in daily practice.

**Results:** Three possible treatment outcomes were identified after resective treatment of peri-implantitis: 1) healthy implant with a reduced support, 2) peri-implant mucositis with a reduced support, and 3) recurrent/refractory peri-implantitis. After regenerative treatment for peri-implantitis, the peri-implant condition was classified according to the same diagnoses with the addition of healthy implant or peri-implant mucositis after complete regeneration for cases where complete regeneration was attained. Criteria for successful treatment of peri-implantitis were proposed. After resective therapy, a successful treatment outcome was defined as healthy implant with a reduced support,

whereas, after regenerative therapy, a successful outcome was described as either peri-implant health after complete regeneration or healthy implant with a reduced support.

**Conclusions:** The proposed classification system of peri-implant status after treatment for peri-implantitis provides a framework for diagnosing the various forms of peri-implant stability or disease in order to guide clinical decision-making post-treatment.

<PE-FRONTEND>

### *Background*

Peri-implant disease etiology is believed to be primarily microbially-mediated, with evidence to support that additional factors can influence susceptibility, including but not limited to the width and thickness of peri-implant keratinized mucosa and implant positioning<sup>1, 2</sup>. An exposure-response relationship between the accumulation of bacterial biofilm and subsequent inflammatory changes in peri-implant soft tissues has been shown<sup>3, 4</sup>. Peri-implant mucositis is a reversible inflammatory response confined to the soft tissue<sup>5</sup>. If left untreated, peri-implant mucositis can potentially progress into peri-implantitis, involving destruction of peri-implant bone support<sup>1</sup>. The 2017 World Workshop on the classification of periodontal and peri-implant diseases and conditions recently proposed case definitions for both periodontal and peri-implant diseases<sup>1, 6, 7</sup>. For periodontal diseases it set forth a diagnostic framework to classify periodontal health, gingivitis, periodontitis, and status after periodontitis treatment<sup>8, 9</sup>. Although a framework was also proposed for the diagnosis of peri-implant diseases (Figure 1A-C), there is still a need for a classification system which specifically addresses peri-implant status after treatment for peri-implantitis, as this topic was briefly described but not expanded upon in a formal framework<sup>1, 7</sup>. With the current trend towards increasing numbers of implants being placed, the number of peri-implantitis cases will also rise. It has been projected that in the United States alone, dental implant prevalence will rise from 5.7% to 23% by 2026<sup>10</sup>. It is estimated that about 10% of implants inserted will develop peri-implantitis within a 10-year window<sup>11</sup>. The implant- and patient-level prevalence of peri-implantitis has been measured to be around 11.4%<sup>12</sup> and 22-45%, respectively<sup>13, 14</sup>. Between the two extremes of healthy and failing implant for which the treatment needs will be agreed upon by the majority of clinicians, there are grey zones which complicate detection of disease. A classification system characterizing peri-implant status after treatment for peri-implantitis will facilitate diagnosis of the various forms of peri-implant stability or disease in order to guide clinical decision-making post-treatment. Thus, the main objective of this review is to propose a diagnostic classification system of peri-implant status after treatment for peri-implantitis.

*Reduced periodontium in natural dentition as a building block for classifying treated implants with reduced support*

The concept of reduced periodontium associated with natural dentition was introduced in the 2015 American Academy of Periodontology Task Force Report, which updated the 1999 Classification of Periodontal Diseases and Conditions <sup>15</sup>. Patients presenting with a clinical scenario characterized by probing depth (PD)  $\leq 3$  mm with attachment loss and recession following active therapy were classified as health on a reduced periodontium. When bleeding on probing (BOP) was present, the diagnosis shifted to reduced periodontium with inflammation. This modification was developed in order to correctly classify successfully treated periodontal patients presenting with some attachment loss but without clinical signs of recurrent/refractory periodontitis. Finally, the 2017 World Workshop highlighted the difference between a reduced periodontium in a stable periodontal patient and a reduced periodontium in a non-periodontitis patient (as a consequence of recession or crown lengthening procedures) because of the difference in risk for periodontal disease progression <sup>8</sup>. In regard to implants, the term “reduced periodontium” cannot be employed due to the absence of a periodontal ligament and cementum. We propose that the term “reduced peri-implant support” should be utilized to signify an analogous clinical scenario around a dental implant which presents with loss of supporting bone.

*The influence of different surgical therapeutic options on the diagnosis of peri-implant status post-treatment*

As a result of resective therapy, a reduced peri-implant support with significant reduction of probing pocket depth ( $< 4$ mm) is expected <sup>16</sup>. Resective surgery, defined as an apically positioned flap combined with osteoplasty and/or implantoplasty shows favorable results for peri-implantitis treatment <sup>17, 18</sup>. Currently, there are few studies evaluating resective therapy with or without implantoplasty which include PD measurements in the disease resolution outcome criteria. Carcuac and coworkers evaluated resective therapy outcomes in a randomized clinical trial over a 3- year follow- up. The overall success rate of the treatment (defined by no MBL  $> 0.5$  mm, no BOP, no suppuration, and no PD  $> 4$  mm) was 33% <sup>19</sup>. Also, Serino and coworkers showed in a 2- year follow- up prospective study that resective and bone recontouring treatment had a 48% peri-implantitis resolution index. In their study, “healthy” implants were defined on the basis of PD  $< 4$  mm, no bleeding/suppuration on probing, and no bone loss after remodeling <sup>20</sup>. In regard to post-treatment peri-implant mucositis, an increase in PD can arise from either decreased peri-implant

mucosal probing resistance or edema of the gingival margin. As a result, a PD of <6 mm was used to define peri-implant mucositis after resective surgery in the present classification.

Regenerative therapy is indicated when there is recurrence of peri-implantitis after non-surgical treatment in the presence of intra-bony peri-implant defects. Surgical augmentative peri-implantitis therapy can result in improved clinical and radiographic treatment outcomes<sup>21</sup>, however, outcomes are highly dependent on the morphology of the defect<sup>22</sup>. After regenerative therapy, several factors will play a role in PD measurement, including but not limited to probing pressure, inflammation of the peri-implant tissue, exposure of implant threads, as well as implant abutment, and restorative features. In addition, since the aim of regenerative therapy is to re-establish the bone levels as close as possible to baseline and not to attain pocket elimination, a wide range of pocket depths can be compatible with health or peri-implant mucositis post-treatment. For recurrent/refractory peri-implantitis, the presence of progressive bone loss will predispose towards a deep pocket depth of  $\geq 6$ mm. Therefore, after regenerative treatment, the clinical signs of inflammation and amount of probing depth reduction after surgical therapy (when baseline information is provided) are of more importance than a specific probing depth value. The term recurrent peri-implantitis denotes a clinical scenario where a period of stability is attained after treatment, but over time, progressive bone loss with signs of inflammation redevelop at the site. The term refractory implies that the attempted treatment failed to resolve the peri-implantitis and progressive bone loss continued after surgical therapy.

#### *Bleeding on probing (BOP) as a diagnostic tool for evaluating peri-implant diseases*

The predictive capability of BOP as a diagnostic tool has been a source of study for many years. For diagnosing periodontitis, despite a low sensitivity of 29%, the absence of bleeding on probing is highly specific (88%) for periodontal health<sup>23</sup>. Numerous longitudinal studies monitoring long-term outcomes of treated and maintained periodontitis patients concluded that BOP was a poor predictor of future attachment loss<sup>24-27</sup>.

Differences in the physiologic characteristics between peri-implant soft tissues relative to natural teeth result in different expectations for peri-implant probe penetration, pocket depth measurements, and bleeding on probing tendency. Generally, probing depth penetration and measurements are deeper around implants compared to natural dentition and more likely to penetrate into connective tissue<sup>28</sup>. The deeper penetration of the periodontal probe when measuring PD around healthy implants correlates clinically with an increased tendency for peri-implant BOP<sup>29</sup> with implications for decreased BOP diagnostic sensitivity around implants. When teeth and implants in

the same patients were compared in the absence of disease, BOP was significantly higher at implants compared to teeth <sup>30</sup>.

The 2017 World Workshop identifies BOP as a key diagnostic factor for differentiating between health and peri-implant mucositis or peri-implantitis <sup>7</sup>. When considering the diagnostic utility of BOP, it is important to note that BOP around both natural teeth and implants has been shown to occur in the absence of disease <sup>31</sup>, and to be dependent on numerous factors in addition to inflammation, such as probing force <sup>28, 32</sup>. BOP frequency directly correlates with the magnitude of probing force <sup>33</sup>. Gerber et al. (2009) demonstrated that increasing probing force from 0.15 to 0.25 N corresponded to a 13.7% increase in the prevalence of BOP around implants, but only a 6.6% increase around natural dentition. Small differences in probing force can have an impact on peri-implant BOP measurements complicating the diagnostic analysis.

The literature supports that the absence of BOP is a strong indicator of peri-implant stability <sup>34</sup>, but its presence is not predictive of disease status. In the present classification, BOP must be utilized in conjunction with visual observations of tissue status assessing colour, texture, and contour, in order to differentiate between peri-implant health and peri-implant mucositis after surgical treatment for peri-implantitis. Since the literature supports that BOP may or may not be present around healthy implants, clinical judgement must be utilized when differentiating between peri-implant health and mucositis.

#### *Probing pocket depth (PD) as a clinical diagnostic parameter for evaluating peri-implant diseases*

Different post-surgical PD measurements are expected based on if a resective or regenerative approach is utilized for peri-implantitis treatment. A major goal of resective treatment is to achieve pocket depth resolution, whereas after regenerative therapy, residual probing depths are not incompatible with a state of health. After regenerative therapy, multiple factors can influence PD measurements including but not limited to implant design and implant-abutment connection (i.e. standard versus switched platform and one- versus two-piece implants) <sup>35</sup>, apico-coronal implant position, and prosthesis design (emergence profile) <sup>36</sup>. A randomized clinical trial on the treatment of peri-implant mucositis demonstrated that implants with supra-mucosal restorative margins exhibited significantly greater reductions in PD following treatment compared to those with submucosal restoration margins <sup>37</sup>. Moreover, a recently published systematic review showed that implants with an internal tapered connection exhibited lower PD than implants with non-tapered connections <sup>38</sup>. These prosthetic and abutment-related factors are more likely to influence PD measurements after regenerative treatment compared to resective surgery with apical positioning of the tissues. For this reason, after regenerative treatment, we propose that it is not possible to define a range of specific

probing depth values to differentiate between health and mucositis. This corroborates what was stated in the 2017 World Workshop in that it is not possible to define a range of probing depths compatible with health, and of more importance are the clinical signs of inflammation<sup>7</sup>. However, PD  $\geq 6$  mm is indicative of recurrent/refractory peri-implantitis. Contrarily, after resective treatment, minimal to no influence of abutment and prosthetic-related factors are expected due to apical positioning of the tissues. Therefore, a PD measurement  $\leq 4$  mm is compatible with health in this scenario and deeper PDs are expected only when inflammation and/or progressive bone loss is present. The presence of inflammation can result in decreased resistance to probing and edema of the gingival margin resulting in deeper PD. In addition, other factors which can generally impact PD measurements include size of the probe, probing pressure, and exposed implant threads<sup>39</sup>.

This classification provides threshold values that in the vast majority of cases can aid in differentiating between health and disease. However, clinical judgement is needed when interpreting peri-implant probing depths, as in some cases, elevated probing depths could be associated with both healthy implants and peri-implant mucositis. Hence, in these cases, marginal bone changes should prevail over pocket depth measurements in distinguishing between peri-implant health/mucositis and peri-implantitis.

### *Radiographic bone loss*

The 2017 World Workshop has proposed classifications and case definitions for peri-implant diseases and conditions describing peri-implant health, peri-implant mucositis, and peri-implantitis. The presence of progressive marginal bone loss (MBL) with a threshold for measurement error of 0.5 mm is the main parameter to assess the presence of peri-implantitis if radiographs taken at the time of implant placement are available. In case of the absence of previous radiographs, bone levels  $\geq 3$  mm apical from the most coronal portion of the intra-osseous part of the implant together with PD  $\geq 6$  mm and BOP are considered when diagnosing peri-implantitis. Nevertheless, progressive MBL is the main factor in peri-implantitis diagnosis, since it is the unique differential factor between mucositis and peri-implantitis, as BOP and deep PD can be present in both entities. Accordingly, in the present article, MBL progression after therapy (considering a 0.5 mm error) is the main clinical parameter to determine disease progression<sup>7</sup>.

In case of a submerged regenerative approach, the bone remodeling which occurs due to the formation of the supra-crestal attachment soon after re-opening and crown placement should not be considered progressive bone loss. It is well-known that MBL is a progressive event, normally not due to surgical procedures<sup>40</sup>, that follows a non-linear trend<sup>41</sup>, and that usually begins as a consequence

of biological width establishment or supra-crestal tissue remodelling after crown placement <sup>42</sup>. Indeed, it has been seen that bone remodeling usually occurs in the first 4-6 months with minimal changes of the marginal bone levels occurring after 8 months and up to 5 years <sup>35, 40, 43-45</sup>. The type of connection <sup>46</sup> and prosthetic abutment height <sup>47</sup> have also been shown to play an important role in the physiological or pathological progression of MBL. It is important to highlight that the nature of the biomaterial used for regenerative techniques can influence the radiographic presentation of the regenerated area.

#### *Classification of peri-implant status after surgical treatment for peri-implantitis*

The diagnostic assessment is based on clinical and radiographic findings with the main criteria being PD, BOP/visual inspection, and radiographic crestal bone levels (Table 1). Visual inspection should include assessment of tissue colour, contour, and texture as well as the pattern of BOP tendency (isolated spots, linear, or profuse) <sup>48</sup>. After resective treatment for peri-implantitis, peri-implant status can be classified as:

1. Healthy implant with a reduced support (Figure 2A)
2. Peri-implant mucositis with a reduced support (Figure 2B)
3. Recurrent/refractory peri-implantitis (Figure 2C)

A reduced support is an expected outcome of resective treatment. Although there is evidence in the literature that this surgical modality <sup>49</sup> as well as non-surgical therapy <sup>50</sup> can lead to partial regeneration, the final outcome will still result in an implant with a reduced support. Recurrent/refractory peri-implantitis after resective treatment is characterized by progressive increase in pocket depth and marginal bone loss. It is also important to note that clinical peri-implant health on a reduced support can exist for non-peri-implantitis patients who present with recession and attachment loss for causes including but not limited to implant malpositioning, thin soft tissues, and untreated hard tissue deficiencies present prior to implant placement <sup>51</sup>. These cases can also be diagnosed as either peri-implant health/mucositis with a reduced support according to the proposed classification.

After regenerative treatment for peri-implantitis, the peri-implant status can be classified according to the same diagnoses (Figure 3B, 3D, 3E) with the addition of healthy implant after complete regeneration (Figure 3A) and peri-implant mucositis after complete regeneration (Figure 3C) for the clinical scenarios where bone fill up to the height of the implant shoulder is achieved. If only partial regeneration is achieved, the potential diagnoses of peri-implant status are peri-implant



health or mucositis with a reduced support. The presence of progressive bone loss is indicative of recurrent/refractory peri-implantitis.

The purist approach of resective or regenerative treatment alone is not always indicated since some lesions may present with complex morphologies that are best treated with a combination of these modalities. In cases where a combined resective and regenerative approach is utilized, the outcome will be a reduced support since regeneration in this scenario will not reproduce the bone level at implant placement (healthy implant after complete regeneration).

The goal of the proposed classification is to guide diagnosis of peri-implant status post-treatment for peri-implantitis taking into consideration all the possible clinical scenarios that a clinician can experience in everyday practice. Clinical and radiographic parameters needed for diagnosis must be obtained during at least two separate visits spaced six months apart in order to establish evidence of progression or stability post-treatment. It is valuable to consider that in some cases during regeneration, it may be necessary to remove the prosthesis during the course of peri-implantitis treatment to allow for submerged healing<sup>52</sup>. If the prosthesis is removed during the course of treatment, then the timing for diagnosis must take this into account. The 6-month duration between the two separate visits needed to establish a post-treatment diagnosis must occur when the implant is loaded. The flowchart in Figure 4 describes in detail the decision-making process to arrive at a diagnosis taking into account all the possible clinical scenarios.

#### *Success criteria after surgical treatment for peri-implantitis*

The present article does not aim to suggest the best therapeutic approach, but instead provides a framework to arrive at a diagnosis for an implant previously treated for peri-implantitis. After resective or regenerative therapy for the treatment of peri-implantitis, it is essential to differentiate between disease progression and stability. The proposed classification system can be utilized to differentiate between a successful treatment outcome and cases that require further treatment. After resective treatment, a successful outcome is defined as healthy implant with a reduced support. After regenerative therapy, a successful outcome is described as either healthy implant after complete regeneration if full regeneration is achieved, or healthy implant with a reduced support. It is important to note that even if complete bone fill of the bony defect is attained after regenerative therapy, the implant may still present with reduced support if the crest of the intra-bony defect has resorbed apical to its original position. This scenario corresponds to healthy implant with a reduced support and is still considered a treatment success as disease progression was arrested and stable bone levels with healthy peri-implant soft tissues were attained.

## *Conclusion*

Evaluating the peri-implant condition after surgery is essential in establishing a post-treatment diagnosis to inform post-surgical decision-making. Providing a framework for classifying different variations of health and disease facilitates standardization of terminology and concepts used in communication amongst clinicians and researchers. Our classification system is a proposal which aims to align with and build upon the recent 2017 World Workshops on peri-implant diseases and conditions. Future studies are needed to validate the proposed classification system in order to evaluate its use in patient care.

## **Acknowledgements**

We would like to thank Dr. Fredric Kauffmann for his critical appraisal of this manuscript and for providing valuable suggestions for improvement. All authors declared they have no conflict of interest related to this report.

## **Author Contributions**

Andrea Ravidá<sup>1</sup> DDS, MS, Matthew Galli<sup>1</sup> DDS, Rafael Siqueira<sup>1</sup> DDS, MS, PhD, Muhammad H.A. Saleh<sup>1,2</sup> BDS, MS, Pablo Galindo Moreno DDS, MS, PhD<sup>3</sup>, Hom-Lay Wang<sup>1</sup> DDS, MS, PhD.

A.R., M.G., R.S., H-L.W. contributed to conception, design, data acquisition and interpretation, drafted and critically revised the manuscript;

M.H.A.S., contributed to conception, design, data acquisition, drafted and critically revised the manuscript;

P.G.M., contributed to data interpretation, critically revised the manuscript;

All authors gave final approval and agree to be accountable for all aspects of the work.

This article is protected by copyright. All rights reserved.

## References

1. Schwarz F, Derks J, Monje A, Wang HL. Peri-implantitis. *Journal of periodontology* 2018;89 Suppl 1:S267-S290.
2. Monje A, Pons R, Insua A, Nart J, Wang HL, Schwarz F. Morphology and severity of peri-implantitis bone defects. *Clin Implant Dent Relat Res* 2019;21:635-643.
3. Loe H, Theilade E, Jensen SB. Experimental Gingivitis in Man. *Journal of periodontology* 1965;36:177-187.
4. Pontoriero R, Tonelli MP, Carnevale G, Mombelli A, Nyman SR, Lang NP. Experimentally induced peri-implant mucositis. A clinical study in humans. *Clin Oral Implants Res* 1994;5:254-259.
5. Heitz-Mayfield LJA, Salvi GE. Peri-implant mucositis. *Journal of periodontology* 2018;89 Suppl 1:S257-S266.
6. Papapanou PN, Sanz M, Buduneli N, et al. Periodontitis: Consensus report of workgroup 2 of the 2017 World Workshop on the Classification of Periodontal and Peri-Implant Diseases and Conditions. *J Clin Periodontol* 2018;45 Suppl 20:S162-S170.
7. Berglundh T, Armitage G, Araujo MG, et al. Peri-implant diseases and conditions: Consensus report of workgroup 4 of the 2017 World Workshop on the Classification of Periodontal and Peri-Implant Diseases and Conditions. *Journal of periodontology* 2018;89 Suppl 1:S313-S318.
8. Chapple ILC, Mealey BL, Van Dyke TE, et al. Periodontal health and gingival diseases and conditions on an intact and a reduced periodontium: Consensus report of workgroup 1 of the 2017 World Workshop on the Classification of Periodontal and Peri-Implant Diseases and Conditions. *Journal of periodontology* 2018;89 Suppl 1:S74-S84.
9. Tonetti MS, Greenwell H, Kornman KS. Staging and grading of periodontitis: Framework and proposal of a new classification and case definition. *Journal of periodontology* 2018;89 Suppl 1:S159-S172.
10. Elani HW, Starr JR, Da Silva JD, Gallucci GO. Trends in Dental Implant Use in the U.S., 1999-2016, and Projections to 2026. *Journal of dental research* 2018;97:1424-1430.
11. Tarnow DP. Increasing Prevalence of Peri-implantitis: How Will We Manage? *Journal of dental research* 2016;95:7-8.
12. Koldslund OC, Scheie AA, Aass AM. Prevalence of peri-implantitis related to severity of the disease with different degrees of bone loss. *Journal of periodontology* 2010;81:231-238.
13. Derks J, Tomasi C. Peri-implant health and disease. A systematic review of current epidemiology. *J Clin Periodontol* 2015;42 Suppl 16:S158-171.

14. Derks J, Schaller D, Hakansson J, Wennstrom JL, Tomasi C, Berglundh T. Effectiveness of Implant Therapy Analyzed in a Swedish Population: Prevalence of Peri-implantitis. *Journal of dental research* 2016;95:43-49.
15. American Academy of Periodontology Task Force Report on the Update to the 1999 Classification of Periodontal Diseases and Conditions. *Journal of periodontology* 2015;86:835-838.
16. Englezos E, Cosyn J, Koole S, Jacquet W, De Bruyn H. Resective Treatment of Peri-implantitis: Clinical and Radiographic Outcomes After 2 Years. *Int J Periodontics Restorative Dent* 2018;38:729-735.
17. Schwarz F, Hegewald A, John G, Sahm N, Becker J. Four-year follow-up of combined surgical therapy of advanced peri-implantitis evaluating two methods of surface decontamination. *J Clin Periodontol* 2013;40:962-967.
18. Romeo E, Lops D, Chiapasco M, Ghisolfi M, Vogel G. Therapy of peri-implantitis with resective surgery. A 3-year clinical trial on rough screw-shaped oral implants. Part II: radiographic outcome. *Clin Oral Implants Res* 2007;18:179-187.
19. Carcuac O, Derks J, Abrahamsson I, Wennstrom JL, Petzold M, Berglundh T. Surgical treatment of peri-implantitis: 3-year results from a randomized controlled clinical trial. *J Clin Periodontol* 2017;44:1294-1303.
20. Serino G, Turri A. Outcome of surgical treatment of peri-implantitis: results from a 2-year prospective clinical study in humans. *Clin Oral Implants Res* 2011;22:1214-1220.
21. Froum SJ, Froum SH, Rosen PS. A Regenerative Approach to the Successful Treatment of Peri-implantitis: A Consecutive Series of 170 Implants in 100 Patients with 2- to 10-Year Follow-up. *Int J Periodontics Restorative Dent* 2015;35:857-863.
22. Schwarz F, Sahm N, Schwarz K, Becker J. Impact of defect configuration on the clinical outcome following surgical regenerative therapy of peri-implantitis. *J Clin Periodontol* 2010;37:449-455.
23. Lang NP, Adler R, Joss A, Nyman S. Absence of bleeding on probing. An indicator of periodontal stability. *J Clin Periodontol* 1990;17:714-721.
24. Badersten A, Nilveus R, Egelberg J. Effect of nonsurgical periodontal therapy. VII. Bleeding, suppuration and probing depth in sites with probing attachment loss. *J Clin Periodontol* 1985;12:432-440.
25. Kaldahl WB, Kalkwarf KL, Patil KD, Molvar MP. Relationship of gingival bleeding, gingival suppuration, and supragingival plaque to attachment loss. *Journal of periodontology* 1990;61:347-351.
26. Chaves ES, Caffesse RG, Morrison EC, Stults DL. Diagnostic discrimination of bleeding on probing during maintenance periodontal therapy. *American journal of dentistry* 1990;3:167-170.

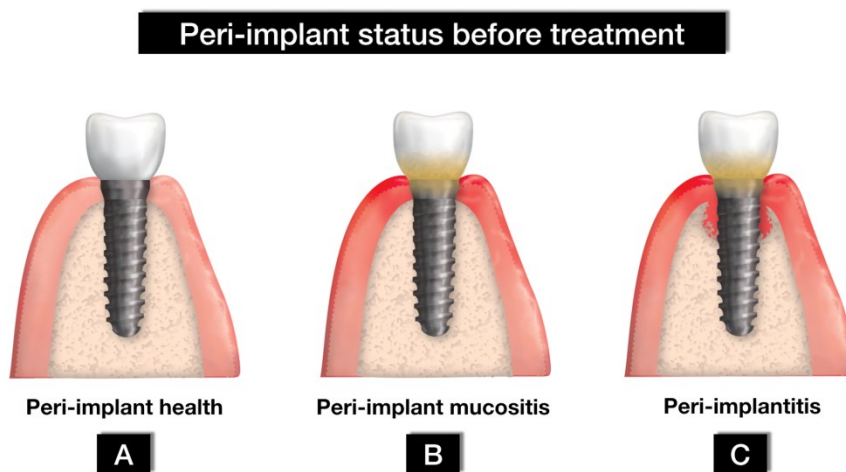
27. Lindhe J, Haffajee AD, Socransky SS. Progression of periodontal disease in adult subjects in the absence of periodontal therapy. *J Clin Periodontol* 1983;10:433-442.
28. Gerber JA, Tan WC, Balmer TE, Salvi GE, Lang NP. Bleeding on probing and pocket probing depth in relation to probing pressure and mucosal health around oral implants. *Clin Oral Implants Res* 2009;20:75-78.
29. Abrahamsson I, Berglundh T, Wennstrom J, Lindhe J. The peri-implant hard and soft tissues at different implant systems. A comparative study in the dog. *Clin Oral Implants Res* 1996;7:212-219.
30. Cionca N, Hashim D, Cancela J, Giannopoulou C, Mombelli A. Pro-inflammatory cytokines at zirconia implants and teeth. A cross-sectional assessment. *Clin Oral Investig* 2016;20:2285-2291.
31. Lang NP, Nyman S, Senn C, Joss A. Bleeding on probing as it relates to probing pressure and gingival health. *J Clin Periodontol* 1991;18:257-261.
32. Lang NP, Tonetti MS. Periodontal diagnosis in treated periodontitis. Why, when and how to use clinical parameters. *J Clin Periodontol* 1996;23:240-250.
33. Karayiannis A, Lang NP, Joss A, Nyman S. Bleeding on probing as it relates to probing pressure and gingival health in patients with a reduced but healthy periodontium. A clinical study. *J Clin Periodontol* 1992;19:471-475.
34. Jepsen S, Ruhling A, Jepsen K, Ohlenbusch B, Albers HK. Progressive peri-implantitis. Incidence and prediction of peri-implant attachment loss. *Clin Oral Implants Res* 1996;7:133-142.
35. Hermann JS, Buser D, Schenk RK, Schoolfield JD, Cochran DL. Biologic Width around one- and two-piece titanium implants. *Clin Oral Implants Res* 2001;12:559-571.
36. Caram SJ, Huynh-Ba G, Schoolfield JD, Jones AA, Cochran DL, Belser UC. Biologic width around different implant-abutment interface configurations. A radiographic evaluation of the effect of horizontal offset and concave abutment profile in the canine mandible. *Int J Oral Maxillofac Implants* 2014;29:1114-1122.
37. Heltz-Mayfield LJ, Salvi GE, Botticelli D, et al. Anti-infective treatment of peri-implant mucositis: a randomised controlled clinical trial. *Clin Oral Implants Res* 2011;22:237-241.
38. Yu X, Han Y, Wang J. Is an internal tapered connection more efficient than an internal nontapered connection? A systematic review and meta-analysis. *J Prosthet Dent* 2019. doi: 10.1016/j.prosdent.2019.07.018. Ahead of Print E-pub.
39. Mombelli A, Lang NP. The diagnosis and treatment of peri-implantitis. *Periodontol* 2000 1998;17:63-76.

40. Galindo-Moreno P, Leon-Cano A, Ortega-Oller I, Monje A, F OV, Catena A. Marginal bone loss as success criterion in implant dentistry: beyond 2 mm. *Clin Oral Implants Res* 2015;26:e28-e34.
41. Borges T, Leitao B, Pereira M, Carvalho A, Galindo-Moreno P. Influence of the abutment height and connection timing in early peri-implant marginal bone changes: A prospective randomized clinical trial. *Clin Oral Implants Res* 2018;29:907-914.
42. Cochran DL, Hermann JS, Schenk RK, Higginbottom FL, Buser D. Biologic width around titanium implants. A histometric analysis of the implanto-gingival junction around unloaded and loaded nonsubmerged implants in the canine mandible. *Journal of periodontology* 1997;68:186-198.
43. de Siqueira RAC, Fontao F, Sartori IAM, Santos PGF, Bernardes SR, Tioosi R. Effect of different implant placement depths on crestal bone levels and soft tissue behavior: a randomized clinical trial. *Clin Oral Implants Res* 2017;28:1227-1233.
44. de Siqueira RAC, Savaget Goncalves Junior R, Dos Santos PGF, de Mattias Sartori IA, Wang HL, Fontao F. Effect of different implant placement depths on crestal bone levels and soft tissue behavior: A 5-year randomized clinical trial. *Clin Oral Implants Res* 2019. doi: 10.1111/clr.13569. Ahead of Print E-pub 2020
45. Ericsson I, Nilner K, Klinge B, Glantz PO. Radiographical and histological characteristics of submerged and nonsubmerged titanium implants. An experimental study in the Labrador dog. *Clin Oral Implants Res* 1996;7:20-26.
46. Laurell L, Lundgren D. Marginal bone level changes at dental implants after 5 years in function: a meta-analysis. *Clin Implant Dent Relat Res* 2011;13:19-28.
47. Galindo-Moreno P, Leon-Cano A, Ortega-Oller I, et al. Prosthetic Abutment Height is a Key Factor in Peri-implant Marginal Bone Loss. *Journal of dental research* 2014;93:80S-85S.
48. Mombelli A, van Oosten MA, Schurch E, Jr., Land NP. The microbiota associated with successful or failing osseointegrated titanium implants. *Oral Microbiol Immunol* 1987;2:145-151.
49. Carral C, Munoz F, Permuy M, Linares A, Dard M, Blanco J. Mechanical and chemical implant decontamination in surgical peri-implantitis treatment: preclinical "in vivo" study. *J Clin Periodontol* 2016;43:694-701.
50. Linares A, Pico A, Blanco C, Blanco J. Adjunctive Systemic Metronidazole to Nonsurgical Therapy of Peri-implantitis with Intrabony Defects: A Retrospective Case Series Study. *Int J Oral Maxillofac Implants* 2019;34:1237-1245.
51. Hammerle CHF, Tarnow D. The etiology of hard- and soft-tissue deficiencies at dental implants: A narrative review. *J Clin Periodontol* 2018;45 Suppl 20:S267-S277.
52. Machtei EE. Treatment Alternatives to Negotiate Peri-Implantitis. *Adv Med* 2014;2014:487903.

Table and Figure Legends:

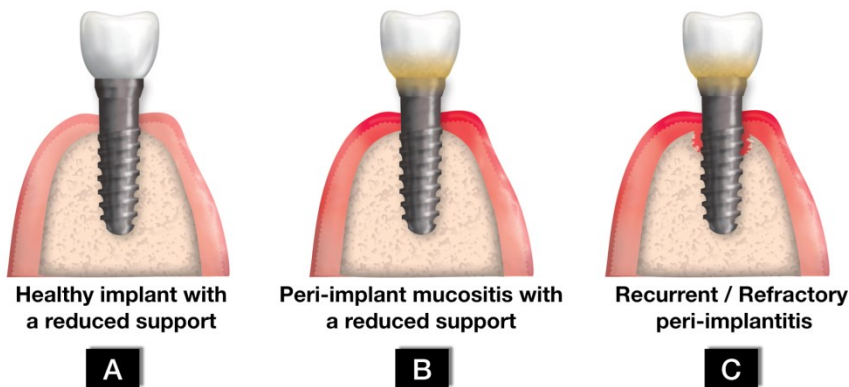
Table 1: Diagnosis of peri-implant status following peri-implantitis treatment for both resective and regenerative procedures.

Figure 1: Peri-implant status before treatment: health (1A), peri-implant mucositis (1B), or peri-implantitis (1C)



*Figure 2: Peri-implant status after resective treatment: A reduced level of support is an expected outcome of resective treatment. 2A: Healthy implant with a reduced support denotes a successful treatment outcome with no progression of bone loss and resolution of inflammation. 2B: Peri-implant mucositis with a reduced support is characterized by inflammation localized within the soft tissue without progressive bone loss. 2C: Recurrent/refractory peri-implantitis corresponds with progressive bone loss after treatment. Note the smooth surface of the supra-bony portion of the implant after implantoplasty.*

### Peri-implant status after resective treatment



Author



*Figure 3: Peri-implant status after regenerative treatment: 3A) Healthy implant after complete regeneration denotes a successful treatment outcome and is characterized by complete regeneration of the bone support to the original position at the time of implant placement. 3B) Healthy implant with a reduced support is another possible treatment outcome where partial bone fill is attained. In addition, this outcome is possible in cases of complete bone fill if the crest of the intra-bony defect has resorbed apical to its original position. 3C) Peri-implant mucositis after complete regeneration corresponds to the clinical scenario where complete regeneration has been attained but soft tissue inflammation is present. 3D) Peri-implant mucositis with a reduced support corresponds to a regenerative outcome where the bone level is apical to the original position at the time of implant placement and soft tissue inflammation is present. 3E) Recurrent/refractory peri-implantitis is characterized by progressive bone loss after treatment.*

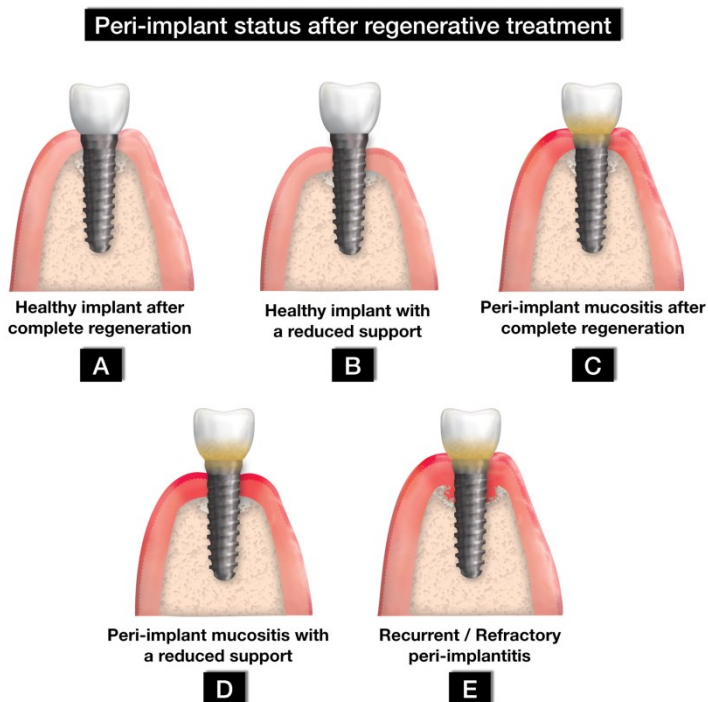


Figure 4: A flowchart illustrating how to utilize the proposed classification system for diagnosing peri-implant status following peri-implantitis treatment. Baseline radiographic and clinical parameters refer to pre-surgical charting and post-surgical radiographs. If signs and symptoms of inflammation such as suppuration are present the implant must be treated accordingly. If the prosthesis must be removed during the course of treatment, the 6-month duration between the two separate visits needed to establish a post-treatment diagnosis must occur after the implant prosthesis is re-inserted, and the implant is loaded.

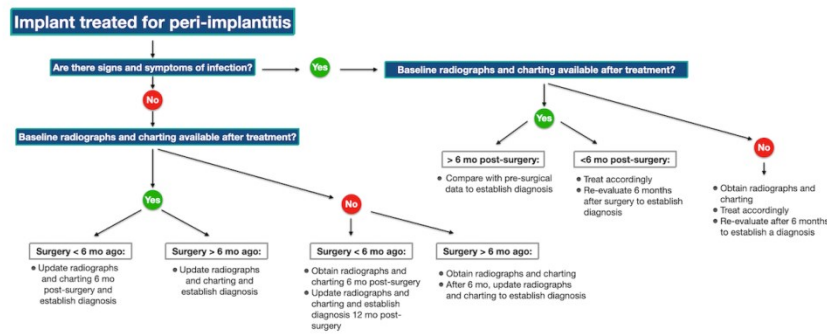


Table 1: Diagnosis of peri-implant status following peri-implantitis treatment for both resective and regenerative procedures.

<b>Diagnosis of peri-implant status after resective treatment</b>			
<b>Diagnosis</b>	<b>PD</b>	<b>BOP/Clinical presentation</b>	<b>Radiographic bone loss</b>
Healthy implant with a reduced support	$\leq 4 \text{ mm}$	Negative or positive without tissue color and texture changes related to inflammation (clinical judgement). No evidence of suppuration.	No progressive bone loss
Peri-implant mucositis with a reduced support	$< 6 \text{ mm}$	Positive with tissue color and texture changes related to inflammation and/or suppuration	No progressive bone loss
Recurrent/Refractory peri-implantitis	$\geq 4 \text{ mm}$	Positive with tissue color and texture changes related to inflammation and/or suppuration	Progressive bone loss
<b>Diagnosis of peri-implant status after regenerative treatment</b>			
<b>Diagnosis</b>	<b>PD</b>	<b>BOP/Clinical presentation</b>	<b>Radiographic bone loss</b>
Healthy implant after complete regeneration	Not possible to define	Negative or positive without tissue color and texture changes related to inflammation (clinical judgement). No evidence of suppuration.	Complete bone fill 6 months after surgery
Healthy implant with a reduced support	Not possible to define	Negative or positive without tissue color and texture changes related to inflammation (clinical judgement). No evidence of suppuration.	Partial bone fill 6 months after surgery
Peri-implant mucositis after complete regeneration	Not possible to define	Positive with tissue color and texture changes related to inflammation and/or suppuration	Complete bone fill 6 months after surgery
Peri-implant mucositis with a reduced support	Not possible to define	Positive with tissue color and texture changes related to inflammation and/or suppuration	Partial bone fill 6 months after surgery
Recurrent/Refractory peri-implantitis	$\geq 6 \text{ mm}$	Positive with tissue color and texture changes related to inflammation and/or suppuration	Progressive bone loss