



ORIGINAL COMMUNICATION

Mandibular canal vs. inferior alveolar canal: Evidence-based terminology analysis

Joe Iwanaga^{1,2,3}  | Yuki Matsushita^{4,5} | Tess Decater^{1,6} | Soichiro Ibaragi⁷ | R. Shane Tubbs^{1,6,8,9} ¹Department of Neurosurgery, Tulane Center for Clinical Neurosciences, Tulane University School of Medicine, New Orleans, Louisiana²Dental and Oral Medical Center, Kurume University School of Medicine, Kurume, Japan³Division of Gross and Clinical Anatomy, Department of Anatomy, Kurume University School of Medicine, Kurume, Japan⁴School of Dentistry, University of Michigan, Ann Arbor, Michigan⁵Department of Clinical Oral Oncology, Nagasaki University Graduate School of Biomedical Sciences, Nagasaki, Japan⁶Department of Anatomical Sciences, St. George's University, St. George's, Grenada⁷Department of Oral and Maxillofacial Surgery, Okayama University Graduate School of Medicine, Dentistry and Pharmaceutical Sciences, Okayama, Japan⁸Department of Structural and Cellular Biology, Tulane University School of Medicine, New Orleans, Louisiana⁹Department of Neurosurgery and Ochsner Neuroscience Institute, Ochsner Health System, New Orleans, Louisiana

Correspondence

Joe Iwanaga, Department of Neurosurgery, Tulane Center for Clinical Neurosciences, Tulane University School of Medicine, 131 S. Robertson Street, Suite 1300, New Orleans, LA 70112.
Email: iwanagajoe@ca@gmail.com

Abstract

Introduction: The mandibular canal, as it was formerly named in *Terminologia Anatomica (TA)*, has also been called the inferior alveolar (nerve) canal in many scientific publications. This study was conducted to investigate how these terms have been understood in different regions and different areas of expertise and to discuss the appropriate future application of the term “mandibular canal.”**Methods:** A literature search was conducted using PubMed, and articles using different terms for this structure were classified into two groups, inferior alveolar canal/inferior alveolar nerve canal (IAC/IANC) and the mandibular canal (MC). The 50 most recent articles in each group were included. Publication year, journal title, country of the first author, and affiliation of all authors were recorded in both groups for all 100 articles.**Results:** There was a significant difference between the IAC/IANC and MC groups in the numbers of anatomy journals, other journals, and anatomy affiliations. Turkey published most frequently with a total of 15 articles, followed by Iran with 10 articles, and China/India/United States with seven each. When the six countries of the first author that had three or more publications in each group were compared, only Turkey appeared in both groups; otherwise, different countries were in the two groups.**Conclusions:** Based on the results of this analysis, and considering that the tentative new term “inferior alveolar foramen” is used in the latest *TA*, we suggest that the mandibular canal should be renamed the “inferior alveolar canal.”

KEYWORDS

dentistry, inferior alveolar canal, inferior alveolar foramen, mandibular canal, mandibular foramen, *Terminologia Anatomica*, terminology

1 | INTRODUCTION

Physicians and anatomists often use different terms for the same structures (Gardner, Stowell, & Dutlinger, 1947; Tubbs et al., 2005). The use of different terms, which can vary from region and discipline, might result in miscommunication, translation issues, or potentially, medical complications. One example of diverse anatomical term usage is the mandibular canal versus the inferior alveolar canal.

The mandibular canal is the pathway for the inferior alveolar neurovascular bundles in the mandible. It has the mandibular foramen and mental foramen as entrance and exit, respectively (Stranding, 2015). “Mandibular canal” has long been the accepted anatomical term for this bony canal. However, many dentists and anatomists realize that the “inferior alveolar canal” (or even the “inferior alveolar nerve canal”) is also a well-known term for this canal and is accepted in many scientific journals (Mortazavi et al., 2019; Sánchez-Torres, Soler-Capdevila,

Ustrell-Barral, & Gay-Escoda, 2019). Thus, the terminology for this bony canal is often confusing. In general, a bony canal is named after the neurovascular bundle that passes through it, for example, the infraorbital and obturator foramina, and hypoglossal canals. The “mandibular canal” is a clear exception to this rule, so some believe it should be termed the “inferior alveolar canal” consistent with other bony canals. Notably, the Federative International Program for Anatomical Terminology (FIPAT), which prescribes international anatomical terminology, recently decided to use “inferior alveolar foramen” tentatively instead of “mandibular foramen” with the logic “there are other foramina in the mandible” in *Terminologia Anatomica second edition* published in 2019 (Figure 1) (FIPAT, 2019). Therefore, we believed now was a good time to align the term of the foramen with the term used for the canal. However, the “mandibular canal” is still the term of choice for this bony canal such that the following description is used: the inferior alveolar foramen is the entrance of the mandibular canal, through which the inferior neurovascular bundles pass (FIPAT, 2019). Such a description could lead to potential misunderstanding and, thus, should be simplified. Therefore, the goal of this study was to investigate how these terms are used and understood in different regions and areas of expertise and to discuss the appropriate future application of the term “mandibular canal.”

2 | MATERIALS AND METHODS

2.1 | Screening

A literature search was conducted using PubMed on February 10, 2020. The following search words were used: “inferior alveolar canal” OR “inferior alveolar nerve canal” and “inferior alveolar canal” OR “inferior alveolar nerve canal” OR “mandibular canal.” These searches resulted in 277 and 1,223 articles, respectively. From the latest article in the list on PubMed, the Title, Abstract, Manuscript, Figure, and Figure Legends were reviewed. Terms in the Keywords and References were not reviewed.

2.2 | “inferior alveolar canal” OR “inferior alveolar nerve canal” (277 article hits)

Commentaries and letters to the editor were excluded first.

The most recent, consecutive 50 articles containing “inferior alveolar canal” or “inferior alveolar nerve canal” were included (defined as the IAC/IANC group) (Adibi, Shahidi, Nikanjam, Paknahad, & Ranjbar, 2017; Afsa & Rahmati, 2017; Al-Ekrish et al., 2018; Al-Ekrish et al., 2020; Ali, Mosleh, & Shawky, 2018; Aljarbou, Aldosimani, Althumairy, Alhezam, & Aldawsari, 2019; Arbel et al., 2019; Atef & Mounir, 2018; Česaitienė, Česaitis, Junevičius, & Venskutonis, 2017; Y. Chen, Liu, Pei, Liu, & Pan, 2018; Clark, Barbu, Lorean, Mijiritsky, & Levin, 2017; Demirel & Akbulut, 2020; Dutra et al., 2019; Elkhateeb & Awad, 2018; Ghai & Choudhury, 2018; Goller Bulut & Köse, 2018; Gumusok, Alkurt, Museyibov, & Ucok, 2016; He, Wang, Hu, & Liu, 2019; Ishii, Abe, Moro, Yokomizo, & Kobayashi, 2017; Kablan, Abu-Sobeh, Lorean, & Levin, 2020; Khojastepour, Khaghaninejad, Hasanshahi, Forghani, & Ahrari, 2019; Kubota, Imai, Nakazawa, & Uzawa, 2020; S. Lee, Lee, Kim, & Nam, 2019; Liu, Sidell, Huon, & Torre, 2018; Luangchana, Pornprasertsuk-Damrongsri, Kitisubkanchana, & Wongchuensoontorn, 2019; Mortazavi, Baharvand, & Rezaeifar, 2018; Mortazavi, Baharvand, Safi, & Behnaz, 2019; Mortazavi, Baharvand, Safi, Dalaie, et al., 2019; Patil, Pai, Vineetha, Rajagopal, & Dkhar, 2019; Patrick, Birur, Gurushanth, Raghavan, & Gurudath, 2017; Pour, Sedaghati, & Shamshiri, 2020; Prakash et al., 2018; Qi et al., 2019; Rytönen & Ventä, 2018; Saha, Kedarnath, & Singh, 2019; Şahin, Odabaşı, Demiralp, Kurşun-Çakmak, & Aliyev, 2019; Sharifi, Beshkar, Mobayeni, & Hasheminasab, 2018; Shokry et al., 2019; Sirin, Yildirimturk, Horasan, & Guven, 2020; Tabrizi et al., 2019; Tachinami, Tomihara, Fujiwara, Nakamori, & Noguchi, 2017; Tudtiam et al., 2019; Uchida, Motoyoshi, Namura, & Shimizu, 2017; Uzun, Sumer, & Sumer, 2019; Vidya, Pathi, Rout, Sethi, & Sangamesh, 2019; Wang et al., 2018; Xie et al., 2019; Yong, Lum, Makmur, Seet, & Lim, 2019; Zahedi, Mostafavi, & Lotfirikan, 2018; Zirk et al., 2019).

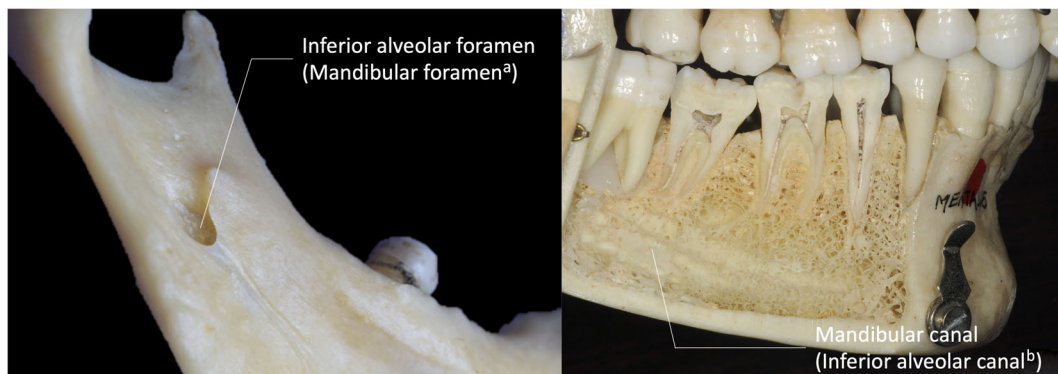


FIGURE 1 Mandible with labeling according to current terminology in *Terminologia Anatomica* second ed. ^aAccording to TA second ed., the mandibular foramen is tentatively categorized as a synonym of the inferior alveolar foramen. ^bAccording to TA second ed., the inferior alveolar canal is tentatively categorized as a synonym of the mandibular canal [Color figure can be viewed at wileyonlinelibrary.com]

2.3 | “inferior alveolar canal” OR “inferior alveolar nerve canal” OR “mandibular canal” (1,223 article hits)

Commentaries and letters to the editor were excluded first.

The articles that were included in the IAC/IANC group were excluded from this group. The most recent, consecutive 50 articles containing “mandibular canal” but neither “inferior alveolar canal” nor “inferior alveolar nerve canal” were included (defined as the MC group) (Abd Fattah, Hariri, Nambiar, Abu Bakar, & Abdul Rahman, 2019; Al-Shayyab, Qabba'ah, Alsoleihat, & Baqain, 2019; Alves, Dias, Mansa, & Machado, 2020; Arias et al., 2019; Bosykh, Turkina, Franco, Franco, & Makeeva, 2019; Bozkurt & Görürgöz, 2019; Burian et al., 2019; Cârstocea, Săndulescu, Hostiu, & Rusu, 2020; M. H. Chen et al., 2019; Costa et al., 2019; Esposito et al., 2019; Felice et al., 2019; Felice, Barausse, Pistilli, Ippolito, & Esposito, 2019; Fistarol, De Stavola, Fincato, & Bressan, 2019; Freire, Nascimento, Vasconcelos, Freitas, & Haiter-Neto, 2019; Friedrich, Matschke, & Wilczak, 2019; Iwanaga et al., 2020, 2020; Iwanaga, Wong, Kikuta, & Tubbs, 2019; Kalabalik & Aytuğar, 2019; Koç, Eroğlu, & Bilgili, 2019; Komal, Bedi, Wadhvani, Aurora, & Chauhan, 2020; K. C. Lee, Yoon, Philipone, & Peters, 2019; Liye et al., 2019; Matsuda, Yoshimura, & Sano, 2019; Matzen, Petersen, Schropp, & Wenzel, 2019; Matzen, Villefrance, Nørholt, Bak, & Wenzel, 2020; Munhoz, Arita, Nishimura, & Watanabe, 2019; Na et al., 2019; Ngeow & Chai, 2020a, 2020b; Nicol, Loncle, Pasquet, & Vacher, 2019; Okumuş & Dumlu, 2019; Oliveira et al., 2019; Ozdede, 2020; Pedersen, Matzen, Hermann, & Nørholt, 2019; Predoiu, Rusu, & Chiriță, 2019; Pucito, Lipski, Sroczyk-Jaszczyńska, Pucito, & Nowicka, 2020; Raju et al., 2019; Sahl, Alqahtani, Alqahtani, & Gallez, 2018; Satir, 2019; Sholapurkar & Davies, 2019; Sinha et al., 2019; Sun et al., 2019; Tereshchuk & Sukharev, 2019; Uğur Aydın & Göller Bulut, 2019; Valdec et al., 2019; Vranckx et al., 2019; Yalcin & Akyol, 2020; Yalcin & Artas, 2020).

2.3.1 | IAC/IANC group and MC group reviewed

The full text for both groups (100 articles) was reviewed again to confirm that the IAC/IANC group included the papers that used the term “inferior alveolar canal” and/or “inferior alveolar nerve canal” (either with or without mandibular canal), and the MC group included papers that used the term “mandibular canal” but neither “inferior alveolar canal” nor “inferior alveolar nerve canal” (Figure 2).

2.4 | Data collection

Publication year, journal title, country of the first author, and affiliations of all authors were recorded in both groups for all 100 articles.

Statistical analysis was made comparing the two groups using Student *t* tests with $p < .05$ considered significant.

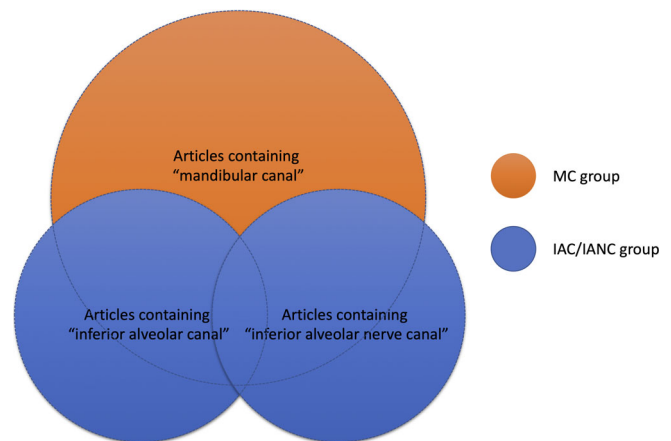


FIGURE 2 Inferior alveolar canal/inferior alveolar nerve canal (IAC/IANC) group and mandibular canal (MC) group [Color figure can be viewed at wileyonlinelibrary.com]

3 | RESULTS

3.1 | Publication year

The IAC/IANC group included six articles in 2020, 21 in 2019, 14 in 2018, eight in 2017, and one in 2016. The MC group included 12 articles in 2020, 37 in 2019, and one in 2018 (Figure 3).

3.2 | Journal

Journals were classified into three groups: Anatomy journals, Dental journals, and other journals.

“Anatomy journals” included any journals that focus on anatomy and morphology. “Dental journal” included any journals with at least one of the following in the title; oral, dent, maxillofacial, craniofacial, periodont, odont, endod, or quintessence. The journals that were not included in either of the above were categorized as “other journals.” The distribution of the journals is shown in Figure 4.

There was a statistically significant difference between the IAC/IANC and MC groups in the numbers of anatomy journals and other journals in which they were included ($p < .05$).

3.3 | Country

Turkey was the country that published most frequently with 15 articles out of the total 100, followed by Iran with 10 articles, and China/India/United States with seven articles each (Figure 5).

Iran, Turkey, and China were the countries that used the term “inferior alveolar canal” or “inferior alveolar nerve canal” most frequently. Turkey, the United States, and Brazil were the countries that used the term “mandibular canal” most frequently (Figure 6).

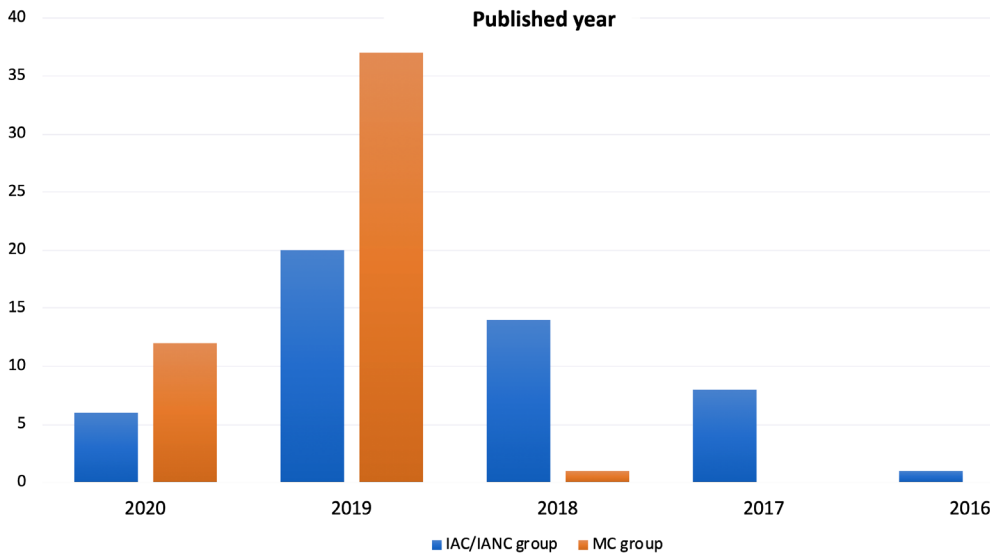


FIGURE 3 Difference between inferior alveolar canal/inferior alveolar nerve canal (IAC/IANC) group and mandibular canal (MC) group for the published year [Color figure can be viewed at wileyonlinelibrary.com]

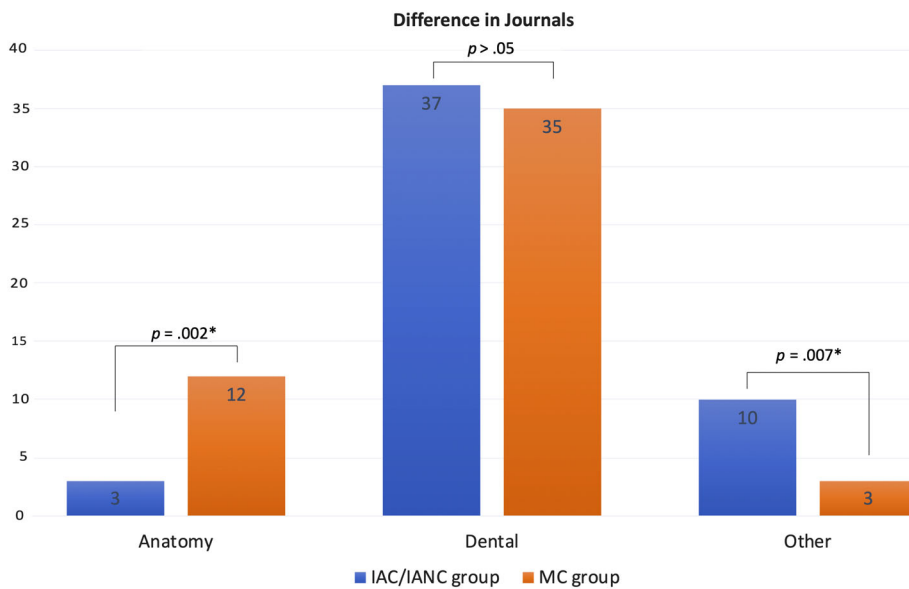


FIGURE 4 Difference between inferior alveolar canal/inferior alveolar nerve canal (IAC/IANC) group and mandibular canal (MC) group for three journal types [Color figure can be viewed at wileyonlinelibrary.com]

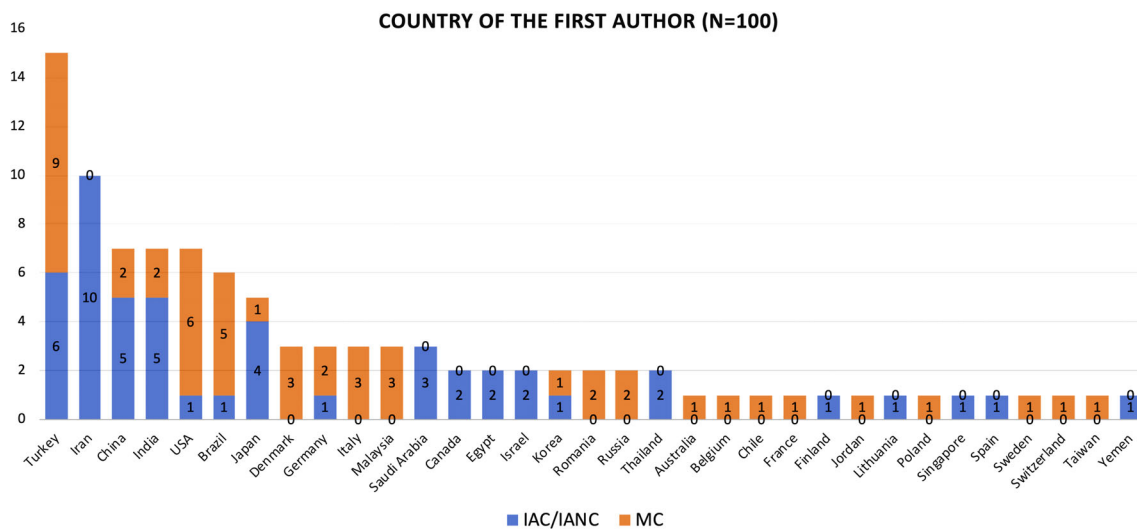


FIGURE 5 Country of the first author including both inferior alveolar canal/inferior alveolar nerve canal (IAC/IANC) group and mandibular canal (MC) group [Color figure can be viewed at wileyonlinelibrary.com]

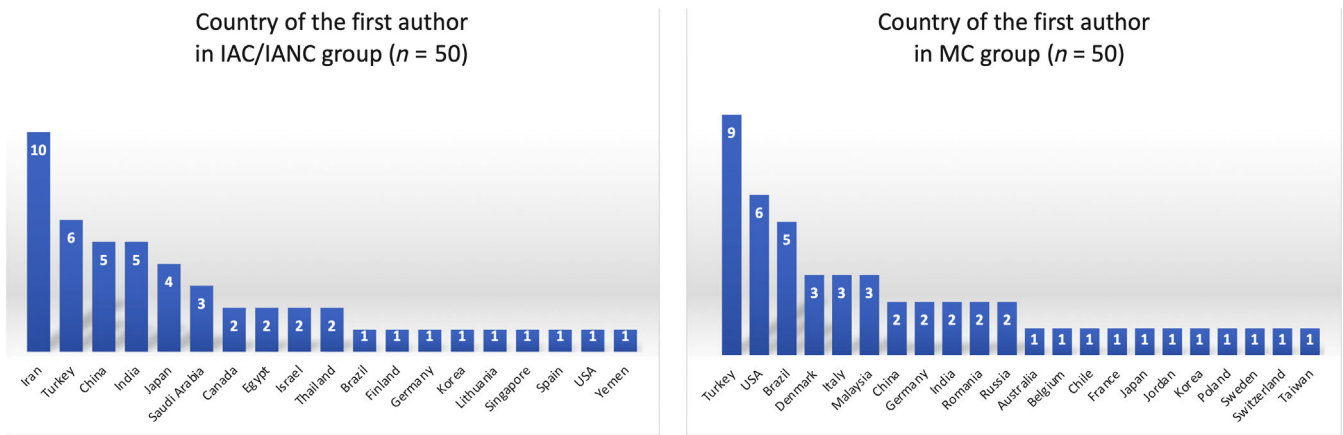
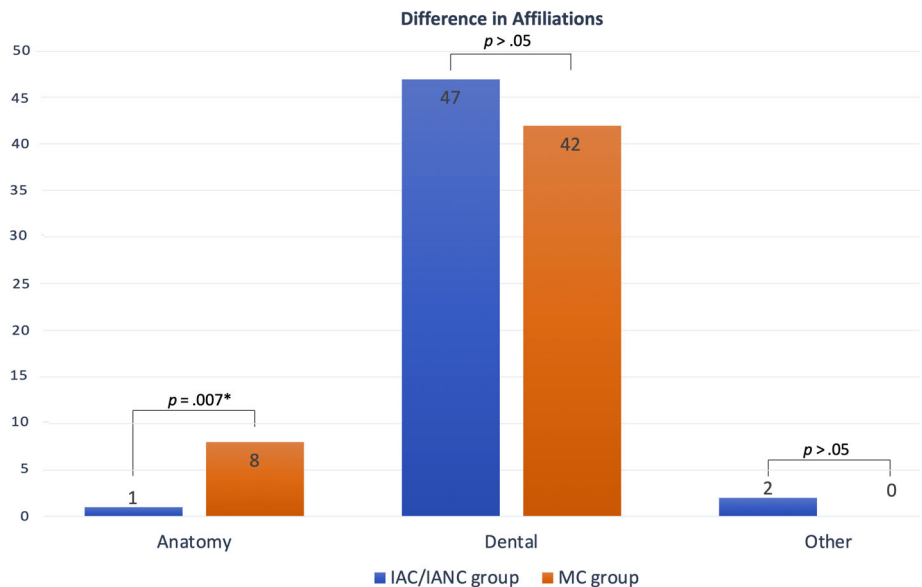


FIGURE 6 Country of the first author in the inferior alveolar canal/inferior alveolar nerve canal (IAC/IANC) group (left) and mandibular canal (MC) group (right) [Color figure can be viewed at wileyonlinelibrary.com]

FIGURE 7 Difference between inferior alveolar canal/inferior alveolar nerve canal (IAC/IANC) group and mandibular canal (MC) group for three affiliation types [Color figure can be viewed at wileyonlinelibrary.com]



When the countries of the first author that had three or more publications in each group were compared, only Turkey appeared in both groups; otherwise, the two groups were occupied by different countries.

3.4 | Affiliation

Three categories of affiliation were distinguished: Anatomy, Dental, and others.

Any article with anatomy or biology in the title or the affiliation of any co-authors was classified as an “anatomy affiliation.” Any that included oral, dent, maxillofacial, craniofacial, periodont, ortho, odont, or endod were categorized as a “dental affiliation.” If none of the above was included, the category applied was “other affiliation.”

The distribution of the affiliations is shown in Figure 7.

There was a statistically significant difference in the number of anatomy affiliations between the IAC/IANC and MC groups ($p < .05$).

4 | DISCUSSION

Anatomy has a long history with occasional changes in terminology. Terms for the mandibular canal are no exception and have changed many times over the years, for example, inferior alveolar canal (IAC), the inferior alveolar nerve canal (IANC), alveolar canal, dental canal, and the inferior dental canal (Mortazavi, Baharvand, Safi, Dalaie, et al., 2019; Schäfer & Thane, 1890; Standing, 2015).

In general, anatomists are more familiar with TA and usually use this terminology more strictly than dentists or others. Therefore, anatomists prefer to use the “mandibular canal” as this is the term in TA. This probably explains the significant difference between the

IAC/IANC and MC groups in anatomy journals. There was also a significant difference between the groups in the number of “other journals,” which included non-anatomy and non-dental journals. In other words, the editors/reviewers and readers of “other journals” might be less familiar with the terminology in TA or use it less strictly than those of “anatomy journals.”

Countries of the first author that had five or more publications were: Turkey (15), Iran (10), China (seven), India (seven), United States (seven), Brazil (six), and Japan (five). Among these, interestingly, no articles from Iran were categorized in the MC group; all 10 were in the IAC/IANC group. Also, most of the publications from China, India, and Japan were in the IAC/IANC group. When the countries of the first author that had three or more publications in each group were compared (Figure 6), only Turkey appeared in both groups; otherwise, the two groups were occupied by different countries. This implies a tendency to use only one of the two terms in those countries. However, this does not determine, which country uses the “right” term for the mandibular canal.

The affiliations of the authors also affected the results. There was a significant difference between the IAC/IANC and MC groups in the number of publications with an anatomy (or anatomy-related) affiliation. This could be interpreted as mentioned earlier: those with an anatomy affiliation, who are supposed to be more familiar with TA and are likely to use the terminology more strictly, are more likely to be anatomists than those with a dental affiliation.

As shown earlier, 277 and 1,223 articles in PubMed appeared in the “inferior alveolar canal” or “inferior alveolar nerve canal” and “inferior alveolar canal” or “inferior alveolar nerve canal” or “mandibular canal” searches, respectively. The number “277” is not small and should not be ignored. Both anatomists and dentists sometimes say “inferior alveolar canal is a wrong term” and refer to the TA as evidence, but they do not explore the matter. We believe that “the inferior alveolar canal” should not be considered a wrong term. It is probably used because of human nature/habit/comfort as the structure it denotes contains the inferior alveolar neurovascular bundles.

Our study shows the results of a small sampling ($n = 100$) from a potentially large pool of articles. If we continue to avoid addressing this difference in terminologies, the choice of term selection could become more polarized, that is, mandibular canal and inferior alveolar canal, in the near future depending on expertise or country.

5 | CONCLUSION

Based on this analysis and considering that the new tentative term “inferior alveolar foramen” is used in the latest TA, we suggest mandibular canal be renamed as the “inferior alveolar canal.”

6 | LIMITATIONS

There are limitations to this study. The data included were based only on a PubMed search. Some journals are not in PubMed, which could have affected the data analysis. As seen in the publication year data,

the MC group had no articles published in either 2017 or 2016 and only one in 2018, due to the limited number of articles included. In 2020, the number is still increasing because the data search was conducted in February. Therefore, we might be able to compare the numbers of publications between the two groups only in 2019 (21 articles in the IAC/IANC group vs. 37 in the MC group). There could be differences between radiology affiliations and other clinical affiliations, but we could not differentiate them because of complexities in the names of departments and the existence of multiple authors in the same articles. Some countries have unique medical terms in their language, and sometimes the meanings of these terms differ from those in English. Therefore, if they were directly translated into English, the authors' intended meaning could be lost.

CONFLICT OF INTEREST

The authors declare no potential conflict of interest.

ORCID

Joe Iwanaga  <https://orcid.org/0000-0002-8502-7952>

R. Shane Tubbs  <https://orcid.org/0000-0003-1317-1047>

REFERENCES

- Abd Fattah, S. Y. A. S., Hariri, F., Nambiar, P., Abu Bakar, Z., & Abdul Rahman, Z. A. (2019). Determining the accuracy of the mandibular canal region in 3D biomodels fabricated from CBCT scanned data: A cadaveric study. *Current Medical Imaging Reviews*, 15, 645–653.
- Adibi, S., Shahidi, S., Nikanjam, S., Paknahad, M., & Ranjbar, M. (2017). Influence of head position on the CBCT accuracy in assessment of the proximity of the root apices to the inferior alveolar canal. *Journal of Dentistry (Shiraz)*, 18, 181–186.
- Afsa, M., & Rahmati, H. (2017). Branching of mandibular canal on cone beam computed tomography images. *Singapore Dental Journal*, 38, 21–25.
- Al-Ekrish, A. A., Alfaleh, W., Hörmann, R., Alabdulwahid, A., Puelacher, W., & Widmann, G. (2018). Localization of the inferior alveolar canal using ultralow dose CT with iterative reconstruction techniques. *DentoMaxilloFacial Radiology*, 47, 20170477.
- Al-Ekrish, A. A., Alzahrani, A., Zaman, M. U., Alfaleh, W., Hörmann, R., & Widmann, G. (2020). Assessment of potential reduction in multidetector computed tomography doses using FBP and SAFIRE for detection and measurement of the position of the inferior alveolar canal. *Oral Surgery, Oral Medicine, Oral Pathology, Oral Radiology*, 129, 65–71.
- Ali, H. T., Moseleh, M. I., & Shawky, M. (2018). Variables predictive of the intensity of postoperative pain following mandibular third molar surgery: A prospective study. *Minerva Stomatologica*, 67, 111–116.
- Aljarbou, F. A., Aldosimani, M., Althumairy, R. I., Alhezam, A. A., & Aldawsari, A. I. (2019). An analysis of the first and second mandibular molar roots proximity to the inferior alveolar canal and cortical plates using cone beam computed tomography among the Saudi population. *Saudi Medical Journal*, 40, 189–194.
- Al-Shayyab, M. H., Qabba'ah, K., Alsoleihat, F., & Baqain, Z. H. (2019). Age and gender variations in the cone-beam computed tomographic location of mandibular canal: Implications for mandibular sagittal split osteotomy. *Medicina Oral, Patología Oral y Cirugía Bucal*, 24, e545–e554.
- Alves, F. R. F., Dias, M. C. C., Mansa, M. G. C. B., & Machado, M. D. (2020). Permanent labiomandibular paresthesia after bioceramic sealer extrusion: A case report. *Journal of Endodontics*, 46, 301–306.
- Arbel, Y., Lvovsky, A., Azizi, H., Hadad, A., Averbuch Zehavi, E., Via, S., ... Solomonov, M. (2019). Autotransplantation after primary bone repair of a recipient site with a large periradicular lesion: A case report. *International Endodontic Journal*, 52, 1789–1796.

- Arias, A., Venegas, C., Soto, N., Montiel, I., Farfán, C., Navarro, P., & Fuentes, R. (2019). Location and course of the mandibular canal in dentate patients: Morphometric study using cone beam computed tomography. *Folia Morphologica*. [Epub ahead of print]
- Atef, M., & Mounir, M. (2018). Computer-guided inferior alveolar nerve lateralization with simultaneous implant placement: A preliminary report. *The Journal of Oral Implantology*, 44, 192–197.
- Bosykh, Y. Y., Turkina, A. Y., Franco, R. P. A. V., Franco, A., & Makeeva, M. K. (2019). Cone beam computed tomography study on the relation between mental foramen and roots of mandibular teeth, presence of anterior loop and satellite foramina. *Morphologie*, 103, 65–71.
- Bozkurt, P., & Görürgöz, C. (2019). Detecting direct inferior alveolar nerve - Third molar contact and canal decorticalization by cone-beam computed tomography to predict postoperative sensory impairment. *Journal of Stomatology, Oral and Maxillofacial Surgery*. [Epub ahead of print]
- Burian, E., Probst, F. A., Weidlich, D., Cornelius, C. P., Maier, L., Robl, T., ... Probst, M. (2019). MRI of the inferior alveolar nerve and lingual nerve-anatomical variation and morphometric benchmark values of nerve diameters in healthy subjects. *Clinical Oral Investigations*. [Epub ahead of print]
- Cârstocea, L., Sândulescu, M., Hostiuc, S., & Rusu, M. C. (2020). The unusually lower position of the mandibular foramen and the canal of the neck of mandible. *Morphologie*, 104, 143–146.
- Česaitienė, G., Česaitis, K., Junevičius, J., & Venskutonis, T. (2017). The reliability of panoramic radiography versus cone beam computed tomography when evaluating the distance to the alveolar nerve in the site of lateral teeth. *Medical Science Monitor*, 23, 3247–3252.
- Chen, M. H., Kao, C. T., Yu-Fong Chang, J., Wang, Y. P., Wu, Y. H., & Chiang, C. P. (2019). Stafne bone defect of the molar region of the mandible. *Journal of Dental Sciences*, 14, 378–382.
- Chen, Y., Liu, J., Pei, J., Liu, Y., & Pan, J. (2018). The risk factors that can increase possibility of mandibular canal wall damage in adult: A cone-beam computed tomography (CBCT) study in a Chinese population. *Medical Science Monitor*, 24, 26–36.
- Clark, D., Barbu, H., Lorean, A., Mijiritsky, E., & Levin, L. (2017). Incidental findings of implant complications on postimplantation CBCTs: A cross-sectional study. *Clinical Implant Dentistry and Related Research*, 19, 776–782.
- Costa, E. D., Peyneau, P. D., Visconti, M. A., Devito, K. L., Ambrosano, G. M. B., & Verner, F. S. (2019). Double mandibular canal and triple mental foramina: Detection of multiple anatomical variations in a single patient. *General Dentistry*, 67, 46–49.
- Demirel, O., & Akbulut, A. (2020). Evaluation of the relationship between gonial angle and impacted mandibular third molar teeth. *Anatomical Science International*, 95, 134–142.
- Dutra, K. L., Haas, L. F., Zimmermann, G. S., Melo, G., Minamisako, M. C., Flores-Mir, C., & Corrêa, M. (2019). Prevalence of radiographic findings on jaws exposed to antiresorptive therapy: A meta-analysis. *DentoMaxilloFacial Radiology*, 48, 20180112.
- Elkhateeb, S. M., & Awad, S. S. (2018). Accuracy of panoramic radiographic predictor signs in the assessment of proximity of impacted third molars with the mandibular canal. *Journal of Taibah University Medical Sciences*, 13, 254–261.
- Esposito, M., Barausse, C., Pistilli, R., Piattelli, M., Di Simone, S., Ippolito, D. R., & Felice, P. (2019). Posterior atrophic jaws rehabilitated with prostheses supported by 5 × 5 mm implants with a nanostructured calcium-incorporated titanium surface or by longer implants in augmented bone. Five-year results from a randomised controlled trial. *International Journal of Oral Implantology (New Malden)*, 12, 39–54.
- Federative International Programme for Anatomical Terminology. (2019). *Terminologia anatomica* (2nd ed.).
- Felice, P., Barausse, C., Pistilli, R., Ippolito, D. R., & Esposito, M. (2019). Five-year results from a randomised controlled trial comparing prostheses supported by 5-mm long implants or by longer implants in augmented bone in posterior atrophic edentulous jaws. *International Journal of Oral Implantology (New Malden)*, 12, 25–37.
- Felice, P., Pistilli, R., Barausse, C., Piattelli, M., Buti, J., & Esposito, M. (2019). Posterior atrophic jaws rehabilitated with prostheses supported by 6-mm-long 4-mm-wide implants or by longer implants in augmented bone. Five-year post-loading results from a within-person randomised controlled trial. *International Journal of Oral Implantology (New Malden)*, 12, 57–72.
- Fistarol, F., De Stavola, L., Fincato, A., & Bressan, E. (2019). Mandibular canal position in posterior mandible: Anatomical study and surgical considerations in relation to bone harvesting procedures. *The International Journal of Periodontics & Restorative Dentistry*, 39, e211–e218.
- Freire, B. B., Nascimento, E. H. L., Vasconcelos, K. F., Freitas, D. Q., & Haiter-Neto, F. (2019). Radiologic assessment of mandibular third molars: An ex vivo comparative study of panoramic radiography, extraoral bitewing radiography, and cone beam computed tomography. *Oral Surgery, Oral Medicine, Oral Pathology, Oral Radiology*, 128, 166–175.
- Friedrich, R. E., Matschke, J., & Wilczak, W. (2019). Unilaterally enlarged mandibular foramina and canal associated with hyperplastic lymphatic tissue of inferior alveolar nerve: Case report and short literature survey. *Anticancer Research*, 39, 3991–4002.
- Gardner, W. J., Stowell, A., & Dutlinger, R. (1947). Resection of the greater superficial petrosal nerve in the treatment of unilateral headache. *Journal of Neurosurgery*, 4, 105–114.
- Ghai, S., & Choudhury, S. (2018). Role of panoramic imaging and cone beam CT for assessment of inferior alveolar nerve exposure and subsequent paresthesia following removal of impacted mandibular third molar. *Journal of Maxillofacial and Oral Surgery*, 17, 242–247.
- Goller Bulut, D., & Köse, E. (2018). Available bone morphology and status of neural structures in the mandibular interforaminal region: Three-dimensional analysis of anatomical structures. *Surgical and Radiologic Anatomy*, 40, 1243–1252.
- Gumusok, M., Alkurt, M. T., Museyibov, F., & Ucok, O. (2016). Evaluation of keratocystic odontogenic tumors using cone beam computed tomography. *Journal of Istanbul University Faculty of Dentistry*, 50, 32–37.
- He, J., Wang, J., Hu, Y., & Liu, W. (2019). Diagnosis and management of stafne bone cavity with emphasis on unusual contents and location. *Journal of Dental Sciences*, 14, 435–439.
- Ishii, S., Abe, S., Moro, A., Yokomizo, N., & Kobayashi, Y. (2017). The horizontal inclination angle is associated with the risk of inferior alveolar nerve injury during the extraction of mandibular third molars. *International Journal of Oral and Maxillofacial Surgery*, 46, 1626–1634.
- Iwanaga, J., Anand, M. K., Jain, M. N., Nagata, M., Matsushita, Y., Ibaragi, S., ... Tubbs, R. S. (2020). Microsurgical anatomy of the superior wall of the mandibular canal and surrounding structures: Suggestion for new classifications for dental implantology. *Clinical Anatomy*, 33, 223–231.
- Iwanaga, J., Kikuta, S., Ibaragi, S., Watanabe, K., Kusakawa, J., & Tubbs, R. S. (2020). Clinical anatomy of the accessory mandibular foramen: Application to mandibular ramus osteotomy. *Surgical and Radiologic Anatomy*, 42, 41–47.
- Iwanaga, J., Wong, T. L., Kikuta, S., & Tubbs, R. S. (2019). Stafne bone cavity: A rare cadaveric case report. *Anatomy & Cell Biology*, 52, 354–356.
- Kablan, F., Abu-Sobeh, A., Lorean, A., & Levin, L. (2020). Spontaneous mandibular fracture as a complication of inferior alveolar nerve transposition and placement of endosseous dental implants in the atrophic mandible: A review of the literature and a report of two cases and their nonsurgical conservative management. *Quintessence International*, 51, 230–237.
- Kalabalik, F., & Aytuğ, E. (2019). Localization of the mandibular canal in a Turkish population: A retrospective cone-beam computed tomography study. *Journal of Oral & Maxillofacial Research*, 10, e2.
- Khojastepour, L., Khaghaninejad, M. S., Hasanshahi, R., Forghani, M., & Ahrari, F. (2019). Does the Winter or Pell and Gregory classification

- system indicate the apical position of impacted mandibular third molars? *Journal of Oral and Maxillofacial Surgery*, 77, 2222.e1–2222.e9.
- Koç, A., Eroğlu, C. N., & Bilgili, E. (2019). Assessment of prevalence and volumetric estimation of possible stafne bone concavities on cone beam computed tomography images. *Oral Radiology*. [Epub ahead of print]
- Komal, A., Bedi, R. S., Wadhvani, P., Aurora, J. K., & Chauhan, H. (2020). Study of normal anatomy of mandibular canal and its variations in Indian population using CBCT. *Journal of Maxillofacial and Oral Surgery*, 19, 98–105.
- Kubota, S., Imai, T., Nakazawa, M., & Uzawa, N. (2020). Risk stratification against inferior alveolar nerve injury after lower third molar extraction by scoring on cone-beam computed tomography image. *Odontology*, 108, 124–132.
- Lee, K. C., Yoon, A. J., Philipone, E. M., & Peters, S. M. (2019). Stafne bone defect involving the ascending ramus. *The Journal of Craniofacial Surgery*, 30, e301–e303.
- Lee, S., Lee, C., Kim, J. K., & Nam, W. (2019). An unusual presentation of intraosseous malignant peripheral nerve sheath tumour of mandible. *DentoMaxilloFacial Radiology*, 48, 20180341.
- Liu, S. Y., Sidell, D., Huon, L. K., & Torre, C. (2018). "Split to save": Accessing mandibular lesions using sagittal split osteotomy with virtual surgical planning. *Ear, Nose, & Throat Journal*, 97, 91–96.
- Liye, Q., Zhongwei, Z., Xiaojuan, S., Min, W., Pingping, L., & Kun, C. (2019). Can narrowing of the mandibular canal on pre-operative panoramic radiography predict close anatomical contact of the mandibular canal with the mandibular third molar? A meta-analysis. *Oral Radiology*. [Epub ahead of print]
- Luangchana, P., Pornprasertsuk-Damrongsri, S., Kitisubkanchana, J., & Wongchuensoontorn, C. (2019). Branching patterns of the inferior alveolar canal in a Thai population: A novel classification using cone beam computed tomography. *Quintessence International*, 50, 224–231.
- Matsuda, S., Yoshimura, H., & Sano, K. (2019). A floating inferior alveolar neurovascular bundle in a simple bone cyst: A case report. *Experimental and Therapeutic Medicine*, 17, 4677–4680.
- Matzen, L. H., Petersen, L. B., Schropp, L., & Wenzel, A. (2019). Mandibular canal-related parameters interpreted in panoramic images and CBCT of mandibular third molars as risk factors to predict sensory disturbances of the inferior alveolar nerve. *International Journal of Oral and Maxillofacial Surgery*, 48, 1094–1101.
- Matzen, L. H., Villefrance, J. S., Nørholt, S. E., Bak, J., & Wenzel, A. (2020). Cone beam CT and treatment decision of mandibular third molars: Removal vs. coronectomy—a 3-year audit. *DentoMaxilloFacial Radiology*, 49, 20190250.
- Mortazavi, H., Baharvand, M., & Rezaeifar, K. (2018). Intraosseous migration of second premolar below the inferior alveolar nerve canal: Case report. *Dental and Medical Problems*, 55, 87–90.
- Mortazavi, H., Baharvand, M., Safi, Y., & Behnaz, M. (2019). Common conditions associated with displacement of the inferior alveolar nerve canal: A radiographic diagnostic aid. *Imaging Science in Dentistry*, 49, 79–86.
- Mortazavi, H., Baharvand, M., Safi, Y., Dalaie, K., Behnaz, M., & Safari, F. (2019). Common conditions associated with mandibular canal widening: A literature review. *Imaging Science Dentistry*, 49, 87–95.
- Munhoz, L., Arita, E. S., Nishimura, D. A., & Watanabe, P. C. A. (2019). Maxillofacial manifestations of proteus syndrome: A systematic review with a case report. *Oral Radiology*. [Epub ahead of print]
- Na, J. Y., Han, S. S., Jeon, K., Choi, Y. J., Choi, S. H., & Lee, C. (2019). Prognosis in case of nerve disturbance after mandibular implant surgery in relation to computed tomography findings and symptoms. *Journal of Periodontal & Implant Science*, 49, 127–135.
- Ngeow, W. C., & Chai, W. L. (2020a). The clinical anatomy of accessory mandibular canal in dentistry. *Clinical Anatomy*, 10–14. [Epub ahead of print]
- Ngeow, W. C., & Chai, W. L. (2020b). The clinical significance of the retromolar canal and foramen in dentistry. *Clinical Anatomy*, 1–10. [Epub ahead of print]
- Nicol, P., Loncle, T., Pasquet, G., & Vacher, C. (2019). Surgical implications of the anatomic situation of the mandibular canal for mandibular osteotomies: A cone beam computed tomographic study. *Surgical and Radiologic Anatomy*. [Epub ahead of print]
- Okumuş, Ö., & Dumlu, A. (2019). Prevalence of bifid mandibular canal according to gender, type and side. *Journal of Dental Sciences*, 14, 126–133.
- Oliveira, A. C. S., Candeiro, G. T. M., Pacheco da Costa, F. F. N., Gazzaneo, I. D., Alves, F. R. F., & Marques, F. V. (2019). Distance and bone density between the root apex and the mandibular canal: A cone-beam study of 9202 roots from a Brazilian population. *Journal of Endodontics*, 45, 538–542.e2.
- Ozdede, M. (2020). An unusual case of double stafne bone cavities. *Surgical and Radiologic Anatomy*, 42, 543–546.
- Patil, V., Pai, K. M., Vineetha, R., Rajagopal, K. V., & Dkhar, W. (2019). Comparison of conventional techniques and higher imaging modalities in the evaluation of relation between the third molar and inferior alveolar nerve canal: A pilot study. *Contemporary Clinical Dentistry*, 10, 93–98.
- Patrick, S., Birur, N. P., Gurushanth, K., Raghavan, A. S., & Gurudath, S. (2017). Comparison of gray values of cone-beam computed tomography with hounsfield units of multislice computed tomography: An in vitro study. *Indian Journal of Dental Research*, 28, 66–70.
- Pedersen, M. H., Matzen, L. H., Hermann, L., & Nørholt, S. E. (2019). Migration of the root complex after coronectomy occurs within the first year after surgery: A 5-year radiographic analysis and protocol suggestion. *Oral Surgery, Oral Medicine, Oral Pathology, Oral Radiology*, 128, 357–365.
- Pour, D. G., Sedaghati, A., & Shamshiri, A. R. (2020). Effect of resolution and bit depth on inferior alveolar canal visualization on exported mandibular cone-beam computed tomography images. *Journal of Oral and Maxillofacial Surgery*. [Epub ahead of print]
- Prakash, O., Srivastava, P. K., Jyoti, B., Mushtaq, R., Vyas, T., & Usha, P. (2018). Radiographic evaluation of anterior loop of inferior alveolar nerve: A cone-beam computer tomography study. *Nigerian Journal of Surgery*, 24, 90–94.
- Predoiu, M., Rusu, M. C., & Chiriță, A. L. (2019). A rare anatomic variation: triple mentalforamina. *Morphologie*, 103, 110–115.
- Puciło, M., Lipski, M., Sroczyk-Jaszczyńska, M., Puciło, A., & Nowicka, A. (2020). The anatomical relationship between the roots of erupted permanent teeth and the mandibular canal: A systematic review. *Surgical and Radiologic Anatomy*, 42, 529–542.
- Qi, W., Lei, J., Liu, Y. N., Li, J. N., Pan, J., & Yu, G. Y. (2019). Evaluating the risk of post-extraction inferior alveolar nerve injury through the relative position of the lower third molar root and inferior alveolar canal. *International Journal of Oral and Maxillofacial Surgery*, 48, 1577–1583.
- Raju, N., Zhang, W., Jadhav, A., Ioannou, A., Eswaran, S., & Weltman, R. (2019). Cone-beam computed tomography analysis of the prevalence, length, and passage of the anterior loop of the mandibular canal. *The Journal of Oral Implantology*, 45, 463–468.
- Rytkönen, K., & Ventä, I. (2018). Distance between mandibular canal and third molar root among 20-year-old subjects. *Clinical Oral Investigations*, 22, 2505–2509.
- Saha, N., Kedarnath, N. S., & Singh, M. (2019). Orthopantomography and cone-beam computed tomography for the relation of inferior alveolar nerve to the impacted mandibular third molars. *Annals of Maxillofacial Surgery*, 9, 4–9.
- Şahin, O., Odabaşı, O., Demiralp, K. Ö., Kurşun-Çakmak, E. Ş., & Aliyev, T. (2019). Comparison of findings of radiographic and fractal dimension analyses on panoramic radiographs of patients with early-stage and advanced-stage medication-related osteonecrosis of the jaw. *Oral Surgery, Oral Medicine, Oral Pathology, Oral Radiology*, 128, 78–86.

- Sahl, E., Alqahtani, A., Alqahtani, N. M., & Gallez, F. (2018). Partial explanation of failed dental implants placed in mandibular canal: A case report. *The Journal of Oral Implantology*, 44, 456–461.
- Sánchez-Torres, A., Soler-Capdevila, J., Ustrell-Barral, M., & Gay-Escoda, C. (2019). Patient, radiological, and operative factors associated with surgical difficulty in the extraction of third molars: A systematic review. *International Journal of Oral and Maxillofacial Surgery*. [Epub ahead of print]
- Satir, S. (2019). Determination of mandibular morphology in a Turkish population with down syndrome using panoramic radiography. *BMC Oral Health*, 19, 36.
- Schäfer, E. A., & Thane, G. D. (1890). Vol. II osteology. In *Quain's elements of anatomy* (p. 59). London, England: Longmans, Green and Co.
- Sharifi, R., Beshkar, M., Mobayeni, M. R., & Hasheminasab, M. (2018). Inferior alveolar nerve medialization for dental implant placement: Case report with the introduction of a new technique. *The International Journal of Oral & Maxillofacial Implants*, 33, e113–e115.
- Shokry, S. M., Alshaib, S. A., Al Mohaimeed, Z. Z., Ghanimah, F., Altyebe, M. M., Alenezi, M. A., ... Alotaibi, M. M. (2019). Assessment of the inferior alveolar nerve canal course among Saudis by cone beam computed tomography (pilot study). *Journal of Maxillofacial and Oral Surgery*, 18, 452–458.
- Sholapurkar, A., & Davies, C. (2019). Bilateral bifid mandibular canals - Special relevance for a general dental practitioner. Report of 2 cases. *Journal of Clinical and Experimental Dentistry*, 11, e287–e289.
- Sinha, S., Kandula, S., Sangamesh, N. C., Rout, P., Mishra, S., & Bajoria, A. A. (2019). Assessment of the anterior loop of the mandibular canal using cone-beam computed tomography in Eastern India: A record-based study. *Journal of International Society of Preventive & Community Dentistry*, 9, 290–295.
- Sirin, Y., Yildirimturk, S., Horasan, S., & Guven, K. (2020). Diagnostic potential of panoramic radiography and CBCT in detecting implant-related ex vivo injuries of the inferior alveolar canal border. *The Journal of Oral Implantology*, 46, 206–213.
- Standring, S. (2015). *Gray's anatomy 41st ed.: The anatomical basis of clinical practice*. London, England: Elsevier Health Sciences.
- Sun, R., Sun, L., Sun, Z., Li, G., Zhao, Y., Ma, X., & Sun, C. K. (2019). A three-dimensional study of hemimandibular hyperplasia, hemimandibular elongation, solitary condylar hyperplasia, simple mandibular asymmetry and condylar osteoma or osteochondroma. *Journal of Cranio-Maxillofacial Surgery*, 47, 1665–1675.
- Tabrizi, R., Farahani, Z., Barouj, M. D., Kheirkhahi, M., Jafari, M., & Sadeghi, H. M. (2019). What is a safe distance for preservation of the inferior alveolar nerve in lower gingival squamous cell carcinoma? A radiographic and histopathological study. *The Journal of Craniofacial Surgery*, 30, e327–e330.
- Tachinami, H., Tomihara, K., Fujiwara, K., Nakamori, K., & Noguchi, M. (2017). Combined preoperative measurement of three inferior alveolar canal factors using computed tomography predicts the risk of inferior alveolar nerve injury during lower third molar extraction. *International Journal of Oral and Maxillofacial Surgery*, 46, 1479–1483.
- Tereshchuk, S., & Sukharev, V. (2019). Refined approach to preservation of the inferior alveolar nerve during resection and primary reconstruction of the mandible. *Cranio-maxillofacial Trauma & Reconstruction*, 12, 34–38.
- Tubbs, R. S., Custis, J. W., Salter, E. G., Sheetz, J., Zehren, S. J., & Oakes, W. J. (2005). Landmarks for the greater petrosal nerve. *Clinical Anatomy*, 18, 210–214.
- Tudtiam, T., Leelarungsun, R., Khoo, L. K., Chaiyasamut, T., Arayasantiparb, R., & Wongsirichat, N. (2019). The study of inferior alveolar canal at the lower third molar apical region with cone beam computed tomography. *Journal of Clinical Medicine Research*, 11, 353–359.
- Uchida, Y., Motoyoshi, M., Namura, Y., & Shimizu, N. (2017). Three-dimensional evaluation of the location of the mandibular canal using cone-beam computed tomography for orthodontic anchorage devices. *Journal of Oral Science*, 59, 257–262.
- Uğur Aydın, Z., & Göller Bulut, D. (2019). Relationship between the anatomic structures and mandibular posterior teeth for endodontic surgery in a Turkish population: A cone-beam computed tomographic analysis. *Clinical Oral Investigations*, 23, 3637–3644.
- Uzun, C., Sumer, A. P., & Sumer, M. (2019). Assessment of the reliability of radiographic signs on panoramic radiographs to determine the relationship between mandibular third molars and the inferior alveolar canal. *Oral Surgery, Oral Medicine, Oral Pathology, Oral Radiology*. [Epub ahead of print]
- Valdec, S., Borm, J. M., Casparis, S., Damerau, G., Locher, M., & Stadlinger, B. (2019). Vestibular bone thickness of the mandible in relation to the mandibular canal—a retrospective CBCT-based study. *International Journal of Implant Dentistry*, 5, 37.
- Vidya, K. C., Pathi, J., Rout, S., Sethi, A., & Sangamesh, N. C. (2019). Inferior alveolar nerve canal position in relation to mandibular molars: A cone-beam computed tomography study. *National Journal of Maxillofacial Surgery*, 10, 168–174.
- Vranckx, M., Ockerman, A., Coucke, W., Claerhout, E., Grommen, B., Mielotte, A., ... Jacobs, R. (2019). Radiographic prediction of mandibular third molar eruption and mandibular canal involvement based on angulation. *Orthodontics & Craniofacial Research*, 22, 118–123.
- Wang, D., Lin, T., Wang, Y., Sun, C., Yang, L., Jiang, H., & Cheng, J. (2018). Radiographic features of anatomic relationship between impacted third molar and inferior alveolar canal on coronal CBCT images: Risk factors for nerve injury after tooth extraction. *Archives of Medical Science*, 14, 532–540.
- Xie, L., Li, T., Chen, J., Yin, D., Wang, W., & Xie, Z. (2019). Cone-beam CT assessment of implant-related anatomy landmarks of the anterior mandible in a Chinese population. *Surgical and Radiologic Anatomy*, 41, 927–934.
- Yalcin, E. D., & Akyol, S. (2020). Assessment of the temporal crest canal using cone-beam computed tomography. *British Journal of Oral and Maxillofacial Surgery*, 58, 199–202.
- Yalcin, E. D., & Artas, A. (2020). Juxta-apical radiolucency and relations with surrounding structures on cone-beam computed tomography. *British Journal of Oral and Maxillofacial Surgery*. [Epub ahead of print]
- Yong, C. W., Lum, J. L., Makmur, A., Seet, J. E., & Lim, A. A. T. (2019). Unusual metastatic presentations of a primary right parapharyngeal acinic cell adenocarcinoma. *International Journal of Oral and Maxillofacial Surgery*. [Epub ahead of print]
- Zahedi, S., Mostafavi, M., & Lotfirikan, N. (2018). Anatomic study of mandibular posterior teeth using cone-beam computed tomography for endodontic surgery. *Journal of Endodontics*, 44, 738–743.
- Zirk, M., Buller, J., Zöller, J. E., Heneweer, C., Kübler, N., & Lentzen, M. P. (2019). Volumetric analysis of MRONJ lesions by semiautomatic segmentation of CBCT images. *Oral and Maxillofacial Surgery*, 23, 465–472.

How to cite this article: Iwanaga J, Matsushita Y, Decater T, Ibaragi S, Tubbs RS. Mandibular canal vs. inferior alveolar canal: Evidence-based terminology analysis. *Clinical Anatomy*. 2021;34:209–217. <https://doi.org/10.1002/ca.23648>