

CASE REPORT

Management of a neurological lesion involving Canalis Sinuosus: A case report

Gabriele Rosano DDS, PhD^{1,2} | Tiziano Testori MD, DDS, FICD^{3,4,5,6} |
 Tommaso Clauser DDS^{4,7} | Massimo Del Fabbro BSc, PhD^{4,7}

¹Senior Lecturer at Lake Como Institute Implant Advanced Training Center, Como, Italy

²Private Practitioner in Barzanò (Lecco), Barzanò, Italy

³IRCCS Orthopedic Institute Galeazzi, Dental Clinic, Head of Section of Implantology and Oral Rehabilitation, Milan, Italy

⁴Department of Biomedical, Surgical, and Dental Sciences, University of Milan, Milan, Italy

⁵Department of Periodontics and Oral Medicine, School of Dentistry, University of Michigan, Ann Arbor, Michigan, USA

⁶Private Practitioner, Como, Italy

⁷IRCCS Orthopedic Institute Galeazzi, Dental Clinic, Milan, Italy

Correspondence

Massimo Del Fabbro, University of Milano, Department of Biomedical, Surgical and Dental Sciences, Milan, Italy.

Email: massimo.delfabbro@unimi.it

Abstract

This case report describes the management of a lesion involving the Canalis Sinuosus (CS), that is a bone channel originating from the infraorbital canal below the orbital margin and posterior to the infraorbital foramen and coursing in an anterolateral direction to the anterior wall of the nasal cavity. A female patient, 62y, ASA 1, wearing full mobile dentures, came to our clinic asking for upper jaw rehabilitation. Due to a severe bone atrophy, a graft procedure was performed and the placement of eight implants was planned. One week after implants were positioned, the patient referred pain in the upper right central incisor region, that was compatible with a normal post-operative healing. After 15 days, since the symptoms worsened and became localized and persistent, a more detailed CBCT analysis was carried out. The images demonstrated that a CS on the right side was compressed by the apex of the implant in position #11. The implant was replaced with a shorter one and adequate pharmacological therapy was prescribed. All the symptoms completely disappeared after 30 days.

KEYWORDS

case report, implant, nerve injury, orofacial pain

1 | INTRODUCTION

The infraorbital nerve, a branch of maxillary nerve, is the second division of the trigeminal nerve that gives sensitivity to the dermis and the mucosa of the middle third of the face. The infraorbital nerve emerging from the corresponding foramen divides into three proximal alveolar branches (anterior superior, middle and posterior alveolar nerves) and four distal branches (inferior eyelid, external nasal, internal nasal and upper lip). The Canalis Sinuosus (CS) is a tortuous bone channel which originates from the posterior infraorbital foramen and courses in an anterolateral direction to the anterior wall of the nasal antrum below the orbital margin. Then, it sharply runs downward along the pyriform apertures tracing an “S” and moving downwards again issuing into the palatine mucosa through an accessory foramen.¹⁻³

The term CS describes the double curvature journey of the same, that courses for 55 mm through the maxilla and is characterized by an

overlying thin bone that makes it more prone to lesions in case of trauma. It contains the anterior superior alveolar nerve (ASAN) and the relative veins and arteries: the ASAN is in fact a division of the maxillary branch of the trigeminal nerve which courses in the CS through the anterior maxilla to innervate the incisors and canines (Figure 1). The third ending of the ASAN comprises multiple nerve connections which, in case of damage, ensures sensitivity in the innervated zone. The presence of a CS and accessory foramen (Figure 2) is often ignored in surgical practice as these anatomical variations can only be revealed after a careful examination of pre-op radiological images.¹⁻⁴ Moreover, their presence may directly influence the efficacy of the treatment.^{5,6}

In this case, an intraoperative lesion, which involves the canine innervations, is described. This lesion caused post-operative hypoesthesia, paraesthesia and pain. In this scenario an implant placed in the CS zone can potentially lead to various types of permanent discomfort via the transection or compression of the CS.⁷⁻⁹

As stated in literature, trigeminal nerve injury is often due to dental surgical procedures with serious medical as well as legal implications¹⁰ since it considerably affects the patient's quality of life.

Considering the relative lack of scientific papers published on peer-reviewed journals about this trigeminal nerve anatomical variant, we think that the present case report could be of interest.

2 | CASE REPORT

A female patient, 62y, ASA 1, wearing full mobile dentures, came to our office asking for upper jaw rehabilitation. Initial radiological exams showed severe bone atrophy. Hence, placement of eight implants was planned after bilateral sinus elevation to support a Toronto-Bridge type prosthesis. Eight months after sinus elevation, healing of the grafted sites was verified by means of a CBCT (Figure 3). Then, implant surgery was carried out under local anesthesia, after antibiotic prophylaxis, and a 2-stage protocol was applied.

The day before surgery the patient started prophylaxis with 1 g of amoxicillin and clavulanic acid (Augmentin, Roche, Milan, Italy) administered every 12 h for 6 days.

Preoperatively, the patient rinsed her mouth with an antiseptic mouthwash (Curasept 0.20%, Curaden Healthcare s.r.l., Saronno, Milan, Italy) to reduce the risk of contaminating the surgical field.

Treatment was provided under local anesthesia with articainechlorohydrate 4% and adrenaline 1:100.000 (Alfacaina N, Weimer Pharma, Rastat, Germany).

A midcrestal incision was performed from the right maxillary tuberosity to the left one with two vertical distal releasing incisions and a full mucoperiosteal tissue flap was mobilized and reflected for placing eight dental implants (BioHorizons, Inc. - Birmingham,

What is known:

- Canalis Sinuosus is a tortuous bone channel characterized by an "S" course lateral to the pyriform apertures, issuing into the palatine mucosa.
- It contains the anterior superior alveolar nerve (ASAN) which courses in the CS through the anterior maxilla to innervate the incisors and canines.

What this study adds:

- What this case report adds: Careful preliminary radiological detection of Canalis Sinuosus is strongly recommended prior to dental implant placement at the anterior maxilla in order to avoid neurological lesions potentially leading to long term sequelae.

Alabama, USA). All the implants were submerged and placed with a final torque insertion <35 N/cm.

Implant site preparation was carried out at 1200 rpm drill speed under constant irrigation of saline solution at room temperature; moreover, care was taken not to insert the implants at excessive torque values in order not to generate any frictional heat.

The patient, regularly followed up, developed pain after 7 days in the upper right central incisor region zone, which initially appeared in line with normal post-op course and compatible with a nociceptive, inflammatory, typically short lasting pain.

Fifteen days later, symptoms worsened becoming localized, persistent pain patient described as 'electric shock' or 'stabbing'

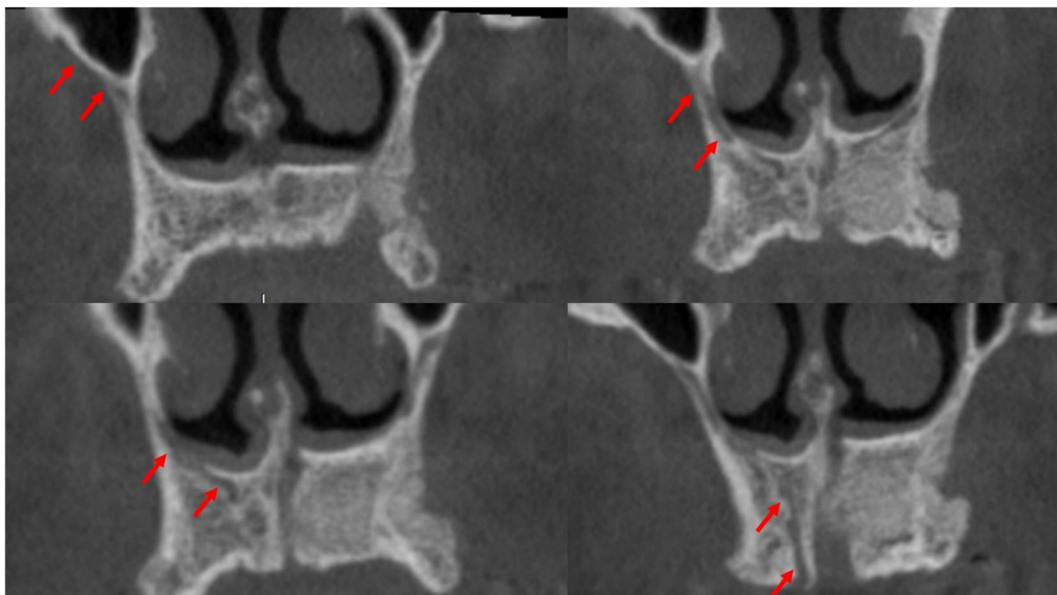


FIGURE 1 Pre-op coronal sections showing the Canalis Sinuosus (CS) outline in the premaxillary area

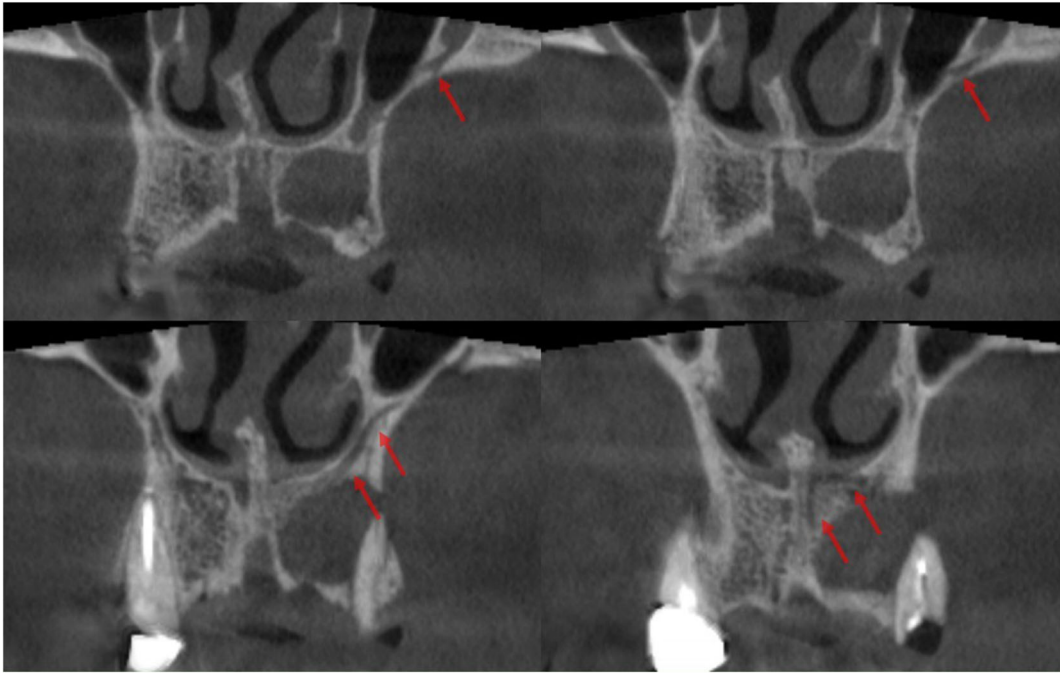
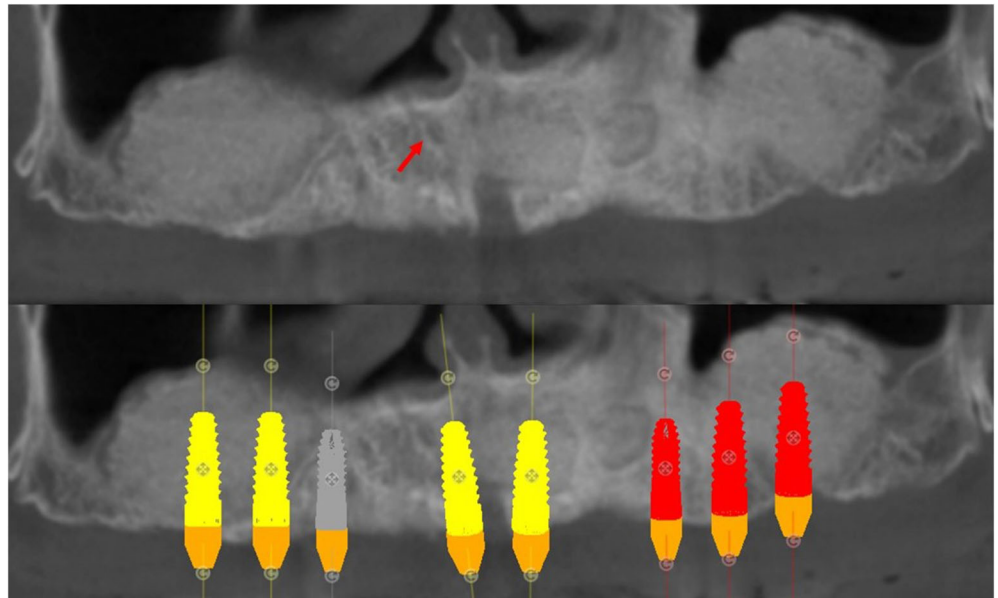


FIGURE 2 CBCT coronal sections showing the accessory foramen of a Canalis Sinuosus (CS) issuing into the palatine mucosa (see red arrows)

FIGURE 3 Pre-op panorex after bilateral sinus lifting and showing pre-op virtual implant planning. The red arrow shows the presence of a right Canalis Sinuosus (CS) in the premaxillary area



exacerbated by touching or brushing the area around the implant at site #11. Nevertheless, no clinical signs of infection were detected in this area.

At this stage a new post-op, more focused CBCT analysis was carried out (Figures 4-7) aiming at identifying the reason for such issue. The images demonstrated that a CS on the right side, not previously identified but already present in the pre-op CBCT scans (Figures 1 and 3), was compressed by the apex of the implant in position #11 (Figures 4-7). This condition was considered compatible with the symptoms the patient reported.

The management of implant-related nerve injury included the offending fixture removal and its replacement with a shorter one (8-mm long) that did not intersect the course of CS (Figure 8). In the immediate postoperative period combination drug therapies with oral prednisone (five-day tapering schedule of 50, 40, 30, 20 and 10 mg per day), antibiotics (amoxicillin (875 mg) and clavulanic acid (125 mg), 1 g every 12 h for 5 days), non-steroidal anti-inflammatory drugs (NSAIDs) (for example, ibuprofen 600 mg every 8 h), and vitamins (B and C) were administered to decrease compression of the nerve trunk by edema or hematomas, to avoid the onset of infections and to prevent fibrous tissue scarring.

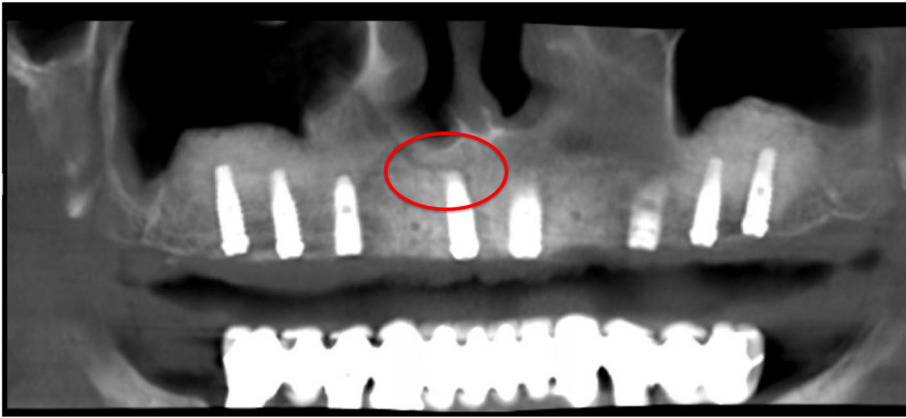


FIGURE 4 Post-op panorex revealing a Canalis Sinuosus (CS) compression by the apex of the implant in position #11

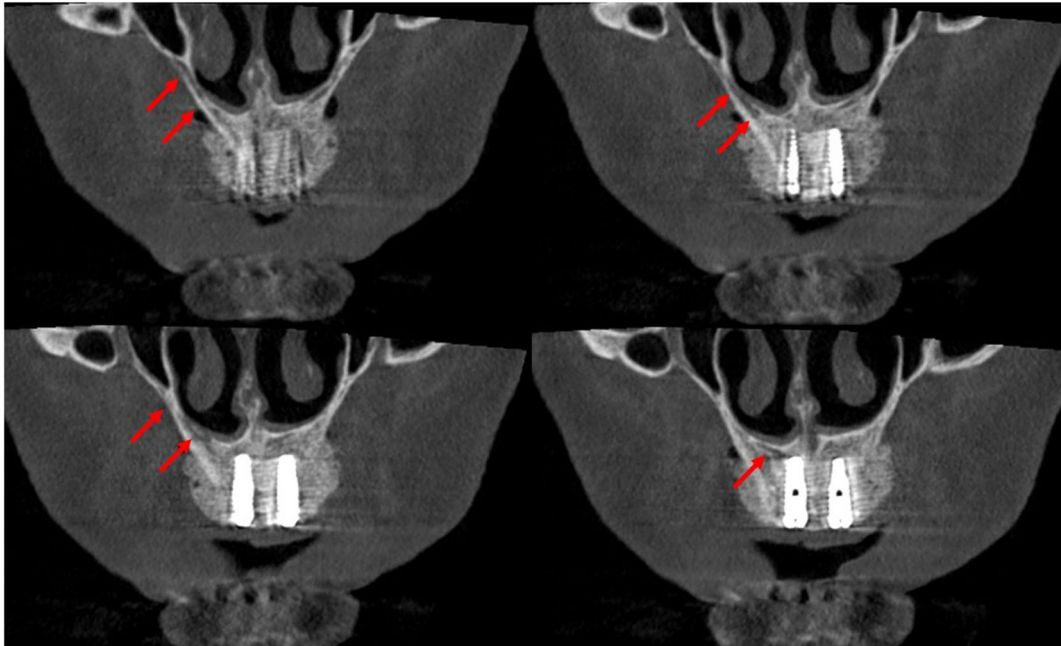


FIGURE 5 Course of Canalis Sinuosus (CS) highlighted in the coronal reconstruction of the post-op CBCT image

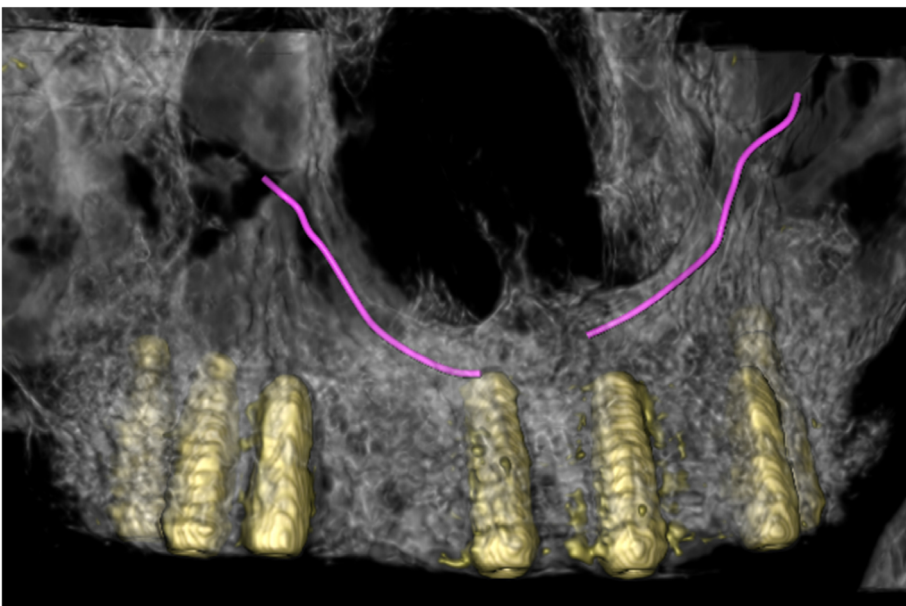


FIGURE 6 Volume rendering showing Canalis Sinuosus (CS) after implant placement

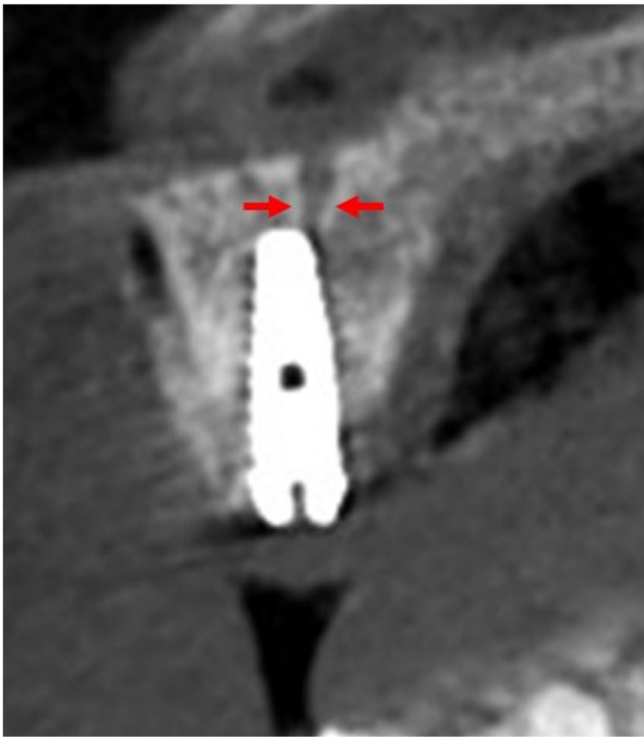

FIGURE 7 Paraxial CBCT image showing the implant in position #11 compressing the Canalis Sinuosus (CS)

Then, the patient was examined on a daily basis. Her condition gradually improved and all symptoms completely disappeared after 30 days from new fixture replacement. Then, the patient continued on a regular schedule.

3 | DISCUSSION

If the patient complains of severe pain with evident signs of neuropathy appearing after implant surgery, watchful waiting is contraindicated.

According to Delcanho and Moncada 2014, the risk that symptoms of neuropathy will not reverse is minimized when the implant is removed less than 36 hours after its placement.¹¹

In the present case, symptoms have been reversed even though the implant was removed after 2 weeks; however, there is limited evidence on how timing could affect neurological sequelae and it is likely to depend on the severity of nerve compression. Also, additional surgery, once osseointegration has occurred, may cause further damage.¹²

In such a perspective, it seems to be mandatory for clinicians to realize the differences between nociceptive, inflammatory and neuropathic pain (NP).

After surgery, a short-lasting, nociceptive pain is often experienced. The inflammatory process accompanying the pain tends to protect the patient by eliminating the causes of the injury and accelerates the healing process.

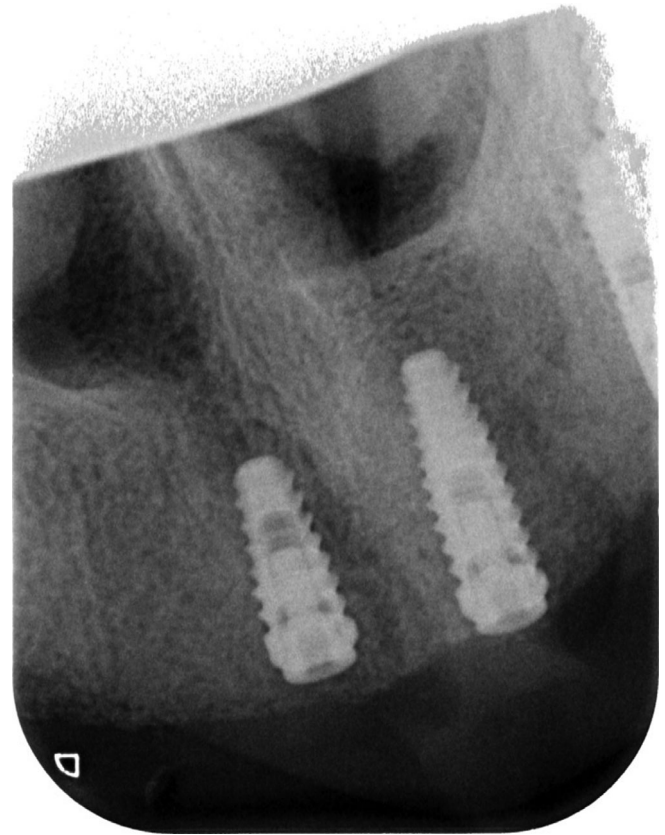


FIGURE 8 Endoral X-ray showing the replaced shorter implant not intersecting the course of Canalis Sinuosus (CS)

On the other hand, NP is caused by a lesion or disease in the somatosensory nervous system,¹³ leading to a sharp burning and prickling sensation.¹⁴⁻¹⁷

NP can be spontaneous or evoked, with characteristic positive amplified sensation or negative signs or both, as in the present study. An area of abnormal sensation is nearly always encountered.

Establishing the prognosis when injuries to nerve trunks occur is not easy: both the duration and reversibility are affected mainly by the nature of the damage. Flap reflection, provided the 8% elastic limit is not exceeded and the stretching is not too abrupt may cause reversible compression by edema as well as hematomas.¹⁸

Clinical evolution of sensory disturbances produced by implant placement in close proximity of a main or accessory neurological structure is strongly connected to immediate implant removal which often leads to full sensory recovery.

Lesions to nerve trunks during osteotomy, conversely, are more likely to produce permanent sensory alterations with the appearance of hyperalgesia symptoms.¹⁹

In the present case the full sensory recovery in a 30-day period after implant removal seems to further demonstrate that patient's symptoms were due to the compression of the implant impinging on a CS accessory trunk.

Since no frictional heat was generated at the time of surgery and no soft tissue lesion, swelling or suppuration was observed at follow up, the Authors excluded the eventuality that patient's clinical symptoms and the radiolucent area appeared in the apical portion of the implant #11 were caused by a thermally induced bone necrosis during implant surgery.

Surgical procedures carried out within the pre-maxillary area are usually considered free from severe complications, due to the adequate cortical bone density in that region and the absence of main neurological structures, but the naso-palatine nerve.

However, the international scientific literature on this issue reports a rare neurological anatomical variation^{2,4,5,7,8} which may be damaged during surgical interventions at this level.

As a consequence, obtaining as much information as possible concerning possible anatomical variants, especially by mean of radiological exams, is essential in order to render surgical procedures safer and minimize the risk of iatrogenic lesions of ASAN. These complications can cause serious post-operative discomfort leading to chronic pain that does not respond to pharmacological treatment, necessitating new surgery procedures.

In modern dental surgery the CBCT has achieved a major role in pre-op assessment for the rehabilitation of partially or totally edentulous patients. A careful diagnostic evaluation through radiographic images such as Panorex reconstruction (Figures 3 and 4) or coronal images (Figures 1, 2, and 5) is essential to locate a possible CS. It is therefore possible to identify the origin of the infraorbital nerve, the double curve at the level of pyriform aperture and the coronal course until its emergence in the accessory foramen.

Canalis Sinuosus is rarely evaluated when planning an implant placement, but cases of permanent symptoms after its damage have been described.^{8,9} So, a careful preliminary assessment is recommended to detect its presence prior to implant placement. When neurological damage happens, implant should be removed immediately and a corticosteroids therapy given.⁶ After management of this case as described, the symptoms were compatible with normal healing process.

4 | CONCLUSIONS

The implant-related CS injury described satisfies the diagnostic criteria for NP.

Clinicians not only should have a deep knowledge of the normal anatomy, but also must be aware of all possible anatomical variations. The latter should be investigated in order to minimize the risk of complications correlated to implant surgery. They also must promptly identify any adverse event and be prepared to manage them in the most appropriate way.

As a general rule, to further limit the risk of injury to the CS or any other neurological bundle, it is the Authors' opinion that, in agreement with the study by Greenstein and Tarnow,²⁰ the customary 2-millimeter safety zone recommended above a bundle could be extended to 4 mm.

Further studies with a higher level of evidence will be necessary to confirm our considerations.

ACKNOWLEDGMENTS

The authors wish to thank Dr. Nicolò Vercellini, Research Fellow at "Innovative Technology and Engineered Biomaterial" Research Centre, Department of Medicine and Surgery, University of Insubria, Varese, Italy, for assistance with surgical interventions and patient' follow-up procedures.

AUTHOR CONTRIBUTION

Gabriele Rosano, Tiziano Testori, and Massimo Del Fabbro conceived and designed the study. Literature search for the topic was performed and analyzed by Gabriele Rosano, Tommaso Clauser and Massimo Del Fabbro. Surgical interventions and implant insertion were performed by Gabriele Rosano. Follow-up data was collected by Gabriele Rosano. All the authors contributed on interpretation of data for the work. Gabriele Rosano and Tommaso Clauser drafted the work and wrote the manuscript with input from all authors. Tiziano Testori and Massimo Del Fabbro revised the work critically for intellectual content. Integrity of the work was appropriately investigated and resolved by all authors. All authors contributed and approved equally to the final version of the manuscript.

DATA AVAILABILITY STATEMENT

Research data not shared.

ORCID

Tommaso Clauser  <https://orcid.org/0000-0002-7124-4761>

Massimo Del Fabbro  <https://orcid.org/0000-0001-7144-0984>

REFERENCES

1. Machado V d C, Chrcanovic BR, Felipe MB, Manhães Júnior LRC, de Carvalho PSP. Assessment of accessory canals of the canalis sinuosus: a study of 1000 cone beam computed tomography examinations. *Int J Oral Maxillofac Surg*. 2016;45:1586-1591.
2. Neves FS, Crusoé-Souza M, Franco LCS, Caria PHF, Bonfim-Almeida P, Crusoé-Rebello I. Canalis sinuosus: a rare anatomical variation. *Surg Radiol Anat*. 2012;34:563-566.
3. Wanzeler AMV, Marinho CG, Junior SMA, Manzi FR, Tuji FM. Anatomical study of the canalis sinuosus in 100 cone beam computed tomography examinations. *Oral Maxillofac Surg*. 2015;19:49-53.
4. von Arx T, Lozanoff S, Sendi P, Bornstein MM. Assessment of bone channels other than the nasopalatine canal in the anterior maxilla using limited cone beam computed tomography. *Surg Radiol Anat*. 2013;35:783-790.
5. Olenczak JB, Hui-Chou HG, Aguila DJ, Shaeffer CA, Dellon AL, Manson PN. Posttraumatic midface pain: clinical significance of the anterior superior alveolar nerve and canalis sinuosus. *Ann Plast Surg*. 2015;75:543-547.
6. Shelley AM, Wardle L, Goodwin M, Brunton P, Horner K. A questionnaire study to investigate custom and practice of imaging methods for the anterior region of the mandible prior to dental implant placement. *Dento Maxillo Facial Radiol*. 2013;42:20120179.
7. Torres MGG, de Faro Valverde L, Vidal MTA, Crusoé-Rebello IM. Branch of the canalis sinuosus: a rare anatomical variation—a case report. *Surg Radiol Anat*. 2015;37:879-881.

8. Arruda JA, Silva P, Silva L, et al. Dental implant in the Canalis Sinuosus: a case report and review of the literature. *Case Rep Dent*. 2017;2017:1-5.
9. Volberg R, Mordanov O. Canalis Sinuosus damage after immediate dental implant placement in the esthetic zone. *Case Rep Dent*. 2019; 2019:1-5.
10. Caissie R, Goulet J, Fortin M, Morielli D. Iatrogenic paresthesia in the third division of the trigeminal nerve: 12 years of clinical experience. *J Can Dent Assoc*. 2005;71:185-190.
11. Delcanho R, Moncada E. Persistent pain after dental implant placement. *J Am Dent Assoc*. 2014;145:1268-1271.
12. Khawaja N, Renton T. Case studies on implant removal influencing the resolution of inferior alveolar nerve injury. *Br Dent J*. 2009;206: 365-370.
13. Jensen TS, Baron R, Haanpää M, et al. A new definition of neuropathic pain. *Pain*. 2011;152:2204-2205.
14. Greene CS, Murray GM. Atypical odontalgia. *J Am Dent Assoc*. 2011; 142:1031-1032.
15. Svensson P, Drangsholt M, Pfau DB, List T. Neurosensory testing of orofacial pain in the dental clinic. *J Am Dent Assoc*. 2012;143:e37-e39.
16. Klasser GD, Gremillion HA, Epstein JB. Dental treatment for patients with neuropathic orofacial pain. *J Am Dent Assoc*. 2013;144:1006-1008.
17. Ferreira JN, Figueiredo R. Prevention and management of persistent idiopathic facial pain after dental implant placement. *J Am Dent Assoc*. 2013;144:1358-1361.
18. Dao TT, Mellor A. Sensory disturbances associated with implant surgery. *Int J Prosthodont*. 1998;11:462-469.
19. Wismeijer D, van Waas MAJ, Vermeeren JJF, Kalk W. Patients' perception of sensory disturbances of the mental nerve before and after implant surgery: a prospective study of 110 patients. *Br J Oral Maxillofac Surg*. 1997;35:254-259.
20. Greenstein G, Tarnow D. The mental foramen and nerve: clinical and anatomical factors related to dental implant placement: a literature review. *J Periodontol*. 2006;77:1933-1943.

How to cite this article: Rosano G, Testori T, Clauser T, Del Fabbro M. Management of a neurological lesion involving Canalis Sinuosus: A case report. *Clin Implant Dent Relat Res*. 2021;23:149–155. <https://doi.org/10.1111/cid.12977>