

**CONTROVERSIAL TOPICS IN ORTHODONTICS:
CAN WE REACH CONSENSUS?**

This volume includes the proceedings of the
Forty-seventh Annual Moyers Symposium and the Forty-fifth
Annual International Conference on Craniofacial Research
February 28-March 1, 2020
Ann Arbor, Michigan

Guest Editor

Bhavna Shroff

Co-Editor

Hera Kim-Berman

Copy Editor

Dawn Bielawski

Volume 57
Craniofacial Growth Series

Department of Orthodontics and Pediatric Dentistry
School of Dentistry

The University of Michigan
Ann Arbor, Michigan

©2021 by the Department of Orthodontics and Pediatric Dentistry,
School of Dentistry, University of Michigan
Ann Arbor, MI 48109

Publisher's Cataloguing in Publication Data

Department of Orthodontics and Pediatric Dentistry
Craniofacial Growth Series
Controversial Topics in Orthodontics:
Can We Reach a Consensus?
Volume 57

ISSN 0162 7279

ISBN 0-929921-00-3

No part of this publication may be reproduced, stored in a retrieval system, or transmitted in any form by any means, electronic, mechanical, photocopying, recording, or otherwise, without the prior written permission of the Editor-in-Chief of the Craniofacial Growth Series or designate

CONTRIBUTORS

ZAHRAA ALLOHAIBI, Department of Orthodontics and Pediatric Dentistry, School of Dentistry, University of Michigan, Ann Arbor, MI.

SIBEL ALTUN, Postgraduate Student, Department of Orthodontics, University of Illinois at Chicago, IL.

SHARON ARONOVICH, Clinical Associate Professor, Department Oral and Maxillofacial Surgery and Hospital Dentistry, School of Dentistry, University of Michigan, Ann Arbor, MI.

TAKAFUMI ASAKI, Assistant Professor, Civil, Environmental, and Biomedical Engineering Department, College of Engineering, Technology, and Architecture, University of Hartford, West Hartford, CT.

LAWRENCE ASHMAN, Director of the TMD and Orofacial Clinic, Program Director of the Advanced Dentistry Education Program in Orofacial Pain, School of Dentistry, University of Michigan, Ann Arbor, MI, USA.

PHIMON ATSAWASUWAN, Associate Professor, Department of Orthodontics, University of Illinois at Chicago, IL.

SEBASTIAN BAUMGAERTEL, Clinical Associate Professor, Department of Orthodontics, School of Dental Medicine, Case Western Reserve University, Cleveland, OH.

ERIKA BENAVIDES, Clinical Professor, Department of Periodontics and Oral Medicine, School of Dentistry, University of Michigan, Ann Arbor, MI.

JONAS BIANCHI, Post-doctoral researcher, University of Michigan, Department of Orthodontics and Pediatric Dentistry, Ann Arbor, MI.

LUCIANA BITTENCOURT, Department of Orthodontics and Pediatric Dentistry, School of Dentistry, University of Michigan, Ann Arbor, MI.

NIKO C. BOCK, Department of Orthodontics, Justus-Liebig-University, Giessen, Germany.

S. JAY BOWMAN, Adjunct Clinical Associate Professor, Saint Louis University – C.A.D.E.; Assistant Clinical Professor, Case Western Reserve University; Instructor, University of Michigan, Ann Arbor, MI.

PO-JUNG CHEN, Resident, Division of Orthodontics, University of Connecticut Health, Farmington, CT.

CHRISTYNE CHMIL, Postgraduate student, Department of Orthodontics, University of Illinois at Chicago, IL.

ALEXANDRE F. DASILVA, Director, Headache & Orofacial Pain Effort (H.O.P.E.), Associate Professor, Department of Biologic and Materials Sciences, School of Dentistry, University of Michigan, Ann Arbor, MI.

PRISCILLE DE DUMAST, Department of Orthodontics and Pediatric Dentistry, School of Dentistry, University of Michigan, Ann Arbor, MI.

RICCARDO DI GIANFILIPPO, Postgraduate student, Department of Periodontics and Oral Medicine, University of Michigan School of Dentistry, Ann Arbor, MI.

MOHAMMED ELNAGAR, Assistant Professor, Department of Orthodontics, University of Illinois at Chicago, IL.

LIANA FATTORI, Department of Orthodontics and Pediatric Dentistry, School of Dentistry, University of Michigan, Ann Arbor, MI.

LORENZO FRANCHI, Associate Professor, Department of Experimental and Clinical Medicine, University of Florence, Florence, Italy; Thomas M. Graber Visiting Scholar, Department of Orthodontics and Pediatric Dentistry, University of Michigan, Ann Arbor, MI.

SILVIA GIANONI-CAPENAKAS, PhD student- Orthodontics - School of Dentistry, Faculty of Medicine and Dentistry, University of Alberta, Canada.

JOÃO ROBERTO GONÇALVES, Professor, São Paulo State University (UNESP) - Department of Pediatric Dentistry, Araraquara, SP, Brazil.

YOLY GONZALEZ, Associate Professor, Department of Oral Diagnostic Sciences, University at Buffalo School of Dental Medicine, Buffalo, NY.

VERONICA GIUNTINI, Department of Experimental and Clinical Medicine, University of Florence, Florence, Italy.

XIAO-SU HU, Assistant Research Scientist, Department of Biologic and Materials Sciences, School of Dentistry, University of Michigan, Ann Arbor, MI.

CHAO HUANG, Department of Biostatistics, Gillings School of Global Public Health, University of North Carolina, Chapel Hill, NC.

DA IN KIM, Private Practice, School of Dentistry, Faculty of Medicine and Dentistry, University of Alberta, Canada.

MARCOS IOSHIDA, School of Dentistry, University of Michigan, Ann Arbor, MI.

LAURA R. IWASAKI, Professor-Provisional, Chair of the Department of Orthodontics, Oregon Health & Science University School of Dentistry, SD-ORTHO, Portland, OR.

HERA KIM-BERMAN, Program Director, Graduate Orthodontics, Clinical Associate Professor, University of Michigan, School of Dentistry, Department of Orthodontics and Pediatric Dentistry, Ann Arbor, MI.

STEVEN M. LASH, Adjunct Clinical Professor, Department of Orthodontics and Pediatric Dentistry, School of Dentistry, University of Michigan, Ann Arbor, MI.

HONGZENG LIU, Senior Research Associate, Department of Orthodontics, Oregon Health & Science University School of Dentistry, SD-ORTHO, Portland, OR.

YING LIU, Assistant Professor, Department of Biostatistics and Epidemiology, College of Public Health, East Tennessee State University, Johnson City, TN.

GEORGE A MANDELARIS, Private Practice, Periodontal Medicine and Surgical Specialists, Chicago, IL.
Department of Graduate Periodontics, University of Illinois College of Dentistry, Chicago, IL.

CATERINA MASUCCI, Sous-section Orthopédie Dento-Faciale, Faculté de Chirurgie dentaire, Université de Nice-Sophia Antipolis, Nice, France.

JAMES A. MCNAMARA Jr, Thomas M. and Doris Graber Endowed Professor of Dentistry Emeritus, Department of Orthodontics and Pediatric Dentistry, School of Dentistry; Professor Emeritus of Cell and Developmental Biology, School of Medicine; and Research Scientist, Center for Human Growth and Development, University of Michigan, Ann Arbor, MI. Private practice of orthodontics, Ann Arbor, MI.

LAURIE MCNAMARA MCCLATCHEY, Adjunct Clinical Associate Professor, Department of Orthodontics and Pediatric Dentistry, University of Michigan, Ann Arbor, MI. Private practice of orthodontics, Ann Arbor, MI.

LOÏC MICHOD, Department of Orthodontics and Pediatric Dentistry, School of Dentistry, University of Michigan, Ann Arbor, MI.

CLÉMENT MIRABEL, Department of Orthodontics and Pediatric Dentistry, School of Dentistry, University of Michigan, Ann Arbor, MI.

THIAGO D. NASCIMENTO, Assistant Research Scientist, Department of Biologic and Materials Sciences, School of Dentistry, University of Michigan, Ann Arbor, MI.

JEFFREY C. NICKEL, Professor-Provisional, Director of Advanced Education in Orthodontics and Dentofacial Orthopedics, Oregon Health & Science University School of Dentistry, SD-ORTHO, Portland, OR.

ANTÔNIO CARLOS DE OLIVEIRA RUELLAS, Adjunct Clinical Associate Professor, Department of Orthodontics and Pediatric Dentistry, School of Dentistry, University of Michigan, Ann Arbor, MI.

BEATRIZ PANIAGUA, Assistant Director of Medical Computing, Kitware, Inc., Carrboro, NC.

JUAN CARLOS PREITO, Department of Psychiatry, School of Medicine, University of North Carolina, Chapel Hill, NC.

DAVID RICE, Professor and Head of Orthodontics, University of Helsinki and Helsinki University Hospital Finland and Editor, European Journal of Orthodontics.

LILIANE ROSAS GOMES, Department of Orthodontics and Pediatric Dentistry, School of Dentistry, University of Michigan, Ann Arbor, MI.

SABINE RUF, Department of Orthodontics, Justus-Liebig-University, Giessen, Germany.

AMY SEAGRAVES, Postgraduate Student, Department of Orthodontics, University of Illinois at Chicago, IL.

SAJJAD SHIRAZI, Doctorate Student, Department of Oral Biology, University of Illinois at Chicago, IL.

BRANDON S. SHOUKRI, Adjunct Clinical Assistant Professor, Department of Orthodontics and Pediatric Dentistry, School of Dentistry, University of Michigan, Ann Arbor, MI. Private practice of orthodontics, Dexter, MI.

LUCIA HELENA SOARES CEVIDANES, Associate Professor, Department of Orthodontics and Pediatric Dentistry, School of Dentistry, University of Michigan, Ann Arbor, MI.

FABIANA NAOMI SOKI, Clinical Assistant Professor, Department of Periodontics and Oral Medicine, School of Dentistry, University of Michigan, Ann Arbor, MI.

MARTIN STYNER, Department of Psychiatry, School of Medicine, University of North Carolina, Chapel Hill, NC.

JAMES SUGAI, Department of Periodontics and Oral Medicine, School of Dentistry, University of Michigan, Ann Arbor, MI.

NINA TUBAU RIBERA, Department of Orthodontics and Pediatric Dentistry, School of Dentistry, University of Michigan, Ann Arbor, MI.

MADHUR UPADHYAY, Associate Professor, Division of Orthodontics, University of Connecticut Health, CT.

MANUEL O. LAGRAVÈRE VICH, Associate Professor, School of Dentistry, Faculty of Medicine and Dentistry, University of Alberta, Canada.

MEENAKSHI VISHWANATH, Assistant Professor, Department of Growth and Development-Orthodontic Section, University of Nebraska Medical Center, Lincoln, NE.

CHIN-WEI WANG, Clinical Assistant Professor, Department of Periodontics and Oral Medicine, University of Michigan School of Dentistry, Ann Arbor, MI.

MARILIA YATABE, Clinical Assistant Professor, Department of Orthodontics and Pediatric Dentistry, School of Dentistry, University of Michigan, Ann Arbor, MI.

HONGTU ZHU, Department of Biostatistics, Gillings School of Global Public Health, University of North Carolina, Chapel Hill, NC.

PREFACE

At the end of February 2020, we were preparing to attend the 47th Moyers Symposium in Ann Arbor, Michigan with great excitement. This famous international meeting has been held every year on the campus of the University of Michigan and brings together researchers, clinicians, teachers and residents from around the world. It offers this unique opportunity to network with colleagues and friends in a wonderful academic setting.

This past year, the symposium focused on controversies in Orthodontics and the emergence of a consensus. It was such a timely topic for our specialty! New treatment modalities were entering the practice of orthodontics and the very way we practiced our specialty was being challenged by a “do it yourself” approach to treatment. Superb presentations discussed novel and challenging topics for two and a half days during the pre-symposium, giving the audience a sense for the new and the controversies in Orthodontics. New technologies were used to explore the TMD challenge and new appliance designs to treat Class II and Class III applied the principles of old, perhaps forgotten appliances to the demands of the modern patients. The expansion of the maxilla was discussed at length with the introduction of new treatment modalities. The importance of biomechanics as it applies to clear aligners and the principles of accelerated tooth movement were debated. An insightful discussion of the emergence of new trends in practice, took place. Researchers demonstrated that augmented reality and artificial intelligence were entering our specialty and could profoundly impact our future teaching, research and treatment delivery.

We left snow covered Ann Arbor, recharged and refocused after a stimulating exchange of ideas and opinions. The symposium concluded on March 1, 2020 and little did we know about the challenges that laid ahead of us. Rumors of a virus circulating in the Wuhan province of China appeared in the news, followed by the devastation that it left behind. The wave of infections was already reaching Europe and Italy was hit hard. By March 11, 2020 this outbreak of a novel Corona virus was labelled a pandemic, a word that the world had forgotten since the flu outbreak of 1918. Within days, the world and the United States started to shut down to face the unknown. We emerged 10 weeks later and we have been wrestling with the controversies in the information available and the need for a consensus. We have learned from the experiences and experiments of other countries, but in the final analysis, science prevails and science will win.

Controversies will always exist in the field of Orthodontics as they have in the past. Some disappear and some find a second life and resurface. In the end, as providers of care and professionals, we need to examine the data and not settle for empirical evidence. Looking to the future, it is critical that we continue to stay focused on the science that is the foundation of our specialty and the Moyer’s symposium is certainly the place where ideas are discussed and science is presented as a basis to better the clinical practice of orthodontics.

The 47th Annual Moyers Symposium and the 45th Annual International Conference on Craniofacial Research (Presymposium) were held at the University of Michigan on Friday,

February 28, 2020 through Sunday, March 1, 2020. This meeting was sponsored by the Department of Orthodontics and Pediatric Dentistry, School of Dentistry, University of Michigan. The proceeding of this annual meeting is memorialized in the 57th volume of the Craniofacial Growth Series and contains reports, original research, case series and review articles from internationally renowned experts, scientists and clinicians. The 57th volume and the entire Craniofacial Growth Series is made available to the public through the University of Michigan Deep Blue Repository <https://deepblue.lib.umich.edu/handle/2027.42/146667>.

As in previous years, the *Symposium* honored the late Dr. Robert Moyers, Professor Emeritus of Dentistry and Fellow Emeritus and Founding Director of the Center for Human Growth and Development at the University of Michigan.

We thank Michelle Jones of the Office of Continuing Dental Education for coordinating and managing the *Presymposium* and the *Symposium*. We also thank Dawn Bielawski for her invaluable work as Copy Editor and Lea Sarment for verifying all citations and references.

We acknowledge Dr. Nan Hatch, the Chair of the Department of Orthodontics and Pediatric Dentistry for her support of the meeting and this publication.

Finally, we thank the speakers and participants of the *Symposium* and the *Presymposium* and appreciate their attendance and support throughout the 47 years of history of the meeting.

Bhavna Shroff
Guest Editor

Hera Kim-Berman
Co-Editor
February, 2021

TABLE OF CONTENTS

Editor Addresses	ii
Contributors	iii
Preface	vii
<i>Evidence-Based Orthodontics in Solving Controversies and Providing a Basis for Clinical Practice Guidelines</i>	1
David Rice University of Helsinki and Helsinki University Hospital	
<i>Extracellular MicroRNA Expression in Gingival Crevicular Fluid During Tooth Movement</i>	17
Phimon Atsawasawan, Sajjad Shirazi, Sibel Altun, Christyne Chmil, Amy Seagraves, Mohammed Elnagar University of Illinois at Chicago	
<i>The Biology and Modification of Periodontal and Dentoalveolar Bone Phenotype in Orthodontic Patients</i>	32
Riccardo Di Gianfilippo, George A. Mandelaris, Chin-Wei Wang University of Michigan; University of Illinois; Private Practice	
<i>Force System with V-Bends: Two vs. Three-Dimensional Analysis of Tooth Movements – A Preliminary Study</i>	60
Meenakshi Vishwanath, Po-Jung Chen, Takafumi Asaki, Madhur Upadhyay University of Nebraska Medical Center; University of Connecticut Health; University of Hartford	
<i>Quantitative Subchondral Imaging Biomarkers for the Diagnosis of TMJ Osteoarthritis</i>	86
Jonas Bianchi, João Roberto Gonçalves, Antônio Carlos de Oliveira Ruellas, Marília Yatabe, Fabiana Naomi Soki, Erika Benavides, Beatriz Paniagua, Lucia Helena Soares Cevidanes University of Michigan; São Paulo State University (UNESP); Kitware Inc.	
<i>Minimally Invasive Approach for Diagnosing TMJ Osteoarthritis</i>	95
Brandon S. Shoukri, Juan Carlos Preito, Antonio Ruellas, Marilia Yatabe, James Sugai, Martin Styner, Hongtu Zhu, Chao Huang, Beatriz Paniagua, Sharon Aronovich, Lawrence Ashman, Erika Benavides, Priscille de Dumast, Nina Tubau Ribera, Clément Mirabel, Loïc Michoud, Zahraa Allohaibi, Marcos Ioshida, Luciana Bittencourt, Liana Fattori, Liliane Rosas Gomes, Lucia Cevidanes University of Michigan; University of North Carolina, Chapel Hill; Kitware Inc.	

<i>Self-Reported Parafunction Not Validated by Measured Masseter Muscle Activity</i>	103
<p>Jeffrey C. Nickel, Yoly M. Gonzalez, Ying Liu, Hongzeng Liu, Laura R. Iwasaki Oregon Health & Science University; University at Buffalo School of Dental Medicine; East Tennessee State University</p>	
<i>An Observational Study of Mechano-Allostatic Load and Chronic Temporomandibular Pain in Humans</i>	112
<p>Yoly Gonzalez, Laura R. Iwasaki, Hongzeng Liu, Ying Liu, Jeffrey C. Nickel University at Buffalo School of Dental Medicine; Oregon Health & Science University; East Tennessee State University</p>	
<i>Post-Pubertal Assessment of the Dentoskeletal Effects Produced by the Alt-RAMEC Protocol for the Early Treatment of Class III Malocclusion</i>	123
<p>Lorenzo Franchi, Veronica Giuntini, James A. McNamara Jr., Caterina Masucci University of Michigan; University of Florence Florence, Italy; Université de Nice-Sophia Antipolis, Nice, France</p>	
<i>Evaluating New Approaches to the Treatment of Class II and Class III Malocclusions: The Carriere® Motion™ Appliance</i>	139
<p>James A McNamara Jr., Lorenzo Franchi, Laurie McNamara McClatchey, Hera Kim-Berman University of Michigan; Private Practice</p>	
<i>Non-Surgical Adult Expansion Using MARPE or Dresden Expanders</i>	165
<p>Manuel O Lagravère Vich, Silvia Gianoni-Capenakas, Da In Kim University of Alberta</p>	
<i>Long-Term Oral Health Effects of Orthodontic Class II Treatment</i>	179
<p>Niko C. Bock, Sabine Ruf Justus-Liebig-University, Giessen, Germany</p>	
<i>How to Get Better at Temporary Anchorage Devices (TADS) Quickly</i>	199
<p>Sebastian Baumgaertel Case Western Reserve University</p>	
<i>Augmented Reality and Artificial Intelligence: A (Human) Brainstorm on How They Are Revolutionizing Pain Research, Education, and Treatment</i>	210
<p>Thiago D. Nascimento, Xiao-Su Hu, Alexandre F. DaSilva University of Michigan</p>	

<i>Drastic Plastic: Enhancing the Predictability of Clear Aligners</i>	219
S. Jay Bowman	
Saint Louis University – C.A.D.E.;	
Case Western Reserve University; University of Michigan	
<i>Space Management of Labially Impacted Maxillary Canines</i>	254
Steven M. Lash	
University of Michigan	

EVIDENCE-BASED ORTHODONTICS IN SOLVING CONTROVERSIES AND PROVIDING A BASIS FOR CLINICAL PRACTICE GUIDELINES

David Rice

ABSTRACT

This review focuses on how to solve controversies in clinical orthodontic practice through evidence-based debate and consensus. The importance of quality retrospective and prospective primary research is highlighted in helping us increase our knowledge-base, as is the value of carefully defining the question or controversy to be resolved with a PICO-based approach. Focus is then given to randomized controlled trials and systematic reviews (secondary studies) and initiatives to improve their quality and their reporting in orthodontics. An historical perspective of orthodontic clinical research is made before an appraisal of research today. Finally, the value of best practice guidelines is discussed, and a look is taken at the best ways to establish clinical practice guidelines and clinical care pathways in orthodontics.

KEY WORDS: Evidence-based Orthodontics, Consensus, Best Practice, Clinical Guidelines

CONTROVERSIES AND CONSENSUS

Controversy, the prolonged public disagreement about an issue, usually occurs because the issue affects or is important to many people or stakeholders. Some clinical approaches are driven by scientific evidence, politics, philosophy, some by commerce, others by the resources or desire of the patient, others by resources, skills or competence of the clinician. While some disagreements may solve themselves or run their natural course, controversies should be resolved through a combination of stakeholder communication, debate and discussion based on evidence. Consensus is hopefully reached, and this may result in optimal clinical care, best practice guidelines and ultimately in recommended patient care plans or pathways (Figure 1).



Figure 1. The resolution of clinical controversies should be based on evidence from scientific research. Hopefully stakeholder discussion can be concluded in consensus, best practice guidelines agreed upon and implemented with an improvement in clinical care. However, clinical practice guidelines in orthodontics are rare, and this idealistic process is often bypassed or short-cut.

Regarding best practice in clinical orthodontics, controversies arise at multiple levels. Patient A comes in with problem X; what is the best practice for diagnosis and treatment planning? Does the problem need active treatment? What should be done? How to do it? When to do it? Who should do it and who should pay for it? Broadly these issues can also be categorized into patient care pathways, diagnostics, treatment planning, treatment timing, specific treatment techniques, risk management of iatrogenic damage to the patient or potential harm to the providers of orthodontic care.

EVIDENCE-BASED ORTHODONTICS

The resolution of controversies should be based on evidence. Evidence-based orthodontics (EBO) is not an isolated academic phenomenon, but primarily intended for patient and clinician (Figure 2). Three equal parts should be considered when deciding on individual patient care: evidence from research; clinical skills, competence and resources; and patient factors [1].

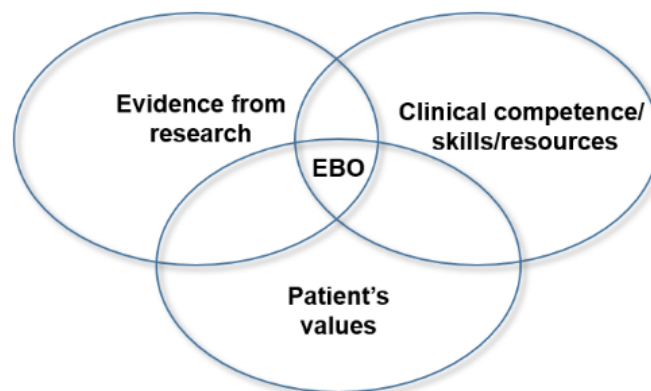


Figure 2. Evidence-based orthodontics (EBO), adapted from Bondemark 2019 [1].

Pyramids of evidence show us levels of increasing quality of proof [1-3]. They tell us that prospective, randomized controlled trials are the highest level of primary studies and thereafter systematic reviews with meta analyses should be used in formulating clinical practice guidelines (secondary studies) (Figure 3).




Figure 3. Research design and the quality of evidence. The pyramid of evidence shows us increasing levels of evidence. Starting with reports with no design, then interventional primary studies and secondary studies. Adapted from Bondemark 2019 [1].

'It is always the case that: prospective trials generate stronger evidence than retrospective, and that controlled trials are always superior to non-controlled' [1]. Non-randomized clinical trials (non-RCTs), cross-sectional studies, case-controlled and cohort studies including longitudinal studies are more prone to bias and confounders and consequently more difficult to establish causality. So, is it that only prospective randomized controlled trials (RCTs) will do, and that all other studies are worthless? Not at all. Non-RCTs are used extensively to describe the distribution of disease and exposure in populations, develop predictive and diagnostic models and to generate hypotheses. These hypotheses can then be tested, possibly in RCTs. 'both randomized and non-randomized designs are important to build a broad, informative evidence base' [1, 2, 4, 5].

In the early 2000s, orthodontics, indeed most of dentistry and medicine, underwent somewhat of a revolution in the formalization and standardization of clinical research design and implementation. Part of this process was the introduction of research reporting guidelines. These by design and adoption aim to improve the quality of clinical research and evidence.

The EQUATOR network (Enhancing the QUALity and Transparency Of health Research), established in 2006, is an 'international initiative that seeks to improve the reliability and value of published health research literature by promoting transparent and accurate reporting and wider use of robust reporting guidelines' [6]. Its website is a one-stop resource for over 400 reporting guidelines including those by CONSORT (Consolidated Standards of Reporting Trials) on randomized trials; STROBE (Strengthening the Reporting of Observational Studies in Epidemiology) on observational studies; PRISMA (Preferred Reporting Items for Systematic Reviews and Meta-Analyses) on systematic reviews; STARD (Standards for Reporting Diagnostic Accuracy Studies) on diagnostic studies; CARE (Case Report guidelines) on case reports; AGREE (Appraisal of Guidelines, Research, and Evaluation) on clinical practice guidelines; SRQR (Standards for Reporting Qualitative Research) on qualitative research; CHEERS (Consolidated Health Economic Evaluation Reporting Standards) on economic evaluations; and ARRIVE (Animal Research: Reporting of *In Vivo* Experiments) on animal pre-clinical studies.

PRIMARY STUDIES

CONSORT (Consolidated Standards of Reporting Trials) was established in 1996 and its statement and guidelines were endorsed by many orthodontic journals in the early 2000s [7]. It is thought that orthodontic clinical research quality significantly improves if researchers adhere to CONSORT guidelines [8, 9]. This is probably true. Almost by definition pre-registered, prospective, randomized, controlled, appropriately powered studies are designed to minimize the effects of bias and of confounders. So, what effect did the CONSORT adoption have on the reporting quality in the field of orthodontics?

In their seminal study published in 2012, Fleming et al. assessed adherence to the CONSORT checklist and thereby the quality of reporting in abstracts in four leading orthodontic journals: American Journal of Orthodontics and Dentofacial Orthopedics (AJODO), European Journal of Orthodontics (EJO), Journal of Orthodontics (JO), and The Angle Orthodontist (AO) [10]. In the years 2006-2011, that is to say after CONSORT adoption, 117 RCT were published (AJODO 62, AO 27, EJO 17, JO 11). They found good reporting for interventions (97%), objectives (93%) and the number of participants (96%). However, the over-riding message was that they found poor reporting of randomization procedures, allocation concealment, blinding, confidence intervals, harms, registrations and funding. Overall, the reporting quality score was poor, at 60%. What was particularly disappointing was that they did not notice any improvement with time over the 5 years assessed.

The lack of improvement was confirmed in a study looking at 128 RCTs from 50 issues (2001-2013) from the same four leading orthodontic journals [11]. Again, reporting was suboptimal and did not improve with time. Over a similar time period (2003-2012), Sandhu et al. assessed 309 orthodontic RCTs from 46 different journals [12]. They found, similarly, that adherence to CONSORT was poor but that in the more

recent years there had been an improvement in some items, namely identification as randomized in the title, sample size, blinding and randomization reporting.

Unsurprisingly, orthodontics was not alone. Poor reporting quality was discovered in the 228 RCTs (2008-2011) published in 7 leading journals representing different dental specialties (AJODO, British Journal of Oral and Maxillofacial Surgery (BJOMS), Clinical Oral Implants Research (COIR), International Journal of Prosthodontics (IJP), Journal of Clinical Periodontology (JCP), Journal of Endodontics (JOE) and Pediatric Dentistry (PD) [13]. These findings were not exclusive to dental journals but widespread in general medical journals [14].

Initiatives to improve compliance with CONSORT

Although CONSORT guidelines had been endorsed by orthodontic journals in the early 2000s, a decade later reporting of orthodontic clinical trials was far from optimal [10, 11, 13]. This led to initiatives by the orthodontic journals to improve reporting, with the rationale that if adherence to CONSORT could be improved, the quality of the research could hopefully also be improved and thereby the value of orthodontic trials to the orthodontic community could be improved. Nikolaos Pandis, in his role as associate editor of the AJODO and also in collaboration with the EJO, lead the way. In 2011, the AJODO, with Vincent G. Kokich as Editor-in-Chief, started a more proactive implementation of CONSORT guidelines, summarized by Koletsi et al. in 2017 [15-17]. This was followed in 2012 by measures from the EJO [18]. AO, Orthodontics and Craniofacial Research (OCR) and JO have also taken concerted action.

Measures adopted included updating author guidelines, editorial staff actively checking CONSORT adherence at the submission stage (CONSORT checklists and flow charts) as well as during the peer review process and advising authors regarding how to comply with and improve adherence to guidelines. Editorials and journal articles were published, and congress presentations and debates took place to highlight the importance of evidence quality and adherence to CONSORT and the changes taking place in the orthodontic journals [16-19] [4, 20]. These initiatives were well timed as a major update of the CONSORT statement, checklist and flow chart had been published in 2010 [21].

Structured subtitles to improve quality of reporting

An integral part of adherence to CONSORT is the use of structured articles including abstracts with designated subheadings for authors to follow. Studies have shown that structured abstracts for clinical medical studies are typically more informative and more accessible than non-structured [22]. This holds true for orthodontic research too, with the quality of information in the abstract being greater when in a structured compared to an unstructured format is utilized. What's more the quality of information in the abstracts increases when a specific journal changes to a structured format [23].

The AJODO and AO had adopted structured abstracts already in 2005, with the EJO following suit in 2013. However, all three journals subsequently adopted a much more proactive approach (2011-2014) by specifically using CONSORT subtitles in both abstracts and in article main body texts. [24].

Does the relatively simple measure of structuring an article format to have subtitles in the abstract and in the article text have any effect in the orthodontic context? Yes. The use of tailored subheadings has been shown to enhance compliance with CONSORT [15]. In this elegant and simple approach, a standard format of abstract which incorporated tailored subtitles which mirrored those of the CONSORT guidelines was introduced in the AJODO in 2014. Following this introduction, CONSORT compliance was assessed in submissions of RCTs for a 30-month period. Seventy-one articles were submitted, 49 with subheadings and 22 without. Reporting quality of the submitted RCTs was 15.2% higher when a subheadings format was used compared to studies that without subheadings. This was most striking for the reporting of a sample size

calculation where 51% of studies with subheadings documented a sample size calculation compared to only 27% reporting in studies that did not use the subheading format. The reporting of trial setting, recruitment, randomization implementation, allocation, blinding, baseline data, limitations, harms and generalizability all followed a similar pattern (Figure 4).

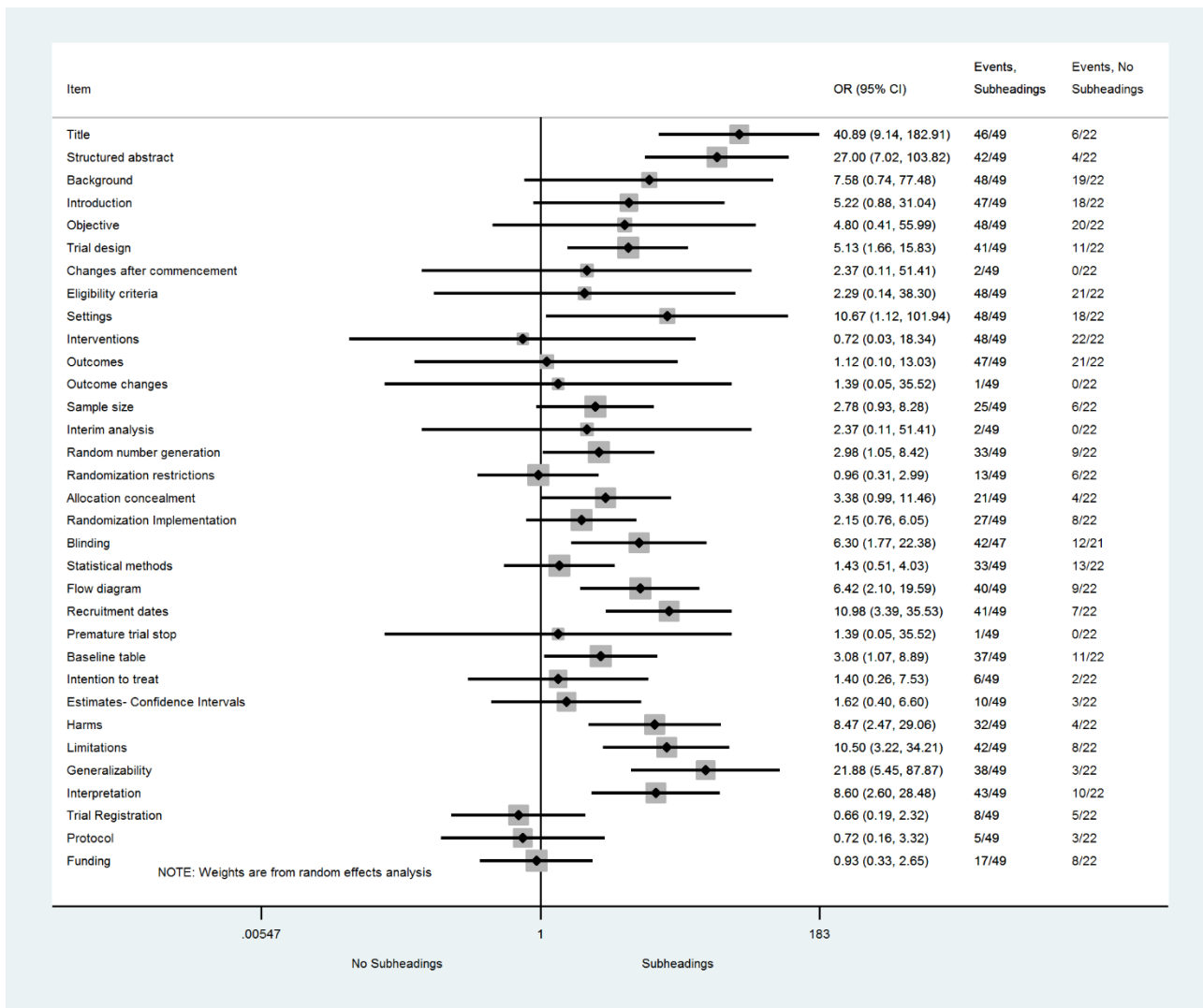


Figure 4. Forest plot from Kolesti et al. showing improvement in reporting in RCT when using a structured format with subheadings. Reproduced with permission [15].

Further developments to help orthodontic clinical researchers and improve clinical trial methodology have included comprehensive series of articles on bias, statistical power, the importance of suitable control, blinding, randomization, clustering and confounding [2, 25-36]. The effect of performing an orthodontic trial rather than the effect of the intervention itself has also been studied and highlighted. The behavior of both patients and clinicians who know that they are in a trial can affect the results of the trial [37]. The Hawthorne effect and novelty effects may result in false-positive bias due to knowledge and interest that one is either in a trial or conducting a trial.

Behavioral effects can not only affect those in an intervention group but also conversely participants in the control group. With the John Henry effect, members of the control group may actively work harder to overcome the ‘disadvantage’ of being in the control group, therefore making the results of the trial harder to interpret and less reliable [37, 38]. Despite their potential to introduce bias, it has been demonstrated that the effects of participant or clinician behavior on the outcome is rarely considered in orthodontic trials [37].

Poor handling and reporting of the issues of adverse reactions, harms and sample dropouts can result in bias [39]. The reporting of dropouts and how to deal with their effects in outcome analyses, notably by performing an intention to treat analysis, have been the subjects of investigation. Analysis of 90 RCTs from 5 orthodontic journals (2013-2017) showed that only 6 (6.7%) performed and reported the intention to treat analysis correctly. Most studies used a per protocol analysis, which may reduce statistical power due to a smaller sample size and has the potential to overestimate the results. The study demonstrated a lack of consideration for the issue of dropouts in orthodontic trials and highlights how trial integrity can be undermined [40]. Increased understanding of the issues above can minimize clinical research shortcomings and can help optimize trial planning, design, execution, analysis and reporting [1].

Is the quality of clinical trials in orthodontics improving?

The number of RCTs reported in orthodontics is increasing. Comparing the 5 decades prior to 2017, the number of RCTs reported has more than doubled every 10 years. From 2008 to 2017, 619 RCT publications were produced [2, 3, 41] (Figure 5).

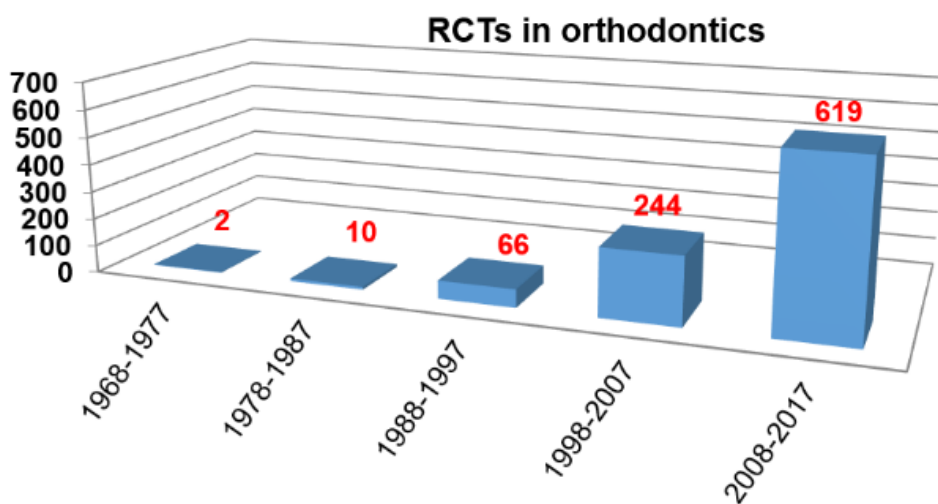


Figure 5. Number of RCTs published in orthodontics 1968-2017, data from Bondemark 2019 [41].

But has the quality of clinical trials improved and has the quality of evidence on which to base our clinical decisions improved as a result? If the number of RCTs is increasing, according to the evidence pyramid, the level of evidence should be improving, but is this the case?

An investigation into the quality of report of RCT abstracts in 4 orthodontic journals (2012-2017) may suggest that although overall reporting is still suboptimal, there is an improvement [42]. Alharbi and Almuzian found that 94% of RCT abstracts were structured (total N=224). This is a good sign as we know that the use of structured abstracts improves the quality of information, and that the use of tailored, structured subheadings in general improves CONSORT compliance [15, 23]. Good reporting was noted for author information details, trial design, the number of participants, interventions, objectives, outcomes, recruitment, results and conclusions. Moderately good reporting was noted for the title, registration, funding, and the number of analyzed participants. Poor reporting was noted for blinding, harms and the mean overall quality score was 69%, that is to say suboptimal.

Blinding

If abstract reporting of blinding is poor, how is blinding addressed in orthodontic RCTs? From 2012-2018, 10 orthodontic journals have been assessed on whether blinding has been conducted and type of blinding carried out [43]. Following the assessment of 203 RCTs, it was found that 62% had some form of blinding, most often blinding of the outcome assessor (40%). This is understandable as in orthodontic trials it is often impossible to mask the patient and clinicians from knowing the specifics of the intervention. Fifteen percent of RCTs included single-blinding, while double-blinding (3%) or triple-blinding (3%) were rarely performed. Interestingly, journals that have adopted CONSORT guidelines (AJODO, EJO, JO, OCR) published significantly more RCTs that had performed blinding than journals not following CONSORT [43].

Trial registration

Prospective trial registration is a good benchmark. It demonstrates forethought and good planning, and a degree of transparency. Also, it has been demonstrated that unregistered trials in orthodontics are more prone to bias, with unregistered trials reporting more beneficial treatment effects than registered ones [44]. In contrast to Alharbi and Almuzian, who found that reporting of RCT registration was moderately good (2012-2017), others have found major problems [42, 45]. A study of discrepancies in trial registrations and published RCTs in orthodontics analyzed 336 RCTs (2000-2018) from 5 prominent publicly accessible registries (ClinicalTrials.gov, ISRCTN, EU Clinical Trials Register, ANZCTR, CTRI) [46]. Results showed that only 16% (53/336) of published orthodontic RCTs were registered, with the vast majority of these being registered retrospectively, 70%!

However, trial registration status may well be improving. In a study of 150 orthodontic trials (not only RCTs) published in 2017-2018, 34% were registered: 15 had prospective trial registration (10.0%); 36 retrospective trial registration (24%); 99 (66%) no trial registration. While clearly not optimal the results are similar to those in periodontal research which has previously been seen to set the highest standard in dentistry [47].

So how are things today? Is it possible to publish an RCT in a top orthodontic journal without registration? Unfortunately, the answer is Yes! (Table 1)

Table 1. Number of RCTs published in the top orthodontics journals in 2019 and whether registered in an open access database or not. American Journal of Orthodontics and Dentofacial Orthopedics (AJODO), The Angle Orthodontist (AO), European Journal of Orthodontics (EJO), Korean Journal of Orthodontics (KJO) Journal of Orthodontics (JO), Orthodontics and Craniofacial Research (OCR), Progress in Orthodontics (Prog Orthod).

	Registered	Unregistered	Total
AJODO	3 (43%)	4 (57%)	7
AO	6 (50%)	6 (50%)	12
EJO	12 (80%)	3 (20%)	15
KJO	0	1 (100%)	1
JO	0	0	0
OCR	2 (100%)	0	2
Prog Orthod	1 (25%)	3 (75%)	4

If we know that prospective trial registration is a positive benchmark, how is this possible that unregistered RCTs are still being accepted? There are several reasons: orthodontic trials may take several years to complete especially if they have a long observation period; trials may also take years to write up and publish. At the time when the trial started registration may not have been commonplace. This reason should be obsolete in a relatively short time period. The study itself with or without registration may still be valuable and therefore publishable. But probably the main reason is that journals need to publish and can only publish the best studies that are submitted.

In summary, it seems obvious that the number of higher standard trials (RCTs) being published is increasing and a cursory glance at an RCT abstract 10 years ago compared to the top RCT abstracts today will tell you that reporting has improved. It is clear that there are many excellent research papers in orthodontics and that these tick many of the right boxes with regard to many of the guidelines outlined in EQUATOR, not only RCTs. Are we getting better at reporting only, or is the quality of the evidence and usefulness of the information improving too? This later point can largely be addressed by optimizing the research question. The PICO model helps us do this. PICO is a systematic tool/method which, according to the most relevant question and best evidence helps us define the target problem, patient or population (P), the intervention (I) the best control (C) and most appropriate outcome (O) [48]. Regarding any improvement in both the quality of evidence and usefulness of the information from orthodontic clinical research, it is tempting to think that both are improving, but to conclude this we need to wait for further audit.

SECONDARY STUDIES

For evidence to be considered of the highest quality, primary studies need to be replicated, results from multiple studies can then be pooled and finally, if the quality of the data is high, conclusions may be drawn. Analogous to CONSORT setting standardized methodology for reporting and by inference planning and undertaking clinical trials (primary studies), so too there is standardized methodology for collating primary studies (systematic review) and for analyzing primary studies (meta-analyses).

The Cochrane organization sets the benchmark for systematic review methodology. Cochrane is a global, independent, non-profit network which gathers and summarizes the best evidence from research to help us make informed healthcare decisions. It is an organization with the highest levels of transparency and makes its library of systematic reviews openly accessible to the general public. Cochrane states that 'A systematic review attempts to identify, appraise and synthesize all the empirical evidence that meets pre-specified eligibility criteria to answer a specific research question. Researchers conducting systematic reviews use explicit, systematic methods that are selected with a view aimed at minimizing bias, to produce more reliable findings to inform decision making' [49]. Meta-analysis is the use of statistical methods to summarize and combine the results of more than one study [50]. A meta-analysis aims to provide a more precise estimate of the effects of an intervention and to reduce uncertainty [49].

PRISMA (Preferred Reporting Items for Systematic Reviews and Meta-Analyses) is an evidence-based minimum set of items aimed at helping authors report a wide array of systematic reviews and meta-analyses that assess the benefits and harms of a health care intervention. PRISMA helps authors report systematic reviews in a transparent and complete manner [51]. Analogous to the good reporting of primary studies, so too the good reporting of systematic reviews makes extensive use of structured abstracts and subheadings in the abstract and in the article main body text. In general, the reporting of systematic reviews in orthodontics is poor. The mean quality of reporting score for the 389 systematic reviews in orthodontics (1990-2018) was only 53% [52]. However, the situation is improving. PRISMA introduced a new checklist in 2013 (PRISMA-A) and since that time the reporting score has improved (48% before 2013 n=207, 59% after 2013 n=182). Reporting of all the following items has improved: title, information from databases, risk of bias, included studies, synthesis of results, interpretation of results, financing and conflict of interest, and registration [52].

Similar to primary trials, the prospective registration of secondary studies reduces bias and increases transparency. A priori registration in a publicly accessible database (PROSPERO) has been shown to increase the quality of orthodontic systematic reviews, according to the AMSTAR tool (Assessment of Multiple Systematic Reviews) [53].

Although it is good that a large number of systematic reviews have been undertaken in orthodontics, we are sometimes disappointed to read the following kinds of statements in many of these studies 'need for high quality studies', 'low quality evidence', 'high risk of bias, low quality', 'not enough evidence to make conclusion', 'high study heterogeneity: meta-analysis was deemed inappropriate'. These statements are not unique to orthodontic reviews. An analysis of the quality of evidence of Cochrane reviews for all health care using the GRADE tool (Grades of Recommendation, Assessment, Development, and Evaluation) over an 18-month period found that only 13.5% reported a high quality of evidence. A moderate level of evidence was recorded in 30.8% reviews, a low level in 31.7%, and a very low level in 24% [54]. As might be expected high quality of evidence was more often found in studies with pharmacological interventions compared to other types of interventions. This does not bode well for orthodontics in which studies with pharmacological interventions are rare.

The quality of systematic reviews and meta-analyses might be reduced by the poor quality of the primary studies assayed, but also by the quality of the meta-analyses itself (risk of bias, indirectness, imprecision, inconsistency and publication bias), which can affect the validity of the findings [55]. The number of orthodontic systematic reviews published in recent years has increased rapidly. Some justification of this can be given in that there should be some replication and overlap of secondary studies. Also, updated meta-analyses provide higher quality information [54] but only provided that the inadequacies of an initial review have been corrected and/or additional primary studies have been published since the initial review. One problem might be that number of primary studies has not kept pace with the increase in the number of secondary studies [55]. This may be due to many reasons but the increased demands of planning, conducting and reporting a primary study compared a secondary study are many. All in all, there is an opinion that there are too many systematic reviews and too few trials [55].

So, is there any hope?

Of the Cochrane reviews in orthodontics, relatively few give us anything positive to take home. But within these Cochrane reviews and other high-quality secondary studies there are some pearls. For example, in the Cochrane review on the effectiveness of fluorides in white spot lesions during fixed orthodontics, Benson et al. concluded that there was a low level of certainty that either 12,300 ppm F foam applied professionally or high fluoride toothpaste (5000 ppm F) were effective at reducing the proportion of patients with new lesions [56]. At the face of it this does not sound very good. However, the reason for the low level of certainty was not the fact that the 2 trials concerned were poor [57, 58]. No, it was because there was only one primary study for each intervention and these results have not been corroborated independently, which might raise the level of certainty. So, what are needed are more RCTs.

In the Cochrane review on the treatment of class II malocclusion, focus has been placed on whether early or late intervention might be more effective at treating the class II malocclusion or whether one specific appliance is better than another. And for these outcomes there has been a low quality of evidence [59, 60]. But regarding trauma risk to the incisors the evidence is better. Early treatment (7-11 years) 'may significantly reduce the incidence of incisal trauma'. The risk reduction is 33% for functional appliance therapy and 41% for headgear therapy. This equates to early functional appliance therapy preventing 1 incidence of incisal trauma for every 10 patients, and early headgear treatment preventing 1 incidence of incisal trauma for every 6 patients with increased overjet [60]. Even though the number of studies was low, the authors of the systematic reviews state that the findings are 'clinically important' and of 'moderate' scientific quality [59].

Other secondary studies may provide valuable information about prevalence rates or the success of a particular technical tool. For example, one meta-analysis that the pooled data of 16 RCTs and 30 prospective cohort studies found that miniscrews used for orthodontic skeletal anchorage have an acceptably low failure rate (13.5%) [61]. While the data should be interpreted with some caution, due to high heterogeneity and unbalanced groups, and the lack of information provided about whether treatment method A is superior to method B, this information is still a useful step forward.

CLINICAL PRACTICE GUIDELINES AND CLINICAL CARE PATHWAYS

Clinical practice guidelines aim to guide patient and practitioner decisions regarding individual diagnosis, management, and treatment. Clinical practice guidelines are based on best evidence and may be summarized in a consensus statement. Once published, a healthcare provider can then decide whether to follow the recommendations of a guideline for an individual patient [62-64]. Clinical practice guidelines are designed to support daily practice. Their development should combine scientific evidence with clinical experience and should include stakeholder consultation [65].

Clinical care pathways attempt to standardize in a stepwise manner the care process with the aim of reducing clinical practice variability and improving the quality of care and maximizing outcomes. They are structured and translate guidelines or evidence into a clinical decision or action. A single clinical pathway may refer to multiple clinical guidelines on different topics [66, 67]. In orthodontics, the case for clinical practice guidelines is not new. In 2007, David Turpin, the Editor-in-Chief of the AJODO, wrote ‘Do we know how to predictably prevent, manage, and treat malocclusions? If the answer is yes, based on the best available evidence, is it appropriate to write guidelines for the management and correction of malocclusions?’ [68]. He continued in 2009 with words that are still pertinent today, “As the issue of who is best qualified to deliver specialty care percolates throughout society, it becomes more critical than ever to specify which procedures lead to the best treatment outcomes.” “Although most academicians knowledgeable about evidence-based practice believe that we might never have high-level evidence for more than 50% of the procedures, we must strive to make use of what is well known.” “Guidelines must be written in the best interests of the patient and not for those with specific ideologies or profit motives.” [69]. Most orthodontists work in relative isolation and clear guidelines may help us maintain standards and safety.

Since 1996, the American Association of Orthodontists (AAO) has published wide ranging Clinical Practice Guidelines for Orthodontics and Dentofacial Orthopedics and this is updated regularly [70]. Tejani et al. assessed guidelines published between 1990-2012 and found only 7 directly related to orthodontics: Management of the palatally ectopic maxillary canine (2012) [71] by the Royal College of Surgeons, England (RCS); Management of unerupted maxillary incisors (1997, 2010) (RCS); Orthodontic Retention (2008) (RCS); Mini/Micro screw implantation for orthodontic anchorage (2007) by National Institute for Health and Clinical Excellence (NICE) [72]; Use of radiographs in clinical orthodontics (2008) by the British Orthodontic Society (BOS); CPG for orthodontics and dentofacial orthopedics (2008) by the AAO; Radiation Protection: Cone Beam CT for Dental and Maxillofacial Radiology; Evidence based guidelines (2012) by SedentexCT [73, 74].

Tejani et al. analyzed not the validity of guidelines or quality of evidence but rather the quality of reporting according to transparency, clarity and conflicts of interest using the AGREE II instrument (Appraisal of Guidelines, Research, and Evaluation) [74-76]. They found that only those published by NICE and SedentexCT had high scores. Since this study, a few new guidelines have been published and others updated (Table 2).

It has been reported that dental clinical practice guidelines that have been published more recently have improved reporting quality [83]. Guidelines that score highly with the quality items in the AGREE II tool have been recommended for implementation [74]. An important factor, which determines the quality of a clinical practice guideline, is the development process and the reporting of this process [82]. Following

publication and implementation a clinical practice guideline, its effectiveness should be tested in a clinical trial [84].

Table 2: Orthodontic clinical practice guidelines published 2014-2020 (Two additional guidelines are on orthodontic radiographs and prevention of white spots are in development by the Dutch Association of Orthodontists).

Clinical Practice Guideline	Organization
Management of unerupted maxillary incisors (2018) [77] Management of palatally ectopic maxillary canine (2016) [78] A guideline for the extraction of first permanent molars in children (2014) [79]	Royal College Surgeons, England (RCS) & (BOS)
Guidelines for the use of radiographs in clinical orthodontics (2015) [80]	British Orthodontic Society (BOS)
Orthodontics and dentofacial orthopedics (2019) [70]	American Association of Orthodontists (AAO)
Caries preventive measures in orthodontic practice: the development of a clinical practice guideline (2016) [65] Development of a clinical practice guideline for orthodontic retention (2019) [81] Development of a clinical practice guideline for orthodontically induced external apical root resorption (2020) [82]	Dutch Association of Orthodontists

A way forward?

So, is there a way forward to develop orthodontic clinical practice guidelines based on the evidence that considers all stakeholders? The most recent guidelines by the Royal College Surgeons, England, with the British Orthodontic Society and in particular the Dutch Association of Orthodontists, may point to the best approach to date [77, 82, 84].

The guideline on orthodontically induced external apical root resorption (EARR) used from its initiation the AGREE II instrument, and reported according to the RIGHT statement [82, 85]. It started with a systematic review followed by a survey of Dutch orthodontists and identified 4 clinical questions: 1. What types of radiographs enable the diagnosis/detection of orthodontically induced EARR? 2. What factors increase the risk of developing EARR? 3. What treatment protocol should be followed when EARR is detected during treatment? 4. What is the follow-up protocol for patients with EARR? Following this, a task force formulated considerations and recommendations, and a draft guideline was formulated and distributed to stakeholders for comment. The final document, which includes 13 recommendations, was authorized by the Dutch Association of Orthodontists. The recommendations were based on the 4 clinical questions raised in the initial survey and covered the areas of diagnosis, risk factors, treatment strategy, and after-treatment care. The recommendations were graded as weak, moderate or strong. The whole process took 3 years (Figure 6). Once established, it is planned to assess the effectiveness of guidelines in a randomized clinical trial [84]. It has been suggested that clinical practice guidelines in orthodontics be re-evaluated every 5 years. [81].

Regarding orthodontic retention, Littlewood et al. have performed a Cochrane review and concluded that ‘there is insufficient evidence to make recommendations on orthodontic retention procedures after orthodontic treatment and advised further high-quality RCTs.’ [86]. The same team of Dutch Orthodontists that produced the Sondeijker et al. 2020 guidelines on root resorption have also produced a clinical practice

guideline on orthodontic retention [81]. In this the authors conclude that ‘it is feasible to develop a clinical practice guideline for retention according to an established scientific methodology, since a clinical practice guideline is not just based on evidence, but also on experience and consensus’ [81].

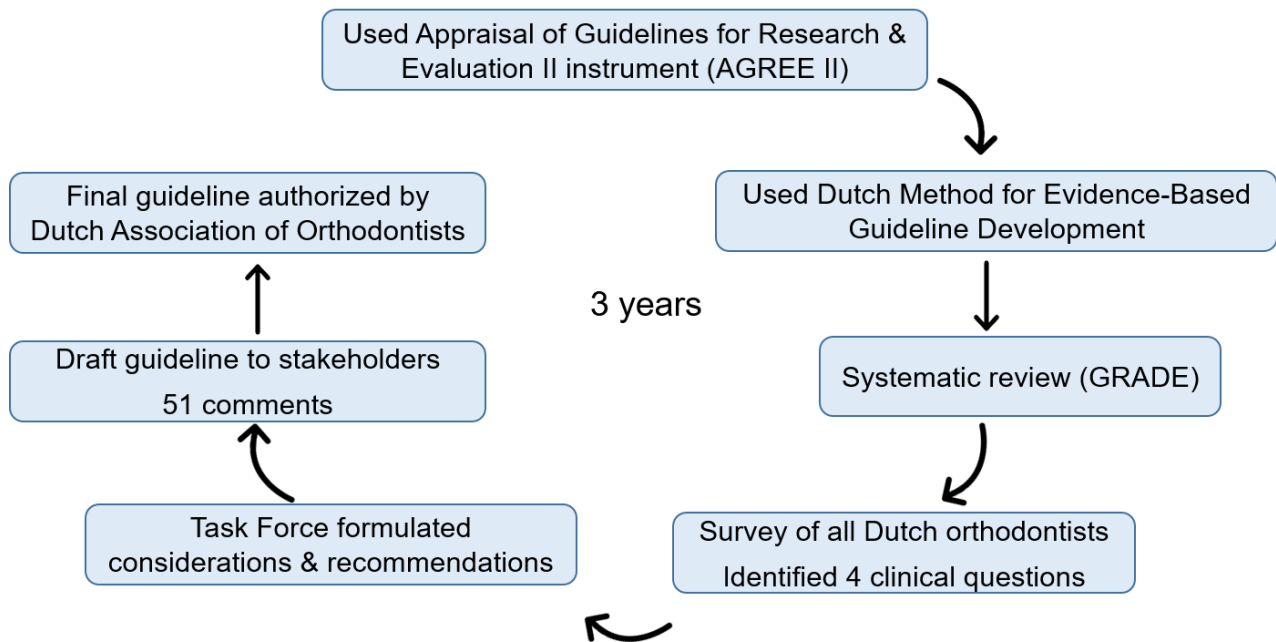


Figure 6. Development process of clinical practice guideline according to Sondejker et al. 2020 [82].

SUMMARY AND CONCLUSIONS

As new controversies evolve, there is a continual need to increase our knowledge-base in observational, interventional, retrospective and prospective studies. There is a clear need to conduct good quality primary studies that answer comparable PICO-based questions and use standardized comparable methodology and outcomes. The quality of primary and secondary in orthodontics studies is improving, and based on recent clinical practice guidelines, we have a framework or roadmap, not only to solve important controversies but possibly to develop further clinical practice guidelines and clinical care pathways.

REFERENCES

1. Bondemark L. How to succeed with high quality randomised clinical trials in clinical orthodontic research. *J Orthod* 2019;46(Suppl 1):13-16.
2. Pandis N. The evidence pyramid and introduction to randomized controlled trials. *Am J Orthod Dentofacial Orthop* 2011;140(3):446-447.
3. Sackett D. Evidence-based medicine. *Lancet* 1995;346(8983):1171.
4. Bondemark L, Ruf S. Randomized controlled trial: the gold standard or an unobtainable fallacy? *Eur J Orthod* 2015;37(5):457-461.
5. Pandis N, Tu YK, Fleming PS, Polychronopoulou A. Randomized and nonrandomized studies: complementary or competing? *Am J Orthod Dentofacial Orthop* 2014;146(5):633-640.
6. EQUATOR Network. Enhancing the QUALity and Transparency Of health Research

[<https://www.equator-network.org/>]

7. Turpin DL. CONSORT and QUOROM guidelines for reporting randomized clinical trials and systematic reviews. *Am J Orthod Dentofacial Orthop* 2005;128(6):681-685.
8. Alqaydi AR, Kanavakis G, Naser-Ud-Din S, Athanasiou AE. Authorship characteristics of orthodontic randomized controlled trials, systematic reviews, and meta-analyses in non-orthodontic journals with impact factor. *Eur J Orthod* 2018;40(5):480-487.
9. Flint HE, Harrison JE. How well do reports of clinical trials in the orthodontic literature comply with the CONSORT statement? *J Orthod* 2010;37(4):250-261.
10. Fleming PS, Buckley N, Seehra J, Polychronopoulou A, Pandis N. Reporting quality of abstracts of randomized controlled trials published in leading orthodontic journals from 2006 to 2011. *Am J Orthod Dentofacial Orthop* 2012;142(4):451-458.
11. Lempesi E, Koletsi D, Fleming PS, Pandis N. The reporting quality of randomized controlled trials in orthodontics. *J Evid Based Dent Pract* 2014;14(2):46-52.
12. Sandhu SS, Sandhu J, Kaur H. Reporting quality of randomized controlled trials in orthodontics--what affects it and did it improve over the last 10 years? *Eur J Orthod* 2015;37(4):356-366.
13. Seehra J, Wright NS, Polychronopoulou A, Cobourne MT, Pandis N. Reporting quality of abstracts of randomized controlled trials published in dental specialty journals. *J Evid Based Dent Pract* 2013;13(1):1-8.
14. Turner L, Shamseer L, Altman DG, Schulz KF, Moher D. Does use of the CONSORT Statement impact the completeness of reporting of randomised controlled trials published in medical journals? A Cochrane review. *Syst Rev* 2012;1:60.
15. Koletsi D, Fleming PS, Behrents RG, Lynch CD, Pandis N. The use of tailored subheadings was successful in enhancing compliance with CONSORT in a dental journal. *J Dent* 2017;67:66-71.
16. Pandis N, Shamseer L, Kokich V, Moher D. Implementation of adherence to the CONSORT guidelines by the American Journal of Orthodontics and Dentofacial Orthopedics (AJO-DO). In: *Peer Review Congress*. Chicago, USA 2013.
17. Pandis N, Shamseer L, Kokich VG, Fleming PS, Moher D. Active implementation strategy of CONSORT adherence by a dental specialty journal improved randomized clinical trial reporting. *J Clin Epidemiol* 2014;67(9):1044-1048.
18. Pandis N. Why do we need to adopt the CONSORT & PRISMA Reporting Guidelines? In: *EJO Open session at EOS Annual Congress*. Warsaw, Poland 2014.
19. Pandis N, Turpin DL. Enhancing CONSORT compliance for improved reporting of randomized controlled trials. *Am J Orthod Dentofacial Orthop* 2014;145(1):1.
20. Pandis N, Fleming PS, Hopewell S, Altman DG. The CONSORT Statement: Application within and adaptations for orthodontic trials. *Am J Orthod Dentofacial Orthop* 2015;147(6):663-679.
21. Schulz KF, Altman DG, Moher D, Group C. CONSORT 2010 statement: updated guidelines for reporting parallel group randomised trials. *BMJ* 2010;340:c332.
22. Hartley J. Current findings from research on structured abstracts. *J Med Libr Assoc* 2004;92(3):368-371.
23. Sharma S, Harrison JE. Structured abstracts: Do they improve the quality of information in abstracts? *American Journal of Orthodontics and Dentofacial Orthopedics* 2006;130(4):523-534.
24. Hopewell S, Clarke M, Moher D, Wager E, Middleton P, Altman DG, et al. CONSORT for reporting randomized controlled trials in journal and conference abstracts: explanation and elaboration. *PLoS Med* 2008;5(1):e20.
25. Pandis N. Sources of bias in clinical trials. *Am J Orthod Dentofacial Orthop* 2011;140(4):595-596.
26. Pandis N, Polychronopoulou A, Eliades T. Sample size estimation: an overview with applications to orthodontic clinical trial designs. *Am J Orthod Dentofacial Orthop* 2011;140(4):e141-146.
27. Pandis N. Use of controls in clinical trials. *Am J Orthod Dentofacial Orthop* 2012;141(2):250-251.
28. Pandis N. Blinding or masking. *Am J Orthod Dentofacial Orthop* 2012;141(3):389-390.
29. Pandis N, Polychronopoulou A, Eliades T. Randomization in clinical trials in orthodontics: its significance in research design and methods to achieve it. *Eur J Orthod* 2011;33(6):684-690.
30. Koletsi D, Pandis N, Polychronopoulou A, Eliades T. Does published orthodontic research account for clustering effects during statistical data analysis? *Eur J Orthod* 2012;34(3):287-292.

31. Spanou A, Koletsi D, Fleming PS, Polychronopoulou A, Pandis N. Statistical analysis in orthodontic journals: are we ignoring confounding? *Eur J Orthod* 2016;38(1):32-38.
32. Papageorgiou SN. Confounders in epidemiological associations. *J Orthod* 2019;46(3):267-269.
33. Papageorgiou SN. Clinically relevant sample size calculations for trials. *J Orthod* 201; 46(2):178-180.
34. Papageorgiou SN. Planning and interpreting the sample size of trials with multiple outcomes. *J Orthod* 2019;46(1):74-76.
35. Papageorgiou SN. On the Sample Size of Clinical Trials - Revisited. *J Orthod* 2018;45(4):296-298.
36. Harrison JE, Burnside G. Why does clustering matter in orthodontic trials? *Eur J Orthod* 2012;34(3):293-295.
37. Abdulraheem S, Bondemark L. Hawthorne effect reporting in orthodontic randomized controlled trials: truth or myth? Blessing or curse? *Eur J Orthod* 2018;40(5):475-479.
38. Brauholtz DA, Edwards SJ, Lilford RJ. Are randomized clinical trials good for us (in the short term)? Evidence for a "trial effect". *J Clin Epidemiol* 2001;54(3):217-224.
39. Papageorgiou SN. Patient drop-outs in clinical trials. *J Orthod* 2019;46(4):378-380.
40. Bondemark L, Abdulraheem S. Intention to treat (ITT) analysis as reported in orthodontic randomized controlled trials-evaluations of methodology and recommendations for the accurate use of ITT analysis and handling dropouts. *Eur J Orthod* 2018;40(4):409-413.
41. Bondemark L. Publication pattern, study design, authors and countries involved in orthodontic RCTs - a bibliometric MEDLINE survey over the past 50 years. *J Orthod* 2019;46(2):110-117.
42. Alharbi F, Almuzian M. The quality of reporting RCT abstracts in four major orthodontics journals for the period 2012-2017. *Journal of Orthodontics* 2019;46(3):225-234.
43. Abdulraheem S, Bondemark L. The reporting of blinding in orthodontic randomized controlled trials: where do we stand? *Eur J Orthod* 2019;41(1):54-58.
44. Papageorgiou SN, Xavier GM, Cobourne MT, Eliades T. Registered trials report less beneficial treatment effects than unregistered ones: a meta-epidemiological study in orthodontics. *J Clin Epidemiol* 2018;100:44-52.
45. Papageorgiou SN, Antonoglou GN, Sandor GK, Eliades T. Randomized clinical trials in orthodontics are rarely registered a priori and often published late or not at all. *Plos One* 2017;12(8).
46. Koufatzidou M, Koletsi D, Fleming PS, Polychronopoulou A, Pandis N. Outcome reporting discrepancies between trial entries and published final reports of orthodontic randomized controlled trials. *European Journal of Orthodontics* 2019;41(3):225-230.
47. Papageorgiou SN, Antonoglou GN, Martin C, Eliades T. Methods, transparency and reporting of clinical trials in orthodontics and periodontics. *J Orthod* 2019;46(2):101-109.
48. Richardson WS, Wilson MC, Nishikawa J, Hayward RS. The well-built clinical question: a key to evidence-based decisions. *ACP J Club* 1995;123(3):A12-13.
49. About Cochrane Reviews. What is a systematic review? [<https://www.cochranelibrary.com/about/about-cochrane-reviews>]
50. Liberati A, Altman DG, Tetzlaff J, Mulrow C, Gotzsche PC, Ioannidis JPA, et al. The PRISMA statement for reporting systematic reviews and meta-analyses of studies that evaluate healthcare interventions: explanation and elaboration. *Bmj-British Medical Journal* 2009;339.
51. Moher D, Liberati A, Tetzlaff J, Altman DG, Group P. Preferred reporting items for systematic reviews and meta-analyses: the PRISMA statement. *PLoS Med* 2009;6(7):e1000097.
52. Vasquez-Cardenas J, Zapata-Norena O, Carvajal-Florez A, Barbosa-Liz DM, Giannakopoulos NN, Faggion CM, Jr. Systematic reviews in orthodontics: Impact of the PRISMA for Abstracts checklist on completeness of reporting. *Am J Orthod Dentofacial Orthop* 2019;156(4):442-452 e412.
53. Sideri S, Papageorgiou SN, Eliades T. Registration in the international prospective register of systematic reviews (PROSPERO) of systematic review protocols was associated with increased review quality. *Journal of Clinical Epidemiology* 2018;100:103-110.
54. Fleming PS, Koletsi D, Ioannidis JPA, Pandis N. High quality of the evidence for medical and other health-related interventions was uncommon in Cochrane systematic reviews. *Journal of Clinical Epidemiology* 2016;78:34-42.
55. Papageorgiou SN, Eliades T. Evidence-based orthodontics: Too many systematic reviews, too few trials.

J Orthod 2019;46(Suppl 1):9-12.

56. Benson PE, Parkin N, Dyer F, Millett DT, Germain P. Fluorides for preventing early tooth decay (demineralised lesions) during fixed brace treatment. *Cochrane Database Syst Rev* 2019;(11).
57. Sonesson M, Twetman S, Bondemark L. Effectiveness of high-fluoride toothpaste on enamel demineralization during orthodontic treatment-a multicenter randomized controlled trial. *European Journal of Orthodontics* 2014;36(6):678-682.
58. Jiang H, Hua F, Yao L, Tai B, Du M. Effect of 1.23% acidulated phosphate fluoride foam on white spot lesions in orthodontic patients: a randomized trial. *Pediatr Dent* 2013;35(3):275-278.
59. Batista KB, Thiruvengkatachari B, Harrison JE, O'Brien KD. Orthodontic treatment for prominent upper front teeth (Class II malocclusion) in children and adolescents. *Cochrane Database Syst Rev* 2018;3:CD003452.
60. Thiruvengkatachari B, Harrison J, Worthington H, O'Brien K. Early orthodontic treatment for Class II malocclusion reduces the chance of incisal trauma: Results of a Cochrane systematic review. *Am J Orthod Dentofacial Orthop* 2015;148(1):47-59.
61. Alharbi F, Almuzian M, Bearn D. Miniscrews failure rate in orthodontics: systematic review and meta-analysis. *Eur J Orthod* 2018;40(5):519-530.
62. Field MJ, Lohr KN. Guidelines for Clinical Practice: From Development to Use. In: *Guidelines for Clinical Practice: From Development to Use*. edn. Edited by Field MJ, Lohr KN. Washington (DC); 1992.
63. Shekelle PG, Woolf SH, Eccles M, Grimshaw J. Clinical guidelines: developing guidelines. *BMJ* 1999;318(7183):593-596.
64. Council of Europe: Developing a methodology for drawing up guidelines on best medical practices. (Recommendation (2001)13 and explanatory memorandum). In: *Council of Europe Publishing*. 2003/09/11 edn. F-67075 Strasbourg Cedex: Council of Europe Publishing; 2002: 5-59.
65. Oosterkamp BCM, van der Sanden WJM, Frencken JEFM, Kuijpers-Jagtman AM. Caries preventive measures in orthodontic practice: the development of a clinical practice guideline. *Orthodontics & Craniofacial Research* 2016;19(1):36-45.
66. Lawal AK, Rotter T, Kinsman L, Machotta A, Ronellenfitch U, Scott SD, et al. What is a clinical pathway? Refinement of an operational definition to identify clinical pathway studies for a Cochrane systematic review. *Bmc Medicine* 2016;14.
67. Kinsman L, Rotter T, James E, Snow P, Willis J. What is a clinical pathway? Development of a definition to inform the debate. *Bmc Medicine* 2010;8.
68. Turpin DL. The case for treatment guidelines. *Am J Orthod Dentofacial Orthop* 2007;131(2):159.
69. Turpin DL. Improve care with clinical practice guidelines. *Am J Orthod Dentofacial Orthop* 2009;136(4):475-476.
70. American Association of Orthodontists: Clinical practice guidelines for orthodontics and dentofacial orthopedics. In: *American Association of Orthodontists*; 2019.
71. Tejani T, Mubeen S, Seehra J, Cobourne MT. An exploratory quality assessment of orthodontic clinical guidelines using the AGREE II instrument. *European Journal of Orthodontics* 2017;39(6):654-659.
72. Husain J, Burden D, McSherry P, Morris D, Allen M. Clinical Standards Committee of the Faculty of Dental Surgery RCoSoE: National clinical guidelines for management of the palatally ectopic maxillary canine. *Br Dent J* 2012;213(4):171-176.
73. Mini/micro screw implantation for orthodontic anchorage, Interventional procedures guidance [IPG238]. In: *National Institute for Health and Clinical Excellence* 2007.
74. Energy Protection Radiation No 172: Cone Beam CT for Dental and Maxillofacial Radiology. Evidence based guidelines. In: *European Commition* 2012.
75. AGREE, Advancing the science of practice guidelines [<https://www.agreetrust.org/>]
76. Brouwers MC, Kerkvliet K, Spithoff K, Consortium ANS: The AGREE Reporting Checklist: a tool to improve reporting of clinical practice guidelines. *Bmj-British Medical Journal* 2016;352.
77. Seehra J, Yaqoob O, Patel S, O'Neill J, Bryant C, Noar J, et al. National clinical guidelines for the management of unerupted maxillary incisors in children. *Br Dent J* 2018;224(10):779-785.
78. Husain J, Burden D, McSherry P. Management of the Palatally Ectopic Maxillary Canine. In: *Royal College of Surgeons of England Faculty of Dental Surgery* 2016.

79. Cobourne MT, Williams A, Harrison M. National clinical guidelines for the extraction of first permanent molars in children. *Br Dent J* 2014;217(11):643-648.
80. Isaacson KG, Thom AR, Atack NE, Horner K, Whaites E. Guidelines for the use of radiographs in clinical orthodontics In: *British Orthodontic Society* 2015.
81. Wouters C, Lamberts TA, Kuijpers-Jagtman AM, Renkema AM. Development of a clinical practice guideline for orthodontic retention. *Orthod Craniofac Res* 2019;22(2):69-80.
82. Sondejker CFW, Lamberts AA, Beckmann SH, Kuitert RB, van Westing K, Persoon S, et al. Development of a clinical practice guideline for orthodontically induced external apical root resorption. *Eur J Orthod* 2020;42(2):115-124.
83. Mubeen S, Patel K, Cunningham Z, O'Rourke N, Pandis N, Cobourne MT et al. Assessing the quality of dental clinical practice guidelines. *J Dent* 2017;67:102-106.
84. Oosterkamp BCM, Wafae A, Schols JGJH, van der Sanden WJM, Wensing M. Effectiveness of a clinical guideline to improve dental health among orthodontically treated patients: study protocol for a cluster randomized controlled trial. *Trials* 2016;17:201.
85. Chen Y, Yang K, Marusic A, Qaseem A, Meerpohl JJ, Flottorp S, et al. A Reporting Tool for Practice Guidelines in Health Care: The RIGHT Statement. *Ann Intern Med* 2017;166(2):128-132.
86. Littlewood SJ, Millett DT, Doubleday B, Bearn DR, Worthington HV. Retention procedures for stabilising tooth position after treatment with orthodontic braces. *Cochrane Database Syst Rev* 2016(1):CD002283.

EXTRACELLULAR MICRORNA EXPRESSION IN GINGIVAL CREVICULAR FLUID DURING TOOTH MOVEMENT

*Phimon Atsawasuwan, Sajjad Shirazi, Sibel Altun, Christyne Chmil, Amy Seagraves,
Mohammed Elnagar*

ABSTRACT

Orthodontic tooth movement is a relay process of mechanical force into periodontal ligament and alveolar bone cells to initiate biological signaling cascades for periodontal tissue and alveolar bone remodeling, and these processes are strictly regulated at post-transcriptional and post-translational levels. MicroRNAs are small noncoding RNAs emerging as critical post-translational modulators of proliferation, differentiation, and survival of periodontal ligament cells, osteoblasts, osteocytes, and osteoclasts, which are the crucial cells for orthodontic tooth movement. In addition, certain miRNAs are responsive to the mechanical force loading; and the disruption of normal miRNA expression in the crucial cells for orthodontic tooth movement leads to dysfunction of these cells and abnormal periodontal tissue remodeling resulting in defective orthodontic tooth movement *in vivo*. Emerging discovery of extracellular miRNAs in gingival crevicular fluid (GCF) sheds light on their potential as biomarkers/biomolecules for many oral diseases and the treatment including modification of orthodontic tooth movement. Several extracellular miRNAs demonstrated a good correlation between their expression in GCF and the distance of tooth movement in humans during orthodontic treatment. These extracellular miRNAs could potentially be used as biomarkers or modifiers of the rate of tooth movement in the future.

KEY WORDS: Extracellular microRNA, Gingival Crevicular Fluid, Orthodontic Tooth Movement, Biomarkers

INTRODUCTION

Orthodontic tooth movement is a complex biological process of bone remodeling which involves translation of mechanical loading to biological signals by periodontal ligament (PDL) and alveolar bone (AB) cells such as osteocytes, osteoblasts, and osteoclasts. The mechanotransduction of signals involves dynamic cellular communication and requires a coordinated cellular response for alveolar bone remodeling [1]. The signal on teeth initiates a series of cascades of biological processes involving adaptive tissue remodeling of periodontium for both anabolic and catabolic events. The forces relayed from orthodontic appliances create stress and strain to the PDL and AB cells and their surrounding extracellular matrices (ECM) leading to the expression and secretion of biologic mediators and inflammatory cytokines, apoptotic factors, osteoclast differentiation factors and ECM proteins and their modifying enzymes and proteases. These cellular and molecular events are strictly controlled at transcriptional, post-transcriptional, and translational levels and the interference of these events affects the rate of tooth movement [2].

The central dogma of biology – that information is transferred from DNA to mRNA to protein in a linear fashion – is an oversimplification of the true process. There are a plethora of intricate steps and molecules involved in the complex process, and one such molecule is microRNA (miRNA). miRNAs are small (~22 nucleotides, nt), endogenous non-coding RNAs that orchestrate complex posttranscriptional regulatory networks essential to the regulation of gene expression [3-5]. Biogenesis of miRNA begins with primary miRNA (pri-miRNA) strand that is either transcribed directly from genes or from the introns of the genes via RNA polymerase II, and independently folded into hairpin loops. Ribonuclease (RNase) Drosha and DiGeorge syndrome chromosomal region 8 (DGCR8) form a micro-processing complex to identify and cleave the pri-miRNA into precursor miRNA (pre-miRNA), which is 65-70 nt long [6]. Then the pre-miRNA is recognized by exportin-5 and transported out of the nucleus via Ran-GTP-dependent mechanism [3, 6]. Once the pre-miRNA is in the cytoplasm, Dicer splices it to ~22-24 nt long segments. Dicer interacts with the protein Argonaute (Ago) to form the miRNA/miRNA duplex where Ago unwinds the hairpin loop structure. In most circumstances, one strand, known as the passenger strand, is released and degraded in the cytoplasm while the other strand, known as the guide strand, continues to interact with Ago alone or with Ago and glycine-tryptophan protein of 182 kD (GW182). This complex is known as miRNA induced silencing complex (miRISC) and houses the mature miRNA strand. miRISC is guided to targeted mRNAs and binds to the 3' untranslated region (3'UTR) of target mRNAs through complement base pairing to inhibit translation or cause deadenylation of the poly(A) tail to enhance the degradation of the target mRNA [7, 8]. The components involved in the miRISC complex determine how gene silencing will occur. If Ago is only present in the miRISC, the mRNA will be degraded. If the miRISC consists of GW182 and Ago, then the complex will perform translational repression [9, 10].

Studies showed that miRNAs are highly conserved in nature and important in the development of healthy and diseased states in organisms. miRNAs do not act as a gene silencer with an on/off switch but rather act epigenetically to calibrate gene expression [11]. Furthermore, miRNAs with other transcription factors can use single-negative or double-negative feedback loops for self-regulation [7]. Understanding the complexity of miRNA function has been challenging because there is not one miRNA for one mRNA. Due to the short nucleotide sequences, specificity for certain targets is limited, thus one miRNA may have many complementary binding sites. The perfect complementary pairing of all the nucleotides will result in endonucleolytic cleavage of the miRNA by Ago2. However, partial complementary pairing will induce gene regulation as well. The usual motif of perfect pairing occurs in a seed region from the 2nd to 7th nt at the 5' end of the miRNA. If this seeding pairing does not occur, then extensive pairing is needed at the 3' end of the miRNA. If there is an imperfect pairing, deadenylation of the poly(A) tail will occur. This flexibility allows for one miRNA to bind to numerous sites of a single mRNA and for one mRNA to pair with multiple miRNAs at its 3' UTR sites [8].

miRNAs with periodontal tissue and alveolar bone remodeling

Orthodontic tooth movement is a biological process that requires the relay of mechanical loading forces to initiate biological signals by periodontal ligament (PDL) and alveolar bone (AB) cells such as osteoblasts, osteocytes and osteoclasts [12, 13]. Reports showed several miRNAs play critical roles in the proliferation, differentiation, and maturation of these critical cells (See Table 1). The disruption of certain miRNAs in these cells causes abnormal tissue remodeling during orthodontic tooth movement resulting in either deceleration or acceleration of the rate of tooth movement.

Table 1. Selected miRNAs and their target genes and functions on PDL cells and AB cells.

Periodontal ligament cells

miRNA(s)	Target gene (s)	Cell model (s)	Function
miR-21 [14-17]	SMAD5, PLAP-1, ACVR2B, PCDC4	hPDL stem cells	Inhibit osteogenic differentiation
	HIF1 α pathway	mPDL cells	Promote osteogenic differentiation
miR-22 [18]	HDAC5	hPDL stem cells	Promote osteogenic differentiation
miR-23a [19]	BMPR1B	hPDL stem cells	Inhibit osteogenic differentiation
miR-24-3p [20]	SMAD5	hPDL stem cells	Promote osteogenic differentiation
miR-29 [21]	Coll, III, V	hPDL cells	Inhibit osteogenic differentiation
miR-101 [17]	PLAP-1	hPDL cells	Inhibit osteogenic differentiation
miR-125 [22]	NKIRAS2	hPDL cells	Inhibit osteogenic differentiation
miR-132 [23]	GDF5	hPDL stem cells	Inhibit osteogenic differentiation
miR-146a [24]	IL-17, IL-35	hPDL stem cells	Inhibit proliferation
miR-195-5p [25]	WNT3A, BMPR1A	hPDL cells	Inhibit osteogenic differentiation
miR-210 [26]	HIF3 α	hPDL cells	Decrease cell apoptosis
miR-214 [27, 28]	CTNNB1	hPDL stem cells	Promote osteogenic differentiation
	ATF4	hPDL stem cells	Inhibit osteogenic differentiation
miR-543 [29]	ERBB2	hPDL stem cells	Promote osteogenic differentiation
miR-646 [30]	IGF-1	hPDL cells	Promote cell apoptosis

hPDL; human periodontal ligament cells

Osteoblasts

miRNA(s)	Target gene(s)	Cell model(s)	Function
miR-23a [31-33]	FAS, RUNX2, SATB2	MC3T3-E1	Suppress cell differentiation
miR-27 [34, 35]	APC, SFRP1	hFOB	Promote cell differentiation
miR-29a [36]	DKK1, Kremen2, SFRP2	hFOB	Promote cell differentiation
miR-29 [37, 38]	SPARC, ACVR2a, DUSP2, TGF- β 3, CTNNBIP1, HDAC4	MC3T3-E1	Promote cell differentiation
miR-30c [32, 39]	RUNX2, SMAD1	MC3T3-E1	Suppress cell differentiation
miR-34 [32, 40]	RUNX2, SATB2	MC3T3-E1	Suppress cell differentiation
miR-93 [41]	SP7	MC3T3-E1	Suppress cell differentiation
miR-96 [42]	HB-EGF	MC3T3-E1	Promote cell differentiation
miR-103a [43]	RUNX2	hFOB	Suppress cell differentiation
miR-124 [44, 45]	DLX2, 3 and 5, MSX2	MC3T3-E1	Suppress cell differentiation
miR-133,135,137 [32]	RUNX2	MC3T3-E1	Suppress cell differentiation
miR-141 [46]	DLX5, SVCT2	MC3T3-E1	Suppress cell differentiation
miR-143 [47]	SP7	MC3T3-E1	Suppress cell differentiation
miR-145 [48]	SP7	MC3T3-E1	Suppress cell differentiation

miR-146a [49]	SMAD 2 and 3	h Osteoblast	Suppress cell differentiation
miR-155 [50, 51]	SOCS1, SMAD5	MC3T3-E1	Suppress cell differentiation
miR-181a [52]	TFG- β i	MC3T3-E1	Promote cell differentiation
miR-194 [53, 54]	T β R-I/ALK5	MC3T3-E1	Promote cell differentiation
miR-200a [46]	RGS4	MC3T3-E1	Suppress cell differentiation
miR-203 [55]	GATA6	h Osteoblast	Suppress cell differentiation
miR-204 [32, 56]	STAT1	MC3T3-E1	Promote cell differentiation
miR-205 [32]	RUNX2	MC3T3-E1	Suppress cell differentiation
miR-211 [56]	DLX5, SVCT2	MC3T3-E1	Suppress cell differentiation
miR-214 [57]	DLX5	h Osteoblast	Suppress cell differentiation
miR-214 [58]	RUNX2	MC3T3-E1	Suppress cell differentiation
miR-217 [32]	RUNX2	MC3T3-E1	Suppress cell differentiation
miR-218 [59]	RUNX2	MC3T3-E1	Suppress cell differentiation
miR-223-5p [60]	ATF4, SP7	MC3T3-E1, hFOB	Suppress cell differentiation
miR-320b [55]	RUNX2	MC3T3 E1	Suppress cell differentiation
miR-322 [61]	DDK2, SFRP2, SOST	MC3T3-E1	Promote cell differentiation
miR-375-3p [62]	COUP-TFII	MC3T3-E1	Promote cell differentiation
miR-433-3p [63]	DLX5	h Osteoblast	Suppress cell differentiation
miR-505 [64]	TOB2	MC3T3-E1	Suppress cell differentiation
miR-542-3p [65]	FGFR2, RUNX2	MC3T3 E1	Suppress cell differentiation
miR-764-5p [66]	LRP5, β -catenin	MC3T3-E1	Suppress osteogenesis

MC3T3-E1: mouse calvarial preosteoblast cells. hFOB: human osteoblast

Osteocytes

miRNA(s)	Target gene(s)	Cell model(s)	Function
miR-21 [67, 68]	PTEN	MLO-Y4 primary bone cells	Increased apoptosis Reduced cell viability in females Increased cell viability in males
miR-27a [69]	PRDM16	primary bone cells	Promote differentiation
miR-145-5p [70]	β -catenin	primary bone cells	Impaired osteocytogenesis
miR-199-3p [71]	IGF-I, mTOR	MLO-Y4	Induce autophagy of cells

MLO-Y4: mouse osteocyte-like cells

Osteoclasts

miRNA(s)	Target gene (s)	Cell model (s)	Function
miR-7b [72]	DC-STAMP	RAW264.7	Inhibit osteoclastogenesis
miR-9 [73]	CBL	RAW264.7	Increase osteoclastogenesis
miR-20a [74]	ATG1611	RAW264.7	Increase osteoclastogenesis
miR-21 [75, 76]	c-FOS/ PDCD4, FASL	Dicer and DGCR8 deficient, BMMs	Increase osteoclastogenesis
miR-26a [77]	CTGF	BMMs	Inhibit osteoclastogenesis
miR-27a [78]	PPAR γ , APC	mBMMs	Inhibit osteoclastogenesis
miR-29 [79]	CDC42, SrGAP2, NFIA, CD93, CALCR	BMMs, RAW 264.7	Increase osteoclastogenesis

miR-29 [80, 81]	TNFSF13b, C-FOS, MMP2	BMMs, hPBMCs	Inhibit osteoclastogenesis
miR-30a [82]	DC-STAMP	BMMs	Inhibit osteoclastogenesis
miR-31 [83]	RHOA	mBMMs	Increase osteoclastogenesis
miR-34a [84]	TGIF2	mBMMs, hPBMCs	Inhibit osteoclastogenesis
miR-34c [85]	LGR4	RAW264.7, BMMs	Increase osteoclastogenesis
miR-100-5p [86]	FGF21	mBMMs	Inhibit osteoclastogenesis
miR-101-3p [87]	Rap1b	BMMs	Inhibit osteoclastogenesis
miR-106b [88]	RANKL	mBMMs	Inhibit osteoclastogenesis
miR-124 [89, 90]	NFATc1, RAB27a	BMMs	Inhibit osteoclastogenesis
miR-125a [91]	TRAF6	PBMCs	Inhibit osteoclastogenesis
miR-125a-5p [92]	TNFRSF1B	RAW 264.7	Increase osteoclastogenesis
miR-126-5p [93]	MMP13	mBMMs	Inhibit osteoclastogenesis
miR-142-5p [94]	PTEN	rBMMs	Increase osteoclastogenesis
miR-145-5p [95]	OPG	BMCS, RAW264.7	Increase osteoclastogenesis
miR-145 [96]	SMAD3	BMMs	Inhibit osteoclastogenesis
miR-148a [97]	MAFB	PBMCs, PBMCs	Increase osteoclastogenesis
miR-155 [98]	SOCS1, MITF	mBMMs	Inhibit osteoclastogenesis
miR-181a [73]	CBL	RAW264.7	Increase osteoclastogenesis
miR-181b-5p [99]	Oncostatin M	RAW264.7	Inhibit osteoclastogenesis
miR-183 [100]	HO-1	RAW264.7	Increase osteoclastogenesis
miR-199a-5p [101]	MAFB	mBMMs, RAW 264.7	Increase osteoclastogenesis
miR-214-3p [102, 103]	TRAF3, PTEN	mBMMs, RAW 264.7	Increase osteoclastogenesis
miR-218 [104, 105]	c-FOS, NFATc1, MMP9, TNFR1	PBMCs, RAW264.7	Inhibit osteoclastogenesis
miR-223 [106]	NFI-A, M-CSFR	mBMMs	Inhibit osteoclastogenesis
miR-338-3p [107, 108]	IKK β , RANK	RAW264.7	Inhibit osteoclastogenesis
miR-340 [109]	MITF	mBMMs	Inhibit osteoclastogenesis
miR-483-5p [110]	IGF2	hPBMCs	Increase osteoclastogenesis
miR-503 [111]	RANK	hPBMCs	Inhibit osteoclastogenesis
miR-506-3p [112]	NFATc1	rBMMs	Inhibit osteoclastogenesis
miR-9718 [113]	STAT3 (PIAS3)	RAW 264.7	Increase osteoclastogenesis

RAW 264.7: mouse macrophage, h: human, m: mouse, BMM: bone marrow macrophage, PBMC: peripheral blood mononuclear cell

Extracellular microRNAs

miRNAs can be characterized as intracellular or extracellular miRNAs. The extracellular miRNAs are also referred to as circulatory or secretory because they are not located in cells, but rather in body fluids. The extracellular miRNAs were found to be remarkably stable under wide ranges of temperatures and pH [114, 115]. Several studies showed that extracellular miRNAs are associated with microvesicles, exosome, and apoptotic bodies. Some of these miRNAs bind with lipoprotein complexes such as high-density lipoprotein (HDL) or RNA binding protein such as Ago2, so they are protected from degradation [116, 117] (Figure 1). Since the extracellular miRNAs are found in many body fluids, they have become attractive candidates for biomarkers of healthy and diseased states. Hundreds of detectable miRNAs have been isolated from 12 body fluids: saliva, cerebrospinal fluid, tears, plasma, bronchial lavage, peritoneal fluid, pleural fluid, urine, amniotic fluid, breast milk, colostrum and seminal fluid and later found in

follicular fluid [118, 119]. In the field of dentistry, extracellular miRNAs have been found in saliva and gingival crevicular fluid (GCF) [120- 122].

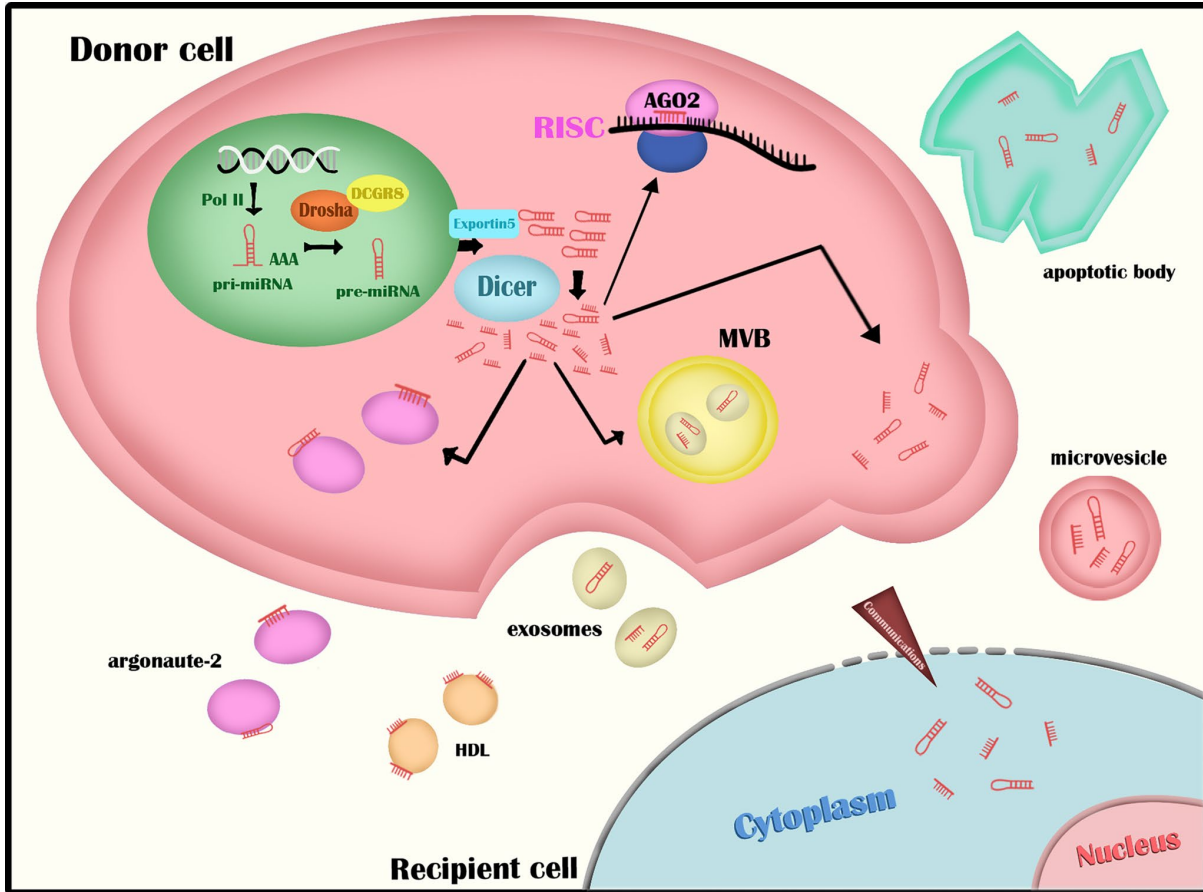


Figure 1. miRNA biogenesis and reported release mechanism of extracellular miRNA. Pri-miRNAs are transcribed by RNA polymerase II and further processed by Drosha and DGCR8 to Pre-miRNA. Exportin 5 transferred the Pre-miRNAs from nucleus to cytoplasm where Dicer cleaved their structures into mature miRNAs. Mature miRNAs are selectively incorporated into either canonical pathway and function as intracellular miRNAs or incorporated into multivesicular bodies (MVB) and packaged with exosomes, microvesicles or coupled with Argonaute-2 (Ago2) protein or high-density lipoprotein (HDL) and released into extracellular environment.

Gingival crevicular fluid (GCF)

GCF was first described by Waerhaug in 1952 [123]. It is a serum transudate or exudate depending on local inflammatory conditions that surround the tooth in the gingival sulcus. It is originated from the gingival plexus of blood vessels located in the gingival corium and is subjacent to the epithelial lining of the sulcus [124]. It contains cytokines, proteins, growth factors, inorganic ions, enzymes, bacterial products, and miRNAs [121, 122, 125, 126]. The ease and convenience of collecting GCF through absorbent filter Periopaper® strips have made it a promising and well-studied tool for evaluating biomarkers of oral diseases, especially periodontal disease [121, 122, 124, 126].

Extracellular microRNA and orthodontic tooth movement

Previous studies have revealed that miRNAs are critical post-transcriptional modulators during cell formation, differentiation and maturation of periodontal ligament cells, osteoblasts, osteocytes and osteoclasts [127-129]. Since alveolar bone and periodontal tissue remodeling are required during orthodontic tooth movement when the periodontal cells/tissue and alveolar bone are subjected to mechanical forces via orthodontic appliances, certain miRNAs have been demonstrated to respond to mechanical loading in cultured human periodontal ligament cells, osteoblast and osteocytes [21, 28, 130-135]. In addition, the expression of certain miRNAs in periodontal tissues has been shown to be correlated with the loading force during orthodontic tooth movement *in vivo*. miRNA -21 is one of the several miRNAs that play a significant role in PDL cells and osteoclasts during tooth movement. miRNA-21 deficiency inhibited orthodontic tooth movement in mice and the expression of miRNA-21 in periodontal tissue responded to the orthodontic force in a dose and time-dependent manner by targeting programmed cell death 4 (PDCD4) [15]. Several possible mechanisms of how miRNA -21 contribute to defective tooth movement *in vivo* have been shown such as targeting hypoxia-inducible factor-1 α (HIF-1 α) in periodontal ligament, targeting PDCD4 in osteoclasts [16, 136] and modulating the RANKL/OPG balance in T cells [16, 137]. miRNA -34a has been shown to play a critical role in the inhibition of osteoclastogenesis by targeting transforming growth factor-induced factor 2 (TGIF2) and local-delivery of miRNA -34a into the alveolar bone during tooth movement *in vivo* enhanced expression of osteogenic protein such as Runx2, Collagen I, and diminished tooth movement [84, 138]. miRNA -29 has been shown to affect osteoblast and osteoclast differentiation and the expression patterns of miR-29 family (a,b,c) in human PDL cells were affected by types of loading forces [21, 38, 70, 139]. The suppression of the miRNA -29 family in mice inhibited osteoclastogenesis and led to delayed tooth movement [140]. The presence of extracellular miRNAs in GCF was recently reported and mainly associated with periodontal diseases and few with orthodontic tooth movement [121, 122, 141-143].

The first study of an association between extracellular microRNAs in the GCF was conducted using a human canine retraction model. The study evaluated the presence of extracellular miRNA-29 family in the GCF and demonstrated the expression profiles of the miRNA-29 family during the canine retraction using the elastomeric chain for a 6-week period. In addition, the result suggested that the extracellular miRNAs in the GCF were closely associated with exosome in the GCF [122]. In order to verify the correlation of constant orthodontic force, the distance of tooth movement and the expression of extracellular miRNA in the GCF during orthodontic tooth movement, the 100-g of calibrated springs were used to retract the canine for space closure and the superimposition of digital model scans at each time-point of the study using Geomagic 3D software was used for evaluation of the distance of tooth movement during 7-week of human canine retraction. The GCF was collected with Periopaper® strips at baseline before treatment, day of bracket bonding, 2-week, 5-week and 7-week after bonding (Figure 2). The result verified the presence of extracellular miRNAs in GCF during tooth movement and several miRNAs such as miRNA-21, -27 family, -29 family, -124, -143, -145, and -155 showed a moderate correlation of their expression with the distance of tooth movement (unpublished data).

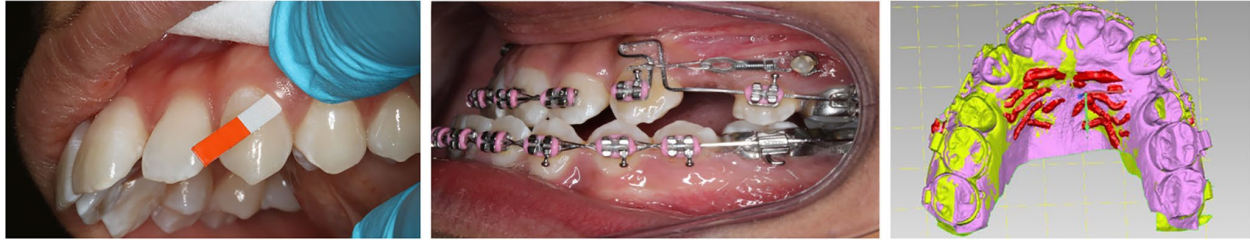


Figure 2. **Left:** The collection of gingival crevicular fluid (GCF) after the supragingival plaque was removed and the canine is isolated with a cotton roll. A Periopaper[®] was inserted gently 1-2 mm in the gingival sulcus for 60 seconds then placed into the storage medium. **Middle:** The setting of canine retraction: The sectional 016x022 stainless steel wire with an L-loop was ligated onto the retracted canine and the 100g calibrated spring was ligated to a temporary anchorage miniscrew placed between second premolar and first molar, and the front arm of the L-loop. Note that there was a 3 mm gap between the front and back arm of the L-loop to allow the distal movement of the retracted canine during the period of study. **Right:** The superimposition of intraoral digital scans using rugae and the miniscrew as stable landmarks. T1 (yellow), T4 (pink), Rugae (red).

CONCLUSIONS

The presence of extracellular miRNAs in GCF and the association of their expression levels with the distance of tooth movement showed the promising indication as biomarkers for tooth movement. However, the limitation of the evaluation of these extracellular microRNAs is the volume of GCF and the normalization process of these miRNAs in the specific body fluid such as GCF [122]. As the discovery of extracellular microRNAs in GCF and their correlation with the distance of tooth movement has been elucidated, the remaining questions of what target genes are involved in tooth movement and the cells that generate these extracellular miRNAs need to be further investigated.

REFERENCES

1. King GJ, Keeling SD, McCoy EA, Ward TH. Measuring dental drift and orthodontic tooth movement in response to various initial forces in adult rats. *Am J Orthod Dentofacial Orthop* 1991;99:456-465.
2. Krishnan V, Davidovitch Z. On a path to unfolding the biological mechanisms of orthodontic tooth movement. *J Dent Res* 2009;88:597-608.
3. Bartel DP. Metazoan MicroRNAs. *Cell* 2018;173:20-51.
4. Eulalio A, Huntzinger E, Izaurralde E. Getting to the root of miRNA-mediated gene silencing. *Cell* 2008;132:9-14.
5. Yates LA, Norbury CJ, Gilbert RJ. The long and short of microRNA. *Cell* 2013;153:516-519.
6. Denli AM, Tops BB, Plasterk RH, Ketting RF, Hannon GJ. Processing of primary microRNAs by the Microprocessor complex. *Nature* 2004;432:231-235.
7. Krol J, Loedige I, Filipowicz W. The widespread regulation of microRNA biogenesis, function and decay. *Nat Rev Genet* 2010;11:597-610.
8. Pasquinelli AE. MicroRNAs and their targets: recognition, regulation and an emerging reciprocal relationship. *Nat Rev Genet* 2012;13:271-282.

9. Fabian MR, Sonenberg N. The mechanics of miRNA-mediated gene silencing: a look under the hood of miRISC. *Nat Struct Mol Biol* 2012;19:586-593.
10. Huntzinger E, Izaurralde E. Gene silencing by microRNAs: contributions of translational repression and mRNA decay. *Nat Rev Genet* 2011;12:99-110.
11. Sera SR, Zur Nieden NI. microRNA Regulation of Skeletal Development. *Curr Osteoporos Rep* 2017;15:353-366.
12. Atsawasuwan P, Shirazi S. Advances in Orthodontic Tooth Movement: Gene Therapy and Molecular Biology Aspect. In: *Current Approaches in Orthodontics*. Aslan BI, Uzuner FD, eds: IntechOpen 2018; 51-72.
13. Shirazi S, Kachoei M, Shahvaghari-Asl N, Shirazi S, Sharghi R. Arch width changes in patients with Class II division 1 malocclusion treated with maxillary first premolar extraction and non-extraction method. *Journal of clinical and experimental dentistry* 2016;8:403-408.
14. Wei F, Yang S, Guo Q, Zhang X, Ren D, Lv T, et al. MicroRNA-21 regulates Osteogenic Differentiation of Periodontal Ligament Stem Cells by targeting Smad5. *Sci Rep* 2017;7:16608.
15. Chen N, Sui BD, Hu CH, Cao J, Zheng CX, Hou R, et al. MicroRNA-21 Contributes to Orthodontic Tooth Movement. *J Dent Res* 2016;95:1425-1433.
16. Zhang X, Chen D, Zheng J, Deng L, Chen Z, Ling J, et al. Effect of microRNA-21 on hypoxia-inducible factor-1 α in orthodontic tooth movement and human periodontal ligament cells under hypoxia. *Exp Ther Med* 2019;17:2830-2836.
17. Li C, Li C, Yue J, Huang X, Chen M, Gao J, et al. miR-21 and miR-101 regulate PLAP-1 expression in periodontal ligament cells. *Mol Med Rep* 2012;5:1340-1346.
18. Yan GQ, Wang X, Yang F, Yang ML, Zhang GR, Wang GK, et al. MicroRNA-22 Promoted Osteogenic Differentiation of Human Periodontal Ligament Stem Cells by Targeting HDAC6. *J Cell Biochem* 2017;118:1653-1658.
19. Zhang Y, Li S, Yuan S, Zhang H, Liu J. MicroRNA-23a inhibits osteogenesis of periodontal mesenchymal stem cells by targeting bone morphogenetic protein signaling. *Arch Oral Biol* 2019;102:93-100.
20. Li Z, Sun Y, Cao S, Zhang J, Wei J. Downregulation of miR-24-3p promotes osteogenic differentiation of human periodontal ligament stem cells by targeting SMAD family member 5. *J Cell Physiol* 2019;234:7411-7419.
21. Chen Y, Mohammed A, Oubaidin M, Evans CA, Zhou X, Luan X, et al. Cyclic stretch and compression forces alter microRNA-29 expression of human periodontal ligament cells. *Gene* 2015;566:13-17.
22. Xue N, Qi L, Zhang G, Zhang Y. miRNA-125b Regulates Osteogenic Differentiation of Periodontal Ligament Cells Through NKIRAS2/NF-kappaB Pathway. *Cell Physiol Biochem* 2018;48:1771-1781.
23. Xu Y, Ren C, Zhao X, Wang W, Zhang N. microRNA-132 inhibits osteogenic differentiation of periodontal ligament stem cells via GDF5 and the NF-kappaB signaling pathway. *Pathol Res Pract* 2019;215:152722.
24. Zhao S, Cheng Y, Kim JG. microRNA-146a downregulates IL-17 and IL-35 and inhibits proliferation of human periodontal ligament stem cells. *J Cell Biochem* 2019;120:13861-13866.
25. Chang M, Lin H, Fu H, Wang B, Han G, Fan M. MicroRNA-195-5p Regulates Osteogenic Differentiation of Periodontal Ligament Cells Under Mechanical Loading. *J Cell Physiol* 2017;232:3762-3774.
26. Jia S, Yang X, Yang X, Zhang F. MicroRNA-210 protects against periodontitis through targeting HIF-3 α and inhibiting p38MAPK/NF-kappaB pathway. *Artif Cells Nanomed Biotechnol* 2020;48:129-136.
27. Cao F, Zhan J, Chen X, Zhang K, Lai R, Feng Z. miR-214 promotes periodontal ligament stem cell osteoblastic differentiation by modulating Wnt/betacatenin signaling. *Mol Med Rep* 2017;16:9301-9308.

28. Yao S, Zhao W, Ou Q, Liang L, Lin X, Wang Y. MicroRNA-214 Suppresses Osteogenic Differentiation of Human Periodontal Ligament Stem Cells by Targeting ATF4. *Stem Cells Int* 2017;2017:3028647.
29. Ge Y, Li J, Hao Y, Hu Y, Chen D, Wu B, et al. MicroRNA-543 functions as an osteogenesis promoter in human periodontal ligament-derived stem cells by inhibiting transducer of ERBB2, 2. *J Periodontal Res* 2018;53:832-841.
30. Yang J, Zhou J, Cui B, Yu T. Evaluation of Hypoxia on the Expression of miR-646/IGF-1 Signaling in Human Periodontal Ligament Cells (hPDLs). *Med Sci Monit* 2018;24:5282-5291.
31. Dong J, Cui X, Jiang Z, Sun J. MicroRNA-23a modulates tumor necrosis factor-alpha-induced osteoblasts apoptosis by directly targeting Fas. *J Cell Biochem* 2013;114:2738-2745.
32. Zhang Y, Xie RL, Croce CM, Stein JL, Lian JB, van Wijnen AJ, et al. A program of microRNAs controls osteogenic lineage progression by targeting transcription factor Runx2. *Proc Natl Acad Sci U S A* 2011;108:9863-9868.
33. Hassan MQ, Gordon JA, Beloti MM, Croce CM, van Wijnen AJ, Stein JL, et al. A network connecting Runx2, SATB2, and the miR-23a~27a~24-2 cluster regulates the osteoblast differentiation program. *Proc Natl Acad Sci U S A* 2010;107:19879-19884.
34. Wang T, Xu Z. miR-27 promotes osteoblast differentiation by modulating Wnt signaling. *Biochem Biophys Res Commun* 2010;402:186-189.
35. Guo D, Li Q, Lv Q, Wei Q, Cao S, Gu J. MiR-27a targets sFRP1 in hFOB cells to regulate proliferation, apoptosis and differentiation. *PLoS One* 2014;9:91354.
36. Kapinas K, Kessler C, Ricks T, Gronowicz G, Delany AM. miR-29 modulates Wnt signaling in human osteoblasts through a positive feedback loop. *J Biol Chem* 2010;285:25221-25231.
37. Kapinas K, Kessler CB, Delany AM. miR-29 suppression of osteonectin in osteoblasts: regulation during differentiation and by canonical Wnt signaling. *J Cell Biochem* 2009;108:216-224.
38. Li Z, Hassan MQ, Jafferji M, Aqeilan RI, Garzon R, Croce CM, et al. Biological functions of miR-29b contribute to positive regulation of osteoblast differentiation. *J Biol Chem* 2009;284:15676-15684.
39. Wu T, Zhou H, Hong Y, Li J, Jiang X, Huang H. miR-30 family members negatively regulate osteoblast differentiation. *J Biol Chem* 2012;287:7503-7511.
40. Wei J, Shi Y, Zheng L, Zhou B, Inose H, Wang J, et al. miR-34s inhibit osteoblast proliferation and differentiation in the mouse by targeting SATB2. *J Cell Biol* 2012;197:509-521.
41. Yang L, Cheng P, Chen C, He HB, Xie GQ, Zhou HD, et al. miR-93/Sp7 function loop mediates osteoblast mineralization. *J Bone Miner Res* 2012;27:1598-1606.
42. Yang M, Pan Y, Zhou Y. miR-96 promotes osteogenic differentiation by suppressing HBEGF-EGFR signaling in osteoblastic cells. *FEBS Lett* 2014;588:4761-4768.
43. Zuo B, Zhu J, Li J, Wang C, Zhao X, Cai G, et al. microRNA-103a functions as a mechanosensitive microRNA to inhibit bone formation through targeting Runx2. *J Bone Miner Res* 2015;30:330-345.
44. Qadir AS, Um S, Lee H, Baek K, Seo BM, Lee G, et al. miR-124 negatively regulates osteogenic differentiation and in vivo bone formation of mesenchymal stem cells. *J Cell Biochem* 2015;116:730-742.
45. Okamoto H, Matsumi Y, Hoshikawa Y, Takubo K, Ryoke K, Shiota G. Involvement of microRNAs in regulation of osteoblastic differentiation in mouse induced pluripotent stem cells. *PLoS One* 2012;7:43800.
46. Itoh T, Nozawa Y, Akao Y. MicroRNA-141 and -200a are involved in bone morphogenetic protein-2-induced mouse pre-osteoblast differentiation by targeting distal-less homeobox 5. *J Biol Chem* 2009;284:19272-19279.
47. Li E, Zhang J, Yuan T, Ma B. MiR-143 suppresses osteogenic differentiation by targeting Osterix. *Mol Cell Biochem* 2014;390:69-74.

48. Jia J, Tian Q, Ling S, Liu Y, Yang S, Shao Z. miR-145 suppresses osteogenic differentiation by targeting Sp7. *FEBS Lett* 2013;587:3027-3031.
49. Cheung KS, Sposito N, Stumpf PS, Wilson DI, Sanchez-Elsner T, Oreffo RO. MicroRNA-146a regulates human foetal femur derived skeletal stem cell differentiation by down-regulating SMAD2 and SMAD3. *PLoS One* 2014;9:98063.
50. Wu T, Xie M, Wang X, Jiang X, Li J, Huang H. miR-155 modulates TNF- α -inhibited osteogenic differentiation by targeting SOCS1 expression. *Bone* 2012;51:498-505.
51. Gu Y, Ma L, Song L, Li X, Chen D, Bai X. miR-155 Inhibits Mouse Osteoblast Differentiation by Suppressing SMAD5 Expression. *Biomed Res Int* 2017;2017:1893520.
52. Bhushan R, Grünhagen J, Becker J, Robinson PN, Ott CE, Knaus P. miR-181a promotes osteoblastic differentiation through repression of TGF- β signaling molecules. *Int J Biochem Cell Biol* 2013;45:696-705.
53. Kang IH, Jeong BC, Hur SW, Choi H, Choi SH, Ryu JH, et al. MicroRNA-302a stimulates osteoblastic differentiation by repressing COUP-TFII expression. *J Cell Physiol* 2015;230:911-921.
54. Li J, He X, Wei W, Zhou X. MicroRNA-194 promotes osteoblast differentiation via downregulating STAT1. *Biochem Biophys Res Commun* 2015;460:482-488.
55. Laxman N, Mallmin H, Nilsson O, Kindmark A. miR-203 and miR-320 Regulate Bone Morphogenetic Protein-2-Induced Osteoblast Differentiation by Targeting Distal-Less Homeobox 5 (Dlx5). *Genes (Basel)* 2016;8:4.
56. Huang J, Zhao L, Xing L, Chen D. MicroRNA-204 regulates Runx2 protein expression and mesenchymal progenitor cell differentiation. *Stem Cells* 2010;28:357-364.
57. Wang X, Guo B, Li Q, Peng J, Yang Z, Wang A, et al. miR-214 targets ATF4 to inhibit bone formation. *Nat Med* 2013;19:93-100.
58. Shi K, Lu J, Zhao Y, Wang L, Li J, Qi B, et al. MicroRNA-214 suppresses osteogenic differentiation of C2C12 myoblast cells by targeting Osterix. *Bone* 2013;55:487-494.
59. Hassan MQ, Maeda Y, Taipaleenmaki H, Zhang W, Jafferji M, Gordon JA, et al. miR-218 directs a Wnt signaling circuit to promote differentiation of osteoblasts and osteomimicry of metastatic cancer cells. *J Biol Chem* 2012;287:42084-42092.
60. Chen J, He G, Wang Y, Cai D. MicroRNA-223 promotes osteoblast differentiation of MC3T3-E1 cells by targeting histone deacetylase 2. *Int J Mol Med* 2019;43:1513-1521.
61. Gámez B, Rodríguez-Carballo E, Bartrons R, Rosa JL, Ventura F. MicroRNA-322 (miR-322) and its target protein Tob2 modulate Osterix (Osx) mRNA stability. *J Biol Chem* 2013;288:14264-14275.
62. Sun T, Li CT, Xiong L, Ning Z, Leung F, Peng S, et al. miR-375-3p negatively regulates osteogenesis by targeting and decreasing the expression levels of LRP5 and β -catenin. *PLoS One* 2017;12:0171281.
63. Tang X, Lin J, Wang G, Lu J. MicroRNA-433-3p promotes osteoblast differentiation through targeting DKK1 expression. *PLoS One* 2017;12:0179860.
64. Li W, Chen Z, Cai C, Li G, Wang X, Shi Z. MicroRNA-505 is involved in the regulation of osteogenic differentiation of MC3T3-E1 cells partially by targeting RUNX2. *J Orthop Surg Res* 2020;15:143.
65. Kureel J, Dixit M, Tyagi AM, Mansoori MN, Srivastava K, Raghuvanshi A, et al. miR-542-3p suppresses osteoblast cell proliferation and differentiation, targets BMP-7 signaling and inhibits bone formation. *Cell Death Dis* 2014;5:1050.
66. Guo J, Ren F, Wang Y, Li S, Gao Z, Wang X, et al. miR-764-5p promotes osteoblast differentiation through inhibition of CHIP/STUB1 expression. *J Bone Miner Res* 2012;27:1607-1618.
67. Davis HM, Pacheco-Costa R, Atkinson EG, Brun LR, Gortazar AR, Harris J, et al. Disruption of the Cx43/miR21 pathway leads to osteocyte apoptosis and increased osteoclastogenesis with aging. *Aging Cell* 2017;16:551-563.
68. Davis HM, Deosthale PJ, Pacheco-Costa R, Essex AL, Atkinson EG, Aref MW, et al. Osteocytic miR21 deficiency improves bone strength independent of sex despite having sex divergent effects on

- osteocyte viability and bone turnover. *FEBS J* 2020;287:941-963.
69. Zeng HC, Bae Y, Dawson BC, Chen Y, Bertin T, Munivez E, et al. MicroRNA miR-23a cluster promotes osteocyte differentiation by regulating TGF-beta signalling in osteoblasts. *Nat Commun* 2017;8:15000.
 70. Zhang J, Chen H, Leung RKK, Choy KW, Lam TP, Ng BKW, et al. Aberrant miR-145-5p/beta-catenin signal impairs osteocyte function in adolescent idiopathic scoliosis. *FASEB J* 2018:fj201800281.
 71. Fu J, Hao L, Tian Y, Liu Y, Gu Y, Wu J. miR-199a-3p is involved in estrogen-mediated autophagy through the IGF-1/mTOR pathway in osteocyte-like MLO-Y4 cells. *J Cell Physiol* 2018;233:2292-2303.
 72. Dou C, Zhang C, Kang F, Yang X, Jiang H, Bai Y, et al. MiR-7b directly targets DC-STAMP causing suppression of NFATc1 and c-Fos signaling during osteoclast fusion and differentiation. *Biochim Biophys Acta* 2014;1839:1084-1096.
 73. Wang S, Tang C, Zhang Q, Chen W. Reduced miR-9 and miR-181a expression down-regulates Bim concentration and promote osteoclasts survival. *Int J Clin Exp Pathol* 2014;7:2209-2218.
 74. Sun KT, Chen MY, Tu MG, Wang IK, Chang SS, Li CY. MicroRNA-20a regulates autophagy related protein-ATG16L1 in hypoxia-induced osteoclast differentiation. *Bone* 2015;73:145-153.
 75. Sugatani T, Vacher J, Hruska KA. A microRNA expression signature of osteoclastogenesis. *Blood* 2011;117:3648-3657.
 76. Sugatani T, Hruska KA. Down-regulation of miR-21 biogenesis by estrogen action contributes to osteoclastic apoptosis. *J Cell Biochem* 2013;114:1217-1222.
 77. Kim K, Kim JH, Kim I, Lee J, Seong S, Park YW, et al. MicroRNA-26a regulates RANKL-induced osteoclast formation. *Mol Cells* 2015;38:75-80.
 78. Guo L, Chen K, Yuan J, Huang P, Xu X, Li C, et al. Estrogen inhibits osteoclasts formation and bone resorption via microRNA-27a targeting PPAR γ and APC. *J Cell Physiol* 2018;234:581-594.
 79. Franceschetti T, Kessler CB, Lee SK, Delany AM. miR-29 promotes murine osteoclastogenesis by regulating osteoclast commitment and migration. *J Biol Chem* 2013;288:33347-33360.
 80. Wu RW, Lian WS, Chen YS, Kuo CW, Ke HC, Hsieh CK, et al. MicroRNA-29a Counteracts Glucocorticoid Induction of Bone Loss through Repressing TNFSF13b Modulation of Osteoclastogenesis. *Int J Mol Sci* 2019;20.
 81. Rossi M, Pitari MR, Amodio N, Di Martino MT, Conforti F, Leone E, et al. miR-29b negatively regulates human osteoclastic cell differentiation and function: implications for the treatment of multiple myeloma-related bone disease. *J Cell Physiol* 2013;228:1506-1515.
 82. Yin Y, Tang L, Chen J, Lu X. MiR-30a attenuates osteoclastogenesis via targeting DC-STAMP-c-Fos-NFATc1 signaling. *Am J Transl Res* 2017;9:5743-5753.
 83. Mizoguchi F, Murakami Y, Saito T, Miyasaka N, Kohsaka H. miR-31 controls osteoclast formation and bone resorption by targeting RhoA. *Arthritis Res Ther* 2013;15:R102.
 84. Krzeszinski JY, Wei W, Huynh H, Jin Z, Wang X, Chang TC, et al. miR-34a blocks osteoporosis and bone metastasis by inhibiting osteoclastogenesis and Tgif2. *Nature* 2014;512:431-435.
 85. Cong F, Wu N, Tian X, Fan J, Liu J, Song T, et al. MicroRNA-34c promotes osteoclast differentiation through targeting LGR4. *Gene* 2017;610:1-8.
 86. Zhou L, Song HY, Gao LL, Yang LY, Mu S, Fu Q. MicroRNA-100-5p inhibits osteoclastogenesis and bone resorption by regulating fibroblast growth factor 21. *Int J Mol Med* 2019;43:727-738.
 87. Li J, Li Y, Wang S, Che H, Wu J, Ren Y. miR-101-3p/Rap1b signal pathway plays a key role in osteoclast differentiation after treatment with bisphosphonates. *BMB Rep* 2019;52:572-576.
 88. Wang T, Yin H, Wang J, Li Z, Wei H, Liu Za, et al. MicroRNA-106b inhibits osteoclastogenesis and osteolysis by targeting RANKL in giant cell tumor of bone. *Oncotarget* 2015;6:18980-18996.
 89. Lee Y, Kim HJ, Park CK, Kim YG, Lee HJ, Kim JY, et al. MicroRNA-124 regulates osteoclast differentiation. *Bone* 2013;56:383-389.

90. Tang L, Yin Y, Liu J, Li Z, Lu X. MiR-124 Attenuates Osteoclastogenic Differentiation of Bone Marrow Monocytes Via Targeting Rab27a. *Cell Physiol Biochem* 2017;43:1663-1672.
91. Guo LJ, Liao L, Yang L, Li Y, Jiang TJ. MiR-125a TNF receptor-associated factor 6 to inhibit osteoclastogenesis. *Exp Cell Res* 2014;321:142-152.
92. Sun L, Lian JX, Meng S. MiR-125a-5p promotes osteoclastogenesis by targeting TNFRSF1B. *Cell Mol Biol Lett* 2019;24:23.
93. Wu Z, Yin H, Liu T, Yan W, Li Z, Chen J, et al. MiR-126-5p regulates osteoclast differentiation and bone resorption in giant cell tumor through inhibition of MMP-13. *Biochem Biophys Res Commun* 2014;443:944-949.
94. Lou Z, Peng Z, Wang B, Li X, Li X, Zhang X. miR-142-5p promotes the osteoclast differentiation of bone marrow-derived macrophages via PTEN/PI3K/AKT/FoxO1 pathway. *J Bone Miner Metab* 2019;37:815-824.
95. Chen Y, Wang X, Yang M, Ruan W, Wei W, Gu D, et al. miR-145-5p Increases Osteoclast Numbers In Vitro and Aggravates Bone Erosion in Collagen-Induced Arthritis by Targeting Osteoprotegerin. *Med Sci Monit* 2018;24:5292-5300.
96. Yu FY, Xie CQ, Sun JT, Peng W, Huang XW. Overexpressed miR-145 inhibits osteoclastogenesis in RANKL-induced bone marrow-derived macrophages and ovariectomized mice by regulation of Smad3. *Life Sci* 2018;202:11-20.
97. Cheng P, Chen C, He HB, Hu R, Zhou HD, Xie H, et al. miR-148a regulates osteoclastogenesis by targeting V-maf musculoaponeurotic fibrosarcoma oncogene homolog B. *J Bone Miner Res* 2013;28:1180-1190.
98. Zhao H, Zhang J, Shao H, Liu J, Jin M, Chen J, et al. Transforming Growth Factor β 1/Smad4 Signaling Affects Osteoclast Differentiation via Regulation of miR-155 Expression. *Mol Cells* 2017;40:211-221.
99. Han Z, Zhan R, Chen S, Deng J, Shi J, Wang W. miR-181b/Oncostatin m axis inhibits prostate cancer bone metastasis via modulating osteoclast differentiation. *J Cell Biochem* 2020;121:1664-1674.
100. Ke K, Sul OJ, Rajasekaran M, Choi HS. MicroRNA-183 increases osteoclastogenesis by repressing heme oxygenase-1. *Bone* 2015;81:237-246.
101. Guo K, Zhang D, Wu H, Zhu Q, Yang C, Zhu J. MiRNA-199a-5p positively regulated RANKL-induced osteoclast differentiation by target Mafk protein. *J Cell Biochem* 2018;10.
102. Liu J, Li D, Dang L, Liang C, Guo B, Lu C, et al. Osteoclastic miR-214 targets TRAF3 to contribute to osteolytic bone metastasis of breast cancer. *Sci Rep* 2017;7:40487.
103. Zhao C, Sun W, Zhang P, Ling S, Li Y, Zhao D, et al. miR-214 promotes osteoclastogenesis by targeting Pten/PI3k/Akt pathway. *RNA Biol* 2015;12:343-353.
104. Yao Y, Jia T, Pan Y, Gou H, Li Y, Sun Y, et al. Using a novel microRNA delivery system to inhibit osteoclastogenesis. *Int J Mol Sci* 2015;16:8337-8350.
105. Guo J, Zeng X, Miao J, Liu C, Wei F, Liu D, et al. MiRNA-218 regulates osteoclast differentiation and inflammation response in periodontitis rats through Mmp9. *Cell Microbiol* 2019;21:12979.
106. Sugatani T, Hruska KA. Impaired micro-RNA pathways diminish osteoclast differentiation and function. *J Biol Chem* 2009;284:4667-4678.
107. Niu D, Gong Z, Sun X, Yuan J, Zheng T, Wang X, et al. miR-338-3p regulates osteoclastogenesis via targeting IKK β gene. *In Vitro Cell Dev Biol Anim* 2019;55:243-251.
108. Zhang XH, Geng GL, Su B, Liang CP, Wang F, Bao JC. MicroRNA-338-3p inhibits glucocorticoid-induced osteoclast formation through RANKL targeting. *Genet Mol Res* 2016;15.
109. Zhao H, Zhang J, Shao H, Liu J, Jin M, Chen J, et al. miRNA-340 inhibits osteoclast differentiation via repression of MITF. *Biosci Rep* 2017;37.
110. Li K, Chen S, Cai P, Chen K, Li L, Yang X, et al. MiRNA-483-5p is involved in the pathogenesis of osteoporosis by promoting osteoclast differentiation. *Mol Cell Probes* 2020;49:101479.

111. Chen C, Cheng P, Xie H, Zhou HD, Wu XP, Liao EY, et al. MiR-503 regulates osteoclastogenesis via targeting RANK. *J Bone Miner Res* 2014;29:338-347.
112. Dinesh P, Kalaiselvan S, Sujitha S, Rasool M. miR-506-3p alleviates uncontrolled osteoclastogenesis via repression of RANKL/NFATc1 signaling pathway. *J Cell Physiol* 2020;10.
113. Liu T, Qin AP, Liao B, Shao HG, Guo LJ, Xie GQ, et al. A novel microRNA regulates osteoclast differentiation via targeting protein inhibitor of activated STAT3 (PIAS3). *Bone* 2014;67:156-165.
114. Mitchell PS, Parkin RK, Kroh EM, Fritz BR, Wyman SK, Pogosova-Agadjanyan EL, et al. Circulating microRNAs as stable blood-based markers for cancer detection. *Proc Natl Acad Sci U S A* 2008;105:10513-10518.
115. Chen X. MicroRNA metabolism in plants. *Curr Top Microbiol Immunol* 2008;320:117-136.
116. Creemers EE, Tijssen AJ, Pinto YM. Circulating microRNAs: novel biomarkers and extracellular communicators in cardiovascular disease? *Circ Res* 2012;110:483-495.
117. Vickers KC, Palmisano BT, Shoucri BM, Shamburek RD, Remaley AT. MicroRNAs are transported in plasma and delivered to recipient cells by high-density lipoproteins. *Nat Cell Biol* 2011;13:423-433.
118. Weber JA, Baxter DH, Zhang S, Huang DY, Huang KH, Lee MJ, et al. The microRNA spectrum in 12 body fluids. *Clin Chem* 2010;56:1733-1741.
119. da Silveira JC, Veeramachaneni DN, Winger QA, Carnevale EM, Bouma GJ. Cell-secreted vesicles in equine ovarian follicular fluid contain miRNAs and proteins: a possible new form of cell communication within the ovarian follicle. *Biol Reprod* 2012;86:71.
120. Park NJ, Zhou H, Elashoff D, Henson BS, Kastratovic DA, Abemayor E, et al. Salivary microRNA: discovery, characterization, and clinical utility for oral cancer detection. *Clin Cancer Res* 2009;15:5473-5477.
121. Saito A, Horie M, Ejiri K, Aoki A, Katagiri S, Maekawa S, et al. MicroRNA profiling in gingival crevicular fluid of periodontitis-a pilot study. *FEBS Open Bio* 2017;7:981-994.
122. Atsawasuan P, Lazari P, Chen Y, Zhou X, Viana G, Evans CA. Secretory microRNA-29 expression in gingival crevicular fluid during orthodontic tooth movement. *PLoS One* 2018;13:0194238.
123. Waerhaug J, Steen E. The presence or absence of bacteria in gingival pockets and the reaction in healthy pockets to certain pure cultures; a bacteriological and histological investigation. *Odontol Tidskr* 1952;60:1-24.
124. Khurshid Z, Mali M, Naseem M, Najeeb S, Zafar MS. Human Gingival Crevicular Fluids (GCF) Proteomics: An Overview. *Dent J (Basel)* 2017;5:12.
125. Griffiths GS. Formation, collection and significance of gingival crevice fluid. *Periodontol* 2000 2003;31:32-42.
126. Champagne CM, Buchanan W, Reddy MS, Preisser JS, Beck JD, Offenbacher S. Potential for gingival crevice fluid measures as predictors of risk for periodontal diseases. *Periodontol* 2000 2003;31:167-180.
127. Ibrahim M, Mohan S, Xing MJ, Kesavan C. Conditional Knockout of the MicroRNA 17-92 Cluster in Type-I Collagen-Expressing Cells Decreases Alveolar Bone Size and Incisor Tooth Mechanical Properties. *Folia Biol (Praha)* 2016;62:175-179.
128. Irwandi RA, Vacharaksa A. The role of microRNA in periodontal tissue: A review of the literature. *Arch Oral Biol* 2016;72:66-74.
129. Luan X, Zhou X, Trombetta-eSilva J, Francis M, Gaharwar AK, Atsawasuan P, et al. MicroRNAs and Periodontal Homeostasis. *J Dent Res* 2017;96:491-500.
130. Wu Y, Ou Y, Liao C, Liang S, Wang Y. High-throughput sequencing analysis of the expression profile of microRNAs and target genes in mechanical force-induced osteoblastic/cementoblastic differentiation of human periodontal ligament cells. *Am J Transl Res* 2019;11:3398-3411.
131. Yuan Y, Guo J, Zhang L, Tong X, Zhang S, Zhou X, et al. MiR-214 Attenuates the Osteogenic Effects of Mechanical Loading on Osteoblasts. *Int J Sports Med* 2019;40:931-940.

132. Zeng Q, Wang Y, Gao J, Yan Z, Li Z, Zou X, et al. miR-29b-3p regulated osteoblast differentiation via regulating IGF-1 secretion of mechanically stimulated osteocytes. *Cell Mol Biol Lett* 2019;24:11.
133. Wang Y, Jia L, Zheng Y, Li W. Bone remodeling induced by mechanical forces is regulated by miRNAs. *Biosci Rep* 2018;38:BSR20180448.
134. Kanzaki H, Wada S, Yamaguchi Y, Katsumata Y, Itohiya K, Fukaya S, et al. Compression and tension variably alter Osteoprotegerin expression via miR-3198 in periodontal ligament cells. *BMC Mol Cell Biol* 2019;20:6.
135. Chang M, Lin H, Luo M, Wang J, Han G. Integrated miRNA and mRNA expression profiling of tension force-induced bone formation in periodontal ligament cells. *In Vitro Cell Dev Biol Anim* 2015;51:797-807.
136. Zhang Y, Tian Y, Yang X, Zhao Z, Feng C, Zhang Y. MicroRNA21 serves an important role during PAOOfacilitated orthodontic tooth movement. *Mol Med Rep* 2020;22:474-482.
137. Wu L, Su Y, Lin F, Zhu S, Wang J, Hou Y, et al. MicroRNA-21 promotes orthodontic tooth movement by modulating the RANKL/OPG balance in T cells. *Oral Dis* 2020;26:370-380.
138. Yu W, Zheng Y, Yang Z, Fei H, Wang Y, Hou X, et al. N-AC-l-Leu-PEI-mediated miR-34a delivery improves osteogenic differentiation under orthodontic force. *Oncotarget* 2017;8:110460-110473.
139. Kapinas K, Delany AM. MicroRNA biogenesis and regulation of bone remodeling. *Arthritis Res Ther* 2011;13:220.
140. Dong Y, Lu A, Patel P, Quan Y, Al-Qaysi A, Zhou X, et al. Delayed tooth movement in miRNA-29 sponge transgenic mice. *J Dental Res* 2018;97:429.
141. Radovic N, Nikolic Jakoba N, Petrovic N, Milosavljevic A, Brkovic B, Roganovic J. MicroRNA-146a and microRNA-155 as novel crevicular fluid biomarkers for periodontitis in non-diabetic and type 2 diabetic patients. *J Clin Periodontol* 2018;45:663-671.
142. Mico-Martinez P, Garcia-Gimenez JL, Seco-Cervera M, Lopez-Roldan A, Alminana-Pastor PJ, Alpiste-Illueca F, et al. miR-1226 detection in GCF as potential biomarker of chronic periodontitis: A pilot study. *Med Oral Patol Oral Cir Bucal* 2018;23:308-314.
143. Luan X, Zhou X, Naqvi A, Francis M, Foyle D, Nares S, et al. MicroRNAs and immunity in periodontal health and disease. *Int J Oral Sci* 2018;10:24.

THE BIOLOGY AND MODIFICATION OF PERIODONTAL AND DENTOALVEOLAR BONE PHENOTYPE IN ORTHODONTIC PATIENTS

Riccardo Di Gianfilippo, George A. Mandelaris, Chin-Wei Wang

ABSTRACT

The alveolar bone is a highly dynamic mineralized tissue constantly remodeling with the periodontium to support the dentition throughout a lifetime. The tissue quality and phenotype of both periodontium and dentoalveolar bone are crucial to withstand the orthodontic treatment and support long-term health and stability of the tooth-supporting tissue. The development, eruption, position, and orientation of the tooth can influence the anatomy of the alveolar bone, and thus orthodontic tooth movement can also have a significant impact on the surrounding tissue. A thin phenotype of the alveolar bone often predisposes and results in dehiscence or fenestrations defect; together with a thin periodontal soft tissue, any tooth movement would compromise the support of the dentition and also causes gingival recession overtime. Technology advancement, including the use of cone beam computerized tomography, ultrasonography, and digital scanners, offers new tool to diagnose periodontal and dentoalveolar phenotype to stratify risk for each individual patient and examine orthodontic boundaries for tooth movement. Periodontal phenotype augmentation is indicated in patients with higher risk not only to avoid future periodontal complications but also to strengthen tissue and treatment stability. The emerging challenge with adult orthodontics and complex treatment plan relies on a synergized interdisciplinary collaborative patient care to ensure success and to achieve a new high standard together.

KEY WORDS: Phenotype, Periodontium, Dentoalveolar Bone, Gingival Recession; Bone Remodeling, Bone Grafting; Cone-Beam Computed Tomography.

INTRODUCTION

a. ANATOMY AND PHYSIOLOGY OF DENTOALVEOLAR BONE

i. Introduction

The alveolar bone is a specialized mineralized connective tissue that gives physical support to the teeth, other than contributing to the multiple systemic functions of the skeleton, such as regulation of calcium metabolism or physiognomy [1]. The alveolar bone is also one of the four tissues that constitute the periodontium, together with the gingiva, periodontal ligament and cementum. Periodontal tissues are

a complex functional unit that dissipate forces from occlusion and contribute to long-term preservation of natural dentition [1-3].

From an embryological standpoint, both mandible and maxilla originate from the first branchial arch [4]. The mandible precedes the maxilla, with ossification starting at 6th week of development from a center located at the bifurcation between the inferior alveolar nerve and the incisor nerve [5]. Development of the maxilla starts at 7 weeks. Similar to the mandible, the maxillary center of ossification appears in the angle between the divisions of a nerve, the anterosuperior dental nerve and the infraorbital nerve [5]. Once the bone outline is completed, bone growth of the cranial base induces a movement of the maxillary bones inferiorly and anteriorly, responsible for the characteristic physiognomy of human face [6].

Volume and shape of human jaws have changed considerably with evolution of the species. Compared to apes, human skull had a significant decrease in volume of the viscerocranium, especially for the maxillary and mandibular jaws. Simultaneously, the neurocranium, located in the superior-posterior area of the head and dedicated to the protection of the brain, has progressively increased in volume. Genetic polymorphisms of proteins of masticatory muscles drove this anthropological transformation. A frameshifting mutation for the myosin heavy chain (MYH) was found inactivated in humans compared to large primates [7]. It is believed that lack of genetic trophism for masticatory muscles had secondary effects on the anatomy of bone segments [8, 9]. Reduced contractile force for temporalis muscle manifested as reduced stress on the jaw bones and on the cranial sutures with the opportunity to expand the neurocranium and reduce the overall volume of the face bones [10, 11].

Other than genetic components, environmental factors like diet change could have played a role in anthropological evolution. Diet change has been proposed to influence craniofacial dimensions in two different ways. First, higher body weight has been associated with muscle hypertrophy which in turn would increase the trophic stimuli on muscle insertions [12]. Second, hard diet required higher chewing force to bite and promoted vertical growth of the ramus and anterior translocation of the maxilla [13]. Despite the reported somatic change that diet can induce on muscle biting force and skeletal growth, heritability of a genetic variance remains to be determined. In other words, the genetic or epigenetic effects of diet that would be responsible for human species evolution remains to be determined.

A further macroscopic dimensional modification of jaws anatomy is seen in case of edentulism [14]. For the edentulous mandible, the antero-posterior dimension of the ramus decreases due to anterior and posterior resorptive processes, inducing a secondary increase of the length of the mandible's body. The arch length is preserved, and the overall mandible length is increased due to the opening of the corpus-ramus angle. The edentulous maxilla is dominated by resorptive processes inducing an overall reduction in arch length, as well as antero-posterior and latero-lateral atrophy [15]. Anterior sextant of the maxilla seems to be affected the most by resorptive processes, inducing a significant flattening of the face profile. The overall jawbone tends to resorb overtime, especially at sites with muscle insertion and attachment. The dentoalveolar bone, especially mandibular anterior sextant is considered part of the "resorptive fields", that this bone atrophy will gradually become more evident in adult orthodontic patients.

ii. Macroscopic anatomy of alveolar bone

The alveolar bone is the process of the jaws that bridges between the basal bone and teeth. It is composed by cancellous trabeculae between two layers of compact bone. The anatomy of the alveolar

bone usually follows the volume, position and angulation of the dental roots. Bone thickness is higher on the palatal/lingual side as compared to the facial side, and it is largely conditioned by the position of the tooth root [1, 16]. Many factors may change the root position affecting the thickness of facial and palatal bone plates, and the most common are orthodontic therapy, crowding, ectopic eruption, and all environmental forces directed on the dental arches. Facial root positioning may cause defects of the facial bone resulting in lingual bone volume that is thicker than that of the facial. On the other hand, more palatal positioning of the root leads to a thicker facial plate (Figure 1). A clinical implication of a thick highly mineralized palatal bone relies in a challenging orthodontic tooth movement.

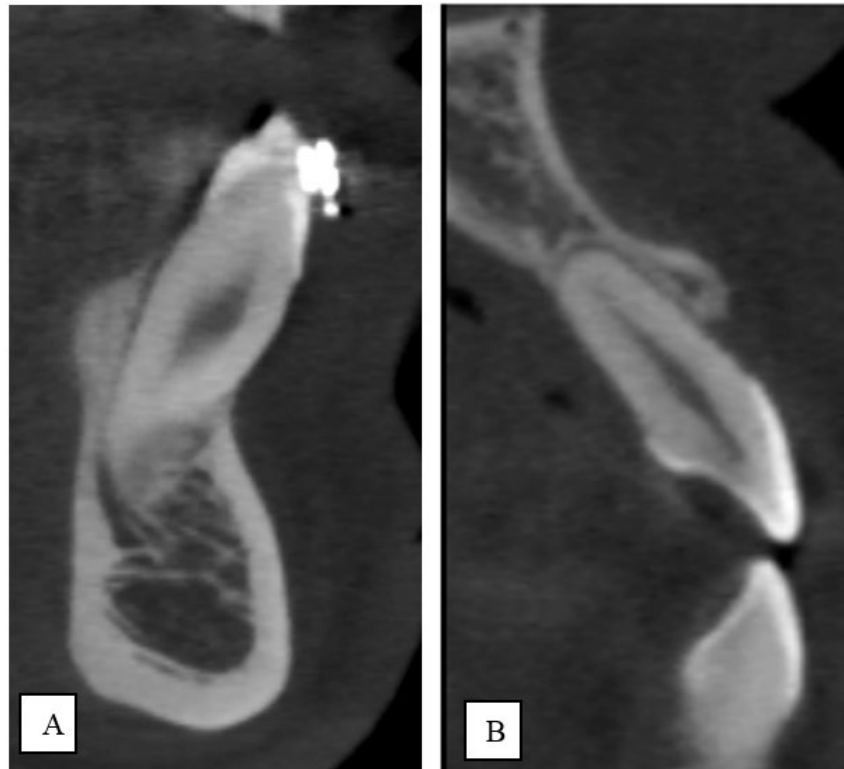


Figure 1. Cross sectional evaluation of the alveolar bone from cone beam computed tomography (CBCT). Note how tooth positioning influences the thickness of the facial or palatal bone. (A) A facially inclined lower right canine (#27) with limited facial bone and thick lingual bone. (B) An upper right central incisor (#8) presented with palatal positioning of the slightly resorbed root resulted in thick facial bone and thin palatal bone.

It is not rare that root prominence, angulation or position makes the overlying bone so thin that it directly exposes a portion of the root surface to the attachment of the soft tissue. These localized discontinuities are named **dehiscences** if are connected to the coronal bone margin, and **fenestrations** if they are more apical and not connected with the coronal bone margin (Figure 2). The prevalence of dehiscences and fenestrations has been estimated to be around 5% and 10%, respectively [16-19]. Interestingly, the prevalence increased to 51% for dehiscences and 36% for fenestrations in patients with Class I and II malocclusion [20]. Malpositioning, labial protrusion of the root, prominent root convexities, in combination with a thin bony plate, are predisposing factors for dehiscences or fenestrations [21].

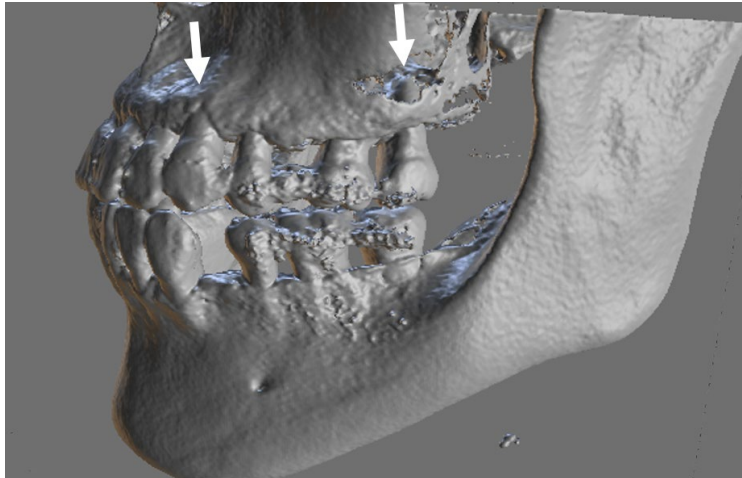


Figure 2. Three-dimensional reconstruction of a young female patient's dentition and jawbone after orthodontic treatment with CBCT showing dehiscences of the crestal bone of the upper left canine (#11) and fenestration of the radicular bone with exposure of the root surface of the upper left second molar (#15). The dehiscence and the fenestration are indicated with white arrows.

Even in patients with severe crowding, bony dehiscence may already exist in limited native alveolar bone (Figure 3). These anatomical conditions are not considered pathologic in nature but may pose higher risk for negative consequences, especially after orthodontic treatment. The effect of orthodontic tooth movement on bone thickness has been investigated in animal and human studies. Karring et al. (1982) noted creation of dehiscence of about 2mm when maxillary incisors of three dogs were experimentally tipped in facial direction [22]. Human observations also support the direct relationship between facial movement and thinning of buccal bone. In a study on eight girls with intact baseline bone thickness, rapid palatal expansion was followed by decrease of bone thickness of almost 1 mm [23]. While facial dehiscences have obvious implications in the context of a patient seeking esthetic treatment of recession, palatal dehiscences have minor clinical relevance and often remain undiagnosed.

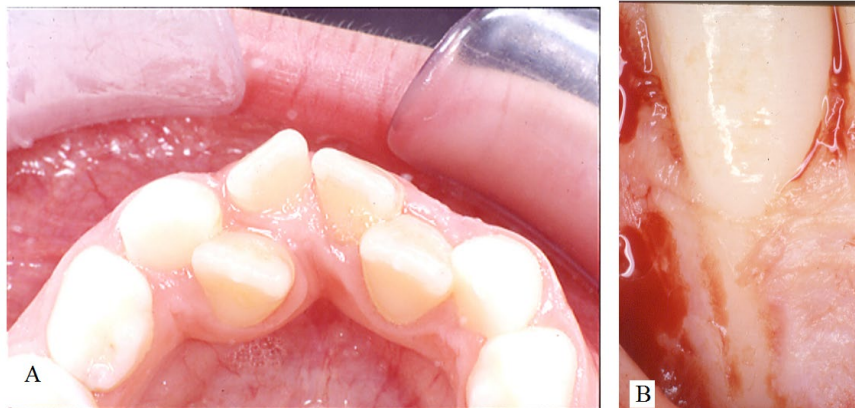

Figure 3. A patient with severe crowding of mandibular anterior teeth with alveolar bone deficiency. (A) Mandibular incisors are positioned facially and lingually due to limited arch space. (B) The teeth with more facial position perforate the buccal bone plate and show dehiscence of the bone crest. *Courtesy of Professor Pini Prato.*

iii. Classification of dentoalveolar phenotypes

The dentoalveolar apparatus can be divided into two zones, consecutive in the apico-coronal direction. At CBCT analysis, the crestal zone represents the region located between the cemento-enamel junction (CEJ) up to 4mm apical to it, as opposed to the radicular zone located from the base of the crestal zone until the apical extent of the root. Both crestal and radicular zones are classified as thick if the buccal bone plate is equal or thicker than 1mm, or as thin if the buccal bone is less than 1mm thick [24]. As result, the bone phenotype of each patient could fall into one of four categories: (i) thick crestal zone and thick radicular zone, (ii) thick crestal zone and thin radicular zone, (iii) thin crestal zone and thick radicular zone, or (iv) thin crestal zone and thin radicular zone (Table 1, Figure 4).

Table 1: Classification of dentoalveolar phenotypes

	Thick phenotype	Thin phenotype
Crestal zone	Thickness of crestal bone \geq 1mm	Thickness of crestal bone $<$ 1mm
Radicular zone	Thickness of radicular bone \geq 1mm	Thickness of radicular bone $<$ 1mm
Crestal zone: from the CEJ to 4mm apical		
Radicular zone: from the base of the crestal zone to the apex		

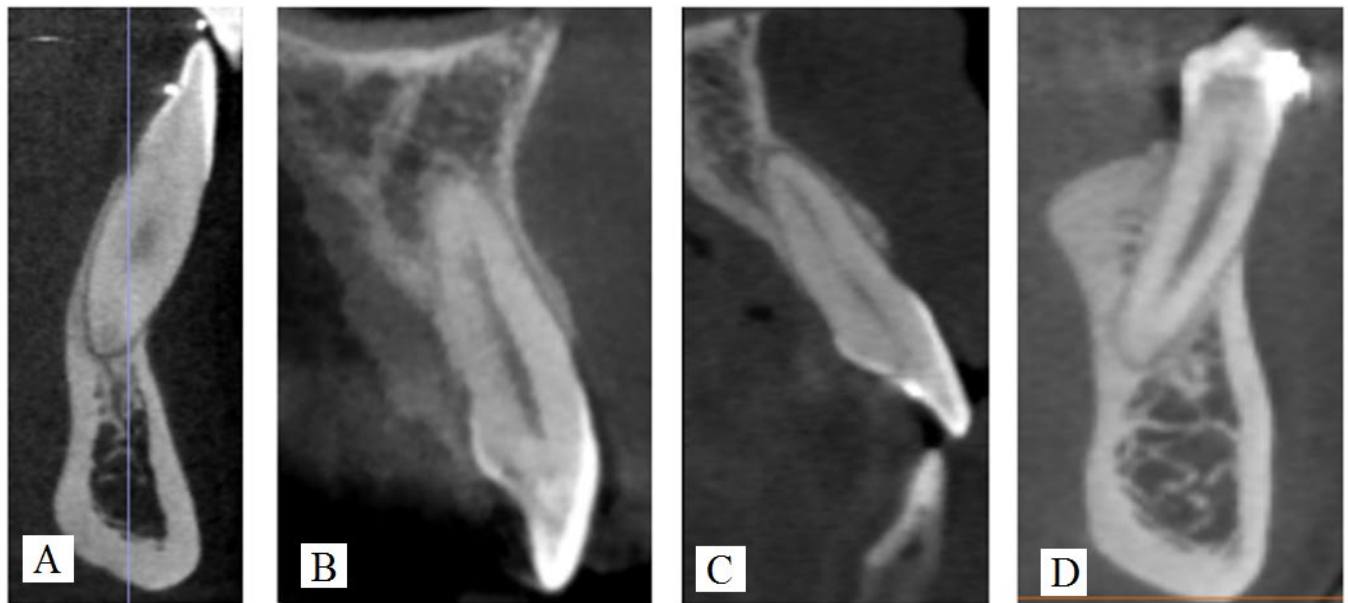


Figure 4. Examples of different alveolar bone phenotype, which is primarily determined by the thickness of the crestal and radicular facial bone. (A) thin-crestal thin-radicular phenotype. (B) thick-crestal thick-radicular phenotype. C: thick-crestal thin-radicular phenotype. D: thin-crestal thick-radicular phenotype.

The proposed classification has strong clinical implications in terms of diagnostics and treatment planning. Thickness of dentoalveolar bone was shown to be associated with gingival phenotype, and gingival recessions are often reported in patients with bone deformities [25]. In a previous classification by Richman et al. (2011), dentoalveolar bone was classified as “ideal” if thicker than 1.5mm, “compromised” if the thickness was between 0.5 and 1.5mm, and “high-risk” if thinner than 0.5mm, without distinction between crestal or radicular zones. New classifications, as proposed by Mandelaris et al. (2013), stresses the importance of implementing an apico-coronal variable to differentiate the crestal zone from the radicular zone. Indeed, patients with thin crestal zone and thick radicular zone are at higher risk of bone dehiscence and gingival recessions. On the other hand, patients with thick crestal zone and thin radicular zone are less susceptible to recession but a higher risk of apical fenestrations. Oftentimes after orthodontic treatment, those bone defects and deficiency were hidden under the periodontal tissue and can only be revealed with CBCT imaging (Figure 5). While gingival recessions may be treated due to esthetic concerns, apical fenestrations without gingival recessions can remain undiagnosed until tooth extraction or after the occurrence of periodontal disease. Extraction of a tooth with apical fenestration may lead to severe resorption of the ridge requiring advanced bone augmentation for implant placement. In addition, periodontal disease progression of a tooth with apical fenestration may induce unexpected hypermobility due to lack of apical support.

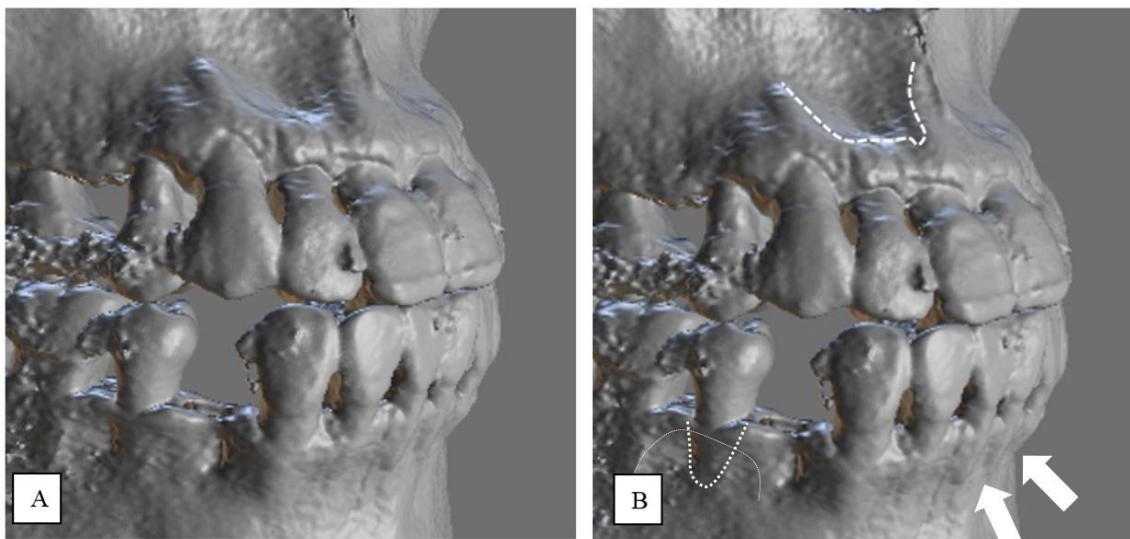


Figure 5. A CBCT 3D reconstruction of an alveolar bone in a young female patient after orthodontic treatment. (A) Thick-crestal thin-radicular phenotype was noted for the upper right lateral incisor (#7) and mandibular alveolar bone is characterized by thin-crestal phenotype. mandibular right second premolar (#29) also presented with root prominence. (B) Note both the significant bone concavity at the apical third of the root that was highlighted with a dotted line. Mandibular incisors (#25, 26) presented with root prominence with complete facial dehiscence, as pointed with two white arrows.

The classification system based on the crestal and radicular dentoalveolar bone phenotypes finds therapeutic implications related to surgically-facilitated orthodontic therapy and phenotype conversion therapy [24]. Indeed, orthodontic expansion of areas with thick-crestal thin-radicular zone should receive apical bone grafting to avoid significant protrusion of the root outside of the bone housing, while

expansion of thin-crestal thick-radicular bone should receive crestal grafting to prevent incidence of dehiscence and recessions.

The proposed classification finds important implications also for patient-clinician communication. The patient can be educated and informed on their unfavorable anatomy and the need of phenotype augmentation procedures, as well as on the intrinsic risks associated with orthodontic tooth movement.

iv. Imaging for phenotype diagnosis

Non-invasive diagnostics for better investigation of local anatomy is one of the pillars of dental fields. The first paragraph of this chapter reported on bone anatomy and on the role of adequate bone thickness as opposed to fenestration or dehiscence. The second paragraph provided a classification that would guide the clinician over a better diagnosis and decision-making process. The role of the following paragraph is to report on radiographic diagnostics useful to detect dehiscences and fenestration. As previously mentioned, knowledge of bone anatomy is of paramount importance and neglected understanding of the dentoalveolar bone thickness before orthodontic treatment may put the patient at risk for recession-based attachment loss and other iatrogenic consequences.

Elevating a mucoperiosteal flap for diagnostic purposes is unacceptable for ethical reasons. Today, technological advances offer a wide panel of imaging techniques that allow an in-depth investigation of quality and volume of oral soft and hard tissues. Cone beam computer tomography (CBCT) is a low-dose volumetric radiographic technique evolved by the traditional computer tomography. Its role goes far beyond the detection of bone deformities. It is routinely used in dental fields for 3-D investigation of anatomical structures and their relation to implant placement, investigation of maxillary sinuses and their relation with site development procedures, skeletal deformities and their treatment, digital planning of implant-supported rehabilitations, evaluation of root morphology and associated pathology, investigation of anatomical variation in addition to other secondary roles like patient motivation and legal documentation [26-31].

The Best Evidence Consensus from the American Academy of Periodontology (AAP) focused on the possible advantages that the CBCT brings to dental implantology, orthodontics and periodontology [31]. Existing literature does not support the routine use of CBCT as alternative to intraoral radiographs for diagnosis of periodontitis; however, it is recognized that CBCT could bring significant advantages for multidisciplinary cases providing additional details regarding bone levels of teeth with unfavorable to hopeless prognosis. The digital platform and simulated planning can also be a great tool for interdisciplinary communication, treatment planning and precision execution of the plan for the patients.

CBCT resulted to be appropriate for implant planning, allowing minimal invasiveness of implant surgeries. For example, CBCT and software for image elaboration allow simulated placement of implants in the alveolar bone. In a cross-sectional study involving more than one hundred implants placed in the posterior mandible, undercuts of the lingual bone plate were present in 66% of patients. Existing lingual undercut led to a rate of “virtual” perforation of 1% when 12mm length implants were used. The study clearly showed the key role of a pre-operative CBCT for knowledge of local anatomy and for safe planning [32].

Regarding multidisciplinary periodontal-orthodontic treatments, as reported by the AAP Best Evidence Consensus [31] and Best Evidence Review [33], the use of the CBCT is indicated in the following situations:

1. When the patient has a thin dentoalveolar phenotype, and dentoalveolar bone deficiencies are suspected,
2. When the orthodontic patient presents with concomitant mucogingival deformities (recession),
3. When the malocclusion requires advanced tooth movement and there is increased risk for positioning the roots outside of the bone boundary conditions,
4. When the patient presents with other specific considerations requiring more global analysis (e.g., impacted third molars, temporomandibular joint disorders, dentofacial disharmonies requiring orthodontic-periodontal-orthognathic approaches for management, congenitally missing teeth, or requirement for skeletal anchorage).

There is no doubt that a conventional radiograph is not enough to examine and diagnose the underlying alveolar bone phenotype; and there are a few limitations of CBCT linked with the existing dose of radiation and the scarce diagnostic power for soft tissues. Latest technological advances like ultrasonography, can help with radiation-free screening of soft tissue thickness and underlining bone architecture (Figure 6). Ultrasonography uses ultrasound waves in the range of 1 to 20MHz and converts the ultrasound echoes returning from the tissues into images. Ultrasound waves showed excellent reliability to detect tissue thickness with an accuracy higher than conventional CBCTs or transgingival probing [34-36]. Its power to detect bone thickness or tooth structures is currently under investigation, showing promising results for high resolution imaging of the soft-hard tissue interfaces [34, 35, 37-39].

i. Microscopic anatomy and bone cell-molecular physiology

Bone is a specialized type of connective tissue characterized by mineralized extracellular matrix. At anatomical cross-sectional examination, trabecular bone can be detected in between external layers of compact (or lamellar) bone. Trabecular bone appears as a tridimensional intricate ramification of bone spicules, while compact bone appears as a single compact mass. At higher magnification, the compact bone appears organized in multiple layers of parallel structures of 3 to 7 μ m named *lamellae*. Each lamella is composed by cells, intercellular matrix and canals. Resident bone cells (osteocytes) relies in voids name *lacunae* and communicate each other through cellular projections as described later in the paragraph. The organic component of the extracellular matrix is predominantly composed of Type I collagen, followed by glycoproteins like fibronectin, thrombospondin, osteopontin or other non-collagenous protein. Composition and weight of the inorganic component of the extracellular matrix fluctuate during bone development and during aging; overall minerals are predominantly present as hydroxyapatite $\text{Ca}_{10}(\text{PO}_4)_6(\text{OH})_2$ organized in lines following the direction of the collagen fibrils. Despite the mineralization of the extracellular matrix, bone remodels continuously allowing adaptation to different stimuli. Orthodontic tooth movement is allowed by the remodeling of existing bone structure; it is an extremely active process guided by the activity of osteoclasts, osteoblasts, osteocytes and their finely regulated signaling molecules (Table 2). Those signals hold promising future development in refining our control over orthodontic tooth movement through harnessing the rate of bone remodeling as another perspective for biomechanics. Therefore, understanding the role of key cellular players is also critical before we can further decipher those signals for clinical translation in the next century.

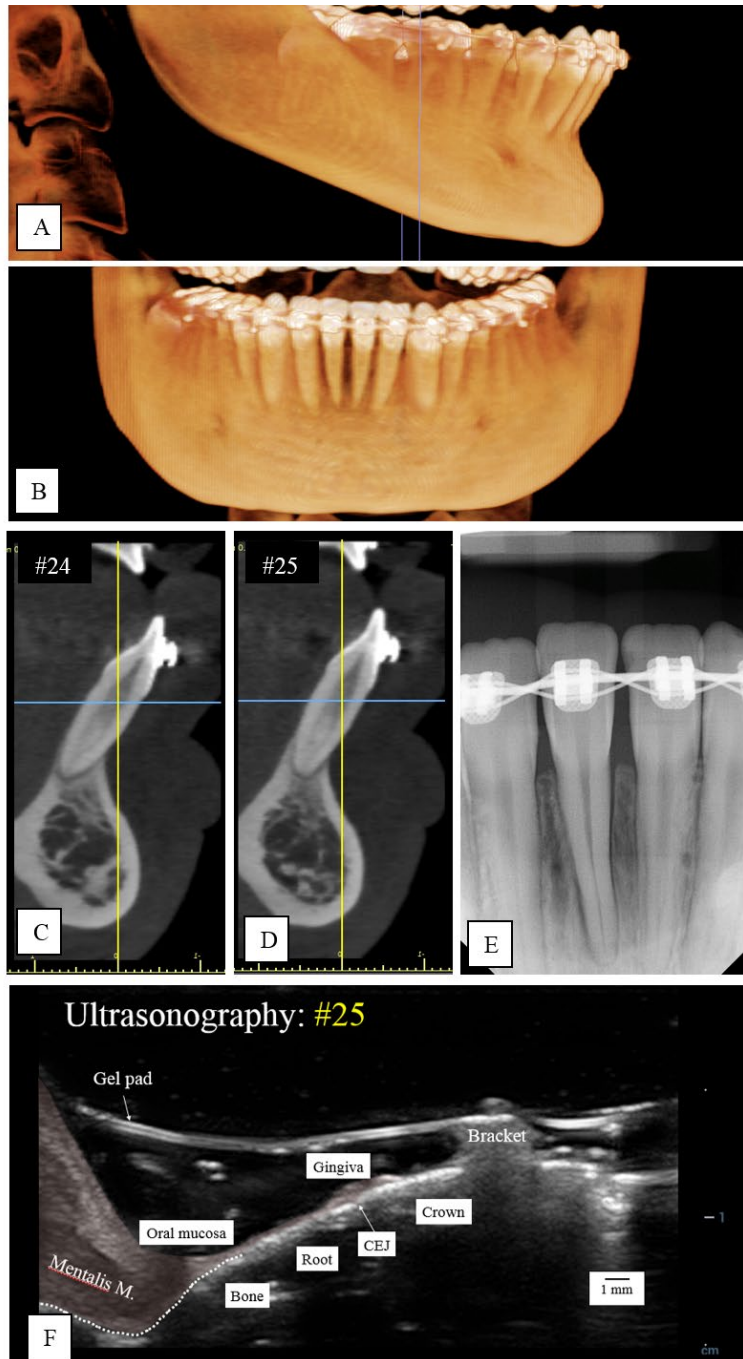


Figure 6. Comparison of different imaging technology on a patient with thin alveolar bone phenotype undergoing orthodontic treatment. (A) Three-dimensional lateral view; lower incisors presented with proclination and facial convexity outside of the bone contour. (B) Three-dimensional frontal view; deep facial dehiscence with exposure of the root surface were notable for mandibular incisors. (C&D) CBCT cross section of central incisors (#24 and 25) showed thin crestal thin radicular phenotype on both facial and lingual side. (E) Periapical radiograph showed preserved interproximal bone height. (F) Ultrasonography image of facial surface of #25; notable anatomical landmarks are the cemento-enamel junction (CEJ), thin gingival phenotype, lack of facial bone, thick muscle fibers at the apical third of the root. *Ultrasonography courtesy of Dr. Albert Chan.*

Table 2: List of the most documented markers of bone remodeling organized according to the cell target.

Osteoblast specific transcription factors	Osteoblast differentiation factors	Osteoclast primary factors	Osteoclast secondary factors
Runt-related transcription factor 2 (Runx2)	Wnt signaling	Macrophage-Colony Stimulating Factor (M-CSF)	ParaThyroid Hormone related Protein (PTHrP)
Distal-less homeobox 5 (Dlx5)	Bone Morphogenetic Proteins (BMPs)	RANK/RANKL/OPG axis	Interleukin-1 β (IL-1 β)
Osterix (Osx)	Micro RNAs (MiRNAs)		Interleukin-6 (IL-6)
	Connexin 43 (Cx43)		Tumor Necrosis Factor- α (TNF)
	Fibroblast grow factor (FGF)		

Osteoclasts are giant multinucleated cells deriving from the hematopoietic monocyte/macrophage lineage [40]. Their key morphologic features are related with the function of bone resorption [41]. Osteoclasts present a complex bone-facing membrane called “*sealing membrane*” that is featured by membrane expansions known as “*ruffled border*” [42]. As opposed to the sealing membrane that faces the bone, the “*basolateral membrane*” is oriented towards the vascular compartment [43]. The sealing membrane is enriched in adhesion podosomes, that form a ring (“*actin ring*”) on the peripheral area of the osteoclasts [44]. After anchorage and sealing of a resorption microenvironment, proton pump and chloride channel mediate the acidification of the resorption lacuna to degrade the bone inorganic matrix hydroxyapatite [45-47]. Acidification of the resorption lacuna not only demineralizes the bone matrix but also exposes the organic components, made up for 95% of type I collagen. The release of lysosomal enzymes, mainly cathepsin K and the tartrate resistant acid phosphatase, mediate the degradation of the organic components of bone [47]. Finally, vesicles are responsible for the endocytosis of degraded protein fragments, their transportation to the basolateral surface of the cell and discharge into the vascular compartment. Osteoclasts are the driving force for bone remodeling and bone remodeling is not only critical for bone resorption but also bone homeostasis.

Osteoblasts are bone cells dedicated to apposition. They represent the 4-6% of the total resident cells in the bone and originate from the pluripotent mesenchymal stem cells [48]. Osteoblasts have a key role in processes like bone matrix synthesis, regulation of osteoclastogenesis, and endocrine signaling. Bone building by osteoblasts implies the secretion of collagen proteins, mainly type I collagen, non-collagen proteins and proteoglycans. The newly formed non-mineralized bone matrix is called osteoid. The osteoid is soon mineralized by growth of hydroxyapatite crystals, derived by matrix vesicles from the membrane surface of osteoblasts [49]. Once an osteoblast stops actively forming new bone matrix, (i) it can become a quiescent cell on the bone surface, known as a lining cell; (ii) it can undergo programmed

cell death via the process of apoptosis; (iii) or it can become embedded in its own osteoid and differentiate into an osteocyte [50]. Bone lining cells are quiescent flat shaped osteoblasts covering the bone surface, functionally representing the resting phase of the bone remodeling. A likely role of these cells is to prevent the direct interaction between osteoclasts and bone matrix, when bone resorption should not occur [45].

Osteocytes are spider-shaped cells buried in mineralized bone matrix and are the last stadium of differentiation of the osteoblasts [51]. Osteocytes are the most numerous bone cells in the bone, accounting for more than 90% of the bone cell count [48]. Osteocytes are localized in the mineral lacuna and surrounded by bone fluid derived from plasma. They are, therefore, exposed to systemic regulators of bone remodeling such as PTH, estrogens and Vit.D. [52]. They are also interconnected by dendritic processes that create communication between osteocytes and osteoblasts, and between neighboring osteocytes with gap junction [52, 53]. Osteocytes regulate bone remodeling acting on osteoclasts; osteocytes express RANKL and M-CSF to promote osteoclast formation, and OPG and NO to inhibit osteoclast formation and activity. Osteocytes also secrete modulators of the Wnt signaling pathway: prostaglandin E2 (PGE2), nitric oxide (NO), and adenosine triphosphate (ATP) act to activate Wnt signaling, whereas sclerostin, DKK1, and SFRP1 inhibit Wnt signaling and subsequent osteoblast activity. The life span of the osteocyte is determined by rates of bone turnover, so that osteocytes may have a half-life of even decades if they are located within a bone that has a slow turnover rate [52].

ii. **Bone remodeling and orthodontic tooth movement**

It is well established that bone, including the alveolar bone, is a tissue of dynamic remodeling [54]. The whole skeleton remodels entirely multiple times in a lifetime period and its function goes far beyond mechanical purposes, contributing to calcium distribution, hematopoiesis, local inflammatory process and more [48]. Plasticity of dentoalveolar bone allows temporary conversion of the mineralized matrix in unmineralized matrix, allowing tooth movement through the decalcified matrix, and re-mineralizes the bone matrix when compression forces are suspended. Regardless of the nature of the stressors applied on the bone surface the process of bone remodeling is constantly characterized by phases of (i) osteoclastic bone resorption, (ii) reversal from catabolism to apposition and (iii) restoration of new bone by osteoblasts [55, 56]. All phases are finely regulated by cellular and molecular mechanisms needed to avoid bone pathologies (Table 2) and the same phases exist for the orthodontically induced tooth movement [57].

After application of any kind of mechanical stress on the tooth surface, periodontal ligament and bone become stimulated by both tensile and compressive forces [58]. Compression induces constriction of the microvasculature, hyalinization of the periodontal ligament and temporary localized necrosis. Necrotic areas are then removed by clastic cells migrating from the surrounding bone marrow sites [59]. The resorptive phase creates a non-mineralized matrix and allows tooth movement. Failure of the resorptive phase is followed by delayed movement or immobility, in addition to altered bone apposition. In other terms, no bone apposition can occur on the tension side until the necrotic tissue on the compression side has been removed [60]. Under ideal conditions, resorption occurs on compressed area at the periodontal ligament-bone interface, the tooth is free to occupy a new position, and bone apposition occurs on the tension side and on the external surface of the alveolar process [61]. Bone growth is composed of two processes: deposition of organic matrix and its mineralization. The initial organic matrix is mainly composed of collagen type 1 and it is called osteoid. The process of mineralization starts with the synthesis of hydroxyapatite crystals within the matrix vesicles of osteoblasts and chondrocytes [49]. The hydroxylation of tricalcium phosphate $[\text{Ca}_3(\text{PO}_4)_2]$ forms hydroxyapatite, which

is released in the extracellular space. In the phase of nucleation, nuclei of hydroxyapatite start to grow due to the increased number of ions and their orientation [62].

The bone remodeling is obviously different in adults and the plasticity of the alveolar bone following orthodontic tooth movement is limited. The pattern of bone remodeling associated with orthodontic tooth movement in the context of aging, anti-resorptive agents, and bone grafting is currently under investigation and, hopefully, it will provide new insights for phenotype modification therapy soon.

b. ERUPTION AND DEVELOPMENT OF PERIODONTAL PHENOTYPE

i. Clinical examination of periodontal phenotype

Examination of soft and hard tissue phenotype is of paramount importance to predict tissue behavior during orthodontic therapy, and to prevent long-term complications such as late-onset recessions.

Thickness of gingival phenotype can be assessed with: (i) conventional probing, (ii) aided colored probes, (iii) transgingival penetration with needle, endodontic file or probe, (iv) caliper after flap elevation and (v) ultrasonography [63]. The use of conventional probe is surely the most inexpensive, fast, non-invasive methodology of phenotype assessment. The insertion of the tip of the probe into the periodontal sulcus induces a temporary stretching of the free gingiva. Visual assessment of the tissue response following probing was used in the past to classify “thin” phenotypes if the probe was notable as a transparency through the tissue, versus “thick” phenotypes if the probe was not visible through the tissue [64, 65]. Gingival thickness of 1mm was proposed as cutoff between thin and thick tissues assessed with the conventional probe. Later investigations attempted a more systematic and quantitative measure of gingival thickness. Kouklos et al. (2018) investigated gingival thickness comparing ultrasonography, transgingival probing, colored probe, and needle acupuncture. Ultrasound and transgingival probing showed to be the most repeatable and reliable assessment of the real gingival thickness. Bone thickness is of more difficult investigation and, often, only a rough estimate of bone thickness is obtainable. The CBCT is routinely used to assess bone thickness, as described in the previous paragraph on imaging for diagnostics. Periodontal phenotype is tightly associated with pattern of eruption. Thick phenotypes are less prone to recessions but more prone to altered passive eruption; on the other hand, thin phenotypes are at high risk of dehiscence and recession. The following paragraphs present different types of tooth eruption and how they relate with the development and phenotype of periodontium.

ii. Physiologic and pathologic eruption

Tooth eruption is a dynamic process that simultaneously involves osteoclastic bone resorption coronal to the tooth that is erupting, together with PDL formation and root elongation in the apical zones.

Physiologic eruption is the emergence of a tooth from its follicle into the oral cavity. It comprises two phases: an active eruption phase in which the tooth appears into the oral cavity and actively moves coronally until the occlusal plane; and a passive eruption phase that is characterized by apical migration of the soft tissue to fully expose the clinical crown [66]. Eruption, specifically the dental follicle, has a major role for bone development. Classical studies show that if the dental follicle is surgically removed from the tooth, the tooth does not erupt, and the bone stops its development [67]. On the other hand, if the dental follicle is left intact but the tooth is surgically removed and replaced with a metallic substitute, the replica erupts with concomitant bone growth [68]. Further studies investigated the role of different

regions of the dental follicle for tooth eruption and bone development. Animal studies reported that the coronal part of the dental follicle seems to be of higher importance for eruption and development; indeed, selective removal of the coronal half impaired tooth eruption while the selective removal of the apical part did not [69]. Macroscopically, active eruption is noted as the appearance of the tooth into the oral cavity and its coronal migration until the occlusal plane is reached. Passive eruption is represented by the apical migration of the mucogingival and bone complex at the level of the cemento-enamel junction (CEJ) after completion of active eruption. The relationship between tooth eruption and alveolar bone height has always been of interest to the researcher and clinicians. We will discuss the significant impact to the alveolar bone from tooth impaction later in this section. In some cases of tooth hypereruption (active secondary eruption), the periodontium will follow the tooth coronally, and potentially alter the level of dentoalveolar bone. However, in most physiologic eruption, it is accompanied by passive eruption [70].

Active secondary eruption represents the process of extrusion of a tooth to a position more coronal than the occlusal plane. Extrusion, or over-eruption, is triggered by missing occlusal stimulation with secondary production of apical cementum. Three types of active secondary eruption have been described [71] (Table 3). Type 1 is characterized by tooth wear and over-eruption to meet its antagonist counterpart [72, 73]. Type 2 occurs in case of over-eruption due to missing antagonist or significant loss of structure from the antagonist tooth. In Type 1 and Type 2 active secondary eruption, the gingival margin follows the coronal extrusion of the crown with eruption of the whole dentoalveolar process. Type 3, lastly, represents the phenomenon of extrusion without coronal migration of the gingival margin; the crown in this case will appear elongated and will expose root structure to the oral cavity (Figure 7).

Table 3: Etiologic classification of Active Secondary Eruption and its implication on periodontal tissue.

	Type 1	Type 2	Type 3
Etiology	Tooth wear	Missing antagonist or wear antagonist	Missing antagonist or wear antagonist
Occlusal plane	Maintained	Altered	Altered
Antagonist tooth	Preserved	Missing or affected by tooth wear	Missing or affected by tooth wear
Position of the gingival contour	Coronal migration	Coronal migration	Original position
Root exposure	Not exposure	Not exposure	Recession with exposure of the root to the oral cavity

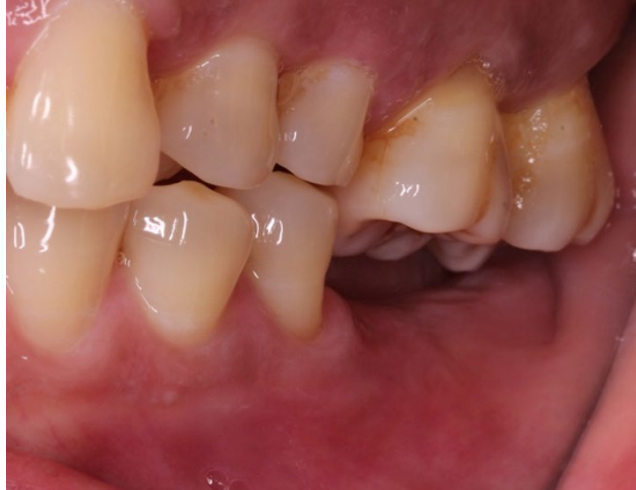

Figure 7. Clinical examination showed extrusion of first and second maxillary left molars (#14 & 15) due to missing opposing contacts. Despite the significant overeruption, the periodontal apparatus did not appear to migrate coronally. Due to the hypereruption with concomitant recession, the case was classified as type 3 active secondary eruption.

At the end of the process of active eruption, the tooth is in contact with the antagonist at the level of the occlusal plane; however, its crown has reduced apico-coronal distance due to coronal positioning of the gingival margin. In the process of physiological passive eruption, the mucogingival complex migrates apically to re-establish its position at the level of the cemento-enamel junction (CEJ). During passive eruption, the crown will appear progressively longer not because further eruption, but due to the apical migration of the gingival margin. Sometimes, the tooth erupts normally but the mucogingival complex does not migrate apically. This condition is named altered passive eruption and usually represents an esthetic concern due to appearance of short clinical crown.

Altered passive eruption refers to the failure of the process of passive eruption. Typically, when the gingival margin remains coronal to the CEJ giving the appearance of “short” clinical crown. The prevalence of altered passive eruption is estimated to be approximately 12% [74]. In a well-known classification by Coslet et al. (1977), altered passive eruption was described based on different presentations of keratinized gingiva and bone height [75]. Type 1 refers to cases presenting abundant width of keratinized tissues (KT) and with a mucogingival junction (MGJ) more apical than the bone crest, as opposed to Type 2 which is featured by a physiological or reduced KT width and an MGJ positioned more coronal than the bone crest. Subgroup A is used when the bone crest is located 1 to 2 mm apically to the CEJ allowing normal attachment of the supracrestal connective tissue fibers on the root cementum, as opposed to Subgroup B in which the bone crest is close than 1 mm to the CEJ impinging on the space for connective tissue fiber attachment. The combination of Types and Subgroups brings to 4 possible scenarios as shown in Table 4.

It is interesting that orthodontic treatment has been proposed as one of the etiologies of altered passive eruptions. Orthodontically treated patients had a 30% increased prevalence of altered passive eruption compared to untreated control patients despite no statistically significant difference was achieved [76]. It is unknown whether the increased prevalence of altered passive eruption was a result of orthodontic treatment itself, that decreased the distance between the CEJ and the alveolar crest, or if the

orthodontic force altered the eruption process. The impact and clinical implications may warrant future classification and investigation.

At present, thick periodontal phenotype is the most acknowledged etiologic factor for altered passive eruption [76]. Manifestation of altered active eruption appears as excessive gingival display and “gummy smile” that requires esthetic crown lengthening. During esthetic crown lengthening, bone architecture is contoured and thinned to improve the display of the anatomical crown into clinical crown. Esthetic crown lengthening is, therefore, a subtractive phenotype modification procedure.

Table 4: Classification of clinical presentations of Altered Passive Eruption with recommended treatment

	Subgroup A	Subgroup B
Type 1	Adequate KT, physiological distance between bone and CEJ	Adequate KT, bone close to the CEJ
Recommended treatment	Gingivectomy	Internal bevel flap with bone reduction
Type 2	Inadequate KT, physiological distance between bone and CEJ	Inadequate KT, bone close to the CEJ
Recommended treatment	Apically positioned flap	Apically positioned flap with bone reduction

Abbreviations. CEJ: cemento-enamel junction. KT: keratinized tissue.

iii. Tooth impaction

Tooth impaction describes the presence of an unerupted tooth after the end of the physiological period of eruption. It is an anomaly of eruption that affects permanent dentition, despite there have been studies documenting impaction of primary teeth [77, 78]. The overall prevalence ranges from 0.8 to 3.6% of the general population [79, 80]. Most affected primary teeth are primary molars, while the most commonly impacted permanent teeth are, in sequence, third molars, maxillary canines, second premolars and maxillary incisors [79, 81, 82]. The incidence of impacted third molars is much higher than other teeth and ranges from 16 to 68% [83]. Although sometimes erupted third molars can be used as an anchorage for orthodontic treatment, extraction of erupted or impacted third molars may leave a socket defect over the alveolar bone and resulted in residual periodontal pocket of the distal surface of the second molars [84]. Clinical studies found lower incidence of residual defects in younger patients and more favorable outcomes in case of bone grafting after the extraction [85]. Interestingly, age was found to be a confounding factor for both recovery after extraction and defect resolution [84].

Impaction is often associated with altered skeletal bone development [86]. Biological plausibility relates to a reduced mechanical stimulation due to the lack of occlusion on the impacted tooth or the stagnant follicle that guided both tooth eruption and remodeling of the alveolar bone. As a result, there is a reduced biological stimulation for bone growth secondary to the lack of tooth eruption [87]. Classical research has demonstrated the key role of bone growth and eruption. Animal studies found that tooth eruption was associated with increased formation of bone trabeculae [88]. Studies on knockout mice deficient in membrane-type 1 (MT1) MMP showed slow eruption with reduced bone formation [89, 90]. Human studies validated the theories that low bone development occurred in areas of impacted teeth. A CBCT study found reduced bone height and width on the impacted side compared to the healthy

contralateral [86]. An impacted tooth can also cause bony defect and alter the anatomy of the alveolar ridge (Figure 8).

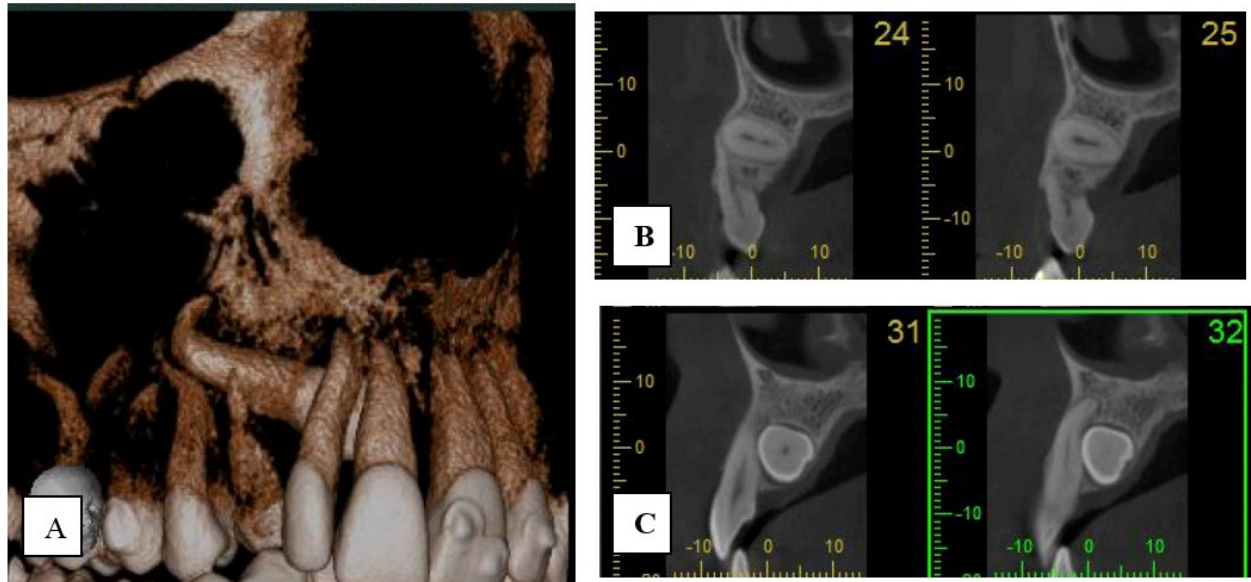


Figure 8. Three-dimensional reconstruction and cross sections of CBCT images revealed how an impacted upper right canine could impact the anatomy of the bone and phenotype. (A) The impacted canine shows a palatal position compared to the roots of the upper incisors. (B) Cross section images reveal a the very thin facial bone that most likely presented with fenestration defect in relation to the roots of the retained primary canine and impacted permanent canine. (C) Dilaceration of the root of the lateral incisor with the impacted canine crown that perforated the palatal cortical bone.

Maxillary canines are the secondary category of teeth at higher risk of impaction. The prevalence of maxillary canine impaction ranges from 0.8 to 2.8% [82, 91]. The position of the impacted canine is often palatal with a ratio of palatal:facial impaction from 2:1 to 6:1 [92-94]. Two main theories have been proposed to explain the etiology of maxillary impacted canines and they are the (1) genetic theory and the (2) guidance theory [95-98]. The genetic theory hypothesize that maxillary palatal impaction has familial and hereditary component and it is often encountered in patients with other dental anomalies [95]. On the other hand, the guidance theory postulates that the canine erupts along the distal surface of the root of the lateral incisor, which serves as a guide. If the root of the lateral incisor is absent, malformed (peg-shaped), or if the canine is severely misplaced, the canine may not erupt [99]. Other etiologic theories have been proposed to be responsible of canine impaction. Maxillary hypoplasia could contribute through obstruction of local anatomy with roots of adjacent teeth, or with ectopic position of the impacted element, or in case of syndromic conditions idiopathically associated with altered eruptive process [100]. The treatment of impacted maxillary canines is multidisciplinary and usually involves either 1) extraction of an impacted tooth, 2) extraction of an adjacent tooth or 3) non-extraction treatment involving orthodontic space development and surgical exposure [101]. Extraction of the impacted tooth may result in significant bone deficiency, depending from length, positioning and inclination of the maxillary canine. In case of ridge healing with significantly reduced bucco-palatal bone width, staged bone augmentation is recommended to develop the site for future implant placement. More conservative treatment options consider surgical exposure of the impacted canine followed by orthodontic positioning

of the tooth into a physiological position in the alveolar arch. Multiple techniques have been described for canine exposure and the open-eruption technique, apically positioned flap, and closed-eruption technique are among the most documented [101].

iv. Buccal ectopic eruption

Buccally erupted teeth oftentimes present with dehiscence defects over the alveolar bone and a lack of keratinized gingiva [102]. Orthodontic traction is successful to improve the hard tissue facial to the tooth; however, the absence of attached gingiva may persist after tooth alignment. A series of surgical techniques have been proposed to reconstruct the facial mucogingival complex during the process of eruption, and they take the name of “mucogingival interceptive surgery” of the buccally erupted teeth [102, 103]. The goal of the mucogingival interceptive surgery is to obtain keratinized gingiva (KG) on the facial surface of the permanent tooth, preserving the native gingiva and positioning it to a favorable location on the tooth for long-term health. The apico-coronal eruption plays an important role in terms of the phenotype of the residual gingiva on the facial side of the erupting tooth. While teeth that erupt at the level of the mucogingival junction (MGJ) may still present with a facial narrow band of KG, those erupted apical to the MGJ often have total absence of facial KG. In both scenarios, most of the available KG is entrapped palatally to the permanent tooth, attached to the retained deciduous element, if present, via epithelial or connective tissue attachment (Figure 9). Oftentimes, the existing gingiva is loosely attached to the primary tooth and would easily remodel with the extraction of the primary element [102, 103]. To preserve the available KG before its loss, a double pedicle flap or an apically positioned flap were proposed to apically move the entrapped gingiva from the space between permanent and deciduous tooth to the zone facial to the permanent tooth [104, 105]. Free soft tissue graft was recommended for the more unfavorable clinical scenario of a permanent tooth which has significantly erupted apically to the MGJ. Randomized split-mouth trials documented the efficacy of the mucogingival interceptive surgery to achieve and maintain a healthy phenotype with adequate keratinized mucosa. Randomly allocated bilateral buccal erupted teeth were placed into either a test group and treated with alignment and interceptive surgery as previously described, or a control group that received only tooth alignment without interceptive surgery [104]. Two years after therapy, the test group showed significantly higher KG width compared to the untreated control side (KG: 2.9 vs. 1.3 mm; test vs. control). In addition, incipient recession of 1 mm was noted for the control group only. Long term results of mucogingival interceptive techniques showed also successful outcomes. A 7-year follow-up of treated teeth maintained a physiological mucogingival dimension that was comparable to the pristine phenotype of the physiologically erupted control sites [105]. Therefore, the phenotype of a facially-erupted tooth needs to be examined carefully and mucogingival interceptive surgery may be indicated.

v. Congenitally missing teeth

Congenitally missing teeth (CMT) refers to the agenesis of one or more teeth of the permanent and/or primary dentition. CMT is a result of disturbances during the early stages of development and has strong genetic predisposition to the etiology [106, 107]. The most supported etiological theory suggests a multifactorial interaction between a polygenic inheritance together with environmental factors like infection, trauma or drugs [108, 109]. Bone deficiency in the area of CMT is due to the absence of stimulating factors normally produced by the dental follicle. A plethora of trophic signaling molecules, like OPG, RANKL, CSF-1, VEGF, TNF- α , EMAP-II, MCP-1, and SFRP-1 is produced by the dental follicle and is finely orchestrated during the process of bone growth concomitant to the tooth eruption [110]. In case

there is an absence of the follicle, no bone trophic proteins are produced, resulting in a reduced bone mass and density.

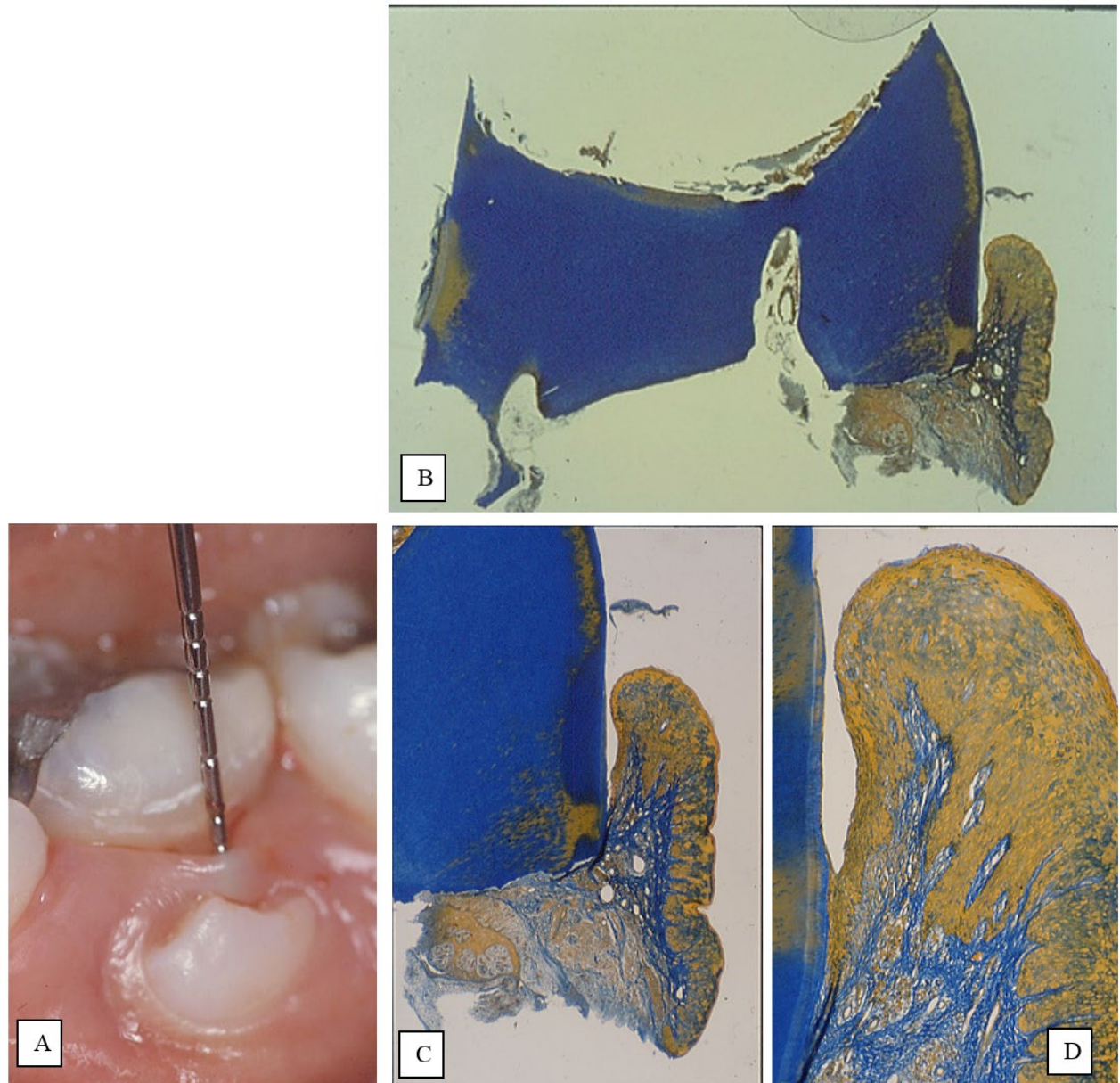


Figure 9. Ectopically erupted maxillary premolar showed keratinized tissue entrapped between the permanent tooth and the deciduous molar retained in the dental arch. (A) The permanent tooth presented with narrow band of keratinized gingiva on the facial side. (B) Entrapped gingival tissue was captured with histology at the time of the extraction of the deciduous tooth. (C&D) At higher magnification, epithelial and connective tissue attachment are noted between the tissue and the deciduous tooth. Epithelial attachment featured the facial interface between deciduous tooth and gingiva, while connective tissue attachment was found apically to it. *Courtesy of Prof. Pini Prato.*

To overcome the problem of poor-quality bone density, recent studies documented the beneficial adjunct of bone-trophic molecules loaded on the implant surface to enhance osteogenesis [111]. The clinical impact of the compromised bone volume is then accentuated in the case of multiple missing teeth. Dental aplasia is classified based on the number of missing teeth at radiographic examination. The prevalence of CMT is low in primary dentition, with a range between 0.1% and 2.4% [112]. However, primary dental aplasia is usually followed by permanent tooth missing. The prevalence of CMT in the permanent dentition ranges between 0.15% and 16.2%, excluding the third molars [112]. CMT is associated with reduced ridge volume due to the lack of trophic effect that the dental follicle would had had on dentoalveolar bone. As result of the bone deficiency, a multidisciplinary treatment involving site development is often advocated. The edentulous space can be either left open for implant-supported restoration, or closed by orthodontic means [113, 114]. Other treatment modalities might include auto-transplantation or protraction of the third molars, which are otherwise extracted [114, 115]. In case of space opening for implant-retained restoration, the volume of available bone is often inadequate for implant purposes and site development procedures are needed. Multiple surgical approaches have been proposed to increase the bone volume for implant purposes; meta-analysis concluded that available techniques are equally effective to increase of the amount of bone volume without statistically significant differences [116]. Regarding timing of site development, a recent case series successfully documented simultaneous orthodontic uprighting with bone grafting for ridge augmentation [117]. In the interdisciplinary treatment plan for site development before implant placement, guided bone regeneration could be performed after or concomitantly during early active phase of orthodontic treatment [117, 118].

c. PHENOTYPE MODIFICATION THERAPY

Phenotype modification therapy [119, 120] includes various surgical interventions aimed to modify and usually augment the soft and hard tissues surrounding natural dentition. It has been discussed previously in the chapter how thin gingiva and bone dehiscence represent anatomical predisposing factors for recessions. Thin soft- and hard-tissue phenotype are largely prevalent among the population and may or may not be followed by recession [121]. Despite some patients present with thin phenotype without recession, traumatic factors could induce unexpected tissue remodeling and trigger the onset of recessions [122]. Orthodontic therapy has been considered as one of the precipitating factors able to induce recession especially in areas with predisposed thin phenotype [33]. While short term studies found no association between orthodontic tooth movement and gingival recessions, longer follow-ups study reported an increase from 7% post treatment, to 20% after 2 years, to 38% after 5 years [123, 124]. In the light of the previous considerations, phenotype conversion therapy aims to thicken the soft and hard tissues to eliminate the anatomical predisposing conditions such as bone dehiscence and thin gingiva, allowing for safe orthodontic treatment without long-term risk of gingival recession. Augmentation of periodontal phenotype can involve hard and/or soft tissues. As shown in Figure 10, a young female complained about a progressive gingival recession over #24 during orthodontic treatment. Significant root prominence and interradicular concavities were noted indicating alveolar bone deficiency in addition to a very thin periodontal phenotype. Both hard and soft tissue augmentations were performed in this case resulted in complete root coverage and increased tissue contour (Figure 10). Increasing evidence supports the use of bone grafting for hard-tissue augmentation, while the effect of soft-tissue grafting was less studied in the context of orthodontic patients and the bulk of knowledge derives from periodontal plastic literature [120, 125, 126].

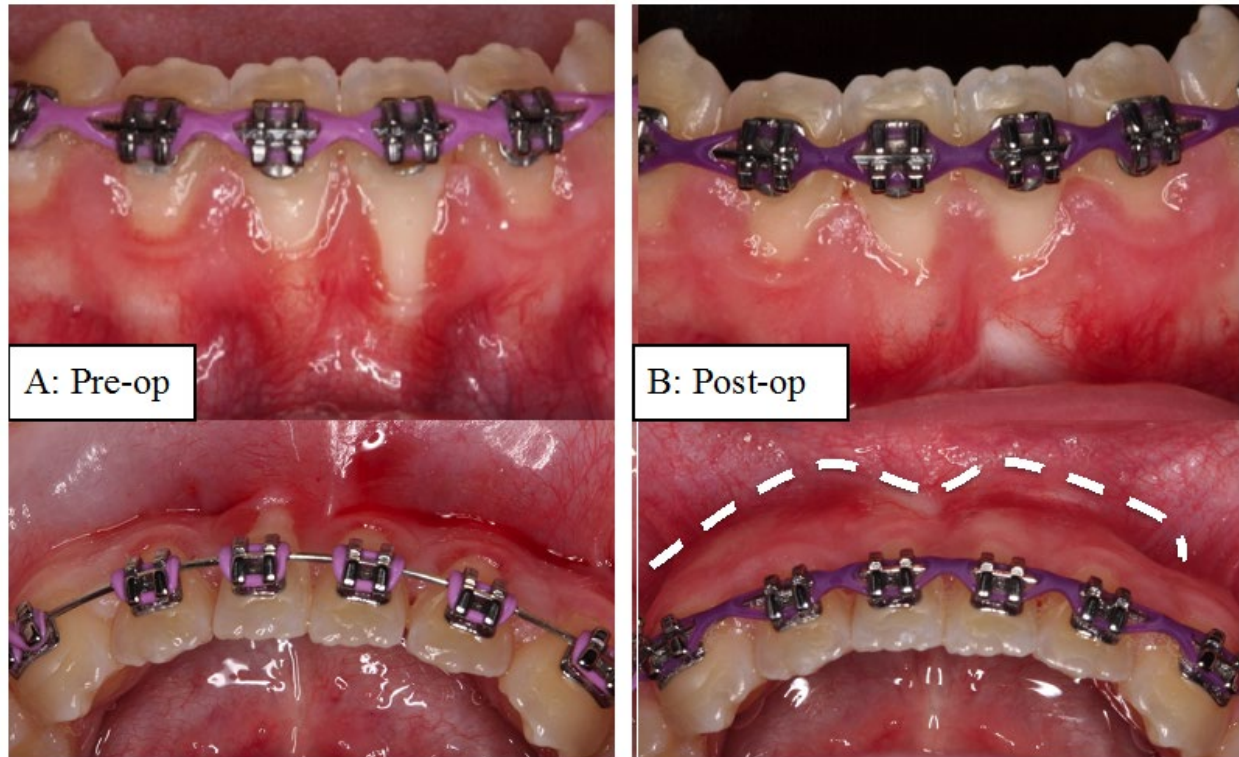


Figure 10. Complete root coverage and tissue contour augmentation achieved after periodontal phenotype augmentation via both hard and soft tissue augmentation in 16-year-old female receiving orthodontic treatment. Frontal and incisal view pre- and 6 months post-operative. (A) As shown in the frontal view that a progressive gingival recession over #24 revealed during orthodontic treatment. Significant root prominence and interradicular concavities were also noted indicating alveolar bone deficiency in addition to a very thin periodontal phenotype. (B) Both hard and soft tissue augmentations were performed for periodontal phenotype augmentation and resulted in complete root coverage, increased tissue contour and increased keratinized tissue width. Also noted in deepening of the vestibule space due to muscle release during the procedure to achieve long-term tissue stability.

i. Hard tissue augmentation

Hard tissue augmentation, as one of the approaches to modify phenotype, has been used to increase the alveolar bone volume [119]. It offers distinct advantages that can help overcome some commonly encountered limitations of conventional orthodontics. First, adult patients usually have slower bone metabolism for remodeling and slower orthodontic tooth movement rate. As a result, they often refuse orthodontic therapy due to the expected longer treatment times. For this purpose, cortical penetration of the alveolar bone as part of the hard-tissue augmentation showed to accelerate orthodontic tooth movement due to the regional acceleratory phenomenon. If utilized correctly with coordinated orthodontics-periodontics interdisciplinary care, it can be effective to reduce the treatment duration about half of the time compared to the control group where no surgery. The beneficial effects of surgically assisted orthodontic therapy was also confirmed in systematic reviews and meta-analyses [127, 128]. A second indication for bone phenotype augmentation is when proposed orthodontic tooth movement plan goes beyond the limitation outlined by Proffit's envelope of discrepancy. Orthodontic

solutions for the adult patient with crowding are (1) extraction retraction therapy or (2) expansion and potentially positioning the dentition outside the orthodontic boundaries. As previously discussed, facial movement may reduce the buccal bone thickness and predispose to dehiscence and recession [129, 130]. To prevent the occurrence of bone deficiency, bone grafting can successfully increase the thickness of the buccal bone outside of the native envelope, and especially over mandibular anterior sextants where published studies have demonstrated successfully [131]. Phenotype augmentation also contributes to increased stability and reduced relapse after orthodontic therapy. A study comparing the Little's Irregularity Index between non-surgical, conventional orthodontics and corticotomy-assisted orthodontics involving bone grafting reported better post-orthodontic stability/retention rates for the surgical group after both 5 and 10 years [132]. Studies investigating surgically facilitated orthodontics with bone grafting reported no complication like compromised root length or pulpal vitality compared to the traditional non-surgical orthodontics [132-134]. Phenotype augmentation was also found beneficial when compared to the surgically accelerated orthodontics without bone grafting. Both modalities had reduced treatment time, however, the adjunctive use of bone grafting allowed for thickening of native bone. Specifically, bone grafting at the time of the cortical penetration improved bone density and bone thickness compared to the cortical penetration alone, without any disadvantage in terms of periodontal health, esthetics, root length or treatment timing [135, 136].

ii. Soft tissue augmentation

The goal of soft-tissue augmentation is to prevent the onset or progression of recession by increasing gingival thickness without modifying the underlying bone. Although the concern is less if the tooth is planned to be orthodontically retracted lingually, it is indicated when there is less than 2mm keratinized tissue, especially without attachment. According to the 2020 AAP Best Evidence Review, controlled studies are lacking regarding the outcome of soft tissue grafting for phenotype augmentation in orthodontic patients, only two studies were available but with limited outcome reporting [120]. A classical retrospective study by Maynard and Ochsenein recommended free gingival graft as interceptive and corrective therapy for pediatric patients. The authors concerned the high incidence of mucogingival deformities among orthodontic patients and recommended pre-orthodontic soft-tissue grafting for sites with 1 mm or less of keratinized tissue. The results showed the test side increased keratinized tissue thickness and the authors concluded that autogenous gingival graft should be recommended to patients with insufficient keratinized tissue [137]. A comparative study investigating lingual retraction of mandibular teeth with or without soft tissue graft, found similar results for gingival recession between the two groups [138]. It should be noted, however, that free gingival graft procedure was used in the study, that is not ideal for root coverage purposes. While earlier studies reported on the use of free gingival graft for soft tissue augmentation, no studies investigated the use of connective tissue graft in the orthodontic patients. High quality randomized clinical trials and long-term studies from periodontal literature showed unarguable phenotype thickening with the use of autogenous connective tissue graft and collagen substitute materials but their use for phenotype augmentation in orthodontic patients remains to be investigated [125, 126].

CONCLUSIONS

Alveolar bone is a highly dynamic tissue associated with the periodontium as they both are configured together during growth development and tooth eruption. Orthodontic tooth movement has a gradual life-long impact on the periodontium and dentoalveolar bone. The phenotype of the periodontium and the alveolar bone should be examined carefully before the orthodontic treatment

embarks, especially for adults when there is atrophy of the alveolar bone and the plasticity has become limited. Clinical examination and 3D radiographic imaging can provide insight into the risk associated with thin tissue phenotype and limited orthodontic boundaries. Periodontal phenotype modification should be considered in patients with higher risk not only to avoid future periodontal complications but also to strengthen tissue and treatment stability.

ACKNOWLEDGEMENTS

We would like to thank Professor Pini Prato (Tuscany Academy of Dental Research ATRO, Florence, Italy) for kindly providing clinical and histological images shown in Figure 3 and 10. We would also like to thank Dr. Hsun-Liang Chan (Department of Periodontics and Oral Medicine, University of Michigan, Ann Arbor, MI, USA) for kindly providing the ultrasound image shown in Figure 7F.

REFERENCES

1. Saffar JL, Lasfargues JJ, Cherruau M. Alveolar bone and the alveolar process: the socket that is never stable. *Periodontol 2000* 1997;13:76-90.
2. Glickman I, Smulow JB. Adaptive alterations in the periodontium of the rhesus monkey in chronic trauma from occlusion. *J Periodontol* 1968; 39(2):101-105.
3. Pini Prato G, Di Gianfilippo R, Wang H-L. Success in periodontology: An evolutive concept. *J Clin Periodontol* 2019; 46(8):840-845.
4. Ten Cate AR. The development of the periodontium--a largely ectomesenchymally derived unit. *Periodontol 2000* 1997;13:9-19.
5. Nanci A. *Ten Cate's Oral Histology*, 8 edn. St. Louis, Missouri: Elsevier Mosby 2013.
6. Enlow DH, Moyers RE. Growth and architecture of the face. *J Am Dent Assoc* 1971, 82(4):763-774.
7. Stedman HH, Kozyak BW, Nelson A, Thesier DM, Su LT, Low DW, et al. Myosin gene mutation correlates with anatomical changes in the human lineage. *Nature* 2004;428(6981):415-418.
8. McPherron AC, Lawler AM, Lee SJ. Regulation of skeletal muscle mass in mice by a new TGF-beta superfamily member. *Nature* 1997;387(6628):83-90.
9. Hamrick MW, McPherron AC, Lovejoy CO, Hudson J. Femoral morphology and cross-sectional geometry of adult myostatin-deficient mice. *Bone* 2000;27(3):343-349.
10. Hohl TH. Masticatory muscle transposition in primates: effects on craniofacial growth. *J Maxillofac Surg* 1983;11(4):149-156.
11. Brennan M, Antonyshyn O. The effects of temporalis muscle manipulation on skull growth: an experimental study. *Plast Reconstr Surg* 1996;97(1):13-24.
12. Christiansen P, Wroe S. Bite forces and evolutionary adaptations to feeding ecology in carnivores. *Ecology* 2007;88(2):347-358.
13. Varrelle J. Dimensional variation of craniofacial structures in relation to changing masticatory-functional demands. *Eur J Orthod* 1992;14(1):31-36.
14. Enlow DH, Bianco HJ, Eklund S. The remodeling of the edentulous mandible. *J Prosthet Dent* 1976;36(6):685-693.
15. Avci M, Iplikcioglu H. An analysis of edentulous maxillary arch width and palatal height. *Int J Prosthodont* 1992;5(1):73-77.
16. Nowzari H, Molayem S, Chiu CH, Rich SK. Cone beam computed tomographic measurement of

- maxillary central incisors to determine prevalence of facial alveolar bone width ≥ 2 mm. *Clin Implant Dent Relat Res* 2012;14(4):595-602.
17. Ghassemian M, Nowzari H, Lajolo C, Verdugo F, Pirronti T, D'Addona A. The thickness of facial alveolar bone overlying healthy maxillary anterior teeth. *J Periodontol* 2012;83(2):187-197.
 18. Peterson AG, Wang M, Gonzalez S, Covell DA, Jr., Katancik J, Sehgal HS. An In Vivo and Cone Beam Computed Tomography Investigation of the Accuracy in Measuring Alveolar Bone Height and Detecting Dehiscence and Fenestration Defects. *Int J Oral Maxillofac Implants* 2018;33(6):1296-1304.
 19. Rupprecht RD, Horning GM, Nicoll BK, Cohen ME. Prevalence of dehiscences and fenestrations in modern American skulls. *J Periodontol* 2001;72(6):722-729.
 20. Evangelista K, Vasconcelos Kde F, Bumann A, Hirsch E, Nitka M, Silva MA. Dehiscence and fenestration in patients with Class I and Class II Division 1 malocclusion assessed with cone-beam computed tomography. *Am J Orthod Dentofacial Orthop* 2010;138(2):133 e131-137; discussion 133-135.
 21. Grimoud AM, Gibbon VE, Ribot I. Predictive factors for alveolar fenestration and dehiscence. *Homo* 2017;68(3):167-175.
 22. Karring T, Nyman S, Thilander B, Magnusson I. Bone regeneration in orthodontically produced alveolar bone dehiscences. *J Periodontal Res* 1982;17(3):309-315.
 23. Garib DG, Henriques JF, Janson G, de Freitas MR, Fernandes AY. Periodontal effects of rapid maxillary expansion with tooth-tissue-borne and tooth-borne expanders: a computed tomography evaluation. *Am J Orthod Dentofacial Orthop* 2006;129(6):749-758.
 24. Mandelaris GA, Vence BS, Rosenfeld AL, Forbes DP. A classification system for crestal and radicular dentoalveolar bone phenotypes. *Int J Periodontics Restorative Dent* 2013;33(3):289-296.
 25. Richman C. Is gingival recession a consequence of an orthodontic tooth size and/or tooth position discrepancy? "A paradigm shift". *Compend Contin Educ Dent* 2011;32(1):62-69.
 26. Askar H, Di Gianfilippo R, Askar G, Chan H-L, Wang H-L. Morphometric analysis of the Mental Foramina, Accessory Mental Foramina, and Anterior Loops: A CBCT Study. *Acta Scientific Dental Sciences* 2018;2(12):126-132.
 27. Mandelaris GA, Rosenfeld AL. Alternative applications of guided surgery: precise outlining of the lateral window in antral sinus bone grafting. *J Oral Maxillofac Surg* 2009;67(Suppl 11):23-30.
 28. Mandelaris GA, Rosenfeld AL. A novel approach to the antral sinus bone graft technique: the use of a prototype cutting guide for precise outlining of the lateral wall. A case report. *Int J Periodontics Restorative Dent* 2008;28(6):569-575.
 29. Gibson CF, Mandelaris GA. Restoration of the Anterior Segment in a Cleft Palate in Conjunction with Surgically Facilitated Orthodontic Therapy: An Interdisciplinary Approach. *Dent Clin North Am* 2015;59(3):733-753.
 30. Mandelaris GA, Rosenfeld AL, King SD, Nevins ML. Computer-guided implant dentistry for precise implant placement: combining specialized stereolithographically generated drilling guides and surgical implant instrumentation. *Int J Periodontics Restorative Dent* 2010;30(3):275-281.
 31. Mandelaris GA, Scheyer ET, Evans M, Kim D, McAllister B, Nevins ML, et al. American Academy of Periodontology Best Evidence Consensus Statement on Selected Oral Applications for Cone-Beam Computed Tomography. *J Periodontol* 2017;88(10):939-945.
 32. Chan HL, Benavides E, Yeh CY, Fu JH, Rudek IE, Wang HL. Risk assessment of lingual plate perforation in posterior mandibular region: a virtual implant placement study using cone-beam computed tomography. *J Periodontol* 2011;82(1):129-135.
 33. Mandelaris GA, Neiva R, Chambrone L. Cone-Beam Computed Tomography and Interdisciplinary Dentofacial Therapy: An American Academy of Periodontology Best Evidence Review Focusing on Risk Assessment of the Dentoalveolar Bone Changes Influenced by Tooth Movement. *J Periodontol*

- 2017;88(10):960-977.
34. Nguyen KC, Le LH, Kaipatur NR, Major PW. Imaging the Cemento-Enamel Junction Using a 20-MHz Ultrasonic Transducer. *Ultrasound Med Biol* 2016;42(1):333-338.
 35. Nguyen KT, Le LH, Kaipatur NR, Zheng R, Lou EH, Major PW. High-Resolution Ultrasonic Imaging of Dento-Periodontal Tissues Using a Multi-Element Phased Array System. *Ann Biomed Eng* 2016;44(10):2874-2886.
 36. Tsiolis FI, Needleman IG, Griffiths GS. Periodontal ultrasonography. *J Clin Periodontol* 2003;30(10):849-854.
 37. Chifor R, Hedesiu M, Bolfa P, Catoi C, Crisan M, Serbanescu A, et al. The evaluation of 20 MHz ultrasonography, computed tomography scans as compared to direct microscopy for periodontal system assessment. *Med Ultrason* 2011;13(2):120-126.
 38. Chan HL, Sinjab K, Chung MP, Chiang YC, Wang HL, Giannobile WV, et al. Non-invasive evaluation of facial crestal bone with ultrasonography. *PLoS One* 2017;12(2):e0171237.
 39. Chan HL, Wang HL, Fowlkes JB, Giannobile WV, Kripfgans OD. Non-ionizing real-time ultrasonography in implant and oral surgery: A feasibility study. *Clin Oral Implants Res* 2017;28(3):341-347.
 40. Teitelbaum SL. Osteoclasts: what do they do and how do they do it? *Am J Pathol* 2007;170(2):427-435.
 41. Cappariello A, Maurizi A, Veeriah V, Teti A. The Great Beauty of the osteoclast. *Arch Biochem Biophys* 2014;558:70-78.
 42. Domon T, Yamazaki Y, Fukui A, Ohnishi Y, Takahashi S, Yamamoto T, Wakita M. Three-dimensional distribution of the clear zone of migrating osteoclasts on dentin slices in vitro. *Tissue Cell* 2002;34(5):326-336.
 43. Baron R. Polarity and membrane transport in osteoclasts. *Connect Tissue Res* 1989;20(1-4):109-120.
 44. Gay CV, Weber JA. Regulation of differentiated osteoclasts. *Crit Rev Eukaryot Gene Expr* 2000;10(3-4):213-230.
 45. Del Fattore A, Teti A. The tight relationship between osteoclasts and the immune system. *Inflamm Allergy Drug Targets* 2012;11(3):181-187.
 46. Duong LT, Lakkakorpi P, Nakamura I, Rodan GA. Integrins and signaling in osteoclast function. *Matrix Biol* 2000;19(2):97-105.
 47. Blair HC, Kahn AJ, Crouch EC, Jeffrey JJ, Teitelbaum SL. Isolated osteoclasts resorb the organic and inorganic components of bone. *J Cell Biol* 1986;102(4):1164-1172.
 48. Capulli M, Paone R, Rucci N. Osteoblast and osteocyte: games without frontiers. *Arch Biochem Biophys* 2014;561:3-12.
 49. Anderson HC. Matrix vesicles and calcification. *Curr Rheumatol Rep* 2003;5(3):222-226.
 50. Manolagas SC. Birth and death of bone cells: basic regulatory mechanisms and implications for the pathogenesis and treatment of osteoporosis. *Endocr Rev* 2000;21(2):115-137.
 51. Bonewald LF. The amazing osteocyte. *J Bone Miner Res* 2011;26(2):229-238.
 52. Dallas SL, Prideaux M, Bonewald LF. The osteocyte: an endocrine cell ... and more. *Endocr Rev* 2013;34(5):658-690.
 53. Doty SB. Morphological evidence of gap junctions between bone cells. *Calcif Tissue Int* 1981;33(5):509-512.
 54. Kim BJ, Koh JM. Coupling factors involved in preserving bone balance. *Cell Mol Life Sci* 2019;76(7):1243-1253.
 55. Matsuo K, Irie N. Osteoclast-osteoblast communication. *Arch Biochem Biophys* 200; 473(2):201-209.
 56. Zaidi M. Skeletal remodeling in health and disease. *Nat Med* 2007;13(7):791-801.
 57. Negishi-Koga T, Takayanagi H. Bone cell communication factors and Semaphorins. *Bonekey Rep* 2012;1:183.

58. Antoun JS, Mei L, Gibbs K, Farella M. Effect of orthodontic treatment on the periodontal tissues. *Periodontol 2000* 2017;74(1):140-157.
59. Brudvik P, Rygh P. Multi-nucleated cells remove the main hyalinized tissue and start resorption of adjacent root surfaces. *Eur J Orthod* 1994;16(4):265-273.
60. Meikle MC. The tissue, cellular, and molecular regulation of orthodontic tooth movement: 100 years after Carl Sandstedt. *Eur J Orthod* 2006;28(3):221-240.
61. Melsen B. Tissue reaction to orthodontic tooth movement--a new paradigm. *Eur J Orthod* 2001;23(6):671-681.
62. Yoshiko Y, Candelieri GA, Maeda N, Aubin JE. Osteoblast autonomous Pi regulation via Pit1 plays a role in bone mineralization. *Mol Cell Biol* 2007;27(12):4465-4474.
63. Kloukos D, Koukos G, Doulis I, Sculean A, Stavropoulos A, Katsaros C. Gingival thickness assessment at the mandibular incisors with four methods: A cross-sectional study. *J Periodontol* 2018;89(11):1300-1309.
64. Frost NA, Mealey BL, Jones AA, Huynh-Ba G. Periodontal Biotype: Gingival Thickness as It Relates to Probe Visibility and Buccal Plate Thickness. *J Periodontol* 2015;86(10):1141-1149.
65. Kan JY, Morimoto T, Rungcharassaeng K, Roe P, Smith DH. Gingival biotype assessment in the esthetic zone: visual versus direct measurement. *Int J Periodontics Restorative Dent* 2010;30(3):237-243.
66. Mele M, Felice P, Sharma P, Mazzotti C, Bellone P, Zucchelli G. Esthetic treatment of altered passive eruption. *Periodontol 2000* 2018;77(1):65-83.
67. Cahill DR, Marks SC, Jr. Tooth eruption: evidence for the central role of the dental follicle. *J Oral Pathol* 1980;9(4):189-200.
68. Marks SC, Jr., Cahill DR. Experimental study in the dog of the non-active role of the tooth in the eruptive process. *Arch Oral Biol* 1984;29(4):311-322.
69. Marks SC, Jr., Cahill DR. Regional control by the dental follicle of alterations in alveolar bone metabolism during tooth eruption. *J Oral Pathol* 1987;16(4):164-169.
70. Varrela TM, Paunio K, Wouters FR, Tiekso J, Soder PO. The relation between tooth eruption and alveolar crest height in a human skeletal sample. *Arch Oral Biol* 1995;40(3):175-180.
71. Ahmad I. Altered passive eruption (APE) and active secondary eruption (ASE): differential diagnosis and management. *Int J Esthet Dent* 2017;12(3):352-376.
72. Compagnon D, Woda A. Supraeruption of the unopposed maxillary first molar. *J Prosthet Dent* 1991;66(1):29-34.
73. Lam WY, Ho EH, Pow EH. Rehabilitation of molar-incisor hypomineralization (MIH) complicated with localized tooth surface loss: a case report. *Quintessence Int* 2014;45(5):377-379.
74. Robbins JW. Differential diagnosis and treatment of excess gingival display. *Pract Periodontics Aesthet Dent* 1999;11(2):265-272; quiz 273.
75. Coslet JG, Vanarsdall R, Weisgold A. Diagnosis and classification of delayed passive eruption of the dentogingival junction in the adult. *Alpha Omegan* 1977;70(3):24-28.
76. Nart J, Carrio N, Valles C, Solis-Moreno C, Nart M, Rene R, et al. Prevalence of altered passive eruption in orthodontically treated and untreated patients. *J Periodontol* 2014;85(11):e348-353.
77. Kwon SO, Lee S, Lee N. Treatment of Combined Primary Impaction of Primary Second Molars and Permanent First Molars. *Pediatr Dent* 2016;38(7):143-147.
78. Gunduz K, Muglali M, Inal S. Total impaction of deciduous maxillary molars: two case reports. *J Contemp Dent Pract* 2007;8(6):64-71.
79. Chu FC, Li TK, Lui VK, Newsome PR, Chow RL, Cheung LK. Prevalence of impacted teeth and associated pathologies--a radiographic study of the Hong Kong Chinese population. *Hong Kong Med J* 2003;9(3):158-163.
80. Hattab FN, Rawashdeh MA, Fahmy MS. Impaction status of third molars in Jordanian students. *Oral*

- Surg Oral Med Oral Pathol Oral Radiol Endod 1995;79(1):24-29.
81. Dachi SF, Howell FV. A survey of 3,874 routine full-mouth radiographs. I. A study of retained roots and teeth. *Oral Surg Oral Med Oral Pathol* 1961;14:916-924.
 82. Grover PS, Lorton L. The incidence of unerupted permanent teeth and related clinical cases. *Oral Surg Oral Med Oral Pathol* 1985;59(4):420-425.
 83. Hashemipour MA, Tahmasbi-Arashlow M, Fahimi-Hanzaei F. Incidence of impacted mandibular and maxillary third molars: a radiographic study in a Southeast Iran population. *Med Oral Patol Oral Cir Bucal* 2013;18(1):e140-145.
 84. Askar H, Di Gianfilippo R, Ravidia A, Tattan M, Majzoub J, Wang HL. Incidence and severity of postoperative complications following oral, periodontal, and implant surgeries: A retrospective study. *J Periodontol* 2019;90(11):1270-1278.
 85. Sammartino G, Tia M, Bucci T, Wang HL. Prevention of mandibular third molar extraction-associated periodontal defects: a comparative study. *J Periodontol* 2009;80(3):389-396.
 86. Tadinada A, Mahdian M, Vishwanath M, Allareddy V, Upadhyay M, Yadav S. Evaluation of alveolar bone dimensions in unilateral palatally impacted canine: a cone-beam computed tomographic analyses. *Eur J Orthod* 2015;37(6):596-602.
 87. Yao S, Prpic V, Pan F, Wise GE. TNF-alpha upregulates expression of BMP-2 and BMP-3 genes in the rat dental follicle--implications for tooth eruption. *Connect Tissue Res* 2010;51(1):59-66.
 88. Cahill DR. The histology and rate of tooth eruption with and without temporary impaction in the dog. *Anat Rec* 1970;166(2):225-237.
 89. Beertsen W, Holmbeck K, Niehof A, Bianco P, Chrysovergis K, Birkedal-Hansen H, et al. On the role of MT1-MMP, a matrix metalloproteinase essential to collagen remodeling, in murine molar eruption and root growth. *Eur J Oral Sci* 2002;110(6):445-451.
 90. Bartlett JD, Zhou Z, Skobe Z, Dobeck JM, Tryggvason K. Delayed tooth eruption in membrane type-1 matrix metalloproteinase deficient mice. *Connect Tissue Res* 2003;44 (Suppl 1):300-304.
 91. Aydin U, Yilmaz HH, Yildirim D. Incidence of canine impaction and transmigration in a patient population. *Dentomaxillofac Radiol* 2004;33(3):164-169.
 92. Gaulis R, Joho JP. The marginal periodontium of impacted upper canines. Evaluation following various methods of surgical approach and orthodontic procedures. *SSO Schweiz Monatsschr Zahnheilkd* 1978;88(11):1249-1261.
 93. Fournier A, Turcotte JY, Bernard C. Orthodontic considerations in the treatment of maxillary impacted canines. *Am J Orthod* 1982;81(3):236-239.
 94. Jacoby H. The etiology of maxillary canine impactions. *Am J Orthod* 1983;84(2):125-132.
 95. Peck S, Peck L, Kataja M. The palatally displaced canine as a dental anomaly of genetic origin. *Angle Orthod* 1994;64(4):249-256.
 96. Bjerklin K, Kuroi J, Valentin J. Ectopic eruption of maxillary first permanent molars and association with other tooth and developmental disturbances. *Eur J Orthod* 1992;14(5):369-375.
 97. Bass TB. Observations on the misplaced upper canine tooth. *Dent Pract Dent Rec* 1967;18(1):25-33.
 98. Becker A, Smith P, Behar R. The incidence of anomalous maxillary lateral incisors in relation to palatally-displaced cuspids. *Angle Orthod* 1981;51(1):24-29.
 99. Brin I, Becker A, Shalhav M. Position of the maxillary permanent canine in relation to anomalous or missing lateral incisors: a population study. *Eur J Orthod* 1986;8(1):12-16.
 100. Becker A, Chaushu S. Etiology of maxillary canine impaction: a review. *Am J Orthod Dentofacial Orthop* 2015;148(4):557-567.
 101. Kaczor-Urbanowicz K, Zadurska M, Czochrowska E. Impacted Teeth: An Interdisciplinary Perspective. *Adv Clin Exp Med* 2016;25(3):575-585.
 102. Agudio G, Pini Prato G, De Paoli S, Nevins M. Mucogingival interceptive therapy. *Int J Periodontics Restorative Dent* 1985;5(5):48-59.

103. Pini Prato GP, Clauser C, Cortellini P. Periodontal plastic and mucogingival surgery. *Periodontol* 2000 1995;9:90-105.
104. Pini Prato G, Baccetti T, Giorgetti R, Agudio G, Cortellini P. Mucogingival interceptive surgery of buccally-erupted premolars in patients scheduled for orthodontic treatment. II. Surgically treated versus nonsurgically treated cases. *J Periodontol* 2000;71(2):182-187.
105. Pini Prato G, Baccetti T, Magnani C, Agudio G, Cortellini P. Mucogingival interceptive surgery of buccally-erupted premolars in patients scheduled for orthodontic treatment. I. A 7-year longitudinal study. *J Periodontol* 2000;71(2):172-181.
106. Fekonja A. Hypodontia in orthodontically treated children. *Eur J Orthod* 2005, 27(5):457-460.
107. Varela M, Trujillo-Tiebas MJ, Garcia-Camba P: Case report: identical twins revealing discordant hypodontia. The rationale of dental arch differences in monozygotic twins. *Eur Arch Paediatr Dent* 2011;12(6):318-322.
108. Varela M, Arrieta P, Ventureira C. Non-syndromic concomitant hypodontia and supernumerary teeth in an orthodontic population. *Eur J Orthod* 2009;31(6):632-637.
109. Thesleff I. The genetic basis of tooth development and dental defects. *Am J Med Genet A* 2006;140(23):2530-2535.
110. Wise GE. Cellular and molecular basis of tooth eruption. *Orthod Craniofac Res* 2009;12(2):67-73.
111. Di Gianfilippo R, Di Gianfilippo C, Pini Prato G. The Role of Epigenetics on Dental Implant Therapy: A Systematic Review. *Epigenomes* 2017;1(2):12.
112. Rakhshan V. Congenitally missing teeth (hypodontia): A review of the literature concerning the etiology, prevalence, risk factors, patterns and treatment. *Dent Res J (Isfahan)* 2015;12(1):1-13.
113. Kokich VG, Kokich VO. Congenitally missing mandibular second premolars: clinical options. *Am J Orthod Dentofacial Orthop* 2006;130(4):437-444.
114. Chung CJ, Han JH, Kim KH. The pattern and prevalence of hypodontia in Koreans. *Oral Dis* 2008;14(7):620-625.
115. Chung KR, Cho JH, Kim SH, Kook YA, Cozzani M. Unusual extraction treatment in Class II division 1 using C-orthodontic mini-implants. *Angle Orthod* 2007;77(1):155-166.
116. Elnayef B, Monje A, Gargallo-Albiol J, Galindo-Moreno P, Wang HL, Hernandez-Alfaro F. Vertical Ridge Augmentation in the Atrophic Mandible: A Systematic Review and Meta-Analysis. *Int J Oral Maxillofac Implants* 2017;32(2):291-312.
117. Wang CW, Chou MY, Chen R, Rowe T, Masoud M, Kim DM, Intini G. Simultaneous Ridge Augmentation and Accelerated Molar Uprighting for Implant Site Development: Two Case Reports with a Split-Mouth Design. *Int J Periodontics Restorative Dent* 2017;37(3):423-430.
118. Wang C. Personalized Precision Integration of Augmentation and Implant Surgeries with Accelerated Adult Orthodontics for Synergized Interdisciplinary Care. In: Kim-Berman H, Franchi L, Ruellas A, eds *Effective, Efficient and Personalized Orthodontics: Patient-centered Approaches and Innovations Craniofacial Growth Series*, Center for Human Growth and Development, The University of Michigan, Ann Arbor, MI 2018;55:173-197.
119. Kao RT, Curtis DA, Kim DM, Lin GH, Wang CW, Cobb CM, et al. American Academy of Periodontology best evidence consensus statement on modifying periodontal phenotype in preparation for orthodontic and restorative treatment. *J Periodontol* 2020.91(3):289-298.
120. Wang CW, Yu SH, Mandelaris GA, Wang HL. Is periodontal phenotype modification therapy beneficial for patients receiving orthodontic treatment? An American Academy of Periodontology best evidence review. *J Periodontol* 2020;91(3):299-310.
121. Zweers J, Thomas RZ, Slot DE, Weisgold AS, Van der Weijden FG. Characteristics of periodontal biotype, its dimensions, associations and prevalence: a systematic review. *J Clin Periodontol* 2014;41(10):958-971.
122. Hall WB. Present status of soft tissue grafting. *J Periodontol* 1977;48(9):587-597.

123. Ruf S, Hansen K, Pancherz H. Does orthodontic proclination of lower incisors in children and adolescents cause gingival recession? *Am J Orthod Dentofacial Orthop* 1998;114(1):100-106.
124. Renkema AM, Fudalej PS, Renkema A, Kiekens R, Katsaros C. Development of labial gingival recessions in orthodontically treated patients. *Am J Orthod Dentofacial Orthop* 2013;143(2):206-212.
125. Barootchi S, Tavelli L, Di Gianfilippo R, Byun HY, Oh TJ, Barbato L, et al. Long term assessment of root coverage stability using connective tissue graft with or without an epithelial collar for gingival recession treatment. A 12-year follow-up from a randomized clinical trial. *J Clin Periodontol* 2019;46(11):1124-1133.
126. Tavelli L, Barootchi S, Di Gianfilippo R, Modarressi M, Cairo F, Rasperini G, et al. Acellular dermal matrix and coronally advanced flap or tunnel technique in the treatment of multiple adjacent gingival recessions. A 12-year follow-up from a randomized clinical trial. *J Clin Periodontol* 2019;46(9):937-948.
127. Hoogeveen EJ, Jansma J, Ren Y. Surgically facilitated orthodontic treatment: a systematic review. *Am J Orthod Dentofacial Orthop* 2014;145(Suppl 4):S51-64.
128. Zimmo N, Sal MHA, Sinjab K, Wang CW, Mandelaris G, Wang HL. Corticotomy-Assisted Orthodontics for Canine Distalization: A Systematic Review and Meta-Analysis of Clinical Controlled Trials. *J Int Acad Periodontol* 2018;20(4):153-162.
129. Engelking G, Zachrisson BU. Effects of incisor repositioning on monkey periodontium after expansion through the cortical plate. *Am J Orthod* 1982;82(1):23-32.
130. Renkema AM, Fudalej PS, Renkema AA, Abbas F, Bronkhorst E, Katsaros C. Gingival labial recessions in orthodontically treated and untreated individuals: a case - control study. *J Clin Periodontol* 2013;40(6):631-637.
131. Brugnami F, Caiazzo A, Mehra P. Can corticotomy (with or without bone grafting) expand the limits of safe orthodontic therapy? *J Oral Biol Craniofac Res* 2018;8(1):1-6.
132. Makki L, Ferguson DJ, Wilcko MT, Wilcko WM, Bjerklin K, Stapelberg R, et al. Mandibular irregularity index stability following alveolar corticotomy and grafting: a 10-year preliminary study. *Angle Orthod* 2015;85(5):743-749.
133. Ahn HW, Seo DH, Kim SH, Park YG, Chung KR, Nelson G. Morphologic evaluation of dentoalveolar structures of mandibular anterior teeth during augmented corticotomy-assisted decompensation. *Am J Orthod Dentofacial Orthop* 2016;150(4):659-669.
134. Wilcko MT, Ferguson DJ, Makki L, Wilcko WM. Keratinized Gingiva Height Increases After Alveolar Corticotomy and Augmentation Bone Grafting. *J Periodontol* 2015;86(10):1107-1115.
135. Bahammam MA. Effectiveness of bovine-derived xenograft versus bioactive glass with periodontally accelerated osteogenic orthodontics in adults: a randomized, controlled clinical trial. *BMC Oral Health* 2016;16(1):126.
136. Shoreibah EA, Ibrahim SA, Attia MS, Diab MM. Clinical and radiographic evaluation of bone grafting in corticotomy-facilitated orthodontics in adults. *J Int Acad Periodontol* 2012;14(4):105-113.
137. Maynard JG, Jr., Ochsenein C. Mucogingival problems, prevalence and therapy in children. *J Periodontol* 1975;46(9):543-552.
138. Ngan PW, Burch JG, Wei SH. Grafted and ungrafted labial gingival recession in pediatric orthodontic patients: effects of retraction and inflammation. *Quintessence Int* 1991;22(2):103-111.

FORCE SYSTEM WITH V-BENDS: TWO VS. THREE-DIMENSIONAL ANALYSIS OF TOOTH MOVEMENTS – A PRELIMINARY STUDY

Meenakshi Vishwanath, Po-Jung Chen, Takafumi Asaki, Madhur Upadhyay

ABSTRACT

The application of a predictable force system requires an understanding of the mechanical principles commonly used in clinical orthodontics. In order to unravel the archwire-bracket interactions of a multi-bracketed appliance system, it is critical to analyze the force system created by a two-bracket system. The previous understanding of the two-bracket force system using the V-bend mechanics was primarily from a two-dimensional (2-D) analysis of archwire bracket interactions in the second order. These analyses did not take into consideration the three-dimensional (3-D) nature of orthodontic appliances which also involves third order wire-bracket interactions. The main objective of this paper was to perform a preliminary evaluation of the force system generated by orthodontic arch wires undergoing large and small deflections (vertical V-bends) in a 2 x 2 appliance set up. It was based on in-vitro studies where the maxillary molar and incisor brackets were arranged in a dental arch form and attached to load cells capable of measuring forces and moments in all three planes (x, y, and z) of space. Symmetrical V-bends (right and left sides) of 12 and 30 degrees (°) were placed at 11 different locations along rectangular stainless steel (SS) archwires. The force system produced by the bracket–archwire interaction was assessed. Specifically, the vertical forces (Fz) and antero-posterior moments (Mx) were analyzed. As the archwire stiffness increased, both the Fz and Mx increased at the two brackets (P < 0.05). The vertical forces were linear and symmetric in nature, increasing in magnitude as the bends moved closer to either bracket. The Mx curves were asymmetric and non-linear displaying higher magnitudes for molar bracket. As the bends were moved closer to the molar bracket a distinct flattening of the incisor Mx curve was noted. This chapter aims to provide pivotal information on the 3-D understanding of the V-bend mechanics with relevant clinical translation.

KEY WORDS: V-bends, 3-D Force System, Biomechanics of Orthodontic Tooth Movement, Quasi-static Equilibrium, Orthodontic Wire Tester

INTRODUCTION

Force/moment (F/M) systems applied to teeth are composed of forces and/or couples[1]. Unlike objects that accelerate (dynamic) when acted upon by an unbalanced force system, teeth remain in a state of rest or equilibrium [2]. For a particle/body to be in such a state of equilibrium, the net force experienced should be zero ($\Sigma F = 0$). Orthodontic biomechanics utilizes these concepts to analyze the F/M system delivered by various appliances. Tooth movement is a slow process occurring over a prolonged period of time (0.5-1.1 mm/month)[3]. Therefore, at any given 'instant of time' tooth movement/acceleration is close to zero and the force system is in balance. Such a system is said to be

'quasi-static' i.e. a process that goes through a sequence of states that are infinitesimally close to equilibrium. At any 'instant' a force analysis may be carried out by invoking the laws of equilibrium without erring appreciably [4].

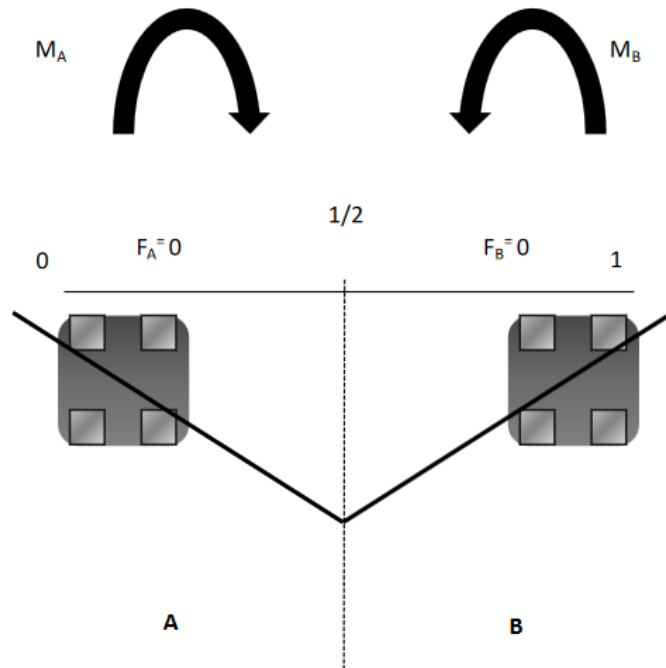
An appliance that creates a couple at one end and a single force at the other, is a statically determinate system wherein, all the forces and moments can be theoretically determined. A classic example is the cantilever spring which creates a one couple force system. However, conventional orthodontics utilizes multibracket appliances producing a complex set of forces which are statically indeterminate. In other words, static equilibrium equations are insufficient for theoretical determination of the precise nature of the force system of multibracket appliances. One way to get around this problem is to break down the multibracket appliance system into smaller units. An example of such a basic unit is an active wire inserted into two edgewise brackets. Unraveling the mechanics of such a system is fundamental to understanding the mechanical principles governing tooth movement [4].

MECHANICS OF A TWO-BRACKET FORCE SYSTEM

Force systems produced by archwire-bracket interactions are either created by inserting a straight wire in non-colinear brackets or by a bent wire in colinear brackets. This was first systematically evaluated by Burstone and Koenig in 1974 [5]. They analyzed the force system created by placing a 0.016-inch stainless steel wire between misaligned canine and premolar brackets. The authors further explored a similar two-bracket arrangement by placing 'V' and 'step' bends and engaging them in aligned brackets [6]. Additional investigations were performed by changing the bend angle, spatial distance between the brackets, modulus of elasticity & moment of inertia of wires [7, 8]. In all these studies, bends were placed between a canine and premolar bracket or between two premolar brackets where the archwire bracket interactions took place specifically in the second order. The force system created with all the variations outlined were remarkably similar.

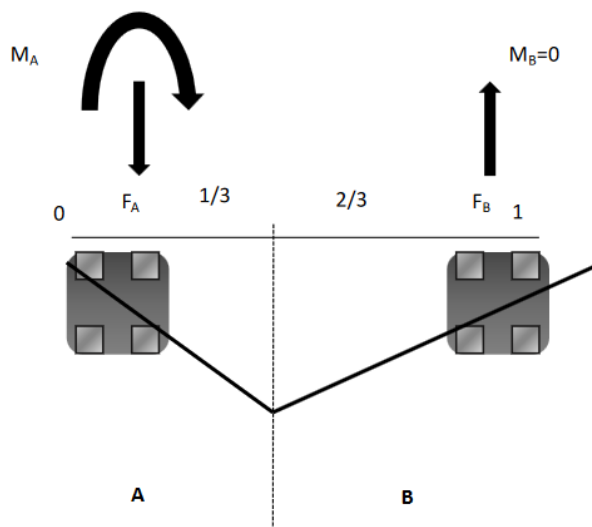
Through these investigations, predictable force systems were outlined using six possible geometries [5, 6]. Upadhyay et al. summarized these configurations into three distinct force systems that are detailed here (Fig 1 a-c) [9]. A V- bend, when placed equidistant between two brackets A & B will produce 'equal and opposite bending moments', without any vertical forces at either bracket (neutral point). When the bend is moved closer to bracket A, the moment on that bracket increases and vertical forces are generated at both brackets to maintain equilibrium. When the bend is at one-third the distance between the brackets, the moment on the more distant bracket B is zero (called the point of dissociation for bracket B). Further displacement of the bend towards A will cause the moment to increase on bracket A with a 'reversal of moment' on B (called the point of reversal for B) in the same direction as the larger moment. This appears to be a result of the wire deflecting within the slots of bracket B due to the close proximity of the bend to bracket A. As the moments are in the same direction, they are additive, leading to large vertical forces produced at both brackets. Now, if the bend is placed in a similar manner, but this time closer to bracket B a similar set of F/M system would be created. In other words, the F/M system between the two brackets shows perfect symmetry or represents mirror images of each other and are therefore interchangeable. It is important to note that the six geometries are representative of a continuum of possible configurations and force systems between the two brackets. The results of the above studies lead to a greater understanding of the statically indeterminate force system in orthodontics.

1A



Neutral point

1B



Dissociation point

1C

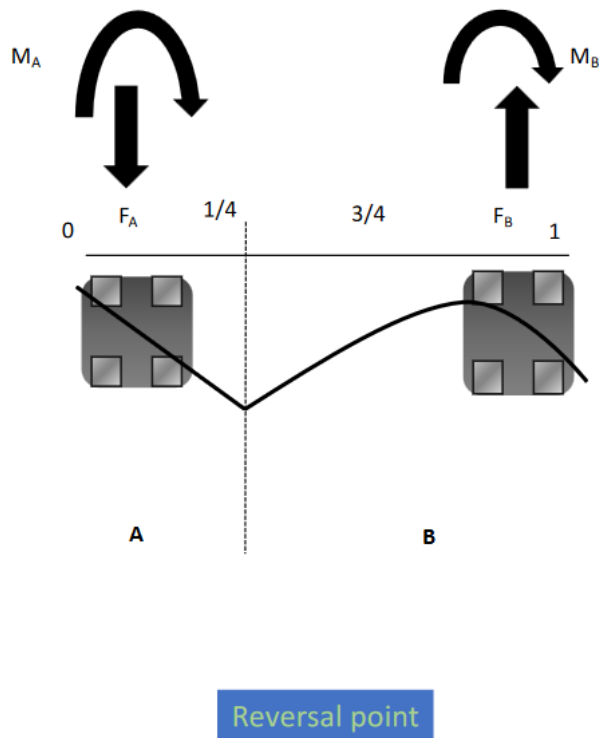


Figure 1. Force system produced by V-bends in two collinear brackets. A- Neutral point with V-bend at the halfway point. B- Disassociation point with V-bend closer ($1/3^{\text{rd}}$ the distance) to bracket A. C- Reversal point with V-bend ($1/4^{\text{th}}$ the distance) very close bracket A.

Note: There is complete symmetry between bracket A and B and moving the bend closer to bracket B will lead to similar force patterns. (The figures are not drawn to scale).

Two important inferences can be drawn from the three geometries described above. Firstly, we see a dramatic change in the moment produced at bracket B when the bend is moved away from it. The specific positions of the bend can be termed 'critical points' as they carry notable clinical relevance and applications. Secondly, due to the virtue of the brackets being in the same plane or order (in this case second order), brackets A and B are mirror images of each other and swapping them just reverses the moments and forces between the two brackets together with the geometries and critical points.

The vertical V- bend, in special situations, also known as the tip-back bend or anchor bend has been typically used to reinforce anchorage. It is also sometimes referred to as the gable bend and/or intrusion bend when used for relative or absolute intrusion. The biomechanical applications of the two-couple force system for Class II correction, anterior crossbite correction, canine retraction, and protraction have been previously outlined [1, 10-14]. On careful analysis, the limitations of applying a purely second order archwire-bracket interaction [5-8] for all clinical situations become fairly obvious. This is due to the fact that only one plane of space, namely the second order, is considered and the two brackets are collinear & parallel in arrangement i.e. they have a two-dimensional (2-D) arrangement. However, clinically, one of the common applications of V-bend is between the molar and incisor in a 2x4 or 2x2 type appliance system which involve both second and third order wire-bracket interactions (Figure 2).

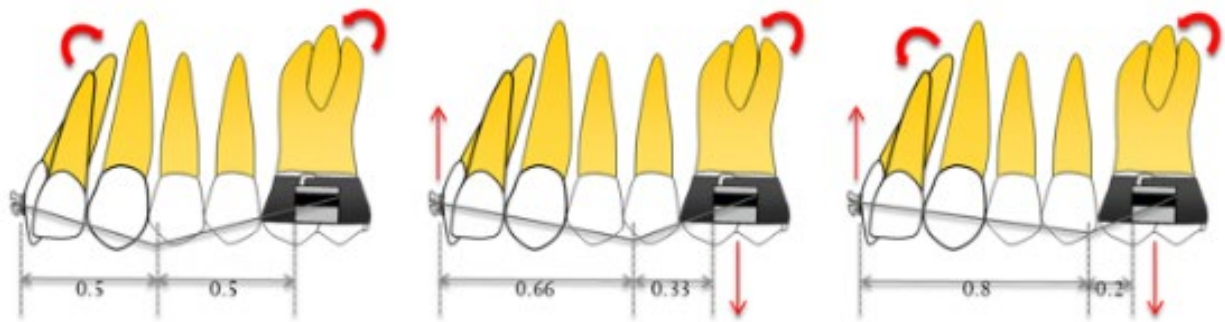


Figure 2. Force system of a 2 x 4 appliance based on the mechanics derived from second order archwire-bracket interactions only.

Isaacson et al. recognized some of these drawbacks and hypothesized that the effects produced by a three-dimensional (3-D) rectangular wire with a single vertical V-bend will produce different moments and forces than those reported for the same bend in a 2-D system [15]. Using an FEM model of a 2x2 appliance system they placed a center V-bend on a 0.017 x 0.025- inch² SS archwire and found that the curves of the 3-D system are not symmetrical nor centered as reported for 2-D systems. However, despite finding a clear difference between the two systems they concluded that the data, while significantly different from the data developed by previous two-couple models, did not radically modify the clinical use of arch wires. Additionally, these studies utilized mathematical models and/or computer-based analysis/simulations [2, 5-8, 15]. Certain boundary conditions were also imposed for running the simulations that might not hold true in actual clinical situations and deviations might occur. More recently, Upadhyay et al, have made attempts to understand and quantify the force system generated in a 3-D two bracket set up involving the molar and incisors with vertical V-bends [9].

The main objective of this preliminary study was to experimentally quantify the force system generated by a two-bracket set up involving the molar and incisors with V-bends placed at specific locations along stainless steel archwires of different sizes. Additionally, as the force system generated for a large or a small deflection 3-D set up has not been qualitatively or quantitatively defined, we wanted to test two different bend angles. Both, a null and alternate hypothesis were defined for the study. The null hypothesis was that there is no difference in the F/M system generated in a 3-D set up simulating a 2x2 appliance when compared to a 2-D set up. The alternate hypothesis was that there will be a difference in the F/M system generated in a 3-D set up simulating a 2x2 appliance when compared to a 2-D set up. This was based on preliminary theoretical modeling and a scaled visual model (Figure 3), which will be described in the Materials and Methods section. It was our intention to generate a set of preliminary graphs/data through which the force system of V-bend could be predicted for 2x2 appliances.

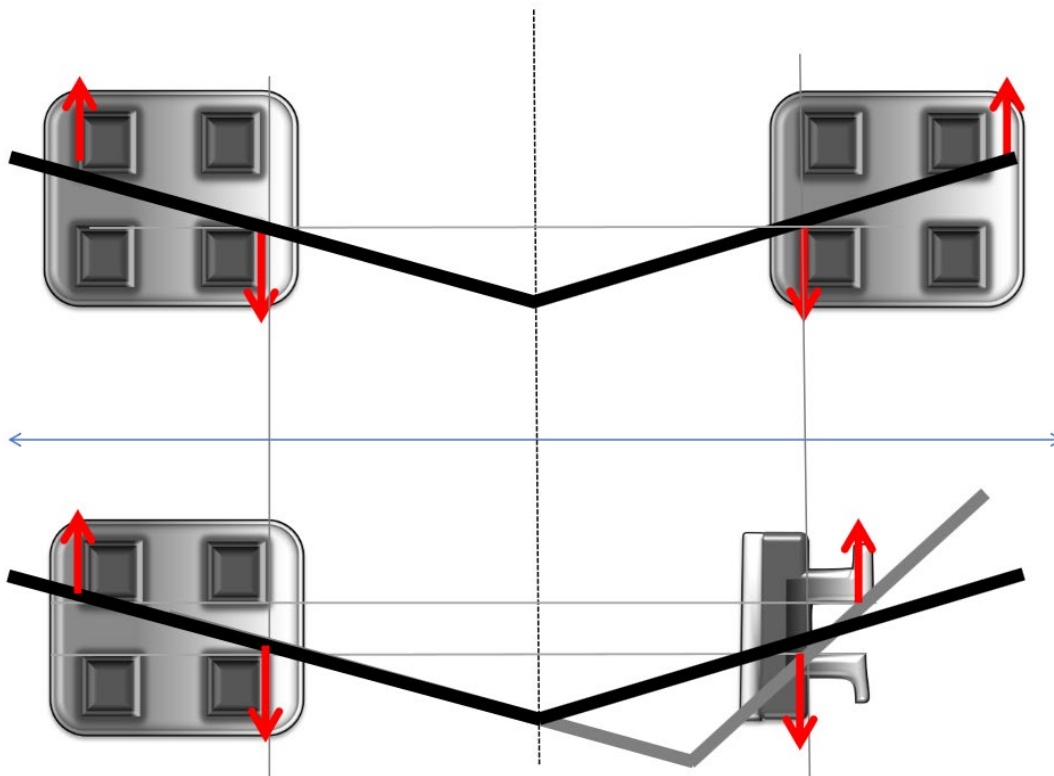


Figure 3. Visual assessment of a V- bend placed in collinear brackets undergoing: A) only second order interactions B) second order and third order interactions.

Note: The wire (black) does not make a two-point contact on the incisor bracket unless the bend is placed very close to it (grey wire).

MATERIALS AND METHODS

A. Archwire bends

A theoretical framework was established in order to determine the deflection angles that would be incorporated into the study. Calculating these angles for the large and small deflections were based on research methods elucidated in previous studies [16].

1. The value for the small deflection angle was determined from the initial study by Burstone et al. where they defined deflection of a 0.016 inch SS archwire in millimeters [6]. Trigonometric calculations were used to convert it to a more meaningful angular measurements (θ). When we consider a symmetric V-bend placed in a wire engaged in two parallel collinear brackets at a distance of 7mm from each other, with a delta value of 0.35mm, we get a right-angled triangle as depicted at the half way point with a deflection angle of 11.4 degrees ($^{\circ}$). This was rounded to 12 $^{\circ}$. This angulation allowed us to directly compare our results with the previous research. It also served as the control group (Figure 4).

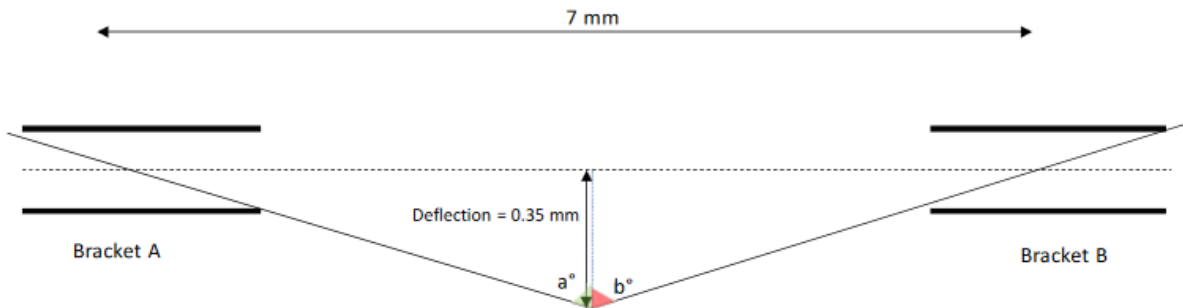


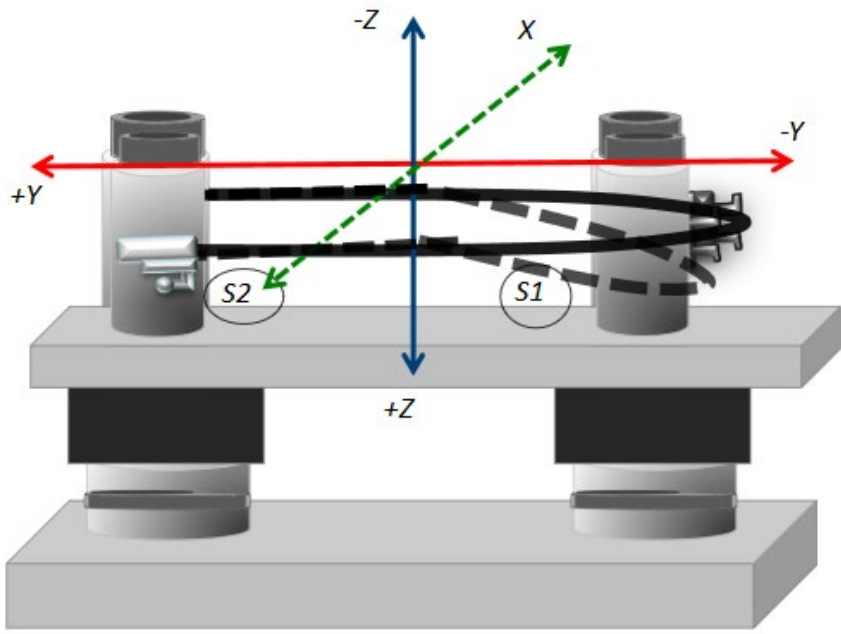
Figure 4. Archwire bracket setup in the second order (Burstone et al)[5, 6] for obtaining small bend angle.

2. The large deflection angle was based on the value of critical contact angles (θ_c) with the smallest size wires. Critical contact angle is defined as the angle where the clearance between the archwire and the bracket first disappears [17]. The θ_c was calculated for both the molar as well as the incisor bracket. For a 0.016-inch SS wire inserted into a molar tube with a length of 3 mm and a slot height of 0.022 inch, θ_c was determined as 3 degrees. Hence, for a 0.016-inch wire to achieve a two-point contact in a 0.022 bracket, the bend had to be at least 3° in the sagittal plane of space. For a 0.016-inch SS wire inserted in an incisor bracket with a slot height of 0.022 inches and depth of 0.028 inches, the θ_c was determined to be approximately 31.5° . The substitution of the bracket length with bracket depth for calculating second order clearance vs third order alters the critical contact angle by approximately a factor of 4, meaning the wire has to be bent to a higher degree to make a two-point contact. The large deflection angle was set at 30° . Therefore, the two bend angulations used for the current study were: 168 and 150 degrees.

B. Experimental Set-Up

To measure the orthodontic force system in vitro, force transducers/ load cells capable of multi-axis measurements were used. A load cell is a mechanical device that can measure the forces and moments applied to it in all the three planes (x-y-z). By using two of these load cells (S1 & S2), from Industrial Automation (ATI NANO 17 SI-50-0.50 7560 & 7651) connected to an incisor and molar bracket a testing apparatus was constructed (Figure 5). The testing apparatus was placed in a glass enclosure. The temperature was maintained at 37°Celsius (Figure 6) [9, 18-20].

5A



5B

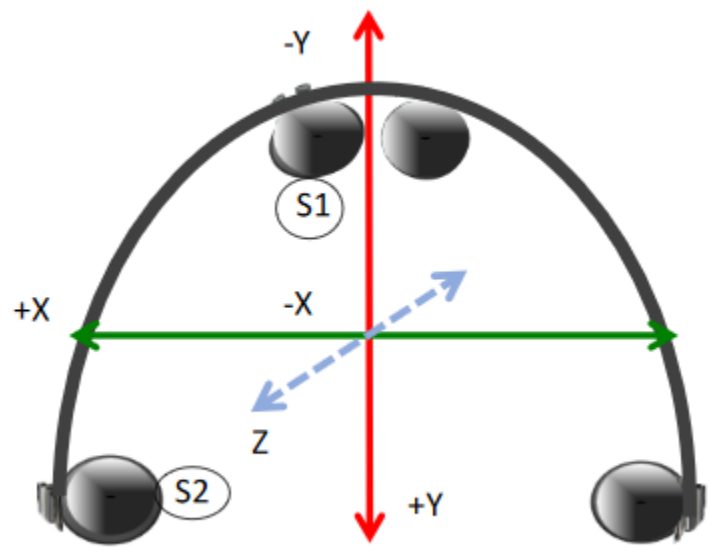


Figure 5. Experimental set up of the load cells with the x-y-z coordinates A) lateral view B) occlusal view.




Figure 6. The orthodontic wire tester: A- Testing apparatus B- Measuring platform C-Temperature monitor.

Aluminum pegs representing the molar and incisor were arranged in the shape of a maxillary dental arch using a predefined arch form, (OrthoForm III – Ovoid from 3M Unitek). The pegs were positioned along the arch such that when brackets were adhered to them, the bracket slots followed the arch form. The distances between the pegs were calculated using average tooth widths. Self-ligating standard edgewise brackets (Empower series from American Orthodontics, 0.022 x 0.028-inch slot dimension) were bonded to the incisor and molar pegs using composite resin. A full dimension stainless steel archwire (0.021 x 0.025 inch²) was used as a jig to align the brackets and ensure that they were bonded in a neutral position, meaning they would express 0° tip and 0° torque. The sensors of the load cell were connected to the aluminum pegs via custom-made connector. This meant that the force system was being measured at the sensors and not the brackets. Force system transformations called ‘Jacobian transformations’ were used to transform the force system measured at the sensors to the bracket


interface [18]. Each load cell was in turn connected to a data acquisition card in a computer. LabVIEW (Laboratory Virtual Instrumentation Engineering Workbench), Version 7.1 platform was used for data acquisition, processing, and instrument control. The software application performed the mathematical calculations and generated real-time 3-D displays of forces and moments acting on every tooth. All the measurements were recorded on a Microsoft excel worksheet [9].

Stainless Steel archwires measuring: 0.016×0.022 and 0.019×0.025 inch² were used for this experiment. On each archwire V-bends (right and left sides) were placed, using a standardized wire bending protocol. They were placed at 11 different locations along the archwires at equal distances (further described below). The protocol consisted of:

- 1) placing a new archwire on the template archwire/graph paper to transfer one of the eleven bend positions bilaterally to the archwire (Figure 7a),
- 2) bending the archwire at the marked positions to one of three predetermined angles,
- 3) checking the measurement of the angle made by the two ends of the archwire with a protractor mounted on a glass slab/ flat surface (Figure 7b). Each V-bend position was tested in ten archwires of a particular size and bend angle.

Therefore, a total of 440 archwires were tested. All of the arch wires where procured in the maxillary arch ovoid form from Ortho Arch Company.

7A



7B




Figure 7. Standardized bending protocol: A- Transferring the bend position to the archwire from the graph paper B- Measuring the angle made by the two ends of the archwire with a protractor mounted on a flat surface.

The V-bends were placed at 11 different locations along the archwires with each successive bend at equal distances (3.7mm) from each other (Figure 8).

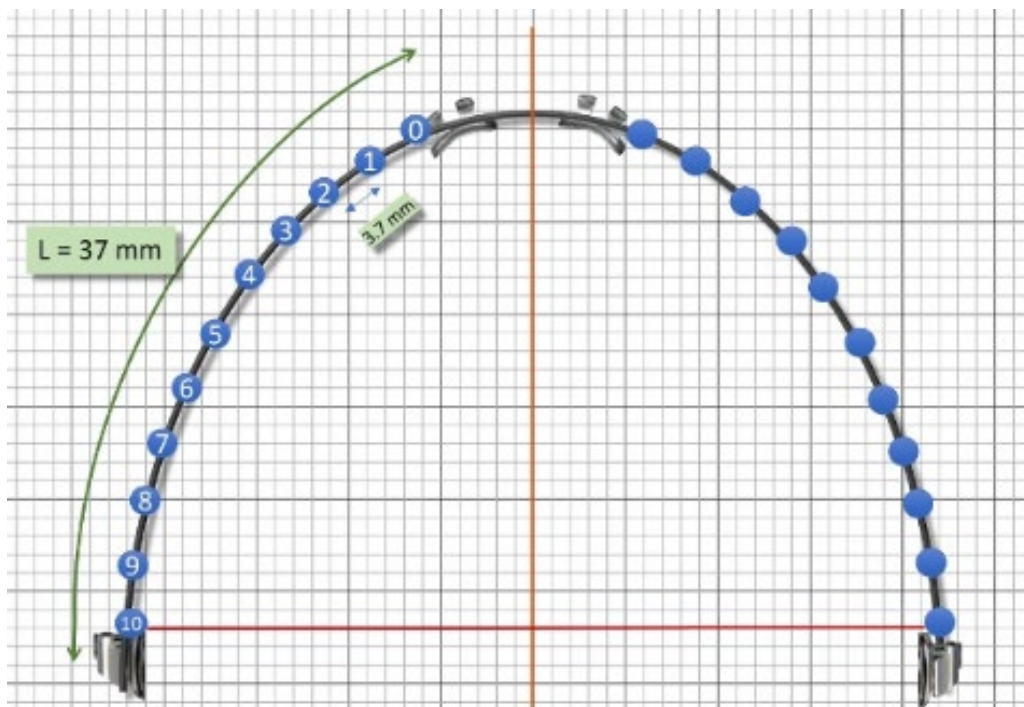


Figure 8. Each blue dot represents one of the 11 V-bend positions - the distance 'a' measured along the length 'L' of the archwire from the incisor to molar bracket.

Each bend position is represented by an a/L ratio, where 'a' is the position of the bend in relation to the incisor bracket and 'L' the distance between the mesial edge of the molar tube and the distal edge of the incisor bracket measured along the arch wire (37 mm as measured along the arch form). For example, the first bend that is immediately adjacent to the incisor bracket will have a a/L ratio of $0/37$ ($a=3.7 \times 0$) which is zero. Similarly, a bend placed at an a/L ratio of 0.3mm would be the fourth bend from the incisor at 11.1mm ($a=3.7 \times 3$) from the incisor bracket.

C. Testing

The force system measured at each sensor was represented by their three orthogonal components. F_x , F_y , and F_z represented the force components while M_x , M_y , and M_z represented the moments along the x, y and z axes, respectively. The process entailed the following steps:

1. The software program for the data is set to 'zero point.' All three force and moment values are confirmed to be imperceptible (forces < 1 g and moments < 1 g·mm).
2. The wire is engaged into the first molar and central incisor brackets, representing a 2x2 appliance. The wire is held in place using the passive self-ligation system on the central incisor brackets (Figure 9).
3. Force system recording is begun by clicking the 'start save' button on the software program. The three force and the three moment components for the particular V-bend are recorded for 10 seconds in real time for each of the two sensors.
4. Each cycle generates hundred readings over the ten second period for each component. (F_x , F_y , F_z , M_x , M_y , M_z). The wire sample is removed from the apparatus, and the computer program is stopped.
5. Steps 1-4 is repeated for each wire sample.




Figure 9. Archwire engaged in the molar and central incisor brackets, held in place using the passive self-ligation system on the central incisor brackets.

D. Analysis

A coordinate system was established for each of the two-sensors that corresponded to the brackets at molar and incisor positions. As the 3-D coordinate system was assumed to be for the maxillary dental arch (Figure 5). The total force and moment experienced by each sensor at the center of the sensor

plate was represented by their three orthogonal components: F_x , F_y , and F_z and M_x , M_y , and M_z respectively. Since it is only clinically relevant to determine the force system applied at the brackets rather than the sensors, the initial measurements were converted mathematically to represent the force system at the bracket. Additionally, archwire symmetry was assumed and only the right half of the archwire was modeled. The force was measured in Newton (N) but converted into gram-force or gram (g) for convenience.

In order to obtain data that was clinically translatable, the current study defined the analysis to specifically focus on : the vertical forces at the molar (F_{zm}) and incisor brackets (F_{zi}), the second order rotation (mesio-distal tipping) at the molar bracket (M_{xm}) and the third order rotation (labio-lingual tipping) at the incisor bracket (M_{xi}). Since, moments generated in one plane have negligible effect on those generated out of plane therefore, our analysis was limited to only F_z & M_x [21]. The positive/negative sign conventions used throughout the study indicated the specific direction along each of the three axes (Table 1).

Table 1: The movements in orthodontic clinical terms in each axis. One can also see from this table that our focus was on forces and moments in Z and X axes.

F/M system	Molar(M)	Incisor(I)
$F_z (+)$	Intrusive	Intrusive
$F_z (-)$	Extrusive	Extrusive
$M_x (+)$	Mesial tip	Facial/labial tip
$M_x (-)$	Distal tip	Palatal/lingual tip

Error data

In order to calibrate the orthodontic testing machine, we used weights obtained from the International Bureau of Weights and Measurements. Different loads were applied over the z-axis of both the sensors. For weights less than 50g, the error was found to be 5%. The average error for weights from 50g to 500g was calculated to be 0.5%.

The percentage error was calculated by the following equation:

$$\% \text{ Error} = \frac{\text{Actual value} - \text{Expected value}}{\text{Expected value}} \times 100$$

As we knew the value of the weight/load those were the expected values, and the observed results detected by the testing machine were the actual values.

E. Statistical Methods

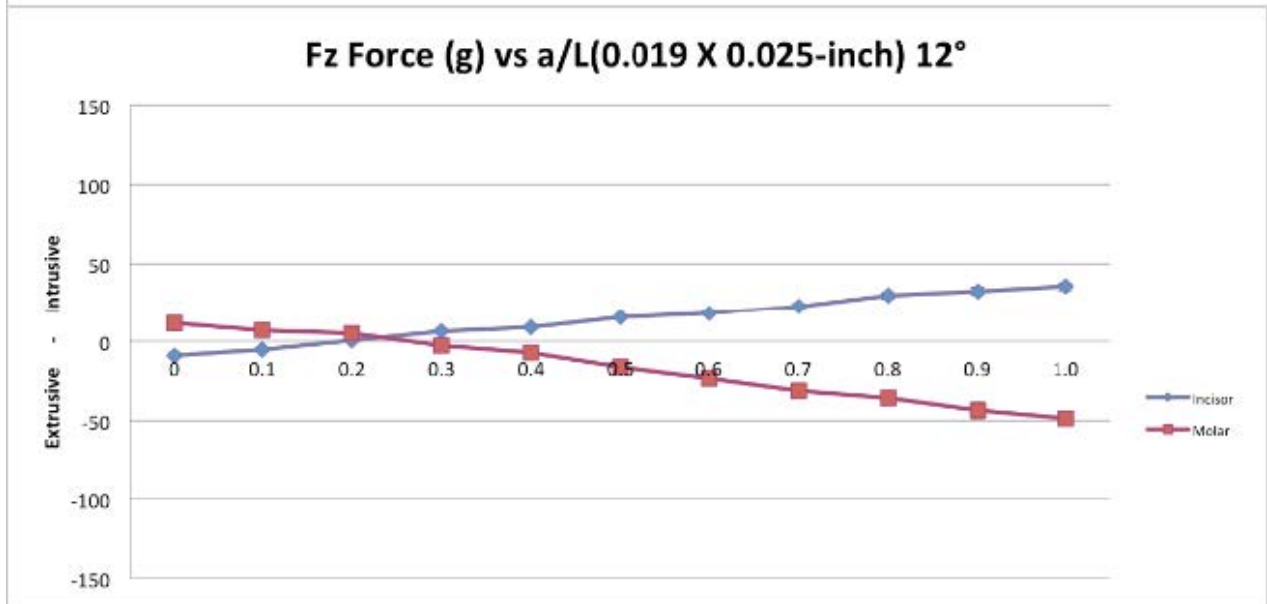
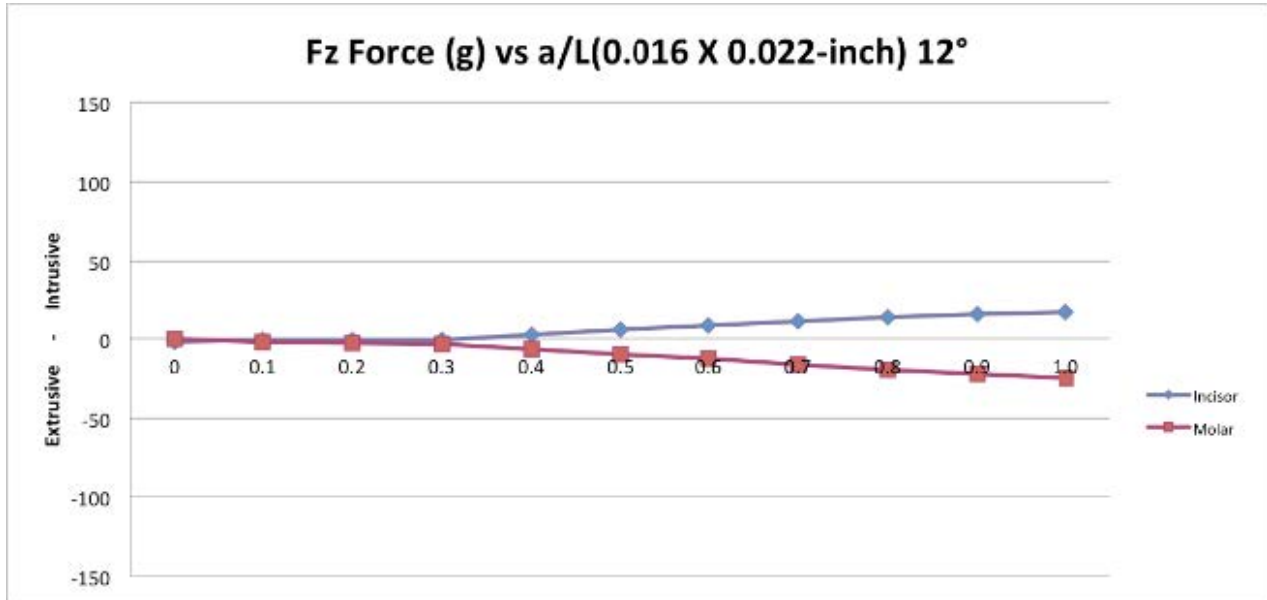
Descriptive statistics were used for this study. Statistical analyses were performed using Graph Pad Prism (GraphPad Software, Inc., La Jolla, CA). Individual statistical analyses were performed for Fz and Mx. Analyses of variance (ANOVA) were used to examine differences in the curves for the force and moment components across the four arch wires used. Each curve was considered a data set and consisted of the mean values of the force or moment component at each a/L ratio.

RESULTS

Ten samples were tested for each combination of wire specifications (wire deflection, wire dimension, and position of v-bend) to take into consideration variations caused by factors such as operator error, slight differences in wire insertion or activation, and differences in the exact position or angle of the v-bends for each wire sample. Thus, for each group of ten wire samples with the same specifications, the mean and standard deviations were calculated for each force and moment component in both coordinate systems. The data was collected over a 10 second period for each individual wire sample, thereby producing a hundred readings for each component (Fx, Fy, Fz, Mx, My, and Mz) at each sensor (incisor and molar). Within the given time period any variations in the data were minimal ($p > 0.05$). The standard deviations for the mean values were < 0.75 g for the forces and < 5 g·mm for the moments. For each set of 100 values, the mean was calculated to generate a set of twelve values (six components at two sensors) for each of the two coordinate systems. Close attention was paid to the sign convention during data collection and equilibrium of the force system was checked at every step.

A series of graphs were created from the raw data (Figures 10 & 11). The lines on the graphs are color coded to distinguish the forces and moments produced by the incisor and the molar and they are labeled with (I) or (M), respectively. The horizontal axis represents the a/L ratio and is labeled from 0 to 1.0. Each point on the graphs shown below represents the mean value of the ten wire samples in that group. For each wire size and bend angulation, there are two sets of graphs. First set of graphs are indicative of the vertical force at the molar (Fzm) and incisor brackets (Fzi) and the second set indicate the moment (mesiodistal tipping) at the molar bracket (Mxm), and moment/torque (labio-lingual tipping) at the incisor bracket (Mxi) versus the a/L ratio in relation to the individual tooth coordinate. For the purposes of clinical applicability, forces and moments in the graphs were labeled to describe the direction of tooth movement likely to occur above or below the horizontal axis, and the positive and negative signs can be ignored. The magnitude of the force or the moment is dependent on the distance of the point on the graph to the horizontal axis. When close to the horizontal axis (either above or below) it signifies a force or moment with a low magnitude, and a point farther from the horizontal axis (either above or below) signifies a force of higher magnitude. The vertical axes are labeled with the direction of tooth movement above and below the horizontal axis. Additionally, the graphs are grouped by the amount of deflection placed on the wire: 12° and 30° generating a total of 4 graphs with each representing both sizes - 0.016×0.022 inch² and 0.019×0.025 - inch² stainless steel.

10A



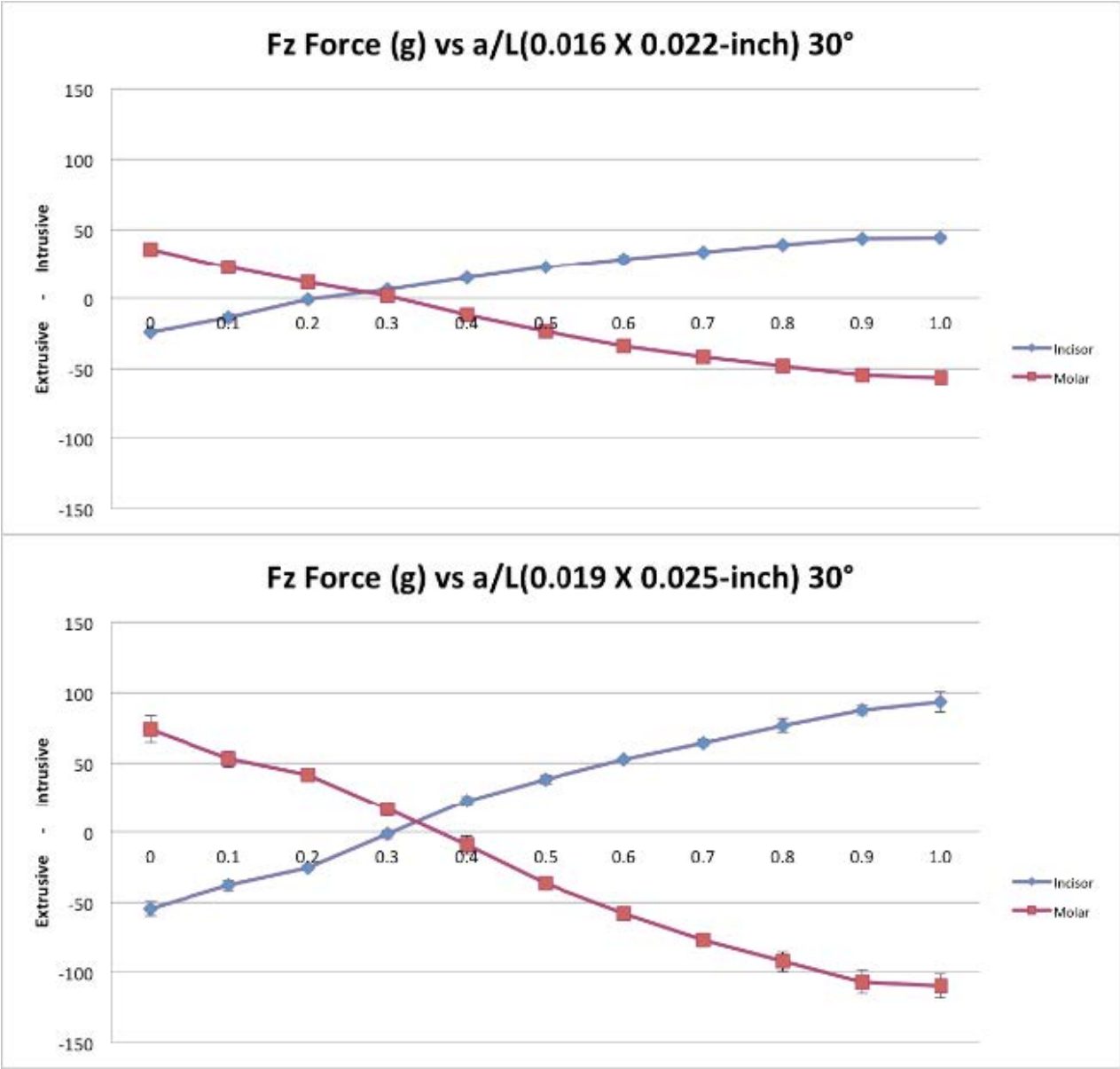


Figure 10. Graphical representation of the vertical force system (Fz) produced in the vertical plane at the molar (RED) and incisor (BLUE) brackets with. A- 12 ° bend, B-30 ° bend.

An overall comparison of the effect of archwire size on the force system showed that with increasing both the wire size and the amount of wire deflection both Fz and Mx increased at the two brackets. Thereby, quantitatively a 0.019 x 0.025 inch² SS wire bent at 30° produced the largest forces and moments for any given a/L ratio. Within each archwire type, the bends closest to the incisor produced lower magnitude of force and moment as compared to the bends at the same distance from the molar tube. Also, as the a/L ratio approached 0.2 to 0.3 there was a reduction in both the force and moment generated at the individual brackets. Analysis of the Fz (force) curves showed vertical linear symmetry

(around the horizontal axis) for the molar and incisor brackets. However, the Mx (moment) curves did not reveal a symmetrical relationship in either of the two planes that were being assessed. The Mx curve for the molar bracket was linear but asymmetric, while that of the incisor bracket was non-linear and asymmetric, and flattened off as the bend approached the molar bracket.

The alternate hypothesis was accepted. There was a difference in the Force/Moment system generated in a 3-D set up mimicking a 2x2 appliance system when compared to a 2-D set up. No symmetry was found between the force system at S1 and S2 i.e. they were not interchangeable unlike the force system found in collinear brackets. The torsional and bending moments created their own unique force systems at each bracket. The point of dissociation, point of reversal and the neutral points were not consistent with a 2-D description of the two-bracket force system.

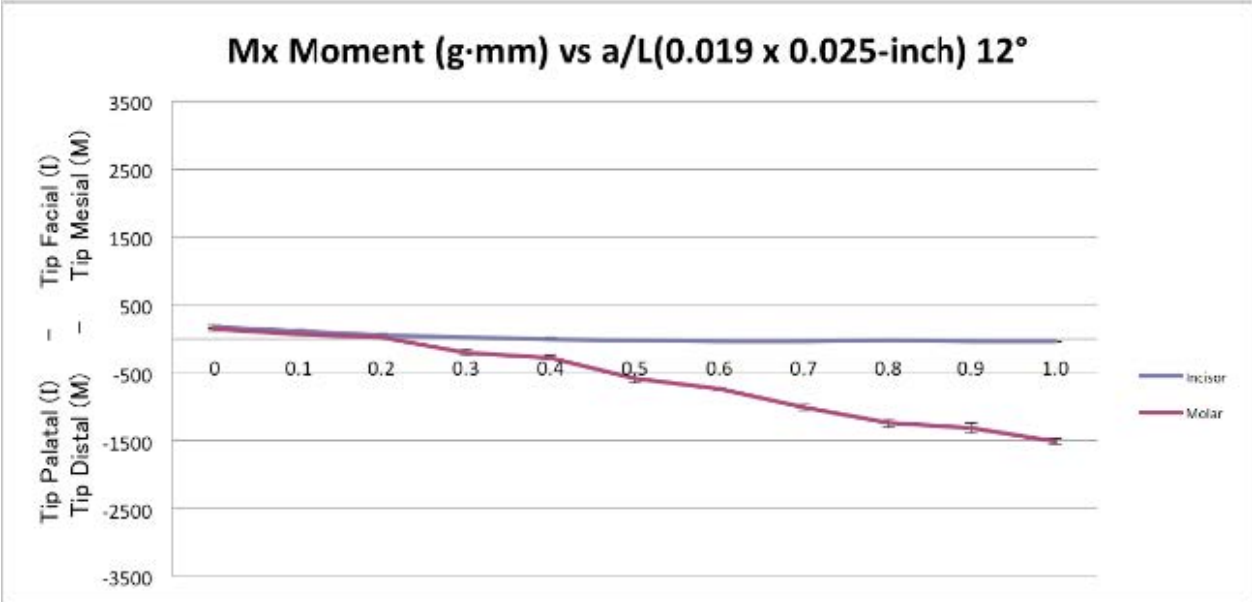
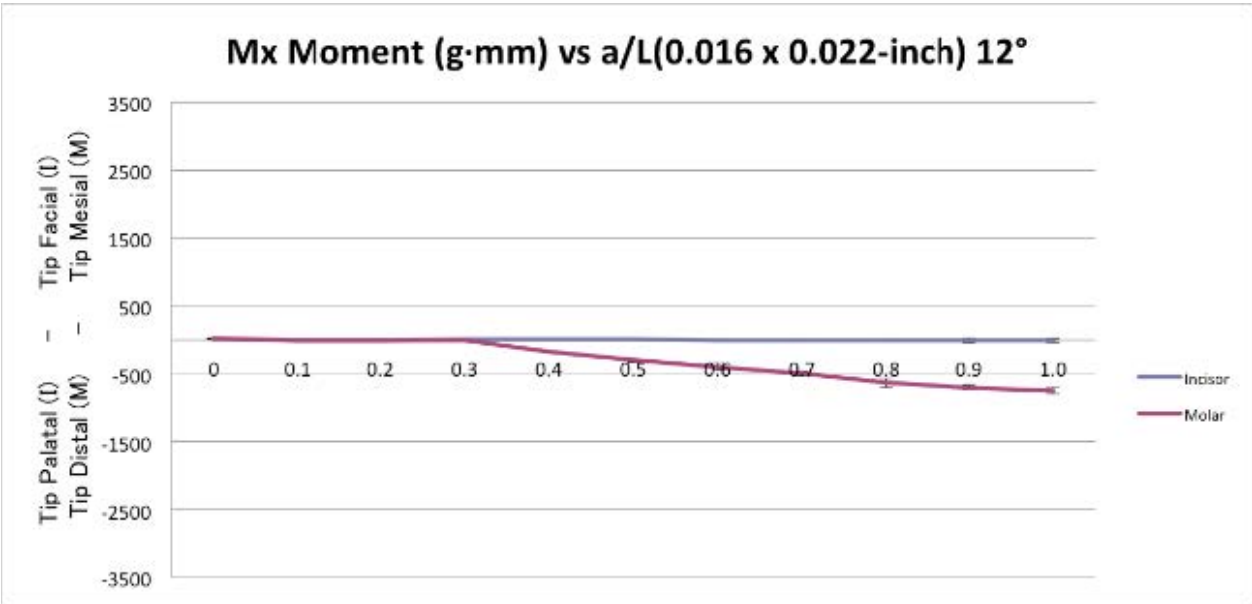
DISCUSSION

The methodology of the present study differed from the previous analyses of V-bend mechanics in many significant ways. This was an in-vitro experimental study which did not rely upon computer models or finite element-based simulations [15]. Not only bending moments (second order wire bracket interactions) but also torsional moments (third order interactions) were analyzed at the two brackets. No boundary conditions were imposed [9]. V-bends were placed on two different dimensions of stainless-steel wires at eleven points along the incisor-molar span at three deflection angles to simulate clinically reality.

The data from the current study diverged significantly when compared to previous evaluations. This occurred due to the 3-D nature of the current set-up compared to the perfectly symmetrical and uniplanar set up used previously [5-8]. Two similar brackets in the same plane will produce a perfectly balanced and symmetrical force system with a bend placed in the middle (Figure 1a). However, the current set up did not create any symmetry. The results were skewed. The archwire interacted with the molar bracket in the second order and with the incisor in the third order, producing asymmetrical critical contact angles. By recognizing the fact that when an archwire establishes contact with the opposite ends of a bracket, critical contact angle is established, which is crucial for creating a moment due to a couple. The multi-planar nature of the dental arch is primarily responsible for the asymmetrical nature of the force system between the two brackets.

A broad observation of all the data makes it immediately obvious that the change in position of the V-bend in both archwire dimensions and both small and large deflection angles, produces a distinctive pattern (Figures 10 & 11). Focusing on the pattern of the force graphs (Fz) one can readily observe the cross-spread of the red (molar) and the blue (incisor) lines. The Fz (intrusive/ extrusive force) increases both at the incisor bracket (Fzi) and the molar bracket (Fzm) as the bend moves towards the molar bracket ($a/L > 0.3$). This is due to the larger couple produced at the molar bracket as the angle of entry of the archwire in the molar tube is greater than for the incisor bracket. On the other hand, as the V-bend approaches the incisor bracket ($a/L \leq 0.3$), vertical forces (Fzi and Fzm) decrease and approach zero. In large deflections placed on stiffer wires a similar crossover occurs with reversal of Fz, however the magnitude is bigger. The observed pattern is indicative of a force system that lacks symmetry and is skewed (Figure 10).

11A



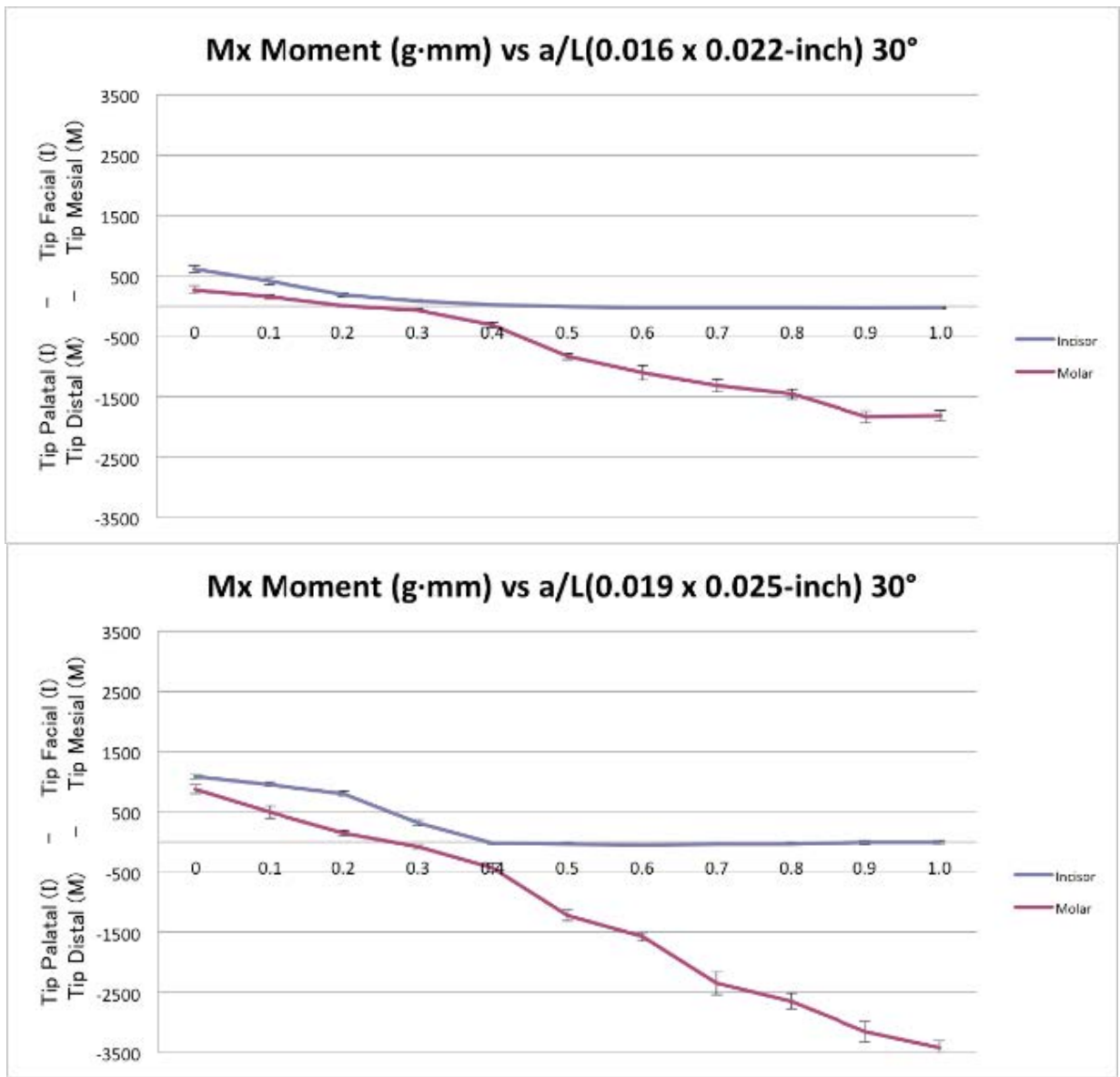
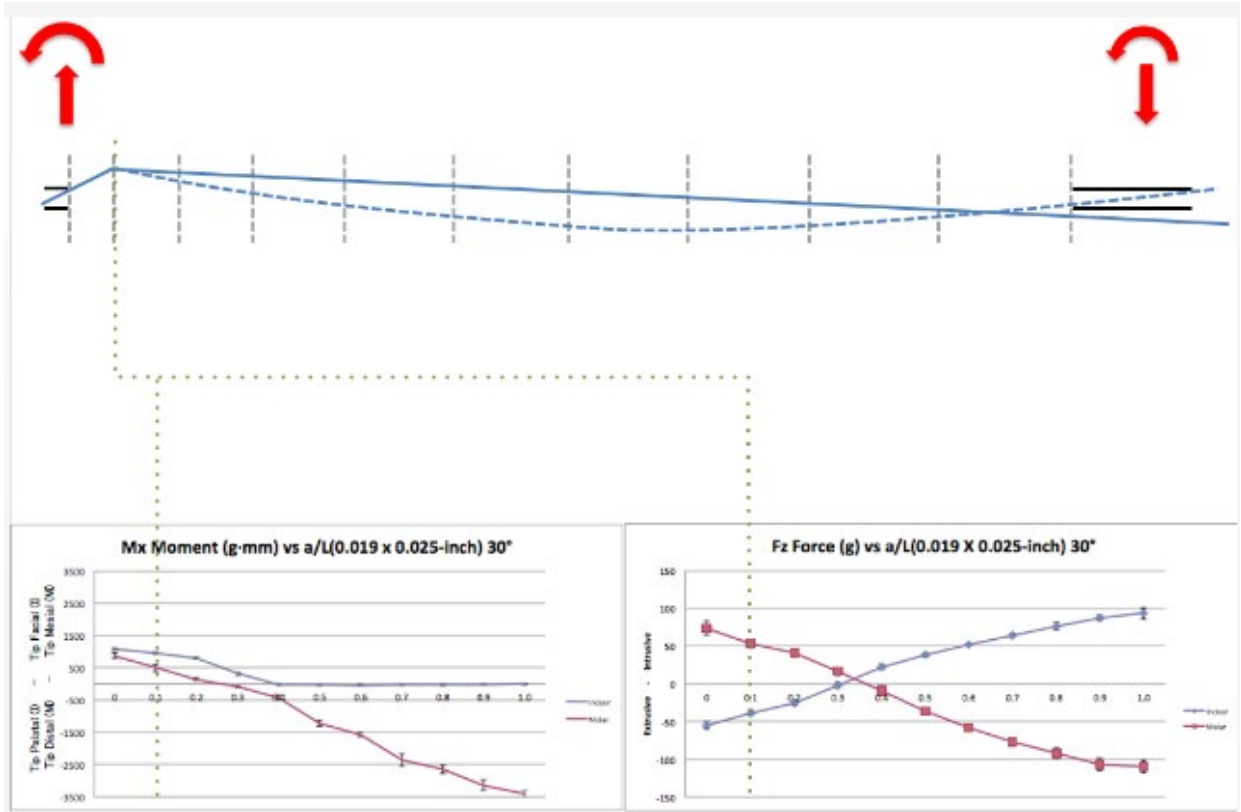


Figure 11. Graphical representation of the moments produced in the transverse plane (Mx) at the molar (RED) and incisor (Blue) brackets with. A- 12 ° bend, B-30 ° bend.

The interpretation of the moment graphs again reflects the non-linear and asymmetric nature of our results when compared with previous data. When the V-bend approximates the incisor bracket ($a/L < 0.3$) the moment (M_{xi}) increases while it decreases at the molar bracket (M_{xm}) (Figure 11). At an a/L of 0.2-0.35 (based on the wire dimension and bend angle) a point of dissociation for the molar ($M_{xm} \approx 0$) is obtained. As the a/L ratio decreases further i.e. the bend moves closer to the incisor bracket, a reversal in the direction of M_{xm} is observed. M_{xm} and M_{xi} are now in the same direction. The reversal of moment

at the molar bracket is a result of the bending properties of the wire in the second order. Bending close to the incisor bracket causes the wire to reverse its direction of curvature as it enters the molar tube (Figure 12).

12A



12B


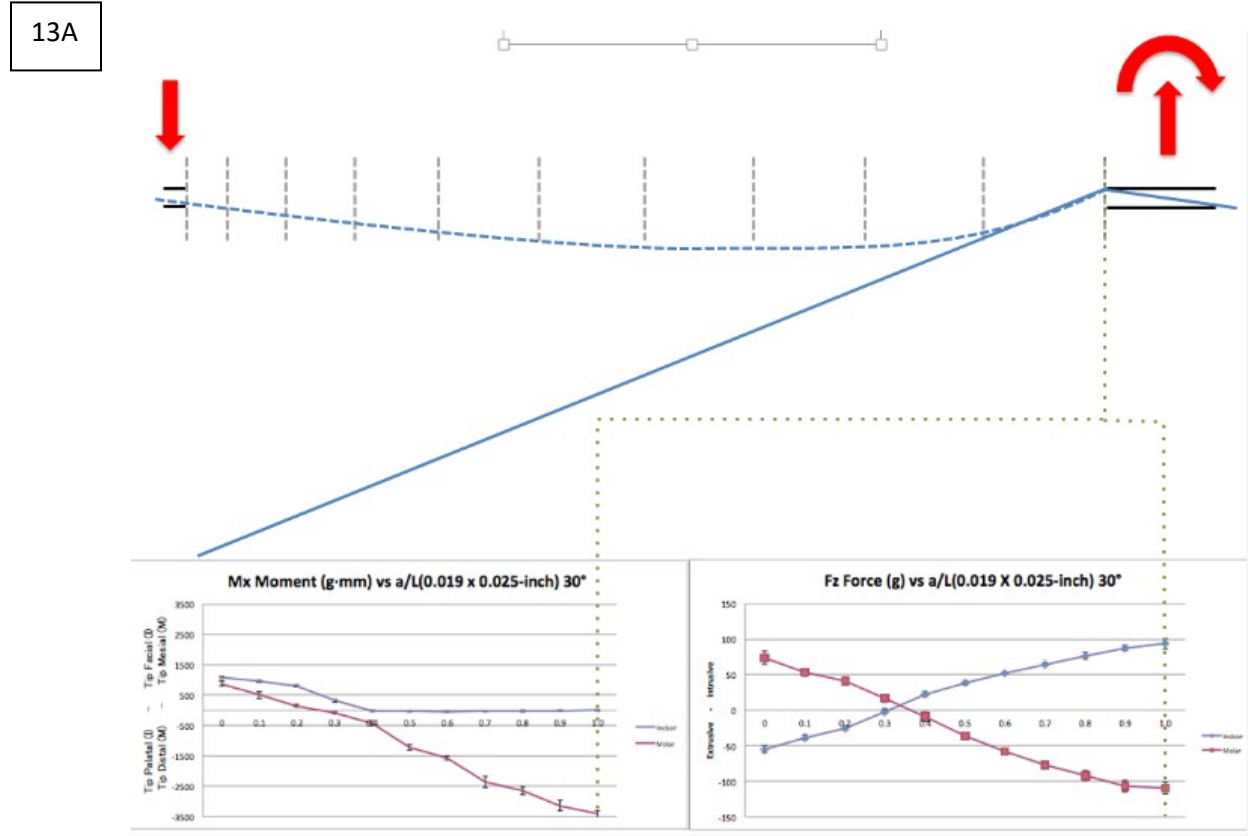


Figure 12. Reversal of the moment (M_{xm}) direction at the molar bracket. A-Schematic representation of the reversal of M_{xm} when the bend position is close to the incisor bracket. B- High-resolution image of the of the archwire-bracket interaction.

Although the reversal of the moment has been observed in previous studies, the divergence of the current results can be found by observing the magnitude of the moments. As the V-bend approaches

the incisor bracket ($a/L < 0.3$) the magnitude of M_{xm} becomes equivalent to M_{xi} . In fact, in the stiffer archwire (0.019 x 0.025 inch² SS), M_{xm} exceeded M_{xi} , which was in contrast with the 2-D models, in which M_{xi} should have been greater than M_{xm} because the bend was closer to the incisor bracket. The explanation for this lies in the fact that moments created at either bracket are a function of the couple forces at the edges of the bracket slot and the distance between them. As elucidated both visually and mathematically (Figs 3 & 4) due to the orientation of the brackets, the molar tube creates a two-point contact more efficiently as compared to the incisor (bracket length \gg bracket depth). This precludes the incisor bracket from having a larger moment unless the bend is placed sufficiently close to it so that the couple forces are very high, partially compensating for the lack of distance between them.

As the V-bend is moved slightly away from the incisor bracket, at an a/L of 0.3-0.4 the neutral point is established. Here both M_{xi} and M_{xm} are equal in magnitude and opposite in direction (Figure 13 a-c). Though observed in both archwire sizes, it is clearly discernable with the 0.019 x 0.025-inch² SS at the 30° bend angle. The location of the neutral point further highlights the asymmetry observed in the 3-D set up as opposed to the previous renderings of a similar set up. The equal and opposite moments in such a set up are only created when the bend is moved closer to the incisor bracket so that the wire is able to engage the edges of the incisor bracket in the third order and generate a moment opposite in sense to that on the molar bracket. Interestingly, a projection of the 3-D two-bracket set up on a 2-D plane further exaggerates this 'off centering' of the V-bend (Figure 3). An a/L ratio of 0.4 when viewed from a buccal perspective is actually located 11.1 mm from the incisor bracket and 25.9 mm from the molar bracket.



13B




Figure 13. A-Schematic representation of the lack of two-point contact at the incisor bracket. Flattening of the moment curve (M_{xi}) when the bend is placed away from the incisor bracket. B- A high-resolution image of the experimental set up shows the archwire-bracket interaction at the incisor bracket. (Note: the lack of two-point contact to create a couple).

As the V- bend is moved progressively closer to the molar bracket ($a/L > 0.4$), the magnitude of the M_{xm} incrementally increases while M_{xi} decreases. Once the bend moves beyond a/L of 0.4 the point of dissociation for the incisor is observed i.e. M_{xi} becomes zero. However, the most significant and exceptional finding of the current study was that M_{xi} remained zero for any further changes in the a/L ratios and a point of reversal is never observed, i.e. M_{xi} never reverses in direction as predicted by the 2-D model, indicating that M_{xi} is nonlinear, flattening out and remaining close to 0 g.mm through a/L of 0.4–1 (Figure 13).[6] To summarize, the moment on the incisor decreases considerably as the bend is moved away from it, but never reverses in direction.

Clinical Relevance

The results of the current study lead to an improved understanding of the two-bracket force system in the 3-D plane of space. This in turn, lends itself to revised clinical applicability. In summary, three distinct F/M systems can be identified that have direct and appreciable clinical ramifications (Figure 14):

1. **Type I** (pink zone): Bends placed at an a/L of 0.4 or greater will create a very small moment at the incisor and a relatively large moment at the molar tube ($M_{xi}/M_{xm} \approx 0$). Clinically, this can be interpreted as, any bend placed as far as 25 mm mesial to the molar bracket will not produce any significant moment due to couple at the incisor bracket for the purpose of torque control. Clinical translation of Type I mechanics is depicted in Figure 15.

2. **Type II** (blue zone): Bends placed at an a/L of 0.25 to 0.4 (depending on wire size and bend angulation) will show moments of low magnitude but opposite in direction ($M_{xi} / M_{xm} < 0$). Clinically, this translates into placing a V-bend closer to the incisor bracket in order to obtain equal and opposite moments. Most preformed Curve of Spee (COS) wires function on the principle of Type II mechanics.

3. **Type III** (green zone): Bends placed at an a/L ratio of 0.0 to 0.3 i.e a V-bend very close to the incisor bracket. This produces moments in the same direction ($M_{xi} / M_{xm} > 0$). This position of V-bend could be used for maintaining incisor torque control or flaring of the incisors. It can also prove effective for molar protraction. Clinical translation of Type III mechanics is seen in Figure 16.

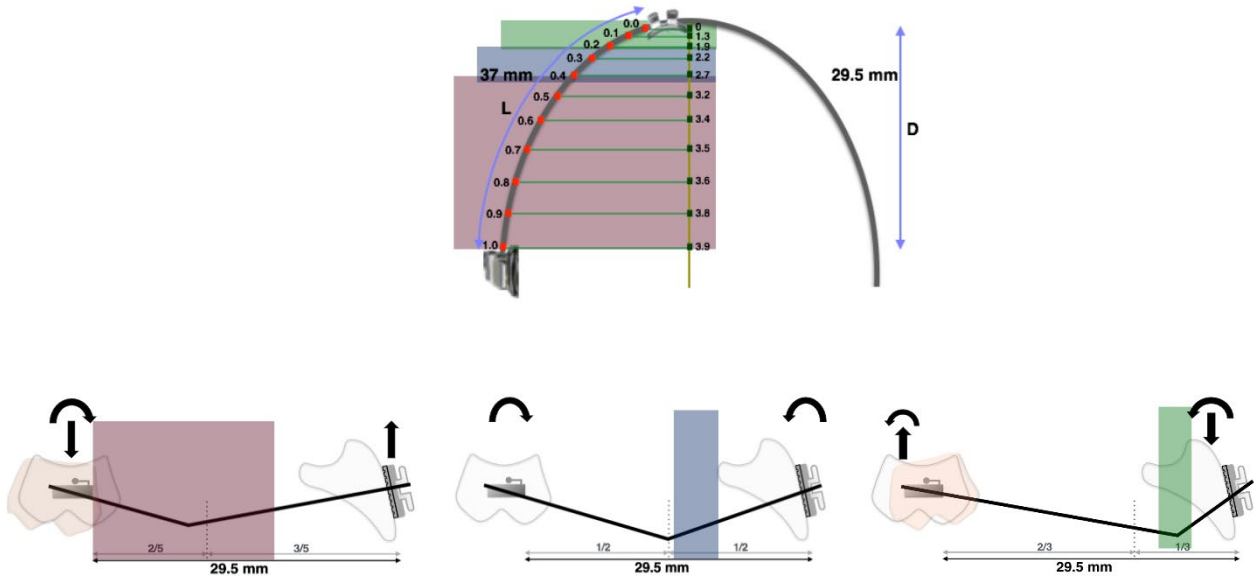


Figure 14. The force system from a V-bend can be divided into 3 zones. Type 1) Pink Zone: no moment is created at the incisor bracket. Type 2) Blue zone: the moments are equal and opposite moments at the two brackets. Type 3) Green zone: the moment at the incisor and molar are in the same direction.

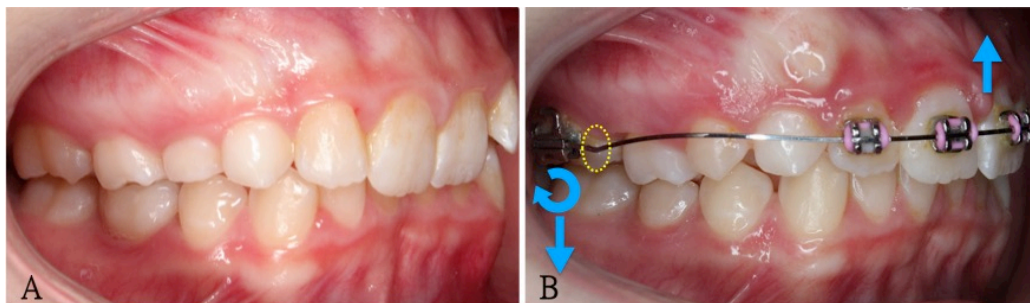


Figure 15. Type I mechanics- A) Patient with a Class II (end-on) molar relation. B) V-bend placed 2-3 mm mesial to the molar tube on a 0.019 x 0.025-inch² SS archwire. A clockwise moment of a couple is created in the molar tube which tips the molar back to a Class I relation. The incisor brackets experience an intrusive force only with no moment of a couple.

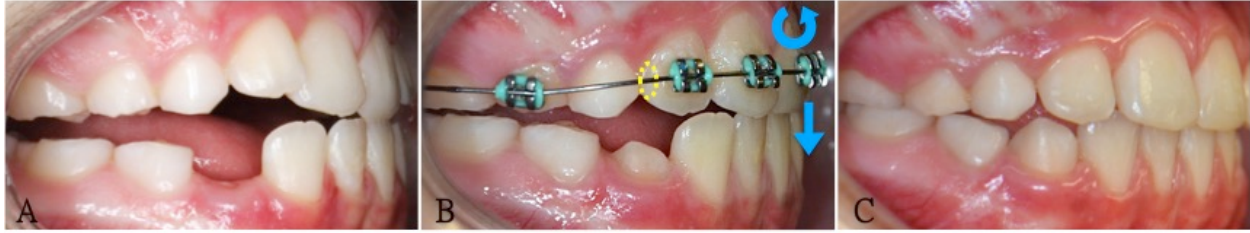


Figure 16. Type III mechanics- A) A patient with an edge to edge bite in centric relation. B) V-bend placed 2-3 mm distal to incisor brackets on a 0.017 x 0.025-inch² SS archwire. A counter-clockwise moment of a couple and occlusal force in the incisor brackets. C) This results in flaring and extrusion of the incisors resulting in a normal overjet and overbite.

CONCLUSIONS

The force system obtained by the analysis of the 3-D in-vitro model was significantly different from previous 2-D interpretations of the same. The overall pattern of the force system created by varying the degree of deflection was similar between the different stainless steel archwire sizes. Changing both the archwire size and the amount of deflection produced significant differences in the magnitude of the force system produced. vertical forces were symmetrical and linear in nature, but moments were not. The torsional (third order) and bending (second order) moments created their own unique force systems at each bracket. A new model for a two-bracket force system has been established which might have significant clinical applications.

APPENDIX

The conditions of coplanar (one plane) equilibrium state that sum of all the forces and moments in any plane are zero. The two-bracket set up described should therefore satisfy the conditions of equilibrium. Here, the assumption is that the arch is symmetrical; therefore, the force system is symmetrical between the right and left sides.

A) Solving for the forces in the vertical axis (z):

$$\Sigma \vec{Fz} = 0.$$

$$\text{Also, } \Sigma \vec{Fz} = \vec{Fz}_{(m)} + \vec{Fz}_{(i)}$$

$$\text{Or, } -\vec{Fz}_{(m)} = \vec{Fz}_{(i)}$$

$$\vec{Fz}_{(i)} / \vec{Fz}_{(m)} = -1$$

Here, $\vec{Fz}_{(m)}$ and $\vec{Fz}_{(i)}$ are vertical forces on the molar and incisor brackets respectively.

B) Solving for the moments around the transverse axis (x):

$$\Sigma \vec{Mx} = 0$$

$$\text{Also, } \Sigma \vec{Mx} = \vec{Mx}_{(m)} + \vec{Mx}_{(i)} + \vec{Fz}_{(m)} \text{ or } \vec{Fz}_{(i)} \times D \text{ (Interbracket distance = 29.5 mm)}$$

$$\text{Or, } |\vec{Mx}_{(m)} + \vec{Mx}_{(i)}| = |\vec{Fz}_{(m)} \text{ or } \vec{Fz}_{(i)} \times D|$$

Here, $\vec{Mx}_{(m)}$ and $\vec{Mx}_{(i)}$ are the moments of couple at the molar and incisor brackets around the transverse axis.

Please note that $M_{x(i)}$ and $M_{x(m)}$ are two unequal couples. Therefore, the entire system will tend to rotate in one direction. To maintain equilibrium an additional pair of equal and opposite forces is oriented to rotate the whole system in an equal and opposite direction given by the equation: $\vec{Fz}_{(m)}$ or $\vec{Fz}_{(i)} \times D$.

ACKNOWLEDGEMENTS

This research was made possible by collaboration with Bioengineering Department at Uconn Health. We also would like to thank the American Association of Orthodontists Foundation for supporting this research.

REFERENCES

1. Isaacson RJ, Lindauer SJ, Davidovitch M. The ground rules for arch wire design. *Semin Orthod* 1995; 1(1):3-11.
2. Demange C. Equilibrium situations in bend force systems. *Am J Orthod Dentofacial Orthop* 1990; 98(4):333-339.
3. Iwasaki LR, Crouch LD, Tutor A, Gibson S, Hukmani N, Marx DB, et al. Tooth movement and cytokines in gingival crevicular fluid and whole blood in growing and adult subjects. *American Journal of Orthodontics and Dentofacial Orthopedics: Official Publication of the American Association of Orthodontists, its constituent societies, and the American Board of Orthodontics* 2005; 128(4):483-491.
4. Madhur U, Nanda R. Biomechanics in Orthodontics. In: *Esthetics and Biomechanics in Orthodontics*, 2nd Edition. Elsevier 2015;74-89.
5. Burstone CJ, Koenig HA. Force systems from an ideal arch. *Am J Orthod* 1974; 65(3):270-289.
6. Burstone CJ, Koenig HA. Creative wire bending--the force system from step and V bends. *Am J Orthod Dentofacial Orthop* 1988; 93(1):59-67.
7. Koenig HA, Burstone CJ. Force systems from an ideal arch--large deflection considerations. *Angle Orthod* 1989; 59(1):11-16.
8. Ronay F, Kleinert W, Melsen B, Burstone CJ. Force system developed by V bends in an elastic orthodontic wire. *Am J Orthod Dentofacial Orthop* 1989; 96(4):295-301.
9. Upadhyay M, Shah R, Peterson D, Asaki T, Yadav S, Agarwal S. Force system generated by elastic archwires with vertical V bends: a three-dimensional analysis. *Eur J Orthod* 2017; 39(2):202-208.
10. Mulligan TF. Common sense mechanics. *J Clin Orthod* 1979; 13(10):676-683.
11. Nasiopoulos AT, Taft L, Greenberg SN. A cephalometric study of Class II, division 1 treatment using differential torque mechanics. *Am J Orthod Dentofacial Orthop* 1992; 101(3):276-280.
12. Siatkowski RE. Force system analysis of V-bend sliding mechanics. *J Clin Orthod* 1994; 28(9):539-546.
13. Willmot DR. The anchorage bend in the Begg technique. *Br J Orthod* 1983; 10(3):128-133.
14. Davidovitch M, Rebellato J. Two-couple orthodontic appliance systems utility arches: a two-couple intrusion arch. *Semin Orthod* 1995; 1(1):25-30.
15. Isacson RJ, Lindauer SJ, Conley P. Responses of 3-dimensional arch wires to vertical v-bends: comparisons with existing 2-dimensional data in the lateral view. *Semin Orthod* 1995; 1(1):57-63.
16. Kusy RP, Whitley JQ. Assessment of second-order clearances between orthodontic archwires and bracket slots via the critical contact angle for binding. *Angle Orthod* 1999; 69(1):71-80.
17. Kusy RP, Whitley JQ. Influence of archwire and bracket dimensions on sliding mechanics: derivations

- and determinations of the critical contact angles for binding. *Eur J Orthod* 1999; 21(2):199-208.
18. Venkatesan A. Automation of orthodontic wire tester for performing three point bending tests. http://digitalcommons.uconn.edu/gs_theses/171: University of Connecticut; 2011.
 19. Badawi HM, Toogood RW, Carey JP, Heo G, Major PW. Three-dimensional orthodontic force measurements. *Am J Orthod Dentofacial Orthop* 2009; 136(4):518-528.
 20. Upadhyay M, Shah R, Agarwal S, Vishwanath M, Chen PJ, Asaki T, et al. Force System with Vertical V-Bends: A 3D In Vitro Assessment of Elastic and Rigid Rectangular Archwires. *J Vis Exp* 2018; (137).
 21. Raboud DW, Faulkner MG, Lipsett AW, Haberstock DL. Three-dimensional effects in retraction appliance design. *Am J Orthod Dentofacial Orthop* 1997; 112(4):378-392.

QUANTITATIVE SUBCHONDRAL IMAGING BIOMARKERS FOR THE DIAGNOSIS OF TMJ OSTEOARTHRITIS

*Jonas Bianchi, João Roberto Gonçalves, Antônio Carlos de Oliveira Ruellas,
Marília Yatabe, Fabiana Naomi Soki, Erika Benavides,
Beatriz Paniagua, Lucia Helena Soares Cevidanes*

ABSTRACT

The temporomandibular joint (TMJ) osteoarthritis (OA) is a degenerative musculoskeletal disease that causes pain, discomfort, loss of the masticatory function, and aesthetics problems. These clinical conditions are mainly due to the presence and maintenance of the chronic stages of the disease, and usually demanding an invasive treatment strategy, such as TMJ surgery or arthrocentesis. If the diagnosis could be made earlier, the patient may benefit from it, having a conservative treatment, avoiding the TMJ OA progression. However, there are no such diagnostic tools to detect early stages of this disease, and the radiographic imaging criteria to confirm the presence of the degenerative joint disease is based mostly on subjective radiographic assessment findings, such as osteophytes, cysts, generalized sclerosis, and erosion. For this reason, in this chapter, we described a new approach to quantify the subchondral bone imaging biomarkers, also known as radiomics, from high-resolution cone-beam computed tomography.

KEY WORDS: Cone-beam Computed Tomography, Osteoarthritis, Temporomandibular Joint, Biomarkers

INTRODUCTION

Osteoarthritis (OA) is the most common musculoskeletal degenerative disease and affects more than 25% of the population over 18 years old [1]. The classic signals and symptoms include chronic inflammation leading to cartilage loss, joint destruction, and loss of function, getting worse with the aging process [2]. Also, there is bone remodeling occurring in different phases of the OA, causing severe bone resorption, atypical bone apposition (osteophytes), and sclerosis caused by the recurrent inflammation in the musculoskeletal tissues (Figure 1).

In the dental field, the term temporomandibular disorders (TMD) is used to describe different clinical conditions that affect the mastication musculature, joints, and adjacent structures [3]. Among those, temporomandibular joint (TMJ) osteoarthritis is a degenerative musculoskeletal inflammatory disease that can cause pain and affects the quality of life of the patients [4]. However, in the disease's initial stages, there are no confirmatory clinical signs/symptoms, and there are no radiographic variations in the mandibular condyle shape when seen in the CBCT slices. On the other hand, in the late stages of the disease, the clinical symptoms and signs are more accentuated, and the diagnosis can be confirmed by the radiographic changes in the mandibular condyle shape visualized through the CBCT assessment (Figure 2) [5]. The big challenge seems to be to diagnose the TMJ OA before those most significant bone changes occur.

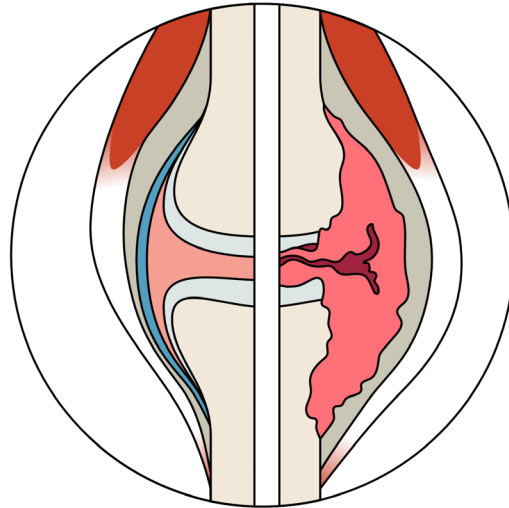


Figure 1. Normal and osteoarthritic knee joints. On the left, it can be observed a healthy joint, and in the right, a joint with a chronic inflammation process, leading to bone modulation and remodeling.

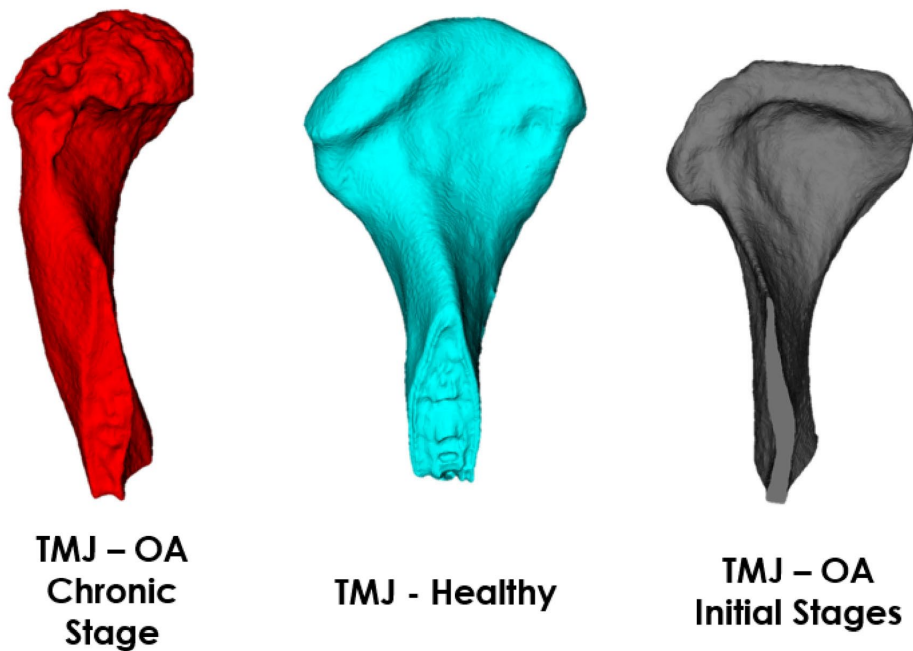


Figure 2. 3D reconstruction of TMJ Condyles: Healthy, with TMJ OA in chronic and initial stages. In red color, a mandibular condyle in chronic stages is shown (severe bone destruction can be seen), in blue, the healthy condyle that is very similar in shape with a TMJ OA condyle in initial stages (gray color). These images show the necessity to obtain more information from the image/volume that is not only based on the surface changes to detect the TMJ OA in initial stages.

For this reason, it is necessary to combine multiple biomarkers from different sources, such as proteins, images, and clinical data, to get accurate and early disease diagnosis. The traditional radiographic assessments for the TMJ OA are based on the subjective interpretation of the cone-beam computed images (CBCT) [5, 6]. In the "big data era," the challenge now is to extract a large

amount of information from the existing medical exams and to have adequate and standardized data as well [7, 8]. In this scenario, there is an "omics revolution" occurring in the medical and dental research community. It represents the capacity of extracting a large amount of information from a single exam, providing personalized treatment and diagnostic for the patient, as well as using those data in machine learning approaches to categorizing complex diseases better, earlier, and accurately.

TMJ OSTEOARTHRITIS: TRADITIONAL DIAGNOSIS

Even with the advances in the maxillofacial radiology area, the CBCT exam is still the first modality for clinicians and researchers to assess the maxillofacial bone tissue from a 3D perspective, including the temporomandibular condyle bone changes. For the TMJ OA, this exam has been widely used for characterizing and diagnosing the disease [6, 9–11]. The Diagnostic Criteria for Temporomandibular Disorders (DC/TMD) have proposed, in addition to the clinical evaluation, the imaging criteria to diagnose the degenerative joint disease (DJD) in CBCT images; this classification considers the presence of cysts, erosions, and generalized sclerosis as determinants for TMJ - OA when the clinical symptoms and signs are also present. However, this classification was based initially on CT images, with a slice of 1 mm, suggesting that only cases with more advanced stages of the TMJ OA could be adequately classified [5]. Currently, the majority of the CBCT exams have a voxel size that varies from 0.3 to 0.5 mm³, which allows in most of the cases only a mandibular condyle surface evaluation. On the other hand, CBCT exams with high-resolution (voxel size = 0.08mm³) are becoming more available, and with this exam, it is possible to evaluate the subchondral bone as well (Figure 3); however, there is still a need to better explore those images, and the quantitative bone imaging biomarkers can be useful for this end.

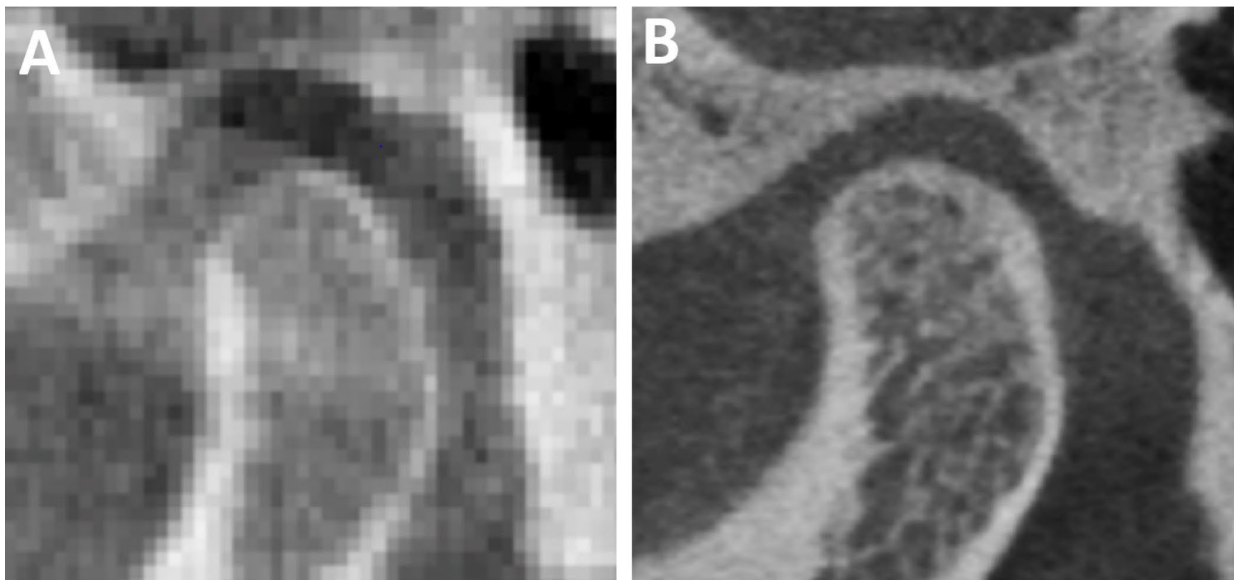


Figure 3. Example of cone-beam computed tomography of the Temporomandibular joint with different resolutions. A) Standard resolution TMJ CBCT with a 0.3 mm³ voxel size and B) High-resolution TMJ CBCT with 0.08 mm³ voxel size.

RADIOMICS APPLIED IN THE HIGH-RESOLUTION CBCT

In recent literature, the term "omics revolution" represents personalized and precision medicine, including genomics, radiomics, proteomics, etc. In the imaging area, radiomics refers to

the large amount of data extracted from images in different modalities such as computed tomography (CT), CBCT, magnetic resonance imaging (MRI), and others [12, 13]. With the recent advances in software development and algorithms implementation, different software were developed to extract radiomics information without complexity. Among the software, the Ibex , ImageJ (BoneJ plugin) , and 3D-slicer (BoneTexture plugin) can be cited as platforms used for this end (Figure 4) [14-17].

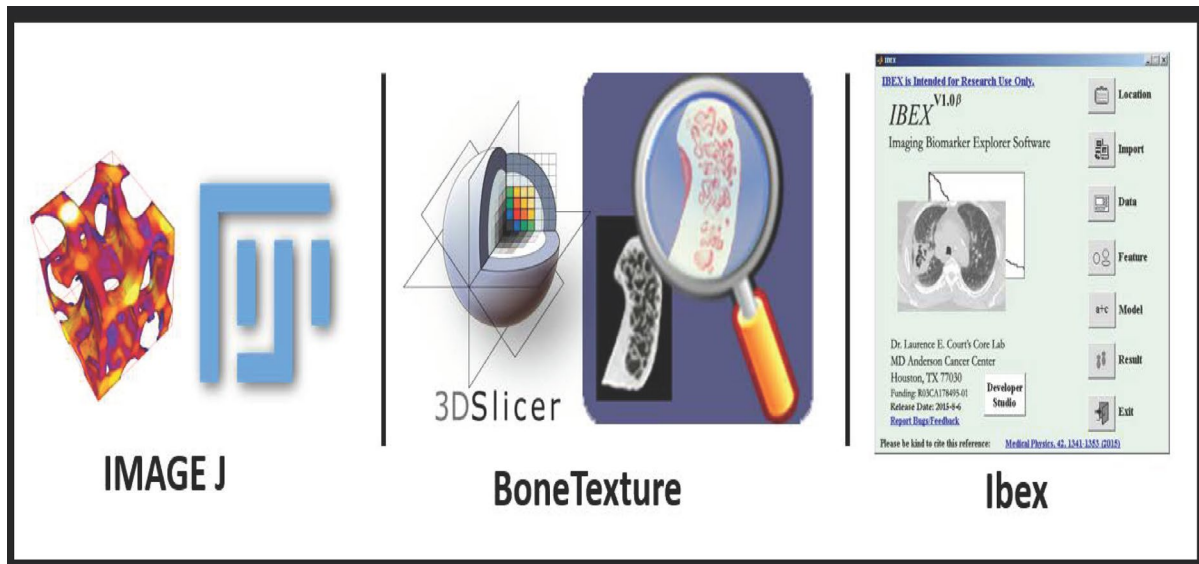


Figure 4. Software used to extract radiomics. The three software programs shown in this figure can be used to obtain (extract and quantify) bone radiomics in CBCT images.

The information that can be extracted from the image (radiomics) usually cannot be seen by the naked eye; however, it can be measured by a large number of variables that can also be called quantitative imaging biomarkers. An example of radiomics extracted from CBCT images is the Grey-level Co-occurrence Matrix (GLCM) that gives the values for the distribution of co-occurring pixel values and includes: Energy, Entropy, Correlation, Inverse Difference Moment, Inertia, Cluster Shade, Cluster Prominence, and Haralick Correlation. Another important group of variables is the Grey-level Run Length matrix (GLRM) that gives the size of homogeneous runs for each grey level and includes: Short Run Emphasis, Long Run Emphasis, Grey Level Non-Uniformity, Run Length Non-Uniformity, Low Grey Level Run Emphasis, High Grey Level Run Emphasis, Short Run Low Grey Level Emphasis, Short Run High Grey Level Emphasis, Long Run Low Grey Level Emphasis and Long Run High Grey Level Emphasis [18, 19].

TMJ OSTEOARTHRITIS: QUANTITATIVE SUBCHONDRAL IMAGING BIOMARKERS

The literature has demonstrated that the TMJ OA causes initial changes in the subchondral bone, and it has a vital role in the pathogenesis of the disease [20, 21]. For this reason, it is reasonable to assess not only the bone surface changes; but also the mandibular condyle subchondral bone changes as well. To our knowledge, only ex-vivo or in-vitro research has addressed this concern in humans. As previously explained, the imaging classification for TMJ OA is based on the surface bone changes, rather than the subchondral changes (Figure 5). With advances in technology, new machines became available to the community, and now it is possible to do TMJ

CBCT scans in patients with a high resolution of 0.08mm^3 (hr-CBCT) respecting the ALARA (as low as reasonably achievable) and ALADA (as low as diagnostically acceptable) principles [22, 23].

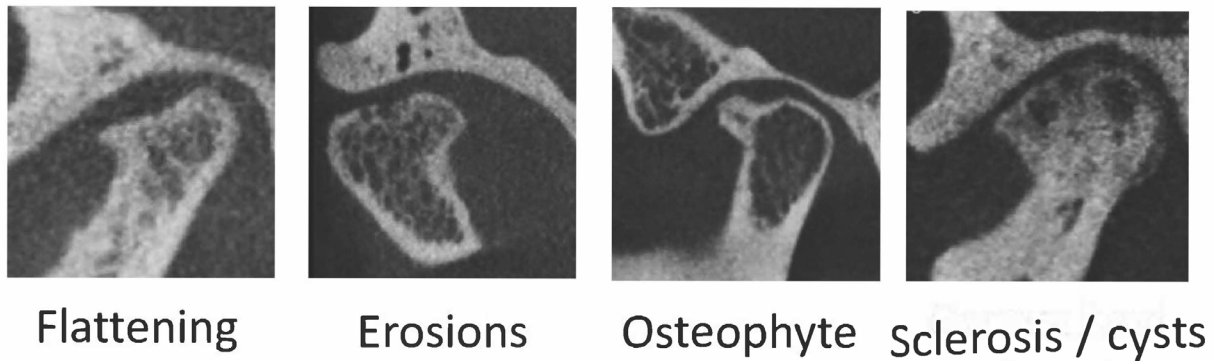


Figure 5. Temporomandibular osteoarthritis: Imaging findings. The radiographic diagnosis of conventional CBCT is based on already existing changes in the mandibular bone, such as flattening, erosions, osteophytes, generalized sclerosis, and cysts.

Figure 6 shows the necessity that researchers and clinicians have been dealing with the diagnostic of OA. Usually, the disease is diagnosed in the late stage, when it is possible to see only the radiographic imaging surface findings (Figure 5); however, with the implementation of the hr-CBCT, the subchondral information can be assessed using radiomics/textural biomarkers assessment.

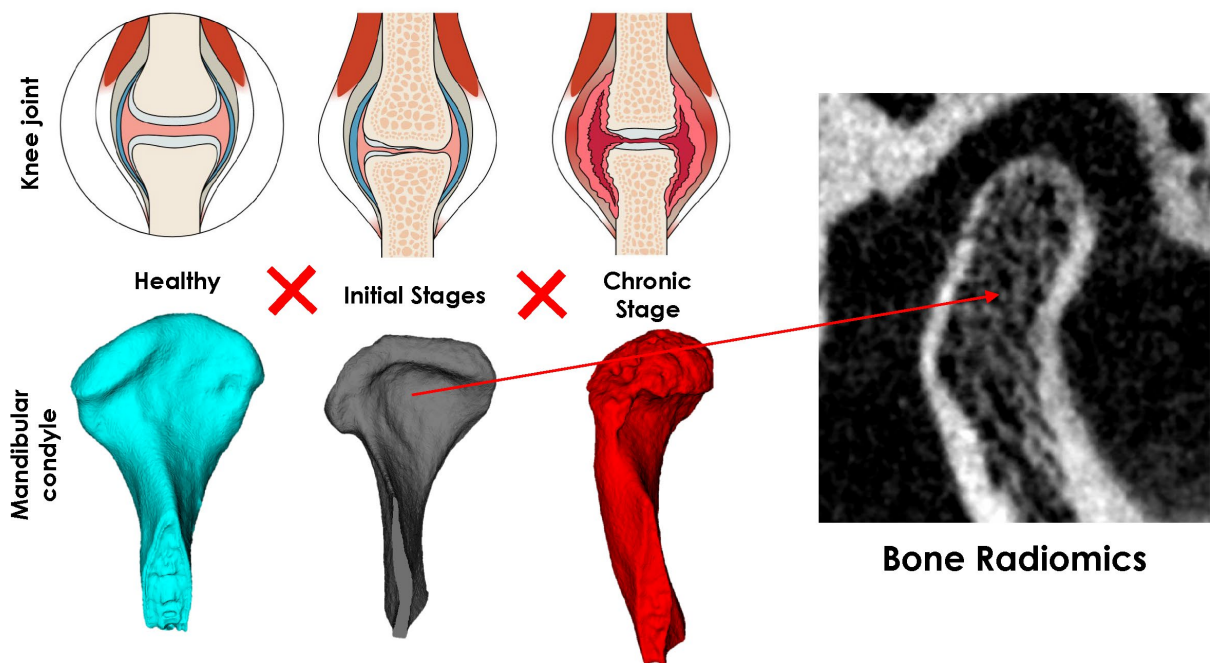


Figure 6. TMJ OA diagnosis: Subchondral information. This figure illustrates the need to obtain more data from the exams. The initial stages of the TMJ OA (gray color) cannot be diagnosed due to the absence of radiographic findings in the mandibular condyle surface; however, with the high-resolution CBCT, the subchondral bone can be assessed, and using different software is it possible to extract radiomics and textural features from the subchondral bone.

It is also essential to highlight that the process to extract quantitative subchondral imaging biomarkers in the temporomandibular condyles demands a detailed protocol, described by Bianchi et al. [17]. Figure 7 demonstrates the basic workflow to extract this information from the subchondral bone.

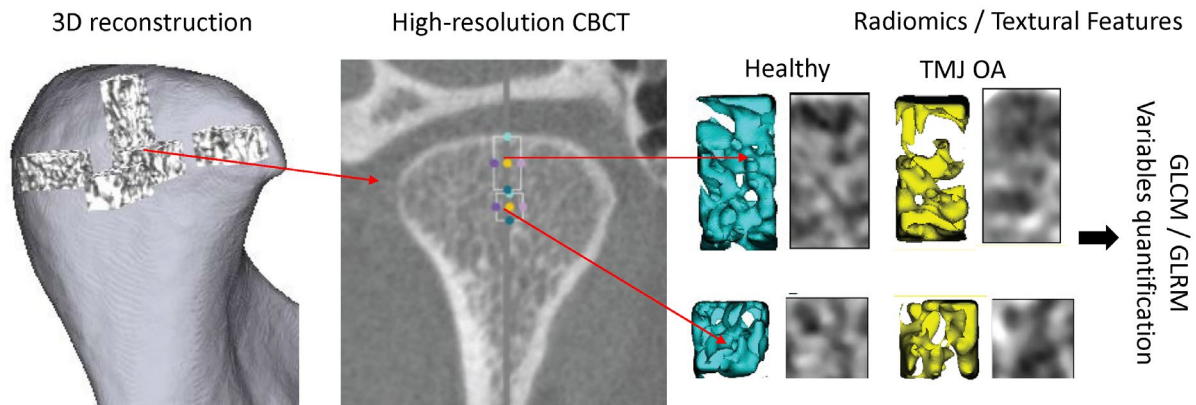


Figure 7. TMJ OA diagnosis: Subchondral quantification. This figure shows the process involved in extracting the subchondral region of interest. Here, you can see a central and superior region of the mandibular condyle being extract to further quantification of the bone radiomics in the software 3D-Slicer, module BoneTexture [17]. The GLCM and GLRLM represent a group of 23 different imaging biomarker variables corresponding to the gray level organization of the mandibular condyle subchondral bone.

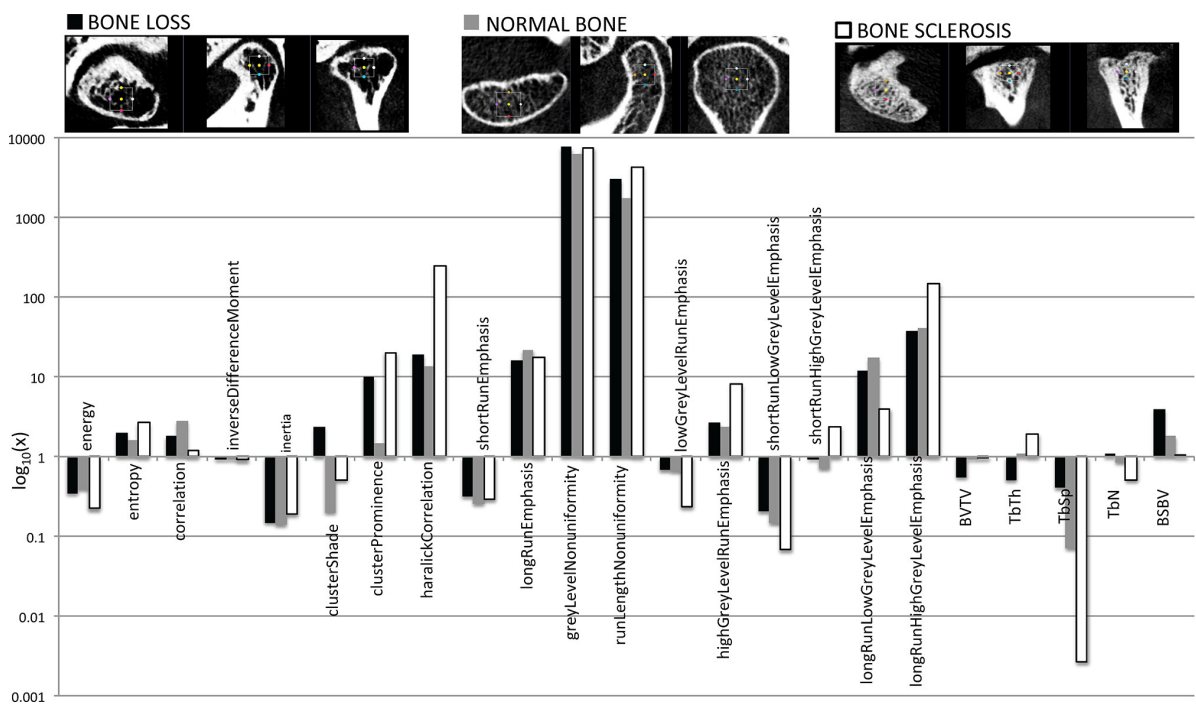


Figure 8. Quantitative subchondral imaging biomarkers. This figure shows the applicability and behavior of each one of the imaging biomarkers in different mandibular condyles conditions [17].

In addition, Figure 8 illustrates the clinical applicability of the radiomics (radiographic quantitative imaging biomarkers) for the characterization of the mandibular condyles. It can be noted that the variables change their values according to the trabecular bone characteristics (loss, normal, or sclerosis).

A receiver operating characteristic (ROC) curve (Fig. 9) was created based on the imaging biomarkers of 51 TMJ OA patients and 43 asymptomatic subjects for detecting TMJ osteoarthritis using the radiomics variables extracted from the hr-CBCT (voxel size = 0.03mm³). It can be seen that those biomarkers have the potential to diagnose the disease status; however, additional studies are necessary in order to properly validate this tool and the imaging biomarkers with direct clinical applications.

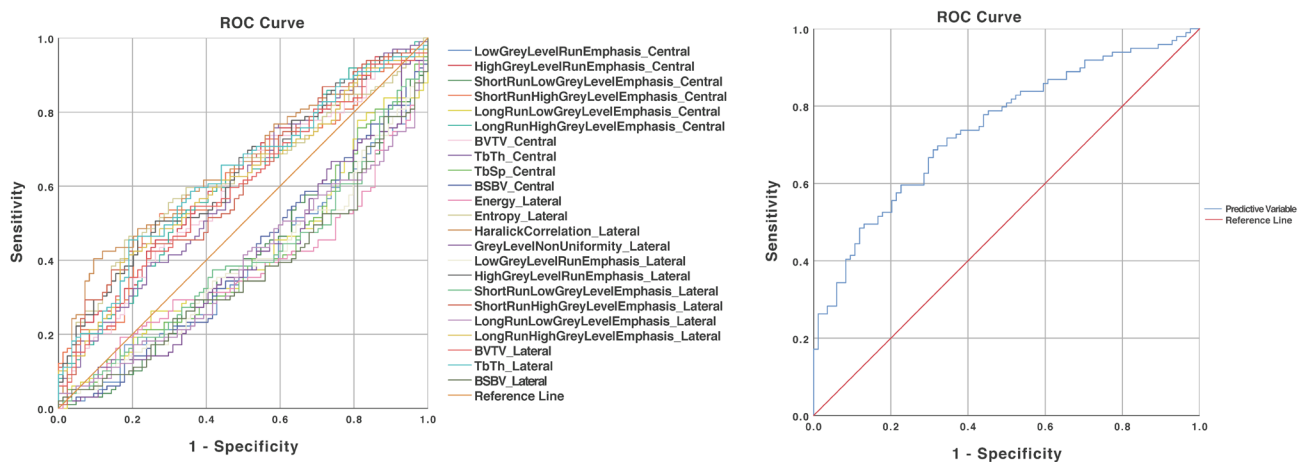


Figure 9. Receiver Operating Characteristic (ROC) curves for detecting osteoarthritis using the imaging variables. A) The lines above the main diagonal represent that the state value (OA Group) will increase as the test variable decreases, and the lines under the main diagonal represent that the state value (OA Group) will decrease as the test variable decreases. B) The ROC curve for the predictive variable created through binary logistic regression combining all the variables. The Area Under the Curve (AUC) was 0.74 (95% CI were 0.67 to 0.82).

CONCLUSIONS

In conclusion, in the initial stages of the TMJ OA, most patients may not present the typical radiographic findings found in the chronic stages of the disease. For this reason, the hr-CBCT with a localized field of view of the TMJs can generate data with greater details and quality, allowing the examiner to see more information, including the subchondral bone radiographic aspects and characteristics. To quantify the trabecular bone, the radiomics concept can be applied, and using software such as the 3D-Slicer and BoneTexture extension it is possible for the user to extract useful and quantitative imaging biomarkers information for each patient. The personalized medicine and big data is an emergent topic, and those quantitative imaging biomarkers can help to improve the TMJ OA diagnosis in integration with multi-source biomarkers and machine learning algorithms (Figure 10).

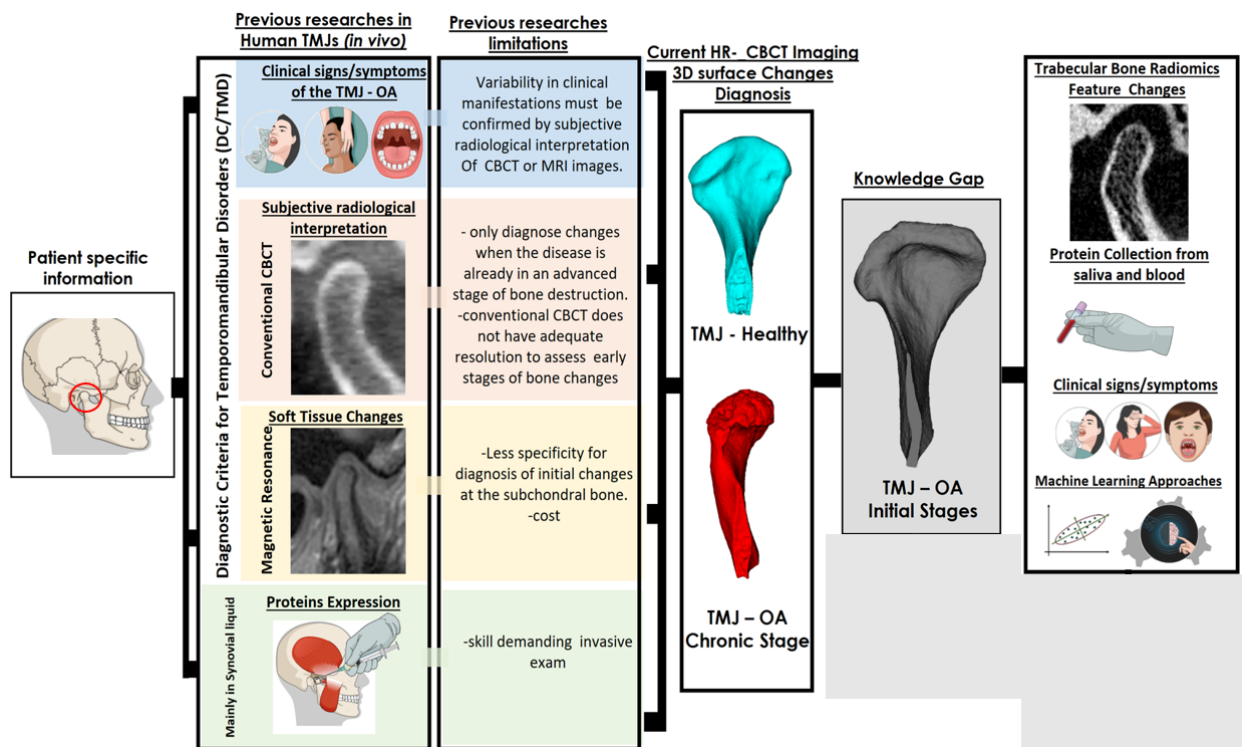


Figure 10. Future perspectives integrating multi-source biomarkers.

ACKNOWLEDGEMENTS

This research was supported by NIH grants DE R01DE024450 and R21DE025306.

REFERENCES

1. Arden N, Nevitt MC. Osteoarthritis: Epidemiology. *Best Pract Res Clin Rheumatol* 2006;20:3–25.
2. Rousseau J-C, Delmas PD. Biological markers in osteoarthritis. *Nat Clin Pract Rheumatol* 2007;3:346–56.
3. Wadhwa S, Kapila S. TMJ disorders: future innovations in diagnostics and therapeutics. *J Dent Educ* 2008;72:930–47.
4. Mercuri LG. Osteoarthritis, Osteoarthrosis, and Idiopathic Condylar Resorption. *Oral Maxillofac Surg Clin North Am* 2008;20:169–83.
5. Schiffman E, Ohrbach R, Truelove E, Look J, Anderson G, Goulet J-P, et al. Diagnostic Criteria for Temporomandibular Disorders (DC/TMD) for Clinical and Research Applications: recommendations of the International RDC/TMD Consortium Network* and Orofacial Pain Special Interest Group†. *J oral facial pain headache* 2014; 28(1):6-27.
6. Larheim TA, Abrahamsson A-K, M Kristensen Arvidsson LZ. Temporomandibular Joint Imaging Using CBCT. *Dentomaxillofac Radiol* 2015;44(1):20140235.
7. Cai L, Zhu Y. The Challenges of Data Quality and Data Quality Assessment in the Big Data Era. *Data Science J* 2015;14:2.
8. Alyass A, Turcotte M, Meyre D. From big data analysis to personalized medicine for all: Challenges and opportunities. *BMC Med Genomics* 2015;8:1–12.
9. Pauwels R, Araki K, Siewerdsen JH, Thongvigitmanee SS. Technical aspects of dental CBCT:

State of the art. *Dentomaxillofacial Radiol* 2015;44:1–20.

10. Kapila SD, Nervina JM. CBCT in orthodontics: assessment of treatment outcomes and indications for its use. *Dentomaxillofac Radiol* 2014;44:20140282.
11. Tsiklakis K, Syriopoulos K, Stamatakis HC. Radiographic examination of the temporomandibular joint using cone beam computed tomography. *Dentomaxillofacial Radiol* 2004;33:196–201.
12. Lambin P, Rios-Velazquez E, Leijenaar R, Carvalho S, Van Stiphout RGPM, Granton P, et al. Radiomics: Extracting more information from medical images using advanced feature analysis. *Eur J Cancer* 2012;48:441–6.
13. Gillies RJ, Kinahan PE, Hricak H. Radiomics: Images Are More than Pictures, They Are Data. *Radiology* 2016;278:563–77.
14. Zhang L, Fried D V., Fave XJ, Hunter LA, Yang J, Court LE. Ibex: An open infrastructure software platform to facilitate collaborative work in radiomics. *Med Phys* 2015;42:1341–53.
15. Doube M, Kłosowski MM, Arganda-Carreras I, Cordelières FP, Dougherty RP, Jackson JS, et al. BoneJ: Free and extensible bone image analysis in ImageJ. *Bone* 2010;47:1076–9.
16. Vimort J-B, McCormick M, Budin F, Paniagua B. Computing Textural Feature Maps for N-Dimensional images. *Insight Journal* 2017. <http://hdl.handle.net/10380/3574>. Accessed 2 Jan 2019.
17. Bianchi J, Gonçalves JR, Ruellas AC de O, Vimort J-B, Yatabe M, Paniagua B, et al. Software comparison to analyze bone radiomics from high resolution CBCT scans of mandibular condyles. *Dentomaxillofac Radiol* 2019;20190049.
18. Valentin M, Bom C, Albuquerque M, Albuquerque M, Faria E, Correia M. Texture Classification based on Spectral Analysis and Haralick Features. *Notas Técnicas* 2016;6:28–51.
19. Haralick R, Shanmugan K, Dinstein I. Textural features for image classification. *IEEE Transactions on Systems, Man and Cybernetics* 1973;3:610–21.
20. Li G, Yin J, Gao J, Cheng TS, Pavlos NJ, Zhang C, et al. Subchondral bone in osteoarthritis: insight into risk factors and microstructural changes. *Arthritis Res Ther* 2013;15:223.
21. Bianchi J, de Oliveira Ruellas AC, Gonçalves JR, Paniagua B, Prieto JC, Styner M, et al. Osteoarthritis of the Temporomandibular Joint can be diagnosed earlier using biomarkers and machine learning. *Sci Rep* 2020;10:8012.
22. Jaju PP, Jaju SP. Cone-beam computed tomography: Time to move from ALARA to ALADA. *Imaging Sci Dent* 2015;45:263–5.
23. Editorial. ALARA still applies. *Oral Surg Oral Med Oral Pathol Oral Radiol Endod* 2005;100:395–7.

MINIMALLY INVASIVE APPROACH FOR DIAGNOSING TMJ OSTEOARTHRITIS

Brandon S. Shoukri, Juan Carlos Preito, Antonio Ruellas, Marilia Yatabe, James Sugai, Martin Styner, Hongtu Zhu, Chao Huang, Beatriz Paniagua, Sharon Aronovich, Lawrence Ashman, Erika Benavides, Priscille de Dumast, Nina Tubau Ribera, Clément Mirabel, Loïc Michoud, Zahraa Allohaibi, Marcos Ioshida, Luciana Bittencourt, Liana Fattori, Liliane Rosas Gomes, Lucia Cevidanes

ABSTRACT

This study's objectives were to test correlations among groups of biomarkers that are associated with condylar morphology and to apply artificial intelligence to test shape analysis features in a neural network (NN) to stage condylar morphology in temporomandibular joint osteoarthritis (TMJOA). TMJOA patients (N=17) experiencing signs and symptoms of the disease for less than 10 years and 17 age- and sex-matched control subjects completed a questionnaire, had a TMJ clinical exam, blood and saliva samples drawn, and high-resolution CBCT scans taken. Serum and salivary levels of 17 inflammatory biomarkers were quantified using protein microarrays. A NN was trained with 259 other condyles to detect and classify the stage of TMJOA and then compared to repeated clinical experts' classifications. Levels of the salivary biomarkers MMP-3, VE-cadherin, 6Ckine, and PAI-1 were correlated to each other in TMJOA patients and were significantly correlated with condylar morphological variability on the posterior surface of the condyle. In serum, VE-cadherin and VEGF were correlated with one another and with significant morphological variability on the anterior surface of the condyle, while MMP-3 and CXCL16 presented statistically significant associations with variability on the anterior surface, lateral pole, and superior-posterior surface of the condyle. The repeated clinician consensus classification had 97.8% agreement on degree of degeneration within 1 group difference. Predictive analytics of the NN's staging of TMJOA compared to the repeated clinicians' consensus revealed 73.5% and 91.2% accuracy. This study demonstrated significant correlations among variations in protein expression levels, clinical symptoms, and condylar surface morphology.

KEY WORDS: Temporomandibular Joint, Artificial Intelligence, Machine Learning, Cone Beam Computed Tomography, Biological Markers

INTRODUCTION

Temporomandibular joint disorders (TMD) are a major cause of orofacial pain of non-dental origin [1]. TMD is the second most commonly occurring musculoskeletal condition resulting in pain and disability

and affecting approximately 5 to 12% of the population [2]. TMD involves a wide spectrum of syndromes: myofascial pain disorder, disk derangement disorders, and osteoarthritis (OA) [1]. Joint degeneration occurs from the loss in equilibrium of anabolic and catabolic processes involving chondrocyte initiation, proliferation, differentiation, and matrix synthesis and degradation [3]. Temporomandibular joint osteoarthritis (TMJOA) was once thought to be a 'wear and tear' condition and of non-inflammatory origin. It is now classified as a "low-inflammatory arthritic condition" [4] and associated with inflammatory mediators that lead to harmful effects on the temporomandibular joint's (TMJ) cartilage, bone, and synovium [5].

Advances in the healthcare field have led the drive to utilize biological markers as diagnostic markers of OA. Collecting saliva has become a popular trend to gain real-time levels of biomarkers due to its non-invasiveness, constant availability, and cost-effectiveness [6]. Cevitanes et al. were the first to report an association between specific OA biomarkers and 3-dimensional (3D) morphological variations at specific anatomic regions on the TMJ condylar surface. Synovial fluid and serum samples were collected to measure levels of 50 biomarkers of arthritic inflammation [7].

Computerized methods are a great help to clinicians to discover hidden patterns in data. These methods often employ data mining and machine learning algorithms, lending themselves as the computer-aided diagnosis tool that assists clinicians in making diagnostic decisions [8]. Neural network (NN) applications in computer-aided diagnosis represent the mainstream of computational intelligence in medical imaging [9]. This study aimed to combine a state-of-the-art machine learning technique with a biological and clinical identification scheme to provide novel insights into the molecular basis of TMJOA. We hypothesized that variations in protein levels and clinical symptoms would correlate to the patterns of bone morphology on the condylar articular surfaces of TMJOA subjects, and there is a high degree of conformity between the NN and expert clinicians in classifying the condylar degree of OA.

MATERIALS AND METHODS

Seventeen TMJOA subjects (39.9 ± 11.7 years) that experienced signs and symptoms of the disease for less than 10 years and 17 age- and sex-matched asymptomatic control subjects (39.4 ± 15.2 years) were consented and enrolled in this study. Clinical and radiographic diagnosis of TMJOA followed the diagnostic criteria for temporomandibular disorders (DC/TMD) [2]. The data acquisition and analysis in this study was approved by the University Institutional Review Board.

All TMJOA subjects had a clinical examination of their TMJs by an orofacial pain specialist while all control subjects had a dental specialist perform the clinical examination to rule out signs of TMD. Clinical information describing the signs and symptoms comprised of and followed standardized DC/TMD clinical exam and questionnaire forms [2]. Pain-related questions following a 0 to 10 visual analog scale, and the amount of assisted and unassisted mouth opening measurements were included in the integrative analysis for the clinical markers. Age, a demographic variable, was also evaluated.

Saliva and blood samples were collected and measured. Custom human Quantibody® protein microarrays obtained quantitatively assessed the saliva and serum samples for 17 specific biomarkers previously found to be expressed in synovial fluid and serum of TMJOA subjects: 6Ckine, ANG, BDNF, CXCL16, ENA-78, GM-CSF, IFN- γ , IL-1 α , IL-6, MMP-3, MMP-7, PAI-1, TGF- β 1, TIMP-1, TNF- α , VE-cadherin and VEGF [7]. Each participant had duplicates run for the saliva and serum samples.

Subjects were scanned using a hr-CBCT scanner. The region of interest included the inferior border of the squamous portion of the temporal bone to the condylar neck, the narrowest portion of the condyle process. Reconstruction of the surface models of the right and left condyles from the CBCT images of each subject was performed using ITK-SNAP v.2.4, www.itksnap.org [10]. Each subject had both TMJs scanned, but the biological and clinical data that refer to each subject would be analyzed without being side specific. The joint side of choice used for analysis on the 3D surface meshes data was the side with most severe symptoms in the TMJOA group and the matching control condyle. The surface mesh reconstructions of all left condyles were mirrored in the sagittal plane using 3D slicer, <http://www.slicer.org> to be in the same orientation as the right condyles to facilitate bilateral comparisons [11]. A validated regional superimposition technique was used for across-subject comparisons in a common coordinate system when all of the registered condylar surface models were cropped [12]. SPHARM-PDM [13,14] software was used to generate a mesh with 1002 correspondent points through spherical mapping and spherical parameterization of the surface to analyze the areas of most significant morphological variability [14-16].

De-identified patient data was stored in a flexible secure web-based system: Data Storage, Computation, and Integration (DSCI). The training of the NN was performed in the DSCI system, where the classifier learns from features extracted from the 3D meshes of the condyles. 259 condyles (105 control and 154 from patients with diagnosis of TMJOA), collected from previous studies were used to train the NN [15,17]. The 34 condyles from the subjects enrolled in the current study were then used to test the NN. The total study dataset consisted of 3D surface meshes of 293 condyles. The NN module computed the average shape of each group of condylar dysmorphology as well as geometric features at each vertex of the mesh.

The NN in this study was trained to distinguish different degrees of shape deformation of TMJOA condyles. Two expert clinicians (A.R. and M.Y.) performed a consensus visualization and interpretation of 3D condylar surface morphology and classified the condylar morphology into 6 groups, which included 5 sub-groups with different degrees of condylar degeneration (Groups 1-5). The clinicians scored each condyle based off of the shape, size, and morphology in a 3D overlay compared to the average control group condylar morphology. Group "0" were healthy control shaped condyles and "5" were condyles exhibiting the most degeneration and lacking any resemblance to a normal shape of a condyle. To test reproducibility, the clinicians' classification was repeated for a subset of 46 condyles of the 259 condyles in the training datasets.

Our training database contained fewer samples for some of the disease stage groups. In order not to over-train the NN for one of the groups, the training procedure required the same number of meshes in each training group [18]. To increase the number of datasets in each training group, we simulated data by adding perlin noise of small magnitude to each coordinate in the shape, and then the features were re-computed, which provided us with 530 total 3D condylar meshes including the 259 condyles from the training database [19, 20]. Data was simulated to ensure that 74 meshes were available per group. For groups that had more than 74 meshes, the pre-processing step randomly selected 74 condyles. Thereafter, the NN was used to classify the stage of TMJOA of the testing datasets (34 condylar surface meshes from the subjects enrolled in the current study) and then compared to the clinical experts' classifications twice. We applied Multivariate Functional Shape Data Analysis (MFSDA) to test the integrating information of 3D mesh coordinates, clinical markers, and levels of biological markers.

RESULTS

Eleven of the 17 proteins (ANG, MMP-3, MMP-7, PAI-1, TIMP-1, VE-cadherin, 6Ckine, CXCL16, ENA-78, IL-1 α , VEGF) were found to have protein concentrations of quantifiable levels and found to have a coefficient of determination value greater than 0.96. These biomarkers were quantified and used for further analyses in conjunction with the clinical and imaging markers. When comparing the serum and saliva levels for each biomarker between the control and TMJOA groups, there no significant differences were found.

The MFSDA model tested correlations with morphology of subjects' age, pain-related clinical variables, ranges of mouth opening, and the eleven biological markers that were expressed at the best confidence levels in saliva and serum samples. Age showed significant Pearson correlations with morphological variability on the anterior surface of control condyles and the lateral pole and posterior surface of the TMJOA condyles, which are areas of resorptive changes in TMJOA. The clinical markers "Current Facial Pain Rate," "Average Rate Six Months," and "Facial Worst Pain Rate," were correlated among themselves and together with "Begin Pain Years," which showed statistically significant associations with the superior-posterior articular surfaces. "Range Assisted Mouth Opening" and "Range Unassisted Mouth Opening" demonstrated statistically significant associations with variability in medial and lateral poles of the condyles.

Expression levels of MMP-3, VE-cadherin, 6Ckine, and PAI-1 were correlated among themselves in saliva in the TMJOA group and showed significant Pearson correlations with condylar morphological variability on the posterior surface of the condyle. In serum, VE-cadherin and VEGF levels were correlated with one another and with significant morphological variability on the anterior surface of the condyle, a region that is typically associated with bone proliferation; while, MMP-3 and CXCL16 levels were found to have statistically significant associations with variability on the anterior surface, lateral pole, and superior-posterior surface of the condyle. In the control group, it was found that expression levels of MMP-7 and ENA-78 in saliva and VEGF in serum showed significant Pearson correlations with condylar morphological variability. The level of MMP-7 in saliva was correlated with morphological variability on the anterior surface of the condyle near the condylar neck and posterior surface. The level of ENA-78 in saliva was associated with morphological variability on the latero-posterior surface of the condyle. In serum, the level of VEGF was correlated with significant variability in small regions of the medial pole of the articular surface, and anterior and posterior surfaces of the condylar neck.

The performance of the two clinical experts' assessments is considered the "control" for the NN to be compared against. From the different combinations of features that were used to train the network, the features that led to higher accuracy of the morphological classification compared to the clinical experts' assessments were: normal vectors, mean curvature, and the distances to the average meshes at each mesh vertex. Each column represents the instances in the NN classification group, and each row represents the group instances as assessed by the consensus between two clinical experts. The repeated clinician consensus classification had 97.8% agreement on degree of degeneration within 1 group difference for the training datasets and 97.1% for the testing datasets. Predictive analytics of the NN's staging of TMJOA compared to the repeated clinicians' consensus revealed 73.5% and 91.2% degree of conformity.

DISCUSSION

This is the first study to test biomarkers in pairs or groups to evaluate their correlation with condylar morphology and to apply artificial intelligence to test the shape analysis features in a NN for the staging of condylar morphology in TMJOA. Although significant progress has been made in TMJOA research in recent years, very little is known about the molecular mechanisms of OA initiation and progression. The lateral surface of condyles usually demonstrate resorption in TMJOA patients, with resultant flattening on the latero-posterior condylar [21]. There has been a need for the development of a comprehensive diagnostic model that integrates clinical, morphological, and biomolecular assessments.

The first part of this investigation aimed to detect levels of known inflammatory biomarkers in systemic (serum and saliva) samples, to identify clinical markers, and then to correlate these markers to 3D models of TMJOA. The previous pilot quantitative assays of localized joint synovial fluid and serum samples from TMJOA patients were limited by the inability to test biomarkers in pairs or groups to evaluate whether or not there is cross-reactivity between them that is associated with condylar morphology [7]. The present investigation tested biomarkers in groups to likely be a more accurate representation of the in-vivo state.

No significant difference being found when comparing biomarkers in serum and saliva between the (asymptomatic) controls and TMJOA groups may be explained by the normal presence of these pro-inflammatory proteins in systemic fluids of both groups. The biomarkers that were measured and evaluated in this study serve various physiologic and pathophysiologic processes and may simply play different roles in the progressive degeneration in OA compared to control groups. The application of MFSDA statistics determined a comprehensive model of the integrative correlations between biological and clinical marker levels and morphological condylar surface changes at the 1002 vertices of 3D meshes. The regional correlations between biological markers and morphology for the control group may indicate the roles of these biomarkers in the physiological remodeling with maintenance of homeostasis that occurs in healthy TMJs. In the TMJOA group, the pain-related variables tested were correlated among themselves and showed statistically significant associations only with the superior-posterior articular surfaces, while range of mouth opening variables were correlated among themselves and with the morphological variability in the medial and lateral poles of the condyles.

Levels of VE-cadherin, VEGF, MMP-3, and CXCL16 in serum were highly correlated to areas of bone apposition/reparative proliferation that occurs on the anterior surface of condyles and leads to characteristic changes in condylar torque and morphology. Bone resorption with flattening and reshaping of the lateral pole of the condyle involves molecular pathways with interaction of five proteins measured in this study: VE-cadherin and MMP-3 both in saliva and serum, CXCL16 in serum, and 6ckine and PAI-1 in saliva. In a previous study [7], these same serum biomarkers as well as ENA-78, 6Ckine, TIMP-1, ANG, PAI-1, GM-CSF, IFN- γ , IL-1 α , IL-6 TNF- α , TGF- β 1, BDNF, and other biomarkers not evaluated in this study were found to be correlated with morphological variability on different regions of the condylar surface.

The second part of this investigation aimed to classify different degrees of 3D joint degeneration through novel phenotyping using a NN. The deep learning architecture chosen for this study was able to capture complex morphology patterns. The confusion matrix found adequate agreement between the clinical experts and the NN when classifying the testing dataset condyles.

Variability in patient symptoms and imaging findings can create challenges in diagnosing, which leads to frequent disagreement among clinicians and sometimes misdiagnosis. The difficulties of TMJOA diagnosis include the subjectivity of radiographic interpretation and the pain threshold of an individual. The diagnosis itself may be the biggest barrier in creating biomarker disease profiles for diseased and healthy groups [22]. This study sample of biological and standardized DC/TMD clinical survey data consisted of only 17 TMJOA and 17 asymptomatic controls, while the NN TMJOA morphology disease staging utilized a larger training sample for which only imaging data and clinical diagnosis is available. A more accurate NN may be trained when larger standardized omics data becomes available. The developments in this study and advances in data science in the TMJ health and disease field may aid researchers to gain further insight into biomarkers for diagnostic purposes to help guide treatment choices for TMJOA.

This study established associations between the biochemical/clinical indicators and TMJOA morphology, as well as used a preliminary NN to link TMJOA morphology to clinical diagnoses. The associations computed with the MFSDA statistical modeling were based on the diagnosis of TMJOA or asymptomatic control using the DC/TMD diagnostic criteria. Even though the current NN disease staging is limited by subjective clinician classification of 3D morphological variability and sole dependence on morphologic assessments, this study is the first to train a NN for TMJOA staging of severity of bone degenerative disease. Future studies will train the NN to also include biochemical/clinical indicators, as well as objective quantitative radiomic features of the subchondral bone structure, when larger samples including such data are collected. The future mining of high dimensional clinical, biological, and imaging patient data has the potential to allow clinicians to address the heterogeneity among the TMJOA patients and guide personalized management of the disease.

CONCLUSIONS

Levels of VE-cadherin, VEGF, MMP-3 and CXCL16 in serum, and MMP-3, VE-cadherin, 6Ckine, and PAI-1 in saliva were significantly correlated with specific regions of condylar morphological variability. The ranges of mouth opening were the clinical variables with most significant associations with morphological variability at the medial and lateral condylar poles. The NN presented a high degree of conformity in classifying and categorizing condyles based on the stage and degree of OA the mandibular condyle has exhibited.

REFERENCES

1. Gauer RL, Semidey MJ. Diagnosis and treatment of temporomandibular disorders. *American family physician* 2015;91(6).
2. Schiffman E, Ohrbach R, Truelove E, Look J, Anderson G, Goulet JP, List T, Svensson P, Gonzalez Y, Lobbezoo F et al. Diagnostic criteria for temporomandibular disorders (dc/tmd) for clinical and research applications: Recommendations of the international rdc/tmd consortium network* and orofacial pain special interest group. *Journal of oral & facial pain and headache* 2014; 28(1):6-27.
3. Wadhwa S, Kapila S. Tmj disorders: Future innovations in diagnostics and therapeutics. *Journal of dental education* 2008;72(8):930-947.

4. de Souza RF, da Silva CHL, Nasser M, Fedorowicz Z, Al-Muharraqi MA. Interventions for managing temporomandibular joint osteoarthritis. *Cochrane Database of Systematic Reviews* 2012; (4).
5. Berenbaum F. Osteoarthritis as an inflammatory disease (osteoarthritis is not osteoarthrosis!). *Osteoarthritis and Cartilage* 2013;21(1):16-21.
6. Yan W, Apweiler R, Balgley BM, Boontheung P, Bundy JL, Cargile BJ et al. Systematic comparison of the human saliva and plasma proteomes. *Proteomics Clin Appl* 2009;3(1):116-134.
7. Cevidanes LH, Walker D, Schilling J, Sugai J, Giannobile W, Paniagua B, et al. 3d osteoarthritic changes in tmj condylar morphology correlates with specific systemic and local biomarkers of disease. *Osteoarthritis Cartilage* 2014;22(10):1657-1667.
8. Li R. Data mining and machine learning methods for dementia research. *Biomarkers for alzheimer's disease drug development*. Springer 2018;363-370.
9. Qian W, Zhukov T, Song D, Tockman MS. Computerized analysis of cellular features and biomarkers for cytologic diagnosis of early lung cancer. *Anal Quant Cytol Histol* 2017;29(2):103-111.
10. Yushkevich PA, Piven J, Hazlett HC, Smith RG, Ho S, Gee JC, et al. User-guided 3d active contour segmentation of anatomical structures: Significantly improved efficiency and reliability. *Neuroimage* 2006;31(3):1116-1128.
11. Fedorov A, Beichel R, Kalpathy-Cramer J, Finet J, Fillion-Robin J-C, Pujol S, et al. 3d slicer as an image computing platform for the quantitative imaging network. *Magnetic resonance imaging* 2012;30(9):1323-1341.
12. Schilling J, Gomes LC, Benavides E, Nguyen T, Paniagua B, Styner M, et al. Regional 3d superimposition to assess temporomandibular joint condylar morphology. *Dentomaxillofac Radiol* 2014;43(1):20130273.
13. Paniagua B, Pascal L, Prieto J, Vimort JB, Gomes L, Yatabe M, et al. An open-source tool to classify tmj oa condyles. *Proc SPIE Int Soc Opt Eng* 2017;10137:101372H.
14. Styner M, Oguz I, Xu S, Brechbuhler C, Pantazis D, Levitt JJ, et al. Framework for the statistical shape analysis of brain structures using spharm-pdm. *The insight journal* 2006;(1071):242-250.
15. Brechbühler C, Gerig G, Kübler O. Parametrization of closed surfaces for 3-d shape description. *Computer vision and image understanding* 1995;61(2):154-170.
16. Paniagua B, Cevidanes L, Walker D, Zhu H, Guo R, Styner M. Clinical application of spharm-pdm to quantify temporomandibular joint osteoarthritis. *Comput Med Imaging Graph* 011;35(5):345-352.
17. Gomes LR, Gomes M, Jung B, Paniagua B, Ruellas AC, Gonçalves JR, et at. Diagnostic index of three-dimensional osteoarthritic changes in temporomandibular joint condylar morphology. *J Med Imaging* 2015; 2(3):034501-034501.
18. LeCun Y, Bengio Y, Hinton G. Deep learning. *Nature* 2015;521(7553):436-444.
19. Vtkperlinnoise class reference. VTK 2017. <http://www.vtk.org/doc/nightly/html/classvtkPerlinNoise.html>. Accessed July 24, 2017.
20. de Dumast P, Mirabel C, Cevidanes L, Ruellas A, Yatabe M, Ioshida M, et al. A web-based system for neural network based classification in temporomandibular joint osteoarthritis. *Comput Med Imaging Graph* 2018;67:45-54.
21. Nah KS. Condylar bony changes in patients with temporomandibular disorders: A CBCT study. *Imaging Sci Dent* 2012;42(4):249-253.
22. Ebrahim FH. Salivary biomarkers associated with temporomandibular joint osteoarthritis and the accuracy of cone beam computed tomography in assessing the internal trabecular structure of

the mandibular condyle 2016 [Unpublished master's thesis]. [Ann Arbor, MI]: University of Michigan.

SELF-REPORTED PARAFUNCTION NOT VALIDATED BY MEASURED MASSETER MUSCLE ACTIVITY

Jeffrey C. Nickel, Yoly M. Gonzalez, Ying Liu, Hongzeng Liu, Laura R. Iwasaki

ABSTRACT

Parafunction is thought to contribute to temporomandibular disorders (TMD). **Objectives:** Test for correlation between self-reported parafunction (Oral Behaviors Checklist, OBC) and (1) masseter muscle activities recorded via electromyography and (2) physical symptom severity scores (Patient Health Questionnaire-15, PHQ-15). **Materials and Methods:** Adult subjects gave informed consent to participate according to Institutional Review Board oversight, completed Diagnostic Criteria for TMD (DC-TMD) protocols including OBC and PHQ-15, performed calibration biting tasks, plus recorded ambulatory masseter electromyography in their natural environments. Each subject was trained to record masseter muscle activities on one side using portable equipment and asked to record for 3 daytime and 3 nighttime sessions of ≥ 6 hours each. Masseter electromyography (μV) and bite-forces (N) during biting tasks performed in the laboratory were plotted to determine subject-specific $\mu\text{V}/\text{N}$ relations and used to calibrate ambulatory muscle activities for masseter duty factor measurements (% time of muscle activity/total recording time). Regression analyses determined correlations between OBC scores and (1) masseter duty factors, and (2) PHQ-15 scores. **Results:** Of 242 individuals examined, 122 met inclusion criteria and completed the study. Subjects produced 346 daytime and 357 nighttime electromyography recordings averaging 6.9 ± 2.3 hours and 7.6 ± 1.9 hours respectively. Total OBC scores ranged from 0-50, average masseter duty factors ranged from 0.0-9.0%, and PHQ-15 scores ranged from 0-18. OBC scores showed no correlation with masseter duty factors but were associated with PHQ-15 scores ($R^2=0.28$). **Conclusions:** Self-reported oral parafunction failed to be validated by measured masseter muscle activities but were correlated with self-reported physical symptoms scores.

KEY WORDS: Oral Parafunction, Physical Symptoms, Masticatory Muscle, TMD, TMJ

INTRODUCTION

TMD represents a group of conditions with and without pain, such as temporomandibular joint (TMJ) disc displacement and degenerative disease. Temporomandibular disorders (TMD) are prevalent in 5 – 12% of the population, more so in younger than older individuals and in woman compared to men [1]. Historically, a prevailing perspective was that excessive loading of the TMJs due to oral parafunction was a contributing factor to the early onset of mechanical fatigue and degenerative disease of TMJ articulating tissues [2, 3]. In parallel, associated high levels of parafunction were presumptive etiological factors for development of pain-related TMD [4-6]. However, data from polysomnographic recordings demonstrated that such parafunctional activities of the masticatory muscles were rare and did not differentiate between groups with and without myofascial TMD [7]. Additionally, diurnal data collected using ecological sampling methodology showed that the percentage of time spent with teeth clenching was significantly

smaller than with teeth “touching” [8], and ambulatory electromyographic recordings of day- and nighttime masticatory muscle use showed that activities were low in amplitude and reflected tooth contacts that were low in magnitude [9-11]. Lobbezoo et al. acknowledged the apparent poor concordance between non-instrumental approaches, such as self-report, and instrumental approaches, such as electromyography, to quantify oral behaviors like bruxism [12]. These authors noted the significant associations of oral behaviors with some psychological conditions, and that self-reports of oral behaviors may be more useful as a measure of psychosocial distress than a measure of day- and night-time masticatory muscle activities.

The Diagnostic Criteria for TMD (DC-TMD) are a set of validated tools to identify individuals with and without TMD that are evidence-based, freely available, and supported by an international consortium [13, 14]. Among the recommended self-report questionnaires included in the DC-TMD is the Oral Behaviors Checklist (OBC) [15]. The OBC has 21 items about the frequencies of parafunctional behaviors involving the mouth and jaws over the past month during sleep (two items) and during waking hours (19 items). Each item has 5 possible answers scored from 0-4 ranging from “none of the time” (0) to “4-7 nights/week” (4) during sleep, and “none of the time” (0) to “all of the time” (4) during waking hours. Thus, total OBC scores have the potential to range between 0-84, representing no-high frequencies of self-reported parafunction. A prospective cohort study of 2,737 initially healthy individuals, who were followed for up to 5 years using an earlier version of DC-TMD, showed that those with OBC scores ≥ 25 had a higher incidence of developing TMD [16]. Also included among the DC-TMD tools is the Patient Health Questionnaire-15 (PHQ-15), which is an assessment of psychosocial functioning [14, 17]. The PHQ-15 has 15 questions about physical symptoms with possible choices of “not bothered,” “bothered a little,” and “bothered a lot,” which are scored as 0, 1, and 2, respectively, for total scores that can range from 0-45.

The study reported herein investigated the hypothesis proposed by Lobbezoo et al. of whether or not self-reported parafunction was representative of objectively measured daytime and nighttime muscle activities versus representative of self-reported physical symptoms of psychosocial distress [12]. Thus, the objectives of the study were to test for correlation between self-reported parafunction (OBC) and (1) masseter muscle activities recorded via electromyography and (2) physical symptom severity scores (PHQ-15).

MATERIALS AND METHODS

Adult subjects were recruited at the University at Buffalo School of Dental Medicine between November 2011 and May 2017 to participate in a parent study investigating jaw mechanics and behaviors in individuals with and without TMD. The Institutional Review Boards of the University at Buffalo and University of Missouri-Kansas City approved study protocols. STROBE guidelines for observational studies were implemented. Based on preliminary data and an anticipated attrition rate of 20%, a power analysis indicated that 138 subjects were required to detect statistically significant differences in jaw mechanics and behaviors. Subjects ≥ 18 years of age were screened and gave informed consent before enrollment. At screening, subjects’ intra-oral structures were examined to confirm general oral health. Exclusion criteria included signs of gross tissue inflammation, dental caries, missing dental restorations or teeth anterior of the second permanent molars, and inability to participate in the study protocols (including inability to use the ambulatory electromyographic (EMG) recording equipment).

Subjects underwent the standardized DC-TMD examination protocol and completed the DC/TMD Axis II questionnaires, including the OBC and PHQ-15 [14]. Calibrated clinicians and radiologist determined each subject's assignment to either a bilateral disc displacement (+D) or control (-D) group by implementing a structured examination protocol and criteria from the DC-TMD. To address the issue of potential bias, other investigators were blinded to subjects' diagnostic status until collected data were submitted for statistical analyses.

As described in previous published work, during a first laboratory visit, subjects were taught how to use a portable recorder, which stored EMG signals on a memory card [9-11]. Subjects were shown how to place surface EMG electrodes on one side, two per muscle and one ground electrode over the mastoid process, and to connect these to the recorder (Figure 1).

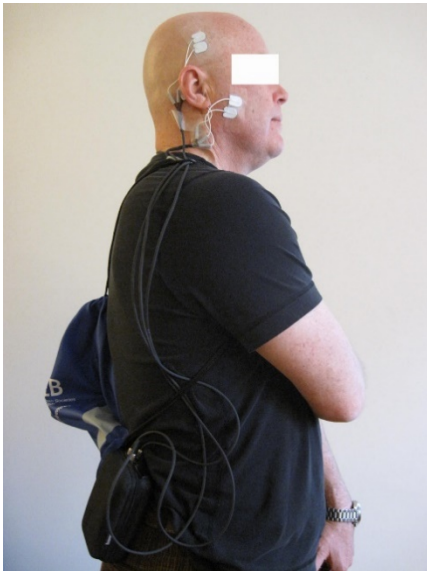

Figure 1. Example of ambulatory EMG recording equipment in use.

Minimum criteria for analysis of muscle activities were 2 daytime and 2 nighttime recordings per subject. Hence, in anticipation of technical difficulties or other factors affecting recording, subjects were asked to produce 3 daytime and 3 nighttime recordings where each was ≥ 6 hours in duration. Following completion of recordings, subjects returned for a second laboratory visit, where the recorded data were reviewed. Subjects were asked to repeat another recording if necessary, to meet minimum criteria.

At both laboratory visits, subjects performed previously described calibration exercises that comprised static and dynamic unilateral biting on the right and left first molars/bicuspids while muscle activities and bite forces were recorded via EMG equipment and a calibrated force transducer, respectively (Figure 2) [9-11]. Subjects were asked to produce light-medium forces, as defined by the subject, without visual feedback. A series of 5 static bites and then four series of approximately 5 dynamic bites were performed on one side, with each series at a different frequency guided by a digital metronome set at 0.5, 1.0, 1.5, 2.0 Hz. The exercises were then performed on the other side. The resulting EMG and bite-force data were plotted for each subject and visit, and linear regression analyses defined the slope of right and left masseter muscle activities per bite-force (mV/N). The slopes from two visits per subject were averaged.

The ambulatory masseter EMG recordings (2000 samples/second/channel) were filtered for low-level noise (WavePad Sound Editor Master Edition, Greenwood Village, CO) and processed as previously described using customized software (MatLab®, MATHWORKS, Natick, MA), to detect, delimit, and calculate root-mean-square values for EMG segments (EMGRMS, mV) defined by 128 ms contiguous rectangular sliding Hamming windows [9, 10, 18]. Average slope (mV/N) for each subject's masseter muscle from laboratory calibration exercises was used to quantify magnitudes of masseter muscle activities during the ambulatory EMG recordings relative to the amount of muscle activity required by each subject to execute bite-forces of a given magnitude. By this previously described method, it was possible to calculate the percentage of time that the masseter muscle was active at the level of a given bite-force magnitude compared to the total recording time (duty factor, %) [9, 10, 18]. Because EMG recorded in subjects' natural setting environments is generally low in amplitude, reflecting tooth contacts that were low in magnitude, masseter duty factors were calculated for bite-force magnitudes of 1, 2, and 5 N [9-11].

Regression analyses determined whether or not there was an association between OBC scores and (1) masseter muscle duty factors, and (2) PHQ-15 physical symptoms scores.

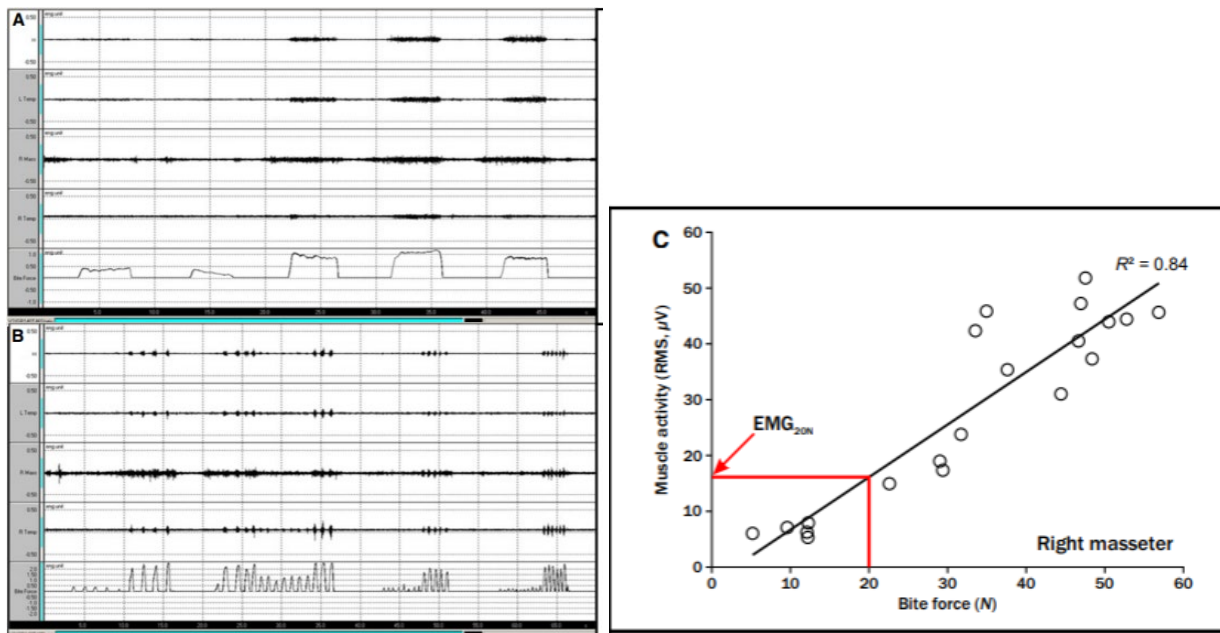


Figure 2. EMG and bite-force recordings from laboratory visits showing A) static and B) dynamic biting tasks where rows 1-4 are outputs from left masseter and temporalis and right masseter and temporalis muscles, respectively, and row 5 is from the bite-force transducer. C) Plot of right masseter activity (μV) versus bite force (N) from the biting tasks where arrow indicates the muscle activity associated with 20 N of bite force determined from the slope ($\mu\text{V}/\text{N}$). Modified with permission [10].

RESULTS

Of the 242 adult individuals screened, 122 subjects (68 females, 54 males) met the inclusion criteria, consented to participate, and completed experimental protocols. Subjects were categorized into three diagnostic groups with (+) and without (-) TMJ disc displacement (DD) and TMJ or masticatory

muscle pain: 46 (19 females, 27 males) had –DD-Pain, 32 (17 females, 15 males) had +DD-Pain, and 44 (32 females, 12 males) had +DD+Pain (Table 1). Average ages between females and males in each group were similar; however, the –DD-Pain group was younger on average than the other two groups by 5-8 years (Table 1). Females in the +DD+Pain group showed the largest average OBC scores during waking hours (21 ± 10) and sleep (6 ± 2) and the largest average PHQ-15 score (10 ± 4) of all gender and diagnostic subgroups but not the largest average masseter duty factors (Table 1).

Overall, subjects produced 346 daytime and 357 nighttime EMG recordings of average duration of 6.9 ± 2.3 hours and 7.6 ± 1.9 hours respectively. Ten subjects (7%) contributed less than 2 daytime recordings. Three subjects were missing duty factor data for one time period each (daytime: one +DD+Pain female, one –DD-Pain male; nighttime: one +DD+Pain female). Average masseter duty factors were larger for daytime compared to nighttime within all gender and diagnostic subgroups, where –DD-Pain females ($1.9 \pm 2.4\%$) and +DD+Pain males ($1.5 \pm 1.1\%$) showed the largest average daytime duty factors (Table 1).

Table 1. Diagnostic groups with (+) and (-) without temporomandibular joint (TMJ) disc displacement (DD) and pain, with number of subjects (N), and averages (\pm standard deviation) for age, OBC score, masseter duty factor and PHQ-15 score.

Diagnostic Group	Gender	N	Age (years)	OBC Score			Masseter Duty Factor (%)		PHQ-15 Score
				Total	Awake	Sleep	Daytime	Nighttime	
-DD -Pain	Female	19	29 ± 9	20 ± 7	18 ± 9	5 ± 2	1.9 ± 2.4	0.6 ± 1.1	4 ± 2
	Male	27	30 ± 11	20 ± 10	17 ± 8	4 ± 2	0.8 ± 0.8	0.3 ± 0.4	3 ± 3
+DD -Pain	Female	17	37 ± 15	18 ± 10	16 ± 8	4 ± 2	0.7 ± 0.8	0.2 ± 0.2	4 ± 3
	Male	15	37 ± 15	18 ± 9	17 ± 7	4 ± 2	0.6 ± 0.7	0.5 ± 1.1	4 ± 3
+DD +Pain	Female	32	35 ± 12	29 ± 11	21 ± 10	6 ± 2	0.8 ± 1.2	0.2 ± 0.3	10 ± 4
	Male	12	36 ± 13	27 ± 10	17 ± 11	5 ± 3	1.5 ± 1.1	0.5 ± 0.5	6 ± 4

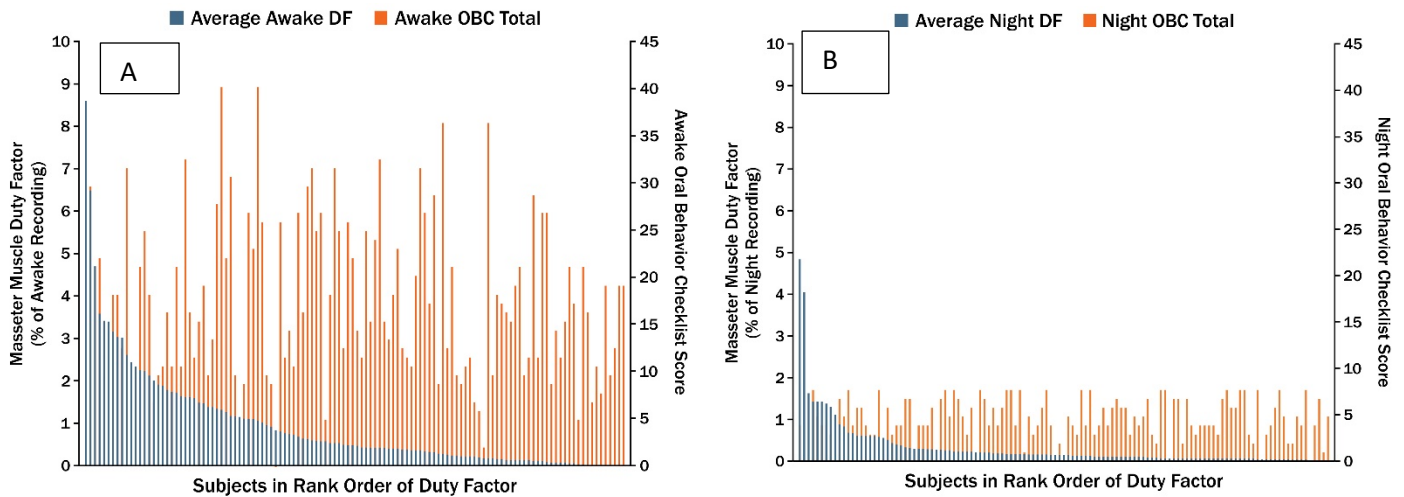


Figure 3. (A-B) Daytime (Awake) and nighttime masseter muscle duty factors (% time of muscle activity/total recording time for bite-forces $\leq 5N$) and OBC scores for all subjects, where results from subjects with the highest-lowest duty factors (black bars) were plotted from right-left.

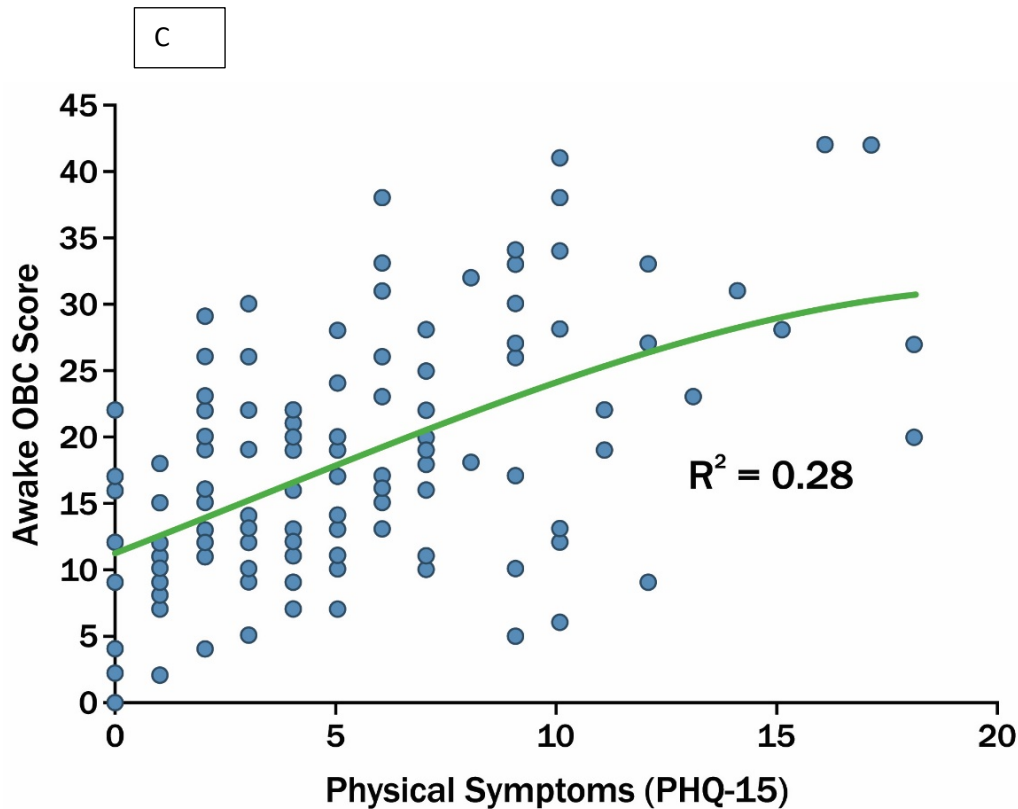


Figure 3. (C) Awake OBC score versus physical symptoms (PHQ-15) score for sample.

For the sample, OBC scores ranged from 0-50 in total, 0-42 for waking hours, and 0-8 for sleep; average masseter duty factors ranged from 0.0-9.0% during daytime and 0.0-5.0% during the nighttime; and PHQ-15 scores ranged from 0-18 (Figure 3). Regression analyses showed that OBC scores during waking hours were not correlated with daytime masseter duty factors (Figure 3A) and OBC scores during sleep were not correlated with nighttime masseter duty factors (Figure 3B). However, OBC scores during waking hours were moderately associated with physical symptoms scores ($R^2=0.28$).

DISCUSSION

The objectives of this study were to test whether or not self-reported parafunctional activities, as determined by OBC scores, were representative of objectively measured daytime and nighttime muscle activities in subjects' natural environments, as determined by masseter duty factors. The current data show the lack of association of OBC scores with objectively measured masseter duty factors and point to the likelihood that self-reported parafunction via OBC scores do not reflect masticatory motor behavior. Findings from a prospective cohort study indicated that self-reported parafunction was a predictor of development of painful TMD, as were psychosocial and physical symptoms scores [16]. However, the modeling results reported more recently by the same group [19] found that self-reported parafunction did not predict persistence of TMD symptoms, whereas physical symptoms had an odds ratio of 1.8 for the development of pain chronicity. These results are consistent with data from the current study, which showed a correlation between OBC scores during waking hours and PHQ-15 scores, and support the

alternative hypothesis of OBC scores being representative of self-reported physical symptoms of psychosocial distress [12].

As noted by Gonzalez et al., dysregulation of sensory processing in the trigeminal ganglia and subnuclei is putatively due to glial cell release of inflammatory molecules such as interleukin 1-beta and calcitonin gene-related peptide [20]. In animal models, psychosocial stress has been shown to cause trigeminal glial cell release of inflammatory molecules, resulting in a chronic state of increased sensitivity to non-noxious sensory stimuli [21]. The inflammation causes membrane instability in trigeminal primary and secondary neurons that normally relay nociceptive information within the brain stem. It is possible that when self-reported physical symptoms scores are large, this is a sign of sub-acute inflammation within the trigeminal system. The moderate correlation ($R^2 = 0.28$) between OBC and PHQ-15 scores suggests that there may be other psychophysiological measures which, in combination, may more accurately reflect the allostatic state of the peripheral and central nervous systems.

Indeed, results from the current study show that those with painful TMD, +DD+Pain females (29 ± 11) and males (27 ± 10) had average total OBC scores greater than the previously reported critical score of ≥ 25 and the largest average PHQ-15 scores among the subgroups. Future studies should investigate further the relationships between these and other psychophysiological measures within and between different TMD diagnostic groups and between genders. In addition, subjects in the -DD-Pain and +DD-Pain groups with large and small duty factors and self-reported scores should be followed longitudinally to understand associations between these measures and progression of or improvement in TMD conditions. Although duty factors were generally small, for example, the largest average duty factor for the -DD-Pain females was 1.9% and equated to 8 minutes of low magnitude (levels associated with ≤ 5 N of bite-force) masseter activity during a 7-hour recording period. However, one individual showed daytime and nighttime duty factors of 9% and 5%, respectively, which would equate to 38 and 21 minutes, respectively, of masseter activity during a similar 7-hour period. Finally, future studies should also address the limitations of the current study by measuring ambulatory EMG bilaterally and from more masticatory muscles, and by possibly measuring or estimating the magnitudes of mechanical loads associated with the frequency of loading that is measurable via duty factors.

To summarize, previously reported data and results of the current study support an alternative interpretation of data produced by the OBC. Rather than a proxy measure of masticatory motor activity, the OBC may be a measure of dysregulated sensory processing, and a strong predictor for the development of both transient and persistent TMD-associated pain, but not intra-articular TMJ status. Our results support that there is no association between self-reported oral parafunction and measured masseter muscle activity.

CONCLUSIONS

Self-reported oral parafunction failed to be validated by measured masseter muscle activities, but these were correlated with self-reported physical symptoms scores. Measured masseter muscle activities were generally low but relatively larger during daytime than nighttime.

ACKNOWLEDGEMENTS

The authors thank the subjects for their participation. Dr. K. Khartha provided the interpretation of TMJ images. Dr. S.N. Khawaja assisted with screening and clinical examinations of subjects. The study was supported by the National Institute for Dental and Craniofacial Research (R01 DE 016417, Nickel-PI). Mr. Kim Theesen prepared the figures. None of the authors have a conflict of interest.

REFERENCES

1. Prevalence of TMJD and its Signs and Symptoms. NIH 2018. <https://www.nidcr.nih.gov/research/data-statistics/facial-pain/prevalence>. Access date December 2020.
2. Israel HA, Diamond B, Saed-Nejad F, Ratcliffe A. The relationship between parafunctional masticatory activity and arthroscopically diagnosed temporomandibular joint pathology. *J Oral Maxillofac Surg* 1999; 57(9):1034-1039.
3. Su N, Liu Y, Yang X, Shen J, Wang H. Association of malocclusion, self-reported bruxism and chewing-side preference with oral health-related quality of life in patients with temporomandibular joint osteoarthritis. *Int Dent J* 2018;68(2):97-104.
4. Carra MC, Huynh N, Morton P, Rompre PH, Papadakis A, Remise C, et al. Prevalence and risk factors of sleep bruxism and wake-time tooth clenching in a 7- to 17-yr-old population. *Eur J Oral Sci* 2011; 119(5):386-394.
5. Ohrbach R, Michelotti A. The Role of Stress in the Etiology of Oral Parafunction and Myofascial Pain. *Oral Maxillofac Surg Clin North Am* 2018; 30(3):369-379.
6. Serra-Negra JM, Ramos-Jorge ML, Flores-Mendoza CE, Paiva SM, Pordeus IA. Influence of psychosocial factors on the development of sleep bruxism among children. *Int J Paediatr Dent* 2009;19(5):309-317.
7. Raphael KG, Sirois DA, Janal MN, Wigren PE, Dubrovsky B, Nemelivsky LV, et al. Sleep bruxism and myofascial temporomandibular disorders: a laboratory-based polysomnographic investigation. *J Am Dent Assoc* 2012;143(11):1223-1231.
8. Glaros AG, Williams K. Tooth contact versus clenching: oral parafunctions and facial pain. *J Orofac Pain* 2012; 26(3):176-180.
9. Gonzalez YM, Nickel JC, Scott JM, Liu H, Iwasaki LR. Psychosocial Scores and Jaw Muscle Activity in Women. *J Oral Facial Pain Headache* 2018; 32(4):381-388.
10. Iwasaki LR, Gonzalez YM, Liu H, Marx DB, Gallo LM, Nickel JC. A pilot study of ambulatory masticatory muscle activities in temporomandibular joint disorders diagnostic groups. *Orthod Craniofac Res* 2015;18(Suppl 1):146-155.
11. Khawaja SN, McCall W, Jr., Dunford R, Nickel JC, Iwasaki LR, Crow HC, et al. Infield masticatory muscle activity in subjects with pain-related temporomandibular disorders diagnoses. *Orthod Craniofac Res* 2015;18 (Suppl 1):137-145.
12. Lobbezoo F, Ahlberg J, Raphael KG, Wetselaar P, Glaros AG, Kato T, et al. International consensus on the assessment of bruxism: Report of a work in progress. *J Oral Rehabil* 2018;45(11):837-844.
13. Diagnostic Criteria for Temporomandibular Disorders. INFORM 2014. <https://ubwp.buffalo.edu/rdc-tmdinternational/tmd-assessmentdiagnosis/dc-tmd/>. Access date December 2020.
14. Schiffman E, Ohrbach R, Truelove E, Look J, Anderson G, Goulet JP, et al. Diagnostic Criteria for

Temporomandibular Disorders (DC/TMD) for Clinical and Research Applications: recommendations of the International RDC/TMD Consortium Network* and Orofacial Pain Special Interest Groupdagger. *J Oral Facial Pain Headache* 2014; 28(1):6-27.

15. Markiewicz MR, Ohrbach R, McCall WD, Jr. Oral behaviors checklist: reliability of performance in targeted waking-state behaviors. *J Orofac Pain* 2006;20(4):306-316.
16. Ohrbach R, Bair E, Fillingim RB, Gonzalez Y, Gordon SM, Lim PF, et al. Clinical orofacial characteristics associated with risk of first-onset TMD: the OPPERA prospective cohort study. *J Pain* 2013;14(Suppl 12):T33-T50.
17. Kroenke K. Physical symptom disorder: a simpler diagnostic category for somatization-spectrum conditions. *J Psychosom Res* 2006;60(4):335-339.
18. Khawaja SN, Nickel JC, Iwasaki LR, Crow HC, Gonzalez Y Association between waking-state oral parafunctional behaviours and bio-psychosocial characteristics. *J Oral Rehabil* 2015;42(9):651-656.
19. Meloto CB, Slade GD, Lichtenwalter RN, Bair E, Rathnayaka N, Diatchenko L, et al. Clinical predictors of persistent temporomandibular disorder in people with first-onset temporomandibular disorder: A prospective case-control study. *J Am Dent Assoc* 2019;150(7):572-581.
20. Gonzalez YM, Iwasaki LR, Liu H, Liu Y, Nickel JC. An Observational Study of Mechano-Allostatic Load and Chronic Temporomandibular Pain in Humans. *Craniofacial Growth Series* in press, 57.
21. Liu LY, Zhang RL, Chen L, Zhao HY, Cai J, Wang JK, et al. Chronic stress increases pain sensitivity via activation of the rACC-BLA pathway in rats. *Exp Neurol* 2019;313:109-123.

AN OBSERVATIONAL STUDY OF MECHANO-ALLOSTATIC LOAD AND CHRONIC TEMPOROMANDIBULAR PAIN IN HUMANS

Yoly Gonzalez, Laura R. Iwasaki, Hongzeng Liu, Ying Liu, Jeffrey C. Nickel

ABSTRACT

Background: Mechanobehavior of mandibular loading, which is the magnitude and frequency of non-nociceptive sensory input, and psychosocial state, may contribute to pain intensity associated with temporomandibular disorders (TMD). **Objectives:** 1) Test for \pm Pain group differences in (i) masseter muscle activity per N of mandibular load, (ii) frequency of awake-state masseter muscle activities, and (iii) psychosocial state. 2) Test for correlation between mechano-allostatic load (MAL = mechanobehavior x psychosocial scores) and pain-related TMD. **Methods:** The study was conducted in accordance with Institutional Review Board oversight and STROBE guidelines. Subjects' psychosocial states and levels of characteristic pain intensity (CPI) were assessed using validated instruments. Mechanobehavior was quantified using masseter muscle activity (mV) per N of mandibular load, and ambulatory awake-state masseter muscle duty factors (%) for mandibular loads ranging from >1 to <5 N. Magnitudes of MAL were estimated using mechanobehavior and psychosocial scores. Mann-Whitney tests determined differences between \pm Pain groups where significance was defined by $p < 0.05$. Regression analysis tested for a correlation between MAL and CPI. **Results:** One hundred and thirty-eight subjects (76 females, 62 males; 58 +Pain, 80 -Pain) produced 358 awake-state EMG recordings of average duration of 6.8 ± 1.9 hrs. The +Pain group showed significantly higher awake-state masseter muscle activity magnitudes (mV/N), duty factors (%), and psychosocial scores compared to the -Pain group (all $p < 0.01$). MAL was 27-fold and significantly higher in +P compared to -P subjects ($p < 0.001$), and positively related to CPI ($R^2 = 0.74$). **Conclusions:** Mechano-allostatic loads were significantly correlated with TMD-associated CPI scores.

KEY WORDS: Mechanobehavior, Awake-state, Chronic Pain, Allostasis, Psychosocial State

INTRODUCTION

There is evidence that chronic pain can develop without a preceding traumatic event [1, 2]. The mechanism for this remains an enigma. Proposed models of chronic pain point to the roles of magnitude and frequency of sensory input, combined with peripheral and/or central glial cell inflammatory states, and thalamic disinhibition and amplification of signal transmission to higher pain processing centers [3].

With respect to temporomandibular disorders (TMD) as a model of chronic pain, magnitude and frequency of non-nociceptive, low threshold mechanoreceptor sensory input from the masticatory muscles may be contributing factors [4-6]. Traditionally, parafunctional activities such as bruxing, and the associated high levels of mandibular loading, were presumptive etiological factors for TMD-related myofascial pain [7-9]. However, data from polysomnographic recordings demonstrated that such

parafunctional activities were rare and did not differentiate between groups with and without myofascial TMD [10]. Polysomnography studies have commonly used maximum voluntary contraction (MVC) to define thresholds for analysis of muscle activities. Notwithstanding, there are limitations of this laboratory approach because MVC lacks reliability, fails to have ecological validity, and does not provide individual-specific calibration of muscle activation (mV) per Newton (N) of load [11-13]. Hence, recorded masticatory muscle activities normalized to MVC can appear to be similar between individuals when the magnitude of the activity (mV/N) and commensurate afferent barrage to the central nervous system is actually very different. Additionally, data suggest that diagnostic group differences in diurnal and nocturnal masticatory muscle activities occur at low levels. These mandibular loads of <5 N [11, 14], are approximately one-quarter of the force produced during mastication. At these low levels, amplitude and frequency of sensory input from low-threshold mechanoreceptors, such as muscle spindles, reflect an individual's biomechanics and autonomic nervous system (ANS) tone [4, 15]. More specifically, diagnostic group differences in sensory input to the trigeminal ganglia and central nervous system nuclei likely result from differences in both the magnitude (mV/N) and frequency of muscle activities during mandibular loading at low levels, not the high levels traditionally associated with bruxism. Masticatory muscle duty factors (%) quantify frequency of muscle activities over a period of ambulatory EMG recording in terms of intensity and duration, and have been reported for awake and sleep states [14, 16]. In particular, increased awake-state masticatory muscle duty factors were associated with self-reported depression and somatic symptoms, despite the findings that awake-state muscle activities resulted from predominantly low level mandibular loads, <5 N, and low frequencies, which rarely exceeded 15 minutes of cumulative time over a 7-hour recording period [16, 17].

Models of chronic pain also include the roles of chronic psychosocial stress-related peripheral and central glial cell inflammation and ANS-associated central disinhibition and amplification of pain transmission [3]. The molecular effect of chronic stress in the development of mechanical allodynia has been demonstrated in animal models [4, 18, 19]. The link between inflammation and disinhibition of pain transmission and ANS function has been demonstrated by the association between glial cell peripheral and central inflammation and sympathetic and parasympathetic dysregulation [2, 20, 21]. Current evidence suggests that psychosocial state produces neuroplastic changes in primary and secondary afferent neuron membranes and synapses. The mechanism is thought to be through increased sympathetic activity, which promotes inflammatory cytokine secretion by glial cells surrounding nociceptive neurons [22]. Additionally, gliogenic long-term potentiation of sensory synapses has been shown to involve diffusible proteins in the cerebrospinal fluid that affect susceptible synapses at remote sites [23-25]. Neuro-inflammation and central sensitization associated with ANS dysregulation may account for stress-related mechanical allodynia through gliogenic homosynaptic and heterosynaptic long-term potentiation of primary and secondary nociceptive neurons [23].

The focus of the current study was to test a working hypothesis that mechano-allostatic load (MAL) within an individual, which represents the combined effects of mechanobehavior and psychosocial state, was correlated with that individual's characteristic pain intensity scores. To test this working hypothesis, characteristic pain intensity scores were estimated in subjects with and without TMD related pain. As a first approximation of magnitude and frequency of sensory barrage on the peripheral and central nervous system trigeminal nuclei, we quantified subjects' mechanobehaviors in their natural environments based on (i) magnitude of masseter muscle activities during mandibular loading (mV/N) and (ii) awake-state masseter muscle duty factors for loads <5 N. To estimate the state of allostasis of the peripheral and central nervous system, we computed psychosocial scores based on the implementation of validated instruments, followed by a summary integration of anxiety (General Anxiety Disorder 7-item

scale, GAD-7), depression (Patient Health Questionnaire-9, PHQ-9), and physical symptoms (PHQ-15) scores.

MATERIALS AND METHODS

In accordance with university Institutional Review Board ethical standards and the Helsinki Declaration of 1975, as revised in 1983, adult subjects ≥ 18 years of age were recruited to participate and gave informed consent before enrollment. Strengthening the Reporting of Observational studies in Epidemiology (STROBE) guidelines for observational studies were implemented (See Table 1).

Table 1. STROBE Statement for *Cohort Studies*

	Item No	Recommendation	Page No
Title and abstract	1	(a) Indicate the study's design with a commonly used term in the title or the abstract	1
		(b) Provide in the abstract an informative and balanced summary of what was done and what was found	2
Introduction			
Background/rationale	2	Explain the scientific background and rationale for the investigation being reported	3
Objectives	3	State specific objectives, including any prespecified hypotheses	5
Methods			
Study design	4	Present key elements of study design early in the paper	6
Setting	5	Describe the setting, locations, and relevant dates, including periods of recruitment, exposure, follow-up, and data collection	6
Participants	6	(a) Give the eligibility criteria, and the sources and methods of selection of participants. Describe methods of follow-up	7
		(b) For matched studies, give matching criteria and number of exposed and unexposed	7
Variables	7	Clearly define all outcomes, exposures, predictors, potential confounders, and effect modifiers. Give diagnostic criteria, if applicable	7
Data sources/ measurement	8*	For each variable of interest, give sources of data and details of methods of assessment (measurement). Describe comparability of assessment methods if there is more than one group	7
Bias	9	Describe any efforts to address potential sources of bias	6
Study size	10	Explain how the study size was arrived at	6
Quantitative variables	11	Explain how quantitative variables were handled in the analyses. If applicable, describe which groupings were chosen and why	6
Statistical methods	12	(a) Describe all statistical methods, including those used to control for confounding	7
		(b) Describe any methods used to examine subgroups and interactions	7
		(c) Explain how missing data were addressed	7
		(d) If applicable, explain how loss to follow-up was addressed	7

		(e) Describe any sensitivity analyses	7
Results			
Participants	13*	(a) Report numbers of individuals at each stage of study—eg numbers potentially eligible, examined for eligibility, confirmed eligible, included in the study, completing follow-up, and analysed (b) Give reasons for non-participation at each stage (c) Consider use of a flow diagram	7 7
Descriptive data	14*	(a) Give characteristics of study participants (eg demographic, clinical, social) and information on exposures and potential confounders (b) Indicate number of participants with missing data for each variable of interest (c) Summarise follow-up time (eg, average and total amount)	7 7 7
Outcome data	15*	Report numbers of outcome events or summary measures over time	7
Main results			
Main results	16	(a) Give unadjusted estimates and, if applicable, confounder-adjusted estimates and their precision (eg, 95% confidence interval). Make clear which confounders were adjusted for and why they were included (b) Report category boundaries when continuous variables were categorized (c) If relevant, consider translating estimates of relative risk into absolute risk for a meaningful time period	8 8 8
Other analyses	17	Report other analyses done—eg analyses of subgroups and interactions, and sensitivity analyses	8
Discussion			
Key results	18	Summarise key results with reference to study objectives	8
Limitations	19	Discuss limitations of the study, taking into account sources of potential bias or imprecision. Discuss both direction and magnitude of any potential bias	9
Interpretation	20	Give a cautious overall interpretation of results considering objectives, limitations, multiplicity of analyses, results from similar studies, and other relevant evidence	10
Generalisability	21	Discuss the generalisability (external validity) of the study results	10
Other information			
Funding	22	Give the source of funding and the role of the funders for the present study and, if applicable, for the original study on which the present article is based	10

*Give information separately for exposed and unexposed groups.

Note: An Explanation and Elaboration article discusses each checklist item and gives methodological background and published examples of transparent reporting. The STROBE checklist is best used in conjunction with this article (freely available on the Web sites of PLoS Medicine at <http://www.plosmedicine.org/>, Annals of Internal Medicine at <http://www.annals.org/>, and Epidemiology at <http://www.epidem.com/>). Information on the STROBE Initiative is available at <http://www.strobe-statement.org>.

Based on preliminary data, an analysis indicated that 138 subjects were required to have adequate power to detect statistically significant differences. Screening examinations and data collection

protocols were performed at the University at Buffalo School of Dental Medicine between November 2011 and May 2017. Subjects' intra-oral structures were examined to confirm general health. Exclusion criteria included signs of gross tissue inflammation, dental caries, missing dental restorations or teeth anterior of the second permanent molars, inability to participate in two laboratory visits for calibration exercises or inability to use the ambulatory electromyographic (EMG) recording equipment.

Subjects underwent the standardized Diagnostic Criteria for TMD (DC-TMD) examination protocol. Subjects also completed the DC/TMD Axis II instruments [26]. These screening instruments included the GAD-7, PHQ-9, and PHQ-15 [27-30] and were used to assess subjects' states of anxiety, depression, and physical symptoms, respectively. Characteristic pain intensity was determined using the Graded Chronic Pain Scale (6 Month). A single investigator determined each subject's diagnostic status (\pm Pain) by implementing a structured examination protocol and criteria from the DC-TMD. To address the issue of potential bias, other investigators were blinded to subjects' diagnostic status until collected data were submitted for statistical analyses.

Subjects participated in two laboratory visits to perform calibration exercises that comprised static and dynamic unilateral biting on the right and left first molars/bicuspids while muscle activities and bite forces were recorded via EMG equipment and a calibrated force transducer device, respectively. Subjects were asked to produce light to medium biting forces, as defined by the subject, without the aid of visual feedback. A series of 5 static bites and then a series of approximately 5 dynamic bites were performed at 4 frequencies (0.5, 1.0, 1.5, 2.0 Hz), aided by digital metronome, on one side and then repeated on the other side at each visit. The resulting EMG and bite-force data were plotted for each subject and visit, and linear regression analyses defined the slope of right and left masseter muscle activity per bite-force (mV/N). The slopes from two visits per subject were averaged.

During the first laboratory visit, subjects were also taught how to use a portable recorder, which stored EMG signals on a micro SD (Secure Digital) flash memory card. Subjects were shown how to place surface EMG electrodes on one side, two per muscle and one ground electrode over the mastoid process, and to connect these to the recorder. In anticipation of technical difficulties or other factors affecting daytime recording, subjects were asked to produce 3 separate days of awake-state masseter muscle activities, where each recording was to be ≥ 6 hours in duration. This approach was chosen to improve the likelihood that each subject would produce a minimum of 2 awake-state recordings. Following completion of recordings, subjects returned for the second laboratory visit, where the recorded data were reviewed. Subjects were asked to repeat another recording, if necessary, to meet minimum criteria for analysis of recordings.

As described in previous published work, the ambulatory masseter EMG recordings were processed using customized software (MatLab®, MATHWORKS, Natick, MA), to detect, delimit, and calculate root-mean-square values for EMG segments (EMGRMS, mV) defined by 128 ms contiguous rectangular sliding Hamming windows [13, 16]. Average slope (mV/N) for each subject's masseter muscle from laboratory calibration exercises was used to quantify magnitudes of muscle activities in the awake-state EMG recordings made in each subject's natural environments [16]. By this method, it was possible to calculate masseter muscle duty factors for mandibular loads from >1 to <5 N.

Each subject's mechano-allostatic load (MAL) was calculated by combining mechanobehavior (mV/N, DF) and psychosocial variables in the following equation:

$$[(mV/N)^2 * DF] * [PHQ15^2 + PHQ9^2 + GAD7^2]$$

where magnitude of muscle activity during mandibular loading (mV/N) and psychosocial variable scores were squared in order to reflect reported contributions to astrocyte pathophysiology regarding the non-linear relationship between amplitude of sensory input and subacute inflammatory state [31].

Mann-Whitney analysis was used to test for diagnostic group differences between the variables: (i) magnitude of masseter muscle activity during mandibular loading (mV/N), (ii) awake-state masseter muscle duty factor (%), (iii) anxiety (GAD-7), (iv) depression (PHQ-9), (v) physical symptoms (PHQ-15), and (vi) mechano-allostatic load (MAL). Regression analysis was used to characterize the relationship between normalized MAL and characteristic pain intensity (CPI). Normalization for these scores was done by division of individual scores by overall peak values of MAL and CPI respectively.

RESULTS

Two hundred and forty-two individuals were examined, of which one hundred and thirty-eight subjects met the inclusion criteria and consented to participate in the study. Fifty-eight subjects with pain (+P: 38 females aged 34.2 ± 12.0 years; 20 males aged 38.0 ± 13.1 years) and 80 subjects without pain (-P: 38 females aged 34.3 ± 12.4 years; 42 males aged 34.1 ± 13.1 years) completed study participation. In total, subjects produced 358 awake-state EMG recordings of average duration of 6.8 ± 1.9 hours. Ten subjects (7%) contributed fewer than 2 awake-state recordings.

Table 2. Comparison of variables between diagnostic groups with (+) and without (-) pain, where: bold font indicates the significantly higher value, * indicates $p < 0.01$, and ** indicates $p < 0.001$.

Variable	Diagnostic Group	N	Mean	Standard Deviation
Masseter Activity Magnitude (mV/N)	-Pain	66	0.05	0.06
	+Pain	62	0.11**	0.13
Masseter Duty Factor (%)	-Pain	66	1.19	2.65
	+Pain	62	1.61**	1.57
Anxiety (GAD7)	-Pain	66	3.91	4.55
	+Pain	62	5.58*	4.39
Depression (PHQ)	-Pain	66	3.00	3.56
	+Pain	62	4.77*	3.87
Physical Symptoms (PHQ15)	-Pain	66	3.42	2.35
	+Pain	62	8.31**	4.29
Mechano-Allostatic Load	-Pain	66	0.11	0.31
	+Pain	62	3.00**	2.44

The measured variables of masseter muscle activity magnitude (mV/N), duty factor (%), anxiety (GAD-7), depression (PHQ-9), physical symptoms (PHQ-15), and MAL were higher in the +Pain compared to the -Pain group by 2.2-, 1.4-, 1.4-, 1.6-, 2.4-, and 27-fold, respectively, and these differences were significant (Table 2, all $p < 0.01$). Regression analysis showed that the MAL was positively related with the CPI (Figure 1, $R^2 = 0.74$).

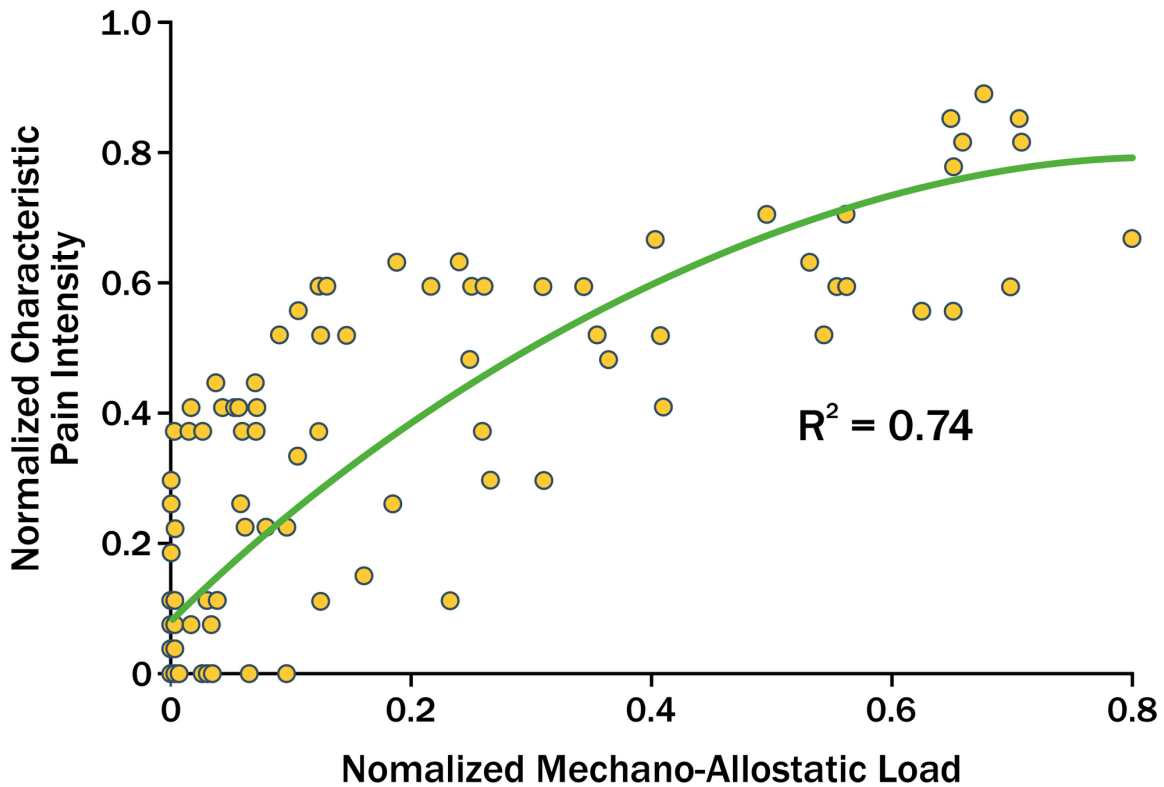


Figure 1. Normalized Mechano-Allostatic Load (MAL) versus Normalized Characteristic Pain Intensity (CPI). Individual subject's MAL and CPI scores were normalized by dividing by overall peak scores. Regression analysis showed that 74% of the variance seen in CPI was accounted for by MAL.

DISCUSSION

For the purpose of this investigation, mechano-allostatic loads were assumed to reflect the magnitude and frequency of diurnal non-nociceptive sensory input from the masseter muscle to trigeminal ganglia and subnuclei, and the general state of subclinical inflammation of the peripheral and central nervous systems. Sensory input was estimated for the masseter muscle by the product of magnitude of activity (mV/N) and masseter muscle duty factors (%) for mandibular loading < 5 N. The data presented are the first to demonstrate the likelihood of \pm Pain group differences in sensory barrage. The +Pain group showed over a 2-fold difference in magnitude of masseter activity during mandibular loading (mV/N) compared to the -Pain group, which suggests that for a given load on the mandible, the +Pain group may have had over a 2-fold difference in amplitude of sensory input to the trigeminal system

compared to the -Pain group. This assumes that there was a linear relationship between low amplitude static and dynamic muscle efferent activity and commensurate muscle spindle afferent input to the trigeminal nuclei. A linear relationship between muscle motor activity and sensory feedback has in fact been suggested, with the relationship influenced by sympathetic nervous system amplification by way of gamma motoneuron innervation of the muscle spindles [32, 33]. This, and evidence that frequency of masticatory muscle activity is also influenced by the sympathetic nervous system, suggest that this system is important in the processing, and ultimately determining the magnitude of non-noxious sensory input to the central nervous system [34].

Previously reported quantitative analysis of ambulatory awake-state jaw muscle electromyography (EMG) demonstrated that jaw behaviors rarely produced large mandibular loads [16]. For example, recordings in women with and without TMD-associated chronic pain showed that the most frequent muscle activities had durations of <4 seconds and loading forces <5 N. Total cumulative duration of these muscle activities lasted on average less than 15 minutes per 7-hour recording period. To date it is unknown if low amplitude and frequency muscle activities could be significant variables in the development and the maintenance of chronic pain. The addition of peripheral and/or central nervous system amplification of sensory information, such as when there is ANS dysregulation due to chronic environmental stressors, may be a significant co-factor that is required for the development of chronic pain related to TMD.

For the purposes of the current study, the state of allostasis of the peripheral and central nervous systems was estimated by using psychosocial scores. Recently reported data suggest that psychosocial status may be predictive of the onset of chronic TMD-related pain [35]. The psychosocial variables of chronic stress are thought to be contributing mechanisms, as well as indicators of dysregulated pain processing by the central nervous system [4, 36, 37]. Chronic stress has been shown to increase sympathetic activity and cause glial cell release of inflammatory mediators. Furthermore, release of interleukin 1beta (IL1 β) and calcitonin gene related peptide (CGRP) by glial cells causes neuroplastic changes of secondary sensory neurons in the spinal tract nuclei that result in electrical instability of cell membranes [38, 39]. Thus, as a consequence of this cell membrane instability of secondary interneurons, non-nociceptive sensory information may be mistakenly routed to pain processing centers of the central nervous system.

The current study has several limitations to be considered for the planning of future investigations. Firstly, to improve the external validity of the results, including equal numbers of females and males, matched for age and psychosocial status, would help to address whether or not there are sex differences with respect to MAL. Equity in recruitment would facilitate addressing the greater concern that females are more likely to develop chronic TMD pain compared to males. Secondly, recording and calibrating jaw muscle activities from both sides and other muscles besides the masseter should be included in future studies to investigate asymmetric mechanobehavior and the contributions of other muscles involved in jaw loading. Additionally, ANS function during the day and night should be recorded to test whether or not nocturnal ANS dysregulation is a variable that is correlated with chronic pain scores. Iwasaki et al. recently reported a non-linear relationship between nocturnal sympathetic and parasympathetic activity and temporalis and masseter muscle duty factors [13]. Given the influence of chronic stress on dysregulation of the ANS, and its influence on sensory and motor neuron physiology and central and peripheral glial cell inflammatory states, future investigations should include in-field collection of data describing the state of the sympathetic and parasympathetic nervous systems.

CONCLUSIONS

Mechano-allostatic loads were 27-fold higher in subjects with painful TMD (+P) and were significantly correlated with characteristic pain intensity. The data suggest that the combination of magnitude and frequency of sensory barrage, as indicated by jaw mechanobehavior, and dysregulated central pain processing, may be significant variables contributing to the maintenance of pain status.

ACKNOWLEDGEMENTS

The authors thank the subjects for their participation. Financial support for the project was provided by the National Institute for Dental and Craniofacial Research (R01 DE016417, Nickel PI). Dianne Gebauer assisted in data management. None of the authors has a conflict of interest.

REFERENCES

1. de Rooij AM, Perez RS, Huygen FJ, van Eijs F, van Kleef M, Bauer MC, et al. Spontaneous onset of complex regional pain syndrome. *Eur J Pain* 2010;14(5):510-513.
2. Monaco A, Cattaneo R, Marci MC, Pietropaoli D, Ortu E. Central Sensitization-Based Classification for Temporomandibular Disorders: A Pathogenetic Hypothesis. *Pain Res Manag* 2017;2017:1-13.
3. Russo M, Georgius P, Santarelli DM. A new hypothesis for the pathophysiology of complex regional pain syndrome. *Med Hypotheses* 2018;119:41-53.
4. Yasui M, Menjyo Y, Tokizane K, Shiozawa A, Tsuda M, Inoue K, et al. Hyperactivation of proprioceptors induces microglia-mediated long-lasting pain in a rat model of chronic fatigue syndrome. *J Neuroinflammation* 2019; 16(1):67.
5. Yasui M, Yoshimura T, Takeuchi S, Tokizane K, Tsuda M, Inoue K, et al. A chronic fatigue syndrome model demonstrates mechanical allodynia and muscular hyperalgesia via spinal microglial activation. *Glia* 2014;62(9):1407-1417.
6. Zhao YJ, Liu Y, Zhao YH, Li Q, Zhang M, Chen YJ. Activation of satellite glial cells in the trigeminal ganglion contributes to masseter mechanical allodynia induced by restraint stress in rats. *Neurosci Lett* 2015;602:150-155.
7. Manfredini D, Ahlberg J, Aarab G, Bracci A, Durham J, Ettlin D, et al. Towards a Standardized Tool for the Assessment of Bruxism (STAB)-Overview and general remarks of a multidimensional bruxism evaluation system. *J Oral Rehabil* 2020;47:549-556.
8. Manfredini D, Ahlberg J, Wetselaar P, Svensson P, Lobbezoo F. The bruxism construct: From cut-off points to a continuum spectrum. *J Oral Rehabil* 2019; 46(11):991-997.
9. Lobbezoo F, Ahlberg J, Raphael KG, Wetselaar P, Glaros AG, Kato T, et al. International consensus on the assessment of bruxism: Report of a work in progress. *J Oral Rehabil* 2018;45(11):837-844.
10. Raphael KG, Sirois DA, Janal MN, Wigren PE, Dubrovsky B, Nemelivsky LV, et al. Sleep bruxism and myofascial temporomandibular disorders: a laboratory-based polysomnographic investigation. *J Am Dent Assoc* 2012;143(11):1223-1231.
11. Wei F, Van Horn MH, Coombs MC, She X, Gonzales TS, Gonzalez YM, et al. A pilot study of nocturnal temporalis muscle activity in TMD diagnostic groups of women. *J Oral Rehabil* 2017; 44(7):517-525.
12. Iwasaki LR, Thornton BR, McCall WD, Jr., Nickel JC. Individual variations in numerically modeled human muscle and temporomandibular joint forces during static biting. *J Orofac Pain* 2004; 18(3):235-245.

13. Iwasaki LR, Gallo LM, Markova M, Erni S, Liu H, Nickel JC. Night-time autonomic nervous system ultradian cycling and masticatory muscle activity. *Orthod Craniofac Res* 2019;22(Suppl 1):107-112.
14. Iwasaki LR, Gonzalez YM, Liu Y, Liu H, Markova M, Gallo LM, et al. Mechanobehavioral Scores in Women with and without TMJ Disc Displacement. *J Dent Res* 2017;96(8):895-901.
15. Sluka KA, Clauw DJ. Neurobiology of fibromyalgia and chronic widespread pain. *Neuroscience* 2016;338:114-129.
16. Iwasaki LR, Gonzalez YM, Liu H, Marx DB, Gallo LM, Nickel JC. A pilot study of ambulatory masticatory muscle activities in temporomandibular joint disorders diagnostic groups. *Orthod Craniofac Res* 2015;18(Suppl 1):146-155.
17. Khawaja SN, Iwasaki LR, Dunford R, Nickel JC, McCall W, Crow HC, et al. Association of Masseter Muscle Activities during Awake and Sleep Periods with Self-Reported Anxiety, Depression, and Somatic Symptoms. *J Dent Health Oral Disord Ther* 2015;2(1).
18. Chichorro JG, Porreca F, Sessle B. Mechanisms of craniofacial pain. *Cephalalgia* 2017;37(7):613-626.
19. Zhang CK, Li ZH, Qiao Y, Zhang T, Lu YC, Chen T, et al. VGLUT1 or VGLUT2 mRNA-positive neurons in spinal trigeminal nucleus provide collateral projections to both the thalamus and the parabrachial nucleus in rats. *Mol Brain* 2018;11(1):22.
20. Kosek E, Altawil R, Kadetoff D, Finn A, Westman M, Le Maitre E, et al. Evidence of different mediators of central inflammation in dysfunctional and inflammatory pain--interleukin-8 in fibromyalgia and interleukin-1 beta in rheumatoid arthritis. *J Neuroimmunol* 2015;280:49-55.
21. Peterlik D, Flor PJ, Uschold-Schmidt N. The Emerging Role of Metabotropic Glutamate Receptors in the Pathophysiology of Chronic Stress-Related Disorders. *Curr Neuropharmacol* 2016;14(5):514-539.
22. Clark AK, Gruber-Schoffnegger D, Drdla-Schutting R, Gerhold KJ, Malcangio M, Sandkuhler J. Selective activation of microglia facilitates synaptic strength. *J Neurosci* 2015;35(11):4552-4570.
23. Kronschlager MT, Drdla-Schutting R, Gassner M, Honsek SD, Teuchmann HL, Sandkuhler J. Gliogenic LTP spreads widely in nociceptive pathways. *Science* 2016;354:1144-1148.
24. Zhou LJ, Liu XG. Glial Activation, A Common Mechanism Underlying Spinal Synaptic Plasticity? *Neurosci Bull* 2017;33(1):121-123.
25. Ji RR, Nackley A, Huh Y, Terrando N, Maixner W. Neuroinflammation and Central Sensitization in Chronic and Widespread Pain. *Anesthesiology* 2018; 129(2):343-366.
26. Schiffman E, Ohrbach R, Truelove E, Look J, Anderson G, Goulet JP, et al. Diagnostic Criteria for Temporomandibular Disorders (DC/TMD) for Clinical and Research Applications: recommendations of the International RDC/TMD Consortium Network* and Orofacial Pain Special Interest Groupdagger. *J Oral Facial Pain Headache* 2014;28(1):6-27.
27. Kroenke K. Physical symptom disorder: a simpler diagnostic category for somatization-spectrum conditions. *J Psychosom Res* 2006; 60(4):335-339.
28. Kroenke K, Spitzer RL, Williams JB. The PHQ-15: validity of a new measure for evaluating the severity of somatic symptoms. *Psychosom Med* 2002; 64(2):258-266.
29. Lowe B, Kroenke K, Herzog W, Grafe K. Measuring depression outcome with a brief self-report instrument: sensitivity to change of the Patient Health Questionnaire (PHQ-9). *J Affect Disord* 2004; 81(1):61-66.
30. Von Korff M, Ormel J, Keefe FJ, Dworkin SF. Grading the severity of chronic pain. *Pain* 1992;50(2):133-149.
31. Huguet G, Joglekar A, Messi LM, Buckalew R, Wong S, Terman D. Neuroprotective Role of Gap Junctions in a Neuron Astrocyte Network Model. *Biophys J* 2016;111(2):452-462.
32. Radovanovic D, Peikert K, Lindstrom M, Domellof FP. Sympathetic innervation of human muscle spindles. *J Anat* 2015;226(6):542-548.

33. Roatta S, Windhorst U, Ljubisavljevic M, Johansson H, Passatore M. Sympathetic modulation of muscle spindle afferent sensitivity to stretch in rabbit jaw closing muscles. *J Physiol* 2002;540:237-248.
34. Schwarz PB, Mir S, Peever JH. Noradrenergic modulation of masseter muscle activity during natural rapid eye movement sleep requires glutamatergic signalling at the trigeminal motor nucleus. *J Physiol* 2014;592(16):3597-3609.
35. Fillingim RB, Slade GD, Greenspan JD, Dubner R, Maixner W, Bair E, et al. Long-term changes in biopsychosocial characteristics related to temporomandibular disorder: findings from the OPPERA study. *Pain* 2018;159(11):2403-2413.
36. Reader BF, Jarrett BL, McKim DB, Wohleb ES, Godbout JP, Sheridan JF. Peripheral and central effects of repeated social defeat stress: monocyte trafficking, microglial activation, and anxiety. *Neuroscience* 2015;289:429-442.
37. Eisenlohr-Moul TA, Crofford LJ, Howard TW, Yepes JF, Carlson CR, de Leeuw R. Parasympathetic reactivity in fibromyalgia and temporomandibular disorder: associations with sleep problems, symptom severity, and functional impairment. *J Pain* 2015; 16(3):247-257.
38. Delpech JC, Madore C, Nadjar A, Joffre C, Wohleb ES, Laye S. Microglia in neuronal plasticity: Influence of stress. *Neuropharmacology* 2015; 96:19-28.
39. Euteneuer F, Schwarz MJ, Hennings A, Riemer S, Stapf T, Selberdinger V, et al. Psychobiological aspects of somatization syndromes: contributions of inflammatory cytokines and neopterin. *Psychiatry Res* 2012;195:60-65.

POST-PUBERTAL ASSESSMENT OF THE DENTOSKELETAL EFFECTS PRODUCED BY THE ALT-RAMEC PROTOCOL FOR THE EARLY TREATMENT OF CLASS III MALOCCLUSION

Lorenzo Franchi, Veronica Giuntini, James A. McNamara Jr., Caterina Masucci

ABSTRACT

The aim of this retrospective study was to evaluate the post-pubertal effects of the Alt-RAMEC and facial mask (FM) approach in juvenile Class III patients. Twenty-one juvenile patients (6.5 ± 0.7 years of age) treated with the Alt-RAMEC/FM treatment approach were evaluated by means of lateral cephalograms taken at 3 observation times: before treatment (T1), after treatment (T2) and in the long term (T3). The Alt-RAMEC/FM group was compared to a sample of 22 Class III patients (6.9 ± 1.2 years) who were treated with a combined rapid maxillary expansion (RME) and FM approach. At T3, all patients presented with a post-pubertal skeletal maturation stage (CS4-CS6). Repeated Measures ANOVA test or Friedman's test was used to perform intra-group statistical analysis. Between-group statistical comparisons at T1 and on the T2-T1, T3-T2 and T3-T1 changes were assessed by means of the independent sample t-test or the Mann-Whitney U test. Both the Alt-RAMEC/FM and RME/FM protocols showed statistically significant favorable treatment outcomes (SNA $+2.2^\circ$ and $+1.6^\circ$, respectively; ANB $+3.6^\circ$ and $+2.8^\circ$, respectively). At the post-pubertal observation (T3), only the advancement of the maxilla (SNA $+2.0^\circ$ and $+1.9^\circ$, respectively) remained stable in both groups. In the short term, the Alt-RAMEC/FM group showed a statistically significant greater improvement in the Wits appraisal ($+1.6\text{mm}$) than did the RME/FM group. At the post-pubertal observation (T3), no statistically significant difference was found between the 2 groups. Neither of the two therapeutic approaches could be considered more efficient and effective than the other, both in the short and long term.

KEY WORDS: Class III malocclusion; Alt-RAMEC protocol; Cephalometrics; Growth modification

INTRODUCTION

The orthopedic treatment of Class III dentoskeletal disharmony always has been considered one of the most important challenges in orthodontics. Although the literature reports that the most commonly-used orthopedic protocol for the early correction of Class III dento-skeletal disharmony, represented by the Rapid Maxillary Expansion and Facemask protocol (RME/FM), is efficient and effective in the short term [1], the findings concerning the long-term stability of its effects have not been as positive [2, 3]. This observation is related to the unfavorable growth pattern that characterizes subjects presenting with Class III dento-skeletal disharmony [4, 5].

For this reason, during the last two decades the attention of researchers and clinicians has turned to the development and validation of new therapeutic approaches for the correction of Class III dento-skeletal disharmony, with the aim of improving the response to treatment and the stability of the treatment results in the long term.

Alternate Rapid Maxillary Expansion and Constriction (Alt-RAMEC) Protocol

In 2005, Liou et al. introduced the Alternate Rapid Maxillary Expansion and Constriction (Alt-RAMEC) protocol associated with intraoral protraction springs for the treatment of Class III malocclusion in cleft patients [6]. After applying a 2-hinged rapid maxillary expander to patients, Liou et al. proposed activating the expander following an alternating weekly sequence of expansion and constriction of the maxilla lasting 7-9 weeks, with the daily amount of expansion or constriction of 1 mm (4 turns).

The alternate activation and deactivation of the expander seemed to promote a more efficient and more extensive activation of the circummaxillary sutural system, including the sutures running coronally and articulating directly to the maxilla and the sutures running sagittally and coronally and articulating indirectly with the maxilla [7]. The increased degree of disarticulation of these sutures would favor a better response to the intraoral β -nickel-titanium springs in terms of protraction of the maxilla.

In a study by Liou et al. on the effectiveness of the Alt-RAMEC protocol in the context of the therapy of unilateral lip and palate cleft patients (ages 9 to 12-years) presenting with maxillary hypoplasia, the investigators compared a sample treated with Rapid Maxillary Expansion (RME, lasting one week) and intraoral protraction springs used during the following 6 months to a sample treated with Alt-RAMEC protocol (lasting 9 weeks) and intraoral protraction springs used during the following 3 months [8]. The results showed that the patients treated according to the Alt-RAMEC protocol achieved a significantly greater advancement of the maxilla (anterior displacement of Point A of 5.8 ± 2.3 mm), compared to the sample treated by means of RME (anterior displacement of Point A of 2.6 ± 1.5 mm).

Overview of the Alt-RAMEC and facial mask (FM) protocol

Motivated by the positive data reported by Liou and collaborators, several investigators began to use the Alt-RAMEC protocol in association with the facial mask for the treatment of Class III dento-skeletal disharmony in growing patients [9-11].

The early studies on the effects of the Alt-RAMEC protocol in association with facial mask therapy showed inconsistent results. Do-deLatour and coworkers in 2009 [9] found no statistically significant differences in terms of treatment outcomes between the Class III sample (9 subjects, age 8.6 ± 1.2 years) treated with the RME/FM standard protocol and the Class III sample (9 subjects, age 8.5 ± 1.2 years) treated with a 7-weeks-Alt-RAMEC protocol and facial mask. In contrast, in 2010 Isci et al. [10] found that a 4-weeks-Alt-RAMEC/FM protocol achieved a significantly greater maxillary advancement (VRL-A 4.1 ± 1.2 mm) with respect to the conventional RME/FM therapy (2.3 ± 1.2 mm) in a sample of 11-year-old Class III patients (15 subjects per group).

In order to avoid the potential periodontal problems around the permanent teeth due to the jiggling movement related to the alternation of expansion and constriction and at the same time to improve the maxillary response to protraction treatment, in 2011 Franchi and collaborators introduced a modified Alt-RAMEC protocol that was used in young Class III patients presenting in the deciduous or early mixed dentition [11, 12]. The alternate sequence of expansion and constriction lasted 4 weeks with 2 activation/deactivation cycles per day (0.4 mm), followed by an expansion phase in order to correct the transversal discrepancy before the protraction phase with the facial mask.

Another study by Masucci et al. evaluated the effects of the modified Alt-RAMEC protocol used in association with facial mask for the early correction of Class III dento-skeletal disharmony [13]. The investigators compared a group of 31 patients (age 6.4 ± 0.8 years) treated with the Alt-RAMEC/FM approach with a group of 31 patients treated with the conventional RME/FM protocol (age 6.9 ± 1.1 years) and a control group of 21 Class III untreated subjects (age 6.5 ± 1.0 years). At the end of active orthopedic therapy, both the Alt-RAMEC/FM group and the RME/FM group showed very favorable effects in terms of maxillary

advancement. The Alt-RAMEC group presented with a statistically significant greater improvement in the sagittal position of the maxilla than did the RME/FM group (SNA change Alt-RAMEC/FM group vs RME/FM = 1.2°).

A randomized controlled trial conducted in 2015 by Liu et al. found similar results [14]. After providing two different types of treatment, a 7-weeks-Alt-RAMEC/FM therapy or a conventional RME/FM therapy, to a sample of 7- to 13-year-old Class III patients, the investigators analyzed the treatment outcomes in the two groups. A statistically significant greater forward movement of Point A was reported in the Alt-RAMEC/FM group (A-VRL 3.0±1.4 mm) with respect to the RME/FM group (A-VRL 2.1±1.0 mm). Although a difference of 0.9 mm was statistically significant, however, the investigators concluded that this difference was not clinically relevant.

During the last decade, with the increasingly common use of the cone beam computed tomography (CBCT) in orthodontics, it was possible to identify the three-dimensional changes obtained with this type of orthopedic therapy. By means of a 3D-analysis of CBCTs, Fischer et al. compared a sample of 17 Class III patients (age 6.0 ± 0.9 years) treated with a 6-weeks-Alt-RAMEC/FM protocol compared to with a sample of 17 Class III patients (age 6.3 ± 0.8 years) treated with the standard RME/FM protocol [15]. The Alt-RAMEC/FM and RME/FM protocols produced similar skeletal and dental effects, with neither group providing more favorable outcomes; for both groups the skeletal protraction effects were represented by a forward (50% A-P) and downward (50% S-I) movement; the forward and downward dental movement was greater with respect to skeletal movements.

On the other hand, using other valid tools of investigation to confirm the effectiveness of orthopedic treatment with the Alt-RAMEC protocol for the correction of Class III malocclusion in growing patients, investigators have performed several systematic reviews and a meta-analysis [16, 17]. In 2018, Almuzian et al. carried out a systematic review and meta-analysis on the effectiveness of the Alt-RAMEC/FM approach to treat the Class III disharmony in growing patients; only RCTs were considered [16]. The final number of trials included was 5 for the systematic review and 4 for the meta-analysis, with all studies comparing a group treated with the Alt-RAMEC/FM protocol and a group treated with the RME/FM protocol.

Regarding the results of the meta-analysis, a total of 117 Chinese Class III patients (initial ages ranging from 9.8 to 12.1 years) were analyzed. The authors reported a greater amount of protraction of the maxilla and a greater improvement of the skeletal sagittal intermaxillary relationship obtained with the Alt-RAMEC/FM protocol with respect to the RME/FM protocol (SNA mean difference Alt-RAMEC/FM protocol vs. RME/FM protocol = 1.2°; ANB mean difference Alt-RAMEC/FM protocol vs. RME/FM protocol = 0.7°).

Similar outcomes were shown by a recent meta-analysis by Wu et al. on the effects of skeletal anchored and tooth anchored maxillary protraction in Class III growing patients [17]. The evaluation of the 26 selected studies demonstrated that the Alt-RAMEC/FM approach was more effective in terms of maxillary protraction with respect to the RME/FM approach (SNA mean difference 1.3°). However, both groups of investigators concluded that high-quality, long-term follow-up studies were needed to confirm the effectiveness and efficiency of the Alt-RAMEC protocol in the correction of Class III dento-skeletal disharmony in growing patients [16, 17].

As mentioned earlier, some relapse/rebound over the long term characterizes the orthopedic treatment of Class III malocclusion, due to the unfavorable growth pattern of Class III patients [3-5]. For this reason, it would be interesting to assess the long term stability of the effects of the Alt-RAMEC/FM protocol and to compare them with the long term effects of RME/FM therapy to determine if the statistically significant—but in many studies not clinically significant—supplemental amount of maxillary advancement achieved by means of the Alt-RAMEC/FM protocol with respect to the RME/FM protocol could play a relevant role in ensuring greater stability of the outcomes of Class III orthopedic treatment results.

Therefore, the present retrospective study was aimed to evaluate the post-pubertal effects of the Alt-RAMEC/FM approach in growing Class III patients and to compare these effects with the ones produced by the conventional RME/FM protocol.

SUBJECTS AND METHODS

The present study obtained the ethical approval (#2020/0000005) from the Pediatric Ethics Committee of the Region of Tuscany, Italy, and informed consent was obtained from each patient family before treatment. Twenty-one patients (11 males and 10 females, mean age 6.5 ± 0.7 yr) presenting with Class III malocclusion and who were consecutively treated at the Orthodontic Clinic of the Careggi University Hospital in Florence with the modified Alt-RAMEC and facial mask protocol (Alt-RAMEC/FM group) (Franchi et al., 2011) during an early stage of skeletal maturation (CS1-CS2) were included in the study [18]. Lateral cephalograms were taken before treatment (T1), at the end of active phase of treatment (T2; mean age 8.3 ± 0.8 yr) and in the long term, about 7 years after the end of active phase of treatment with the Alt-RAMEC/FM protocol (T3; mean age 15.2 ± 1.1 yr). At T3, the patients were in a postpubertal stage of skeletal maturation (CS4-CS6).

The Alt-RAMEC/FM group was compared with a sample of 22 patients (9 males and 13 females, mean age 6.9 ± 1.2 yr) with Class III malocclusion, treated consecutively at the Orthodontic Clinic of the Careggi University Hospital in Florence with a conventional Rapid Maxillary Expansion and facial mask protocol (RME/FM group). The RME/FM group presented with lateral cephalograms taken at the same observation time points as in the Alt-RAMEC/FM group: T1 (before treatment), T2 (at the end of active phase of treatment; age 8.5 ± 1.2 yr) and T3 (postpubertal observation, mean age 15.3 ± 1.2 yr).

All patients had to show the following dento-skeletal features when the pretreatment lateral cephalogram was taken before therapy (T1), to be included in the study:

- European ancestry (white);
- anterior crossbite or edge-to-edge incisor relationship;
- Class III molar relationship;
- Wits appraisal of -2.0 mm or less [19];
- absence of a CO-CR discrepancy (indicating pseudo-Class III malocclusion);
- deciduous or early mixed dentition;
- prepubertal skeletal maturation (CS1 to CS2) [18].

Alt-RAMEC/FM protocol

A maxillary acrylic-splint expander with soldered hooks used for elastics was delivered to all patients. The expander was bonded to the deciduous canines and the first and second deciduous molars [20]. The patient's family was instructed to activate the expansion screw (Leone A2620, Leone Orthodontic Products, Sesto Fiorentino, Firenze, Italy) twice a day (0.2 mm per turn) for one week; then they were instructed to deactivate the expansion screw twice a day for one week. This alternating protocol was repeated twice. After four weeks of Alt-RAMEC therapy, additional maxillary expansion by means of a twice-daily activation of the midline screw was performed until the desired maxillary transverse width was achieved.

At the end of the expansion phase, a facial mask according to the design of Petit (Dynamic Face Mask, Leone Orthodontic Products, Sesto Fiorentino, Firenze, Italy) was delivered to the patients for maxillary

protraction. The extraoral elastics produced orthopedic forces of as much as 400- 500g per side; the elastics were attached from the hooks on the maxillary expander to the support bar of the facial mask in a downward and forward direction of about 30° to the occlusal plane [21]. The patients were instructed to wear the facial mask 14 hours per day for six months, followed by wearing the facial mask at night only for an additional six months.

For all patients a positive dental overjet was achieved before discontinuing treatment, and most of them were overcorrected toward a Class II occlusal relationship. The average duration of Alt-RAMEC/FM treatment was 1.1 ± 0.1 years. After the active therapy with the facial mask, all patients wore a removable mandibular retractor as a retention appliance for at least one year [22]. Between the end of the retention period and the long-term observation (T3) 3 patients underwent a second phase of facial mask treatment and 11 patients underwent fixed appliance therapy.

RME/FM protocol

An acrylic splint expander was bonded to the deciduous canines and the first and second deciduous molars and included the permanent first molars if these teeth were erupted. The expansion screw (Leone A2620, Leone Orthodontic Products, Sesto Fiorentino, Firenze, Italy) was activated 1-2 times per day until the desired maxillary transverse width was achieved. The facial mask was delivered immediately after the end of the expansion phase. The clinical management of the facial mask therapy was similar to the Alt-RAMEC/FM group. All patients were treated at least to a positive dental overjet before discontinuing treatment and most of them were overcorrected toward a Class II occlusal relationship. The average duration of RME/FM treatment was 1.1 ± 0.2 years. A removable mandibular retractor was worn by all patients for at least one year after the end of orthopedic treatment with the facial mask [22]. Six patients underwent a second phase of facial mask treatment and 12 patients underwent a multibrackets therapy before the long-term observation (T3).

As occurs in studies involving any removable device, compliance with the instructions of the orthodontist and staff varied among patients. Therefore, the degree of compliance was monitored and recorded by the clinician at each appointment (every 5 weeks) by questioning the patient's parents about the time during which the patients wore the facial mask. The compliance was appraised by means of a 3-point Likert scale (poor, moderate, good) [23]. Poor compliance was noted if the facial mask was not worn during the day and not regularly at night, moderate compliance when the facial mask was worn regularly only at night, and good compliance when the facial mask was worn 14 hours per day (at night and 3 hours in the afternoon) for the first six months and then at night only for another six months.

Cephalometric Analysis

A customized digitization regimen and analysis provided by Viewbox 3.0. (dHAL Software, Kifissia, Greece) was used to perform the evaluation of the cephalograms in the present study. The cephalometric analysis contained measurements from the analyses of Jacobson, McNamara and Steiner [19, 24, 25]. Thirteen variables, 7 angular and 6 linear, were evaluated for each tracing (Figs. 1 and 2). Magnification was standardized to a 0% enlargement (life size) for all radiographs in the three samples.

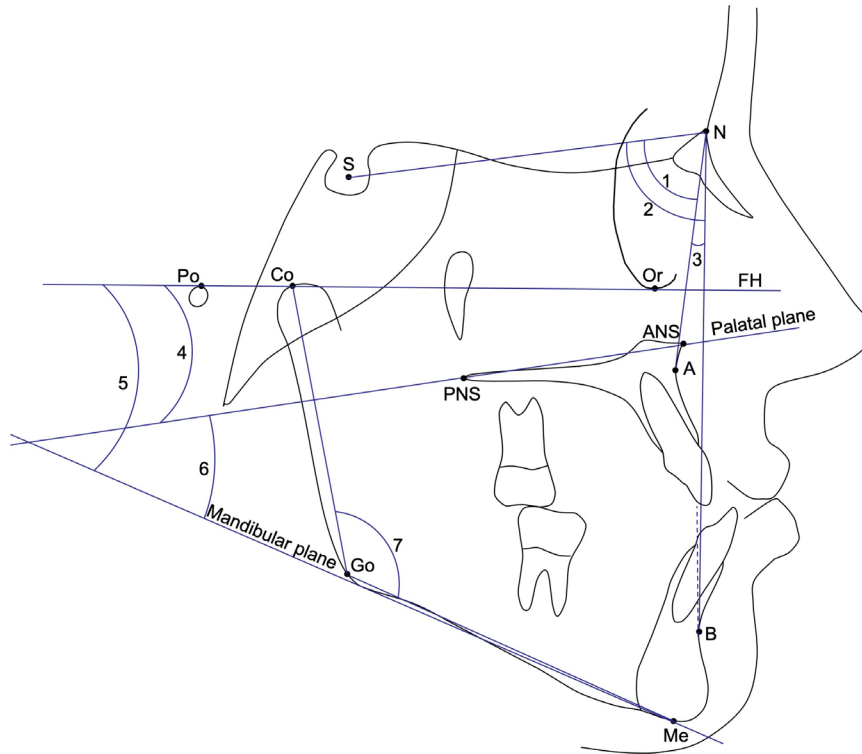


Figure 1. Cephalometric angular measurements. 1 = SNA; 2 = SNB; 3 = ANB; 4 = Frankfort Horizontal (FH) to Palatal Plane; 5 = FH to Mandibular Plane; 6 = Palatal Plane to Mandibular Plane; 7 = CoGoMe.

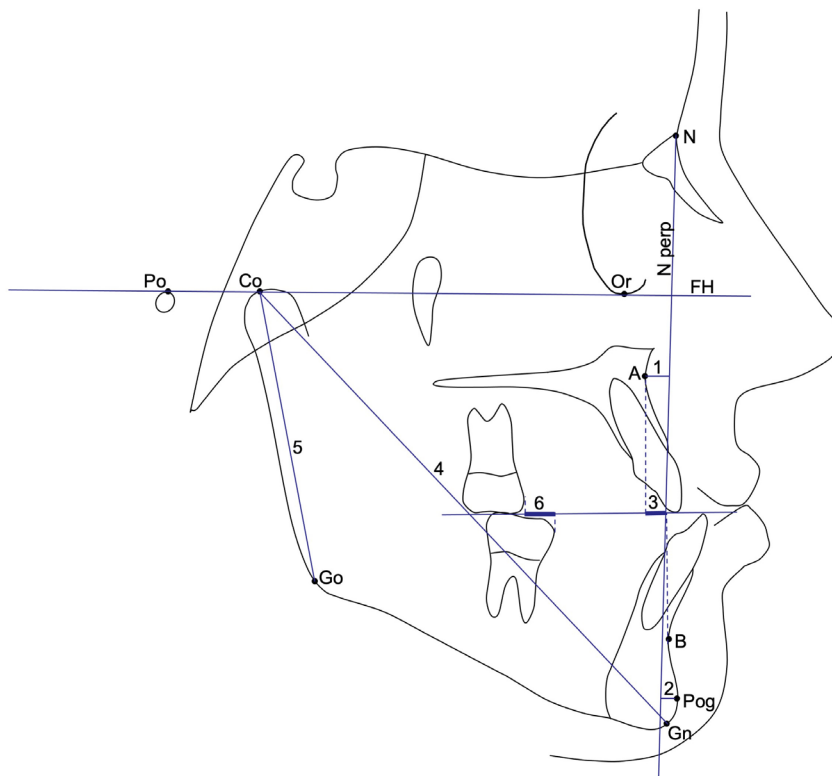


Figure 2. Cephalometric linear measurements. 1 = A to Nasion perpendicular (N perp) ; 2 = Pogonion (Pog) to N perp; 3 = Wits appraisal; 4 = Co-Gn; 5 = Co-Go; 6 = Molar relationship.

Statistical analysis

To assess differences in gender distribution and in the degree of compliance distribution between groups, the Fisher exact test was used. Descriptive statistics and intra-group statistical comparisons for age and all cephalometric variables in the 2 groups at T1, T2, and T3 were calculated by means of the Repeated Measures ANOVA test or Friedman's test. Descriptive statistics and statistical comparisons between the Alt-RAMEC/FM group and the RME/FM group at T1 (starting forms) and for the T2-T1, T3-T2 and T3-T1 changes were assessed by means of the independent sample t-test for the normally distributed variables or by means of the Mann-Whitney U test for the other variables.

Method error

Twenty lateral cephalograms, selected randomly, were traced and measured at 2 times within a week by the same operator (CM). The measurements for each patient at both times were analyzed with the Intraclass correlation coefficient (ICC) for the assessment of the systematic error and with the method of moments estimator (MME) [26] for the assessment of the random error. It has been suggested that MME formula should replace Dahlberg's formula when there are fewer than 25-30 cases replicated [26].

RESULTS

An excellent intra-rater agreement was found, with the values varying between 0.84 for the Wits appraisal and 0.99 for SNB, Pal PI - Mand PI and CoGn. Random error ranged from a minimum of 0.4 for SNB and Molar Relationship to a maximum of 1.3 for Pog to N perp and CoGo. No statistically significant difference was found between the 2 groups for gender distribution (Fisher exact probability test $p=0.547$)

Appraisal of compliance

The analysis of collaboration showed a similar distribution of "poor", "moderate", and "good" degree of cooperation during the orthopedic therapy (i.e., use of the facial mask) in the 2 groups. The Alt-RAMEC group presented with 12 patients with "good" degree of collaboration, 6 patients with "moderate" degree of collaboration, and 3 patients with "poor" degree of collaboration. In the RME/FM group there were 16 patients with "good" degree of collaboration, 4 patients with "moderate" degree of collaboration, and 2 patients with "poor" degree of collaboration. No significant difference was found in the prevalence rates of degree of collaboration between the 2 treated groups (Fisher exact probability test $p=0.585$).

T2-T1 Changes

Descriptive statistics and statistical comparisons at the 3 time periods for the Alt-RAMEC/FM group and for the RME/FM group are reported in Tables 1 and 2. With regard to treatment effects (T2-T1 changes), both the Alt-RAMEC/FM group and the RME/FM group showed statistically significant favorable improvements in terms of sagittal position of the maxilla (SNA $+2.2^\circ$ and $+1.6^\circ$, respectively; A to N perp $+2.0\text{mm}$ and $+1.5\text{mm}$, respectively) and intermaxillary sagittal skeletal relationship (ANB $+3.6^\circ$ and $+2.8^\circ$, respectively). An evaluation of the mandibular sagittal skeletal effects demonstrated a statistically significant decrease in mandibular projection in both Alt-RAMEC/FM and RME/FM groups (SNB -1.3° and -1.2° , respectively).

Table 1. Descriptive statistics and statistical comparisons (Repeated Measures ANOVA) at the 3 time periods for the Alt-RAMEC/FM group.

Variables	T1		T2		T3		T2-T1	T3-T2	T3-T1
	Mean	SD	Mean	SD	Mean	SD			
Age	6.5	0.7	8.3	0.8	15.2	1.1	1.8***	6.9***	8.7***
SNA	80.6	3.8	82.8	4.0	82.6	4.8	2.2***	-0.2ns	2.0***
A to N perp	0.5	3.1	2.5	3.3	2.4	3.3	2.0***	-0.1ns	1.9**
SNB	79.3	3.6	78.0	3.7	80.3	4.4	-1.3**	2.3***	1.0sn
Pog to N perp	-0.7	5.6	-2.4	6.1	2.7	5.8	-1.7ns	5.1**	3.4*
ANB	1.2	1.9	4.8	1.9	2.2	2.0	3.6***	-2.6***	1.0ns
Wits	-4.4	1.8	-2.7	3.1	-2.8	3.3	1.7ns	-0.1ns	1.6ns
FH-Pal. Pl.	-2.1	3.1	-2.5	3.1	-1.9	3.2	-0.4ns	0.6ns	0.2ns
FH-Mand. Pl.	24.6	3.9	26.0	3.7	22.5	4.5	1.4*	-3.5***	-2.1**
Pal. Pl. – Mand. Pl.	26.7	3.9	28.5	4.2	24.3	4.6	1.8**	-4.2***	-2.4*
CoGn	92.8	6.8	96.1	6.4	114.7	8.3	3.3***	18.6***	21.9***
CoGo	42.1	4.2	44.2	3.9	54.6	5.9	2.1***	10.4***	12.5***
CoGoMe	129.2	3.0	127.6	4.1	125.7	5.1	-1.6*	-1.9*	-3.5***
Mol. Rel.	2.8	1.2	-0.8	1.6	2.2	2.2	-3.6***	3.0***	-0.6ns

ns: not significant; * P<0.05; **P<0.01; *** P<0.001

N: Nasion; Perp.: Perpendicular; Pog: Pogonion; FH: Frankfort Horizontal; Pal.: Palatal; Pl.: Plane; Mand.: Mandibular; Mol.: Molar; Rel.: Relationship; IQR: Interquartile Range.

As for the vertical skeletal variables, 3 variables were considered: the mandibular plane angle relative to FH, the angle between the palatal plane and the mandibular plane, and the palatal plane angle relative to FH. Statistically significant increases were found for the mandibular plane angle (+1.4°) and for the angle between the palatal plane and the mandibular plane (+1.8°) in the Alt-RAMEC/FM group. The RME/FM group showed a statistically significant reduction of the palatal plane angle (-1.0°) and a statistically significant increase of the angle between the palatal plane and the mandibular plane (+2.0°).

The Alt-RAMEC/FM protocol also produced a statistically significant decrease of the mandibular angle (CoGoMe -1.6°). The sagittal dental relationship showed favorable improvements in both the Alt-RAMEC/FM and in the RME/FM groups (Mol Rel -3.6mm and -2.9mm, respectively), both of which were statistically significant.

T3-T2 Changes

During the post-treatment period (T3-T2), the Alt-RAMEC/FM group and the RME/FM group presented with a statistically significant increase in the sagittal projection of the mandible (SNB +2.3° and +2.7°, respectively; Pog to N perp +5.1mm and +4.6mm, respectively) and a statistically significant relapse/rebound in terms of the sagittal skeletal intermaxillary relationship (ANB -2.6° and -2.4°, respectively); similar changes were observed in the sagittal dental relationship (Mol Rel +3.0mm in both groups).

As for the vertical skeletal variables, the 2 groups showed a statistically significant closure of the mandibular plane angle (-3.5° and -1.9°, respectively) and a statistically significant decrease of the angle

between the palatal plane and the mandibular plane (-4.2° and -3.1°, respectively). The RME/FM group exhibited a statistically significant increase of the palatal plane angle (+1.0°). During the post-treatment period, the mandibular angle revealed a statistically significant decrease in both Alt-RAMEC/FM and RME/FM groups (-1.9° and -2.6°, respectively).

Table 2. Descriptive statistics and statistical comparisons (Repeated Measures ANOVA) at the 3 time periods for the RME/FM group.

Variables	T1		T2		T3		T2-T1	T3-T2	T3-T1
	Mean	SD	Mean	SD	Mean	SD			
Age	6.9	1.2	8.5	1.2	15.3	1.2	1.6***	6.8***	8.4***
SNA	80.2	4.2	81.8	4.5	82.1	5.0	1.6***	0.3ns	1.9**
A to N perp	-0.2	2.8	1.3	3.2	1.4	3.2	1.5***	0.1ns	1.6**
SNB	79.0	3.8	77.8	3.6	80.5	4.8	-1.2**	2.7***	1.5ns
Pog to N perp	-2.0	4.8	-3.1	5.5	1.5	6.3	-1.1ns	4.6**	3.5*
ANB	1.2	1.8	4.0	2.1	1.6	2.8	2.8***	-2.4***	0.4ns
Wits	-3.9	1.6	-3.5	1.6	-4.0	2.8	0.4ns	-0.5ns	-0.1ns
FH-Pal. Pl.	-1.0	3.6	-2.0	3.1	-0.9	3.1	-1.0*	1.1*	0.1ns
FH-Mand. Pl.	24.1	4.9	25.1	5.5	23.2	5.7	1.0ns	-1.9**	-0.9ns
Pal. Pl. – Mand. Pl.	25.1	4.9	27.1	6.1	24.0	6.0	2.0***	-3.1***	-1.1ns
CoGn	89.2	5.6	93.7	5.9	113.2	8.6	4.5***	19.5***	24.0***
CoGo	41.3	3.0	43.9	2.9	54.5	4.9	2.6***	10.6***	13.2***
CoGoMe	128.7	4.8	127.7	5.7	125.1	5.4	-1.0ns	-2.6***	-3.6***
Mol. Rel.	2.6	1.3	-0.3	1.4	2.7	1.7	-2.9***	3.0***	0.1ns

ns: not significant; * P<0.05; **P<0.01; *** P<0.001

N: Nasion; Perp.: Perpendicular; Pog: Pogonion; FH: Frankfort Horizontal; Pal.: Palatal; Pl.: Plane; Mand.: Mandibular; Mol.: Molar; Rel.: Relationship.

T3-T1 Changes

In the overall observation period (T3-T1), the advancement of the maxilla was statistically significant in both Alt-RAMEC/FM and RME/FM groups (SNA +2.0° and +1.9°, respectively; A to N perp +1.9mm and +1.6mm, respectively), while the correction of the sagittal skeletal intermaxillary relationship was not statistically significant in either group. On the other hand, both groups showed a statistically significant increase in mandibular projection (Pog to N perp +3.4mm in the Alt-RAMEC/FM group and +3.5mm in the RME/FM group). A statistically significant decrease for both the mandibular plane angle (-2.1°) and the angle between the palatal plane and the mandibular plane (-2.4°) was found only in the Alt-RAMEC/FM group. The mandibular angle appeared reduced in both Alt-RAMEC/FM and RME/FM groups (-3.5° and -3.6°, respectively) at statistically significant levels.

Table 3. Descriptive statistics and statistical comparisons (independent sample t-test or Mann-Whitney U test) for the starting forms (baseline characteristics at T1).

Variables	AltRAMEC/FM		RME/FM		Diff.	P	95% C.I.	
	Mean <i>Median</i>	SD <i>IQR</i>	Mean <i>Median</i>	SD <i>IQR</i>			Lower	Upper
Age	6.5	0.7	6.9	1.2	-0.4	0.277	-1.0	0.3
SNA	80.6	3.8	80.2	4.2	0.4	0.774	-2.1	2.8
A to N perp	1.2	5.9	0.2	5.1	1.0	0.362		
SNB	79.3	3.6	79.0	3.8	0.3	0.766	-1.9	2.6
Pog to N perp	-0.7	5.6	-2.0	4.8	1.3	0.405	-1.9	4.6
ANB	1.2	1.9	1.2	1.8	0.0	0.980	-1.1	1.1
Wits	-4.4	1.8	-3.9	1.6	-0.5	0.378	-1.5	0.6
FH-Pal. Pl.	-2.1	3.1	-1.0	3.6	-1.1	0.282	-3.2	1.0
FH-Mand. Pl.	24.6	3.9	24.1	4.9	0.5	0.706	-2.2	3.3
Pal. Pl. – Mand. Pl.	26.7	3.9	25.1	4.9	1.6	0.239	-1.1	4.4
CoGn	92.8	6.8	89.2	5.6	3.6	0.065	-0.2	7.4
CoGo	42.1	4.2	41.3	3.0	0.8	0.487	-1.5	3.0
CoGoMe	129.2	3.0	128.7	4.8	0.5	0.665	-2.0	3.0
Mol. Rel.	2.8	1.2	2.6	1.3	0.2	0.653	-0.6	1.0

N: Nasion; Perp.: Perpendicular; Pog: Pogonion; FH: Frankfort Horizontal; Pal.: Palatal; Pl.: Plane; Mand.: Mandibular; Mol.: Molar; Rel.: Relationship; Diff.: Difference; C.I.: Confidence Interval; IQR: Interquartile Range

Between group comparisons

The descriptive statistics and statistical comparisons for age and the dento-skeletal features at T1 (starting forms) of the 2 groups are reported in Table 3. At T1, there were no statistically significant differences between the Alt-RAMEC/FM group and RME/FM group for any of the analyzed variables.

Table 4 reports the descriptive statistics and statistical comparisons between the 2 groups for the T2-T1 changes. No statistically significant differences were noted between the Alt-RAMEC/FM and the RME/FM groups regarding treatment outcomes except the correction of the sagittal intermaxillary relationship. The Alt-RAMEC/FM group showed a statistically significant greater increase in the Wits appraisal than did the RME/FM group (+ 1.6mm). Considering other treatment effects, the Alt-RAMEC/FM approach produced slightly more favorable (but not significant) modifications in terms of maxillary advancement (SNA diff +0.6°; A to N perp diff +0.5mm), mandibular projection control (Pog to N perp diff –0.6mm; CoGn -1.2mm) and correction of intermaxillary sagittal skeletal and dental relationship (ANB diff +0.8°; Mol. Rel. -0.7mm).

Descriptive statistics and statistical comparisons of the 2 groups for the T3-T2 changes are reported in Table 5. No statistically significant difference was found for any evaluated variable when the Alt-RAMEC/FM group and the RME/FM group were compared. However, during the post-treatment period, the Alt-RAMEC group showed a slightly greater decrease of the mandibular plane angle (diff -1.6°) and of the angle between the palatal plane and the mandibular plane (diff -1.1°), and a slightly better control of the mandibular length (CoGn diff -0.9mm) in comparison to the RME/FM group. On the contrary the mandibular angle was slightly more opened in the Alt-RAMEC/FM group vs the RME/FM group (CoGoMe diff +0.7°).

Table 4. Descriptive statistics and statistical comparisons (independent sample t-test or Mann-Whitney U test) for the T2-T1 changes.

Variables	AltRAMEC/FM		RME/FM		Diff.	P	95% C.I.	
	Mean <i>Median</i>	SD <i>IQR</i>	Mean <i>Median</i>	SD <i>IQR</i>			Lower	Upper
Age	1.8	0.4	1.6	0.5	0.2	0.357	-0.1	0.4
SNA	2.2	1.5	1.6	1.4	0.6	0.141	-0.2	1.5
A to N perp	2.0	1.2	1.5	1.2	0.5	0.192	-0.3	1.3
SNB	-1.3	1.8	-1.2	1.5	-0.1	0.787	-1.1	0.9
Pog to N perp	-1.7	3.1	-1.1	2.7	-0.6	0.493	-2.4	1.2
ANB	3.6	2.2	2.8	1.9	0.8	0.206	-0.5	2.0
Wits	1.7	3.7	0.1	1.7	1.6	0.020		
FH-Pal. Pl.	-0.4	1.9	-1.1	1.9	0.7	0.277	-0.5	1.8
FH-Mand. Pl.	1.4	2.1	1.0	1.9	0.4	0.530	-0.9	1.6
Pal. Pl. – Mand. Pl.	1.8	2.5	2.1	2.2	-0.3	0.748	-1.7	1.2
CoGn	3.3	2.8	4.5	2.7	-1.2	0.170	-2.9	0.5
CoGo	2.1	1.9	2.6	1.7	-0.5	0.359	-1.6	0.6
CoGoMe	-1.6	2.4	-1.0	2.2	-0.6	0.414	-2.0	0.8
Mol. Rel.	-3.6	1.8	-2.9	1.6	-0.7	0.174	-1.8	0.3

N: Nasion; Perp.: Perpendicular; Pog: Pogonion; FH: Frankfort Horizontal; Pal.: Palatal; Pl.: Plane; Mand.: Mandibular; Mol.: Molar; Rel.: Relationship; Diff.: Difference; C.I.: Confidence Interval; IQR: Interquartile Range

Table 5. Descriptive statistics and statistical comparisons (independent sample t-test) for the T3-T2 changes.

Variables	AltRAMEC/FM		RME/FM		Diff.	P	95% C.I.	
	Mean	SD	Mean	SD			Lower	Upper
Age	6.9	1.0	6.8	1.7	0.1	0.927	-0.8	0.9
SNA	-0.2	2.4	0.3	1.7	-0.5	0.404	-1.8	0.7
A to N perp	-0.1	3.0	0.1	2.0	-0.2	0.806	-1.8	1.4
SNB	2.4	2.3	2.7	2.9	-0.3	0.678	-1.9	1.3
Pog to N perp	5.0	6.6	4.6	5.3	0.4	0.821	-3.3	4.1
ANB	-2.6	2.2	-2.3	2.3	-0.3	0.743	-1.6	1.2
Wits	-0.1	3.9	-0.5	2.7	0.4	0.679	-1.6	2.5
FH-Pal. Pl.	0.6	3.4	1.1	1.8	-0.5	0.560	-2.2	1.2
FH-Mand. Pl.	-3.6	3.1	-2.0	2.8	-1.6	0.086	-3.4	0.2
Pal. Pl. – Mand. Pl.	-4.2	3.8	-3.1	3.2	-1.1	0.309	-3.2	1.1
CoGn	18.6	6.5	19.5	8.0	-0.9	0.686	-5.4	3.6
CoGo	10.4	4.4	10.5	4.5	-0.1	0.932	-2.9	2.6
CoGoMe	-1.9	3.2	-2.6	2.7	0.7	0.468	-1.1	2.5
Mol. Rel.	3.0	2.4	3.0	1.9	0.0	0.948	-1.3	1.4

N: Nasion; Perp.: Perpendicular; Pog: Pogonion; FH: Frankfort Horizontal; Pal.: Palatal; Pl.: Plane; Mand.: Mandibular; Mol.: Molar; Rel.: Relationship; Diff.: Difference; C.I.: Confidence Interval

Table 6 presents the descriptive statistics and statistical comparisons between the 2 groups for the T3-T1 changes. The statistical comparison between the changes produced by the Alt-RAMEC/FM and RME/FM approaches during the entire T3-T1 observation interval did not reveal any statistically significant differences. Nevertheless, the Alt-RAMEC/FM group showed a slightly higher stability of the treatment effects than did the RME/FM group in terms of correction of the sagittal skeletal and dental intermaxillary relationships (ANB diff +0.6°; Wits diff +1.7mm; Mol. Rel. -0.6mm). Vertically, the mandibular plane angle (diff -1.2°) and the angle between the palatal plane and the mandibular plane (diff -1.4°) showed a slightly greater decrease in the Alt-RAMEC/FM group vs the RME/FM group. Moreover, a slightly better control of mandibular dimensions was found for the Alt-RAMEC/FM group with respect to the RME/FM group (CoGn diff -2.1mm; CoGo diff -0.7mm, respectively).

Table 6. Descriptive statistics and statistical comparisons (independent sample t-test or Mann-Whitney U test) for the T3-T1 changes.

Variables	AltRAMEC/FM		RME/FM		Diff.	P	95% C.I.	
	Mean <i>Median</i>	SD <i>IQR</i>	Mean <i>Median</i>	SD <i>IQR</i>			Lower	Upper
Age	8.6	1.1	8.4	1.7	0.2	0.703	-0.7	1.0
SNA	2.0	2.0	1.9	2.2	0.1	0.844	-1.2	1.4
A to N perp	0.7	3.9	0.9	2.9	-0.2	0.990		
SNB	1.0	2.7	1.5	2.9	-0.5	0.588	-2.2	1.3
Pog to N perp	3.4	6.0	3.6	5.3	-0.2	0.907	-3.7	3.3
ANB	1.0	2.0	0.4	2.5	0.6	0.424	-0.8	2.0
Wits	1.6	3.5	-0.1	2.9	1.7	0.092	-0.3	3.7
FH-Pal. Pl.	0.2	2.8	0.1	2.5	0.1	0.857	-1.5	1.8
FH-Mand. Pl.	-2.2	2.9	-1.0	3.1	-1.2	0.199	-3.1	0.7
Pal. Pl. – Mand. Pl.	-2.4	3.7	-1.0	3.1	-1.4	0.211	-3.4	0.8
CoGn	21.9	6.8	24.0	8.4	-2.1	0.378	-6.8	2.6
CoGo	12.5	4.9	13.2	4.9	-0.7	0.673	-3.6	2.4
CoGoMe	-3.5	3.4	-3.6	2.6	0.1	0.943	-1.8	1.9
Mol. Rel.	-0.6	1.6	0.0	1.8	-0.6	0.202	-1.7	0.4

N: Nasion; Perp.: Perpendicular; Pog: Pogonion; FH: Frankfort Horizontal; Pal.: Palatal; Pl.: Plane; Mand.: Mandibular; Mol.: Molar; Rel.: Relationship; Diff.: Difference; C.I.: Confidence Interval

DISCUSSION

The Alt-RAMEC/FM protocol has been considered an effective and efficient approach to treat the Class III dentoskeletal disharmony in growing patients [13]. Most of the recent literature has reported that in comparison to conventional RME/FM therapy, the Alt-RAMEC/FM protocol was able to produce more statistically significant favorable outcomes in terms of protraction of the maxilla and improvement of the sagittal skeletal intermaxillary relationship [16, 17]. On the contrary, the study on the three-dimensional changes obtained with the Alt-RAMEC/FM approach, carried out by Fischer et al., showed very similar skeletal and dental effects for the Alt-RAMEC/FM and the RME/FM protocols [15]. These investigators [15-17], however agreed that more high-quality long-term studies were needed in order to confirm the post-pubertal stability of the results of the Alt-RAMEC/FM treatment and to recommend its use with respect to the RME/FM

protocol in the clinical practice. Therefore, the present retrospective study had the objective to evaluate the treatment effects of the Alt-RAMEC/FM approach and to assess their stability at a postpubertal observation.

Two samples of 6-year-old Class III patients were treated consecutively with the Alt-RAMEC/FM protocol (21 patients) or the RME/FM protocol (22 patients). Lateral cephalograms taken before treatment (T1), at the end of treatment (T2), and when all patients demonstrated a postpubertal skeletal maturation stage (T3), were analyzed.

The evaluation of the T2-T1 treatment outcomes showed that both the Alt-RAMEC/FM and the RME/FM protocols produced favorable effects in terms of maxillary advancement (SNA $+2.2^\circ$ and $+1.6^\circ$, respectively; A to N perp $+2.0\text{mm}$ and $+1.5\text{mm}$, respectively) and sagittal skeletal intermaxillary relationship (ANB $+3.6^\circ$ and $+2.8^\circ$, respectively). These data are similar to the results of the recent RCT carried out by Liu et al. [14]. For their 2 samples of 7 to 13 year-old Class III patients treated with the Alt-RAMEC/FM approach or with the RME/FM approach, these investigators reported favorable improvements for both sagittal position of the maxilla and sagittal skeletal intermaxillary relationship (SNA $+2.7^\circ$ and $+1.9^\circ$, respectively; ANB $+4.2^\circ$ and $+4.3^\circ$, respectively; Wits 3.7mm and $+3.3\text{mm}$, respectively). Likewise the statistically significant favorable decrease of the mandibular projection found in both the Alt-RAMEC/FM and RME/FM groups of the present study (SNB -1.3° and -1.2° , respectively) is consistent with the control of mandibular position showed by Liu and coauthors for the Alt-RAMEC/FM and the RME/FM groups (SNB -1.5° and -2.3° , respectively).

Regarding the evaluation of the vertical skeletal variables in this study, both the Alt-RAMEC/FM protocol and the RME/FM protocol produced a *clockwise* rotation of the mandibular plane ($+1.4^\circ$ and $+1.0^\circ$, respectively), while both treatment approaches showed an increase of the angle between the palatal plane and the mandibular plane ($+1.8^\circ$ and $+2.0^\circ$, respectively). The RCT by Liu et al. reported a similar degree of clockwise rotation of the mandible with respect to SN plane in the Alt-RAMEC/FM group ($+2.0^\circ$), while for the RME/FM group a greater amount of mandibular clockwise rotation was found ($+3.3^\circ$) [14].

When the treatment effects achieved with the Alt-RAMEC/FM approach were compared with the treatment outcomes of the RME/FM therapy, no significant differences were found for any of the evaluated variables, with the exception of the correction of the Wits appraisal, which was statistically significantly greater for the Alt-RAMEC/FM approach (Wits diff $+1.6\text{mm}$). These data apparently disagree with most of the studies in the literature that reported statistically significant differences between the 2 treatment approaches.

Liu et al. found that the Alt-RAMEC/FM protocol was able to produce statistically significant greater favorable effects in terms of maxillary protraction (A-VRL $+0.9\text{mm}$ and SNA $+0.7^\circ$) and limitation of the increase of the mandibular plane angle (-1.3°) with respect to the RME/FM protocol [14]. Consistently with the study by Liu and collaborators and differently from the present study, 3 recent meta-analysis [14, 16, 17] found statistically significant differences in terms of treatment effects between the Alt-RAMEC/FM and the RME/FM approaches.

More precisely, in agreement with Almuzian and collaborators, the Alt-RAMEC/FM protocol produced statistically significant greater improvement as for sagittal maxillary position ($+1.2^\circ$) and sagittal intermaxillary relationship ($+0.7^\circ$) than the RME/FM protocol [16]. The Alt-RAMEC/FM approach also induced a statistically significant minimal opening of the mandibular plane angle (-0.2°). Wu et al. reported similar results in terms of more efficient maxillary advancement with the Alt-RAMEC/FM therapy, showing statistically significant larger increase of the SNA angle ($+0.8^\circ$) with respect to the RME/FM protocol [17]. However, considering the actual values of the differences between the 2 treatment approaches reported by these authors, most of these differences, although statistically significant, are less than 1 degree or 1 mm, and probably are not clinically relevant. These values are consistent with the values found in the present study.

During the post-treatment period (T3-T2), both the Alt-RAMEC/FM and the RME/FM groups showed statistically significant modifications. In particular, a statistically significant relapse in sagittal skeletal and dental intermaxillary relationship (ANB -2.6° and -2.4° , respectively; Mol. Rel. +3.0mm in both groups) was found. Moreover, the mandibular projections showed a statistically significant increase in both Alt-RAMEC/FM and RME/FM groups (SNB $+2.3^{\circ}$ and $+2.7^{\circ}$, respectively; Pog to N perp +5.1mm and +4.6mm, respectively).

The vertical skeletal variables revealed a statistically significant reduction in the mandibular plane angle (-3.5° and -1.9° , respectively) and in the angle between the palatal plane and the mandibular plane (-4.2° and -3.1° , respectively). These data are consistent with the findings of the systematic review and meta-analysis on the long-term effects of maxillary protraction therapy performed by Lin et al. [3]. These authors reported that the samples treated with RME/FM protocol, in contrast to untreated Class III subjects, showed during the post-treatment period (T3-T2) a statistically significant decrease of the ANB angle (diff -0.8°) and of the mandibular plane angle (diff -0.9°). A statistically significant relapse of the maxillary advancement was also found by Lin et al. (SNA diff -0.7°), which differed from the present study results.

The statistical comparison between the Alt-RAMEC/FM group and the RME/FM group for the post-treatment changes (T3-T2) did not show any statistically significant difference between the 2 groups.

Evaluating the overall observation period (T3-T1), some statistically significant intra-group modifications were observed. Both the Alt-RAMEC/FM and the RME/FM protocols were able to achieve stable effects in terms of maxillary protraction as indicated by SNA ($+2.0^{\circ}$ and $+1.9^{\circ}$, respectively) and the relationship of Point A to the nasion perpendicular ($+1.9$ mm and $+1.6$ mm, respectively).

Both treatment approaches also produced a statistically significant decrease of the mandibular angle (-3.5° and -3.6° , respectively). On the other hand, at the post-pubertal evaluations only the Alt-RAMEC/FM group showed a statistically significant counterclockwise rotation of the mandible (-2.1°) together with a statistically significant closure of the angle between the palatal plane and the mandibular plane (-2.4°). The statistical comparison between the Alt-RAMEC/FM group and the RME/FM group for the changes during the overall observation interval showed no statistically significant differences.

Therefore, it is possible to state that both the Alt-RAMEC/FM and RME/FM approaches, when performed during the early stage of skeletal maturation, were able to produce very favorable effects immediately after treatment. These positive changes were partially lost during the post-treatment period of 7 years, leading to a slight relapse of the treatment outcomes. However, at the post-pubertal observation the Alt-RAMEC/FM and the RME/FM protocols showed a significantly stable advancement of the maxilla.

On the other hand, neither of the two therapeutic approaches could be considered more efficient and effective than the other, both in the short and long term. To date, therefore, from a clinical point of view, the Alt-RAMEC/FM protocol cannot be recommended as the approach of choice for the therapy of Class III dento-skeletal disharmony in very young subjects compared to the conventional RME/FM protocol.

CONCLUSIONS

- The Alt-RAMEC/FM and the RME/FM protocols are efficient approaches for the treatment of Class III dento-skeletal disharmony in growing patients.
- At the short-term evaluation both Alt-RAMEC/FM and RME/FM protocols produced favorable effects in terms of maxillary advancement, mandibular projection control and correction of sagittal skeletal and dental intermaxillary relationship.

- At the post-pubertal evaluation, the 2 treatment approaches presented with stable effects in terms of maxillary advancement. A closure of the mandibular angle also was found for both Alt-RAMEC/FM and RME/FM protocols.
- Neither protocol was more efficient than the other in both the short and long term.

REFERENCES

1. Cordasco G, Matarese G, Rustico L, Fastuca S, Caprioglio A, Lindauer SJ, Nucera R. Efficacy of orthopedic treatment with protraction facemask on skeletal Class III malocclusion: a systematic review and meta-analysis. *Orthod Craniofac Res* 2014;17:133-143.
2. Masucci C, Franchi L, Mucedero M, Defraia E, Cozza P, Baccetti T. Stability of rapid maxillary expansion and facemask therapy: a long-term controlled study. *Am J Orthod Dentofacial Orthop* 2011;140:493-500.
3. Lin Y, Guo R, Hou L, Fu Z, Li W. Stability of maxillary protraction therapy in children with Class III malocclusion: a systematic review and meta-analysis. *Clin Oral Investig* 2018;22:2639-2652.
4. Baccetti T, Franchi L, McNamara JA Jr. Growth in the untreated Class III subjects. *Semin Orthod* 2007;13:130-142.
5. Rutili V, Nieri M, Giuntini V, McNamara JA Jr, Franchi L. A multilevel analysis of craniofacial growth in subjects with untreated Class III malocclusion. *Orthod Craniofac Res* 2020;23:181-191.
6. Liou EJ. Effective maxillary orthopedic protraction for growing Class III patients: a clinical application simulates distraction osteogenesis. *Prog Orthod* 2005;6:154-171.
7. Wang YC, Chang PM, Liou EJ. Opening of circummaxillary sutures by alternate rapid maxillary expansions and constrictions. *Angle Orthod* 2009;79:230-234.
8. Liou EJ, Tsai WC. A new protocol for maxillary protraction in cleft patients: repetitive weekly protocol of alternate rapid maxillary expansions and constrictions. *Cleft Palate Craniofac J* 2005;42:121-127.
9. Do-deLatour TB, Ngan P, Martin CA, Razmus T, Gunel E. Effect of alternate maxillary expansion and contraction on protraction of the maxilla: a pilot study. *Hong Kong Dent J* 2009;6:72-82.
10. Isci D, Turk T, Elekdag-Turk S. Activation–deactivation rapid palatal expansion and reverse headgear in Class III cases. *Eur J Orthod* 2010;32:706-715.
11. Franchi L, Baccetti T, Masucci C, Defraia E. Early Alt-RAMEC and facial mask protocol in Class III malocclusion. *J Clin Orthod* 2011;45:601-609.
12. Franchi L, Baccetti T, McNamara JA Jr. Postpubertal assessment of treatment timing for maxillary expansion and protraction therapy followed by fixed appliances. *Am J Orthod Dentofacial Orthop* 2004;126:555-568.
13. Masucci C, Franchi L, Giuntini V, Defraia E. Short-term effects of a modified Alt-RAMEC protocol for early treatment of Class III malocclusion: a controlled study. *Orthod Craniofac Res* 2014;17:259-269.
14. Liu W, Zhou Y, Wang X, Liu D, Zhou S. Effect of maxillary protraction with alternating rapid palatal expansion and constriction vs expansion alone in maxillary retrusive patients: A single-center, randomized controlled trial. *Am J Orthod Dentofacial Orthop* 2015;148:641-651.
15. Fischer B, Masucci C, Ruellas A, Cevidanes L, Giuntini V, Nieri M, et al. Three-dimensional evaluation of the maxillary effects of two orthopaedic protocols for the treatment of Class III malocclusion: A prospective study. *Orthod Craniofac Res* 2018;21:248-257.
16. Almuzian M, McConnell E, Darendeliler MA, Alharbi F, Mohammed H. The effectiveness of alternating rapid maxillary expansion and constriction combined with maxillary protraction in the treatment of patients with a class III malocclusion: a systematic review and meta-analysis. *J Orthod* 2018;45:250-259.
17. Wu Z, Zhang X, Li Z, Liu Y, Jin H, Chen Q, Guo J. A Bayesian network meta-analysis of orthopaedic treatment in Class III malocclusion: Maxillary protraction with skeletal anchorage or a rapid maxillary expander. *Orthod Craniofac Res* 2020;23:1-15.
18. McNamara JA Jr, Franchi L. The cervical vertebral maturation method: A user’s guide. *Angle Orthod*

2018;88:133-143.

19. Jacobson A. The "Wits" appraisal of jaw disharmony. *Am J Orthod Dentofacial Orthop* 2003;124:470-479.
20. McNamara JA Jr, Brudon WL. *Orthodontics and dentofacial orthopedics*. Ann Arbor, Mich: Needham Press 2001.
21. Ngan PW, Hägg U, Yiu C, Wei SH. Treatment response and long-term dentofacial adaptations to maxillary expansion and protraction. *Semin Orthod* 1997;3:255-264.
22. Tollaro I, Baccetti T, Franchi L. Mandibular Skeletal Changes Induced by Early Functional Treatment of Class III Malocclusion: A Superimposition Study. *Am J Orthod Dentofacial Orthop* 1995;108:525-532.
23. Slakter MJ, Albino JE, Fox RN, Lewis EA. Reliability and stability of the Orthodontic Patient Cooperation Scale. *Am J Orthod* 1980;78:559-563.
24. McNamara JA Jr. A method of cephalometric evaluation. *Am J Orthod* 1984;86:449-469.
25. Steiner CC. Cephalometrics for you and me. *Am J Orthod* 1953;39:729-755.
26. Springate SD. The effect of sample size and bias on the reliability of estimates of error: a comparative study of Dahlberg's formula. *Eur J Orthod* 2012;34:158-163.

EVALUATING NEW APPROACHES TO THE TREATMENT OF CLASS II AND CLASS III MALOCCLUSIONS: THE CARRIERE® MOTION™ APPLIANCE

*James A McNamara Jr., Lorenzo Franchi,
Laurie McNamara McClatchey, Hera Kim-Berman*

ABSTRACT

This chapter provides an overview of the treatment effects produced by the Carriere® Motion™ appliance that can be used in the resolution of Class II and Class III malocclusions in patients at various maturational levels. This essay begins with a discussion of the force levels produced by intermaxillary elastics, a critical component of Carriere treatment characterized by heavy intermaxillary forces worn nearly full-time by the patient. The Carriere® Motion™ Class II (CM2) appliance was studied retrospectively in 34 adolescents at 3 timepoints: T1 (pretreatment), T2 (removal of CM2), and T3 (post fixed appliance treatment). The comparison group comprised 22 untreated Class II subjects analyzed at T1 and T3. The treatment effects observed were mainly dentoalveolar in nature, including substantial distal movement of the maxillary molars. Some modest skeletal changes also occurred, particularly in the sagittal position of the maxilla and in the vertical dimension. Mandibular length was not affected in comparison to controls. The Carriere® Motion™ Class III (CM3) appliance also was evaluated in 32 late adolescent and adult patients. Minimal skeletal changes were measured sagittally, with only a slight increase in lower anterior facial height observed during treatment. Most of the treatment changes were dentoalveolar in nature, including mesial movement of the maxillary dentition and distal movement of the mandibular dentition during CM3 treatment. Substantial changes in molar relationship and the Wits Appraisal also were observed. Thus, both the CM2 and CM3 appliances were efficient and effective in resolving underlying occlusal problems. Major skeletal treatment effects, however, were not recorded.

KEY WORDS: Carriere Motion Class II, Carriere Motion Class III, Intermaxillary Elastics, Cephalometrics, Treatment Effects

INTRODUCTION

The correction of sagittal malocclusion has long been a major component of routine care within orthodontic practices. The management of Class II and Class III interarch problems provides unique challenges to the clinician, especially in that a patient can present at many levels of maturation: juvenile, adolescent and adult. Thus, the stage of skeletal development is an important consideration in overall treatment success. In some situations, future growth can be helpful; in other situations, it is not.

The optimal time to intervene in a growing Class II patient has been shown to occur during the circumpubertal growth period, when the peak in mandibular growth typically occurs [1-3]. In contrast, early intervention during the prepubertal stage has been shown to be effective in the management of

Class III problems [4, 5]. If a patient present with a severe manifestation of either type of malocclusion in late adolescence or in adulthood, corrective jaw surgery with and without the extraction of permanent teeth remains a viable option.

There have been many attempts to improve routine orthodontic and dentofacial orthopedic treatments over the years, as is illustrated by the large number of appliances and therapies currently commercially available for both Class II and Class III correction. The focus of this chapter is to consider the treatment effects produced by a relatively new approach to sagittal correction—the Carriere® Motion™ appliance, which was introduced to the orthodontic specialty in 2004 by Dr. Luis Carriere of Barcelona, Spain. This treatment approach can be used to manage both Class II and Class III malocclusion in patients at a wide range of maturational stages. Treatment possibilities with this appliance system will be discussed in this chapter.

A DISCUSSION OF ELASTIC FORCE LEVELS

Before describing the Carriere® Motion™ appliances in detail, this chapter will focus on *intermaxillary elastics*, a topic that is not only relevant to the Carriere appliances, but more broadly to almost all orthodontic treatment protocols. Both the Carriere® Motion™ Class II (CM2) and Carriere® Motion™ Class III (CM3) appliances rely on heavy forces generated by Class II and Class III elastics, respectively.

It is well known that intermaxillary elastics are available in a wide range of materials and sizes, as exemplified by the 31 elastic types in the “Zoo Pack” series available through Ormco Corporation (Orange CA). For several of the authors, the most used elastics are *Ram* elastics, described by the manufacturer as a “1/4-inch 6 oz” elastic (Table 1). Another less commonly used elastic are *Fox* elastics, described as a “1/4-inch 3.5 oz” elastic. Logically one would assume that the *Ram* elastic would produce about twice the force than that of the *Fox* elastic, which in fact was the case when tested. We conducted a pilot study of forces generated by these two elastics, measuring the forces generated by *Fox* and *Ram* elastics in a standardized Class II or Class III configuration on a typodont [6]. When stretched, the *Fox* elastic generated about 125 g of force, the *Ram* elastic about 250 g of force (Table 1).

Table 1. Forces generated by intermaxillary elastics.

Type of Elastic	Size	Strength	Force Generated
Fox	1/4-inch	3.5 oz	125 g
Ram	1/4-inch	6 oz	250 g
Force 1	1/4-inch	6 oz	375 g
Force 2	3/16-inch	8 oz	540 g

The developer of the CM2 and CM3 appliances recommends using specific elastics for Carriere treatment—*Force 1* elastics and *Force 2* elastics (Table 1), manufactured by Henry Schein Orthodontics (Carlsbad CA). *Force 1* elastics are described as 1/4-inch in diameter with a strength of 6 oz, the precise description of the Ram elastic mentioned above. *Force 2* elastics are sturdier, measuring 3/16-inch in diameter with a strength of 8 oz. The reader will note that *Ram* elastics from Ormco and *Force 1* elastics from Henry Schein have the same diameter and strength, but when tested the *Force 1* elastic generated about 375 g of force, 50% more than did *Ram* elastic (Table 1). When the *Force 2* elastics were measured, the pull produced was 540 g. Thus, the obvious conclusion is that *elastics with the same descriptions from*

different manufacturers are not necessarily equivalent.

To put these forces into perspective, the Carriere elastics force levels can be compared to the elastics used when an orthopedic facial mask of Petit is connected to hooks on a bonded acrylic splint expander, a combination used to correct a Class III malocclusion in young patients [7,8]. Petit has recommended a sequence of Ormco “Zoo Pack” elastics, with the force increasing in three increments. In a similar pilot study, we determined that the *Tiger* elastics produce about 200 g of force, *Whale* elastics produce about 350 g of force and *Walrus* elastics 600 g of force (Table 2) [9].

Table 2. Forces generated by elastics used in facial mask therapy.

Type of Elastic	Size	Strength	Force Generated
<i>Tiger</i>	3/8-inch	8 oz	200 g
<i>Whale</i>	1/2-inch	14 oz	350 g
<i>Walrus</i>	5/16-inch	14 oz.	600 g

A comparison of the values used in Carriere treatment with those used in RME/facial mask therapy indicates that the forces generated by these two approaches are somewhat similar. Heavy intermaxillary forces from elastics worn as close to as full time as possible may be a primary reason why Carriere treatment has been so efficient and effective, producing substantial changes in the occlusion in both growing and non-growing individuals during a relatively short CM2 phase treatment (5-8 months for a cooperative patient). Fixed appliances or clear aligners then are used to fine detail the occlusion secondary to the use of the Carriere® Motion appliance™ [10]. In some instances, the Carriere appliance is used simultaneously with clear aligners in the opposing arch.

THE CARRIERE® MOTION™ CLASS II APPLIANCE

The Carriere® Motion™ Class II (CM2) appliance, originally described the Carriere® Distalizer™, has been used for Class II correction in patients with a variety of dentitional and maturational stages. The CM2 appliance consists of bilateral bars that are bonded to the upper canines and first molars (Fig. 1). Class II elastics are anchored by hooks on the anterior part of both bars and attach to hooks or buttons that are bonded to the distal permanent molars of the mandible bilaterally.

An important conceptual goal of this method of Class II correction is establishing a Class I relationship early in treatment when patient compliance is at its highest level. The protocol for mandibular anchorage includes the use of a removable passive Essix-type clear (“invisible”) retainer that wraps around the distal of the most posterior molar [11, 12]. The clear retainer is trimmed bilaterally to accommodate the posterior hooks or buttons. Other less-common methods of mandibular anchorage can include active clear aligners, a lower lingual arch, temporary anchorage devices, and fixed appliances [13].

Full-time wear of intermaxillary elastics (at least 22 hours every day) is required. The CM2 phase typically takes 5-8 months to complete, given good patient compliance [14]. In the adolescent patient, the CM2 appliance appears to be more comfortable for the patient to wear, offers a more positive overall experience, and has fewer negative comfort-related side effects compared to other appliances for Class II treatment, such as the Forsus™ Fatigue Resistant Device (3M Unitek, Monrovia, CA) [15].

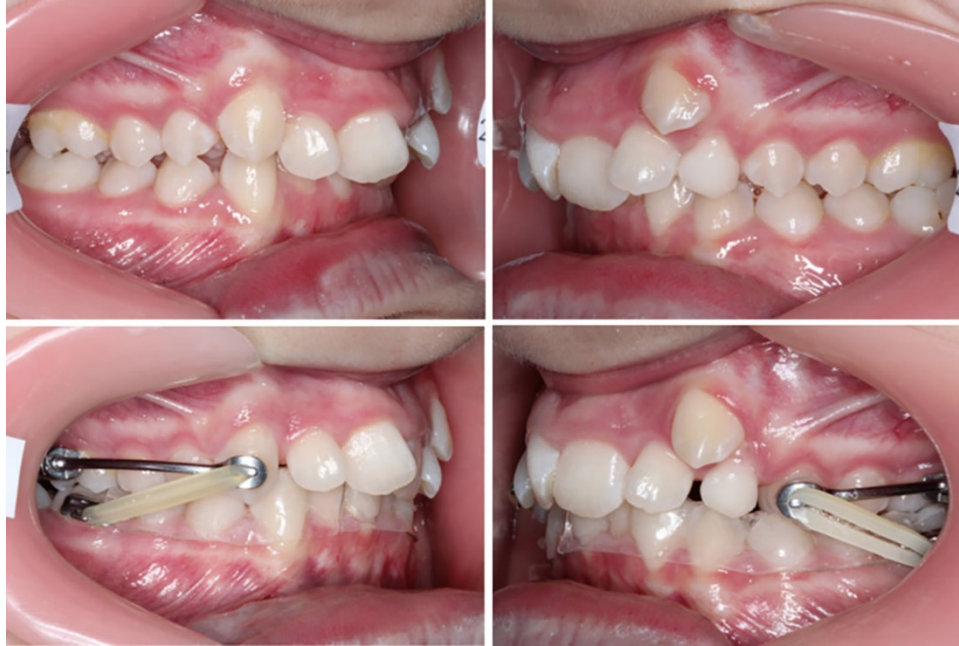

Figure 1. Intraoral views of the CM2 appliance. Top row, pretreatment intraoral photos. Bottom row, intraoral view of the typical CM2 appliance after Class II correction. Note that a “Shorty” version of the CMA appliance was used on the left side when the canine could not be used for attachment. Photographs courtesy of Dr. Luis Carriere. Adapted from Kim-Berman et al, 2018 [14].

Previous Clinical Studies of the CM2 Appliance

To date, there has been a limited number of investigations on treatment effects produced by the CM2 appliance. Existing studies include case reports, case series, and technique-oriented publications [10, 16, 18].

Sandifer et al. examined the treatment effects of the CM2 using two mandibular anchorage protocols, consisting of a lingual arch or fixed appliances [13]. Successful correction of Class II occlusion occurred with use of the CM2 appliance, with minimal maxillary molar tipping observed during molar distalization. Mandibular dental movement also was noted, with the mandibular plane angle opening in the lower lingual arch group only. Overall, Sandifer et al. found no significant differences in the type of mandibular anchorage technique used [13]. It should be noted, however, that the Sandifer study only looked at two timepoints, pretreatment and after CM2 use; treatment rendered following the removal of the CM2 appliance was not considered.

The Ann Arbor-Barcelona CM2 Study

The most comprehensive study to date of the Carriere® Motion™ Class II appliance was that conducted by Kim-Berman and co-workers [14]. This retrospective clinical study analyzed patients who were treated without extraction of permanent teeth (except sometimes third molars), using the CM2 appliance followed by fixed appliances. The details of this study can be found in the March 2019 issue of the Angle Orthodontist [14]. An overview of this CM2 study is provided below.

In this chapter, several terms will be used. Phase I refers to initial treatment with the Carriere® Motion™ appliance, with either the CM2 or CM3 design. Phase II includes the subsequent full fixed appliance phase. Active clear aligners were not used in either of the Carriere clinical studies to be described in this chapter.

Patient Sample. The treated sample was provided by Dr. Luis Carriere, who used his standardized protocol on all patients. Clinica Carriere in Barcelona was asked to provide records of 30 or more consecutively finished patients. Of the 44 such patient records collected, 10 patients were excluded from consideration for one or more of the following reasons:

- Technical radiographic issues that made one or more films in the series unusable;
- The duration of treatment with the CM2 appliance was greater than 12 months; and/or
- Post-treatment records were obtained more than 4 months following the conclusion of active treatment.

The final patient sample consisted of 34 adolescent patients (23 females and 11 males) who were on average 12.8 ± 1.4 years of age at the initial set of records (T1).

Control Sample. The control group consisted of 22 subjects (10 females and 12 males) with untreated Class II malocclusion, the records of whom were selected from the files of the University of Michigan Growth Study (8 subjects), the Denver Child Growth Study (8 subjects), and the Bolton-Brush Growth Study (6 subjects). The lateral cephalograms also were available through the *AAOF Craniofacial Growth Legacy Collection* (https://www.aoflegacycollection.org/aaof_home.html). The average age of the control group at first observation (T1) was 12.2 ± 0.8 years at the time of the first observation.

Treatment Protocol. All patients were treated with the CM2 appliance. In the mandible, buccal tubes with elastic hooks were bonded to the mandibular second or first molars; a clear invisible retainer made from 1 mm thick Essix A+ plastic (Dentsply Sirona, York, PA) was placed (Fig. 1). Elastic wear consisted of *Force 1* elastics (375 g) and *Force 2* elastics (540 g) worn until the end of treatment with the CM2 appliance. Subsequently full fixed appliances with preadjusted 0.022" edgewise brackets (Carriere SLX™ Self-ligating Brackets, Henry Schein Orthodontics, Carlsbad CA) were placed until the end of active treatment.

Cephalometric Analysis. Lateral headfilms of each patient were analyzed at T1, T2, and T3; and for the untreated group, at T1 (first observation) and T3 (second observation). Eleven skeletal and 7 dentoalveolar measurements were used to evaluate changes following treatment (see Table 3). The cephalograms were traced by one investigator (HKB) and then reexamined thoroughly by another examiner (JMc) to verify landmark locations; any disparities in landmark position were resolved by mutual agreement.

Findings

This section is written to provide the interested reader with some of the important details of the CM2 study. The casual reader can move on to the next section of this chapter dealing with the *Clinical Significance* of our CM2 study.

Table 3. Descriptive statistics and statistical comparisons (repeated measures ANOVA) of T1-T2 (pretreatment to removal of CM2), T2-T3 (removal of CM2 to post-treatment) and T1-T3 (pretreatment to post-treatment) changes in the treatment group. Modified from Kim-Berman et al, 2019 [14].

Variables	T1-T2		T2-T3		T1-T3	
	Mean	SD	Mean	SD	Mean	SD
Maxillary Skeletal - sagittal						
SNA Angle (°)	-0.6	1.0	-0.7	1.0	-1.3*	1.4
Point A to Nasion Perp (mm)	-0.4*	1.0	-0.7*	1.1	-1.1*	1.3
Condylion to Point A (mm)	0.4	1.2	0.9	1.4	1.3*	1.8
Mand skeletal - sagittal						
SNB Angle (°)	0.1	1.0	-0.3	1.1	-0.2	1.1
Pogonion to Nasion Perp (mm)	0.5	1.8	-0.5	1.5	0.0	2.1
Condylion to -Gnathion (mm)	2.0*	1.3	3.1*	2.1	5.1*	2.2
Maxillomandibular Relationships						
Wits Appraisal (mm)	-2.1*	2.0	0.1	1.7	-2.0*	2.7
ANB Angle (°)	-0.8*	0.9	-0.3	0.9	-1.1*	1.2
Max-Mand Differential (mm)	1.7*	1.5	2.1*	1.8	3.8*	2.0
Vertical Skeletal Relationships						
ANS to Menton (mm)	1.1*	1.2	2.6*	1.9	3.7*	1.9
FH to Functional Occlusal Plane (°)	3.9*	3.0	-3.6*	3.0	0.3	2.5
FH to Mandibular Plane (°)	0.2	1.4	0.0	1.4	0.2	1.7
Dentoalveolar Relationships						
Overjet (mm)	-2.1*	1.3	-0.8*	1.1	-2.9*	2.0
Overbite (mm)	-2.1*	1.4	-0.5*	1.5	-2.6*	1.2
Molar relationship (mm)	5.1*	2.0	-1.8*	1.6	3.3*	1.6
U1 to Point A Vertical (mm)	0.3	1.2	-0.9*	1.4	-0.6	1.8
L1 to Mandibular Plane (°)	4.9*	3.9	-0.7	6.3	4.2*	5.0
Interincisal Angle (°)	-6.6*	6.0	3.1	9.7	-3.5	9.7

Perp = Perpendicular; Max = Maxillo; Mand = Mandibular; FH = Frankfort Horizontal, U1 = Maxillary Incisor; L1 = Mandibular Incisor; SD, standard deviation.

* p = <0.05

The mean starting age of the CM2 group at T1 was 12.8 years ±1.3 years, 13.2 ±1.5 years at T2 (removal of CM2), and 14.3 ±1.5 years at T3 (post-treatment). Treatment with the Carriere® Motion™ appliance lasted an average of 5.2 months ±2.8 months; Treatment with fixed appliances was 13.0 months

±4.2 months. The total treatment time was an average of 18.2 months ±4.8 months.

The control group was studied at 2 intervals. The average age of the control group at the first observation (T1) was 12.2 ±0.8 years while the average age at the second observation (T3) was 14.4 ±0.8 years. The average interval between the two observations was 26.4 ±4.3 months. To provide a direct comparison of treatment effects, the control data were extrapolated to match the T1 to T3 interval of the CM2 group (i.e., 18 months).

Comparison of Starting Forms (T1)

A comparison of the CM2 patients and controls at T1 indicated that the starting forms were similar between groups [14]. Only two of the 18 variables (overjet and overbite) demonstrated a statistically significant difference ($p < 0.05$); overjet in the treatment group was slightly smaller while the overbite was slightly larger when compared to controls (5.4 mm vs 7.0 mm and 5.7 mm vs 4.2 mm, respectively).

Treatment Effects during Phases I and II (T1-T2, T2-T3, T1-T3)

Table 3 provides mean and standard deviation of the changes in the cephalometric variables and statistical significance at the 3 observation points.

Sagittal Position of the Maxilla. Some restrictive changes were observed. There was a net closure of -1.3° in the SNA angle during the overall treatment period. Similarly, the sagittal distance from Point A to the Nasion Perpendicular¹⁹ was reduced by -1.1 mm during treatment.

Sagittal Position of the Mandible. Mandibular length (Co-Gn) in this adolescent patient population increased 2.0 mm during the 5-month CM2 phase and an additional 3.1 mm during the 12-months fixed appliance phase. The SNB angle, however, increased only 0.1° during Phase I and decrease -0.3° during Phase II, resulting in an insignificant change (-0.2°). Pogonion moved anteriorly 0.5 mm relative to the Nasion Perpendicular during Phase I but rebounded (-0.5 mm) during Phase II.

Maxillo-mandibular Relationships. Treatment with CM2 resulted in a 2.1 mm improvement in the Wits Appraisal value; however, this measurement remained unchanged during the fixed appliance phase. The net change was 2.0 mm. The ANB angle also decreased slightly both during Phase I (-0.8°) and Phase II (-0.3°), resulting in a -1.1° reduction in the ANB angle. The maxillo-mandibular differential, the difference between Co-Pt A and Co-Gn, registered a 1.7 mm increase toward Class I during Phase I and an additional 2.1 mm during Phase II, leading to an overall improvement of 3.8 mm [19].

Vertical Skeletal Relationships. Lower anterior facial height (ANS-Menton) increased by 1.1 mm during Phase I, with an additional 2.6 mm during the fixed appliance phase, resulting an overall increase in lower anterior facial height of 3.7 mm. The mandibular plane angle did not change significantly during either phase of treatment.

One interesting finding was related to the functional occlusal plane (FOP). A clockwise rotation of the FOP relative to the Frankfort horizontal of 3.9° occurred during Phase I. In Phase II, however, there was a substantial rebound in the orientation of FOP (-3.6°), so that the overall change was only -0.3 mm from T1 to T3.

Dentoalveolar Relationships. Molar relationship is determined by the horizontal relationship of the mesial

aspect of the upper and lower first molars. This measure improved by 5.1 mm during Phase I; the same measure rebounded (-1.8 mm) during the CM2 phase, with a net improvement of 3.3 mm toward Class I. Overjet decreased by -2.9 mm overall; overbite decreased by -2.1 mm.

Minimal change (0.3 mm) in the position of the upper incisors was noted during Phase I. Slight retraction (-0.9 mm) of the incisors was observed during the fixed appliance phase. Proclination of the lower incisor of 4.9° occurred during the CM2 phase. During Phase II, a slight uprighting (-0.7°) of the lower incisor was noted.

Regional Superimpositions. Because of word number limitation imposed by the journal,¹⁴ data concerning regional superimpositions on constructed fiducial landmarks within the maxilla and mandible were omitted in the published version of our article; these previously unpublished data are included here (Table 4) [14]. At the time the serial tracings of each patient were made, anterior and posterior fiducials landmarks were construct within the maxilla and mandible, based on the “best fit” superimposition of internal osseous structures evident in each serial headfilm [20, 21]. By using these constructions, an estimate of the movement of the central incisors and first molars relative to their bony bases could be determined.

Table 4. Regional superimposition data based on the use of fiducial landmarks placed anteriorly and posteriorly in the maxilla and mandible. The fiducials were determined based on internal osseous structures in each region. These data were not included in the original publication of the Kim-Berman et al study [14].

REGIONAL SUPERIMPOSITIONS	T2 - T1		T3 - T2		T3 - T1	
	Mean	SD	Mean	SD	Mean	SD
Maxillary Dentoalveolar						
U1 horizontal (mm)	1.3*	1.3	-1.2*	3.0	0.1ns	3.0
U6 horizontal (mm)	-1.0*	1.5	1.7*	2.9	0.7ns	3.0
U1 vertical (mm)	-1.0*	1.3	1.8*	1.4	0.8ns	1.6
U6 vertical (mm)	1.6*	1.3	0.0ns	1.4	1.6*	1.4
Mandibular Dentoalveolar						
L1 horizontal (mm)	0.6ns	1.1	0.0ns	1.7	0.6*	1.6
L6 horizontal (mm)	0.7*	1.2	1.0*	1.6	1.7*	1.5
L1 vertical (mm)	0.1ns	1.2	0.8*	1.2	0.9*	1.6
L6 vertical (mm)	-0.3ns	1.7	2.5*	1.7	2.2*	1.5

Within the maxilla, the upper incisors moved slightly forward (1.3 mm) during the CM2 phase but subsequently rebounded. In contrast, the upper first molar moved backward -1.0 mm during the CM2 phase but then moved forward 1.8 mm during the fixed appliance phase in these growing patients. Vertically, the upper incisors were intruded (-1.0 mm) during the CM2 phase, but then moved downward 1.8 mm during the fixed appliance phase. The upper molar erupted vertically by 1.6 mm during Phase I but not further vertical movement was noted during Phase II.

Within the mandible, the position of the lower incisor was relatively unchanged throughout

treatment relative to mandibular internal structures. In contrast, the lower first molar moved forward 1.6 mm. The vertical position of the lower incisors remained unchanged during Phase I but erupted nearly 1 mm during Phase II. The vertical position of the lower molars was relatively stable during Phase I but erupted 2.5 mm during the fixed appliance phase.

Comparison of the Treatment and Control Groups (T1-T3)

Skeletal relationships. Table 5 provides data concerning a direct comparison between the pretreatment to post-treatment interval and the extrapolated control cephalometric values. *A reduced forward movement of the maxilla at Point A in the treatment group compared to controls* was noted. In contrast, *the chin point at Pogonion remained unchanged relative to the Nasion Perpendicular during T1-T3; the chin moved forward 1.5 mm in the controls.*

Both ANB (-0.9°) and the Wits Appraisal (-2.0 mm) showed significant decreases in the treatment group with respect to controls. *Lower anterior facial height (ANS to Menton) increased in the treatment group by 3.7 mm, almost double of that occurring in the untreated Class II controls.*

Dentoalveolar Relationships. Major changes were observed in the dentoalveolar measures. All six measures of dentoalveolar relationships in the controls remained relatively unchanged from T1 to T3. In the treatment group, however, overjet and overbite improved (-2.9 mm and -2.6 mm, respectively) as did molar relationship (3.3 mm). There was 4.2° of proclination of the lower incisor as well as a slight closure of the interincisal angle (-3.5°).

Clinical Significance of the CM2 Study

When discussing changes in any skeletal or dentoalveolar measure, the differences between statistical significance and clinical significance must be mentioned. For this study, a P value of at least <0.05 was used to determine statistical significance. In our prior clinical investigations, we have chosen to use a change of ≥2.0 mm or ≥2.0° in any cephalometric variable as an indication of clinical significance, following the recommendations of O'Brien and co-workers among others [22-24].

The results of the Ann Arbor-Barcelona study of the Carriere® Motion™ Class II appliance in adolescents indicate that the CM2 is an efficient and effective way of correcting the sagittal component of Class II malocclusion within the first half year of orthodontic treatment. Comprehensive therapy using fixed appliances or other methods such as clear aligners subsequently can be used, sometimes combined with rapid maxillary expansion or dental arch expansion, to refine and detail the occlusion.

Did retraction of the maxilla occur during treatment? A statistically significant (but minimally clinically relevant) restriction of midfacial growth (Co-A, -1.0 mm) was recorded with respect to the control sample. The differences between the treatment and control groups in the SNA angle (-1.8°) and Point A to the Nasion Perpendicular (-1.7 mm) not only were statistically significant but approached clinical significance. Thus, *maxillary adaptations mostly accounted for the favorable intermaxillary changes* with significant decreases, both in the ANB angle (-0.9°) and the Wits Appraisal (-2.0 mm).

Table 5. Descriptive statistics and statistical comparisons (independent-samples t tests and Mann-Whitney U test) of the T1-T3 (pre-treatment to post-treatment) following full fixed appliances) changes in Treatment and Control Groups. Modified from Kim-Berman et al, 2019 [14].

Variables	Treatment Group		Control Group		Diff.
	Mean Median	SD IQR	Mean Median	SD IQR	
Maxillary Skeletal - sagittal					
SNA Angle (°)	-1.3	1.4	0.5	0.8	-1.8***
Point A to Nasion Perp (mm)	-1.1	1.3	0.6	1.8	-1.7**
Condylion to Point A (mm)	1.3	1.8	2.3	1.3	-1.0*
Mandibular skeletal - sagittal					
SNB Angle (°)	-0.2	1.1	0.6	0.8	-0.8**
Pogonion to Nasion Perp (mm)	0.0	2.1	1.5	3.0	-1.5ns
Condylion to Gnathion (mm)	5.1	2.2	4.3	1.7	0.8ns
Maxillo-mandibular					
ANB Angle (°)	-1.1	1.2	-0.2	0.7	-0.9**
WITS Appraisal (mm)	-2.0	2.7	0.0	2.0	-2.0**
Maxillomandibular Differential	3.8	2.0	2.8	1.8	1.0ns
Vertical Skeletal					
ANS to Menton (mm)	3.7	1.9	1.9	1.3	1.8***
FH to Mandibular Plane (°)	0.2	1.7	-1.0	1.4	1.2**
FH to Occlusal Plane (°)	0.3	2.5	-0.6	1.9	0.9ns
Dentoalveolar					
Overjet (mm)	-2.9	2.0	0.0	0.5	-2.9***
Overbite (mm)	-2.6	1.2	0.0	0.8	-2.6***
Molar Relationship (mm)	3.3	1.6	0.2	1.1	3.1***
U1 to Point A Vertical (mm)	-0.6	1.8	0.2	0.8	-0.8*
L1 to Mandibular Plane (°)	4.2	5.0	0.4	2.1	3.8***
Interincisal Angle (°)	-3.5	9.7	0.4	2.9	-3.9*

Perp = Perpendicular; FH = Frankfort Horizontal; U1 – Maxillary Incisor; L1 = Mandibular Incisor
SD= Standard Deviations; IQR= Interquartile Range

*p = <0.05; ** p = <0.01; ***p = <0.001; ns, not statistically significant.

Did the rate of mandibular growth increase during treatment? The mandible was brought forward by heavy elastics worn nearly fulltime by the patient. Thus, one might expect that mandibular length, as measured from Condylion to anatomical Gnathion, would increase during treatment over what would occur during normal growth. In fact, *there was no statistically or clinically significant increase in mandibular length* (Table 5) compared to controls.

The lack of clinically relevant stimulation of mandibular growth also can be ascribed to the relatively short treatment duration with the CM2 (5.2 months). The SNB angle showed a statistically significant though clinically irrelevant decrease (-0.8°). There was no difference in the anteroposterior position of the chin at Pogonion between the two groups. This decrease in the SNB angle could be related to the increase in vertical skeletal relationships that occurred in the CM2 sample with respect to the controls.

What changes occurred in the vertical dimension? One clinically and statistically relevant effect of treatment with CMA occurred in lower anterior facial height (LAFH; ANS-Menton, 1.8 mm) that was associated with a significant increase in the mandibular plane angle (1.2°). The amount of increase in LAFH with the CM2 appliance was smaller than that reported for Class II elastics and fixed appliances (5.0 mm), while it was similar to that described for the crown or acrylic Herbst appliance (3.2 mm and 4.0 mm, respectively) and for the Forsus appliance (4.0 mm) [25-27].

As mentioned previously, a clockwise rotation of the Functional Occlusal Plane relative to the Frankfort horizontal (3.9°) was noted during treatment with the CM2 appliance. Interestingly, a rebound in that measurement (-3.6°) occurred during the fixed appliance phase (Table 4), so there was no statistically significant difference between groups at T3. A similar behavior for the occlusal plane angulation has been reported for Class II elastics combined with fixed appliances [25].

What changes occurred in the dentition? In general, the six dentoalveolar measures remained unchanged in the control group from T1 to T3; *these measures all changed in the treatment group*. The most obvious change was in molar relationship, which improved by 5.1 mm during Phase I when the molar classification went from Class II to Class I (or even “overcorrected” to slight Class III; Table 5). A rebound occurred in this measure (-1.8 mm) as the occlusion was detailed with fixed appliances. In the control group, from T1-T3 there was virtually no change in molar relationship; the overall change in the CM2 group was 3.3 mm (Table 3). Overjet (-2.9 mm), overbite (-2.6 mm) and lower incisor angulation (4.2°) all changed in both a statistically and clinically significant manner. Similar dentoalveolar changes were described also for Class II elastics combined with fixed appliances and for fixed functional appliances [27].

Summary and Conclusions – the CM2 Appliance

This study examined the treatment effects produced by CM2 treatment followed by comprehensive orthodontics. The Carriere® Motion™ Class II appliance was shown to be efficient and effective in resolving Class II malocclusion in adolescents. The following conclusions are reached based on the data analyzed:

- The overall treatment time was relatively short (17.6 months), and Class II correction with the CM2 appliance typically was achieved during the first 5-6 month of treatment;
- The primary treatment effects were dentoalveolar in nature, with changes recorded in molar relationship, overbite, and overjet combined with some lower incisor proclination;
- The most obvious skeletal change was a clinically relevant increase in lower anterior facial height;
- The functional occlusal plane rotated clockwise relative to the Frankfort horizontal during CM2 treatment; a significant rebound of the rotation occurred during the subsequent fixed appliance phase.
- Slight restriction in the forward movement of the maxilla at Point A was noted;
- Mandibular length was not affected by treatment; and,
- The chin point at Pogonion did not move forward in the treatment group due, in part, to the increase in lower anterior facial height.

THE CARRIERE® MOTION™ CLASS III (CM3) APPLIANCE

A logical extension of the Carriere treatment approach is to use the Carriere® Motion™ appliance “in reverse,” that is to bond the bilateral bars of the appliance to the mandibular dentition in an effort to improve an existing Class III malocclusion (Fig. 2). Although the CM3 appliance was introduced formally in San Francisco at the Annual Session of *the American Association of Orthodontist* in 2015, Luis Carriere stated in an interview, however, that interest in using the CM2 appliance to treat Class III patients began several years earlier after the inventor had presented courses on his Class II correction technique, especially those given in Asian countries [28].

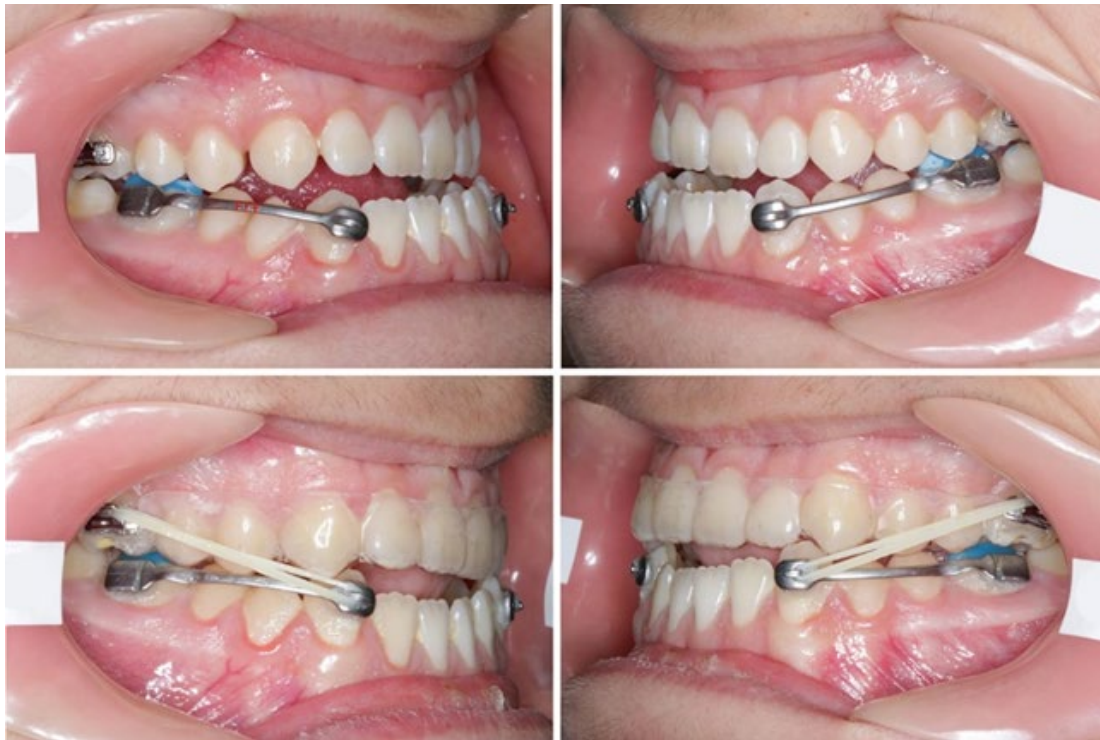

Figure 2. Intraoral views of the CM3 appliance. Top row, initial placement of the appliance before the delivery of the invisible retainer. Note that the bite has been opened posteriorly with blue occlusal composite to facilitate anterior crossbite correction. Bottom row, the invisible retainer is being worn with the canines now in Class I. Photographs courtesy of Dr. Luis Carriere.

As soon as the developer started to use the original CM2 bars in Class III patients, it became apparent to him that a modification in appliance design was indicated. He stated that typically the posterior mandibular segments of the dentition are inclined lingually so that the buccal cusps of the lower posterior teeth occlude between the buccal and lingual cusps of the upper posterior teeth [28]. Carriere found that sometimes the bulk of the ball-and-socket joint of the original CM2 appliance, when used in a Class III configuration, interfered with the occlusion. Additionally, the ball-and-socket hinge was not needed in that derotation of the lower molars was rarely a treatment objective. Thus, the ball-and-socket joint was replaced by a flat molded pad of the CM3 appliance that was bonded to the first molars at the center of their clinical crown to facilitate lower molar movement in a posterior direction. The attachment in the mandibular canine region remained unchanged (Fig. 2). In instances in which a lower canine had

not erupted or had erupted ectopically, the lower first premolar could be used as the anterior attachment, as was described earlier for the CM2 appliance (Fig, 1).

The typical Class III elastic protocol when the CM3 appliance is indicated is to have the patient use bilateral *Force 1* elastics (Henry Schein Orthodontics, Carlsbad CA) that are worn a close to full time as possible (Table 1). The senior author of this chapter often tells his patients that “fulltime” elastic wear simply means that the patient’s elastics can be removed for meals or tooth brushing, but for no longer than 15 minutes (i.e., “The 15-minute rule”) to ensure that continuous forces are applied to the maxillary and mandibular dentition. Obviously, this rule applies to most but not all situations; common sense must prevail.

The developer of the Carriere Motion has recommended that the heavier *Force 2* elastics should be used infrequently in Class III patients, although we have been successful using higher forces in larger patients with thicker facial bone structure. Although anecdotal, no issues related to temporomandibular disorders have been noted to date.

In preparation for writing this portion of the chapter, we carried out an extensive search of the literature to determine what has been published concerning the Carriere® Motion™ 3 appliance. PubMed, Google Scholar and the general Google search engine revealed that there essentially is no literature on this topic. Aside from the interview article with Luis Carriere described above, there were only 2 other publications containing case reports, as well as one “new product” press release [28, 29, 20, 31]. No prospective or retrospective clinical studies of the CM3 appliance could be identified.

The Carriere® Motion™ Class III appliance has proven to be useful in patients at various levels of maturation, including juveniles, adolescents and adults. Thus far we have found that the largest patient population treated with the CM3 appliance followed by fixed appliance has occurred in more mature individuals. Thus, mature Class III patients treated with the CM3 appliance comprise the first group that we studied.

The Ann Arbor - Barcelona CM3 Study

This retrospective clinical study analyzed the results produced in Class III patients who were treated without corrective jaw surgery. The protocol used involved an initial phase of treatment with the Carriere® Motion™ 3 appliance followed by a second phase of fixed appliance therapy. An overview of the CM3 study is presented below. For the details of our CM3 study, the reader is referred to the original publication of this clinical investigation by McNamara and coworkers [32].

Treatment Sample. Digital records of CM3-treated Class III patients were provided by two sources, Clinica Carriere of Barcelona, Spain and McNamara Orthodontics of Ann Arbor, Michigan. The available records on each patient had to include lateral cephalograms obtained at three specific times: T1, at the beginning of treatment; T2, immediately after removal of the bilateral bars of the CM3 appliance; and at T3, after all appliances had been removed.

Only those records of patients having three serial headfilms were considered for inclusion; in addition, we also applied exclusionary rules to the original sample. Because we wanted to evaluate the treatment effects in a sample of supposedly “minimally growing” (i.e., late adolescent and adult) Class III patients, the level of cervical vertebral maturation (CVM) was determined for each patient. In that the neck vertebrae can be visualized easily in good-quality lateral headfilms, these cephalograms were used

for maturational evaluations [1, 33] Each patient had to have reached at least cervical stage CS 4 in the T1 film.

A total of 35 patients from Clinica Carriere, Barcelona, and 14 patients from McNamara Orthodontics, Ann Arbor MI, qualified for initial inclusion in our data base, for a total starting sample of 49 Class III patients. We then evaluated the films further. An additional 17 patients were eliminated for the following reasons:

- Technical radiographic issues N = 4
- Missing posterior teeth N = 5
- Posterior implant N = 1
- Extraction of lower incisor N = 1
- Class I malocclusion N = 6

Thus, the total sample size analyzed in this study was 32 Class III patients, 14 males and 18 females.

In order to verify that our treatment sample was truly Class III, we compared the starting forms of the 32 Class III patients by gender to previously published data from a much larger group of untreated Class I subjects with ideal occlusions and well-balanced faces [34]. The skeletal and dental relationships of 18 female and 14 male Class III patients were compared to 81 female and 44 male Class I ideal subjects, respectively (Tables 6 and 7).

All patients were managed with the CM3 appliance during Phase I. The size of each Carriere bar was determined by measuring the distance from mesial of the lower canine to the midpoint of the lower first molars, according to manufacturer's instructions. In the upper arch, buccal tubes with elastic hooks were bonded to the distal molars, and a clear invisible retainer was fabricated from 1 mm thick Essix A+ plastic (Dentsply Sirona, York, PA) was placed (Fig. 2). Elastic wear consisted of *Force 1* elastics (Henry Schein Orthodontics, Carlsbad CA) that generated about 375 g of force on each side (Table 1). These elastics were worn throughout the first phase of treatment and during the subsequent fixed appliance phase, if necessary.

Serial lateral headfilms of each patient were traced and analyzed simultaneously. Eleven skeletal and seven angular were used to evaluate changes following treatment (Table 8). The cephalograms were traced by one investigator (LMc) and then examined thoroughly by a second investigator (JMc) to verify landmark locations; any disparities were resolved by mutual agreement.

Comparison Groups

Ideally, we would have liked to compare the outcome of CM3 treatment to data from a matched untreated Class III sample monitored for the same length of time. Unfortunately, no longitudinal study of untreated Class III subjects in late adolescence or adulthood exist in the orthodontic literature. In that all Class III patient had to be at least at cervical stage CS 4 to be included in the study, the assumption was made that the CM3 patients would demonstrate minimal craniofacial growth during the study period. Thus, no matched controls were used.

Table 6. Comparison of starting forms of Class III female patients and Class I female controls with ideal occlusions and well-balanced faces. Modified from McNamara and Ellis, 1988[34].

	Treatment Group		Control Group			
	N=18		N=81			
	<i>Mean</i>	<i>SD</i>	<i>Mean</i>	<i>SD</i>	<i>Diff</i>	<i>P</i>
<i>Maxillary skeletal - sagittal</i>						
SNA (°)	81.1	3.9	82.4	3.0	-1.3	0.120
Pt A to Nasion perp (mm)	1.3	3.2	0.4	2.3	0.9	0.167
Co-A (mm)	90.1	5.4	91.0	4.8	-0.9	0.484
<i>Mandibular skeletal - sagittal</i>						
SNB (°)	82.3	3.4	80.0	2.8	2.3	0.003
Pg to Nasion perp (mm)	6.6	6.6	-1.8	4.5	8.4	0.000
Co-Gn (mm)	130.9	8.0	120.2	5.3	10.7	0.000
<i>Maxillo-mandibular</i>						
ANB (°)	-1.2	2.7	2.5	1.4	-3.7	0.000
WITS (mm)	-8.3	3.1	-0.9	2.2	-7.4	0.000
Max.-Mand. Differential	40.9	4.6	29.2	3.3	11.7	0.000
<i>Vertical Skeletal</i>						
ANS to Me (mm)	72.1	5.5	66.7	4.1	5.4	0.000
FH to mandibular plane (°)	26.7	4.9	22.7	4.3	4.0	0.000
<i>Dentoalveolar</i>						
Overjet (mm)	0.0	1.4	3.6	0.9	-3.6	0.000
Overbite (mm)	0.7	1.5	2.7	1.0	-2.0	0.000
Molar relationship (mm)	6.9	1.6	n/a	n/a		
U1 to Pt A vert (mm)	6.6	2.4	5.4	1.7	-1.2	0.014
L1 to mand plane (°)	80.1	7.4	94.9	6.3	-14.8	0.000

n/a = data not available

Table 7. Comparison of starting forms of Class III male patients and Class I male controls with ideal occlusions and well-balanced faces. From McNamara and Ellis, 1988 [34].

	Treatment Group		Control Group		Diff	P
	N=14		N=44			
	Mean	SD	Mean	SD		
Maxillary Skeletal - sagittal						
SNA (°)	80.0	4.6	83.8	3.2	-3.8	0.001
Pt A to Nasion perp (mm)	-1.4	4.9	1.0	2.7	-2.4	0.023
Co-A (mm)	94.6	2.4	99.8	6.0	-5.2	0.003
Mandibular skeletal - sagittal						
SNB (°)	81.6	4.1	81.6	2.7	0.0	1.000
Pg to Nasion perp (mm)	4.5	9.4	-0.3	3.8	4.8	0.007
Co-Gn (mm)	139.4	5.6	132.3	6.8	7.1	0.000
Maxillo-mandibular						
ANB (°)	-1.8	2.9	2.2	1.8	-4.0	0.000
Wits Appraisal (mm)	-8.8	4.2	-0.7	2.8	-8.1	0.000
Max-Mand Differential	44.8	5.2	32.5	4.0	12.3	0.000
Vertical Skeletal						
ANS to Me (mm)	77.4	5.7	74.6	5.0	2.8	0.083
FH to mand plane (°)	25.9	6.3	21.6	3.9	4.3	0.003
Dentoalveolar						
Overjet (mm)	-0.9	2.5	3.3	1.0	-4.2	0.000
Overbite (mm)	1.2	3.2	2.8	1.3	-1.6	0.009
Molar relationship (mm)	8.3	2.4	n/a	n/a		
U1 to Pt A vert (mm)	6.3	2.1	5.3	2.0	1.0	0.113
L1 to mand plane (°)	79.6	9.7	92.3	7.4	-12.7	0.000

n/a = data not available

Table 8. Descriptive statistics and statistical comparisons (repeated measures ANOVA) of T1-T2 (pretreatment to removal of CM3), T2-T3 (removal of CM3 to post-treatment) and T1-T3 (pretreatment to post-treatment) changes in the Treatment Group.

	T1		T2		T3		T2-T1 changes		T3-T2 changes		T3-T1 changes	
	Mean	SD	Mean	SD	Mean	SD	Mean	SD	Mean	SD	Mean	SD
SNA (°)	80.6	4.2	80.8	4.2	80.7	4.1	0.2ns	1.2	-0.1ns	1.0	0.1 ns	1.1
A to Nasion Perp	0.1	4.2	0.5	4.2	0.4	4.2	0.4ns	1.2	-0.1ns	1.0	0.3 ns	1.1
Midfacial Length	92.1	4.9	92.6	4.7	92.5	4.4	0.5ns	1.3	0.0ns	1.2	0.5 ns	1.3
SNB (°)	82.1	3.6	81.2	3.6	81.4	3.6	-0.9***	1.0	0.2ns	0.8	-0.7**	1.1
Pog to Nasion Perp	5.7	7.9	4.0	7.5	5.0	7.9	-1.7**	2.2	1.0**	1.4	-0.7 ns	2.2
Mandibular Length	134.6	8.2	134.8	8.3	135.9	7.9	0.2ns	1.1	1.1**	1.5	1.3***	1.4
ANB (°)	-1.5	2.8	-0.4	2.6	-0.7	2.5	1.1***	1.1	-0.3ns	1.0	0.8***	1.0
Wits Appraisal	-8.5	3.6	-3.6	3.0	-4.6	2.9	5.0***	2.5	-1.0ns	2.8	4.0***	2.8
Max/Man Diff	42.6	5.2	42.3	5.6	43.4	4.8	-0.3ns	1.2	1.1***	1.4	0.8*	1.5
FH-Occ Plane (°)	6.6	4.3	2.7	3.7	3.5	3.8	-4.0***	3.0	0.9ns	3.2	-3.1***	2.8
FH-Mand Plane (°)	26.4	5.5	27.4	5.5	26.9	5.8	1.1**	1.4	-0.5ns	1.1	0.6 ns	1.5
Lower Ant Facial Ht	74.4	6.1	76.6	6.6	76.9	6.3	2.2***	2.0	0.3ns	1.4	2.5***	1.8
Overjet	-0.4	2.0	3.1	1.8	2.4	1.2	3.5***	2.1	-0.7ns	1.8	2.8***	2.2
Overbite	0.9	2.4	-1.2	1.9	1.7	1.0	-2.1**	2.9	2.9***	2.0	0.8 ns	2.6
Molar relationship	7.5	2.1	1.5	2.1	2.8	1.3	-6.0***	1.6	1.2**	1.9	-4.8***	1.8
Upper Inc A Perp	6.4	2.2	8.3	2.4	7.8	2.5	1.9***	1.5	-0.6ns	1.4	1.3**	1.8
Upper Inc to FH (°)	119.1	6.8	125.7	7.6	123.7	8.2	6.6***	6.3	-2.0ns	6.5	4.7**	8.0
Lower Inc to MP (°)	79.9	8.3	79.0	7.0	78.1	7.3	-0.9ns	4.5	-1.0ns	4.7	-1.8 ns	5.3

* P<0.05; ** P<0.01; *** P<0.001

Findings

As mentioned previously for the CM2 study, this findings section is written for the interested reader, in that the important details of the CM3 study are presented below. The casual reader should skip to the *Clinical Significance* heading of the CM3 study below.

The average age of the CM3 sample at T1 was 18.5 ±7.0 years; T2 was 19.0 ±7.1 years and T3 20.1 ±7.0 years. The T1-T2 interval was 6.3 ±4.3 months and the T2-T3 interval 12.9 ±4.6 months. The overall T1-T3 interval was 19.2 ±6.5 months.

Once again, we emphasize the difference between statistical significance and clinical significance, as was mentioned during the discussion of our CM2 study above. We again used a change of ≥2.0 mm or

≥2.0° in any cephalometric variable as an indication of clinical significance.

Comparison of Starting Forms (Tables 6 and 7)

To determine if the treatment sample has both skeletal and dentoalveolar characteristics of Class III malocclusion at the beginning of treatment, we compared T1 cephalometric data from the CM3 sample to a large untreated sample of Class I subjects (N=125) [34]. The study sample demonstrated significant Class III skeletal and dentoalveolar characteristics. Interestingly, all but 5 of the 30 male and female comparisons were statistically significant.

Skeletal Relationships: Both sexes demonstrated a tendency toward retrusion of the maxilla in the CM3 groups relative to the comparison group. The differences according to gender were much greater in CM3 males than in CM3 females.

Significant intergroup differences were noted in the mandibles of both males and females. Mandibular length (Co-Gn) was 7.1 mm greater in the CM3 males than in the Class I males; the same difference in females was 10.7 mm. The SNB angle was similar in both male groups (0°), but the SNB angle in females was 2.3° larger in CM3 patients.

To evaluate the relationship between the two jaws directly, the maxillomandibular differential, the difference between midfacial length (Co-Pt A) and mandibular length, was measured [19]. This value was 12.3 mm larger in Class III males than in Class I females. Similarly, the same variable measured in CM3 females was 11.7 mm than in the comparison females.

Vertically, lower anterior facial height (ANS-Me) was larger in both CM3 males (2.8 mm) and females (5.4 mm) than in the Class I sample, although only the latter value was statistically significant. Both Class III groups had increased mandibular plane angles (4.3° for both groups) in comparison to those with near ideal occlusions.

Dentoalveolar: Statistically significant and clinically relevant differences were observed all in the dentoalveolar comparisons between the Class III and Class I samples. Overjet was reduced substantially in both Class III males (-4.2 mm) and females (-3.6 mm) relative to their Class I counterparts. The molar relationship at T1 was 8.3 mm in Class III males and 6.9 mm in similar females.

Normal values for molar relationship were not available for the Class I sample, but it is well accepted that a normal molar relationship in an ideal occlusion is about 2 mm in both males and females [35, 36]. Thus, the molar relationship of the Class III sample was over 6 mm greater in males and about 5 mm greater in females. Lastly, the lower incisors were tipped lingually by -12.7° in CM3 males and -14.8° in CM3 females compared to controls.

Treatment Effects during the CM3 Phase and the Fixed Appliance Phase

Table 8 displays mean and standard deviation of the changes in the cephalometric variables and statistical significance at 3 observation points (T2-T1, T3-T2 and T3-T1).

Sagittal Position of the Maxilla. No statistically significant or clinically relevant changes in the three maxillary variables were noted during either phase of treatment.

Sagittal Position of the Mandible. Minimal changes were observed in the position of the mandible. There was a slight decrease in the SNB angle (-0.9°) during the CM3 phase, with a decrease in the distance from the chin point at Pogonion to the Nasion Perpendicular of -1.7 mm. A slight rebound occurred during the fixed appliance phase. Overall, the changes in the mandible were not clinically relevant.

Maxillo-mandibular Relationships. The original Wits Appraisal value was -8.5 mm, indicating a strong Class III relationship. This value improved by 5.0 mm toward Class I during Phase I, a value that was clinically relevant. A rebound of -1.0 mm occurred during Phase II, leaving a residual net increase of 4 mm. Other changes were minimal, with a 0.8° increase in the ANB angle and a 0.8 mm increase in the maxillomandibular differential. In essence, there was no change in the relationship of maxillary length to mandibular length.

Vertical Skeletal Relationships. Two clinically relevant changes were noted in the vertical dimension. Lower Anterior Facial Height (ANS-Me) increased by 2.2 mm during Phase I, and there was an overall change of 2.5 mm from T1 to T3. The angle of the Functional Occlusal Plane to the Frankfort Horizontal increased by 5.0° during Phase I, rebounded -1.0° during Phase II, resulting in a 4° opening of the FH-Occ angle at the end of treatment. The mandibular plane opened slightly (1.1°) during T1-T2 and rebounded during T2-T3.

Dentoalveolar Relationships. Several of the most significant treatment effects occurred in the dentition. The most profound change was in molar relationship. The starting value was -7.5 mm; at T2 the molar relationship was reduced by 6.0 mm to -1.5 mm. At T3, the residual value was 2.8 mm.

Similar changes were seen in the anterior dentition. Overjet improved by 3.5 mm during Phase I and rebounded slightly (-0.7 mm) during Phase II, resulting in a residual increase of 2.8 mm. Overbite decreased by -2.1 mm on Phase I, then increased by 2.9 mm during Phase II, resulting in a clinically insignificant deepening of the bite of 0.8 mm.

Regional Superimpositions. We also were interested in examining the movements of the maxillary and mandibular dentition relative to their supporting bones. As described previously, “best fit” superimpositions were made to determine the movement of the anterior and posterior dentitions relative to the maxilla or mandible, based on stable areas of osseous bone morphology; fiducial landmarks were constructed so that these superimpositions could be transferred across tracings (Table 9).

Much tooth movement relative to their bony bases was noted, movement that approached clinical relevance. From a sagittal perspective, both the upper incisors and the upper molars moved forward relative to the fiducial markers by almost 2 mm (1.8 mm and 1.9 mm, respectively) during Phase I. There was minimal rebound (-0.2 mm) in upper molar position during Phase II, resulting in a net forward movement of 1.7 mm at the end of treatment. The upper incisors exhibited a small rebound in position during the fixed appliance phase, with a net result of 1.0 mm.

From a vertical perspective, both the maxillary incisors and molars erupted 1.9 mm during Phase I, with minimal change occurring during Phase II. The lower incisors erupted 0.6 mm and 1.7 mm during Phases I and II, respectively. The vertical position of the lower molars remained relatively unchanged during treatment.

Table 9. CM3 regional superimpositions, based on fiducial landmarks.

REGIONAL SUPERIMPOSITIONS	T2 - T1		T3 - T2		T3 - T1	
	Mean	SD	Mean	SD	Mean	SD
Maxillary Dentoalveolar						
U1 horizontal (mm)	1.8***	1.6	-0.8*	1.5	1.0**	1.7
U6 horizontal (mm)	1.9***	1.7	-0.2ns	1.6	1.7***	1.6
U1 vertical (mm)	1.9***	1.7	-0.2ns	1.6	1.7***	1.6
U6 vertical (mm)	1.9***	1.7	-0.2ns	1.6	1.7***	1.6
Mandibular Dentoalveolar						
L1 horizontal (mm)	-0.5ns	1.4	-1.9***	1.9	-2.4***	2.2
L6 horizontal (mm)	-1.8***	1.4	0.5ns	1.3	-1.4***	1.7
L1 vertical (mm)	0.6**	0.9	1.7***	1.5	2.2***	1.6
L6 vertical (mm)	-0.5ns	1.4	0.8*	1.5	0.3ns	1.5

Individual Variation. Average values, of course, are of interest; however, looking at the distribution of responses of the 32 patients in Figure 3 shows that there was a wide variation in tooth movement among CM3 patients. Responses ranged from -2 mm to 5.5 mm during the CM3 phase (Fig. 3), and from -1 mm to 5 mm during the entire treatment (Fig. 4).

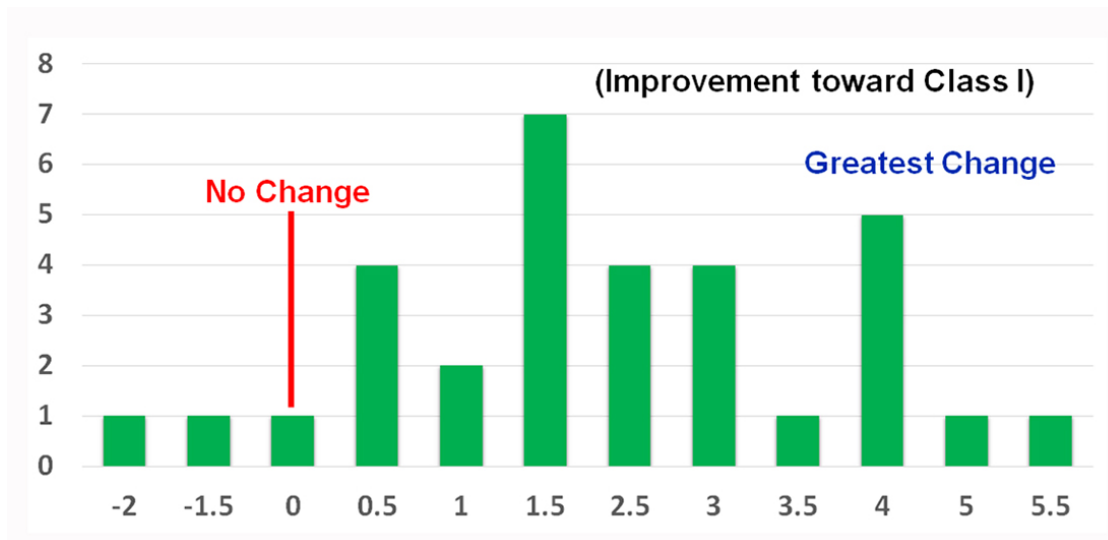


Figure 3. Movement of the upper first molars during the CM3 phase. The horizontal axis indicated the amount of tooth movement and the vertical axis represents the number of patients. A positive number indicated anterior movement of the maxillary first molar; a negative number indicated posterior movement.

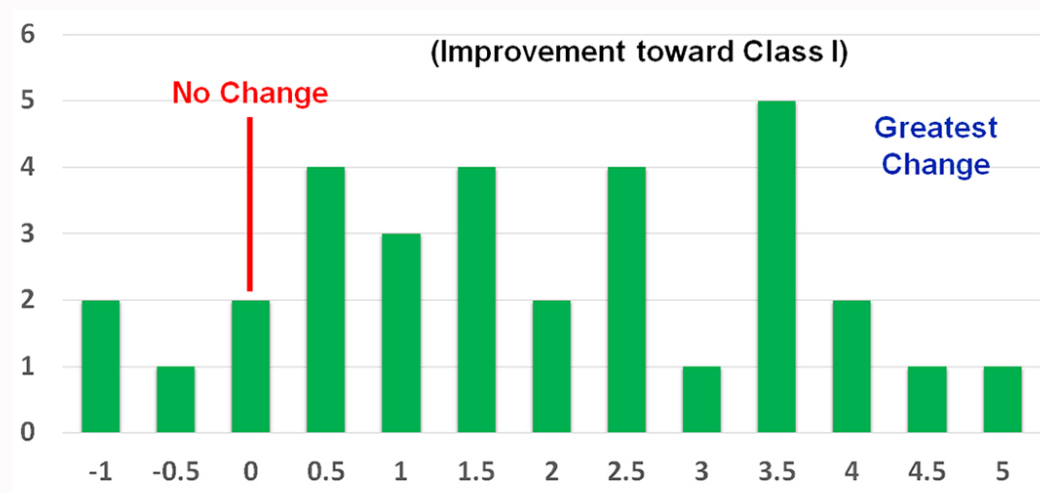


Figure 4. Movement of the upper first molar from the beginning to the end of treatment. The responses were wide ranging.

The most dramatic sagittal response in the lower arch was an average of -1.8 mm posterior movement of the lower molars during the CM3 phase. There was a slight rebound (0.4 mm) during the fixed appliance phase, resulting in a 1.4 mm distalization of the lower molars at the end of treatment. In contrast, the lower incisors moved posteriorly slightly (-0.5 mm) during Phase I and an additional -1.9 mm during Phase II, with a net distalization of -2.4 mm.

When the distribution of responses was examined (Fig. 5), the range was from 0.5 mm of mesial movement to -5 mm of distal movement. When the entire treatment period was considered (Fig. 6), lower molar movement ranges from 2 mm of anterior movement to -5 mm of posterior movement.

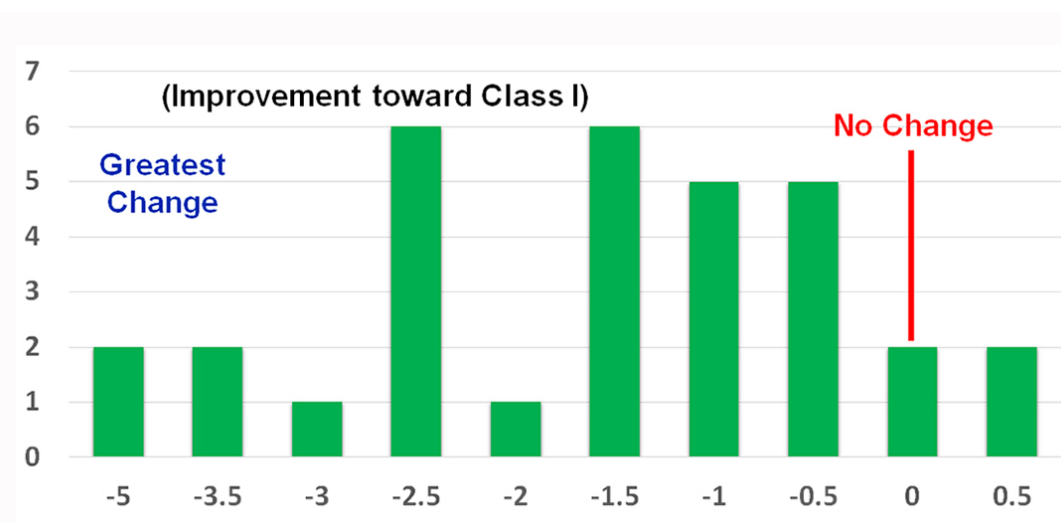

Figure 5. Movement of the lower first molar during the CM3 phase. A positive number indicated anterior movement of the mandibular first molar; a negative number indicated posterior movement. Most patients showed posterior molar movement.

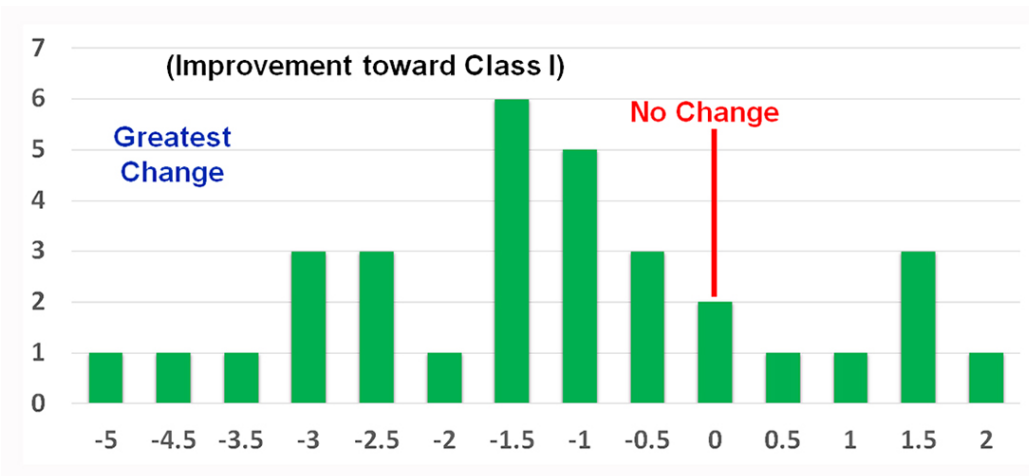


Figure 6. Movement of the lower first molar from the beginning to the end of treatment.

Clinical Significance of the CM3 Study

The Carriere® Motion™ Class III appliance provides a novel approach to the management of Class III problems in mature patients. This protocol offers an alternative to more aggressive therapies that can involve orthodontics alone or a combination of orthodontics and orthognathic surgery, with and without the extraction of lower premolars.

The focus of this initial study was on the mature patient in whom growth during treatment presumably would not be a factor. In that the CM3 appliance was not available commercially until 2015, longitudinal studies of treatment effects produced by the CM3 appliance do not exist. Thus, comparison of the results of our investigation to previous literature is limited.

The finding of this study in mature Class III patients show that the treatment effects of the CM3 appliance were primarily dentoalveolar in nature. We address below some of the questions related to this study of CM3 treatment in “non-growing” individuals.

Were the CM3 patients truly Class III at the beginning of treatment? Comparing the starting form of the CM3 sample to near ideal Class I samples of male and female subjects (Tables 6 and 7) indicated that the treatment sample was Class III skeletally and dentally. All but 5 of the 30 male and female comparisons between treated and controls were statistically significant [35].

Were the CM3 patients “minimally growing”? In that a matched untreated Class III control sample does not exist, the assumption was made that, based on the chronological age and the CVM evaluation, these patients would show a minimal rate of skeletal growth; indeed, that was the case. The average increases in midfacial and mandibular lengths during the 19-month CM3 treatment were only 0.5 mm and 1.3 mm, respectively (Table 8). Although these increases were statistically significant, these values have low clinical relevance.

What skeletal changes were observed both sagittal and vertically? Significant skeletal changes were not observed. As described above, the amount of sagittal skeletal growth in the CM3 group was clinically

irrelevant. Further, the overall change in the maxillomandibular differential was only 0.8 mm, indicating that the relationship of midfacial length to mandibular length remained unchanged during treatment.

What dentoalveolar changes were observed? Most of the larger changes produced were dentoalveolar. At the end of treatment, the Wits Appraisal, reflecting the position of the dentition within their bony bases, moved toward Class I by 4.0 mm, and the molar relationship became more Class I by 4.8 mm.

Were the teeth moved toward Class I relative to their bony bases? Of interest were data from the regional superimpositions, based on fiducial registrations of serial tracings. Statistically significant tooth movements were observed in both jaws. During the CM3 phase, the upper first molars moved anteriorly 1.9 mm when the maxillary fiducial markers were used for superimposition. In contrast, the lower first molars moved posteriorly 1.8 mm relative to the mandible; slight rebounds in both arches occurred during the fixed appliance phase.

It should be emphasized again that there was wide variation among patients in regional tooth movements in both the maxilla and mandible (Figs. 3-6).

Was the occlusal plane affected by CM3 treatment? Alterations in the occlusal plane during the management of Class III problems often is a treatment objective. Such approaches include occlusal plane rotation during orthognathic surgery as well as Class III camouflage treatment with fixed appliances and Class III elastics and with the Multiloop Edgewise Archwire (MEAW) technique [37-41].

The Functional Occlusal Plane rotated -4.0° in a counterclockwise direction during CM3 treatment. A slight rebound occurred during the fixed appliance phase, so that at the end of treatment, the net effect of the CM3 appliance on occlusal plane rotation was -3.1° , a statistically significant and clinically relevant change. An opposite occlusal plane rotation was observed in our earlier study of the CM2 appliance in adolescents [14]. A clockwise rotation of 3.9° was noted in Phase I, but rebounded in Phase II (-3.6°). Thus, the occlusal rotational change in the CM3 patients remained at the conclusion of treatment, but not in the CM2 patients.

Summary and Conclusions – the CM3 Appliance

The Carriere® Motion™ Class III appliance is an effective and efficient adjunct to fixed appliances in the management of Class III malocclusion in mature patients. The following conclusions can be drawn based on the our CM3 study:

- The treatment during Phase I with the CM3 appliance averaged 6-7 months. Phase II with fixed appliances lasted 13 months;
- Most of the treatment effects produced by the CM3 appliance were dentoalveolar in nature, with minimal skeletal adaptations observed;
- A counterclockwise rotation of the occlusal plane was observed, most of which remained at the end of treatment; and,
- The CM3 treatment produced anterior movement of the maxillary dentition relative to the mandible and posterior movement (“distalization”) of the mandibular dentition relative to its bony base.

Thus, no noteworthy skeletal changes can be anticipated with CM3 treatment. Corrective jaw surgery

still is indicated in patients with significant skeletal and profile imbalances.

FINAL REMARKS

Writing this chapter has provided the authors the unique opportunity to evaluate a relatively new orthodontic appliance system that has proved to be useful in many clinical situations. We have been fortunate to study the treatment effects in patients from Clinica Carriere in Barcelona and recently from McNamara Orthodontics in Ann Arbor, two of the early adopters of this technology.

The CM2 appliance has been used clinically by all authors of this chapter in Class II patients from early mixed dentition to adulthood. The CM2 appliance has been particularly helpful in the correction of asymmetries. Of particular interest is the novel Carriere® Motion™ Class III appliance that can be used in juveniles and adolescents as well as in minimally growing patients. The CM3 appliance offers the opportunity to manage Class III problems in older individuals without corrective jaw surgery and without extraction of premolars, providing new answers to otherwise difficult orthodontic problems.

ACKNOWLEDGEMENTS

The authors thank Dr. Luis Carriere for providing records from his patients treated with the CM2 and CM3 appliances. We also acknowledge his help in teaching us how to use the Carriere® Motion™ Class II and Class III appliances effectively and efficiently in everyday practice. We also thank Craig McMullen and Joel Lints for their help with the CM2 study and Sara Kowalski and Camaron Cheeseman for their efforts concerning the CM3 study.

REFERENCES

1. Baccetti T, Franchi L, McNamara JA, Jr. The Cervical Vertebral Maturation (CVM) method for the assessment of optimal treatment timing in dentofacial orthopedics. *Semin Orthod* 2005;11:119-129.
2. Perinetti G, Primožič J, Franchi L, Contardo L. Treatment effects of removable functional appliances in pre-pubertal and pubertal Class II patients: A systematic review and meta-analysis of controlled studies. *PLoS One* 10:e0141198 2015.
3. Pavoni C, Lombardo EC, Lione R, Faltin K, Jr., McNamara JA, Jr, Cozza P et al. Treatment timing for functional jaw orthopaedics followed by fixed appliances: a controlled long-term study. *Eur J Orthod* 2018;40:430-436.
4. Franchi L, Baccetti T, McNamara JA, Jr. Post-pubertal assessment of treatment timing for maxillary expansion and protraction therapy followed by fixed appliances. *Am J Orthod Dentofacial Orthoped* 2004;126:555-568.
5. Angelieri F, Ruellas AC, Yatabe MS, Cevidanes LHS, Franchi L, Toyama-Hino C et al. Zygomaticomaxillary suture maturation: Part II-The influence of sutural maturation on the response to maxillary protraction. *Orthod Craniofacial Res* 2017;20:153-163.
6. McNamara JA, Jr. Unpublished data 2016.
7. Petit HP. Adaptation following accelerated facial mask therapy. In: McNamara JA, Jr, Ribbens KA, Howe RP, editors. *Clinical alterations of the growing face*. Ann Arbor: Monograph 14, Craniofacial Growth Series, Center for Human Growth and Development, The University of Michigan; 1983.
8. McNamara JA, Jr. An orthopedic approach to the treatment of Class III malocclusion in young

- patients. *J Clin Orthod* 1987;21:598-608.
9. McNamara JA, Jr. Unpublished data; 2007.
 10. Carriere LA. New Class II Distalizer. *J Clin Orthod* 2004;38:224-231.
 11. Ponitz RJ. Invisible retainers. *Am J Orthod* 1971;59:266-272.
 12. McNamara JA, Jr, Kramer KL, Jeunker JP. Invisible retainers. *J Clin Orthod* 1985;19:570-578.
 13. Sandifer CL, English JD, Colville CD, Gallerano RL, Akyalcin S. Treatment effects of the Carrière distalizer using lingual arch and full fixed appliances. *J World Fed Orthod* 2014;3:e49-e54.
 14. Kim-Berman H, McNamara JA, Jr, Lints JP, McMullen C, Franchi L. Treatment effects of the Carriere® Motion 3D™ Appliance for the correction of Class II malocclusion in adolescents. *Angle Orthod* 2019;89:839-846.
 15. Hamilton CF, Saltaji H, Preston CB, Flores-Mir C, Tabbaa S. Adolescent patients' experience with the Carriere distalizer appliance. *Eur Paediatr Dent* 2013;14:219-224.
 16. Pardo Lopez B, DeCarlos Villafranca F, Cobo Plana J. Distalizer treatment of an adult Class II Division 2 malocclusion. *J Clin Orthod* 2006;40:561-565.
 17. Rodrigues H. Unilateral application of the Carriere Distalizer. *J Clin Orthod* 2011;45:177-180.
 18. Singh DP, Arora S, Yadav SK, Kedia NB. Intraoral Approaches for Maxillary Molar Distalization: Case Series. *J Clin Diagn Res* 2017;11:ZR01-ZR04.
 19. McNamara JA, Jr. A method of cephalometric evaluation. *Am J Orthod* 1984;86:449-469.
 20. Björk A, Skieller V. Normal and abnormal growth of the mandible. A synthesis of longitudinal cephalometric implant studies over a period of 25 years. *Eur J Orthod* 1983;5:1-46.
 21. Gu Y, McNamara JA, Jr. Cephalometric superimpositions: A comparison of anatomical and metallic implant methods. *Angle Orthod* 2009;78:967-976.
 22. Freeman CS, McNamara JA, Jr, Baccetti T, Franchi L. Treatment effects of the Bionator and high-pull facebow combination followed by fixed appliances in patients with increased vertical dimension. *Am J Orthod Dentofacial Orthoped* 2007;131:184-195.
 23. Schulz SO, McNamara JA, Jr, Baccetti T, Franchi L. Treatment effects of bonded RME and vertical pull chin cup followed by fixed appliances in patients with increased vertical dimension. *Am J Orthod Dentofacial Orthop* 2005;128:326-336.
 24. O'Brien K, Wright J, Conboy F, Sanjie Y, Mandall N, Chadwick S et al. Effectiveness of early orthodontic treatment with the Twin-block appliance: a multicenter, randomized, controlled trial. Part 1: Dental and skeletal effects. *Am J Orthod Dentofacial Orthop* 2003;124:234-243.
 25. Janson G, Sathler R, Fernandes TM, Branco NC, Freitas MR. Correction of Class II malocclusion with Class II elastics: a systematic review. *Am J Orthod Dentofacial Orthop* 2013;143:383-389.
 26. Burkhardt DR, McNamara JA, Jr, Baccetti T. Maxillary molar distalization or mandibular enhancement: A cephalometric comparison of the Pendulum and Herbst appliances. *Am J Orthod Dentofacial Orthop* 2003;123:108-116.
 27. Franchi L, Alvetro L, Giuntini V, Masucci C, Defraia E, Baccetti T. Effectiveness of comprehensive fixed appliance treatment used with the Forsus Fatigue Resistant Device in Class II patients. *Angle Orthod* 2011;81:678-683.
 28. Carriere LA. Interview: Carriere explains facially driven treatment of Class II and Class III. *Ortho Tribune U.S. Edition* 2015;10:1-7.
 29. Carriere LA. Non-surgical correction of severe skeletal Class III malocclusion. *J Clin Orthod* 2016;50:216-230.
 30. Cantor AM. Non-surgical treatment of a Class III malocclusion with missing lateral incisors. *Orthodontic Practice US*, <https://orthopracticeus.com/case-studies/nonsurgical-treatment-of-a-class-iii-malocclusion-with-missing-lateral-incisors>, 2018.
 31. Henry-Schein-Orthodontics. The all-new Carriere Motion Class III appliance.: *Orthodontic Practice US*, <https://orthopracticeus.com/industry-news/the-all-new-carriere-motion-class-iii-appliance->

2/; 2015.

32. McNamara JA, Jr., Franchi L, McClatchey LM, Kowalski SE, Cheeseman CC. Evaluation of late adolescent and adult patients treated with the Carriere® Motion™ Class III appliance followed by fixed appliances. *Angle Orthodontist*, to be published May 2021.
33. McNamara JA, Jr, Franchi L. The cervical vertebral maturation method: A user's guide. *Angle Orthod* 2018;88:133-142.
34. McNamara JA, Jr., Ellis E. Cephalometric analysis of untreated adults with ideal facial and occlusal relationships. *Int J Adult Orthod Orthogn Surg* 1988;3:221-231.
35. Andrews LF. The six keys to normal occlusion. *Am J Orthod* 1972;62:296-309.
36. McNamara JA, Jr, Brudon WL. *Orthodontics and Dentofacial Orthopedics*. Ann Arbor: Needham Press; 2001.
37. Wolford LM, Chemello PD, Hilliard F. Occlusal plane alteration in orthognathic surgery--Part I: Effects on function and esthetics. *Am J Orthod Dentofacial Orthop* 1994;106:304-316.
38. Esteves LS, Ávila C, Medeiros P. Changes in occlusal plane through orthognathic surgery. *Dent Press J Orthod* 2012;17:160-173.
39. Zimmer B, Nischwitz P. Therapeutic changes in the occlusal plane using intermaxillary elastics. *J Orofacial Orthopedics* 2012;73::377-386.
40. Kim YH, Han UK. The versatility and effectiveness of the Multiloop Edgewise Archwire (MEAW) in treatment of various malocclusions. *World J Orthod* 2001;2:208-218.
41. He S, Gao J, Wamawa P, Wang Y, Zou S, Chen S. Camouflage treatment of skeletal Class III malocclusion with multiloop edgewise arch wire and modified Class III elastics by maxillary mini-implant anchorage. *Angle Orthod* 2013;83:630-640.

NON-SURGICAL ADULT EXPANSION USING MARPE OR DRESDEN EXPANDERS

Manuel O Lagravère Vich, Silvia Gianoni-Capenakas, Da In Kim

ABSTRACT

Objective: Compare the skeletal, dental and airway effects of two different types of bone-anchored maxillary expanders in adult patients without the use of previous surgical midpalatal split. **Materials and Methods:** Six adult patients with skeletal transverse maxillary constriction were randomly allocated into one of 2 groups. Group A treatment consisted of a Maxillary Skeletal Expander (MARPE - Moon Design). Group B treatment involved maxillary expansion with the onplant-anchored expansion appliance (Dresden Expander). Once expansion was completed, records were obtained. Complete records were digital volumetric images (full field of view - CBCT), airway assessment (questionnaire and in-office breathing assessment) at T1 (before treatment) and T2 (after expansion). Descriptive statistics, ANOVA and t-test were applied. **Results:** Differences in expansion between the MARPE and Dresden were at most 1.75mm at the alveolar bone distance. Ratio between distances indicates a general tendency for the Dresden expanders to cause a smaller change compared to that of MARPE. With the exception of the left/right infraorbital foramen distance, the Dresden measures were on average, 37.79% smaller than the corresponding measurements for the MARPE. It was found that there was no clear significant difference between changes in breathing perception from the patients using either expander. In-office breathing test showed no difference in the measurements for each of the expanders. **Conclusions:** Use of bone-anchored maxillary expanders in adult patients present favorable results in terms of non-surgical skeletal and dental changes. Concerning airway changes, more subjects need to be analyzed to verify real effects of expansion.

KEY WORDS: Maxillary Expansion, Temporary Anchored Devices, Cone-Beam Computed Tomography, Adult Treatment, Airway Analysis

INTRODUCTION

Rapid maxillary expansion (RME) is indicated in the orthopedic treatment of transverse maxillary deficiency for correction of severe crossbites and improvement of nasal breathing[1].Expansion across the palatal suture of 0.5 to 1.0mm per day can be accomplished with RME [2]. Its primary goal is to maximize the orthopedic and minimize the orthodontic movement of teeth. The expander, a Hyrax-type screw, is banded or bonded at the first premolars and molars in the maxilla. Several studies have reported that with this approach the midpalatal suture was separated by the application of heavy intermittent forces (0.9-4.5kg, approximately 9N to 45N respectively) for a short period of time (1-3 weeks) [3-6]. Cumulative resultant forces of up to 100N can occur[7].

Since traditional expansion appliances use teeth as anchorage for expansion, there are undesired side effects on the teeth during sutural expansion. RME devices have been reported to expand the upper arch mainly by tipping and extruding the maxillary posterior teeth [8-10]. This type of tooth movement is often contraindicated and prone to relapse [11, 12]. All RME treatments involve heavy forces which probably occlude the blood vessels on the compression side in the periodontal membrane [13].

According to Perinetti et al. heavy orthodontic forces of short duration can cause biochemical and biological pulpal disease alterations [14]. A study demonstrated that the dental pulp respiration rate is depressed by 25% with a three-day continuous force application on teeth [15]. Hamersky et al. reported that during orthodontic stress, changes in the dental pulp respiration rate bringing about permanent damage and loss of the dental pulp vitality [16].

Although RME is the treatment of choice to solve transverse maxillary problems, it does not always work. When RME does not appear to be a feasible or successful treatment, surgical assisted rapid maxillary expansion (SARPE) becomes the treatment of choice in non-growing adolescents and adult patients. This procedure involves the pre-surgical split of the midpalatal suture and lateral zygomatic buttresses for later separation of the maxilla with the use of a maxillary expander. SARPE has been reported to be successful in achieving a clinically significant expansion in non-growing patients; however, this type of treatment has not been able to eliminate tipping and extrusion of the anchorage teeth [17-20]. Although widening the maxilla is an unstable procedure when compared to other surgical procedures, SARPE has been advocated to improve stability compared to nonsurgical RME [21, 22].

To overcome the side effects of expanders anchored to teeth, expanders anchored directly to the bone have been developed. Gerlach and Zahl developed a bone-borne transpalatal distractor which attached to the palate through two miniplates (one on each side of the maxilla) [18]. After obtaining positive results following the distraction period, they state that an appliance fixed on the hard palate can safely separate the suture without exerting forces on periodontal tissue or teeth. This approach brought a widening of the paranasal sinuses, preservation of the palatal arch configuration and avoidance of the unwanted dental effects. A similar appliance that does not use teeth for anchorage could conduct the force effects directly through the center of the rotation of the maxilla, therefore, eliminating all the negative dental side effects and obtaining a more linear sutural opening.

Harzer et al. also used a bone-borne expander but it had a different design. Their appliance consisted of a hyrax screw fixed on one side with an implant and the other side on an onplant with a bone screw [23]. The advantages that these bone-borne appliances are the elimination of risks such as root resorption and fenestration of the buccal cortical bone. Another advantage of this particular design of bone-borne expander is that once the screw is removed, the implant left in the palate could be used for future orthodontic anchorage for tooth movement. Harzer et al. used this appliance in surgically assisted RME in adult patients [23].

In recent years, different groups have started research on applying bone-anchored expanders in adults without previous surgical split of the midpalatal suture. One of these groups is located at the University of California Los Angeles (UCLA). The appliance/protocol developed principally by Dr. Moon in 2017 concluded that in the majority of adult cases with maxillary transverse deficiency, Miniscrew Assisted Rapid Palatal Expansion (MARPE) could be a good alternative to SARPE without the side effects discussed earlier. The results also showed a reduction of upper airway resistance and an increase in the dimension of the nasal cavity following the procedure [24]. Currently, there are different bone-anchored expander designs with differences specifically related to the area where the miniscrews are inserted. The

Moon expander, for example, has miniscrews inserted along the palatal suture while the Dresden Expander has the miniscrews inserted at the alveolar bone level between the upper second premolars and first molars [25, 26].

The objective of this study was to compare the skeletal, dental and airway effects of two different types of bone-anchored maxillary expanders in adult patients without the use of previous surgical midpalatal split.

MATERIALS AND METHODS

Trial design and any changes after trial commencement

This was a randomized clinical controlled trial with a 1:1 allocation ratio.

Participants, eligibility criteria, and settings

Ethics approval for this study was granted by the Health Research Ethics Board, University of Alberta (Pro00084145). Six consenting adult patients presenting to the Orthodontic Graduate Program, University of Alberta between July 2019 to December 2019 with skeletal transverse maxillary constriction and unilateral or bilateral posterior crossbite were included. All had a minimum of 5 mm maxillary constriction (cusp-to-fossa) as clinically determined by an orthodontist. The clinical measurement was made based on the differences in inter-molar widths, measured from the palatal cusp of the upper molars to the central fossae of the lower molars (McNamara protocol) [11].

Inclusion criteria were:

- need for maxillary expansion treatment
- need for post-expansion orthognathic surgery
- full permanent dentition erupted (except 3rd molars)
- treatment may involve postexpansion tooth extraction or not
- no syndromic characteristics or systematic diseases clinically determined or based on previous records
- males and females between the ages 17-30 years

Exclusion criteria were:

- patients with palates too narrow for placement of the expander appliance, with large tori and/or asymmetric (canted) maxillary palatal plane

Intervention

Group A treatment consisted of a Maxillary Skeletal Expander (MARPE - Moon Design). Model casts were obtained from the patient and expansion appliance was fabricated consisting of bands located on teeth 16 and 26 and soldered to the Moon design screw. The appliance was inserted in the patient's mouth after local anesthetic was placed around the palatal suture at the level of the upper permanent first molars. The appliance was cemented on teeth 16 and 26 and then four temporary anchorage devices (TADs) of 11-13mm in length were inserted (two on each side of the expansion screw) (Figure 1). The appliance was activated four times per day since the day of insertion until there was a presence of a diastema between the upper central incisors (teeth 11 and 21). Once this space was observed, activation was twice a day until the upper basal bone was wider than the lower basal bone. Once the expansion was completed, a new set of records was obtained. Then, full braces were inserted on the patient's teeth and

orthodontic alignment was started. The expander was removed once the patient wore braces with rectangular wires for a minimum of six months.

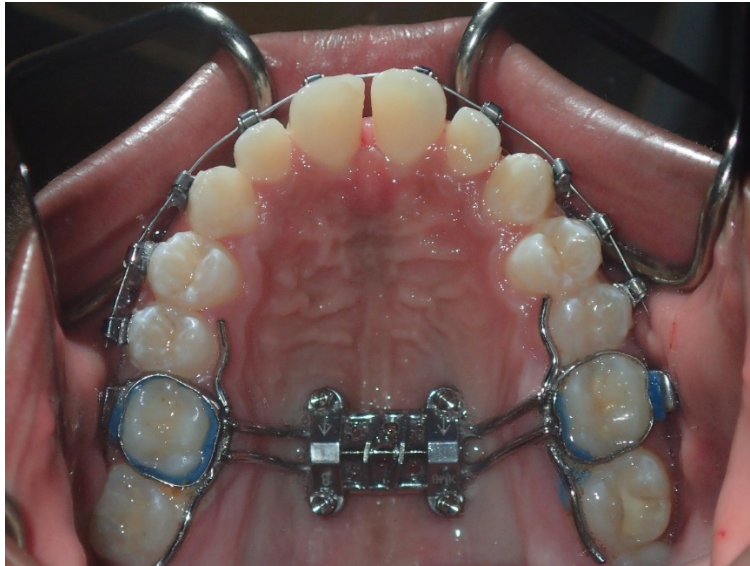

Figure 1. Maxillary Skeletal Expander

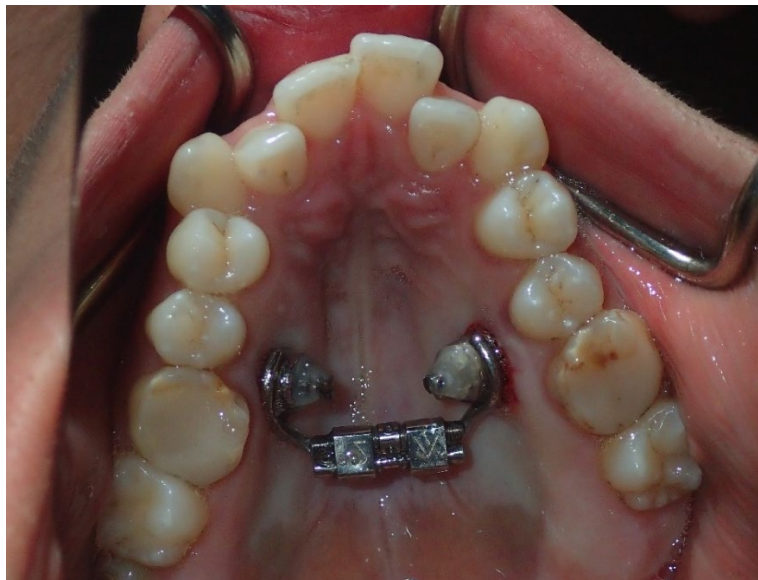

Figure 2. Dresden Expander

Group B treatment involved maxillary expansion with the onplant-anchored expansion appliance (Dresden Expander) (Figure 2) . Model casts were obtained from the patient and an expansion appliance was fabricated consisting of onplants located between the upper second premolar and first molar with an average of 9mm away from the palatal suture. The appliance was inserted in the patient's mouth after local anesthetic was placed in the palatal area between the upper second premolars and first molars. Once the appliance was inserted, two TADs (one on each side) of 9mm-11mm were inserted to hold the appliance in place. The appliance was activated two times per day since the day of insertion until there

was a presence of a diastema between the upper central incisors (teeth 11 and 21). Once this space was seen, activation stayed the same until 20% over-expansion was obtained. Once the complete expansion was realized, a new set of records were obtained. Then, full braces were inserted on the patient's teeth and orthodontic alignment was started. The expander was removed once the patient was wearing braces with rectangular wires.

Complete records consisted of digital volumetric images (full field of view - CBCT), airway assessment (questionnaire and in-office breathing assessment) and extraoral/intraoral photos were taken at T1 (before treatment) and T2 (after treatment).

Randomization (random number generation, allocation concealment, implementation)

Randomization was accomplished using an Excel worksheet creating random number blocks for six patients where these were distributed among two groups. Allocation concealment was achieved when the patient was accepted for the study, the Excel random file was accessed by a third person and the treating doctor and patient were then informed of the designated group (first come, first served).

Blinding

Blinding was only achieved when analyzing the CBCTs obtained for each patient since these were coded in terms of group and time-point. Neither the operator nor the patient could be blinded to the treatment.

Analysis of CBCTs and Airway (Landmarking, Statistical Analysis)

Once all records were obtained, measurements were done for both groups to determine the ratio between dental expansion and skeletal expansion. This was done with the use of cone-beam computed tomography (CBCT) images. Air resistance and nasal peak airflow was compared between the two groups.

3D Landmark Identification

CBCT volumes were viewed in three planes: x-y axial (right-left), x-z coronal (superior-inferior), and y-z sagittal (anterior-posterior). The principal investigator marked all 3D landmarks using virtual sphere markers with a diameter of 0.20 mm. The center of the virtual marker was used to determine the landmark's precise location in this software; hence the marker size did not affect the landmark position. The examiner was blinded to the subject's age, treatment group and time of acquisition to reduce bias.

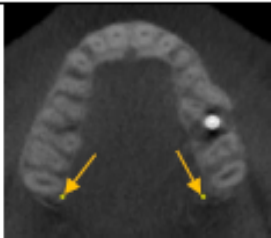
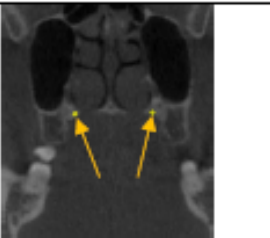
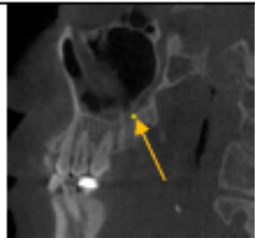
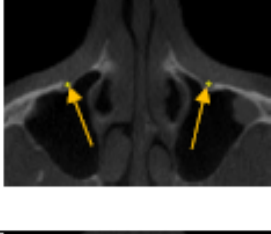

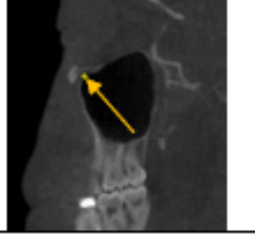
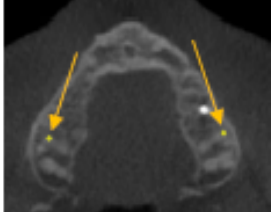
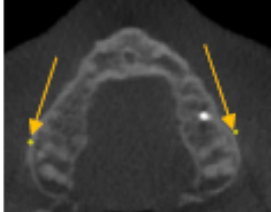
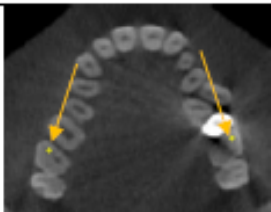
Landmark definitions

Specific definitions of all 3D skeletal and dental landmarks used in this study are detailed in Table 1.

In particular:

1. Inter-molar and inter-premolar crown widths were measured between the tips of pulp-horns (take most mesio-buccal cusp) of bilateral upper first molars and first premolars (PULP.16-26 & PULP.14-24).
2. Dental root widths consisted of orthogonal distances measured between the center of root-tips at the most apical-level (take most mesio-buccal root) of bilateral upper first molars and first premolars (APEX.16-26 & APEX.14-24).
3. Buccal alveolar bones were demarcated by the AVBN landmark, located at the same vertical and sagittal level as its corresponding root apex landmarks (AVBN.16-26 & AVBN.14-24).

Table 1: Landmark descriptions with corresponding CBCT figures (AVIZO)

	Landmarks	Description of identification on CBCT	Figure		
			Axial view (xy)	Coronal view (xz)	Sagittal view (yz)
1	Greater Palatine Foramen (Left/ Right)	Centre-most point of the inferior-most level of the greater palatine canal foramen orifice			
2	Infraorbital Foramen (Left/ Right)	Centre-most point of the inferior and anterior most level of the infraorbital canal orifice			
3	Root Apices (#16/ #26)	Tip of the buccal-mesial most root apex of the specified tooth			
4	Alveolar Bone (#16/ #26)	Centre-most point of the buccal cortical plate that corresponds to a line drawn parallel to the corresponding tooth's root apex			
5	Pulp Chamber (#16/ #26)	Superior most tip of the mesio-buccal pulp horn of the specified tooth			

Statistical analysis

Descriptive statistics were completed on all data gathered. ANOVA and t-test were applied ($p < 0.05$). With these tests, comparisons within the same groups and in between groups were executed.

RESULTS

When comparing changes over time, the differences in expansion between the MARPE and Dresden were at most 1.75mm at the alveolar bone distance (Table 2). Despite measurements via the ANOVA test indicating that all data were statistically insignificant at $\alpha < 0.05$, the small MARPE to Dresden mean difference as well as similar standard deviations between both devices make all measurements comparable.

Table 2. The average mean changes in measurement for the MSE and Dresden expanders. Distance ratios indicate the percentage of the Dresden expander to be $\pm x\%$ compared to the MARPE expander.

	Distances	Mean measurement of MARPE (mm)	Mean measurement of Dresden (mm)	MARPE and Dresden mean difference (mm)	Standard Deviation (mm)		Ratio of MARPE and Dresden distances (%)
					MSE	Dresden	
1	Greater palatine foramen (left/right)	2.44	1.78	0.66	2.32	2.37	-27.05
2	Infraorbital foramen (left/right)	0.80	1.19	-0.39	1.34	1.85	+48.75*
3	Apex 16-26	2.87	1.50	1.37	0.44	0.77	-47.74
4	Alveolar bone 16-26	2.53	0.78	1.75	1.20	0.26	-69.17
5	Pulp 16-26	5.01	4.65	0.36	1.08	0.03	-7.19

* Infraorbital foramen: the Dresden measurements were 48.75% larger than the MARPE

Overall, the ratio between distances indicates a general tendency for the Dresden expanders to cause a smaller change compared to that of the MARPE. With the exception of the left/right infraorbital foramen distance, the Dresden measures on average, 37.79% smaller than its corresponding measurements for the MARPE.

With respect to the analysis in terms of airway questionnaires measured using visual analog scales (VAS), it was found that there was no clear significant difference between changes in breathing perception from the patients using either expander (Figure 3 a,b,c).

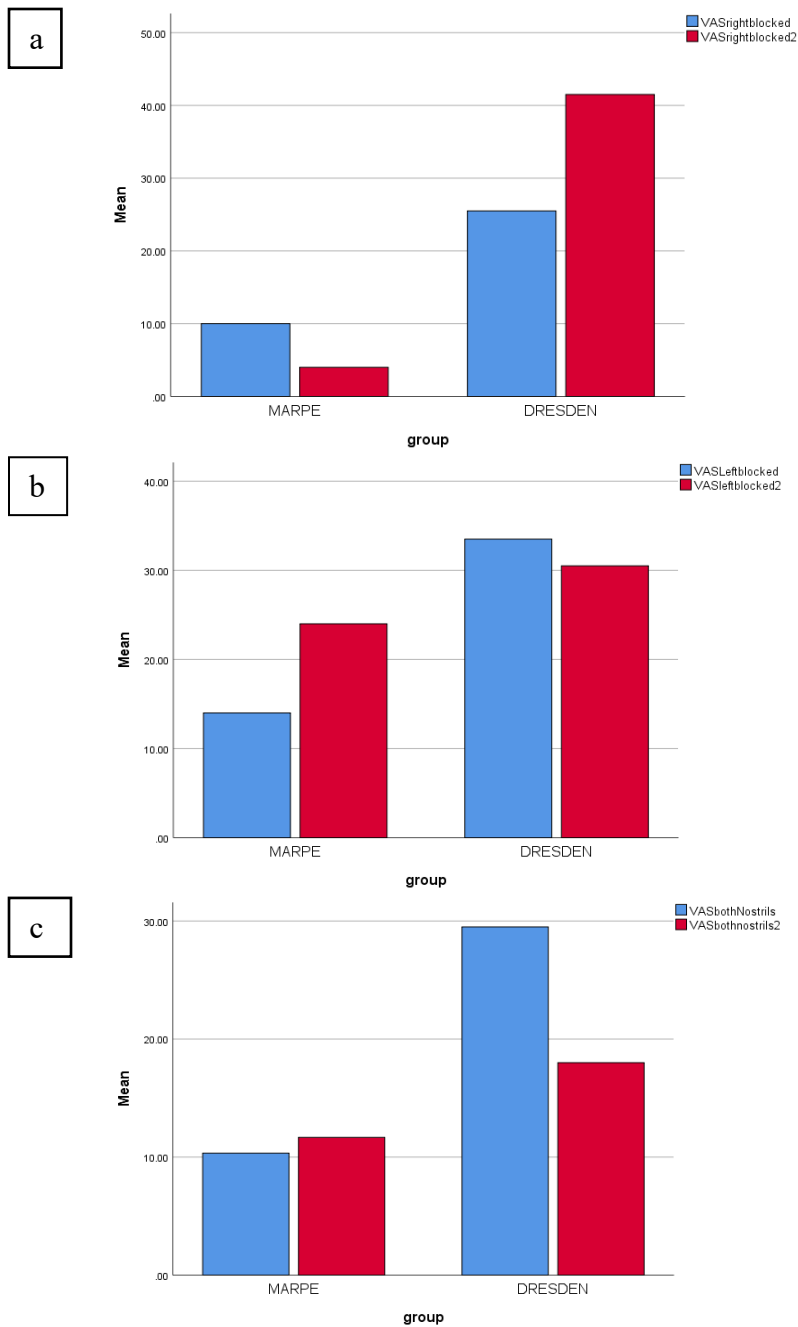
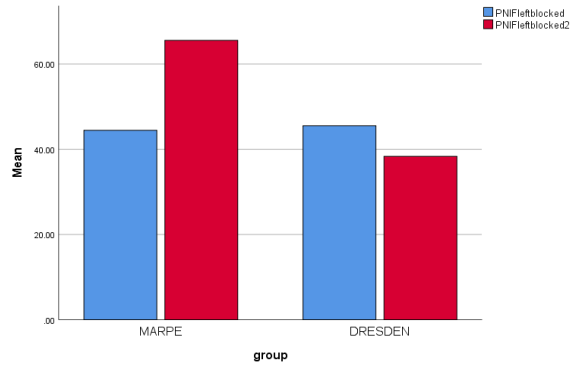


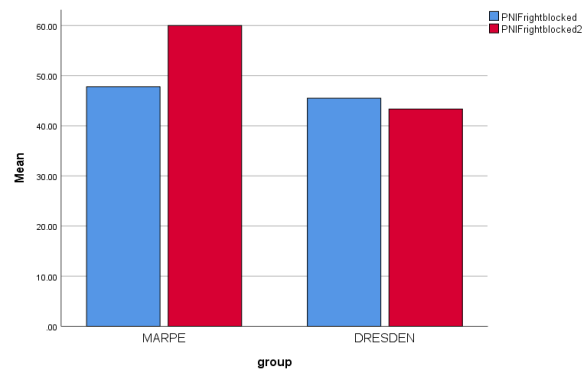
Figure 3. VAS to airway questionnaire in perception of difficulty of breathing - a) VAS with Right Nostril Blocked; b) VAS with Left Nostril Blocked; c) VAS with both Nostrils Opened (Blue - Time 1; Red - Time 2).

When analyzing the values obtained for the in-office breathing test, it was found that for the peak nasal inspiratory flow (PNIF) and for the peak oral inspiratory flow (POIF), no difference was found in the measurements for each of the expanders. Nor was there a difference found after the expansion or between expander groups. (Figure 4 a,b,c,d)

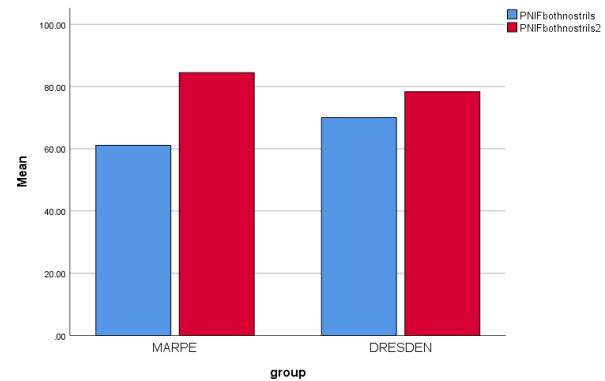
a



b



c



d

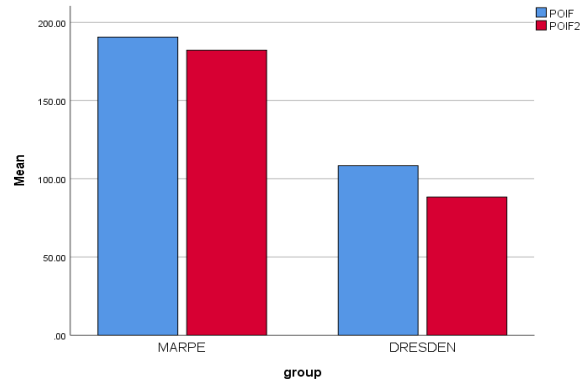


Figure 4. PNIF and POIF obtained from in-office breathing test - a) PNIF with Left Nostril Blocked; b) PNIF with Right Nostril Blocked; c) PNIF with both Nostrils Opened; d) POIF(Blue - Time 1; Red - Time 2)

DISCUSSION

RME has been successfully used in growing children and young adolescents [27]. Nevertheless, when attempting this treatment on adults, its success rate diminishes significantly. This can be due to the increased rigidity of the facial skeleton, mechanical interlocking of the midpalatal suture and the eventual closure of the circummaxillary sutures. Isaacson et al. demonstrated that the facial skeleton resistance increases with age and that the midpalatal suture is not the major resistance to expansion; rather it is the zygomatic articulations with the maxilla that restrain this expansion [28]. Because of this, when RME is being applied in a young adult there is a possibility that basal or alveolar bone movement may not occur [27, 29]. For these reasons, maxillary expansion in adults has been directed toward orthodontic tooth movement and alveolar remodeling or toward skeletal expansion with surgical repositioning using a maxillary osteotomy, such as SARME [27, 30].

When comparing SARME to RME procedures in adult and non-growing patients, a good point to consider is the discomfort associated with the treatment [31]. Even though the surgical intervention is aggressive, the expansion occurs without excessive forces on other midface structures and there is less force applied to the dental support [32]. There are some side effects that may happen which can include paresthesia, post-operative bleeding, sinus healing complications, root resorption, periodontal changes or loss of tooth vitality. These are important to consider if SARME or non-SARME treatment is suitable.

In recent years, an alternative in trying to avoid SARME and side effects from using traditional tooth-anchored maxillary expanders has been the use of bone-anchored maxillary expanders [24, 33]. Although there are several designs of bone-anchored expanders in the market, one of the main differences is the place of anchorage, being, for example, beside the suture MARPE or at the alveolar bone level (Dresden). In the present study, both designs were explored and compared in terms of presenting similar changes skeletally, dentally and airway-related in adult patients treated non-surgically.

When viewing the results, it was found that in the posterior section of the midpalatal suture of the landmark involving the greater palatine foramen, both expanders had successful separation, with the MARPE having 37.08% more expansion compared to the Dresden. The mean value of 2.44mm of expansion achieved in the present study can be compared to the study conducted by Cantarella et al., where the posterior inter-zygomatic distance was found to be 2.4mm, and the anterior intermaxillary distance was found to be 2.4mm [34]. Although these distances were measured using different landmarks such as those that include outer-most points of the zygomaticotemporal sutures, and of the anterior most points of the maxilla, findings are comparable to the present study, as these results indicate that the maxillary and zygomatic bones have been significantly displaced by use of the MSE [34].

The landmark measurements of the infraorbital foramen of both expanders show a relatively smaller amount of expansion compared to their posterior counterparts. The MARPE shows a value of 0.8mm for the infraorbital foraminal change relative to the 2.44mm change in the greater palatine foramen. The Dresden shows a value of 1.19mm and 1.78mm, respectively. This finding corresponds to a study conducted by Braun et al. which found the center of resistance of maxillary expanders to be at the frontonasal suture [35]. With the infraorbital foramen being located slightly superior to this point, heavy pressure is correlated with expansion yet since this location is close to the maxillary fulcrum of rotation, more pressure and less palatal expansion is expected, as was found in the present study [36].

Crown tipping can be analyzed through comparing the apical to pulpal expansion. The Dresden expander had slightly more crown tipping of 3.15mm compared to the MSE which had crown tipping of 2.14mm. However, both findings were not statistically significant ($p>0.05$). Similar findings can be seen in a study published by Lagravère et al. who discovered that for the Dresden expander, there is molar crown displacement of 1.84mm unilaterally, which may lead to asymmetric maxillary constriction [33]. This randomized control trial also had similar findings to the Dresden RME, although it does show a low dental to skeletal expansion which causes an asymmetric pattern of expansion relative to the mid-sagittal plane [33]. On the contrary, the MARPE may achieve less crown tipping through its design of bi-cortical engagement to disarticulate sutures such as that of the pterygopalatine, to transmit less force on the alveolar bone [37]. The same principles may explain the larger alveolar bone expansion of the Dresden (3.87mm) relative to the MARPE (2.48mm).

Results of the current study involving bone-anchored expanders can be compared to maxillary expansion used by surgical methods such as the modified Le Fort I osteotomy without pterygomaxillary separation, SARPE [38]. In a five-year retrospective study conducted by Haq et al., the total amount of separation achieved by SARPEs ranged from 5.19mm to 8.78mm [39]. Similarly, other studies also reported the total separation of the SARPE to be at 8mm [40, 41]. Interestingly, studies have shown that the amount of skeletal expansion was on average at maximum 3.49 ± 1.37 mm [42-44]. Although these studies consider the midpalatal suture separation as well as clinical clues such as the amount of diastema present, they are comparable to posterior bony landmarks such as the greater palatine foramina used in the present study. Despite possible large suture openings by SARPE as previously mentioned, the amount of relapse makes the final result of the SARPE similar to those achieved by the expanders analyzed in this study [45, 46]. A finite element model analysis conducted by Chen et al. has found that the MARPE shows higher stress distribution over to bony structures such as the nasal-maxillary suture, resulting in less dental alveolar changes, which are much more prone to relapse [47].

Using acoustic and sonographic measurements, Wriedt et al. found volumetric changes on the nasal portion of the maxillary complex [48]. The increased dimensions of the nasal airway may result in an improvement in the nasal patency [48-50]. Unfortunately in the present study, no major differences in breathing perception nor in-office tests were noticed after using the maxillary expander nor between expanders. This research should be taken with caution since the sample was small and patients were not evaluated for having sleep apnea problems as an inclusion criterion.

CONCLUSIONS

- Use of bone-anchored maxillary expanders in late adolescents and adult patients presents favorable results in terms of non-surgical skeletal and dental changes.
- Concerning airway changes, more samples need to be analyzed with patients already presenting apnea problems to verify real effects of this expansion.

REFERENCES

1. Basciftci FA, Mutlu N, Karaman AI, Malkoc S, Küçükolbasi H. Does the timing and method of rapid maxillary expansion have an effect on the changes in nasal dimensions? *Angle Orthod* 2002;72(2):118-123.
2. Proffit W, Fields HW. *Contemporary Orthodontics*. St. Louis, MO: Mosby 2000.
3. Wertz R, Dreskin M. Midpalatal suture opening: a normative study. *Am J Orthod* 1977;71(4):367-381.
4. Wertz RA. Skeletal and dental changes accompanying rapid midpalatal opening. *Am J Orthod* 1970;58:41-66.
5. Haas AJ. The treatment of maxillary deficiency by opening the midpalatal suture. *Angle Orthod* 1965;35:200-217.
6. Taşpınar F, Akgül N, Simşek G, Ozdabak N, Gündoğdu C. The histopathological investigation of pulpal tissue following heavy orthopaedic forces produced by rapid maxillary expansion. *J Int Med Res* 2003;31(3):197-201.
7. Zimring JF, Isaacson RJ. Forces produced by rapid maxillary expansion. 3. Forces present during retention. *Angle Orthod* 1965;35:178-186.
8. Asanza S, Cisneros GJ, Nieberg LG. Comparison of Hyrax and bonded expansion appliances. *Angle Orthod* 1997;67(1):15-22.
9. Memikoğlu TU, Iseri H. Nonextraction treatment with a rigid acrylic, bonded rapid maxillary expander. *J Clin Orthod* 1997;31(2):113-118.
10. Işeri H, Özsoy S. Semirapid maxillary expansion--a study of long-term transverse effects in older adolescents and adults. *Angle Orthod* 2004;74(1):71-78.
11. Bell RA. A review of maxillary expansion in relation to rate of expansion and patient's age. *Am J Orthod* 1982;81(1):32-37.
12. Sarnas KV, Bjork A, Rune B. Long-term effect of rapid maxillary expansion studied in one patient with the aid of metallic implants and roentgen stereometry. *Eur J Orthod* 1992;14(6):427-432.
13. Timms DJ. A study of basal movement with rapid maxillary expansion. *Am J Orthod* 1980;77:500-507.
14. Perinetti G, Varvara G, Festa F, Esposito P. Aspartate aminotransferase activity in pulp of orthodontically treated teeth. *Am J Orthod Dentofacial Orthop* 2004;125(1):88-92.
15. Unsterseher RE, Nieberg LG, Weimer AD, Dyer JK. The response of human pulpal tissue after orthodontic force application. *Am J Orthod Dentofacial Orthop* 1987;92(3):220-224.
16. Hamersky PA, Weimer AD, Taintor JF. The effects of orthodontic force application on the pulpal tissue respiration rate in the human premolar. *Am J Orthod* 1980;77(4):368-678.
17. Handelman CS. Nonsurgical rapid maxillary alveolar expansion in adults: a clinical evaluation. *Angle Orthod* 1997;67:291-305; discussion 306-308.
18. Gerlach KL, Zahl C. Transversal palatal expansion using a palatal distractor. *J Orofac Orthop* 2003;64(6):443-449.
19. Glassman AS, Nahigian SJ, Medway JM, Aronowitz HI. Conservative surgical orthodontic adult rapid palatal expansion: sixteen cases. *Am J Orthod* 1984;86(3):207-213.
20. Kraut RA. Surgically assisted rapid maxillary expansion by opening the midpalatal suture. *J Oral Maxillofac Surg* 1984;42(10):651-655.
21. Pogrel MA, Kaban LB, Vargervik K, Baumrind S. Surgically assisted rapid maxillary expansion in adults. *Int J Adult Orthodon Orthognath Surg* 1992;7(1):37-41.
22. Proffit WR, Turvey TA, Phillips C. Orthognathic surgery: a hierarchy of stability. *Int J Adult Orthodon Orthognath Surg* 1996;11(3):191-204.
23. Harzer W, Schneider M, Gedrange T. Rapid maxillary expansion with palatal anchorage of the hyrax expansion screw--pilot study with case presentation. *J Orofac Orthop* 2004;65(5):419-424.

24. Brunetto DP, Sant'Anna EF, Machado AW, Moon W. Non-surgical treatment of transverse deficiency in adults using Microimplant-assisted Rapid Palatal Expansion (MARPE). *Dental Press J Orthod* 2017;22(1):110-125.
25. Choi SH, Shi KK, Cha JY, Park YC, Lee KJ. Nonsurgical miniscrew-assisted rapid maxillary expansion results in acceptable stability in young adults. *Angle Orthod* 2016;86(5):713-720.
26. Tausche E, Hansen L, Hietschold V, Lagravère MO, Harzer W. Three-dimensional evaluation of surgically assisted implant bone-borne rapid maxillary expansion: A pilot study. *Am J Orthod Dentofacial Orthop* 2007;131(4):S92-S99.
27. Lines PA. Adult rapid maxillary expansion with corticotomy. *Am J Orthod* 1975;67(1):44- 56.
28. Isaacson RJ, Wood JL, Ingram AH. Forces produced by rapid maxillary expansion. I. Design of the force measuring system. *Angle Orthod* 1964;34(4):256-270.
29. Isaacson RJ, Murphy TD. Some effects of rapid maxillary expansion in cleft lip and palate patients. *Angle Orthod* 1964;34(3):143-154.
30. Timms DJ. The effect of rapid maxillary expansion on nasal airway resistance. *Br J Orthod* 1986;13(4):221-228.
31. Alpern MC, Yurosko JJ. Rapid palatal expansion in adults with and without surgery. *Angle Orthod* 1987;57(3):245-263.
32. Capelozza Filho L, Mazzottini R, Cardoso Neto J, da Silva Filho OG. Rapid maxillary expansion with surgical assistance. *Ortodontia* 1994;27:21-30.
33. Lagravère MO, Ling CP, Woo J, Harzer W, Major PW, Carey JP. Transverse, vertical, and anterior-posterior changes between tooth-anchored versus Dresden bone-anchored rapid maxillary expansion 6 months post-expansion: A CBCT randomized controlled clinical trial. *Int Orthod* 2020; 18(2): 308-316.
34. Cantarella D, Dominguez-Mompell R, Moschik C, Sfogliano L, Elkenawy I, Pan HC, et al. Zygomaticomaxillary modifications in the horizontal plane induced by micro-implant-supported skeletal expander, analyzed with CBCT images. *Prog Orthod* 2018;19(1):41.
35. Braun S, Bottrel JA, Lee KG, Lunazzi JJ, Legan HL. The biomechanics of rapid maxillary sutural expansion. *Am J Orthod Dentofacial Orthop* 2000;118(3):257-261.
36. MacGinnis M, Chu H, Youssef G, Wu KW, Machado AW, Moon W. The effects of micro-implant assisted rapid palatal expansion (MARPE) on the nasomaxillary complex—a finite element method (FEM) analysis. *Prog Orthod* 2014;15(1):52.
37. Cantarella D, Dominguez-Mompell R, Mallya SM, Moschik C, Pan HC, Miller J, et al. Changes in the midpalatal and pterygopalatine sutures induced by micro-implant-supported skeletal expander, analyzed with a novel 3D method based on CBCT imaging. *Prog Orthod* 2017;18(1):34.
38. Goldenberg DC, Alonso N, Goldenberg FC, Gebrin ES, Amaral TS, Scanavini MA, Ferreira MC. Using computed tomography to evaluate maxillary changes after surgically assisted rapid palatal expansion. *J Craniofac Surg* 2007;18(2):302-311.
39. Haq J, Lo M, Collier J. Five-year experience of SARPE in a craniofacial setting: outcomes, complications and learning points. *Br J Oral Maxillofac Surg* 2017;55(10):75-76.
40. Loddi PP, Pereira MD, Wolosker AB, Hino CT, Kreniski TM, Ferreira LM. Transverse effects after surgically assisted rapid maxillary expansion in the midpalatal suture using computed tomography. *J Craniofac Surg* 2008;19(2):433-438.
41. Harzer W, Schneider M, Gedrange T, Tausche E. Direct bone placement of the hyrax fixation screw for surgically assisted rapid palatal expansion (SARPE). *J Oral Maxillofac Surg* 2006;64(8):1313-1317.
42. Chamberland S, Proffit WR. Closer look at the stability of surgically assisted rapid palatal expansion. *J Oral Maxillofac Surg* 2008;66(9):1895-1900.
43. Byloff FK, Mossaz CF. Skeletal and dental changes following surgically assisted rapid palatal expansion. *Eur J Orthod* 2004;26(4):403-409.

44. Berger JL, Pangrazio-Kulbersh V, Borgula T, Kaczynski R. Stability of orthopedic and surgically assisted rapid palatal expansion over time. *Am J Orthod Dentofacial Orthop* 1998;114(6):638-645.
45. Koudstaal MJ, Poort LJ, van der Wal KG, Wolvius EB, Prah-Andersen B, Schulten AJ. Surgically assisted rapid maxillary expansion (SARME): a review of the literature. *Int J Oral Maxillofac Surg* 2005;34(7):709-714.
46. Lagravère MO, Major PW, Flores-Mir C. Dental and skeletal changes following surgically assisted rapid maxillary expansion. *Int J Oral Maxillofac Surg* 2006;35(6):481-487.
47. Chen YF, Yoon A, Chang HC, Liu SC, Chen YC. Biomechanical and stress distribution effects of maxillary expansion methods (sarpe, marpe, dome) using finite element model. Conference Abstract. *Sleep Medicine* 2017;40 (Suppl 1):57.
48. Wriedt S, Kunkel M, Zentner A, Wahlmann UW. Surgically assisted rapid palatal expansion. An acoustic rhinometric, morphometric and sonographic investigation. *J Orofac Orthop* 2001;62(2):107-115.
49. Gilon Y, Heymans O, Limme M, Brandt L, Raskin S. Indications and implications of surgical maxillary expansion in orthodontic surgery. *Rev Stomatol Chir Maxillofac* 2000;101(5):252-258.
50. Neubert J, Somsiri S, Howaldt HP, Bitter K. Surgical expansion of midpalatal suture by means of modified Le Fort I osteotomy. *Dtsch Z Mund Kiefer Gesichtschir* 1989;13(1):57-64.

LONG-TERM ORAL HEALTH EFFECTS OF ORTHODONTIC CLASS II TREATMENT

Niko C. Bock, Sabine Ruf

ABSTRACT

Long-term data of orthodontically treated patients are generally scarce and especially for oral health. No distinct beneficial long-term effect of any orthodontic treatment procedure has been proven so far. So, the aim of the present investigation was to assess the long-term effects of orthodontic Class II treatment on oral health in terms of tooth decay, periodontal health and signs and symptoms of temporomandibular disorders. The investigation is based on a recall (≥ 15 years post-treatment) of patients treated with a Herbst-Multibracket appliance during adolescence. 72 out of 116 potential participants could be examined. The assessment comprised of an anamnesis, clinical and functional examination, and evaluation of study models as well as intraoral photographs. The treatment and long-term post-treatment data were compared. Additional data were used from a Finnish Class I control group (n=31) of orthodontically untreated but longitudinally monitored subjects with no orthodontic treatment needed during childhood and adolescence as well as from the German Oral Health studies (epidemiological benchmark data from population-representative cross-sectional studies of different age cohorts). The results of the investigation demonstrate the following for Class II malocclusion:

- orthodontically treated patients have a similar risk for oral health impairment in terms of tooth decay and periodontal disease as untreated Class I controls without orthodontic treatment need during adolescence.
- orthodontically treated respectively guided patients have a lower risk for oral health impairment in terms of tooth decay and periodontal disease than the general population.
- Herbst-Multibracket appliance treatment neither decreases nor increases the risk for temporomandibular disorder development in later life.

KEY WORDS: Class II, Long-term, Oral Health, TMD

INTRODUCTION

Orthodontic treatment (Tx) is supposed to result in a state of functional and occlusal balance promoting superb long-term oral health (OH) and oral health related quality of life. While proof for such effects from orthodontic interventions has been demanded by both the authorities and the public, especially in recent years, the benefit of orthodontic Tx on OH still remains controversial.

Systematic reviews have neither been able to demonstrate a direct relationship between crowding and caries nor a positive effect of orthodontic Tx on periodontal health or temporomandibular dysfunction (TMD) [1-4]. On the other hand, an association between existing malocclusion and periodontal disease has been determined as well as a long-term difference in prevalence for tooth-related problems in life when comparing children with normal occlusion and no orthodontic Tx need to those exhibiting occlusal characteristics demanding orthodontic Tx [5, 6]. Such a long-term difference was also found for self-rated dental appearance between treated and

untreated cohorts [7]. In terms of TMD, according to a review, orthodontic Tx seems to neither prevent nor increase the signs and symptoms of TMD long-term [8].

For clinicians, however, these findings – probably not reflecting the effects observed in daily practice – might be difficult to understand. A possible reason for this controversy is the fact that OH including TMD can be influenced by multiple factors besides orthodontics. Furthermore, the rather slow progression of many OH conditions like tooth decay, periodontal disease and also TMD, as well as the sometimes very long latency times of possibly harmful exposures (years to decades), impede an investigation of preventive effects initiated by orthodontic Tx. In terms of TMD, matters are even more complicated due to a known substantial fluctuation [9, 10].

Proving a causal respectively preventive effect of orthodontic Tx or malocclusion would require a randomized trial involving untreated controls; the long-term perspective, however, prohibits this kind of study design from an ethical and financial point of view. And finally, malocclusion is not a uniform condition; instead, a large variety of malocclusions and different degrees of severity can eventuate in countless combinations in which in turn have different effects on OH. This has rarely been considered in the existing respective reviews studies available in the literature. Thus, focusing on a strictly defined type of malocclusion with high severity, it might be possible to determine effects.

Tx of Class II malocclusion has been investigated extensively. Different Tx protocols have been evaluated – mainly in terms of effectiveness and mainly regarding the active Tx period only [11-18]. While long-term data are generally scarce, this is especially true for Class II Tx effects on OH [19-21]. Therefore, it was the aim of the current project to assess the long-term effects of Herbst-Multibracket appliance (MBA) Class II Tx on OH.

MATERIALS & METHODS

After obtaining ethical approval (Nr. 146/13) and registration (WHO: ID DRKS00006354) of the protocol, the archive of the Department of Orthodontics, University of Giessen, Germany was screened for patients fulfilling the following inclusion criteria: Class II malocclusion before Tx, Herbst-MBA Tx, end of active Tx at least 15 years ago.

A total of 152 patients fulfilled these criteria. The mean age was 14.0 years at the start of Herbst-MBA Tx, when all patients exhibited a severe Class II malocclusion; the average Class II molar relationship was 0.8 cusp widths, the mean Peer Assessment Rating (PAR) score 27.4 points [22]. Using the contact details from the period of active Tx and the internet, it was possible to locate 116 patients who were asked to participate in a recall (Figure 1). While 72 of them gave informed consent and took part in the study (group: “treated Class II participants”), 44 did not. Where available, their data as well as those of the patients who could not be located (group: “non-participants”) were used for comparison (Table 1) and preclusion of a selection bias.

After gathering the anamnesis including OH related problems, a clinical intraoral examination was performed and impressions as well as photographs were taken. A functional examination of the TMJ and the associated structures followed. In addition, the mandibular border movements were measured to the nearest 0.5 mm using a manual caliper. To assess the OH changes since the end of active Tx, radiographs, photographs, study models and TMD data (as far as available) from after active orthodontic Tx (T1) were used for evaluation and comparison to the current situation (T2). The general dental status was evaluated using the “Decayed, Missing, Filled Teeth Index” (DMFT) and a DMFT-modification assessed from panoramic radiographs (MFT-Index) [23].

Table 1. Comparison of the treated Class II participants' and non-participants' data: the mean value (Mean), standard deviation (SD) and p-value of the respective group difference are given for age, PAR score, MFT, magnitude of gingival recessions (teeth 32-42), Helkimo Index and RDC/TMD respectively DC/TMD. Reprinted/modified from: "Bock NC, Saffar M, Hudel H, Evälahti M, Heikinheimo K, Rice DP, Ruf S. Long-term oral-health effects of Class II orthodontic treatment. J Orofac Orthop 2018;79(2):96-108".

Table 1		Treated Class II		p	
		participants	non-participants		
		Mean±SD	Mean±SD		
		n=72	n=80		
Age (years)	T1	15.4±1.9	15.9±3.2	0.216	
PAR score (total)	T0	23.9±9.2	30.4±9.7	0.000	
	T1	3.2±2.0	7.5±4.4	0.000	
MFT	T1	3.1±3.8	3.4±3.5	0.499	
Magnitude of gingival recessions (mm)	Tooth 32	0.0±0.0	0.1±0.3	0.131	
	Tooth 31	0.0±0.1	0.1±0.3	0.058	
	Tooth 41	0.0±0.1	0.1±0.6	0.081	
	Tooth 42	0.0±0.0	0.0±0.3	0.227	
Helkimo index	Anamnesis ≥A _I	T0	15.4% (n=6 out of 39)	12.5% (n=4 out of 32)	0.728
		T1	11.4% (n=5 out of 44)	7.0% (n=3 out of 43)	0.479
	Dysfunction ≥D _I	T0	38.5% (n=15 out of 39)	46.9% (n=15 out of 32)	0.475
		T1	27.3% (n=12 out of 44)	27.9% (n=12 out of 43)	0.947
RDC/TMD and DC/TMD	Pathology	T0	17.9% (n=7 out of 39)	12.5% (n=4 out of 32)	0.528
		T1	9.1% (n=4 out of 44)	4.7% (n=2 out of 43)	0.414

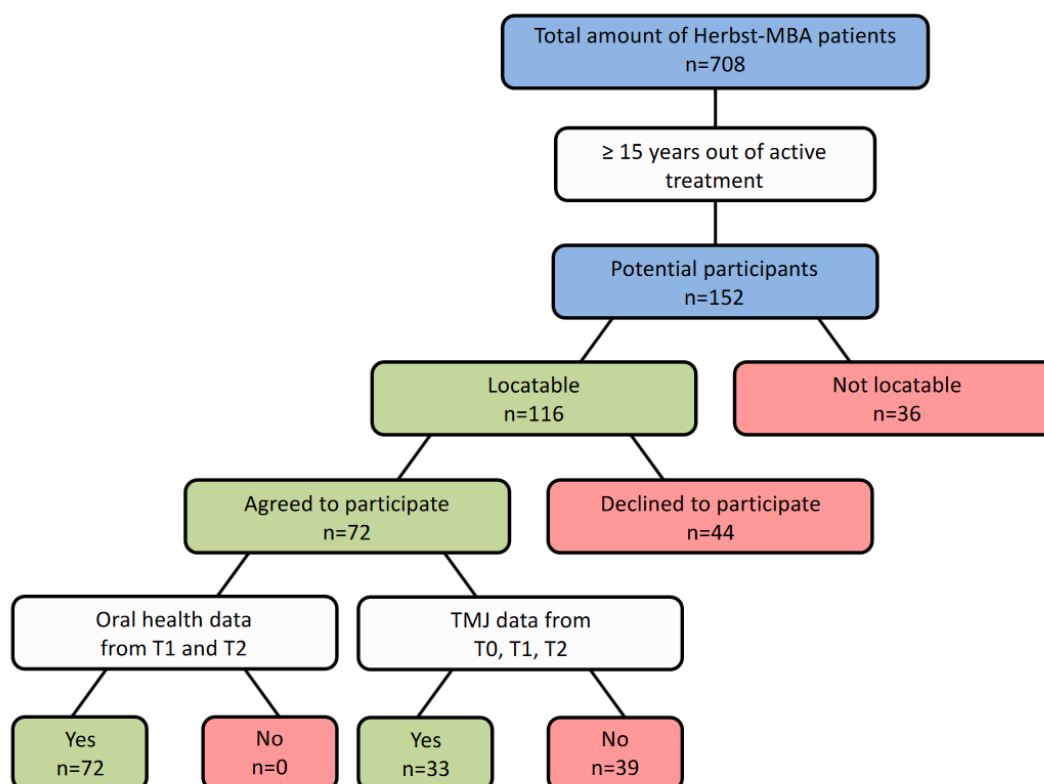


Figure 1. Flow chart of the treated Class II participants and non-participants.

To assess gingival health clinically, the Periodontal Screening Index (PSI/PSR-Index) was applied [24, 25]. In addition, the study casts were assessed for the existence and possible dimension of labial gingival recessions (teeth 32-42); these were quantified in mm by measuring the labial crown height as distance from the center of the incisal edge to the deepest point of the vestibulogingival margin.

Table 2. Categories of the Helkimo anamnestic (A_i) and clinical (D_i) dysfunction index. [26]
Reprinted from: "Ruf S, Bock NC. Long-term (≥ 15 years) effects of Class II treatment: A longitudinal and cross-sectional study on signs and symptoms of temporomandibular disorders. Eur J Orthod 2019;41(2):172-179" by permission of Oxford University Press/European Orthodontic Society.

Table 2			
A_i0	No anamnestic dysfunction	- No symptoms	
A_iI	Mild anamnestic dysfunction	- TMJ sounds (clicking or crepitation)	
		- Jaw fatigue or jaw stiffness	
A_iII	Severe anamnestic dysfunction	- Difficulty in mouth opening or jaw locking	
		- Difficulty in mouth closure or jaw luxation	
		- Painful TMJ region or masticatory musculature	
		- Painful jaw movements	
Clinical dysfunction index (D_i = A+B+C+D+E)			
D_i0	No dysfunction	No clinical symptoms	
D_iI	Mild dysfunction	1-4 points	
D_iII	Moderate dysfunction	5-9 points	
D_iIII	Severe dysfunction	>10 points	
A	Impaired mobility	1P	≤39mm opening or ≤ 6mm lateral
		5P	≤29mm opening or ≤ 3mm lateral
B	Altered function	1P	Uni- or bilateral clicking or crepitation or mandibular deviation ≥ 2mm
		5P	Luxation or locking
C	Muscle Pain	1P	Sensitivity to pressure 1-3 places
		5P	Sensitivity to pressure ≥ 4 places
D	TMJ pain	1P	Sensitivity to lateral pressure
		5P	Sensitivity to posterior pressure
E	Painful function	1P	1 painful movement
		5P	≥2 painful movements

At recall (T2), 42 of the 72 treated Class II participants (58.3%) wore no retainers at all. 29 participants (40.3%) had a lower fixed canine-to-canine retainer (26 fixed on the canines online, 3 fixed on all teeth) which was combined with an upper fixed retainer in 5 participants. One participant (1.4%) wore an upper fixed retainer only.

The findings of the functional examination were categorized according to the Helkimo index [26] (Table 2) and Research Diagnostic Criteria for Temporomandibular Disorders (RDC/TMD) respectively Diagnostic Criteria for Temporomandibular Disorders (DC/TMD) [27, 28]. For 33 of the 72 treated Class II participants previous TMD data from before and after Tx were retrievable from the patient's files. These former TMD data recorded according to RDC/TMD were examined together with the present data recorded according to DC/TMD [27, 28]. The data of the remaining 39 participants and the "non-participants" were used for preclusion of a selection bias. The clinical examinations of the longitudinal TMD subgroup were performed by the same calibrated investigator (S.R.) with long-term TMD experience who had already performed the examinations of these subjects ≥ 15 years ago [29, 30].

Control group

The records of a "double negative, normal" control group were used for comparison [31]. These untreated Class I controls with no orthodontic Tx need (n=31) participated in a longitudinal study on dentoalveolar development in Finland. The respective participants were observed from age 7 years until 33 years. Those records which were obtained at age 15 years (T1) and age 33 years (T2) corresponded best to the treated sample of Class II participants (Table 3).

Study models from T1 and T2 were available as well as panoramic radiograph from T2 (n=28 of 31). In addition, data from a clinical oral examination (Community Periodontal Index=CPI) and the anamnesis including possible complaints regarding the orofacial system (T2) were evaluated [32].

Table 3. Sex, age (in years), duration of the observation period T1-T2 (in years), PAR score and magnitude of gingival recessions (teeth 32-42) of the treated Class II participants and the "normal" untreated Class I controls. The mean value (Mean), standard deviation (SD) and p-value (p) of the respective group difference are given. Reprinted/modified from: "Bock NC, Saffar M, Hudel H, Evälahti M, Heikinheimo K, Rice DP, Ruf S. Long-term oral-health effects of Class II orthodontic treatment. J Orofac Orthop 2018;79(2):96-108".

Table 3		Treated Class II	Untreated Class I	p
		participants	controls	
		Mean±SD	Mean±SD	
		n=72 (40♀:32♂)	n=31 (17♀:14♂)	
Age (years)	T1	15.4±1.9	15.3±0.6	0.329
	T2	33.7±3.0	32.9±1.2	0.219
Observation period (years)	T1-T2	18.3±2.9	17.6±1.2	0.877
PAR score (total)	T1	3.2±2.0	8.7±3.7	0.000
	T2	7.5±5.1	8.8±3.3	0.196
Magnitude of gingival recessions (mm)	Tooth 32	T1	0.0±0.1	0.136
		T2	0.1±0.2	0.469
	Tooth 31	T1	0.0±0.1	0.288
		T2	0.1±0.4	0.267
	Tooth 41	T1	0.0±0.1	0.392
		T2	0.2±0.5	0.903
	Tooth 42	T1	0.0±0.0	0.145
		T2	0.0±0.1	0.845

Table 4. Structure of the relevant data of the German Oral Health Studies (DMS I, DMS III, DMS IV and DMS V), which were population-representative cross-sectional studies with randomly chosen participants of different age cohorts selected on the basis of the relevant WHO criteria and the customary principles of international oral epidemiology. Reprinted from: “Bock NC, Saffar M, Hudel H, Evälahti M, Heikinheimo K, Rice DP, Ruf S. Long-term oral-health effects of Class II orthodontic treatment. *J Orofac Orthop* 2018;79(2):96-108” by permission of Springer Nature.

Table 4	DMS V	DMS IV	DMS III	DMS I
Year of publication	2016	2006	1999	1991
Year of investigation	2014	2005	1997	1989
Number of participants	n=4609	n=4631	n=5040	n=1763
Age cohorts	12	12	12	8-9
	-	15	-	13-14
	35-44	35-44	35-44	35-44
	65-74	65-74	65-74	45-54
	75-100	-	-	-

Benchmark data

Data from the German Oral Health Studies (DMS I, III, IV and V; Table 4) were also applied to judge the OH effects [33-36]. If not otherwise indicated, comparisons were performed exclusively with age-corresponding cohorts.

In addition, epidemiological benchmark data on OH from population-representative cross-sectional studies of different age cohorts (Tables 5 and 6) were used to account for population wide changes during the time interval of approximately 15 years between the recall assessments in the treated Class II participants (2014/2015) and the untreated Class I controls (1998/1999) [33-45].

The PSI [25] is the German version of PSR [24] and very similar to CPI; particularly the grades 0, 1 and 2 (the most relevant in the current investigation) are almost equal. For ease of reading, only the term CPI is used in all respective tables, figures and the discussion of the results.

All study cast measurements were performed twice (N.B.) with the mean value of both measurements being used for further processing to keep the method error to a minimum.

Besides descriptive statistical analysis, normal distribution was assessed using the Shapiro-Wilk and Kolmogorov-Smirnov tests. In case of normal distribution, the t-test and ANOVA were applied. For other data, the Chi-Square-, Mann-Whitney-U- and Kruskal-Wallis-tests respectively the Fisher’s exact- and McNemar-tests were used.

RESULTS

The following results have already been published in these two articles:

- Bock NC, Saffar M, Hudel H, Evälahti M, Heikinheimo K, Rice DP, Ruf S. Long-term oral-health effects of Class II orthodontic treatment. *J Orofac Orthop* 2018;79(2):96-108. [46]
- Ruf S, Bock NC. Long-term (≥ 15 years) effects of Class II treatment: A longitudinal and cross-sectional study on signs and symptoms of temporomandibular disorders. *Eur J Orthod* 2019;41(2):172-179. [47]

The general clinical and occlusal data of all 152 participants and non-participants from before and after Tx as well as their longitudinal changes have been published in two separate articles [48,

49]. For both treated Class II participants and non-participants, Herbst-MBA Tx had resulted in successful Class II correction. There were no significant group differences between the treated Class II participants and the non-participants or between the TMD subgroup and the remaining participants.

Treated Class II participants vs. non-participants (Table 1)

The 72 treated Class II participants and the 80 non-participants did not differ ($p \geq 0.05$) regarding age and MFT after Tx. The total PAR score was by 6.5/4.3 points higher in the non-participants before Tx ($p < 0.001$)/after Tx ($p < 0.001$). The magnitude of gingival recessions on the lower incisors did not show clinically relevant group differences ($p = 0.058-0.227$). In terms of TMD, no group difference existed either ($p \geq 0.05$); the 72 treated Class II participants and 80 non-participants did not differ regarding the prevalence of positive anamnestic and dysfunctional Helkimo index scores or pathologic RDC/TMD and DC/TMD findings.

Oral health data (Tables 3-6, Figures 2-4)

The mean age of the 72 treated Class II participants (40 females, 32 males) was 15.4 ± 1.9 years after Tx (T1) and 33.7 ± 3.0 years at recall (T2). For the untreated Class I controls (17 females, 14 males), the values were 15.3 ± 0.6 years at T1 and 32.9 ± 1.2 years at T2. The duration of the post-Tx observation period was 18.3 ± 2.9 years (treated Class II participants) respectively 17.6 ± 1.2 years (untreated Class I controls) showing good comparability.

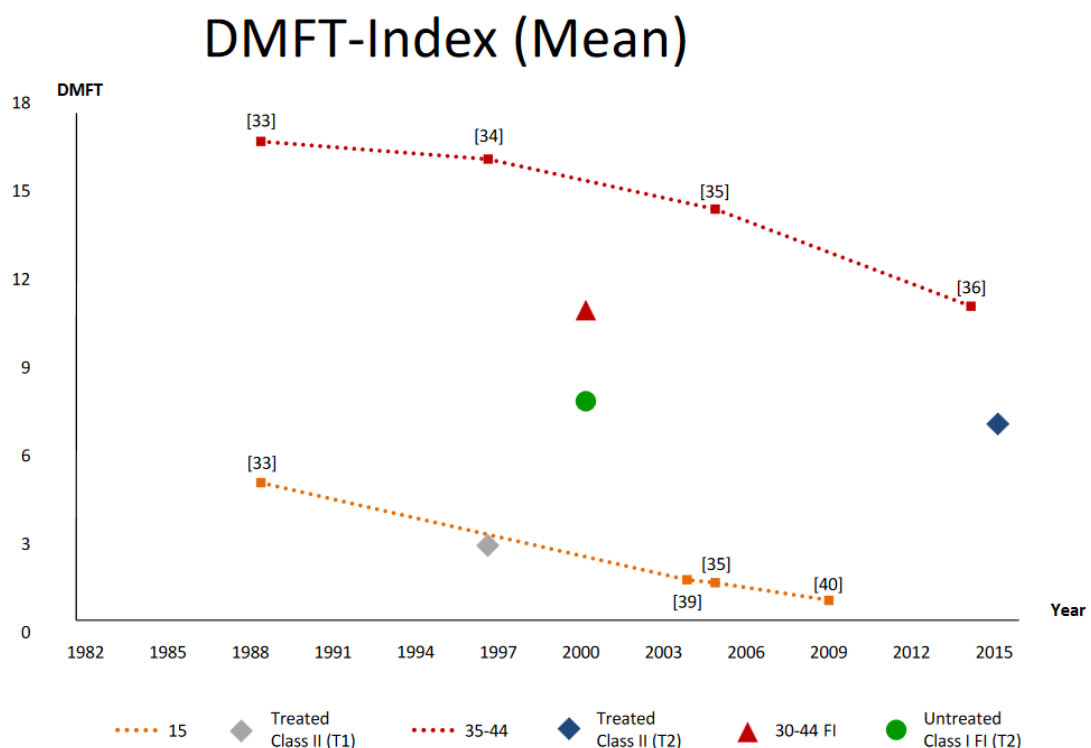


Figure 2. Chart exhibiting the development of the mean (D)MFT scores of the treated Class II participants at T1 and T2 as well as of the untreated Class I controls at T2; the data in the figure are allocated to the respective years of investigation. In addition, population-representative data from Germany (two different age groups: 15 years and 35-44 years) are shown. The respective reference numbers are given. Reprinted from: “Bock NC, Saffar M, Hudel H, Evälahti M, Heikinheimo K, Rice DP, Ruf S. Long-term oral-health effects of Class II orthodontic treatment. J Orofac Orthop 2018;79(2):96-108” by permission of Springer Nature.

Table 5. General dental status: (D)MFT data of the treated Class II participants and the untreated Class I controls as well as comparative data from the literature. Reprinted from: “Bock NC, Saffar M, Hudel H, Evälahti M, Heikinheimo K, Rice DP, Ruf S. Long-term oral-health effects of Class II orthodontic treatment. J Orofac Orthop 2018;79(2):96-108” by permission of Springer Nature.

Table 5	Population	Year(s) of investigation	Type of evaluation	Location	N=	Mean age	Mean (D)MFT	(D)MFT=0
Current investigation	Treated Class II participants	1988-2000 (T1)	Radiographic	DE	68	15.4	3.1±3.8	34%
		2014-2015 (T2)	Clinical		72	33.7	7.1±4.9	7%
	Untreated Class I controls	1998-2002 (T2)	Radiographic	FI	28	32.9	7.9±3.6	4%

Publication	Year of publication	Year(s) of investigation	Type of evaluation	Location	N=	Age	(D)MFT	(D)MFT=0
DMS I ³³	1991	1989	Clinical	DE (West)	452	13-14	5.1	12%
					451	35-44	16.7	1%
DMS III ³⁴	1999	1997	Clinical	DE (West)	516	35-44	16.1±5.7	1%
DMS IV ³⁵	2006	2005	Clinical	DE (West)	1012	15	1.7±2.5	48%
					755	35-44	14.4±5.8	1%
DMS IV ³⁶	2016	2014	Clinical	DE (West)	814	35-44	11.1±5.6	3%
DAJ ^{39,40}	2005	2004	Clinical	DE	1987	15	1.8	46%
	2010	2009		(Hessen)	2656	15	1.1	62%
Splieth et al. ⁴⁵	2003	1997-2001	Clinical	DE	699	25-34	7.6	-
National Public Health Institute ⁴³	2008	2000	Clinical	FI	2148	30-44	11.3	-
National Institute for Health and Welfare ⁴²	2010	1985	Clinical	FI	>10000	15	6.2	-
					>10000	18	9.4	2%
		1994			>10000	15	2.8	-
					>10000	18	4.7	14%
		2000			>10000	15	2.6	-
					>10000	18	4.0	16%
2003	>10000	17	-	20%				
Ankkuri and Ainamo ³⁷	1997	1991	Clinical	FI	4057	20.3	7.3±5.1	7%
Peltola et al. ⁴⁴	2006	1982	Radiographic	FI	176	19.8	11.0±4.2	0%
		2002			231	20.2	2.9±3.2	28%
Kämppi et al. ⁴¹	2013	2011	Clinical	FI	13304	21-23	4.1±4.2	21%
Crocombe et al. ³⁸	2009	2004-2006	Clinical	AUS	5505	16-19	-	24%
						20-34	-	4%
						35-49	-	0%

DE: Germany
 FI: Finland
 AUS: Australia
 -: Data not available

Tx was performed due to a severe Class II malocclusion. During Tx, the PAR score was reduced from 23.9±9.2 (T0) to 3.2±2.0 (T1) points; minor changes had occurred until the recall investigation resulting in a PAR score of 7.5±5.1 (T2). The untreated Class I controls exhibited a PAR score of 8.7±3.7 at age 15 (T1) which remained stable (8.8±3.3) until age 33 (T2). So, the PAR score at T2 did not differ

($p=0.196$) between the treated Class II participants and the untreated Class I controls. More detailed data on the occlusal and alignment changes have been published separately [48, 49].

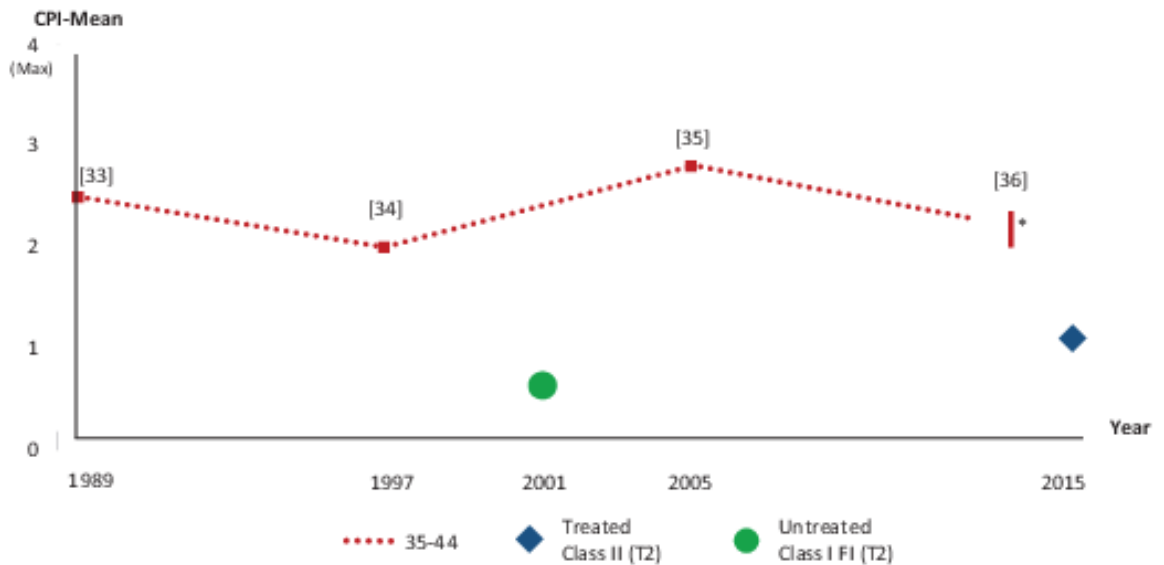
The general dental status (Table 5) showed an MFT score of 3.1 ± 3.8 directly after Tx (T1 – radiologic evaluation) for the treated Class II participants. Unfortunately, no respective data were available for the untreated Class I controls. At recall (T2 – clinical evaluation), the DMFT score was 7.1 ± 4.8 in the treated Class II participants, while the corresponding population-representative age-cohort (DMS V) [36] exhibited a 56% higher value (11.1). The untreated Class I controls showed an MFT score of 7.9 ± 3.6 (T2 – radiologic evaluation), while epidemiological age and year-corresponding control data [43] describe a value which is 43% higher (Figure 2).

Table 6. Gingival health: CPI and gingival recession data of the treated Class II participants and the untreated Class I controls as well as comparative data from the literature. Reprinted from: “Bock NC, Saffar M, Hudel H, Evälahti M, Heikinheimo K, Rice DP, Ruf S. Long-term oral-health effects of Class II orthodontic treatment. *J Orofac Orthop* 2018;79(2):96-108” by permission of Springer Nature.

Table 6	Population	Year(s) of investigation	Type of evaluation	Location	N=	Age	CPI				
							Maximum score				
							Mean	=0	=0,1,2	=3	=4
	Treated Class II participants	2014-2015 (T2)	Clinical	DE	72	33.7	1.6±0.6	4%	100%	0%	0%
	Untreated Class I controls	1998-2002 (T2)	Clinical	FI	31	32.9	1.7±0.9	16%	91%	6%	3%
Publication	Year of publication	Year(s) of investigation	Type of evaluation	Location	N=	Age	CPI				
							Maximum score				
							Mean	=0	=0,1,2	=3	=4
DMS I ³³	1991	1989	Clinical	DE (West)	451	35-44	2.5	6%	45%	40%	15%
DMS III ³⁴	1999	1997	Clinical	DE (West)	509	35-44	2.0	18%	62%	29%	9%
DMS IV ³⁵	2006	2005	Clinical	DE (West)	740	35-44	2.8±0.9	0%	28%	53%	19%
DMS V ³⁶	2016	2014	Clinical	DE (West)	806	35-44	1.9-2.3*	-	39%	51%	10%
DE: Germany											
FI: Finland											
* Exact value not known; best and worse possible value calculated											

In terms of periodontal health (Table 6, Figure 3a), the average CPI maximum scores at recall (T2) amounted to 1.6 ± 0.6 in the treated Class II participants and 1.7 ± 0.9 in the untreated Class I controls ($p=0.479$). The particular value of the respective corresponding population-representative age-cohort (DMS V) [36] is not available, but according to the published data of the CPI maximum scores it ranges between 1.9 (best possible scenario) and 2.3 (worst possible scenario). The previous volume of the epidemiologic evaluation (DMS IV) [35] describes a value of 2.8 ± 0.9 . Looking at the percentage of participants exhibiting a maximum score of 0, 1, or 2 (Figure 3b), this value was 100% for the treated Class II participants, 91% for the untreated Class I controls but only 39% for the corresponding population-representative age-cohort (DMS V) [36].

a) CPI-Index (Mean)



b) CPI-Index (Max 0,1,2)

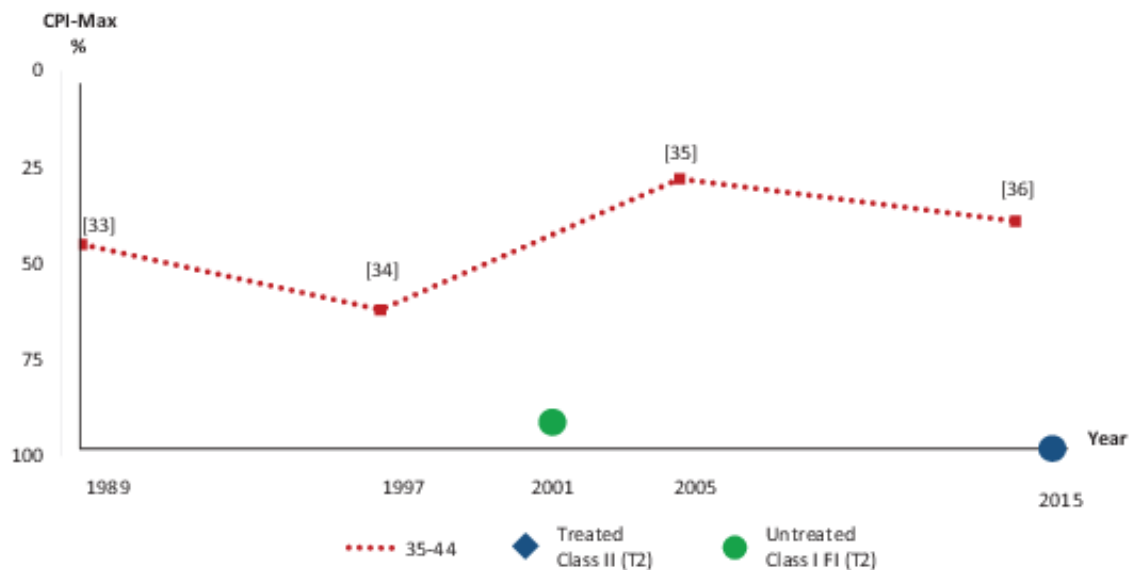
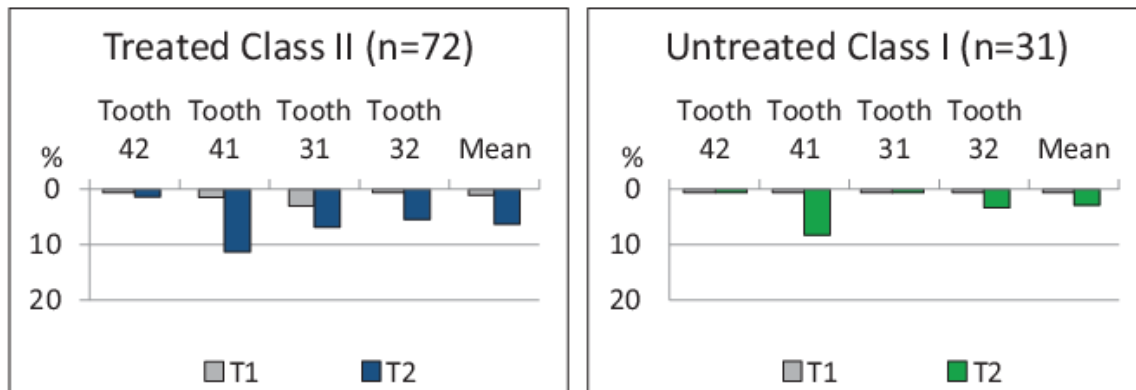


Figure 3. Chart exhibiting the CPI data (a: mean score, b: percentage exhibiting a maximum score of 0, 1 or 2) of the treated Class II participants and the untreated Class I controls at T2. The data in the figure are allocated to the respective years of investigation. In addition, population-representative data from Germany (age groups: 35-44 years) are shown; the respective reference numbers are given. *Exact value not known; best and worst possible value calculated. Reprinted from: "Bock NC, Saffar M, Hudel H, Evälahti M, Heikinheimo K, Rice DP, Ruf S. Long-term oral-health effects of Class II orthodontic treatment. *J Orofac Orthop* 2018;79(2):96-108" by permission of Springer Nature.

a) Prevalence of labial gingival recessions $\geq 0.5\text{mm}$ (%)



b) Magnitude of labial gingival recessions

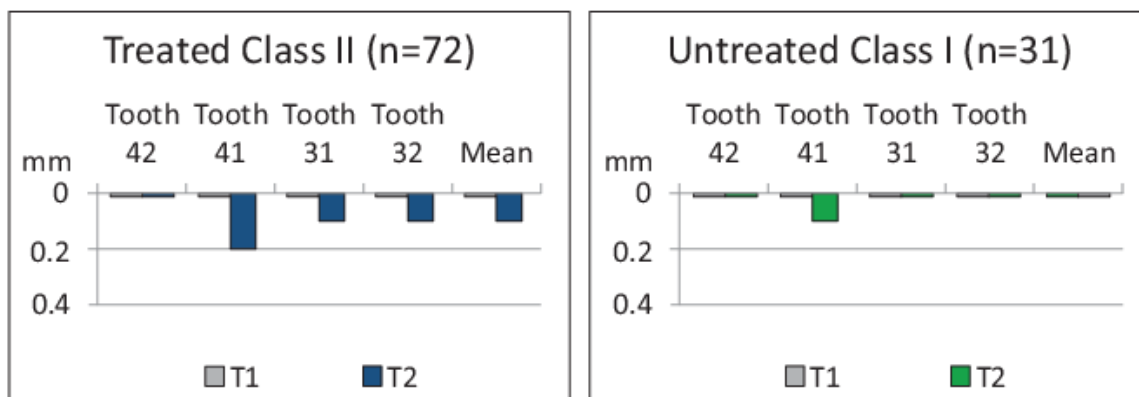
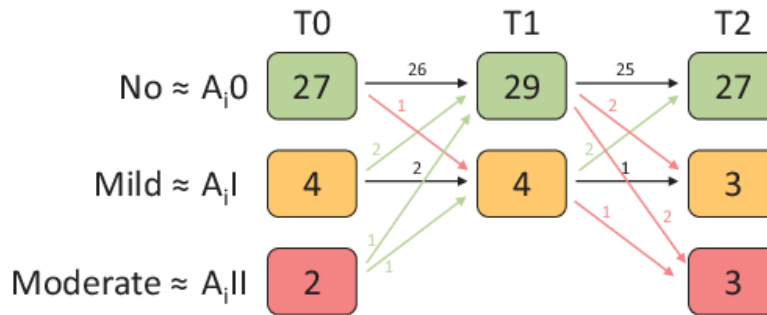
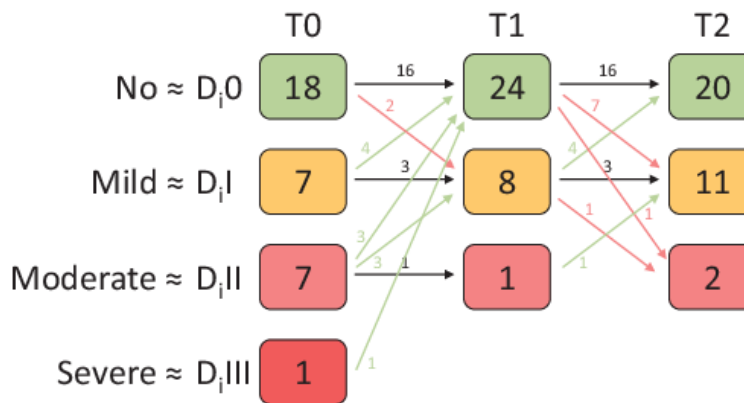


Figure 4. Diagram showing a) the prevalence for labial gingival recessions ≥ 0.5 mm and b) the magnitude of labial gingival recessions on the lower incisors. The individual values for each tooth (32-42) as well as the mean values are given.

a) Helkimo anamnestic index



b) Helkimo dysfunction index



c) DC/TMD

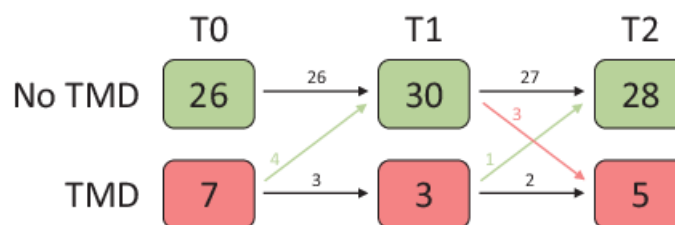


Figure 5. Longitudinal changes of TMD from before Tx (T0) to after Tx (T1) and > 15 years follow-up (T2) in 33 Herbst-MBA patients. The number of patients corresponding to the different categories of a) the Helkimo anamnestic dysfunction index (A_i), b) the Helkimo clinical dysfunction index (D_i) as well as c) the RDC/TMD and DC/TMD are given. The number of patients and their direction of change between the observation time-points is given above the arrows. Please note: None of the changes/differences between the time-points was statistically significant. Reprinted/modified from: "Ruf S, Bock NC. Long-term (≥ 15 years) effects of Class II treatment: A longitudinal and cross-sectional study on signs and symptoms of temporomandibular disorders. Eur J Orthod 2019;41(2):172-179".

Evaluating the study casts, the mean prevalence for gingival recessions (teeth 32/31/41/42) increased from 1.1% (T1) to 6.3% (T2) in the treated Class II participants and from 0.0% (T1) to 2.9% (T2) in the untreated Class I controls (Figure 4a). In addition, the average magnitude of gingival recessions (teeth 32/31/41/42) measured on the study models changed from 0.0±0.0 mm at T1 to 0.1±0.2 mm (treated Class II participants) respectively 0.0±0.1 mm (untreated Class I controls) at T2 (Figure 4b) revealing no group difference ($p=0.193$). Comparable population benchmark data are lacking.

TMD data (Figure 5)

The subgroup of 33 participants with TMD-data available from T0, T1 and T2 did not differ from the remaining 39 participants regarding the prevalence for positive anamnestic and dysfunctional Helkimo index scores as well as pathologic RDC/TMD and DC/TMD findings (Table 1); this was also true for age and gender distribution. Therefore, the subgroup was considered representative for the entire sample of 72 participants, and in the following only their results will be described in terms of TMD data.

At all occasions (T0, T1, T2), 82-88% of the 33 treated Class II participants were free of anamnestic TMD symptoms [Helkimo index A_i ; Figure 5a]. Mild anamnestic TMD symptoms were reported by 9-12% and severe symptoms (T0 and T2 only) by 6-9% of the participants. A fluctuation of anamnestic symptoms between all index categories was seen – with a trend towards improvement between T0 and T1 and towards recurrence between T1 and T2.

Clinical dysfunction [Helkimo index D_i ; Figure 5b] was seen in 55-73% of the treated Class II participants, with the highest percentage of dysfunction-free participants occurring after Tx (73%). Mild dysfunction was detected in 21-33% and moderate dysfunction in 3-21% of the participants. Severe dysfunction was only seen in one patient (3%) and exclusively before Tx. Again, a fluctuation of signs between all index categories was seen with a trend towards improvement between T0 and T1 and for recurrence between T1 and T2.

The TMD prevalence according to RDC/TMD and DC/TMD (Figure 5c) also shows 79-91% of the treated Class II participants to be free of TMD at all occasions (T0-T2). The TMD prevalence changed from 21% (T0) over 9% (T1) to 15% (T2). The specific TMD diagnoses according to RDC/TMD and DC/TMD are given in Table 7. They underline the abovementioned trend towards milder dysfunction with age.

Looking for gender differences, two trends occurred. On the one hand, males showed a more pronounced decrease in prevalence between T0 and T1 compared to females (A_i and D_i as well as RDC/TMD and DC/TMD); on the other hand, the trend for recurrence/increase between T1 and T2 was less pronounced for males (D_i as well as RDC/TMD and DC/TMD). None of the group differences, however, was statistically significant ($p<0.05$).

would not depict the natural aging process of the human dentition [31, 50]. The untreated Class I sample was generated at a different site in Europe but was also of Caucasian descent. Further data for comparison were obtained from population-representative cross-sectional studies especially from the German Oral Health Studies (DMS I, III, IV, V) [33-36].

In terms of TMD, the subgroup comprised of 33 subjects was representative for the entire sample but still rather small when compared to other non-selected longitudinal studies on TMD [9, 10].

When it comes to methodology, the lack of fully comparable OH data must be considered as a limitation. For example, clinical DMFT data were used for the treated Class II participants at T2, while the respective T1 data had to be obtained from radiographs as it was also the case for the T2 data of the untreated Class I controls. Thus, the respective score (MFT) might be slightly underrated. Furthermore, it might be criticized that only the lower anterior teeth 32-42 were considered in terms of gingival recessions. However, according to the literature, gingival recessions are no relevant issue after Herbst-MBA Tx on any other teeth than lower incisors [20, 51].

The analysis of TMD was performed according to both the Helkimo index [26] as well as RDC/TMD respectively DC/TMD [27, 28]. While no specific TMJ information could be obtained from the Helkimo index, it allows a wider comparison with literature. While the DC/TMD criteria have been shown to be reliable, they have also been criticized [52, 53]. In addition, the time interval of ≤ 15 years between the two clinical assessments in the present study, might have led to some evolvement regarding the investigator's evaluation of TMD signs and symptoms, despite the basically high reliability of RDC/TMD and DC/TMD. In addition, it would have been favorable if some imaging modalities were available to underline and possibly complement the clinical diagnosis.

Looking at OH and especially the (D)MFT, both the treated Class II participants and the untreated Class I controls showed similar values at T2. For both groups, the corresponding population-representative age-cohorts exhibited distinctly higher values (by 43-56%). At T1, the treated Class II participants had been "fully normal" when compared to the values of the corresponding population-representative age-cohort at age 15 (Figure 2). So, what is the rationale of this effect? According to the literature, no significant relationship exists between the incidence/prevalence of caries and the alignment of teeth or malocclusion [1, 54, 55]. Therefore, when looking at the treated Class II and the untreated Class I samples of the present investigation, the length of the follow up may have been a factor. Both samples experienced frequent visits and/or Tx by the dental/orthodontic professionals during a rather long period while growing up; they were repeatedly motivated and reminded to maintain good oral hygiene and health. This might have led to improved OH literacy and an appreciation of the value of good oral hygiene, which is in concordance with the literature. Orthodontically treated children have been shown to have lower plaque scores and caries [56-58]. The alignment of the teeth also seems to have a positive psychological effect, motivating the patients and resulting in greater dental awareness [59].

The explanation might be similar regarding the effects on periodontal health: both the treated Class II participants and the untreated Class I controls showed similar and distinctly better CPI values than the German corresponding population-representative age-cohort (unfortunately no data available from Finland). Looking at the literature no significant difference for any periodontal variable was determined when comparing the periodontal status at least 10 years after orthodontic Tx to untreated controls [19]. Another long-term study revealed comparable results but determined a greater prevalence of mild to moderate periodontal disease in the maxillary posterior and mandibular anterior regions in the orthodontically treated group [21]. When looking at the magnitude of lower incisors' gingival recessions, the treated Class II participants exhibited a slightly larger value which might be due to the orthodontic Tx including lower incisor proclination. Alveolar bone loss on the buccal surface of the lower incisors after Herbst Tx was seen in a 3D radiographic investigation but

determined to be without any clinical significance due to the amount of ≤ 0.2 mm [60]. Another long-term (32 years) investigation after Herbst Tx only revealed the development of single gingival recessions which were attributed to other factors like mechanical trauma from tooth brushing or gingival features rather than tooth inclination changes related to orthodontic Tx [61, 62].

Regarding TMD, the prevalence (RDC/TMD and DC/TMD) decreased from 21% at \sim age 13 years over 9% at \sim age 15.5 years to 15% at \sim age 33 years. Using the D_i component of the Helkimo index, a similar trend towards milder symptoms of dysfunction was seen. Similar trends - showing that Tx of severe malocclusions decreases signs and symptoms of TMD from before to 3 years after Tx - have been described before [63, 64] and are in concordance with the literature [9, 10].

In the literature, however, no other publication reports the long-term (>3 years) TMD development exclusively in Class II patients. Other long-term reports analyzed either orthodontically treated samples with a full range of malocclusion, a mixed sample of orthodontically and non-orthodontically treated subjects or a national cohort [9, 65-67]. The TMD prevalence at the age of \sim 30 years ranged from 9.9-45% and was therefore higher than in the present sample of Class II patients after Herbst-MBA Tx and at the age \sim 33 years.

Overall, the results of the present investigation revealed no significant TMD changes during Class II Herbst-MBA Tx and long-term follow-up (Helkimo as well as RDC/TMD and DC/TMD). An unforeseeable fluctuation of signs and symptoms over time was observed. The present results support the currently accepted reality that orthodontic Tx neither decreases nor increases the risk for developing TMD later in life and emphasizes that in general occlusion/malocclusion only accounts for a very limited [8, 68, 69] percentage of the variability in TMD signs and symptoms.

CONCLUSIONS

Orthodontically treated Class II patients have a similar risk for oral health impairment in terms of tooth decay and periodontal disease as untreated Class I controls without orthodontic Tx need during adolescence, while a higher risk exists in the general population. In addition, Class II Herbst-MBA Tx neither decreases nor increases the risk for temporomandibular disorder development in later life.

REFERENCES

1. Hafez HS, Shaarawy SM, Al-Sakiti AA, Mostafa YA. Dental crowding as a caries risk factor: A systematic review. *Am J Orthod Dentofacial Orthop* 2012;142(4):443-450.
2. Bollen AM, Cunha-Cruz J, Bakko DW, Huang GJ, Hujoel PP. The effects of orthodontic therapy on periodontal health. *J Am Dent Assoc* 2008;139(4):413-422.
3. Al-Saleh MAQ, Alsufyani N, Flores-Mir C, Nebbe B, Major PW. Changes in Temporomandibular Joint Morphology in Class II Patients Treated with Fixed Mandibular Repositioning and Evaluated Through 3D Imaging. A Systematic Review. *Orthod Craniofac Res* 2015;18(4):185-201.
4. Luther F. Orthodontics and the temporomandibular joint: where are we now? Part 1. Orthodontic treatment and temporomandibular disorders. *Angle Orthod* 1998;68(4):295-304.
5. Bollen AM. Effects of Malocclusions and Orthodontics on Periodontal Health: Evidence from a Systematic Review. *J Dent Educ* 2008;72(8):912-918.
6. Stenvik A, Espeland L, Berg RE. A 57-year follow-up of occlusal changes, oral health, and attitudes toward teeth. *Am J Orthod Dentofacial Orthop* 2011;139(Suppl 4):102-108.
7. Thomson WM. Orthodontic Treatment Outcomes in the Long-Term: Findings from a Longitudinal Study of New Zealanders. *Angle Orthod* 2002;72(5):449-455.

8. Leite RA, Rodrigues JF, Sakima MT, Sakima T. Relationship between temporomandibular disorders and orthodontic treatment: a literature review. *Dental Press J Orthod* 2013;18(1):150-157.
9. Magnusson T, Egermark I, Carlsson GE. A prospective investigation over two decades on signs and symptoms of temporomandibular disorders and associated variables. A final summary. *Acta Odontol Scand* 2005;63(2):99-109.
10. Mohlin BO, Derweduwen K, Pilley R, Kingdon A, Shaw WC, Kenealy P. Malocclusion and temporomandibular disorder: a comparison of adolescents with moderate to severe dysfunction with those without signs and symptoms of temporomandibular disorder and their further development to 30 years of age. *Angle Orthod* 2004;74(3):319-327.
11. D'Antò V, Bucci R, Franchi L, Rongo R, Michelotti A, Martina R. Class II functional orthopaedic treatment: a systematic review of systematic reviews. *J Oral Rehabil* 2015;42(8):624-642.
12. Ehsani S, Nebbe B, Normando D, Lagravere MO, Flores-Mir C. Short-term treatment effects produced by the Twin-block appliance: a systematic review and meta-analysis. *Eur J Orthod* 2015;37(2):170-176.
13. Janson G, Sathler R, Fernandes TM, Branco NC, Freitas MR. Correction of Class II malocclusion with Class II elastics: a systematic review. *Am J Orthod Dentofacial Orthop* 2013;143(3):383-392.
14. Koretsi V, Zymperdikas VF, Papageorgiou SN, Papadopoulos MA. Treatment effects of removable functional appliances in patients with Class II malocclusion: a systematic review and meta-analysis. *Eur J Orthod* 2015;37(4):418-434.
15. Millett DT, Cunningham SJ, O'Brien KD, Benson PE, de Oliveira CM. Treatment and stability of class II division 2 malocclusion in children and adolescents: a systematic review. *Am J Orthod Dentofacial Orthop* 2012;142(2):159-169.
16. Pacha MM, Fleming PS, Johal A. A comparison of the efficacy of fixed versus removable functional appliances in children with Class II malocclusion: A systematic review. *Eur J Orthod* 2016;38(6):621-630.
17. Yang X, Zhu Y, Long H, Zhou Y, Jian F, Ye N, Gao M, Lai W. The effectiveness of the Herbst appliance for patients with Class II malocclusion: a meta-analysis. *Eur J Orthod* 2016;38(3):324-333.
18. Zymperdikas VF, Koretsi V, Papageorgiou SN, Papadopoulos MA. Treatment effects of fixed functional appliances in patients with Class II malocclusion: a systematic review and meta-analysis. *Eur J Orthod* 2016;38(2):113-126.
19. Polson AM, Subtelny JD, Meitner SW, Polson AP, Sommers EW, Iker HP, Reed BE. Long-term periodontal status after orthodontic treatment. *Am J Orthod Dentofacial Orthop* 1988;93(1):51-58.
20. Ruf S, Hansen K, Pancherz H. Does orthodontic proclination of lower incisors in children and adolescents cause gingival recession? *Am J Orthod Dentofacial Orthop* 1998;114(1):100-106.
21. Sadowsky C, BeGole EA. Long-term effects of orthodontic treatment on periodontal health. *Am J Orthod* 1981;80(2):156-172.
22. Richmond S, Shaw W.C, Roberts CT, Andrews M. The PAR Index (Peer Assessment Rating): methods to determine outcome of orthodontic treatment in terms of improvement and standards. *Eur J Orthod* 1992;14(3):180-187.
23. Klein H, Palmer CE, Knutson JW. Studies on Dental Caries: I. Dental Status and Dental Needs of Elementary Schoolchildren. *Public Health Rep* 1938;53.
24. Landry RG, Jean M. Periodontal Screening and Recording (PSR) Index: precursors, utility and limitations in a clinical setting. *Int Dent J* 2002;52(1):35-40.
25. Meyle J, Jepsen S. Der parodontale Screening-Index (PSI). *dgp-news* 2000; Sonderausgabe: 8-10.
26. Helkimo M. Studies on function and dysfunction of the masticatory system. II. Index for anamnestic and clinical dysfunction and occlusal state. *Sven Tandlakar Tidskr* 1974;67(2):101-121.
27. Dworkin SF, LeResche L. Research diagnostic criteria for temporomandibular disorders: review criteria, examinations and specifications, critique. *J Craniomandib Disord* 1992;6(4):301-355.

28. Schiffman E et al. Diagnostic Criteria for Temporomandibular Disorders (DC/TMD) for Clinical and Research Applications: recommendations of the International RDC/TMD Consortium Network and Orofacial Pain Special Interest Group. *J Oral Facial Pain Headache* 2014;28(1):6-27.
29. Ruf S, Pancherz H. Long-term TMJ effects of Herbst treatment: a clinical and MRI study. *Am J Orthod Dentofacial Orthop* 1998;114(5):475-483.
30. Ruf S, Pancherz H. Does bite-jumping damage the TMJ? A prospective longitudinal clinical and MRI study of Herbst patients. *Angle Orthod* 2000;70(3):183-199.
31. Heikinheimo K, Nyström M, Heikinheimo T, Pirttiniemi P, Pirinen S. Dental arch width, overbite and overjet in a Finnish population with normal occlusion between the ages of 7 and 32 years. *Eur J Orthod* 2012;34(4):418-426.
32. Ainamo J, Barmes D, Beagrie G, Cutress T, Martin J, Sardo-Infirri J. Development of the World Health Organization (WHO) Community Periodontal Index of Treatment Needs (CPITN). *Int Dent J* 1982;32(3):281-291.
33. Bauch J, Dunninger P, Eder-Debye R, Einwag J, Hoeltz J, Keb K, et al. Mundgesundheitszustand und –verhalten in der Bundesrepublik Deutschland. *Deutscher Zahnärzte Verlag DÄV*. Bucher 1991; 11(1): 426.
34. Heinrich R, John M, Lenz E, Michaelis W, Potthoff P, Reich E, et al. Dritte Deutsche Mundgesundheitsstudie (DMS III). *Deutscher Zahnärzte Verlag DÄV*. Bucher 1999;20:530.
35. Hoffman T, John M, Kerschbaum T, Michaelis W, Potthoff P, Reich E, et al. Vierte Deutsche Mundgesundheitsstudie (DMS IV). *Deutscher Zahnärzte Verlag DÄV*. Bucher 2006;31:502.
36. Cholmakow-Bodechtel C, Fubl-Grunig E, Geyer S, Hertrampf K, Hoffmann T, Holtfreter B, et al. Fünfte Deutsche Mundgesundheitsstudie (DMS V). *Deutscher Zahnärzte Verlag DÄV*. Bucher 2016;35:617.
37. Ankkuriniemi O, Ainamo J. Dental health and dental treatment needs among recruits of the Finnish Defence Forces, 1919-91. *Acta Odontol Scand* 1997;55(3):192-197.
38. Crocombe LA, Mejia GC, Koster CR, Slade GD. Comparison of adult oral health in Australia, the USA, Germany and the UK. *Aust Dent J* 2009;54(2):147-153.
39. Piper K. Epidemiologische Begleituntersuchungen zur Gruppenprophylaxe 2004. *Deutsche Arbeitsgemeinschaft für Jugendzahnpflege* 2005.
40. Epidemiologische Begleituntersuchungen zur Gruppenprophylaxe 2004. *Deutsche Arbeitsgemeinschaft für Jugendzahnpflege* 2010.
41. Kämppi A, Tanner T, Pääkkilä J, Patinen P, Järvelin MR, Tjäderhane L, et al. Geographical Distribution of Dental Caries Prevalence and Associated Factors in Young Adults in Finland. *Caries Res* 2013;47(4):346-354.
42. National Institute for Health and Welfare. A Nordic Project of Quality Indicators for Oral Health Care. Report 32/2010, Helsinki, Finland; 2010.
43. National Public Health Institute. Oral Health in the Finnish Adult Population. Publications of the National Public Health Institute B25/2008, Helsinki, Finland; 2008.
44. Peltola JS, Ventä I, Haahtela S, Lakoma A, Ylipaavaniemi P, Turtola L. Dental and oral radiographic findings in first-year university students in 1982 and 2002 in Helsinki, Finland. *Acta Odontol Scand* 2006;64(1):42-46.
45. Splieth C, Schwahn C, Bernhardt O, Kocher T, Born G, John U, et al. Caries Prevalence in an Adult Population: results of the Study of Health in Pomerania, Germany (SHIP). *Oral Health Prev Dent* 2003;1(2):149-155.
46. Bock NC, Saffar M, Hudel H, Evälahti M, Heikinheimo K, Rice DP, et al. Long-term oral-health effects of Class II orthodontic treatment. *J Orofac Orthop* 2018c;79(2):96-108.
47. Ruf S, Bock NC. Long-term (≥ 15 years) effects of Class II treatment: A longitudinal and cross-sectional study on signs and symptoms of temporomandibular disorders. *Eur J Orthod* 2019;41(2):172-179.
48. Bock NC, Saffar M, Hudel H, Evälahti M, Heikinheimo K, Rice DPC, et al. Herbst-multibracket appliance therapy of Class II:1 malocclusions – Long-term stability and outcome quality after ≥ 15 years in comparison to untreated controls. *Eur J Orthod* 2018a;40(2):206-213.

49. Bock NC, Saffar M, Hudel H, Evälahti M, Heikinheimo K, Rice DP, et al. Outcome quality and long-term (≥ 15 years) stability after Class II2 Herbst-multibracket appliance treatment in comparison to untreated Class I controls. *Eur J Orthod* 2018b;40(5):488-495.
50. Henrikson J, Persson M, Thilander B. Long-term stability of dental arch form in normal occlusion from 13 to 31 years of age. *Eur J Orthod* 2001;23(1):51-61.
51. Bock NC, Rühl J, Ruf S. Prevalence, magnitude, and incidence of labial gingival recession with Herbst-multibracket appliance treatment. A retrospective cohort study. *Angle Orthod* 2019;89(4):535-543.
52. Leskinen J, Suvinen T, Teerijoki-Oksa T, Kemppainen P, Näpänkangas R, Alstergren P, et al. Diagnostic criteria for temporomandibular disorders (DC/TMD): interexaminer reliability of the Finnish version of Axis I clinical diagnoses. *J Oral Rehabil* 2017;44(7):493-499.
53. Steenks MH, Türp JC, de Wijer A. Reliability and Validity of the Diagnostic Criteria for Temporomandibular Disorders Axis I in Clinical and Research Settings: A Critical Appraisal. *J Oral Facial Pain Headache* 2018;32(1):7-18.
54. Addy M, Griffiths GS, Dummer PMH, Kingdon A, Hicks R, Hunter ML, et al. The association between tooth irregularity and plaque accumulation, gingivitis, and caries in 11-12-year-old children. *Eur J Orthod* 1988;10(1):76-83.
55. Helm S, Petersen PE. Causal relation between malocclusion and caries. *Acta Odontol Scand* 1989;47(4):217-221.
56. Feliu JL. Long-term benefits of orthodontic treatment on oral hygiene. *Am J Orthod* 1982;82(6):473-477.
57. Davies TM, Shaw WC, Worthington HV, Addy M, Dummer P, Kingdon A. The effect of orthodontic treatment on plaque and gingivitis. *Am J Orthod Dentofacial Orthop* 1991;99(2):155-161.
58. Chen W, Zhou Y. Caries outcomes after orthodontic treatment with fixed appliances: a longitudinal prospective study. *Int J Clin Exp Med* 2015;8(2):2815-2822.
59. Glans R, Larsson E, Øgaard B. Longitudinal changes in gingival condition in crowded and noncrowded dentitions subjected to fixed orthodontic treatment. *Am J Orthod Dentofacial Orthop* 2003;124(6):679-682.
60. Schwartz JP, Raveli TB, Schwartz-Filho HO, Raveli DB. Changes in alveolar bone support induced by the Herbst appliance: a tomographic evaluation. *Dental Press J Orthod* 2016;21(2):95-101.
61. Pancherz H, Bjerklin K. Mandibular incisor inclination, tooth irregularity, and gingival recessions after Herbst therapy: a 32-year follow-up study. *Am J Orthod Dentofacial Orthop* 2014;146(3):310-318.
62. Loe H, Ånerud Å, Boysen H. The Natural History of Periodontal Disease in Man: Prevalence, Severity, and Extent of Gingival Recession. *J Periodontol* 1992;63(6):489-495.
63. Henrikson T, Nilner M, Kurol J. Symptoms and signs of temporomandibular disorders before, during and after orthodontic treatment. *Swed Dent J* 1999;23(5-6):193-207.
64. Abrahamsson C, Henrikson T, Nilner M, Sunzel B, Bondemark L, Ekberg EC. TMD before and after correction of dentofacial deformities by orthodontic and orthognathic treatment. *Int J Oral Maxillofac Surg* 2013;42(6):752-758.
65. Egermark I, Carlsson GE, Magnusson T. A prospective long-term study of signs and symptoms of temporomandibular disorders in patients who received orthodontic treatment in childhood. *Angle Orthod* 2005;75(4):645-650.
66. Macfarlane TV, Kenealy P, Kingdon HA, Mohlin BO, Pilley JR, Richmond S, et al. Twenty-year cohort study of health gain from orthodontic treatment: temporomandibular disorders. *Am J Orthod Dentofacial Orthop* 2009;135(6):692-693.
67. Rutkiewicz T, Könönen M, Suominen-Taipale L, Nordblad A, Alanen P. Occurrence of clinical signs of temporomandibular disorders in adult Finns. *J Orofac Pain* 2006;20(3):208-217.
68. Jiménez-Silva A, Carnevali-Arellano R, Venegas-Aguilera M, Tobar-Reyes J, Palomino-Montenegro H. Temporomandibular disorders in growing patients after treatment of class II and III malocclusion with orthopaedic appliances: a systematic review. *Acta Odontol Scand* 2018;76(4):262-273.

69. Špalj S, Šlaj M, Athanasiou AE, Žak I, Šimunović M, Šlaj M. Temporomandibular disorders and orthodontic treatment need in orthodontically untreated children and adolescents. Coll Anthropol 2015;39(1):151-158.

HOW TO GET BETTER AT TEMPORARY ANCHORAGE DEVICES (TADS) QUICKLY

Sebastian Baumgaertel

ABSTRACT

Temporary anchorage devices (TADs) are now a normal part of everyday orthodontic practice in many offices nationwide. Achieving expertise at miniscrews, and with that the high success rates required for routine application, takes time and insertion of many miniscrews. This article explores if there is a shortcut for beginners to quickly achieve high success rates normally only seen with more experienced clinicians. Citing a recently conducted study, it appears as though focusing on certain sites with advantageous anatomy and high probability outcomes has the ability to allow even the most novice miniscrew user to achieve success rates over 80%.

KEY WORDS: Temporary Anchorage Devices; TADs; Miniscrews; Orthodontics

INTRODUCTION

Orthodontic miniscrews, or temporary anchorage devices (TADs), have become a staple of modern orthodontic practice [1] While the orthodontic benefits are undisputed, their permeation of clinical practice has been slower than expected. The initial excitement faded rather quickly due to lower than required success rates. This has improved over time, as critical factors for success have been identified. Amongst the patient related factors that have been repeatedly found to play a role are both micro- and macroanatomical factors, such as the dental roots, quality and quantity of bone and the soft tissue lining present at an implant site [2-7] Other factors that are considered important factors for TAD success such as insertion torque or facial pattern may simply be regarded as proxy measures for cortical bone thickness [8-11]. Operator factors impacting success that have been suggested in the past are side of insertion which was not corroborated in other studies and experience level of the clinician [12-15]. While violation of these factors may explain the majority of TAD failures, some failures remain without apparent cause. It has been found however that in some patients that have experienced a TAD failure (primary failure), the replacement TAD has a below average probability of survival [16]. In all likelihood there are some other unidentified factors at play, perhaps genetic in nature, that simply make a patient less suitable for successful placement of an orthodontic mini-implant.

It is clear at this point that complete success will remain an elusive ideal, but it should be the goal of the practicing orthodontist to come as close to this ideal as possible. The above discussion underlined that while some factors are beyond our control, it is very realistic to act upon those factors that have an impact. These factors have one common aspect that is the anatomy, and a cursory analysis of the human jaws will reveal that some areas offer a more favorable combination of anatomical factors than others. It would make sense therefore to select an implant site based on anatomical factors and make it a top priority when planning and placing temporary anchorage devices.

The way TAD use in North America is still taught today is predominately through commercial courses provided by orthodontic supply companies, rather than at universities [17]. This can be a problem because there are no standards and current evidence may not be followed or may be presented in a skewed way to follow certain interests. This can lead to less successful outcomes, but at the very least will lead to different ways that TADs are used in different practices, with some approaches perhaps more successful than others. It is interesting to explore why universities are struggling with the implementation of TADs as part of American orthodontic residents' specialty education.

Since the times of Brodie, North American universities have attempted to educate the brightest minds in dentistry to become orthodontic specialists. Orthodontic education at its core is less focused on the precise execution of clinical procedures when compared to general dental education, and more focused on problem solving through application of fundamental knowledge. It generally takes considerable time and effort to implement this change in thinking in a dentist undergoing orthodontic specialty education, but when this goal is successfully attained a capable orthodontic specialist is born.

This aforementioned change in thinking, while essential to successfully treating a wide range of malocclusions, is diametrically opposed to confidently inserting orthodontic miniscrews. While the latter should be considered minimally invasive, it is still an invasive procedure and TAD placement is certainly the execution of a procedure rather than the solving of a problem. The orthodontic treatment plan will influence where the screw is placed to optimize mechanics, but it is the local anatomy at the insertion site that will influence implant site preparation and ultimately the screw placement [3, 18]. Preparing an implant site for a proper insertion can range from small mucosal incisions or fenestrations and pre-drilling pilot holes to simple local anesthesia when only a transmucosal insertion is intended.¹⁸ Either way, the insertion of an orthodontic miniscrew resembles roughly the insertion of a dental implant and as such would fall more into the scope of oral surgery practice than into routine orthodontic practice. This, along with the humbling results many orthodontists experienced when they first attempted miniscrew use, may be a contributing factor to the observation that these little anchorage aids have not been adopted by all practicing orthodontists, despite their obvious utility [17]. It would also explain why miniscrews are widely used, but not systematically taught in many residency programs across North America. There currently aren't enough qualified instructors available to teach miniscrew use in every orthodontic residency program. An additional facet to the problem of teaching this topic in the academic setting is that it is still unclear who should assume this teaching responsibility: should procedure-oriented surgical instructors such as periodontists or oral surgeons teach the insertion of this very small implant, or should orthodontic instructors teach all aspects of miniscrew use, being the end user and in charge of not only planning the biomechanics, but also the location of the insertion site and modality of loading? At Case Western Reserve University in Cleveland, OH we have tried both and very quickly settled on the latter option as being superior. This opinion led to implementation of the first treatment clinic focused on skeletal anchorage cases in an orthodontic residency, over ten years ago.

The Skeletal Anchorage Subspecialty Clinic followed a very strict education and clinical implementation protocol, supervised by the author of this chapter:

- In their first semester, first year residents attended a five-hour course on the fundamentals of miniscrew use, covering topics such as miniscrew design, anatomical and physiological foundations for successful insertion of miniscrews, evidence-based loading protocols, biomechanics, and a discussion of treated cases.

-This course was followed by a multiple-choice exam that evaluated theoretical knowledge of the subject matter, and once passed, residents moved on to
-a tyodont course where residents learned the practical skills necessary to successfully insert miniscrews and load them. If the residents demonstrated adequate skills competency here, they were cleared for the use of miniscrews on patients.

When a resident and his/her core clinic instructor determined a patient had an elevated anchorage requirement the patient was presented to the Skeletal Anchorage Clinic instructor. In addition to the standard orthodontic workup, residents were required to undertake a 'TAD' – workup consisting of anatomical assessment of viable insertion sites using CBCT imaging, suggestion of suitable miniscrew-type and design of the appropriate biomechanics to achieve the desired treatment outcome. Once approved, the patient was scheduled for the insertion by the resident, under the supervision of the instructor.

The insertion followed a very clear protocol. In accordance to Baumgaertel and Tran insertions were done transmucosally in attached gingiva and limited mobility mucosa [19]. Only in highly mobile mucosa or in cases where pre-drilling was planned was a tissue punch performed. All miniscrews used were of self-drilling design, and unless cortical bone thickness exceeded 1.5 mm no pre-drilling procedure was performed. Areas of cortical bone thickness under 1.0 mm were avoided, and areas where it was under 0.5 mm were ruled out. Implant length was chosen with the goal to use the shortest possible miniscrew without compromising retention in the bone. This means that if gingival thickness was ≤ 2 mm then implant length was 6 mm, for between 2-4 mm of gingival thickness the implant length was 8 mm and in very thick gingiva >4 mm the implant length was 10 mm. However, areas with extremely thick gingiva were considered a last resort and generally also avoided. Biomechanics were applied immediately, without a preference for direct or indirect anchorage, allowing the treatment objective and location of the miniscrew to be the main determinants of the type of anchorage employed.

These were the circumstances under which miniscrews were used in the Skeletal Anchorage Clinic at Case Western Reserve University. It can be assumed with this kind of education and training that the residents' theoretical and practical knowledge met or exceeded that of the average private practice clinician in North America at the time (2006-2016). It should be clear though that this training did not create experts. It simply created well-educated beginners that used miniscrews in a defined and tightly controlled setting. Such a setting in a university department proved ideal for an outcome assessment study to evaluate how well beginners can expect to perform when first starting to use miniscrews, if properly trained.

MATERIALS AND METHODS

After Institutional Review Board approval patient charts from the orthodontic clinic at Case Western Reserve University from 2006-2016 were reviewed and all inserted miniscrews with complete documentation in the patient chart were included in the sample [20]. An analysis of 109 consecutively placed miniscrews in 60 patients, 27 males and 33 females with an average age of 18.5 years and a range of 13.3 years to 41.9 years was performed. A power analysis underscored that the sample was of sufficient size.

As explained above, all miniscrews were placed by well-trained residents under the supervision of the author of this paper in the orthodontic clinic at Case Western Reserve University. To further control

the parameters, all screws inserted were tomas® SD Pins (Dentaurum, Ispringen, Germany) in 6-, 8- and 10-mm length (Figure 1), depending on the requirements at the local insertion site, as outlined above.



Figure 1. tomas® Pin in 6mm (left), 8 mm (center), 10 mm (right) length.

For study purposes the insertions were grouped into four main areas that each had a different anatomical build:

- the anterior palate (AP), as defined by Baumgaertel et al. as the palatal area distal to the canines and mesial to the first molars, excluding the midpalatal suture region (Fig 2) [22],
- palatal alveolar process (PAP), as defined by Baumgaertel et al. as the palatal slope of the maxillary alveolar process distal to the maxillary canines and mesial to the maxillary second molars (Fig 2) [22],
- maxillary buccal alveolar process (MxB), defined as the buccal aspect of the maxillary alveolar process, distal to the maxillary canines and mesial to the second molar (Fig 3),
- mandibular alveolar process (MdB), defined as the buccal aspect of the mandibular alveolar process, distal to the mandibular canine and mesial to the second molar (Fig 3).

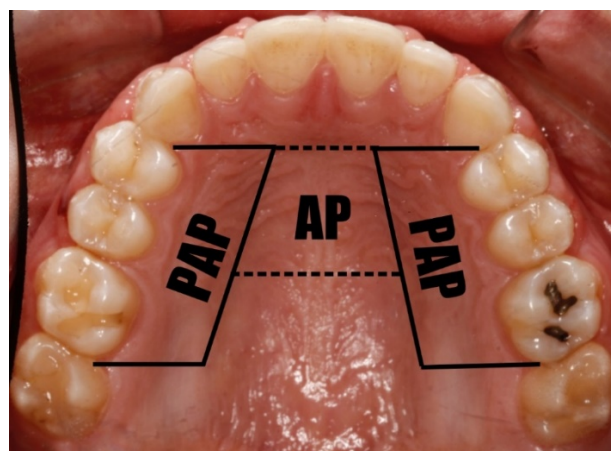


Figure 2. Palatal insertion sites. AP: anterior palate, PAP: posterior alveolar process.

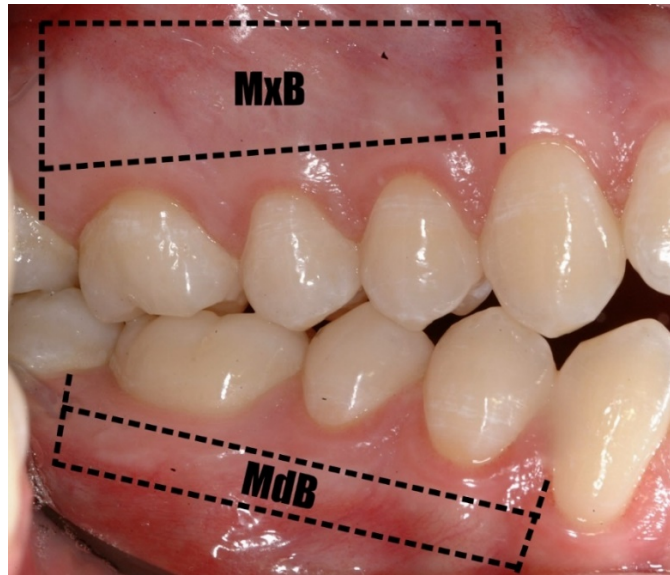

Figure 3. Buccal insertion sites. MxB: maxillary buccal alveolar process, MdB: mandibular buccal alveolar process.

Miniscrews were also grouped by anchorage type. Direct anchorage was defined as a direct force being applied between the miniscrew and the target tooth or group of teeth (Fig 4). Indirect anchorage was defined as stabilization of the traditional anchorage segment using a miniscrew and a connector, either a non-rigid steel ligature or a rigid stainless steel wire segment ligated into the universal cross slot of the tomas[®] Pin head (Fig 5).

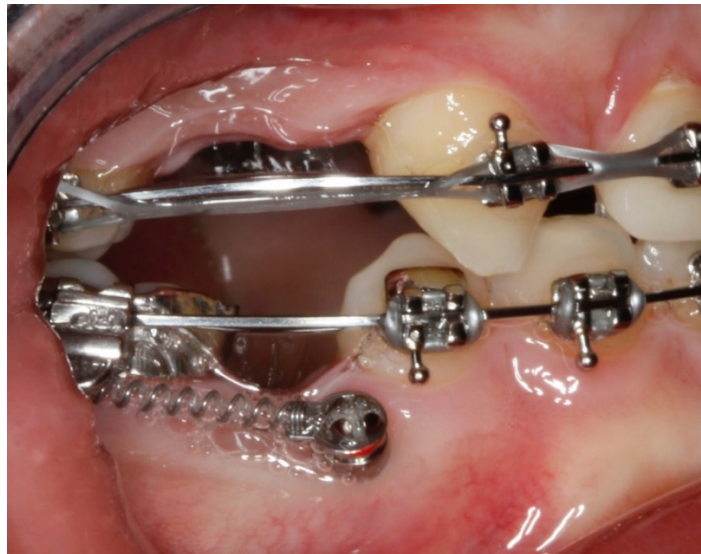


Figure 4. Direct anchorage biomechanics using tomas[®] Coil Spring for molar protraction.

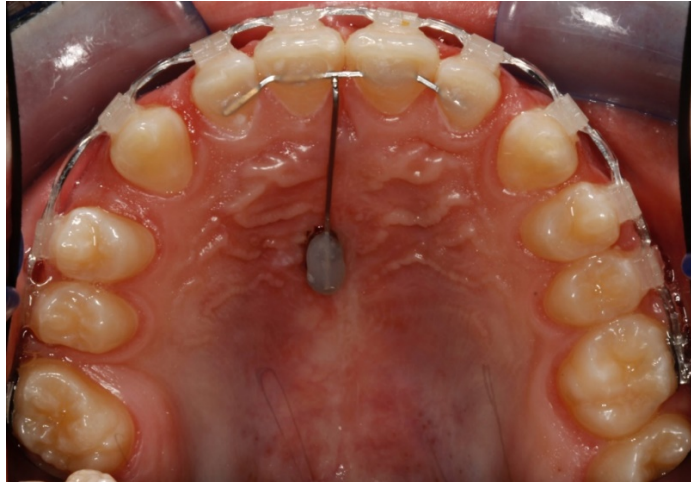


Figure 5. Indirect anchorage biomechanics using a tomas® T-Wire for protraction of posterior segments.

A miniscrew was considered a failure if it became loose before achievement of the treatment goal. Screw mobility was evaluated by visual inspection and manipulation at every appointment. Results were analyzed using a common statistics program (SPSS Version 17.0, SPSS, Chicago, IL) and the level for significance was set at a P value of 0.05. Analysis of variance (ANOVA) was used to determine impact of insertion sites and anchorage type on miniscrew failures. Tukey post hoc analysis was used to further evaluate interactions between different variables.

RESULTS

In the period from 2006 to 2016 residents achieved an overall success rate of 72.5%. Tables 1 and 2 explain the resulting success rates further.

Table 1. Success and failure rates by insertion site.

Insertion Site	n	Success	Failure	Success rate (%)	Sig
Anterior palate	31	26	5	83.9	***
Palatal alveolar process	25	19	6	76	***
Maxillary buccal alveolar process	15	9	6	60	***
Mandibular buccal alveolar process	38	25	13	65.8	***
Overall	109	79	30	72.5	***

Table 2. Success and failure rates by anchorage type.

Insertion site	Direct anchorage	Success	Failure	Success rate (%)	Indirect anchorage	Success	Failure	Success rate (%)	sig
Anterior palate	n/a	n/a	n/a	n/a	31	25	6	83.9	***
Palatal alveolar process	9	5	4	55.5	16	14	2	87.5	***
Maxillary buccal alveolar process	13	8	5	61.5	2	1	1	50%	***
Mandibular buccal alveolar process	29	17	12	58.6	9	8	1	88.8	***
Overall	51	30	21	58.8	58	48	10	82.8	***

Post hoc analysis revealed that there was a statistically significant difference between the palatal sites (both AP and PAP) and the buccal sites, but there was no difference when comparing the palatal sites to each other, or the buccal sites to each other. Indirect anchorage cases also had significantly higher success rate (82.8%) than direct anchorage cases (58.8%). However, all 31 miniscrews placed in the anterior palate, which has the highest success rates of all insertion sites, were used with indirect anchorage [23]. This may artificially inflate the success rate of indirect anchorage and so it would be erroneous to conclude that the results clearly suggest that indirect anchorage has a higher success rate. It can be stated though that at the very least, indirect anchorage is not inferior to direct anchorage.

DISCUSSION

The reported study aimed to investigate the success rates of orthodontic miniscrews when used by beginners with a well-rounded theoretical background. Most studies in the literature reporting success rates either do not mention the level of experience of the providers placing the miniscrews or studies published by well-known experts in the field with years of experience report findings less representative of the general population of orthodontic practitioners, and in particular beginners [24, 25].

It appears that only two published studies have made some indication of the experience level of the clinicians placing the TADs, while a third study allows some assumptions. Garfinkle et al. recruited patients from graduate and faculty practice at the University of Kentucky, assuming that at least some

miniscrews were placed by less experienced residents, but the breakdown between faculty and resident placing TADs was not reported and perhaps, all screw insertions were referred out to the surgical department [26]. The level of experience of the person inserting the screws was not mentioned. The success rate for immediately loaded miniscrews was found to be acceptable at 80.49%.

Kim et al. specifically investigated experience as one factor to potentially affect the success rates of palatal miniscrews and found that with every 18-month interval of miniscrew use, the success rates increased from an initial 75% to >95% after 36 months of miniscrew use [27]. However, it was not clear how many screws were inserted during each 18-month interval, and this should be an important factor to consider. Lastly, Lim et al. investigated the 1-week success rate of miniscrews placed by residents and found an excellent overall 7-day survival rate of 93.1%, however not all residents performed equally well: those with 20 or more insertions had a 3.6-fold higher success rate than their less experienced fellow residents [15].

Therefore, according to the current evidence it does appear that experience matters with regards to how successful one is at placing miniscrews. The residents in our study had neither 18 months of experience, nor had any of them placed more than 10 miniscrews. According to the previous studies, they fell into the category of inexperienced miniscrew users. It should therefore not come as a surprise that their success rates were acceptable, and consistent with many other reports in the literature, but certainly not exceptional, despite their training. In fact, it seems that sound theory cannot replace experience and clinical practice. While according to Kim et al.'s group, it takes time to become successful at placing miniscrews, and according to Lim's group it requires placement of a lot of miniscrews [27], an interesting question worth investigating is the potential for a shortcut, a way to accelerate the learning curve of inexperienced miniscrew users.

The answer to this question can be found in Table 1. While the overall success rate of our residents was 72.5% there were significant differences at different insertion sites. The anterior palate impressed with 83.9% and the posterior alveolar process still had a very good 76% success, while buccal insertions generally had a poor success rate of 60% in the maxilla and 65.8% in the mandible. Clearly, the insertion site plays a role in how successfully TADs are placed. The local anatomy at the palatal sites appears to be so favorable, that even beginners can achieve very good success here, while the buccal sites are so difficult to use that successful insertion requires greater experience. One shortcut would be therefore be to try to limit maxillary insertions to only palatal sites and develop alternative biomechanics with equivalent force systems to buccal biomechanics to achieve similar treatment effects. In the mandible that is not easily achieved. However, an alternative insertion site has been proposed by Chang et al [24]. Use of the buccal shelf (Fig 6) should yield success rates similar to those in the palate and allow an increase of success even for mandibular insertions.

It is recommended, based on our study, that beginners limit themselves to palatal insertion sites for maxillary insertions and buccal shelf insertions for mandibular insertions, where possible. Table 3 illustrates hypothetically what overall success rates could have been if residents focused more on the use of the most successful sites. This scenario assumes that 100% of indications requiring maxillary insertions can be treated with palatal miniscrews, with a simple 50/50 split between the AP and the PAP. Further, the ratios of direct vs. indirect anchorage were maintained in the maxilla, which means that all AP TADs used indirect anchorage, and PAP screws were loaded directly for 36% of them and indirectly for the remaining 64%.

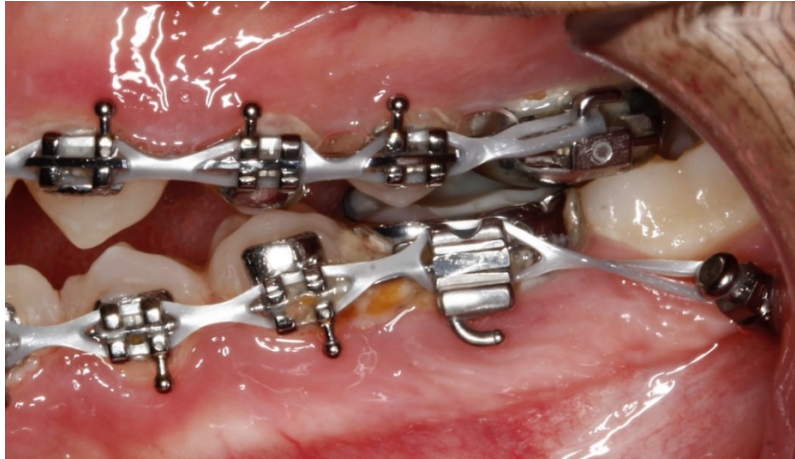


Figure 6. Buccal shelf TAD for retraction of lower arch in Class III patient.

Table 3. Assumed success and failure with exclusive use of 'Target Sites', and indirect anchorage where possible. *success rate for direct anchorage, **success rate for indirect anchorage.

Insertion Site	n	Success	Failure	Success rate (%)
Anterior palate	35	29	6	84
Palatal alveolar process	36	28	8	56*/88** total: 78
Maxillary buccal alveolar process	0	0	0	n/a
Mandibular buccal alveolar process	27	23	4	57*/89** total: 85
Mandibular Buccal shelf	11	10	1	93
Overall	109	90	19	83

In the mandible 30% of all indications requiring miniscrews were assumed to be treated with insertions at the buccal shelf (assuming the author's success rates in his private practice), but the ratio for direct and indirect anchorage was adjusted to reflect a more realistic scenario. Because in the author's practice the main indication for TADs in the mandible is molar protraction, which is generally done indirectly, an assumption is made that 90% of mandibular buccal TADs were loaded using indirect anchorage. Direct use of buccal mandibular TADs has become increasingly rare, as those insertions were migrated to the buccal shelf site. The overall success rate would have been 83%, which is a 10% improvement over the residents' average success rate simply by using only the anatomically very best insertion sites, the so-called 'Target

Sites'. This may not seem like a lot, but a closer examination of the success rates at the different sites shows that this effect was particularly pronounced in the mandible, where failures went from 13 to 5, which is a 62% reduction in failures. This approach finally renders mandibular TAD insertions reliable and allows their use with confidence.

CONCLUSIONS

Inexperienced orthodontists can achieve adequate success rates with miniscrews, given proper theoretical instruction. However, clinical experience seems to play an important role at achieving above average success rates.

This study has demonstrated that in addition to experience, in the hands of beginners both the insertion site and the type of biomechanics applied have an impact on the success rates. This fact can be leveraged by all TAD users, but particularly beginners should focus on selectively using only the most superior insertion sites which are all but guaranteed to produce stable, successful TADs and ideally combine them with indirect anchorage biomechanics for the best outcomes. This may represent a shortcut to achieve clinical success rates otherwise only found with very experienced users. This paper highlighted a realistic, but hypothetical clinical scenario in which only the very best insertion sites were used with mostly indirect anchorage where possible. This selective approach yielded highly successful outcomes, improving success rates by 10.5% from an average of 72.5% to 83%. However, at individual sites this approach led to an improvement of up to 19%.

REFERENCES

1. Markic G, Katsaros C, Pandis N, Eliades T. Temporary anchorage device usage: a survey among Swiss orthodontists. *Prog Orthod*. 2014;15(1):29.
2. Baumgaertel S. Planning and placing temporary anchorage devices (TADs) with the aid of CBCT imaging. *Cone Beam Computed Tomography in Orthodontics: Indications, Insights, and Innovations* Hoboken: Wiley-Blackwell 2014; 411-426.
3. Baumgaertel S. Pre-drilling of the implant site – is it necessary for orthodontic mini-implants? *Am J Orthod Dentofacial Orthop* 2010;137(6):825-829.
4. Asscherickx K, Vande Vannet B, Wehrbein H, Sabzevar MM. Success rate of miniscrews relative to their position to adjacent roots. *Eur J Orthod*. 2008;30(4):330-335.
5. Kuroda S, Yamada K, Deguchi T, Hashimoto T, Kyung HM, Takano-Yamamoto T. Root proximity is a major factor for screw failure in orthodontic anchorage. *Am J Orthod Dentofacial Orthop*. 2007;131 (Suppl 4):68-73.
6. Chen YH, Chang HH, Chen YJ, Lee D, Chiang HH, Yao CC. Root contact during insertion of miniscrews for orthodontic anchorage increases the failure rate: an animal study. *Clin Oral Implants Res*. 2008;19(1):99-106.
7. Viwattanatipa N, Thanakitcharu S, Uttraravichien A, Pitiphat W. Survival analyses of surgical miniscrews as orthodontic anchorage. *Am J Orthod Dentofacial Orthop*. 2009;136(1):29-36.
8. Motoyoshi M, Hirabashi M, Uemura M, Shimizu N. Recommended placement torque when tightening an orthodontic mini-implant. *Clin Oral Implants Res*. 2006;17(1):109-114.
9. Jing Z, Wu Y, Jiang W, Zhao L, Jing D, Zhang N, et al. Factors Affecting the Clinical Success Rate of Miniscrew Implants for Orthodontic Treatment. *Int J Oral Maxillofac Implants*. 2016;31(4):835-841.

10. Motoyoshi M, Yoshida T, Ono A, Shimizu N. Effect of cortical bone thickness and implant placement torque on stability of orthodontic mini-implants. *Int J Oral Maxillofac Implants.* 2007;22(5):779-784.
11. Wilmes B, Rademacher C, Olthoff G, Drescher D. Parameters affecting primary stability of orthodontic mini-implants. *J Orofac Orthop.* 2006;67(3):162-174.
12. Park HS, Jeong SH, Kwon OW. Factors affecting the clinical success of screw implants used as orthodontic anchorage. *Am J Orthod Dentofacial Orthop* 2006;130:18-25.
13. Moon CH, Lee DG, Lee HS, Im JS, Baek SH. Factors associated with the success rate of orthodontic miniscrews placed in the upper and lower posterior buccal region. *Angle Orthod.* 2008;78(1):101-106.
14. Maino G, Pagin P, Di Blasio A. Success of miniscrews used as anchorage for orthodontic treatment: analysis of different factors. *Prog Orthod.* 2012;13(3):202-209.
15. Lim HJ, Choi YJ, Evans CA, Hwang HS. Predictors of initial stability of orthodontic miniscrew implants. *Eur J Orthod.* 2011;33(5):528-532.
16. Uesugi S, Kokai S, Kanno Z, Ono T. Prognosis of primary and secondary insertions of orthodontic miniscrews: What we have learned from 500 implants. *Am J Orthod Dentofacial Orthop.* 2017;152(2):224-231.
17. Keim RG, Gottlieb EL, Vogels DS 3rd, Vogels PB. 2014_JCO_Study_of Orthodontic Diagnosis and Treatment Procedures, Part 1: Results and Trends. *J Clin Orthod.* 2014;48(10):607-630.
18. Baumgaertel S. Orthodontic implantology: A Revolutionary Approach to High-Anchorage Orthodontics. *Gen Dent.* 2009; 57(2):410-414.
19. Baumgaertel S, Tran TT. Mini-implant site selection – the mucosal fallacy. *J Clin Orthod.* 2012;46(7):434-436.
20. Baumgaertel S, Palomo JM, Zaverdinos M, Elshebiny T. Ten years of miniscrew use in a US orthodontic residency program. *Am J Orthod Dentofacial Orthop.* 2020;158(6):834-839.
21. Baumgaertel S. Quantitative investigation of palatal bone depth and cortical bone thickness for mini-implant insertion in adults. *Am J Orthod Dentofacial Orthop.* 2009; 136(1):104-108.
22. Baumgaertel S. Cortical bone thickness and bone depth of the posterior palatal alveolar process for mini-implant insertion in adults. *Am J Orthod Dentofacial Orthop.* 2011;140(6):806-811.
23. Karagkiolidou A, Ludwig B, Pazera P, Gkantidis N, Pandis N, Katsaros C. Survival of palatal miniscrews used for orthodontic appliance anchorage: a retrospective cohort study. *Am J Orthod Dentofacial Orthop.* 2013;143(6):767-772.
24. Chang C, Liu SS, Roberts WE. Primary failure rate for 1680 extra-alveolar mandibular buccal shelf mini-screws placed in movable mucosa or attached gingiva. *Angle Orthod.* 2015;85(6):905-910.
25. Chang CH, Lin JS, Roberts WE. Failure rates for stainless steel versus titanium alloy infrazygomatic crest bone screws: A single-center, randomized double-blind clinical trial. *Angle Orthod.* 2019;89(1):40-46.
26. Garfinkle JS, Cunningham LL Jr, Beeman CS, Kluemper GT, Hicks EP, Kim MO. Evaluation of orthodontic mini-implant anchorage in premolar extraction therapy in adolescents. *Am J Orthod Dentofacial Orthop.* 2008;133(5):642-653.
27. Kim YH, Yang SM, Kim S, Lee JY, Kim KE, Gianelly AA, et al. Midpalatal miniscrews for orthodontic anchorage: factors affecting clinical success. *Am J Orthod Dentofacial Orthop.* 2010;137(1):66-72.

AUGMENTED REALITY AND ARTIFICIAL INTELLIGENCE: A (HUMAN) BRAINSTORM ON HOW THEY ARE REVOLUTIONIZING PAIN RESEARCH, EDUCATION, AND TREATMENT

Thiago D. Nascimento, Xiao-Su Hu, Alexandre F. DaSilva

ABSTRACT

Chronic pain represents a substantial health care problem, with significant economic costs and a burden to society. Scientific evidence is still being developed in the field of chronic pain to better elucidate its etiology, mechanism, and progression. Another important topic that is sometimes overlooked is the way clinicians, researchers and educators measure and evaluate pain. Our research group will shed light on the current evidence related to a more objective and reliable method to measure and evaluate pain. We will also discuss the ways pain affects our brains, and lastly, how we can use emerging neuroimaging technology, associated with augmented reality and artificial intelligence, to improve chronic pain and dental research, education, and most importantly, patient care.

KEY WORDS: Pain, GeoPain, Augmented Reality, Artificial Intelligence, fNIRS

INTRODUCTION

The International Association for the Study of Pain defines pain as an “unpleasant sensory and emotional experience associated with actual or potential tissue damage, or described in terms of such damage”. It also emphasizes that “pain is always subjective” and is “unquestionably a sensation in a part or parts of the body, but it is also always unpleasant and therefore also an emotional experience” [1]. Broadly, they are categorized by a complex interaction of biological, psychological, and social factors [2]. Pain can be defined as acute or chronic pain. Acute pain is the physiological response to an adverse chemical, thermal, or mechanical stimulus, associated with surgery, trauma, and acute illness [3]. Chronic pain is defined as a condition that persists past normal healing time (functional classification) or persists and reoccurs for more than three months (temporal classification) [4].

Studies have suggested that 100 million adults are affected by persistent pain which impacts their quality of life and limits their functional status [5]. Consequently, the estimated annual economic burden to our society ranges from \$560 to \$635 billion [6]. This amount is larger than the costs of major health conditions, such as cardiovascular diseases and neoplasms [5]. It is, therefore, crucial to continue investing in research, treatment, education, and prevention of chronic pain.

Although several chronic pain conditions still lack a refined understanding of their etiology and pathophysiology, there is an initial and crucial question on how to best measure and evaluate pain. Currently, there are no objective tests for clinical pain measurement. Other diseases can rely on

standardized measurements, like blood pressure, for assessment. However, pain has an individual embedded religious, cultural, and belief significance that is extremely difficult and complex to be simplified by a numerical or visual pain scale. The typical question commonly asked pain patients seeking care is to rate their pain level based on a 0 to 10 pain scale (Numeric Rating Scale, NRS), where 0 represents 'no pain', and 10 represents 'Pain as bad as you can imagine' [7]. This standard of care is arbitrary, and current research initiatives can help elucidate new pathways for the measurement of pain.

In this chapter, we will briefly discuss the advances that have been made in chronic pain research, education, and treatment by the use of emerging neuroimaging techniques that are providing new personalized treatments and tools to better improve quality of care, patient outcomes, and education. Three novel aspects will be covered. First, are we measuring clinical pain in the right way, and is there a better clinical tool for the assessment of pain *in vivo*? Second, what is the impact of pain on our brains? Lastly, how can augmented reality (AR) and artificial intelligence (AI) improve the care of patients with chronic pain in a clinical dental setting? To understand these questions, we need to better understand the neuromechanisms associated with pain, and most importantly, the personalization of care.

Are We Measuring Pain the Right Way?

Pain can be considered one of the main reasons patients seek care [8]. It is, therefore, paramount to be able to measure individual pain to utilize this measurement as an additional aid in pain management, and patient care. Pain measurement is so crucial that in 1999, the Veterans Health Administration initiated a strategy to improve pain management for its patients, by requesting their providers to measure and document in the electronic medical record their patient's self-reported pain level. The initiative was called "Pain as the 5th Vital Sign" [9]. Studies have shown that although measuring pain by an NRS system is essential to improve the quality of care, it does not provide adequate comprehension of the quality or character of an individual's pain experience [10, 11]. Moreover, measurement of pain intensity alone does not necessarily increase the health care provider awareness nor increase the rates at which providers recommend the appropriate therapy [8].

To improve the quality of pain management and to better understand each patient's pain level, DaSilva et al. created an interactive mobile application for pain mapping called GeoPain (MoxyTech Inc., MI). By using this application, participants are asked to map their pain area and intensity numerically to obtain an objective sensory-discriminative information of each pain episode [12]. The application provides a three-dimensional body map, including the head and facial regions, with a detailed squared grid system based on anatomical landmarks. Each quadrangle, with vertical and horizontal coordinates, captures well-detailed craniofacial and cervical areas for each patient to express their exact pain location and intensity. More specifically, during each pain attack, patients are asked to draw their pain based on their pain intensity: mild, moderate, or severe pain (Fig. 1). The drawing of pain is then quantified by scoring each of the 220 total cells on a 0 to 3-point scale: 0 (no pain), 1 (mild pain), 2 (moderate pain), and 3 (severe pain). Three pain measures are generated from these values. The first measure is average pain that is the average score of all cells that are colored as painful (scale of 1 to 3). The second is the pain area that is the percentage of the head and neck area that is experiencing pain (scale of 0 to 100% of all cells). Lastly, Pain Area and Intensity Number Summation (P.A.I.N.S.) is the cumulative score in the previous GeoPain version for the 220 cells, with a scale of 0 to 660, which is equal to 220 times 3 for maximum severe pain. The three pain measures can be used to understand how sensory-discriminative pain measures change during the course of treatment, by performing a bilateral or unilateral analysis for the entire body or orofacial region.

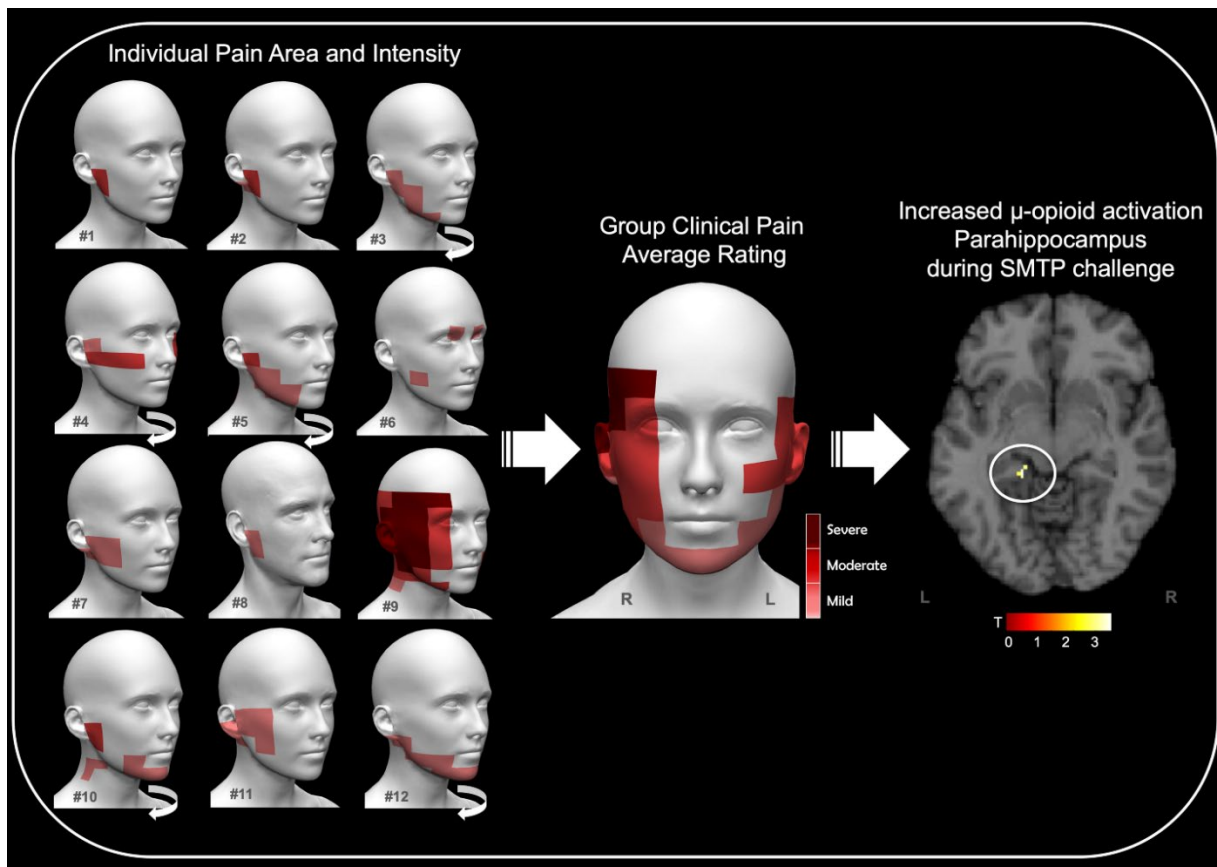


Figure 1. Example of the Interactive mobile application for pain mapping called GeoPain (MoxyTech Inc., MI). Left: By using the GeoPain application, 12 participants with chronic TMD recorded their pain area and intensity during a PET session. Center: The average pain area and intensity is represented as a 3D image. Right: The clinical pain is correlated with brain imaging from a PET session, indicated by the increased endogenous μ -opioid activation in the limbic system of TMD pain patients during chronic pain. (From Journal of Dental Research, vol. 98, 12: pp. 1324-1331, DOI: 10.1177/0022034519871938)

Therefore, this application measures patients' self-report of pain not only by a single number but also by considering the location, area, and intensity of pain. This sensory approach has led to statistically significant improvement in the quality of pain measurement. Donnell et al. evaluated the treatment effects of five daily, 20-minutes sessions of active or sham two milliamps (mA) high-definition transcranial direct current stimulation (HD-tDCS), in patients with chronic temporomandibular disorders (TMD) [13]. In the short term (one-week follow-up), participants that received active HD-tDCS demonstrated a statistically significant reduction in the pain area, intensity, and their number sum (P.A.I.N.S) for pre-post GeoPain measurements of the contralateral side to the HD-tDCS stimulation. Remarkably, it was possible to observe that although some patients would report their pain level using a lower NRS than another participant, their pain area, intensity, and P.A.I.N.S were sometimes higher. This was interpreted as an increased severity in the TMD pain symptoms, which could not be adequately appreciated by the use of NRS alone.

Another recent study using the GeoPain has validated the application by analyzing it and comparing its measurements with two traditional methods used in pain research, the Visual Analog Pain Scale (VAS) and the Positive and Negative Affects Scale (PANAS) [14]. A sample of 24 female patients with chronic TMD was used in the study. The researchers concluded that, over time, there was a significant correlation between the VAS and mood scores interpreted from PANAS. They interpreted that the correlation was likely related to the inherent subjectivity of VAS measure, while sensory-discriminative GeoPain measures and not VAS, showed an association between chronicity and TMD pain in locations that were distant from the patient's epicenter of pain (most commonly reported area). Moreover, an association between TMD pain and chronicity at baseline was not detected by VAS analysis. Interestingly, the effect sizes for P.A.I.N.S were larger compared to VAS; therefore, smaller sample size was needed to evaluate the efficacy of a treatment if P.A.I.N.S is used versus VAS. This validation study was able to demonstrate that P.A.I.N.S is an objective measure that has better sensitivity and reliability for measuring treatment effect over time for sensory-discriminative pain since P.A.I.N.S was not associated with PANAS as compared to VAS.

What Is the Impact of Pain on Our Brains?

Primary headache and chronic TMD have been widely used in dentistry as a model for clinical chronic pain. Primary headache, more specifically migraine, is a neurological disorder with a constellation of signs and symptoms that can last up to three days [15]. Epidemiological studies have shown for decades that the prevalence of Migraine is approximately 18% for women and 6% for men, making migraine the third most prevalent disorder, and globally ranked number seven as the cause of disability [16-19]. In terms of the frequency of headache attacks, migraine can be classified into episodic (EM) and chronic migraine (CM) [15]. Chronic migraineurs have frequent migraines and headaches on at least 15 days per month. Longitudinal population studies estimate that about 3% of EM progress to CM each year [20].

The use of advanced molecular neuroimaging techniques, such as positron emission tomography (PET), have shown the impact migraine has on our brains. A recent study analyzed the brains of 7 healthy controls (HC) and 15 migraineurs (8 EM and 7 CM) during the spontaneous headache phase (ictal) and non-headache phase (interictal) of their migraine [21]. The specific aim was to evaluate the impact the natural migraine headache attacks have on the endogenous opioid system, which is arguably one of the main neuromechanisms centrally involved in pain regulation and experience, and on the μ -opioid receptors (μ ORs) – the primary mediator for opioid analgesia [22]. Subjects underwent PET with the selective μ -opioid receptor (μ OR) radiotracer [11C] carfentanil. During each PET scan, participants also undertook a thermal pain threshold challenge that was developed to reproduce allodynia [23]. Allodynia is defined as an experience of pain from a stimulus that does not normally provoke pain and is considered a clinical risk factor for CM [1, 24]. Overall, researchers were able to identify specific brain regions (Thalamus, Caudate, Amygdala, and Parahippocampal) that had a higher release of endogenous μ -opioid (peptides) during CM attacks and thermal pain threshold challenges, meaning that these regions were activated during a migraine headache attack and trigeminal thermal pain threshold challenge.

The evidence suggests that migraineurs have increased μ -opioid receptor-mediated neurotransmission in brain regions that during a migraine attack are associated with pain perception and modulation. Moreover, the clinical chronification of the attacks and increased pain sensitivity, measured by allodynia, showed that the dysfunctional μ -opioid activity spreads to limbic regions and the right amygdala.

The limbic system is mainly associated with the processing of our emotional and motivational responses [25]. It also plays a role in pain sensitivity and stress response [26, 27]. The limbic dysfunction demonstrated in CM was observed similarly in chronic TMD patients.

TMD is an orofacial pain disorder that affects the masticatory muscles, temporomandibular joint, and/or associated structures. It is prevalent in about 5% to 12% of the population and has an annual incidence of 4% [28, 29]. Similar to migraine, chronic TMD, highly affect the patient's quality of life and represent a burden to society. Approximately 40% of acute TMD patients become chronic, which suggests that TMD also has centrally mediated and neuroplastic changes in the brain [30].

In another recent study, 12 chronic TMD patients and 12 matched HC were also scanned using PET with [11C] carfentanil to investigate the central changes in the endogenous opioid system during resting state and during a sustained masseteric pain challenge [31]. The challenge consisted of a 20-min masseteric injection of 5% hypertonic saline controlled by an electronic PC/Pump system. Blood samples were collected during each scan, and participants were genotyped for different catechol-O-methyltransferase (*COMT*) alleles. *COMT* has been identified as a risk factor for TMD, including the Val¹⁵⁸Met genotype [29].

Investigators observed that TMD patients had increased μ -opioid activation in the limbic system (contralateral parahippocampal region) during the prolonged pain caused by the masseteric challenge. This activation was further modulated by *COMT* ¹⁵⁸Met substitution. Furthermore, TMD patients that had pain beyond five years displayed greater activation of the endogenous opioid system, corroborating the current evidence of the involvement of central mechanisms in the TMD pain processing and modulation.

Therefore, the opioidergic dysfunction in the limbic system of CM and chronic TMD provides insight for the neuromechanistic reasons of why these patients have an increased emotional impact in their pain, increased sensitivity to the environment exemplified by their thermal and masseteric pain thresholds, and likely a higher risk for opiate overuse.

Augmented Reality and Artificial intelligence in Dental Pain

Researchers have been seeking methods to objectively measure pain for a long time. Though a long way to go, the developing neuroimaging, artificial intelligence, computational power, and computer vision techniques opened a window for the new-era pain measurement. Following this trend, in our lab, we designed a research space that integrated these components including an observational space equipped with surveillance cameras, neuroimaging techniques, AR/VR devices, neuro-modulation apparatus, and powerful computers running artificial intelligence algorithms. We name this space "Michigan Clinical Augmented Reality Pain Unit (M-CARP)."

Our first study in the space was on dental pain within a group of patients diagnosed with dentin hypersensitivity. We recruited twenty-one participants and designed an experimental protocol that included resting state and quantitative sensory test (QST) sessions. In the resting state sessions, all participants were sitting on the dental chair relaxed while we collected data from their brains. In the QST session, they received twenty thermal stimuli in sequence. The thermode with descending temperature was designed to trigger participants' pain threshold, and the participants decided when to stop the stimuli. Meanwhile, we used functional near-infrared spectroscopy (fNIRS) imaging technique to monitor participants' brain activations at prefrontal and primary sensory cortices in all sessions.

As a result, we firstly confirmed cortical hemodynamic responses of patients experiencing stepwise noxious cold stimulation in a fully simulated dental clinical environment according to collected fNIRS data. Specifically, we observed pain expectation relevant responses at bilateral prefrontal cortices, while a pain sensation evoked double-peak hemodynamic responses at the contralateral S1 region [32]. Further, we found a possible cascade of brain activations and networks that modulated such dental pain experiences. Specifically, patients' pain experience can be predicted concomitantly by their baseline functional connectivity between cognitive-emotional and sensory-discriminative cortical areas, and their well-defined sequence of hemodynamic responses – from expectation all the way to dental suffering reported [33]. Based on these findings, we developed a prototype of an objective pain assessment framework named clinical augmented reality and artificial intelligence (CLARAI) and tested its feasibility (Fig 2) [34]. Such a framework uses artificial intelligence algorithms (e.g. neural network) to learn the patterns in collected fNIRS data and then predicts pain statuses in patients based on the learned patterns. Specifically, the data subsets collected at the current moment and very recent previous moments were incorporated into a training algorithm. A data-driven model will be gradually fitted to all data subsets during the training process. Then the trained model was applied to predict patients' brain statuses for the newly collected data. We tested this model with 10-fold cross-validation and achieved a classification accuracy of approximately 74% [34]. At the same time, researchers were able to view the data in real-time with its classification through an augmented reality device HoloLens (Microsoft, WA).

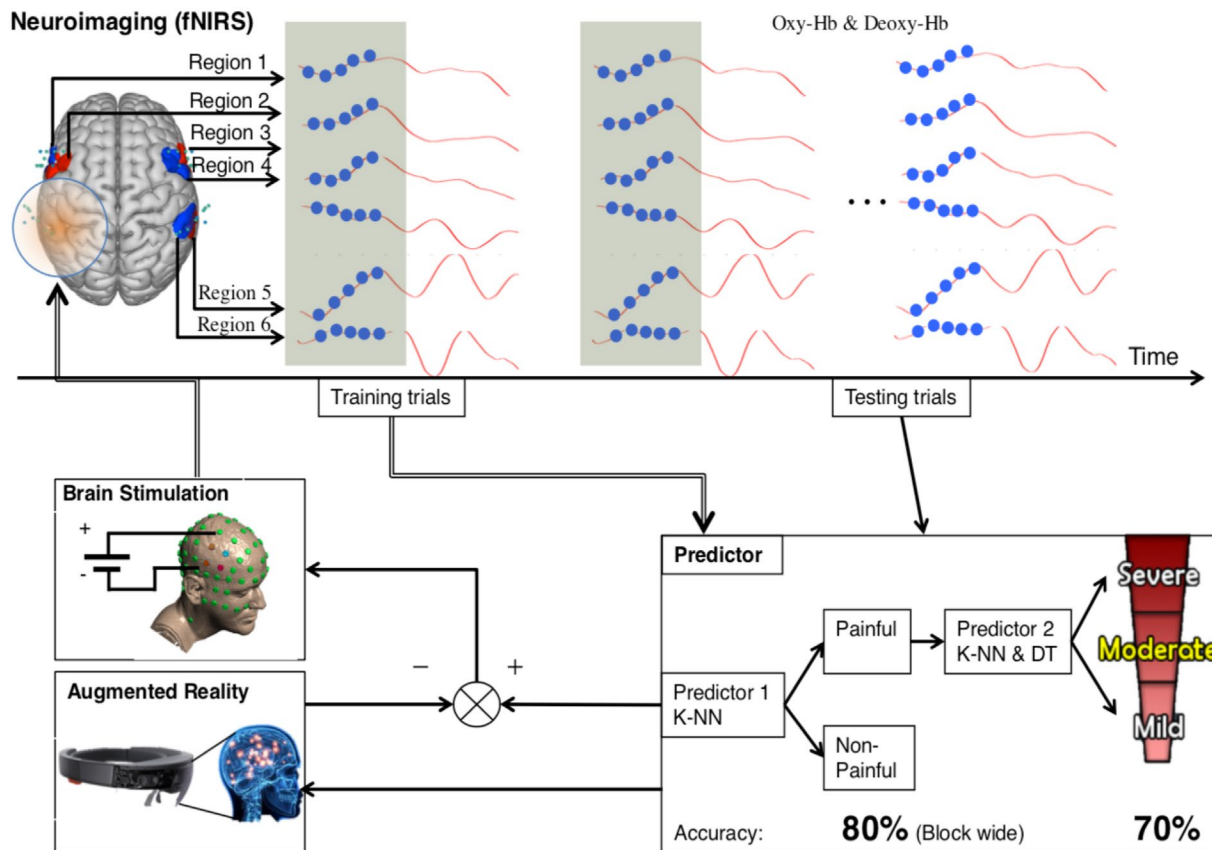


Figure 2. Clinical augmented reality and artificial intelligence (CLARAI) framework for objective pain surveillance (MoxyTech Inc., MI).

In the future, we are planning to extend this framework and the use of the M-CAPR space by adding different artificial intelligence algorithms, and neuromodulation components to study more types of clinical pain problems. In this way, we hope our developed framework can not only predict pain/no-pain brain status but also indicate the pain locations and level. Also, this closed-loop framework will let us pry into how neuromodulation techniques change pain perspectives in the brain.

CONCLUSIONS

Pain measurement and evaluation have become an important topic in the pain field. Chronic pain is a public health problem, and emerging neuroimaging modalities associated with augmented reality and artificial intelligence are being currently used to improve not only our evidence of how pain is processed and modulated in the brain but most importantly, how we can personalize pain management and improve pain education. In addition, the development of technologies granted researchers an opportunity to develop objective pain surveillance methods.

DISCLOSURES

Dr. A. F. DaSilva co-created GeoPain (previously named PainTrek), and also co-founded MoxyTech Inc. that licensed the technology from the University of Michigan. The authors declare that they have no conflict of interest.

REFERENCES

1. Pain terms: a list with definitions and notes on usage. Recommended by the IASP Subcommittee on Taxonomy. *Pain* 1979;6(3):249.
2. Nicholas M, Vlaeyen JWS, Rief W, Barke A, Aziz Q, Benoliel R, et al. The IASP classification of chronic pain for ICD-11: chronic primary pain. *Pain* 2019;160(1):28-37.
3. Carr DB, Goudas LC: Acute pain. *Lancet* 1999;353(9169):2051-2058.
4. Treede RD, Rief W, Barke A, Aziz Q, Bennett MI, Benoliel R, et al. Chronic pain as a symptom or a disease: the IASP Classification of Chronic Pain for the International Classification of Diseases (ICD-11). *Pain* 2019;160(1):19-27.
5. In: *Relieving Pain in America: A Blueprint for Transforming Prevention, Care, Education, and Research*. edn. Washington (DC); 2011.
6. Gaskin DJ, Richard P. The economic costs of pain in the United States. *J Pain* 2012;13(8):715-724.
7. Dworkin RH, Turk DC, Farrar JT, Haythornthwaite JA, Jensen MP, Katz NP, et al. Core outcome measures for chronic pain clinical trials: IMMPACT recommendations. *Pain* 2005;113(1-2):9-19.
8. Mularski RA, White-Chu F, Overbay D, Miller L, Asch SM, Ganzini L. Measuring pain as the 5th vital sign does not improve quality of pain management. *J Gen Intern Med* 2006;21(6):607-612.
9. Pain as the 5th vital sign toolkit. *Veterans Health Administration, Geriatrics and Extended Care Strategic Healthcare Group, National Pain Management Coordinating Committee 2000*, revised edition, <http://www.va.gov/oaa/pocketcard/pain.asp>.
10. Robinson-Papp J, George MC, Dorfman D, Simpson DM. Barriers to Chronic Pain Measurement: A Qualitative Study of Patient Perspectives. *Pain Med* 2015;16(7):1256-1264.
11. Ballantyne J, Fishman S, Rathmell JP. *Bonica's management of pain*, Fifth edition. edn. Philadelphia:

- Wolters Kluwer; 2019.
12. DaSilva AF, Nascimento TD, DosSantos MF, Lucas S, van Holsbeec KH, DeBoer M, et al. Association of mu-Opioid Activation in the Prefrontal Cortex with Spontaneous Migraine Attacks - Brief Report I. *Ann Clin Transl Neurol* 2014;1(6):439-444.
 13. Donnell A, Nascimento TD, Lawrence M, Gupta V, Zieba T, Truong DQ, et al. High-Definition and Non-invasive Brain Modulation of Pain and Motor Dysfunction in Chronic TMD. *Brain Stimul* 2015;8(6):1085-1092.
 14. Kaciroti N, DosSantos MF, Moura B, Bellile EL, Nascimento TD, Maslowski E, et al. Sensory-discriminative 3D-body Pain Mobile App Measures Prevail over Moody VAS: A Validation Study. *JMIR Mhealth Uhealth* 2020.
 15. *Headache Classification Committee of the International Headache S: The International Classification of Headache Disorders, 3rd edition (beta version)*. *Cephalalgia* 2013;33(9):629-808.
 16. Burch RC, Buse DC, Lipton RB. Migraine: Epidemiology, Burden, and Comorbidity. *Neurol Clin* 2019;37(4):631-649.
 17. Lipton RB, Bigal ME, Diamond M, Freitag F, Reed ML, Stewart WF, et al. Migraine prevalence, disease burden, and the need for preventive therapy. *Neurology* 2007;68(5):343-349.
 18. Steiner TJ, Stovner LJ, Birbeck GL. Migraine: the seventh disabling. *J Headache Pain* 2013;14:1.
 19. Vos T, Flaxman AD, Naghavi M, Lozano R, Michaud C, Ezzati M, et al. Years lived with disability (YLDs) for 1160 sequelae of 289 diseases and injuries 1990-2010: a systematic analysis for the Global Burden of Disease Study 2010. *Lancet* 2012;380(9859):2163-2196.
 20. Bigal ME, Serrano D, Buse D, Scher A, Stewart WF, Lipton RB. Acute migraine medications and evolution from episodic to chronic migraine: a longitudinal population-based study. *Headache* 2008;48(8):1157-1168.
 21. Jassar H, Nascimento TD, Kaciroti N, DosSantos MF, Danciu T, Koeppe RA, et al. Impact of chronic migraine attacks and their severity on the endogenous mu-opioid neurotransmission in the limbic system. *Neuroimage Clin* 2019;23:101905.
 22. Zubieta JK, Smith YR, Bueller JA, Xu Y, Kilbourn MR, Jewett DM, et al. mu-opioid receptor-mediated antinociceptive responses differ in men and women. *J Neurosci* 2002;22(12):5100-5107.
 23. Nascimento TD, DosSantos MF, Lucas S, van Holsbeeck H, DeBoer M, Maslowski E, et al. mu-Opioid activation in the midbrain during migraine allodynia - brief report II. *Ann Clin Transl Neurol* 2014;1(6):445-450.
 24. Benatto MT, Florencio LL, Carvalho GF, Dach F, Bigal ME, Chaves TC, et al. Cutaneous allodynia is more frequent in chronic migraine, and its presence and severity seems to be more associated with the duration of the disease. *Arq Neuropsiquiatr* 2017;75(3):153-159.
 25. Aminoff EM, Kveraga K, Bar M. The role of the parahippocampal cortex in cognition. *Trends Cogn Sci* 2013;17(8):379-390.
 26. Grant JA, Courtemanche J, Duerden EG, Duncan GH, Rainville P. Cortical thickness and pain sensitivity in zen meditators. *Emotion* 2010;10(1):43-53.
 27. Li H, Li W, Wei D, Chen Q, Jackson T, Zhang Q, et al. Examining brain structures associated with perceived stress in a large sample of young adults via voxel-based morphometry. *Neuroimage* 2014;92:1-7.
 28. Schiffman E, Ohrbach R, Truelove E, Look J, Anderson G, Goulet JP, et al. Diagnostic Criteria for Temporomandibular Disorders (DC/TMD) for Clinical and Research Applications: recommendations of the International RDC/TMD Consortium Network* and Orofacial Pain Special Interest Groupdagger. *J Oral Facial Pain Headache* 2014;28(1):6-27.
 29. Slade GD, Ohrbach R, Greenspan JD, Fillingim RB, Bair E, Sanders AE, et al. Painful Temporomandibular Disorder: Decade of Discovery from OPPERA Studies. *J Dent Res* 2016;95(10):1084-1092.

30. Rammelsberg P, LeResche L, Dworkin S, Mancl L. Longitudinal outcome of temporomandibular disorders: a 5-year epidemiologic study of muscle disorders defined by research diagnostic criteria for temporomandibular disorders. *J Orofac Pain* 2003;17(1):9-20.
31. Nascimento TD, Yang N, Salman D, Jassar H, Kaciroti N, Bellile E, et al. micro-Opioid Activity in Chronic TMD Pain Is Associated with COMT Polymorphism. *J Dent Res* 2019;98(12):1324-1331.
32. Racek AJ, Hu X, Nascimento TD, Bender MC, Khatib L, Chiego D, et al. Different Brain Responses to Pain and Its Expectation in the Dental Chair. *J Dent Res* 2015;94(7):998-1003.
33. Hu X, Racek AJ, Bellile E, Nascimento TD, Bender MC, Toback RL, et al. Brain Functional Changes before, during, and after Clinical Pain. *J Dent Res* 2018;97(5):523-529.
34. Hu X-S, Nascimento TD, Bender MC, Hall T, Petty S, O'Malley S, et al. Feasibility of a Real-Time Clinical Augmented Reality and Artificial Intelligence Framework for Pain Detection and Localization From the Brain. *J Med Internet Res* 2019;21(6):e13594.

DRASTIC PLASTIC: ENHANCING THE PREDICTABILITY OF CLEAR ALIGNERS

S. Jay Bowman

ABSTRACT

Once limitations of clear aligner treatments were identified, conceptualizing techniques to improve the predictability in producing desired results was the next logical step. A variety of concepts, methods, and adjuncts have subsequently been introduced to enhance the efficiency and effectiveness of clear aligners. As a consequence, the scope of biomechanics and type of malocclusions that can be more predictably treated has increased. As one example, the inclusion of miniscrew temporary skeletal anchorage has permitted the addition of direct and indirect anchorage to support and control more predictable programmed tooth movements with aligners. After reviewing the reported shortcomings of plastic aligners, this chapter explores possibilities for improving predictability of aligner therapy.

KEY WORDS: Clear Aligners, Miniscrews, Bootstrap Elastic, Attachments, Bonded Buttons

INTRODUCTION

It has been 20 years since the introduction of a commercialized clear aligner product to the orthodontic marketplace. Based on suggestion by Harold D. Kesling over 50 years earlier, Invisalign and later, increasingly numerous propriety alternatives have come to pass; including the exponential growth of so-called direct-to-consumer (DTC or DIY) offerings [1]. From the original questions of whether even “acceptable” results could be obtained from a sequence of aligners, these queries have now evolved into: Is an orthodontist even needed to be interjected between the manufacturer’s plastic and their “customers?”

So, the idea of moving teeth with plastic was nothing new, but the use of software to attempt to predict desired tooth movement and the associated 3D representations of individual tooth position were innovative. This enabled the replacement of the labor-intensive process of cutting and creating plaster set-ups and was followed by the game-change of using digital intraoral scanners, instead of the imperfections of impressions. Complementing the evolution of aligners was the development of composite “attachments,” applied to the teeth to increase the surface area contacted by the plastic trays. During this growth and development of clear aligners as a viable alternative to traditional “braces,” the providers themselves created ever-improving treatment planning with an eye to mimicking the results from a century of brackets and wires.

This evolution has been hampered by an unfortunately and unnecessarily tedious evaluation of treatment changes by the orthodontists attempting to assess their results and render improvements. In

other words, an innovator would apply an altered digital set-up, anticipating a positive change. Unfortunately, the effects could not be assessed for long periods of treatment time. This, despite the fact that highly accurate digital representations of the initial malocclusion could have been compared with not only progress “refinement” scans, but also successful final results of similar patients treated around the world. Align Technologies could have been the archivist for the largest preserve of final orthodontic records in our specialty’s history. From that massive archive, changes that actually produced consistent positive improvements could have been gleaned and shared with practitioners, rather than the primitive and individual trial-and-error “testing of ideas” that each of us have had to conduct in private. The corporation could have accomplished this quite simply by commissioning “final records” from orthodontists, made available for research: *Quare sequitur*: What works, what doesn’t?

Instead, information has been divvied and disseminated by key opinion leaders (KOL), each with a selection of their own case reports of what their own isolated trials have revealed with only filtered experience as a guide. Later, these anecdotes were compiled into cohorts, retrospective evaluations subject to influence from various biases, a smattering of prospective investigations, and as would be expected, an ever-growing number of meta-analyses and systematic reviews, looking at virtually the same limited data. All of these reports, when evaluated *en masse*, confirm many of the issues commonly exasperating isolated docs. Some of their responses have been to throw-up their hands and quit, or ignore and live with the compromises, or dig into their armamentaria of orthodontic devices and biomechanical concepts and press forward.

As an active participant in this oddly frustrating progression of clear aligner developments that included starts-and-stops, controversy-and-conundrums, there has been a continual thirst for improvement and enhancement. Sadly, proprietary squabbles among the “companies” have held sway over genuine interest in improving the quality of care for actual patients (not “customers”).

If one takes the time to consider the body of evidence on clear aligners along with guidance from a select few gurus, the undeniable question comes to mind, “Just how predictable is plastic?”

JUST HOW PREDICTABLE ARE CLEAR ALIGNERS?

We have all likely seen innumerable celebrities and professional athletes wearing plastic aligners but probably haven’t been aware, unless they decided to “show-off” in social media and pop culture. Bryan Cranston’s “attachments” were visible in *Breaking Bad*, Sebastian Stan’s (Bucky Barnes) smile transformed during *Captain America: The Winter Soldier*, the Kardashians’ (and wannabes’) flashed their plastic, as did Oprah. Anna Kendrick’s aligner case was labelled “Anna’s Grillz” by her crew, a young Justin Bieber mugged his plastic, Ashton Kutcher placed his aligner cases on public display when eating, and Billie Eilish immortalized the removal of her plastic just as she started recording a song. Although Atlanta Falcons’ Julio Jones was pictured playing football while using his plastic, more impressively, Kansas City Chiefs’ Patrick Mahomes won the Super Bowl and the MVP in 2020 wearing Invisalign as his “mouth guard” (as reported by his girlfriend on Instagram). Actress, Katherine Heigl was photographed removing her aligners and provides the ideal transition into our discussion with her quote, “I like predictability because I know what I’m getting into.”

Aligner Reports and Results

During the first few years of aligners, early adopters began treatments for patients with this esthetic alternative to braces with varying degrees of success. Some teeth got straighter, some

malocclusions improved, but the limits were assumed to be Class I malocclusions with mild to moderate crowding or spacing. Class IIs and IIIs were thought to be verboten and, don't even think about deep or openbites. As the literature was reviewed, it was essential to continually remind oneself of the following quote as it seems evanescent in discussions regarding the effectiveness and predictability of clear aligners:

Compliance is the single most important factor in treatment success.

-Buzz Behrents

Kravitz et al. published a prospective clinical study in 2005 that echoes the question: "How well does Invisalign work?" Is it important to note that this and many of the following investigations were conducted in the era of the original product (plastics and attachments) [2]. In those early days, assumptions were made about the responses of teeth to the vectors of force based on predictions of the resultant, expected movement. The research workers concluded that only 41% of the tooth movement goals were achieved. Shouldn't we assume that subsequent investigations would provide more optimistic results?

So, it wouldn't be a surprise that nine years later, Chisari et al. did observe 57% of tooth movement goals were achieved [3]. Then in 2017, workers from the University of Ferrara noted a mean predictability of 74% [4]. Each of these studies and several others also described the predictability for specific types of tooth movement. For instance, Houle et al. concluded that there was 73% predictability for maxillary expansion and 88% accuracy for the mandible [5]. In contrast, Solano-Mendoza stated that expansion was not predictable [6]. Incisor intrusion was translated (from the predicted "set-up") at between 73-79% accuracy but in a contrasting report, incisor intrusion was said to be "the most inaccurate movements identified" [7, 8].

A systematic review by Rossini et al. in 2015 confirmed what was reported a decade earlier by Kravitz et al., namely, that incisor extrusion is highly unpredictable [2, 9]. In fact, desired extrusion was only 30% accurate. At this point in the review, the question might arise, "why were teeth not translating accurately based on the 3D computer-generated predictions?" Just because you can move around the drawings of teeth in virtual software "cartoons" doesn't mean that the teeth will watch the cartoons and move in response. There are a whole host of accumulated "errors" that are responsible: errors in the impression/scan, in developing the 3D models, plastic molding/heating/"suction" problems, manufacturing tolerances, flexing, distortion, imperfect planned tooth movement, unrealistic expectations, insufficient surface area contact (e.g., short-round teeth), lack of adequate space, and the obvious, nagging specter of unpredictable patient compliance (not to mention the rate of "drop-outs").

Effectiveness and Efficiency of Plastic

Plastic can produce results that patients favor, but how effective, efficient, and predictable are these outcomes? Buschang et al. reported that aligners were more time efficient than braces, offsetting the greater cost and doctor time when using plastic [10]. In comparison, Zheng et al. concluded evidence was lacking regarding claims of aligner effectiveness [22]. Leake et al. stated there was insufficient support for aligners as an alternative to braces [12]. A review from Mahidol University also affirmed the same as aligners were found to be especially deficient in correcting large A-P discrepancies and producing occlusal contacts [12]. A further systematic review also determined "the lack of ability to correct A-P, occlusal contacts, extrusion, and rotations greater than 15 degrees [13]."

Robertson et al. published a systematic review in 2019, concluding that aligners demonstrate low to moderate efficiency in regard to specific tooth movements and cautioned that due to that unpredictability, “more than one set of trays (refinements)” will likely be necessary [15]. Finally, the mean overall efficacy of aligners was pronounced to be only 59% by Simon et al. Bear in mind that’s at least a bit more favorable than the 42% probability of an overall win when playing “blackjack,” but it certainly seems that there is still considerable room for improvement in plastic care [15].

Plastic vs. Braces

So how do treatments with aligners stack up to those with traditional methods? Results from a meta-analysis detailed limitations in effectiveness of plastic in terms of occlusion, torque, and retention [17]. Kuncio et al. also curiously found more relapse with aligners, postulated due to the amount of dental tipping movement with plastic appliances [18].

In an investigation employing the PAR Score, it appeared that aligners were not as effective as fixed appliances in achieving “great improvement” in a malocclusion compared to braces [19]. This was basically the same conclusion from a systematic review published by researchers in Spain [20]. When the ABO objective grading system was applied to the outcomes of braces and aligners, it was concluded that aligners “did not treat malocclusions as well as braces;” especially in terms of buccolingual inclination, A-P, occlusal contacts, and overjet [21]. These findings confirmed those of Wiboonsirikul et al. and also reiterated by a recent meta-analysis in 2019 [13, 22]. Considering that some folks have predicted that plastic will completely supplant metal braces soon, current findings hardly support those prognostications.

The reports of my death are greatly exaggerated
-cable sent by Mark Twain after his obituary was mistakenly published.

Direct-to-Consumer (DTC)

Marketing claims for DTC are plentiful, evidence is lacking. For an example, “Teledentistry employs the same level of professional services as traditional orthodontics and is proven to have equal or better outcomes.” Bold and inescapably disputable words. For instance, if a “customer” purchases an impression “putty” kit as a first step in ordering a series of trays, are they actually capable of generating an accurate foundation to base the rest of the entire process upon? In a university-based investigation, laypersons were given the opportunity to use the same putty materials to take their own impression. It was determined that folks with no dental experience cannot take an accurate, acceptable impression on themselves [23]. That finding is absolutely no surprise to orthodontists who have been exasperated with having even experienced assistants attempt to get quality polyvinyl siloxane (PVS) impressions for aligners.

Therefore, will the consumer’s impression be sufficient for a technician to generate accurate models and ultimately a series of aligners? More importantly, will the resulting set-up models reflect the consumer’s final results? Investigators at Baylor University found that ClinCheck digital set-up models do not accurately reflect the patient’s final occlusion. Izhar and co-workers also determined that predicted software models are not accurate in reflecting final tooth positions [24, 25]. These findings would seem to be somewhat disconcerting if accuracy is a goal.

When is good enough, just good enough? “Customers” are said to be thirsting for plastic treatments so that they might “treat” themselves without a professional interposed in the orderly conduct of commerce. Specifically, the social six teeth might get relatively straighter, but what about that nagging “bite?” The conversation often goes as follows: “Doc, I just want this one tooth fixed, I don’t care about my bite.” They may return not as a “consumer” anymore, but now as a disappointed “patient” with a complaint that, “my teeth feel funny when I bite down.” That’s awkward at minimum. Look, patients don’t crave dispensed or mail-order plastic; they actually desire results [26]. Perhaps, just advertising straighter front teeth (bite be damned) should be taken seriously by the consumer. *Caveat emptor*, especially in the absence of an in-person examination and informed consent.

ANNOYING LIMITATIONS OR STIMULUS FOR INNOVATION

“Learn to view limitations not as annoyances but as welcome editors that force you to think creatively.”
 -Garr Reynolds

A prospective follow-up to Kravitz et al. [2] on the efficacy of tooth movement with aligners was published in 2020 by Haouili et al. [27]. They concluded that although the mean accuracy for all tooth movements was 50%, that was only a 9% improvement in results in an 11-year period since the original publication. It’s not surprising that Rossini et al. had concluded that clear aligner treatments cannot be based on a sequence of plastic trays alone [7]. There is much more than just dispensing plastic. Clear aligner treatment has clearly progressed in terms of attachment design, supplemental auxiliaries, inter proximal reduction (IPR), elastics, adjunct appliances including braces, miniscrews, and even individualizing aligners [28-36].

Some lack of predictability, effectiveness, and efficiency has, in many instances, been overcome by the perseverance of determined and inventive practitioners. Innovations are defined as a new idea, device, or method as well as the act or process of introducing them, in this case, into the specialty of orthodontics. One simple example is the Aligner Chewie* that was introduced early on in the evolution of clear aligners (Figure 1) [31, 37]. When delivering a new aligner in a series, often they fit quite tight and do not seat completely onto the teeth. The Aligner Chewie was designed to replace the use of chewing on dental cotton rolls to assist in pushing the aligner into place as kind of makeshift, “mini-tooth positioner” (Figure 2) [31, 37].

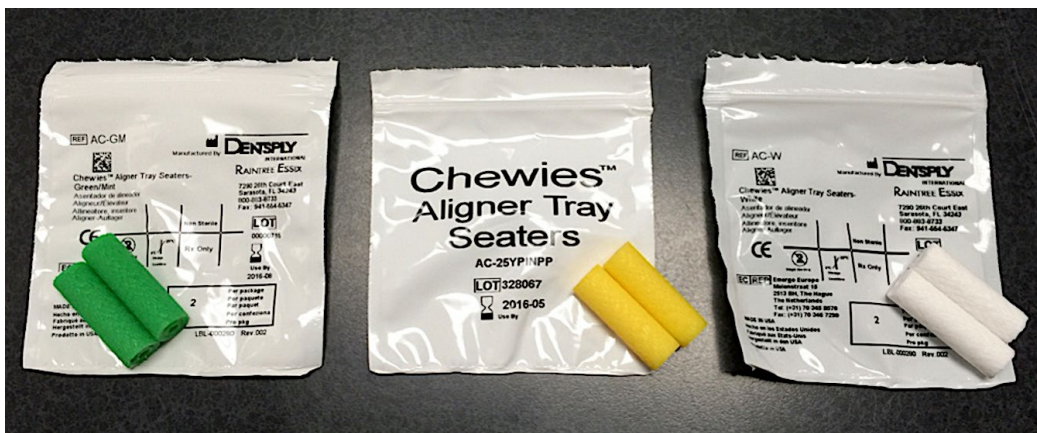

Figure 1. Aligner Chewies* are designed to assist in seating ill-fitting aligners. (Dentsply Raintree Essix, Sarasota, FL).

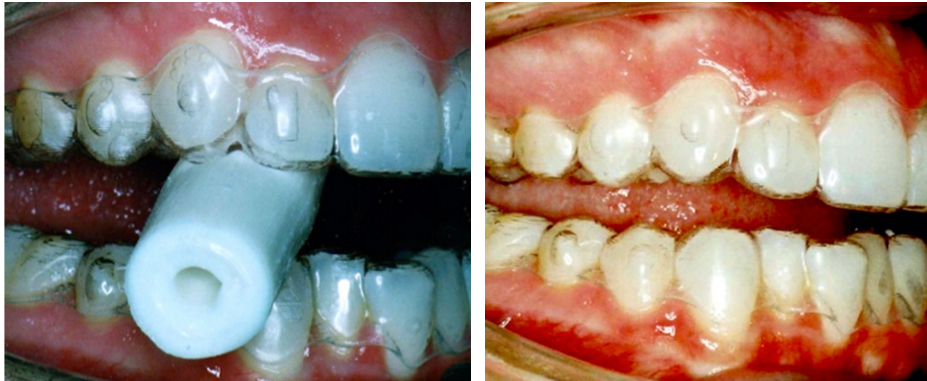


Figure 2 A,B. Chewies are used to reduce “lag” or “air-gaps” indicating the teeth are not “tracking” along with the aligners.

Another innovation was the introduction of a set of instruments designed specifically for individualization of a patient’s aligners. The Clear Collection* (Hu-Friedy, Chicago, IL) was specifically designed to customize aligners to enhance desired biomechanics, and to streamline the addition of individualized adjunctive forces during the course of treatment [30-32, 38, 39]. Specifics regarding these instruments have been detailed in previous publications, but examples are shown below (Figure 3).



Figure 3. The Clear Collection* (Hu-Friedy, Chicago) instruments were designed to individualize or customize aligners.

Lessons from the Invisalign Teen Research Team

The Invisalign Teen Study was initiated in 2008 with 4 practitioners treating 60 teen patients using clear aligners. The original ClinCheck set-ups were found to be problematic and significant refinements were required by nearly all. Data collection for the sample ended in 2010 as treatments were completed (and some patients also simply left the study). Results were published in 2009 and 2012 [40, 41]. Interestingly enough, the TEEN product was introduced to the market in 2009, prior to any collated and published conclusions. In other words, by the time answers were provided, no one much cared what the

questions originally were. Perhaps, the TEEN findings may have helped inform the necessity of innovations and improvements for aligners in general. The most important finding from the work: if aligners were consistently worn, then they did “something.” If not, then the patients got “nothing” at all and may have either moved on to traditional braces or just stopped treatment altogether.

Simple conclusions from the study include:

- 1) Compliance Indicators seemed limited to serving as a “policing tool,” but did not incentivize or motivate patient cooperation (Note: awareness of monitoring may not increase compliance) [42].
- 2) Torque Ridges worked, however, adding substantial amounts of torque to a digital set-up are required to see any effect.
- 3) Eruption tabs (for molars) were useless annoyances and were cut-off.
- 4) Eruption baskets for yet unerupted teeth were fine, but it may be advisable to simply wait until those few teeth erupt before starting treatment.
- 5) Surprisingly, most teens did wear the aligners, but those that didn’t received no improvement, and either were offered a braces alternative, or they elected to forego any orthodontic treatment. As was anticipated, compliance was still the coin of the realm and the best predictor of success.

IMPROVING PREDICTABILITY FOR CLASS II’S

To follow are some suggestions for improving the predictability of clear aligners by enhancing the application of the forces involved. In the early years, treating anything more than some crowding or spacing was frowned upon. Afterall, there seemed no mechanisms that could be applied to aligners to affect changes in antero-posterior (AP) or transverse dimensions. Furthermore, incisor torque, intrusion, and extrusion were not predicted to be successful. The more adventurous began to test those borders, but as noted previously, the predictability was not confidence-inducing. Some were disenchanted and others, challenged.

Class II malocclusions have been subjected to a diverse assortment of remedies for over 100 years. How would any of them be easily added to clear aligners? Phase I dentofacial orthopedics prior to plastic with headgear or functionals? We have recently seen the introduction of removable aligner versions of “MARA’s” and “TwinBlock’s” (the latter unfortunately lead us right back to an emphasis on compliance as king for the correction). There must be something else, especially, since none of these approaches are “growing mandibles.”

Sequential Molar Distalization

Some initial attempts at correcting Class II malocclusions involved two primary strategies. The first was simply applying Class II elastics to the aligners by: 1) bonding buttons onto the aligners themselves, 2) cutting notches into the aligners using rotary dental handpieces burs, 3) employing “ nail clippers” to cut slits in the plastic, or 4) prescribing cuts in the set-up (Figure 4) [18, 43, 44]. Ultimately, these options have been replaced with The Hole Punch* instrument from Hu-Friedy (Figure 5) that is used to create a “half-moon” shaped cut at the gingival margin of the aligners to permit the direct bonding of “button” to the tooth (e.g., mandibular first molar for Class II elastics) [30, 33, 40, 41]. Then the set-up software was occasionally programmed to provide a “bite jump” at some point in treatment, anticipating there had been some kind of positive change in growth differential between the jaws.

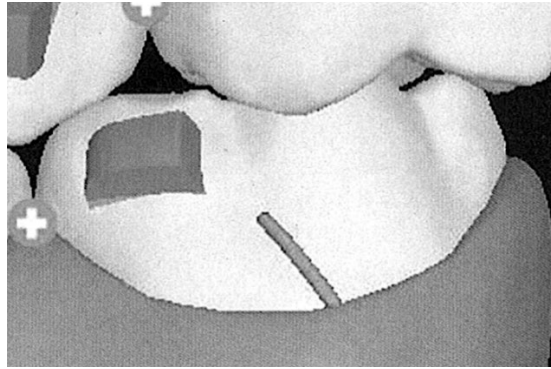


Figure 4. Notches at the gingival margin of the aligners can be used to add typical orthodontic elastics [44].

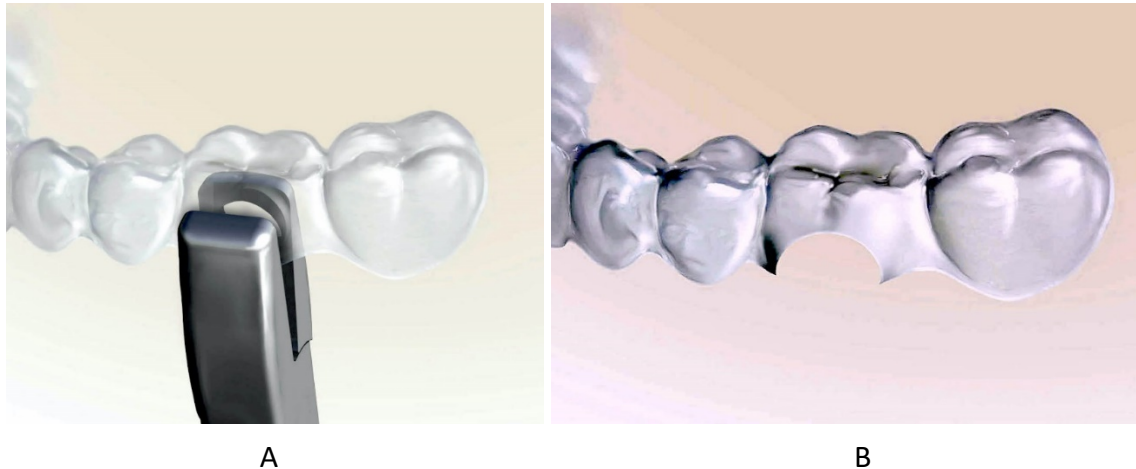


Figure 5 A,B. The Hole Punch instrument (Hu-Friedy, Chicago) is used to cut plastic in a semi-circle for the application of a bonded button for elastics.

A second option was designed to mimic typical maxillary molar distalization techniques that had proven successful with traditional orthodontic fixed braces featuring specialized appliances (e.g., Pendulum, Distal Jet, Jones Jig, etc.) [16, 45, 46]. Sequential maxillary molar distalization begins with a digital set-up to reflect pushing back each of the teeth in a posterior segment from 2nd molar forward [44]. The intent of producing a Class I occlusion in this scenario involves using the plastic to direct this sequence of individual tooth movement, based on the idea that there would be less “anchorage strain” (i.e., labial tipping of anterior teeth in response) due to the full-coverage “capping” of plastic. It became sorely obvious that something more was necessary to add to this equation--traditional Class II elastics would be required, just as had been employed in the “bite jump” alternative. Consequently, the posterior tooth movement was directed by plastic, but forced by Class II elastics (Figure 6) [47]. As an aside, Calvin S. Case provided clear provenance to his introduction of “Intermaxillary Force,” introducing elastics into orthodontics at least as early as 1904 [48]. This is in direct contradiction to Edward Angle who later, inappropriately coined the term, “Baker Anchorage.”

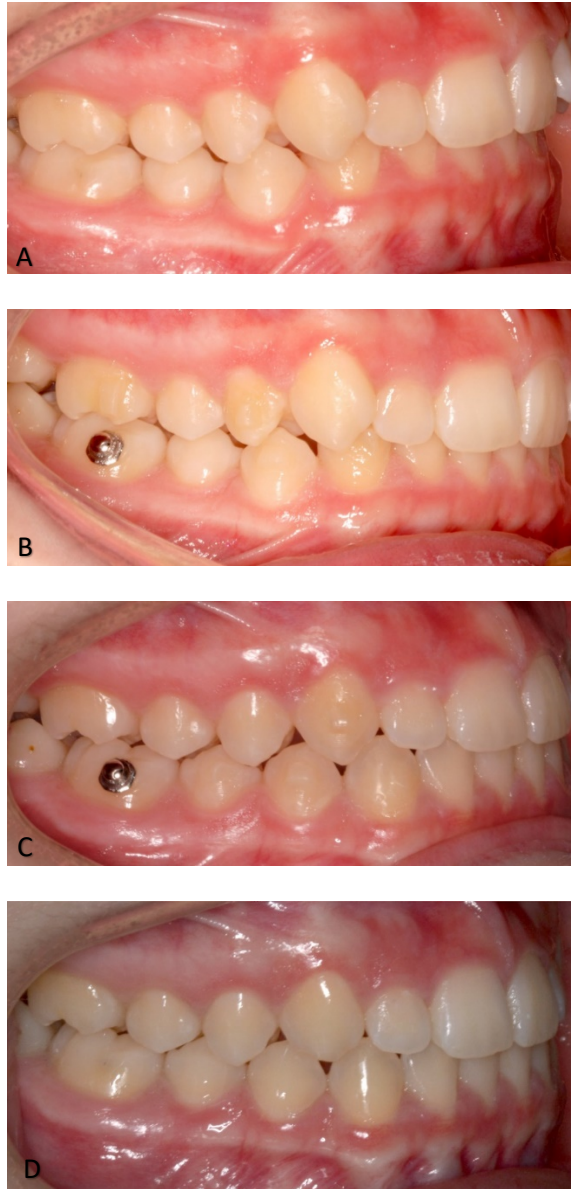


Figure 6 A-D. A,B. Teen female treated with sequential molar distalization, supported by Class II elastics connected to a bonded button on the lower first molar, and a notch at the mesio-gingival margin of the aligner at the upper cuspid. C,D. After achieving a “super” Class I molar relationship, spaces were closed with aligners.

How predictable was this scenario? Klein examined a sample of patients that had been treated using sequential molar distalization with elastic support and reported that the average amount of first molar distal movement was only about 1.4 (+/- 0.8) mm, $p < 0.001$ [49]. If combined with programmed 1st molar distal rotation around the palatal root (Figure 7), this might be enough to resolve mild ½ step Class II molars, obviously, dependent completely on wearing the aligners and the elastics. Ravera et al. followed-up with a multi-center retrospective and found slightly more (2.25 mm, $p < 0.27$) movement [40]. That is still significantly less than the amounts produced by “non-compliance” fixed distalizers [45, 51-53].

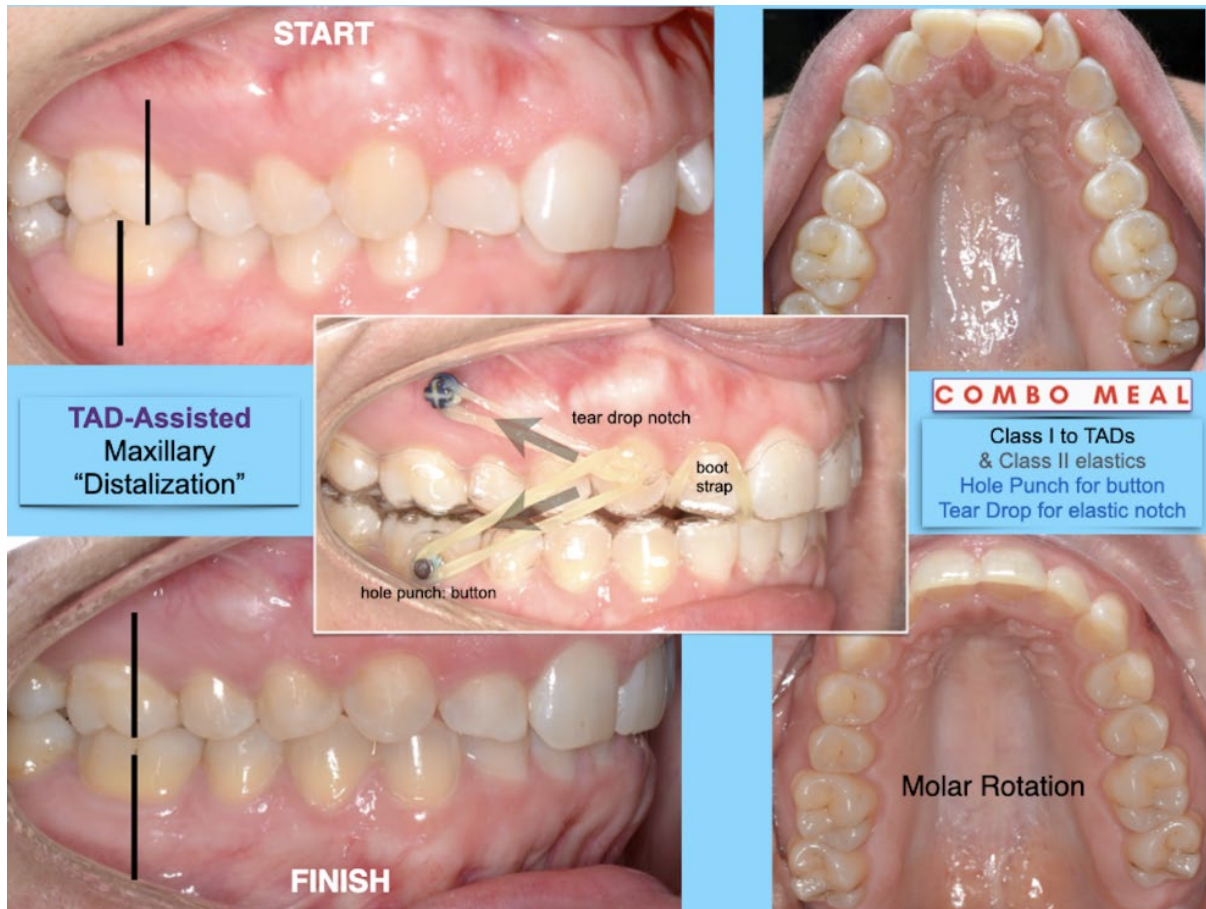


Figure 7. Adult female Class II treated using “TAD-assisted” sequential molar distalization, supported by Class I intramaxillary elastics from a miniscrew to a notch in the aligner at the maxillary cuspid combined with Class II intermaxillary elastics and distal rotation of the maxillary first molars.

Segmental Molar Distalization

If correction of Class IIs using full coverage aligners is limited in capacity to correct anything more than milder AP discrepancies, then resolution may need to involve some type of pre-aligner treatment. Perhaps, using fixed or removable functionals, distalizers, or headgear could be considered as prerequisites to initiating aligners.

The direct bonding of a section of orthodontic wire from maxillary molar to a helix cuspid hook could provide a means to connect Class II elastics (anchored by a lower lingual arch, braces, or even lower aligner), to move a segment of upper teeth distally. This very simple mechanical concept is employed by the Carriere distalizer (Figure 8). In the recent commercial environment focused on “airway-friendly concepts” (i.e., anything that might be considered “backward pushing” could be conceived as impinging upon the airway), this device was rebranded: “Motion,” although by any other name, these “bars” cannot independently move anything. Compliance with elastics is required and untoward side-effects include clockwise rotation of the occlusal plane as mandibular molar and marked maxillary canine extrusion can occur.

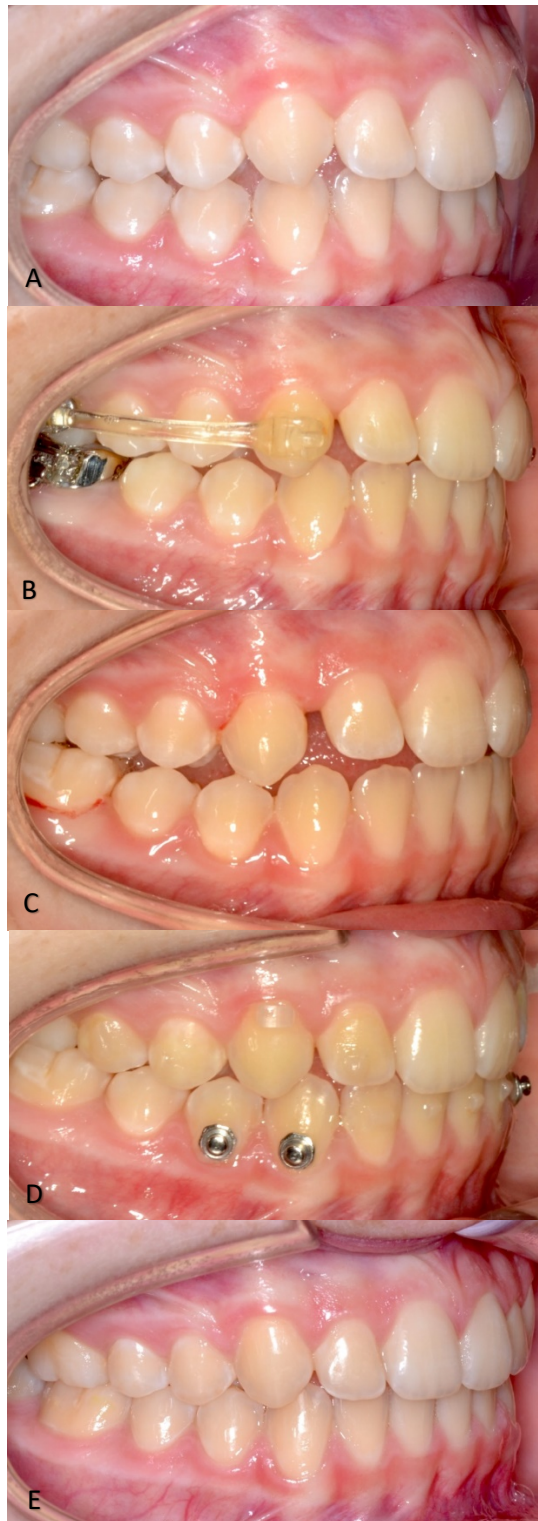


Figure 8 A-E. A,B. Teen female treated by first using distal movement of the posterior segment of maxillary teeth supported by a Carriere and Class II elastics to a lower lingual arch. C. "Super" Class I molar relationship was achieved. D,E This was followed by clear aligners, still supported by Class II elastics, and then finishing with Delta or Triangle elastics from bonded buttons on upper and lower cuspids and lower first premolars.

Although the claim of “Sagittal First” accompanies this product, it is again important to acknowledge provenance for the origins of this concept to Calvin S. Case. In his textbook in 1921, Case introduced “Span-Hooks” for the application of his Class II elastics to move posterior segments of teeth posteriorly [48]. Seems that there is nothing new under the Sun. Furthermore, claims of stimulating mandibular growth with these mechanics is no more accurate than for any other method of Class II correction.

For better or worse, all approaches for growing Class IIs affect the resolution by interrupting dentoalveolar compensation. Interestingly enough, the amount of mandibular response contributing to that correction is the same (give or take a silly 1 mm, if even measurable) among all interventions. It is a bit disheartening to consider that during the past four decades of our specialty we have been slogging it out with the supposition that numerous methods of holding mandibles in a forward position provided something extra beyond normal growth. In other words, we’ve wasted huge sums of money and time trying to find ways of “turning water into wine” (growing jaws) to no avail. That isn’t to say that Class IIs haven’t been corrected with functional approaches. Nevertheless, it certainly seems that while some were railing that the lower jaw was the “right jaw” to address, it slipped by most that the only “action”—the only place that orthodontics can make a difference—has been in the upper [53].

Adding a Spike in the Ice

The application of miniscrew temporary implants as anchorage for both indirect and direct mechanics have stimulated innovators to create new methods of orthodontic treatment (including with aligners) [30-36, 54-60]. Specifically, molar distalization within a Class II treatment became more predictable as reliance upon patient compliance with removable devices or headgear has diminished. The insertion of miniscrews in the buccal alveolus between upper 1st molar and 2nd premolar became a more common “post” to support so-called “Class I” intramaxillary elastic forces [30, 47, 61-63].

Traditional braces mechanisms for correction of Class II for either growing or adult individuals benefited from the use of constant forces from the screws to the dentition for retraction. That could take the form of sequential molar distalization, segmental movements, and even *en masse* retraction encompassing all of the upper dentition. For “growers,” the actual correction primarily involves the interruption of dentoalveolar compensation, while adults require actual distal dental movements.

It did not take much imagination to adapt miniscrews into the world of aligners, at least as far back as 2003 [61, 62]. Sinking anchor “posts” in the buccal alveolus as support for elastics or elastic chain improved the predictability of aligner-directed movement. Perhaps, this concept could be considered as a type of non-compliance “headgear” that can be employed during aligner wear. Taking it a step further, Class II intermaxillary elastics can also be combined with the Class I intramaxillary elastics to generate a net distalizing vector of force for the maxillary dentition—a “Combo Meal” approach (Figure 7, 9)

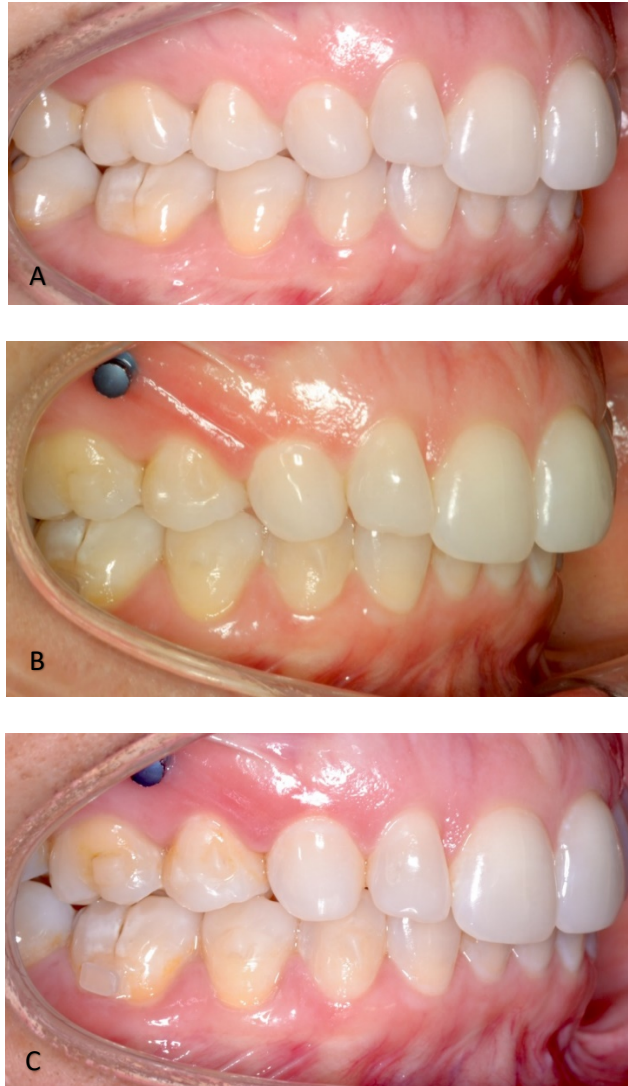


Figure 9 A-C. A,B Adult female with mild Class II and crowding, treated using aligners with a Class I elastic worn from a Tear Drop notch at the maxillary cuspid to a miniscrew inserted in the buccal alveolus between the 1st molar and 2nd premolar. C. Additionally, a typical Class II elastic was worn from the same cuspid to a button bonded on the mandibular 1st molar (plastic was cleared for the button using The Hole Punch instrument (Figure 5)).

Combo Meal Approach

When segmental distalization is desired in an aligner “precursor” scenario, using the “combo meal” concept of applying Class I elastic chain from the hook on the cuspid to the miniscrew, along with Class II elastics, may provide the best of both worlds (Figure 7). This concept encompasses using the cuspid hook on the Carriere device (or a homemade likeness) mentioned earlier (Figure 10). A light, constant force from the elastic chain reduces compliance concerns and also aids in counteracting some of the previously mentioned side-effects. Once the desired distal molar movement is achieved, then the transition to aligners is made to retract the remaining anterior teeth; supported still by the Class II elastics

and Class I elastics from the miniscrews. Better directional forces and predictability are the results in this permutation.

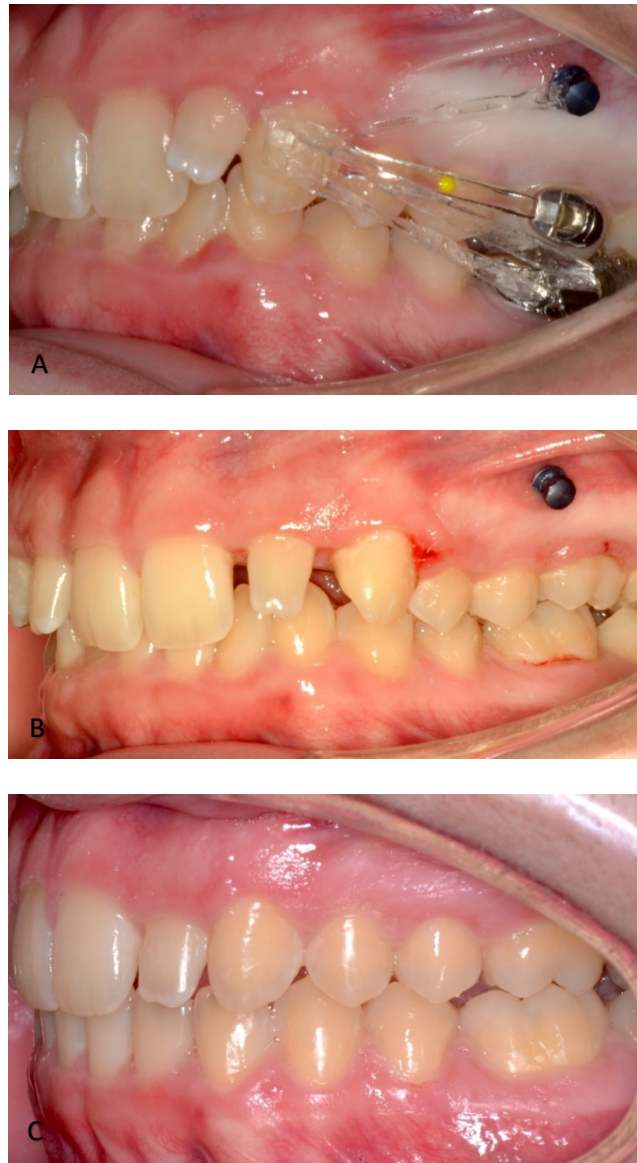

Figure 10 A-C. A. Class II Division 2 male with “peg” laterals treated using pre-aligner Carriere with elastic chain stretched to a miniscrew in the maxillary buccal alveolus along with Class II elastics. B. Upon producing a “super” Class I molar relationship, clear aligners were worn, still supported by elastics to the miniscrew and mandibular molars. C. Final results.

Modifications of Transpalatal Arches (TPAs)

Simple modifications of TPAs, combined with miniscrews, have been introduced as adjuncts to improve predictability for correction of some types of all three Angle Classes of malocclusions [34, 61, 62]. Specifically, the TPA- design permits the addition of simple forces to support retraction of segments of teeth and/or to produce *en masse* retraction for Class IIs. Miniscrews are inserted into the palatal alveolus

between the 2nd premolar and 1st molar, independent from the appliance framework. The TPA+ is used to protract posterior teeth and/or *en masse* protraction in mild Class IIIs. One additional “hook” is added at the mesial of the first molars and vertical intrusive forces can be combined with either TPA design to maintain vertical dimension and/or assist in closing anterior openbites by intrusion of the posterior teeth (Figure 11) [63]. With some inventiveness and ingenuity, these adjuncts can be employed prior to or during clear aligner treatments to improve predictability of mechanics.

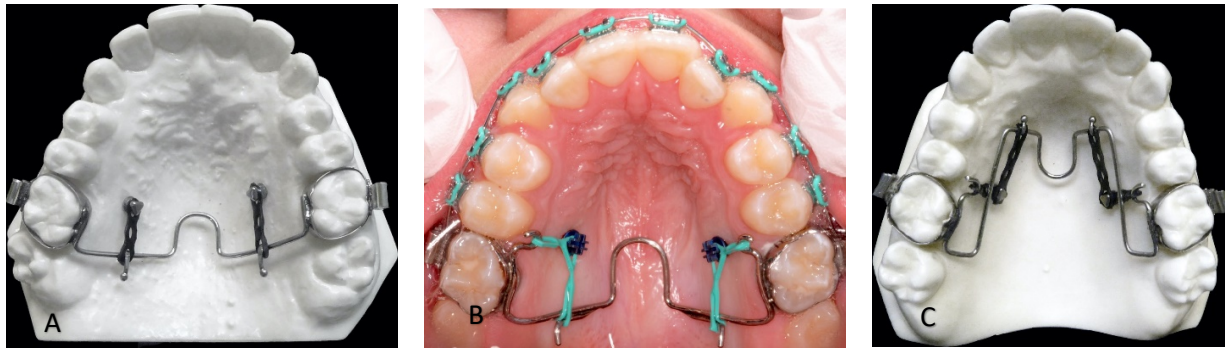


Figure 11 A-C. Simple modifications of transpalatal arches designed to employ miniscrews (inserted into the palatal alveolus) and elastic chain to direct forces for: A. The TPA+ for simple maxillary protraction for mild Class IIIs or instances of missing premolars or lateral incisors; B. Protraction can be combined with intrusion or either, alone, by orienting elastic chain appropriately; C. The TPA- for simple maxillary retraction and intrusion for mild Class IIs or either, alone, by applying elastic chain as necessitated. These TPAs can be used in conjunction with clear aligners or as precursors to plastic treatments.

More Comprehensive Miniscrew-Supported Distalization

The Horseshoe Jet, miniscrew-supported distalizer, offers an option for more difficult Class II situations (Figure 12) [46, 51, 64-67]. This appliance is housed in the maxillary palate where miniscrew insertions have shown to have less failure rates. Molars are pushed by open coil springs on a tracking “horseshoe-shaped” wire, anchored independently by the miniscrews. As there is no indirect anchorage from a palatal Nance or from supports on any teeth anterior the molars in question, no anchorage loss is possible. Distal movement can be accomplished prior to starting aligners or the upper aligners can be sectioned at the 2nd premolars and worn simultaneously. When a “Super-Class I” over-correction is achieved, the Horseshoe Jet is “locked” and becomes a miniscrew-supported holding arch for retraction of the remaining teeth.

The “abbreviated” upper aligners are then targeted for retraction, back to the miniscrew-anchored 1st molars, using Class I elastics or elastic chain to hooks or buttons at the cuspids. Once the upper spaces are closed and cuspids are now in Class I relationship, the Horseshoe Jet is removed for further finishing with aligners. It is important to note that the addition of miniscrews is merely to improve the predictability of the aligner treatment. It may seem obvious that the aligner treatments that involve the extraction of teeth would also significantly benefit from the addition of miniscrew anchorage during aligner therapy (Figure 13).

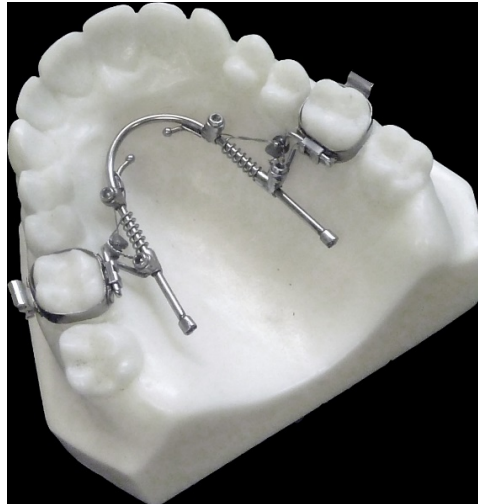

Figure 12. The Horseshoe Jet is a miniscrew-supported maxillary molar distalization appliance. Miniscrews, inserted in the palatal alveolus, provide anchorage for compressed coil springs to push molars posteriorly without any anchorage loss. In this arrangement, the miniscrews are locked-into any framework and can be checked for integrity or replaced easily with making a new appliance. After distalization is complete, the setscrews are tightened to stop further molar movement and the appliance now serves as a miniscrew-supported holding arch for subsequent retraction of the remaining teeth.

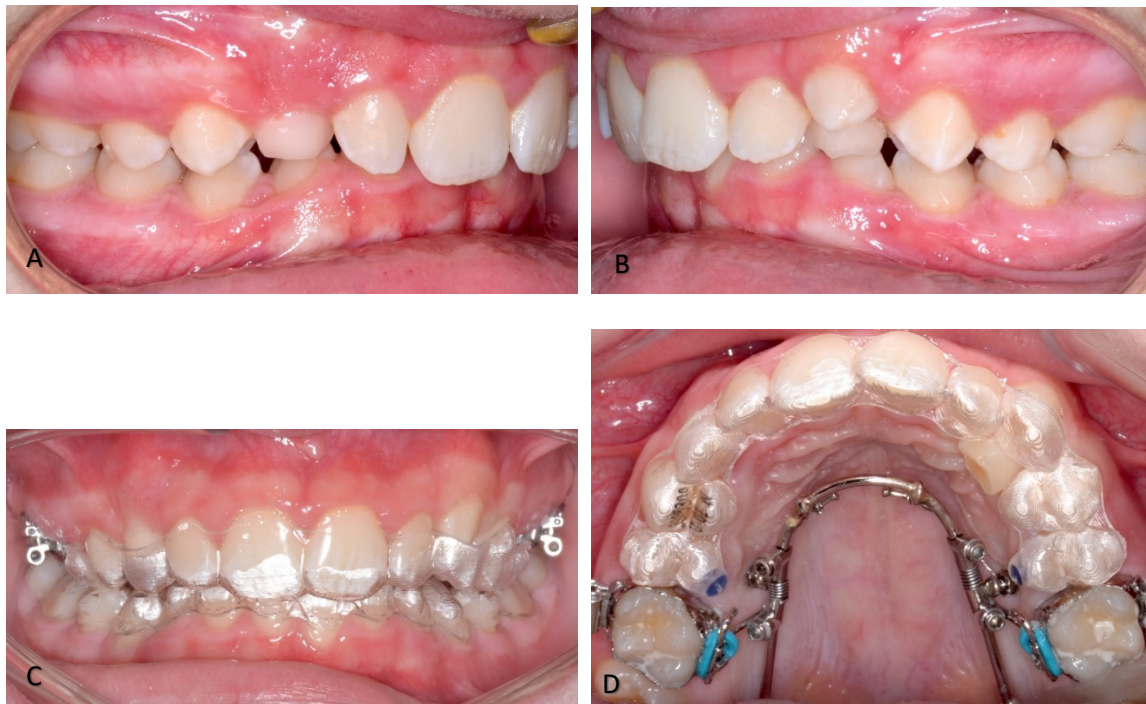

Figure 13 A,B,C,D. Male teen with Class II malocclusion started treatment with a The Horseshoe Jet simultaneously while initiating clear aligner treatment. The maxillary aligners were ended distal to the 2nd premolars to allow the molars to move posteriorly.

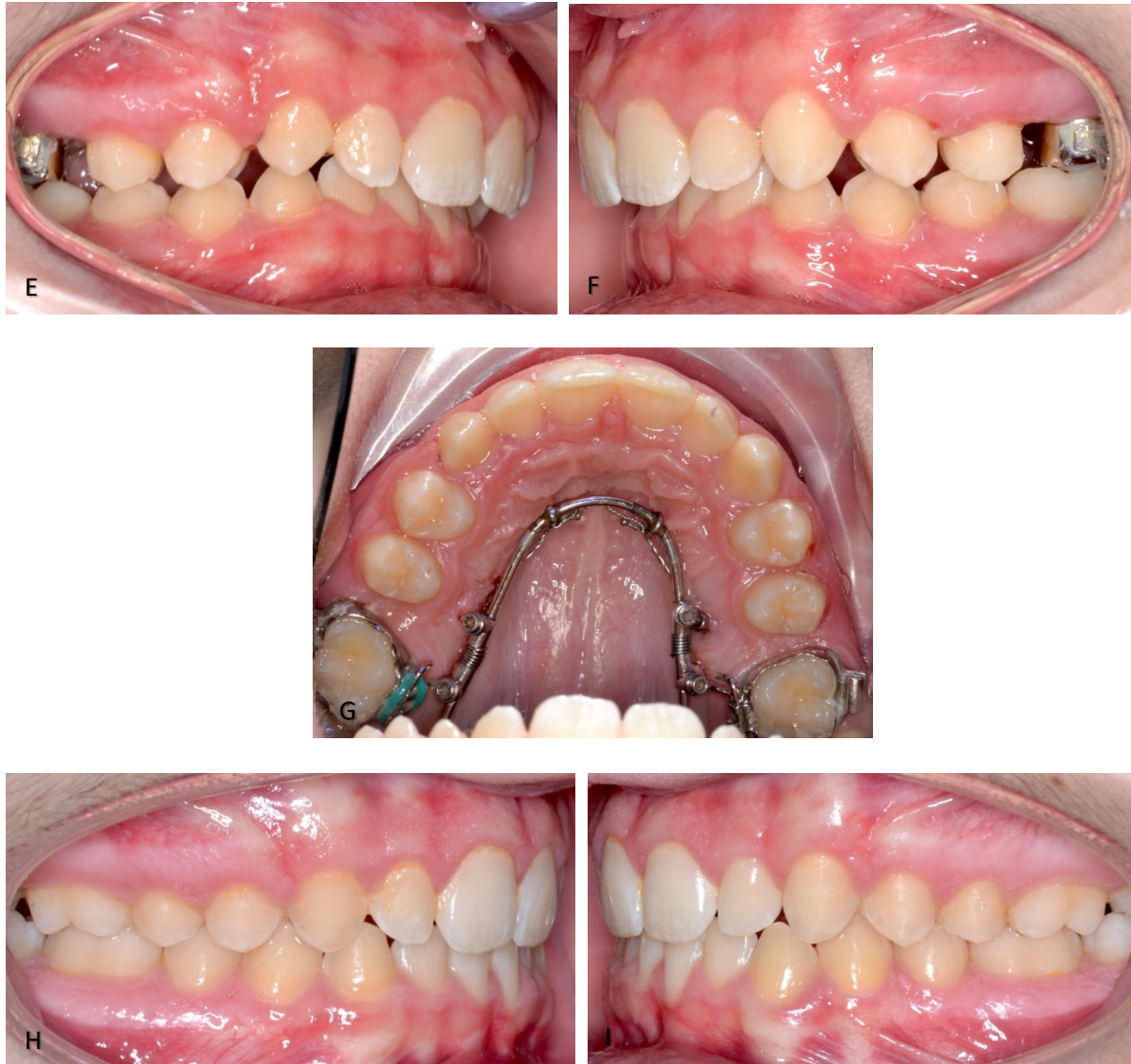

Figure 13 E,F,G,H, I. Upon achieving a Class I molar relationship, the Horseshoe Jet setscrews were locked in place and this miniscrew supported holding arch was used to apply Class I intramaxillary elastics from the molars to notches in the aligners at the cuspids. H, I. The remaining maxillary teeth were retracted en-masse with the aligners, then the appliance was removed, and typical Class II elastics were applied for finishing.

TOOTH MOVEMENT LAG

Dating back to the origins of aligners, there has been clear frustration associated with teeth simply not following the marching orders apportioned for specific movements by the software.^{31,34} What we predict in a digital set-up is often simply not translated [28, 68]. Perhaps, the most perplexing and disconcerting failures with plastic are found in the esthetic zone. The most common of these smile-apparent disappointments are rotations of cuspids and lateral incisors although rotations of lower premolars have also been described as unpredictable [2, 4, 8, 24, 69].

Another issue that seems to crop-up regularly during treatment is the visible lack of “tracking” or tooth movement “lag.” When teeth are lagging, the aligner features an airgap: a visible space between the plastic and the tooth or teeth [31]. Consequently, the tooth is no longer seated into the plastic “socket” where the crown is supposed to be positioned (Figure 14). Therefore, the tooth is not following the prescribed movement as dictated by the plastic trays. Even more disconcerting is when rotations and vertical issues are both lagging simultaneously, especially when it is noted by a disappointed patient. The creation of Aligner Chewies as a possible preventive measure (as noted previously) was a direct result of these common enigmas (Figure 1,2) [31, 37].

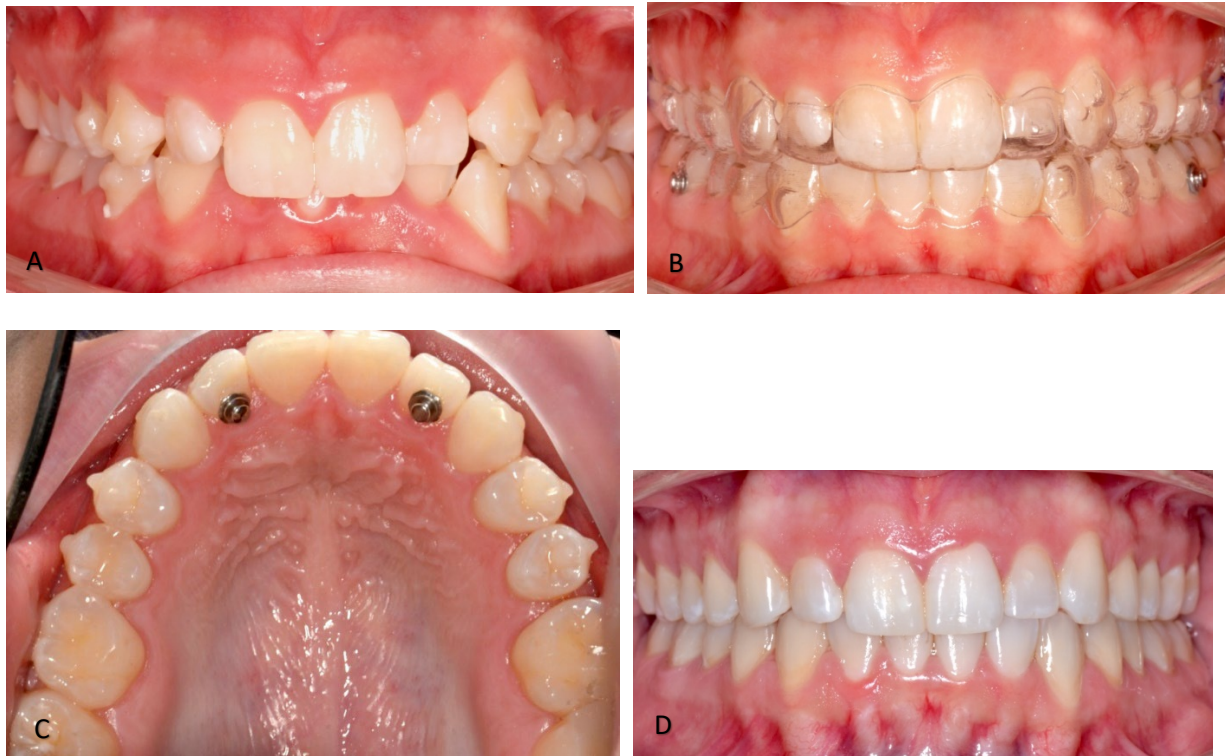

Figure 14 A-D. A,B. Aligner “lag” or loss of tracking is noted when a tooth is no longer seated into the aligner, resulting in an airgap between the tooth and the plastic. C,D. In this situation, elastics were used in a “bootstrap arrangement” of extrude laterals and intrude central incisors.

These irritating annoyances seem to appear out of nowhere with no rhyme nor reason, especially for maxillary lateral incisors. In this regard, Class II Division 2 upper lateral incisors are notorious offenders. They often are crowded, rotated, more apical than the centrals, and require substantial lingual root torque. That is one serious assemblage of complex tooth movements to expect to be modelled predictably with software.

Various remedies have been suggested to assist in correction of rotated or poorly tracking laterals, most often involving larger and more prominent composite attachments. The idea is to increase the contact real estate of plastic on the tooth by adding adhesive attachments; analogous to adding a bigger handle. Nicozisis has popularized the so-called “sash” attachment as one possible solution. A prominent beveled and rectangular block of composite is rotated on the face of the lateral to direct the desired movement (Figure 15). The appearance reminds one of a beauty pageant winner’s ribbon or sash [70]. A

further potential alternative involves the application of attachments on the lingual of the teeth in question [71].

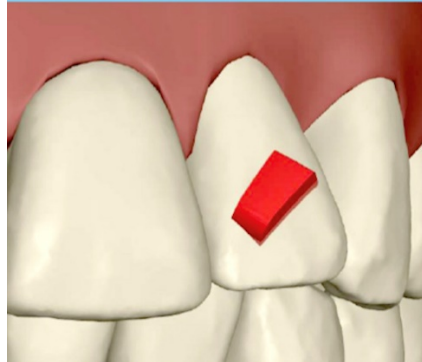


Figure 15. The “sash” attachment [70] to assist in rotating and/or extruding an incisor is prescribed as prominent, rectangular, gingivally-beveled and rotated on the tooth as desired.

Despite large attachments, loss of tracking is still a familiar occurrence [33]. Insufficient mesio-distal space for a particular rotated or lagging tooth is frequent but may not be readily identified as the source of failure (Figure 16). Operators are likely to simply expect that if the teeth are straight in the digital set-up that they will eventually just get to where they’re supposed to be. However, if there is not enough space, the tooth will never follow along and, in fact, will often begin to intrude.

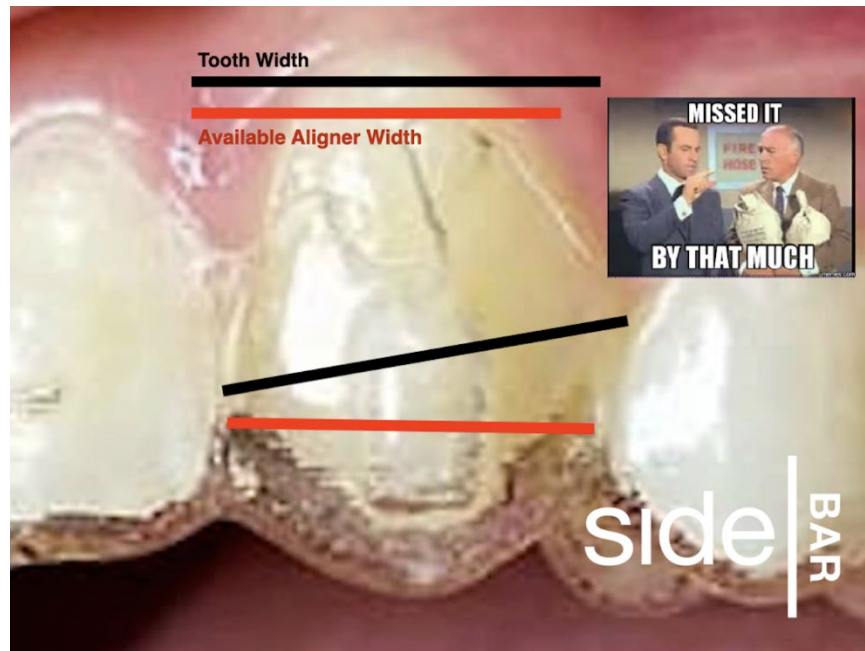


Figure 16. The maxillary cuspid is not “tracking” despite two large attachments. The issue is actually that there is insufficient space for the width dimension of the tooth to fit into the available aligner width. The cuspid is actually being “squeezed” apically by the adjacent lateral and 1st premolar. In other words, the situation cannot improve and will continue to worsen at least until space is created.

In the case of the lowly upper lateral, the two adjacent teeth (cuspid and central) are quite large in comparison. They also feature a rounded anatomy where they contact the lateral on the mesial and distal surface that tends to squeeze the lateral *apically*, often making the situation progressively worse. If space is not created in the set-up for the lateral, then it is unlikely that massive attachments will make much difference. Such is the fate of blade-shaped, short, and especially the microdont or “peg” lateral incisor (Figure 17). Recall that the predictability of both intrusion and especially extrusion of anterior teeth was found to be wanting [2,8,9]. Then, what is one to do when typical efforts have failed? Can we force the issue?

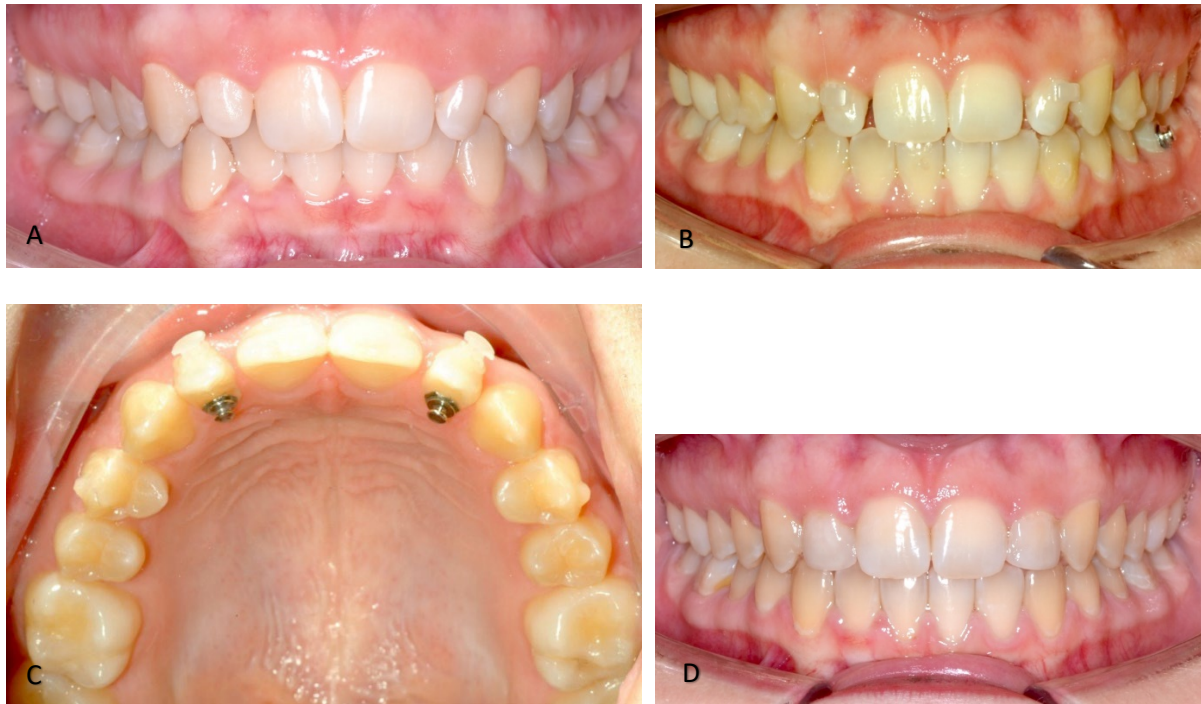

Figure 17 A-D. A. Late teen female with peg-shaped lateral incisors treated with aligners. B. Space was opened adjacent to the laterals for future composite restorations. C,D. So-called “boot-strap” elastics used to direct the eruption of the laterals and intrusion of the central incisors.

Bootstrapping Your Way to Success

When tooth movement has run “off the tracks,” are there means to easily salvage the situation with or without another “refinement” round of aligners (Figure 14)? The process of “refinement” involves new impressions/scans >> new set-up >> more aligners fabricated—not a very efficient process if multiple repetitions are required. In response, a “bail-out” option of adding orthodontic elastics to direct the movement of a specific tooth was developed. Tear drop-shaped notches are cut into the plastic (Figure 18) using The Tear Drop* (Hu-Friedy) at the mesial and distal gingival embrasures to permit the lodging of a small elastic prior to seating the trays in the mouth [30, 31, 38, 39]. On the lingual of the lateral, a bondable “button” is placed near the gingival margin and the plastic on the lingual is cleared (using The Hole Punch instrument)(Figure 5,19) to provide sufficient space for that button (and the tooth) to be slowly pulled incisally [30, 31, 38, 39].

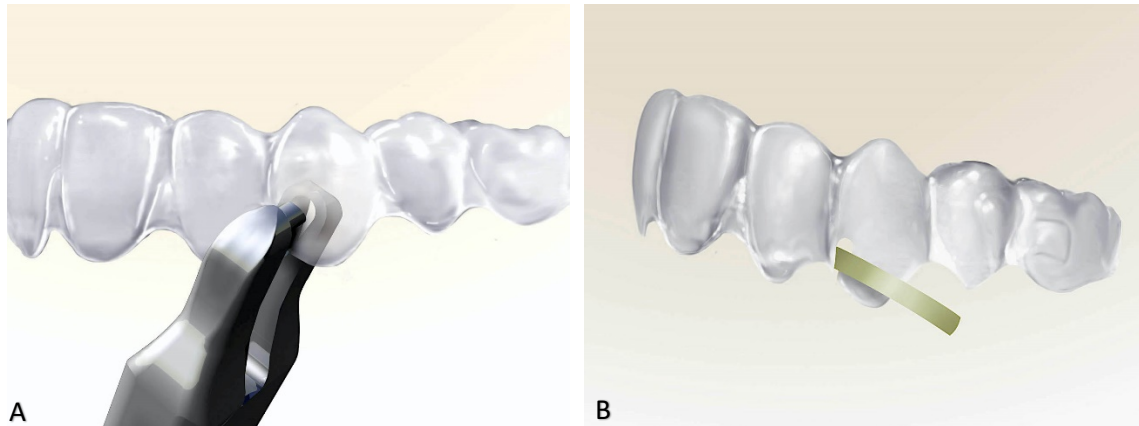


Figure 18 A,B. The Tear Drop instrument (Hu-Friedy, Chicago) is used to cut a tear-drop shaped reservoir at the gingival margin on an aligner to hold an orthodontic elastic in place prior to seating the tray.

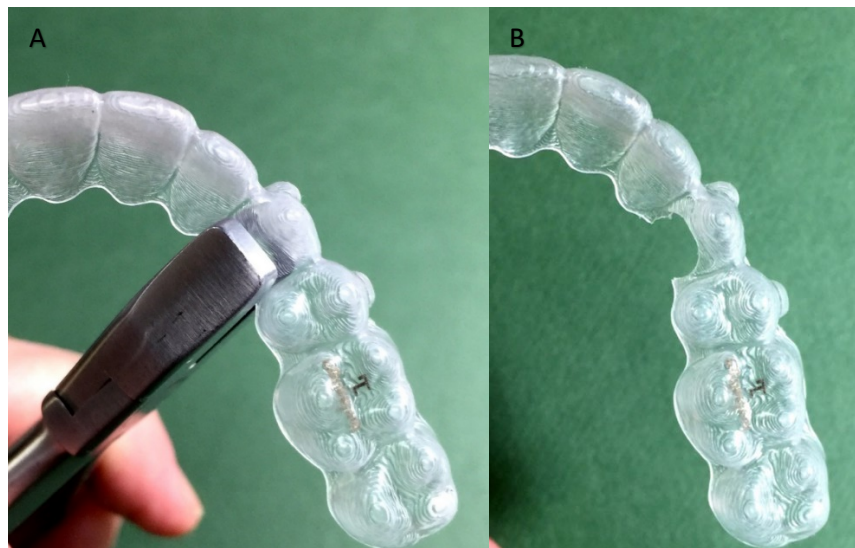


Figure 19 A,B. The Hole Punch instrument is used to cut plastic clearance for a bonded button on the lingual of the tooth to be “erupted.”

After the tray/elastic combination is inserted in the mouth, the elastic is pulled around-and-over the aligner tray to the button (Figure 14,20,21). Another option is to place an esthetic bonded button on the facial of the lateral with plastic clearance for a button-to-button elastic stretched over the tray (Figure 22). The elastic then provides the extrusive force to the stubborn tooth, seating it into the tray; analogous to using the small straps on boots to seat footwear; hence, the name “bootstrapping.” Also keep in mind that the counteracting force on the adjacent teeth may also be used to direct their intrusion if desired.

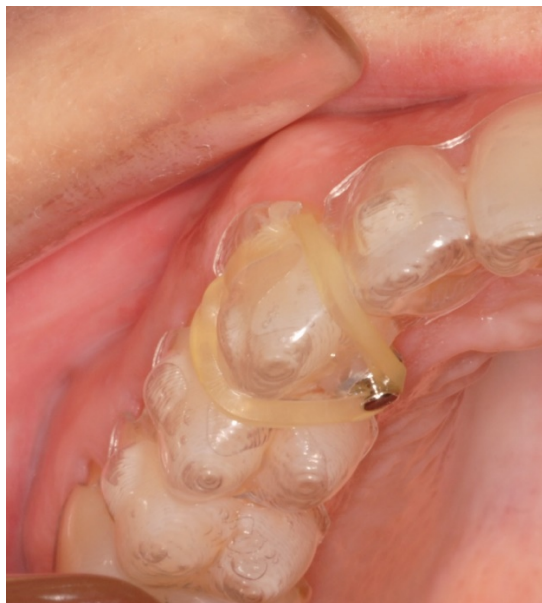

Figure 20. To enhance the movement of a “lagging” tooth, an elastic is applied to “tear-drop shaped notches” at the aligner margin and draped over the plastic to a button on the lingual of the affected tooth.

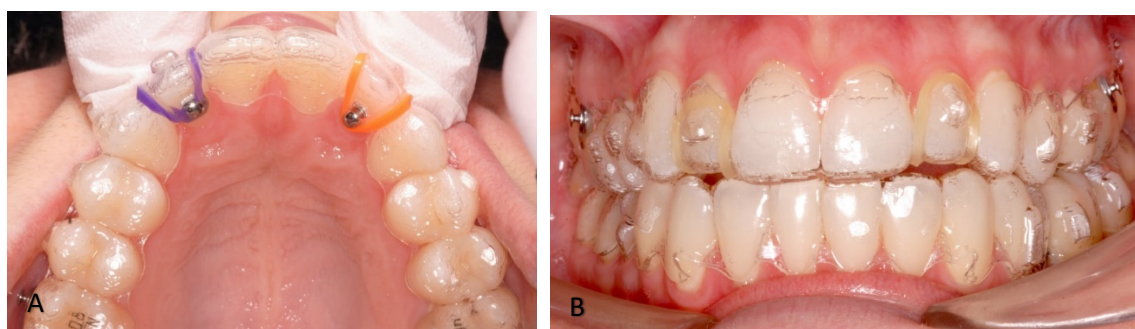


Figure 21 A,B. Lagging maxillary lateral incisors were forcibly erupted using “bootstrap” elastics. Tear drop cuts were made at the mesial and distal gingival embrasures of the labial of both incisors and an elastic is retained in the notches. After the aligner is seated, then the elastic is stretched over the tray to connect to buttons bonded on the lingual of the teeth.

Taking this concept one step beyond, more than just as a rescue mission when a tooth isn't tracking, consider that the direction of eruption and/or rotation of a specific tooth might be more predictable if bootstrapping were initiated from the beginning. In this situation, the final position of the tooth in question (e.g., rotation, eruption, and torque) needs to be incorporated into the digital set-up to appear potentially with the first few aligners in a series. In other words, written direction to the technician (or manipulating the software) will result in a tooth or teeth that appear out of position in the set-up. The first aligner in the series will look odd and suspect in fit for the tooth in question. Bootstrapping begins immediately during the aligner series and the elastics facilitate a more predictable response (Figure 23).

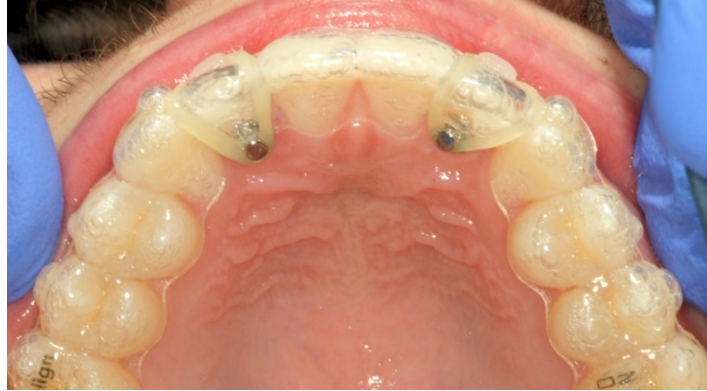

Figure 22. “Button-to-button.” An alternative to the “tear-drop cuts to button” bootstrap is to stretch an elastic over the aligner from an esthetic button, bonded near the facial gingiva, to another button at the gingival margin on the lingual.

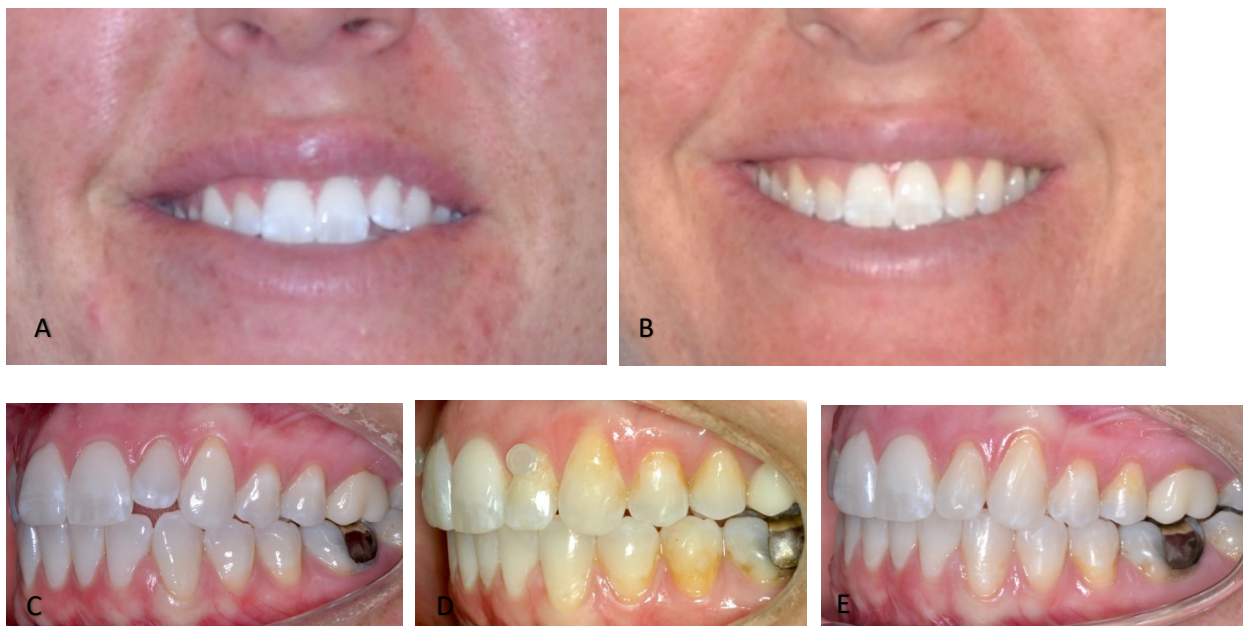

Figure 23 A-E. A,B. An adult female with chief complaint of the position of the lateral incisors. C. Esthetic buttons were bonded on the facial, near the gingival margin, of each tooth. Buttons were also placed on the lingual of the incisors as well. The digital set-up prescribed that the incisors be erupted by 0.25 mm past the incisal edges of the central incisors starting at Stage 1. In other words, the “air gap” was purposefully created as space to direct the eruption the laterals using “button-to-button” bootstrap elastics. D,E. Final results.

A most important concept when creating a software 3D set-up is that of incorporating “overcorrection.” Considering the errors involved in creating aligners, the levels of manufacturing tolerances, and flexibility of the plastic, it may be contended that no correction can occur without built-in overcorrection [25]. For instance, to achieve corrected rotation of any tooth, asking for at least 2-3° of over-rotation may be necessary. Resolving a midline deviation may necessitate over-correction by a

millimeter, and so forth. The Horizontal and The Vertical are also instruments* (Hu-Friedy) to individualize each aligner by placing indents to accent desired movements (Figure 24) [30, 31, 38, 39].

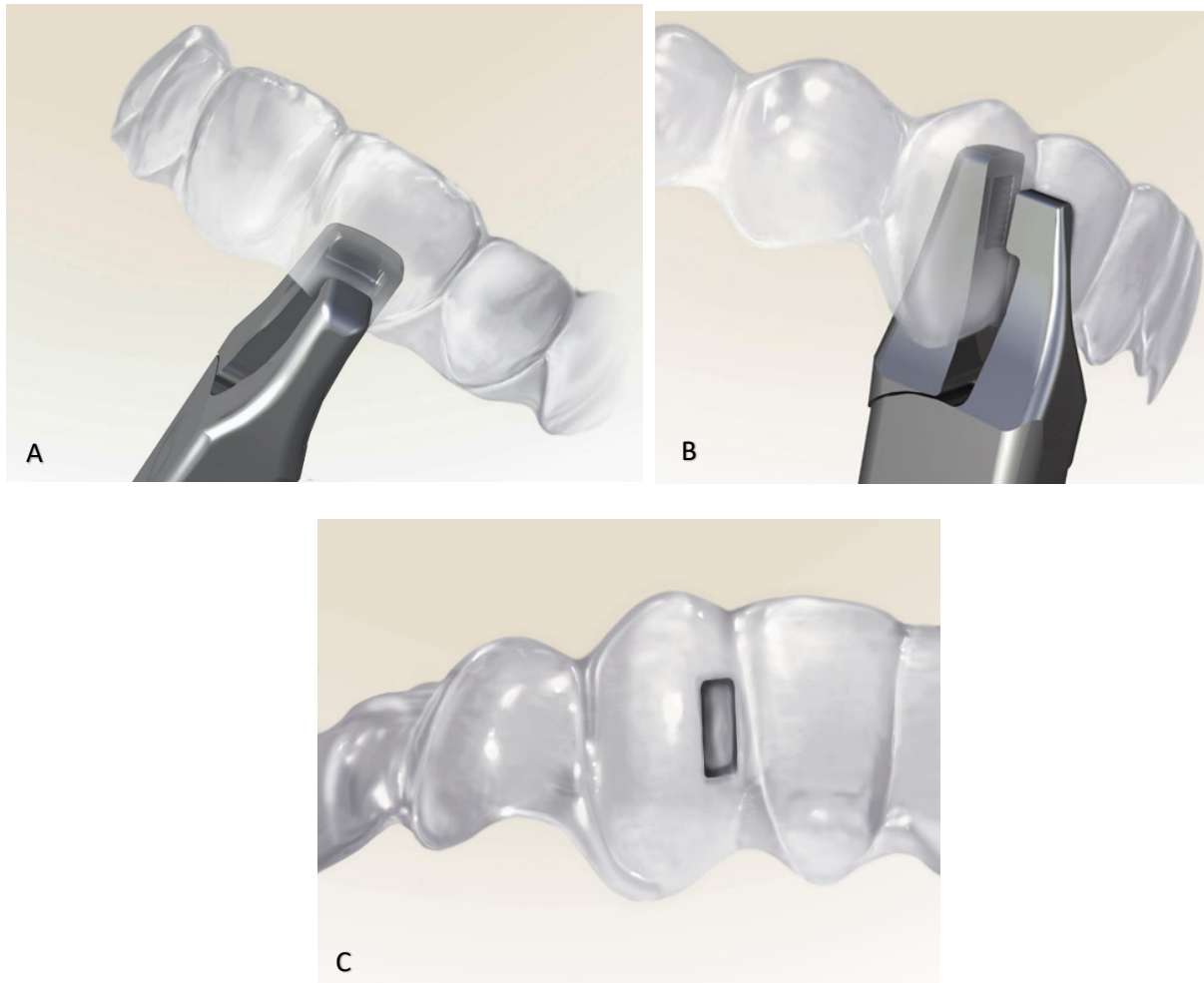


Figure 24 A-C. A. The Horizontal instrument is designed to add indents to the aligner plastic to produce root rotation (i.e., torque) or increase retention of an aligner or clear retainer if used in the posterior. B. The Vertical pliers may be employed to add accent indents in the plastic to generate rotational couples.

SLINGING THE OPENBITE

It has been advocated that anterior openbites might be better resolved with aligners [72-74]. Historically, caution has been advised for closing anterior openbites by extrusion of anterior teeth as possibly an invitation to relapse. Often, it would be more desirable to produce intrusion of posterior teeth to affect a clockwise rotation of the mandibular plane instead. Considering Newton's 3rd law, is it reasonable to expect that plastic on the back teeth will intrude them in deference to the anteriors? If we're looking for a predictable result, that doesn't simply depend upon incisor extrusion, it seems that miniscrew-supported "elastic slings" look to be indispensable (Figure 25).

A "sling" elastic is draped around the maxillary aligner from a miniscrew, inserted in the palatal alveolus, over to one in the buccal alveolus [31, 34].^{31,34} The posterior teeth are directed for intrusion in

the digital set-up and the sling elastic produces the intrusive force. If a mandibular sling is needed, then miniscrews are placed in the buccal alveolus. A button is bonded on the lingual of the 1st molars and the elastic is stretched from the button over the aligner to the buccal miniscrew (Figure 25). The digital set-up must reflect the desired intrusion, but the sling elastics force the issue.

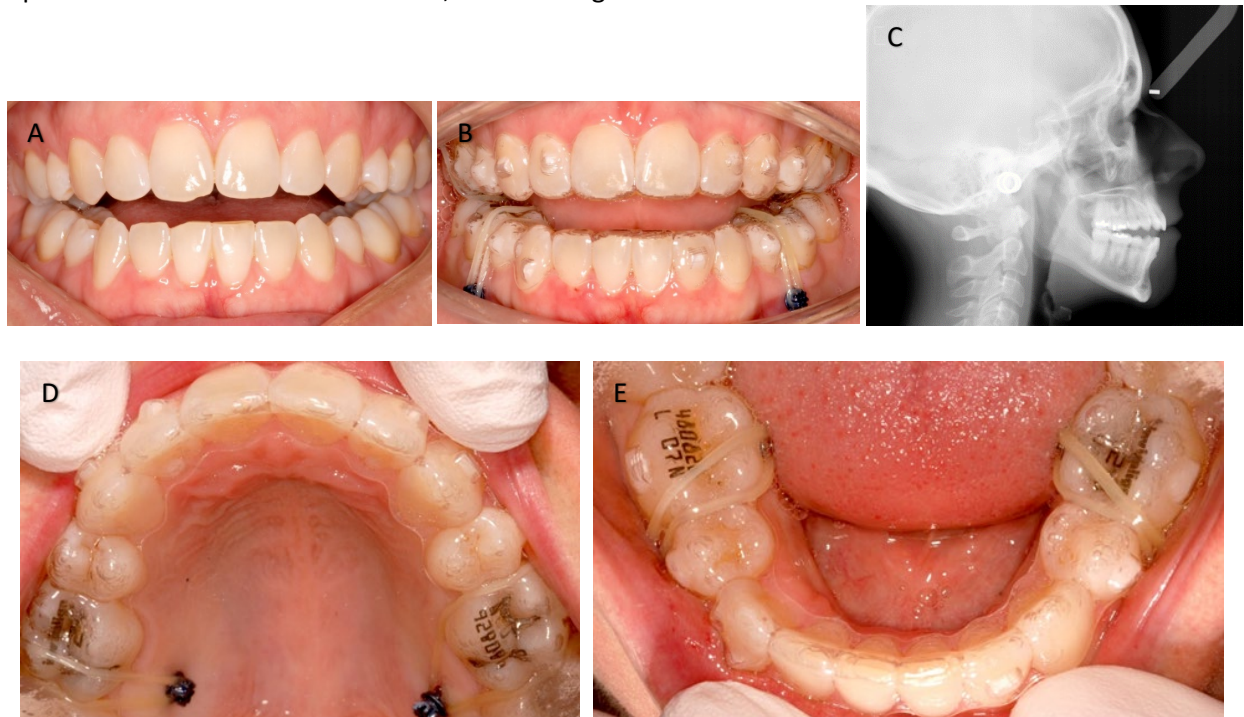


Figure 25. A-E. Adult female with anterior open treated with clear aligners enhanced with miniscrews and elastics in a “sling” arrangement. Miniscrews were placed into the maxillary dentoalveolus on both the buccal and palatal and elastics were worn across the aligners from one anchor to the other to generate posterior intrusion. Miniscrews were also placed in the buccal alveolus in mandible and buttons were bonded on the lingual of the 1st molars. Elastics were “slung” from the buttons to the miniscrews to assist with aligner-directed intrusion.

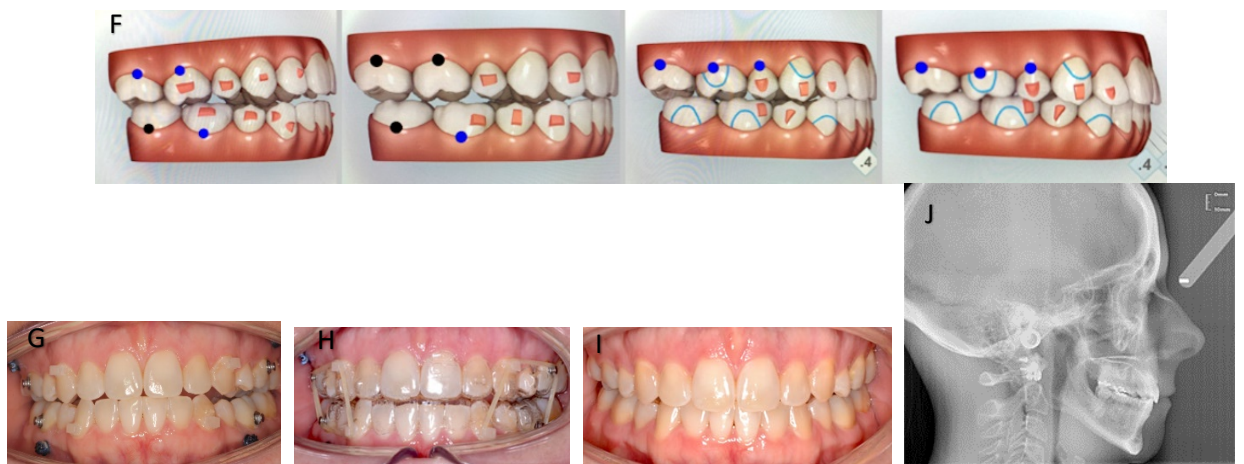

Figure 25. F-J. Programmed posterior intrusion was accompanied by counterclockwise mandibular rotation to aid in closure of the anterior openbite.

Recall, however, that there are circumstances where some anterior extrusion is still appropriate, especially in situations of reverse smile lines (Figure 26).

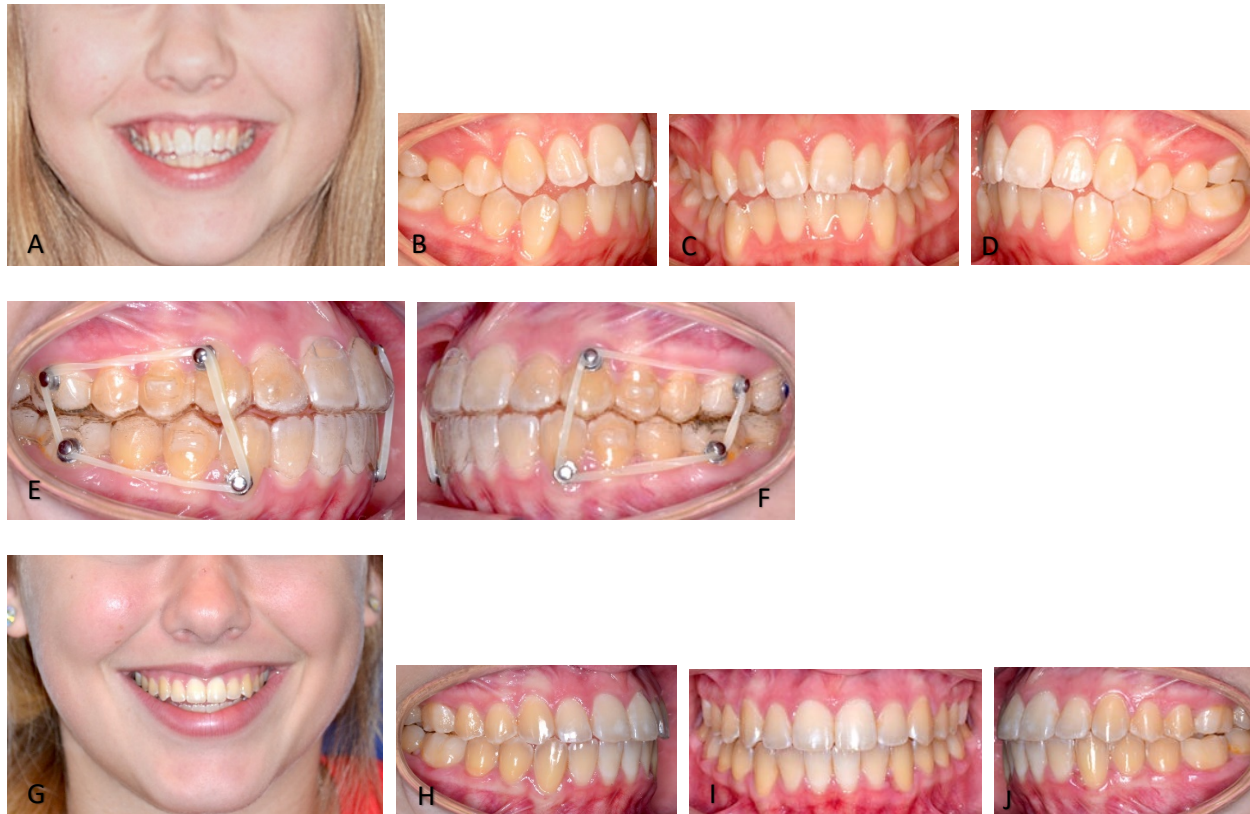

Figure 26 A-J. A-D. Teen patient with mild anterior openbite and reverse smile line. Class III elastics maintained a positive overjet. E-J. Intermaxillary “rectangular” seating elastics to finalize the result.

BACK BITE, BITES BACK

If one is more resolved to create results with aligners equivalent to those with braces, then just aligning the social six is insufficient. Self-examination can be difficult and time consuming such as when preparing case presentations for the American Board of Orthodontics, Angle Society, a study club, or for an audience of your peers. However, there is nothing more instructive than reviewing your own work as you may likely be much more critical and will improve your diagnostic acumen and treatment results. When evaluating aligner results, esthetics are obvious. More revealing than considering the fit of the posterior teeth in a buccal view is also taking a peek from the “tongue side.”

Posterior openbites occasionally appear when there were none. Is it simply the effect of having two thin pieces of plastics sandwiched between the molars for months on end? Is it a kind of “Gelb” splint effect that intrudes the back teeth while the others might be erupting? Or is it incomplete leveling of the Curve of Spee when anterior teeth actually need substantially more intrusion to permit posteriors to touch? If any of these are determined to be the cause, what is to be done to correct this issue or, better yet, prevent it for future patients.

When leveling with braces, not only are anterior teeth intruded, but posterior teeth are often extruded at the same time to maintain occlusion. The same can be designed for aligners. Certainly, incomplete incisor intrusion when leveling the Curve of Spee may be a factor; however, if some positive overjet has not been simultaneously produced for adequate clearance of incisors, then inappropriate contact on anterior teeth will still be present.

Incisor root “torque” is difficult to produce with aligners with reliability due to the flexibility of the plastic in creating a consistent rotational couple. For one thing, the forces involved have a tendency to push the aligner incisally (Figure 27) [75]. A secondary issue was also discovered during the Invisalign Teen Study when examining the effects of “torque ridges” [40, 41]. As more torque was added into the diagnostic set-ups, posterior openbites were observed clinically, especially at the maxillary first molars (Figure 28 A). When considering the forces involved, a distolingual rotational force is applied to the incisor roots, resulting in a resisting force at the distal of the first molars; pushing them anteriorly. In this manner, the molar is squeezed mesially and it tends to tip and intrude mesially; tipping and lifting out of the aligner. The effect mimics additional Stolerization (mesial crown tip and more prominence for the distal of the tooth)(Figure 28 B). Applying a large attachment on the first molars may assist in limiting this type of disconcerting “openbite”; however, if anterior torque is treatment planned, then it may be more predictable to add mesial root tip and/or extrusion of the mesio-buccal cusps of the first molars from the start.

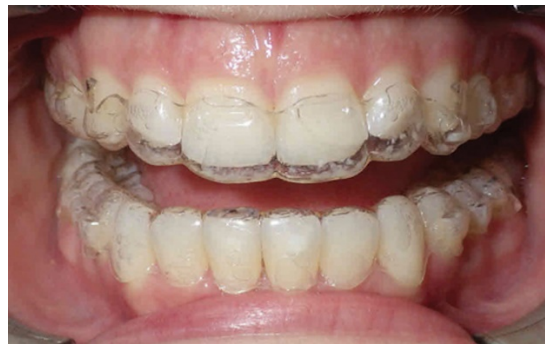

Figure 27. The application of significant maxillary anterior root rotation (i.e., torque) with “torque ridges” may produce the unintended side effect of pushing the aligner incisally; thereby, mimicking “lag.”

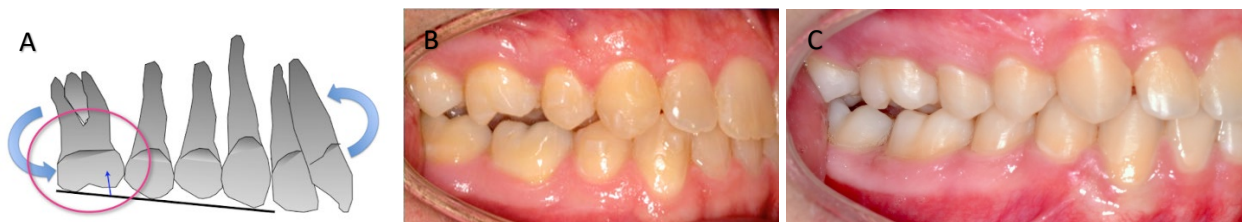

Figure 28 A-C. Maxillary anterior torque application may cause an untoward intrusion and tipping of the first molars in reaction.

When critically evaluating posterior openbites, it is important to note the Curve of Wilson, especially if any maxillary expansion has been produced [76-78]. Often the palatal cusps of the molars and perhaps premolars may be more prominent (or “hanging”), causing the appearance of an openbite

(Figure 29, 30). Adding buccal root torque for posterior teeth during treatment may reduce this common error that is also found with braces as well. Marshall et al. stated, “For proper occlusion, there should be no significant difference between the heights of the buccal and lingual cusps of molars and premolars” [76]. Adding some mild intrusion for second molars may also be necessary to close midarch openbites (Figure 28 C). Finally, aligners can be sectioned distal to cuspids to allow for some settling as well to close posterior openbites.

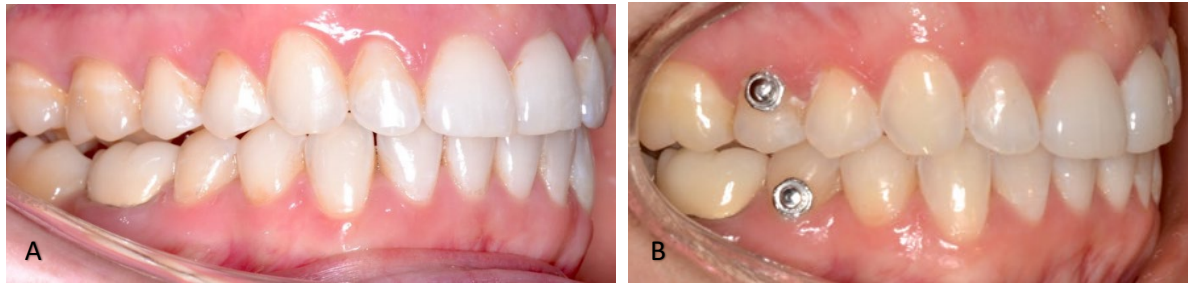


Figure 29 A,B. A. Appearance of a posterior “openbite” marring clear aligner finishing. Inattention to maxillary posterior buccal root torque is the culprit. B. Added posterior torque in refinement with intermaxillary elastics resolved an issue that could have been easily avoided by prior planning.

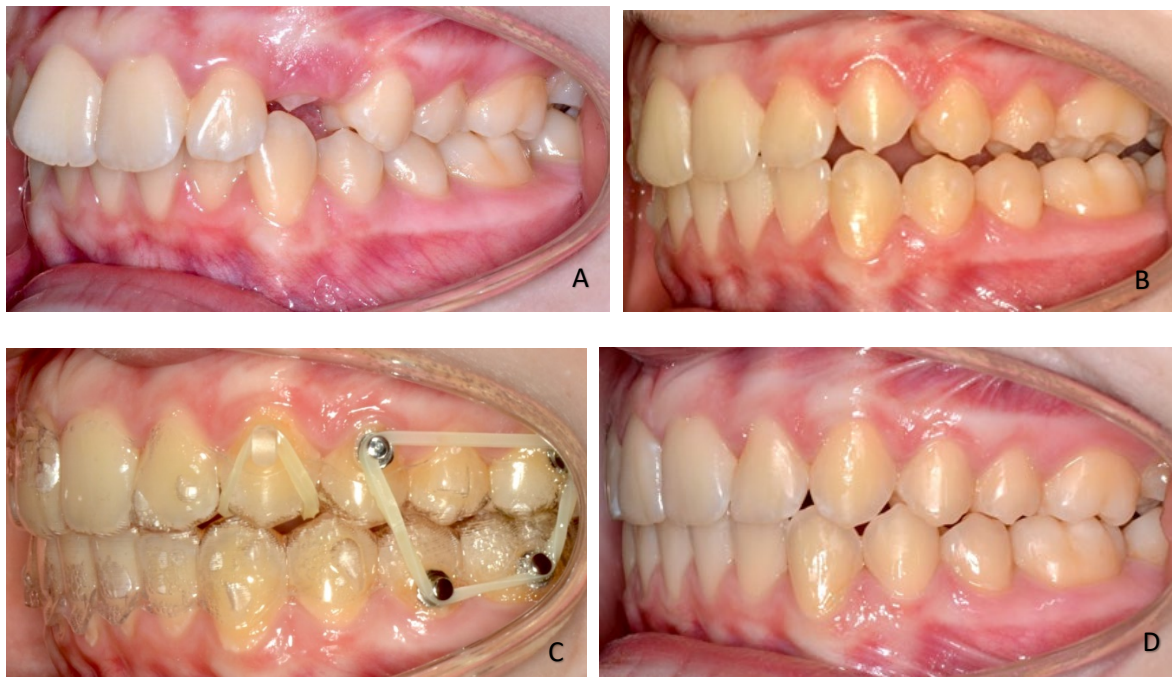

Figure 30 A,B,C,D. A troublesome openbite developed during clear aligner treatment. Adding significant buccal root torque and intermaxillary elastics ultimately resolved the situation.

Another extremely useful solution is the use of “seating” intermaxillary elastics, arrayed in a variety of configurations—just like with braces—in combination with the set-up changes noted above (Figure 27-30). Finally, the intensive use of a custom tooth positioner may be employed as a finishing device [79, 80].

LIMITED TREATMENT & RETENTION ALTERNATIVE

Innumerable strategies and appliances for retention of orthodontic results have populated our literature throughout our history. Recently, Littlewood et al. completed a Cochran Collaboration summarizing much of the information and then offering some best-practices advice [81]. Popular options today include removable (Hawley-type or clear aligner style) and fixed (bonded wires on the lingual of the anterior teeth) retainers.

Although the concept of having “permanent” retention appears to be most appealing, there are many concerns with long-term responsibility and liability, difficulty in maintenance and cleaning, diet restrictions to reduce breakage (there have been reports of swallowing fractured retainers), and also some risks for iatrogenic tooth movement and gingival loss. Survival of bonded retainers has been a primary concern with perhaps 20% failure in the mandible and 50% for the maxilla [82, 83].

A recent modification of the “spring retainer” concept has been recently introduced. The Revolution Spring (Apex Ortho Innovations, Fuquay-Varina, NC)(Figure 31-33,35) features labial and lingual bows that are fabricated from Beta Titanium wire that is flat along the surfaces of the anterior teeth [84, 85]. As there is no acrylic applied over those bows, they are smoother, less bulky (lower profile), and less likely to affect speech than the typical spring retainer. More importantly, these bows can be easily adjusted to accent 1st Order movements using a Quadra-Z pliers (Apex Ortho Innovations)(Figure 34,35). This instrument was designed specifically to avoid fracturing the brittle Beta Titanium.

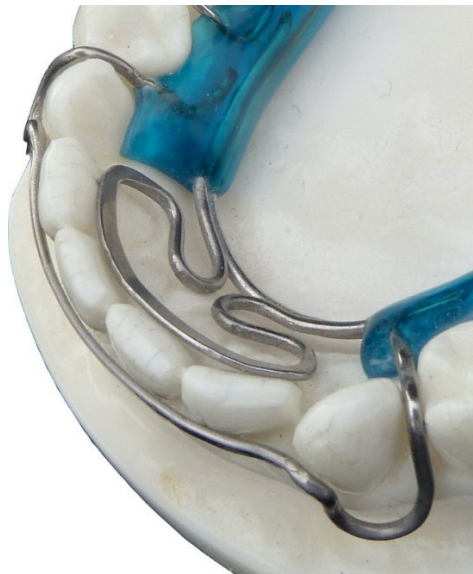

Figure 31. The Revolution Spring appliance was designed as both a retainer and for minor tooth movement issues. “Flat” Beta Titanium bows can be adjusted and yet has better resiliency than stainless steel. There is no acrylic over the wires found in most spring retainers, so there is less bulk or speech concerns.

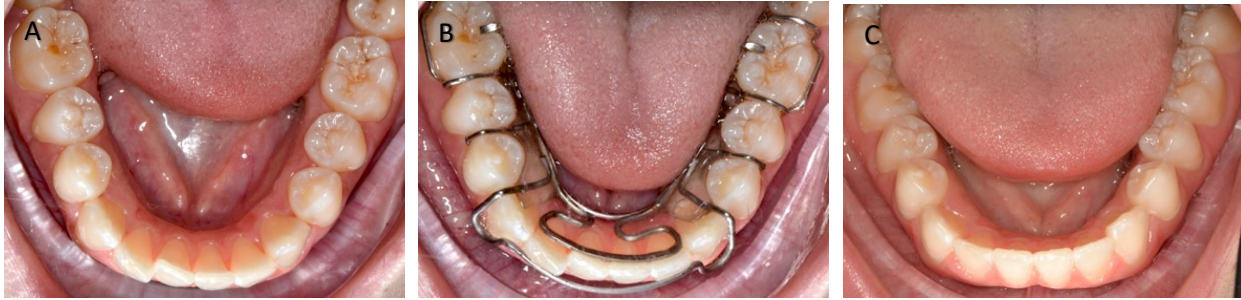

Figure 32 A-C. Correction of mandibular crowding and rotations wearing the Revolution Spring full-time for 4 months.

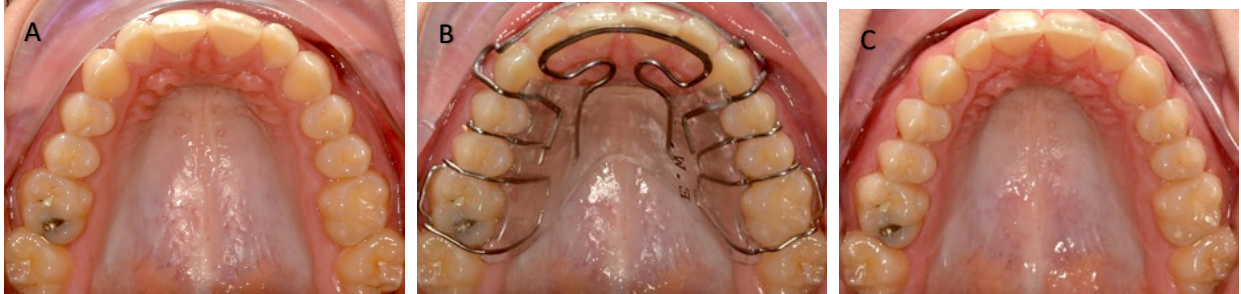

Figure 33 A-C. Correction of maxillary crowding and rotations treated with the Revolution Spring in 1 month.

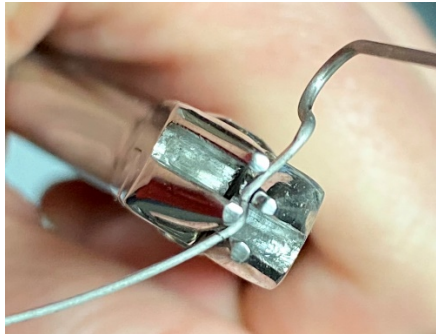


Figure 34. The Quadra-Z pliers (Apex Ortho Innovations) were designed to produce 1st Order bends into the brittle Beta-Titanium bows of the Revolution Spring to accent and individualize minor tooth movement without wire fracture.

The Revolution Spring appliance serves multiple purposes. First, it may be a more reliable alternative to traditional Hawley or spring retainers as the forces from activated Beta Titanium are less prone to dissipate or fatigue over time. Second, if any minor tooth movement is detected, the patient can often correct it themselves by simply wearing the device full-time again. Third, if minor tooth movement is treatment planned, even for new patients, this appliance may serve as a more predictable, rapid, and economical alternative. If a fixed retainer fractures or is dislodged, the patient may not be aware until adverse tooth movement has already occurred. Then a Revolution Spring treatment may be required to recover from the relapse. Using this device from the start of retention, it serves as a kind of insurance policy as the patient is responsible for maintaining their result and if anything changes, they may be able to reverse it with the same aligner.

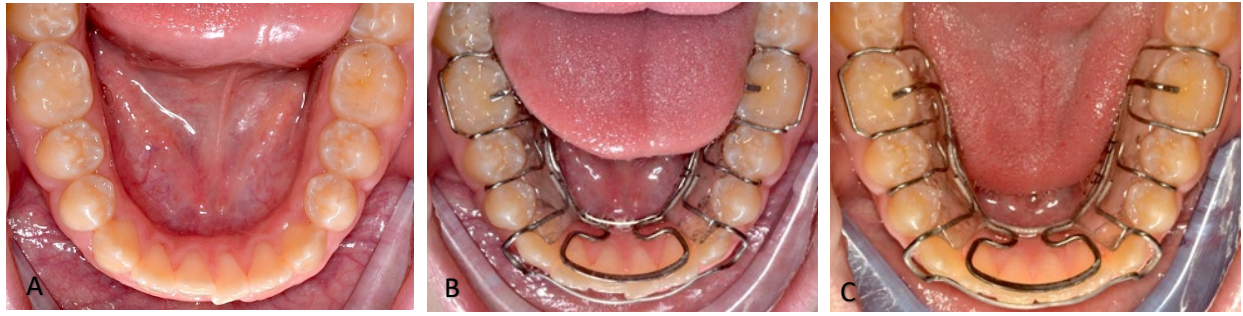

Figure 35 A-C. A. Mandibular “relapse” of rotations and crowding. B. Revolution Spring aligner constructed from digital set-up that included mild labial overcorrection of the lower right central incisor. Mild accent 1st Order bends made in the labial bow with Quadra-Z pliers. C. Final results in 1 month.

THAT’S A WRAP

The basis for clear aligners may be quite old, but their actual clinical use has sprung forth exponentially in only the past 20 years. During the growing pains, it became obvious that just a series of aligners alone cannot resolve the majority of malocclusion issues facing our specialty—no matter the quality of the software design, modeling, nor type of plastic developed. Certainly, the experience of the clinician plays a significant role in diagnosis and treatment planning; however, it is interesting that with millions of patients treated there is simply still a dearth of data gathered from successful final results. If only that information had been archived, even more substantial improvements may have been possible by now.

Instead, it has been innovations brought forward by orthodontists that have moved the needle. Yet, little credit is afforded those individuals as the companies take the credit. Early adopters stood by the aligner concept through the frustrating times, effecting improvements, such as the addition of elastic forces, one-week changes, interesting attachment designs, adjunctive appliances, individualization of aligners, and so on. It was these inventive practitioners that expanded the scope of aligners from mild Class I situations to complex malocclusions and even surgical treatments.

It will be those same forward-thinking individuals who will continue to ever improve the efficiency, effectiveness, and ultimately, the predictability of aligners with or without the limitation of the commercial ventures. These creative innovators may eventually further splinter the already increasing number of companies that are producing aligners by simply just going it alone; fabricating aligners in their own office labs and alliances, unobstructed by the limitations and constraints of corporate governance beholden to “shareholders” instead of to patients and practitioners. In the meantime, the encroachment of direct-to-consumer products have also seemed to stymie and interrupt the evolution of clear plastic treatments. Sadly, profits before patients. Products over practitioners.

Drastic Plastic was the title of the last album (on actual vinyl) by art rock band, Be-Bop Deluxe, released in 1978.

*The author has a financial interest for Aligner Chewies and the Hu-Friedy Clear Collection.

REFERENCES

1. Kesling HD. The philosophy of tooth positioning appliance. *Am J Orthod* 1945;31:297-304.
2. Kravitz ND, Kusnoto B, Begole E, Obrez A, Agran B. How well does Invisalign work? A prospective clinical study evaluating the efficacy of tooth movement with Invisalign. *Am J Orthod Dentofac Orthop* 2009;135:27-35.
3. Chisari JR, McGorray SP, Nair M, Wheeler TT. Variables affecting orthodontic tooth movement with clear aligners. *Am J Orthod Dentofacial Orthop* 2014;145(Suppl 4):S82-91.
4. Lombardo L, Arreghini A, Ramina F, Huanca Ghislazoni LT, Siciliani G. Predictability of orthodontic movement with orthodontic aligners: a retrospective study. *Prog Orthod* 2017;18:35.
5. Houle JP, Piedade L, Todescan Jr R, Pinheiro FHSL. The predictability of transverse changes with Invisalign. *Angle Orthod* 2017;87:19-24.
6. Solano-Mendoza B, Sonnemberg B, Solano-Reina E, Iglesias-Linares A. How effective is the Invisalign system in expansion movement with Ex30' aligners? *Clin Oral Investig* 2017;21(5):1475-1484.
7. Glassick A, Gluck AJ, Kotteman W, Messersmith M. Evaluating the efficacy of lower incisor intrusion with clear aligners. *J Clin Orthod* 2017;51:233-239.
8. Charalampakis O, Iliadi A, Ueno H, Oliver DR, Kim KB. Accuracy of clear aligners: a retrospective study of patients who needed refinement. *Am J Orthod Dentofacial Orthop* 2018;154:47-54.
9. Rossini G, Parrini S, Castroflorio T, Deregibus A, Debernardi CL. Efficacy of clear aligners in controlling orthodontic tooth movement: a systematic review. *Angle Orthod* 2015;85:881-889.
10. Buschang PH, Ross M, Shaw SG, Crosby D, Campbell PM. Predicted and actual end-of-treatment occlusion produced with aligner therapy. *Angle Orthod.* 2015;85:723-727.
11. Zheng M, Liu R, Ni Z, Yu Z. Efficiency, effectiveness and treatment stability of clear aligners: a systematic review and meta-analysis. *Orthod Craniofac Res* 2017;20(3):127-133.
12. Leake J. Does Invisalign line up with evidence? Master's Thesis 2018. Toronto: University of Toronto.
13. Wiboonsirikul S, Manopatanakul S, Dechkunakorn S. Invisalign update: a review of articles. *M Dent J* 2014;34:174-180.
14. Kim AS. Treatment effectiveness of the Invisalign system: a systematic review. Master's Thesis 2013. Philadelphia: Temple University.
15. Robertson L, Kaur H, Fagundes NCF, Romanyk D, Major P, Flores-Mir, C. Effectiveness of clear aligner therapy for orthodontic treatment: a systematic review. *Orthod Craniofac Res* 2020;23(2):133-142.
16. Simon M, Keilig L, Schwarze J, Jung BA, Bourauel C. Treatment outcome and efficacy of an aligner technique—regarding incisor torque, premolar derotation and molar distalization. *BMC Oral Health* 2014;14:68.
17. Ke Y, Zhu Y, Zhu M. A comparison of treatment effectiveness between clear aligner and fixed appliance therapies. *BMC Oral Health* 2019;19:24.
18. Kuncio D, Maganzini A, Shelton C, Freeman K. Invisalign and traditional orthodontic treatment postretention outcomes compared using the American Board of Orthodontics Objective Grading System. *Angle Orthod* 2007;77(5):864-869.
19. Gu J, Tang JS, Skulski B, Fields HW Jr, Beck FM, Firestone AR, et al. Evaluation of Invisalign treatment effectiveness and efficiency compared with conventional fixed appliances using the Peer Assessment Rating Index. *Am J Orthod Dentofac Orthop* 2017;151(2):259-266.
20. Galan-Lopez L, Barcia-Gonzalez J, Plascencia E. A systematic review of the accuracy and efficiency of dental movements with Invisalign. *Korean J Orthod* 2019;49(3):140-149.

21. Djeu G, Shelton C, Maganzini A. Outcome assessment of Invisalign and traditional orthodontic treatment compared with the American Board of Orthodontics objective grading system. *Am J Orthod Dentofacial Orthop* 2005;128:292-8.
22. Papageorgiou SN, Koletsi D, Iliadi A, Peltomaki T, Eliades T. Treatment outcome with orthodontic aligners and fixed appliances: a systematic review with meta-analyses. *Eur J Orthod* 2019;23.
23. Azar JD. Do-it-yourself orthodontics: an objective assessment of dental impression outcomes between an orthodontic resident and patients. Master's Thesis 2016. St. Louis: Saint Louis University – Center for Advanced Dental Education.
24. Buschang PH, Shaw SG, Ross M, Crosby D, Campbell PM. Comparative time efficiency of aligner therapy and conventional edgewise braces. *Angle Orthod* 2014;84(3):391-396.
25. Izhar A, Singh G, Goyal V, Singh R, Gupta N, Pahuja P. A prospective comparative study between the software models and clinical models of clear aligner treatment. *Orthod J of Nepal*, 2019;9(1):28-34.
26. Bowman SJ. They still shoot horses, don't they? *Angle Orthod* 2018;88(3):370-372.
27. Haouili, N, Kravitz, ND, Vaid, NR, Ferguson DJ, Makki L. Has Invisalign improved? A prospective follow-up study on the efficacy of tooth movement with Invisalign. *Am J Orthod Dentofacial Orthop* 2020 158(3):420-425.
28. Gomez JP, Peña FM, Martínez V, Giraldo DC, Cardona CI. Initial force systems during bodily tooth movement with plastic aligners and composite attachments: A three-dimensional finite element analysis. *Angle Orthod* 2015;85:454-460.
29. Glaser B. *The insider's guide to Invisalign treatment*. Sacramento: 3L Publishing, 2017.
30. Bowman SJ, Celenza F, Sparaga J, Papadopoulos MA, Ojima K, Lin JC. Creative adjuncts for clear aligners: part 1: Class II treatments. *J Clin Orthod*. 2015;49:83-94.
31. Bowman SJ, Celenza F, Sparaga J, Papadopoulos MA, Ojima K, Lin JC. Creative adjuncts for clear aligners: part 2: Intrusion, rotation, and extrusion. *J Clin Orthod*. 2015;49:162-174.
32. Bowman SJ, Celenza F, Sparaga J, Papadopoulos MA, Ojima K, Lin JC. Creative adjuncts for clear aligners: part 3: Extraction and interdisciplinary treatment. *J Clin Orthod*. 2015;49:249-262.
33. Bowman SJ. Improving the predictability of clear aligners. *Sem Orthod* 2017;23:65-75.
34. Mompell R, Bowman SJ. Microimplant-assisted aligner therapy. In: Park JH, ed. *Temporary Anchorage Devices (TADs) in Contemporary Orthodontics*. Hoboken: Wiley. 2020;53:567-580.
35. Schupp W, Haubrich J, Ojima K, Boisserele W, Morton J. *Aligner orthodontics: diagnosis, treatment planning, orthodontic and orthopedic treatment*. London: Quintessence Publishing, 2015.
36. Tai S. *Clear aligner technique*. Batavia: Quintessence Publishing, 2018.
37. Tuncay, O. *Clinical Reports & Techniques*. 2005;6(2):1.
38. Bowman SJ. Clear Collection instruments for clear aligner treatments Part I. *Orthod Prac US* 2015;6:74-78.
39. Bowman SJ. Clear Collection instruments for clear aligner treatments Part 2. *Orthod Prac US* 2015;6:48-52.
40. Tuncay O, Bowman SJ, Nicozsis J, Amy B. Effectiveness of clear aligner compliance indicator. *J Clin Orthod* 2009;43(4)263-268.
41. Tuncay O, Bowman SJ, Nicozsis J, Amy B. Aligner treatment in the teenage patient. *J Clin Orthod* 2013;47(2):115-119.
42. Arreghini A, Trigila S, Lombardo L, Siciliani G. Objective assessment of compliance for intra- and extraoral removable appliances. *Angle Orthod* 2017;87:88-95.
43. Schupp W, Haubrich J, Neumann I. Class II correction with the Invisalign system. *J Clin Orthod* 2010;44:28-35.
44. Daher, S. Dr. Sam Daher's techniques for Class II correction with Invisalign and elastics: Align Technology, Inc.; 2011.
<https://s3.amazonaws.com/learn-invisalign/docs/0684000000GHgmAAG.pdf> Accessed 6/11/20.

45. Bowman SJ. Upper-molar distalization and the distal jet. *J Clin Orthod* 2016;50(3):153-163.
46. Bowman SJ. The evolution of the horseshoe jet. In: Papadopoulos MS, ed. *Skeletal Anchorage in Orthodontic Treatment of Class II Malocclusion: Contemporary Applications of Orthodontic Implants, Miniscrew Implants and Miniplates*. St. Louis: Mosby Elsevier, 2015.
47. Sung SJ, Jang GW, Chun YS, Moon YS. Effective en-masse retraction design with orthodontic mini-implant anchorage: a finite element analysis. *Am J Orthod Dentofacial Orthop* 2010;137:648-657.
48. Case CS. *A Practical Treatise on the Technics and Principles of Dental Orthopedia and Prosthetic Correction of the Cleft Palate*. Chicago: C.S. Case, 1921.
49. Klein BM. A cephalometric study of adult mild Class II nonextraction treatment with the Invisalign System. Master's Thesis. 2013. St. Louis: Saint Louis University – Center for Advanced Dental Education.
50. Ravera S, Castroflorio T, Garino F, Daher S, Cugliari G, Deregibus A. Maxillary molar distalization with aligners in adult patients: a multicenter retrospective study. *Prog Orthod* 2016;17:12.
51. Bowman SJ. The horseshoe jet for miniscrew-supported molar distalization, *J Clin Orthod* 2018;51:196-218.
52. Bowman SJ. The effect of vibration on molar distalization. *J Clin Orthod* 2016;50(11):683-693.
53. Tsourakis AK, Johnston LE, Jr. Class II malocclusion: the aftermath of a “perfect storm.” *Sem Orthod*. 2014;20:59-73.
54. Lin JC, Chen S, Liou EJ, Ojima K, Bowman SJ. Interdisciplinary aligner treatment of short-face patients. *J of Clin Orthod* 2017;51(7):382-405.
55. Lin JC, Tsai S, Liou EJW, Bowman SJ. Treatment of challenging malocclusions with Invisalign and miniscrews. *J Clin Orthod* 2014;48(1):23-26.
56. Lin JCY, Yeh CL, Liou EJW, Bowman SJ. Treatment of skeletal–origin gummy smiles with miniscrew anchorage. *J Clin Orthod* 2008;42:285-96.
57. Giancotti A, Germano F, Muzzi F, Greco M. A miniscrew-supported intrusion auxiliary for open-bite treatment with Invisalign. *J Clin Orthod* 2014;48(6):348-358.
58. Choi N-C, Park Y-C, Jo Y-M, Lee K-J. Combined use of miniscrews and clear appliances for the treatment of bialveolar protrusion without conventional brackets. *Am J Orthod Dentofacial Orthop* 2009;135(5):671-81.
59. Ojima K, Dan C, Nishiyama R, Ohtsuka S, Schupp W. Accelerated extraction treatment with Invisalign. *J Clin Orthod* 2014;48(8):487-499.
60. Park YC, Chu JH, Choi YJ, Choi NC. Extraction space closure with vacuum-formed splints and miniscrew anchorage. *J Clin Orthod* 2005;39:76-79.
61. Ludwig B, Baumgaertel S, Bowman SJ. *Mini-Implants in Orthodontics: Innovative Anchorage Concepts*. Chicago: Quintessence 2008.
62. Bowman SJ. Thinking outside the box with miniscrews. In: McNamara JA Jr, Ribbens KA, eds. *Microimplants as Temporary Anchorage in Orthodontics*. Craniofacial Growth Series, Center for Human Growth and Development, The University of Michigan, Ann Arbor, 2008;45:327-390.
63. Bowman SJ. Uno, dos, tres: one concept for three Angle classes. *Sem Orthod* 2018;24:3-16.
64. Bowman SJ. The horseshoe jet for miniscrew-supported molar distalization. *J Clin Orthod* 2018;51(4):196-218.
65. Bowman SJ. Class II combination therapy: molar distalization and fixed Functionals, In: Nanda R, Kapilla S, eds. *Current Therapy in Orthodontics*. St. Louis: Mosby Elsevier 2009:115-136.
66. Bowman SJ. Settling the score with Class IIs using miniscrews. In: Kim KB, ed. *Temporary Skeletal Anchorage Devices—A Guide to Design and Evidence-Based Solutions*. New York City: Springer 2014.
67. Carano A, Bowman SJ. Noncompliance Class II treatment with the distal jet. In: Papadopoulos, MA, ed. *Orthodontic Treatment for the Class II Noncompliant Patient: Current Principles and Techniques*, Edinburgh: Elsevier 2006;249-271.

68. Grunheid T, Loh C, Larson BE. How accurate is Invisalign in nonextraction cases? Are predicted tooth positions achieved. *Angle Orthod* 2017;87:809-815.
69. Papadimitious A, Mousoulea S, Gkantidis N, Kloukos D. Clinical effectiveness of Invisalign orthodontic treatment: a systematic review. *Prog Ortho* 2018;19(1):37.
70. Nicozisis JL. Tripping the plastic fantastic. *Orthod Prod* 2013;Nov:28-34.
71. Savignano R, Valentino R, Razionale AV, Michelotti A, Barone S, D'Anto V. Biomechanical effects of different auxiliary-aligner designs for the extrusion of an upper central incisor: A finite element analysis. *J Healthcare Engineering* 2019;Article ID 9687127:1-9.
72. Guarneri MP, Oliverio T, Silvestre I, Lombardo L, Siciliani G. Open bite treatment using clear aligners, *Angle Orthod* 2013;83:913-919.
73. Schupp, W.; Haubrich, J. and Neumann, I.: Treatment of anterior open bite with the Invisalign system, *J. Clin. Orthod.* 44:501-7, 2010.
74. Boyd R. How successful is Invisalign for treatment of anterior open bite and deep overbite? American Association of Orthodontists Annual Session May 5, 2013 Philadelphia PA. <https://www.aaoinfo.org/system/files/media/documents/Boyd,%20Robert%20--%20Treatment%20of%20Deep%20and%20Open%20bite%20with%20Clear%20Aligners.pdf> Accessed 2/16/21.
75. Glaser B. Dr Glaser's 10 commandments of attachment design. *Orthod Prod* Mar 29, 2016. <https://www.orthodonticproductsonline.com/treatment-products/aligners/dr-glaser-10-commandments-attachment-design/?fbclid=IwAR2QUVq4H6yO5FNRJAL0E5TtkA4oemEZU8E4itfVP3TSo1aYZv3OChLPGB0>. Accessed 6/10/20.
76. Marshall S, Dawson D, Southard KA, Lee AN, Casco JS, Southard TE. Transverse molar movements during growth. *Am J Orthod Dentofacial Orthop* 2013;124:615-624.
77. American Board of Orthodontics. Why case reports do not pass the ABO Phase III clinical examination. *Am J Orthod* 1996;110:559-560.
78. Yang-Powers LC, Sadowsky C, Rosenstein S, BeGole EA. Treatment outcome in a graduate orthodontic clinic using the American Board of Orthodontics grading system. *Am J Orthod Dentofacial Orthop* 2002;122:451-455.
79. Bowman SJ, Carano A. Short-term, intensive use of the tooth positioner in case finishing. *J Clin Orthod* 2002;36:216-219.
80. Park Y, Hartsfield JK, Katona TF, Roberts WE. Tooth positioner effects on occlusal contacts and treatment outcomes. *Angle Orthod* 2008;78(6):1050-1056.
81. Littlewood SJ, Millett DT, Doubleday B, Bearn DR, Worthington HV. Retention procedures for stabilising tooth position after treatment with orthodontic braces. *Cochrane Database Syst Rev* 2016;Jan 29(1):CD002283.
82. Kocher KE, Gebistorf MC, Pandis N, Fudalej PS, Katsaros C. Survival of maxillary and mandibular bonded retainers 10 to 15 years after orthodontic treatment: a retrospective observational study. *Prog Orthod* 2019;20:28.
83. Kravitz ND, Grauer D, Schumacher P, Jo Y. Memotain: a CAD/CAM nickel-titanium lingual retainer. Case reports. *Am J Orthod Dentofac Orthop* 2017;151(4):812-815.
84. Goldberg AJ, Burstone CJ. An evaluation of beta titanium alloys for use in orthodontic appliances. *J Dent Res* 1979;58:593-600.
85. Burstone CJ, Goldberg AJ. Beta titanium: a new orthodontic alloy. *Am J Orthod* 1980;77:121-132.

SPACE MANAGEMENT OF LABIALLY IMPACTED MAXILLARY CANINES

Steven M. Lash

ABSTRACT

Maxillary canines are among the most common impacted teeth. Approximately one-third of all impacted maxillary canines are labially positioned and arch length discrepancy is thought to be a primary etiological factor. This chapter presents a case series which illustrates the decision-making process in the management of labially impacted canines from a clinician with over 50 years of clinical practice experience. Case results that use orthodontic space management techniques to assist labially impacted canines erupt into the dental arch *without surgical exposure, extraction of permanent teeth, intramaxillary or intermaxillary distalization utilizing bone anchored mini-screws (TADS), and (in most cases) conventional rapid palatal expansion, surgically assisted (SARPE) rapid palatal expansion, or miniscrew assisted (MARPE) rapid palatal expansion*, all while maintaining a well-balanced facial profile and a pleasing smile are presented. Canines are recovered by developing space within the dental arch by primarily *distalizing* the maxillary posterior occlusion. Maxillary expansion is utilized when there is a transverse issue and mainly with slow archwire expansion. To date, consistent results using these space management techniques with before and after orthodontic records of nearly 150 patients have been collected.

KEY WORDS: Space management, Labially impacted maxillary canines, Arch length, Surgical exposure

INTRODUCTION

Space management of labially impacted maxillary canines has interested me for years. I began using these techniques very early in my career because of my interest in orthognathic surgery. Soon after I finished my orthodontic residency in 1972 at the University of Michigan, I was hired in the orthodontic department at the University of Detroit Mercy and charged with developing an orthognathic surgery program. I soon discovered that many of the protocols that worked with conventional orthodontics were not appropriate when preparing a patient with a dental-facial deformity for surgery. There were no guidelines in these cases to advise me on when to retrieve an impacted canine or when to extract premolars. For example, if a patient presented with a mandibular retrognathia, a labially impacted maxillary canine or canines, minimal overjet, and linguallly torqued maxillary incisors, my pre-surgical treatment plan was to increase the overjet and the torque of the maxillary incisors in order to maximize the mandibular advancement. It made sense to retrieve the canine(s). So, I made my own rules. If I could develop and define space for an impacted canine *without extractions* before surgery, and within a reasonable time, *I did not initially extract*.

Unwittingly, I began to routinely use these space management techniques for all my patients, orthognathic and conventional. Fourteen years after I completed my training, I reviewed every one of my treatment results in preparation for the American Board exam, and I made some startling discoveries. I found that I was producing results like those in Figure 1 with space management techniques.

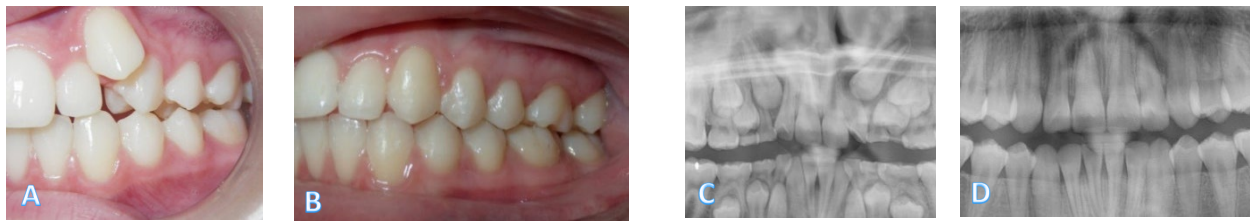


Figure 1. A) Pre-treatment intraoral photograph of a patient with an impacted canine. B) Post-treatment. C) Pre-treatment radiograph of another patient with an impacted maxillary canine. D) Post-treatment.

An impacted canine, according to the American Association of Orthodontics and Dentofacial Orthopedics' website is a canine that has not erupted when expected, cannot erupt because it does not have room, or may be coming in the wrong direction or position [1]. Two thirds of impacted canines are palatal, one third are labial and 85% of the palatally impacted canines have enough space for eruption. Only 17% of the labially impacted canines have space for eruption [3,4,5]. *"Therefore, arch length discrepancy is thought to be a primary etiologic factor for labially impacted canines [6]."*

There is a mountain of material in the literature about recovering palatally impacted canines [2,10], but not much about orthodontically managing *labially* impacted maxillary canines. The majority of the papers in the literature refer to the proper surgical approach [6,7,8,10] to expose the impacted canine (palatal or labial). In the following cases orthodontic space management techniques were employed to assist the eruption of various labially impacted teeth. Some may consider that the results of these cases as old school because they were obtained without *surgical exposure, extraction of permanent teeth, intramaxillary or intermaxillary distalization utilizing bone anchored mini-screws (TADS), and (in most cases,) conventional rapid palatal expansion, surgically assisted (SARPE) rapid palatal expansion, or micro-implant supported (MARPE) rapid palatal*, all while maintaining a well-balanced facial profile and a pleasing smile.

Although labially impacted maxillary canines have been strongly associated with space loss/crowding, there is developing evidence that the maxillary skeletal expander (MSE), a particular type of MARPE, can develop space to aid in the recovery of labially displaced maxillary canines [9]. More long-term data is needed to quantify the efficacy and stability of this appliance, but for those patients who wish NO invasive procedures, the space management techniques used in this article have given consistent results. To date, with the help of my associate, Dr. Rebecca Rubin, we have collected the before and after records of more than 150 patients.

Simply put, my space management techniques of labially impacted canines include:

- 1) Distalization of maxillary posterior teeth
- 2) Protraction of maxillary incisors
- 3) Protecting E-space
- 4) Maxillary expansion mostly using slow archwire expansion

In patients with impacted canines, my basic treatment mechanotherapy include developing and defining space for the impacted canines using springs and elastics (Figure 2), and if necessary, correcting a Class II, Class III, and crossbites with traditional techniques.

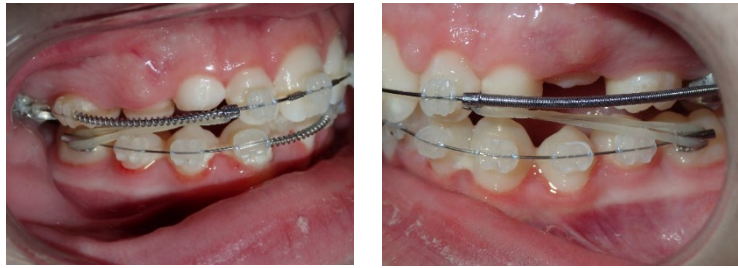


Figure 2. Class II elastics to sliding hooks mesial to open coiled springs at the canine space.

In most cases it will be necessary to reevaluate extractions, exposures, canine replacement or implants after a suitable time based on what was best for the face. My guideline about extractions has always been: *When in doubt about extractions, don't!*

BASIC SPACE MANAGEMENT TREATMENT PROCEDURES

- 1) Start treatment when four to six deciduous teeth remain.
- 2) Protect the E space as loss of the deciduous second molars may increase the molar Class II.
- 3) Band and direct bond all teeth including as many deciduous teeth as possible.
- 4) Ligate everything you can.
- 5) Utilize a rapid palatal expansion appliance with a significant maxillary transverse deficiency otherwise utilize slow archwire expansion.
- 6) Open the bite with a bite plane, turbos, bite blocks, or bumpers.

For retention, I follow my patients after deband for at least two years and most of my patients wear clear Essix-type retainers full time for four to six months and then nighttime for 18 months. When dismissed, the patients are instructed to wear their retainers as much as necessary, so they still fit properly - forever. Patients that were treated with space management techniques show no difference in long term stability than patients that were not.

CASE 1: LONG TERM STABLE RESULTS: 8 YEARS, 9 MONTHS POST DEBAND

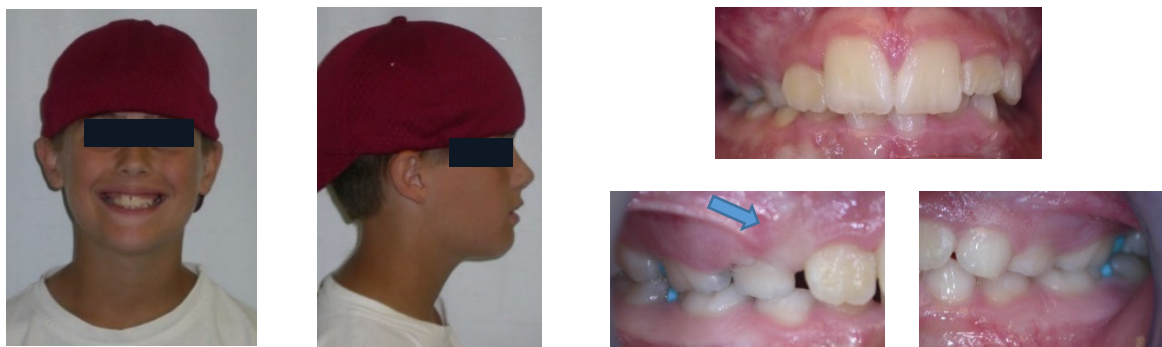


Figure 3. Initial facial and intraoral photographs of a patient with an impacted maxillary right canine. Age: 10-3.

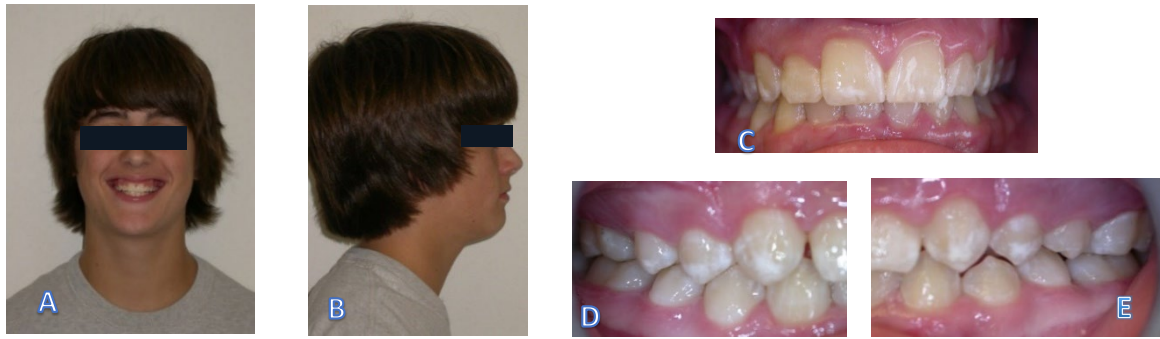


Figure 4. A & B) Post treatment facial and intraoral photographs showing a pleasing smile and good facial balance. B, C, & D) Intraoral photographs showing the retrieved maxillary right canine. Age: 13-4.

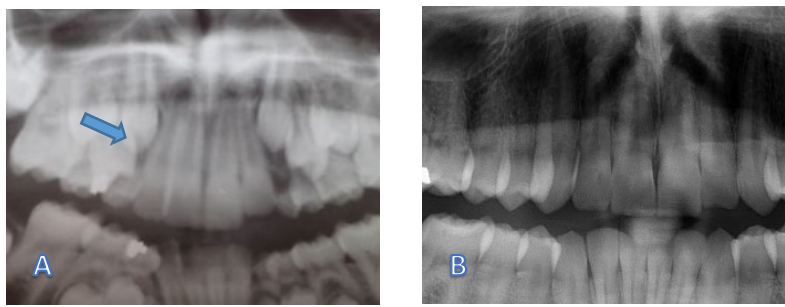


Figure 5. A) Pre-treatment panoramic x-ray. B) Post-treatment radiograph showing the retrieved maxillary right canine.

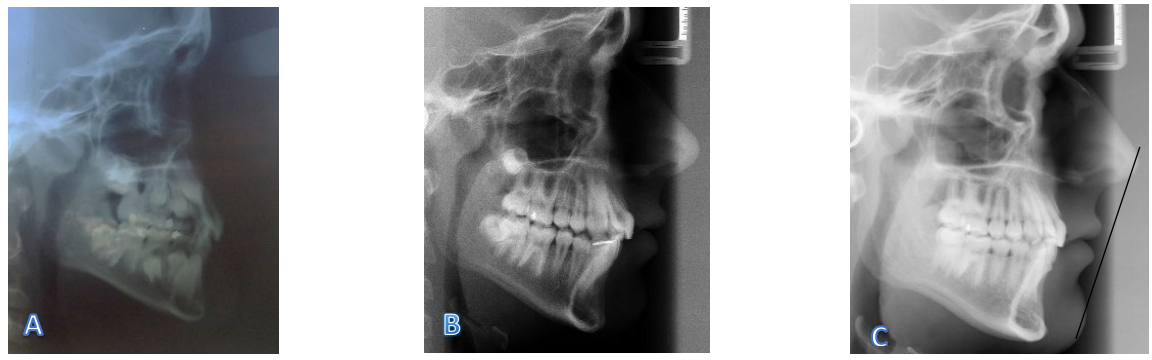


Figure 6. A) Initial cephalogram. Age: 10-3. B) Deband. Age: 13-4. C) 8 years, 9 months post-deband showing a well-balanced facial profile. Age: 22-1.

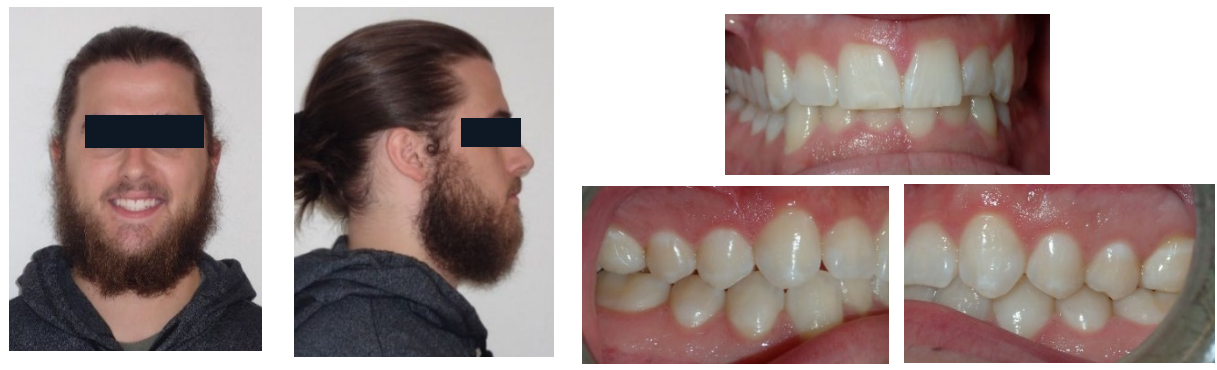

Figure 7. Long term stable result, 8 years, 9 months post-deband. Age: 22-1.

CASE 2: UNILATERAL IMPACTED CANINE, MIXED DENTITION

It is widely recommended to treat patients with impacted canines in the mixed dentition with expansion. The majority of my impacted canine/space loss patients involve maxillary expansion - *slow archwire expansion*. In this Class I mixed dentition patient who presented with a severely impacted maxillary left canine, I wanted to take advantage of the E space and institute space management techniques as soon as possible to develop space and assist eruption of the impacted canine. I did not want to take the time to use a fixed expansion appliance, so I bracketed the maxillary and mandibular incisors, 2nd deciduous molars and first molars and immediately started using open coiled springs and Class II elastics. Often it is also beneficial to extract the deciduous canines but, in this patient, because of her fearful demeanor, I chose not to extract the primary canines. I would reevaluate the need for surgical exposure or extractions after about nine months to a year of treatment with space management techniques.

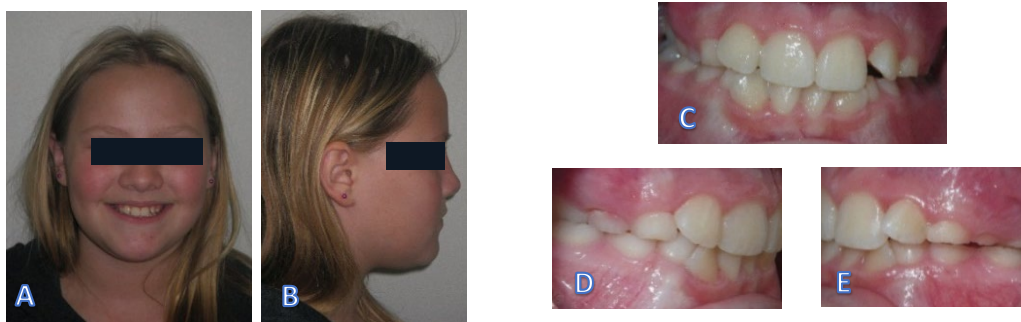

Figure 8. A & B) Pre-treatment facial photographs. C, D, & E) Initial facial photographs that show a Class I-II occlusion, in the mixed dentition. The midline is deviated to the patients left and the maxillary left lateral incisor is rotated and in labial version. Age: 11-3.

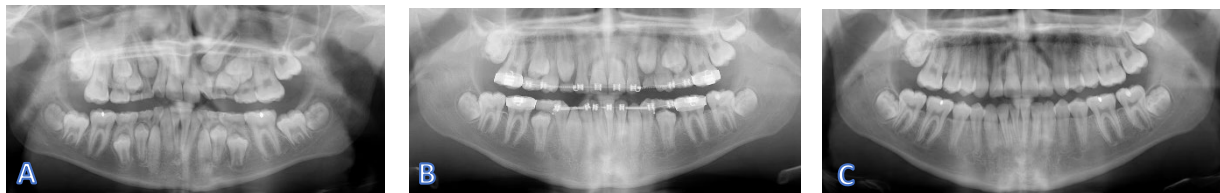


Figure 9. A) Initial panographic x-ray. B) Progress at 18 months. the second deciduous molars are still present, and deciduous canines have not been extracted. Note the open-coiled springs with mesial hooks for Class II elastics between the right and left maxillary lateral incisors and first premolars. C) Panographic x-ray at deband.

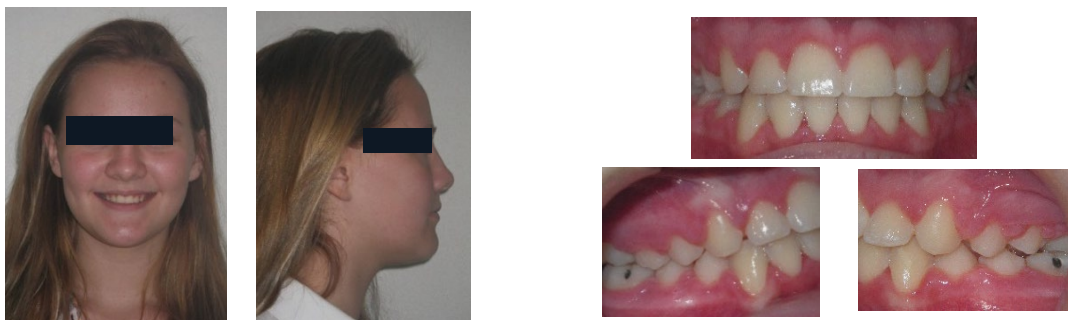


Figure 10. Facial and intraoral photos at deband. Age: 14-3.

CASE 3: BILATERAL IMPACTED CANINES

The patient was a 12-year, 10-month old male with a crowded Class I malocclusion, deep bite, mild bialveolar protrusion, and bilateral labially impacted canines. The initial objective was to develop and define enough space for the eruption of the canines. The initial treatment plan was non-extraction of any teeth, band and direct bond all the permanent teeth available including the maxillary deciduous second molars. The maxillary deciduous canines were not extracted and were not bonded. A bite plate to open the bite and Class II elastics to open coiled springs at the maxillary right and left canines were used. Treatment followed uneventfully without exposing the canines or extracting the first premolars and the patient was debanded after 32 months.

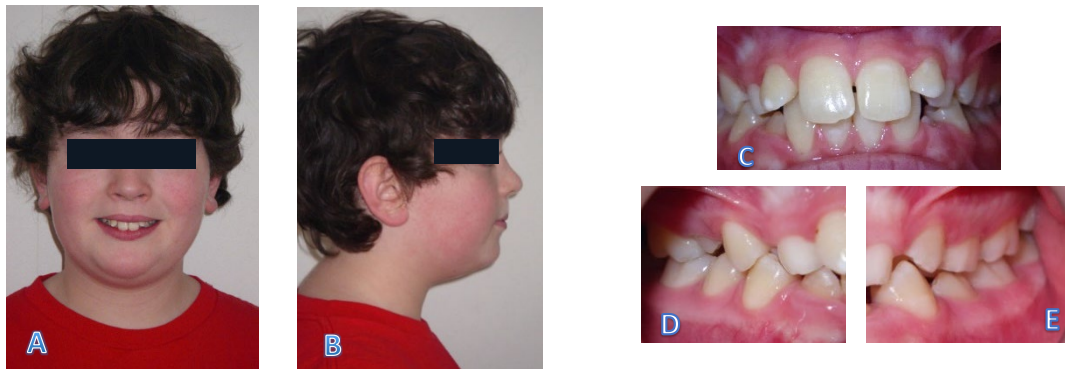

Figure 11. A & B) Pre-treatment facial photographs. C, D, & E) Intraoral photographs. The deciduous canines are present. Age: 12-10.

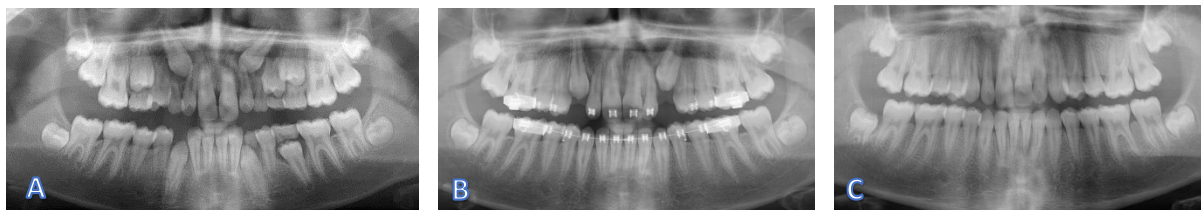

Figure 12. A) Initial panograph. Age: 12-10. B) Progress panograph. Age: 13-9. C) Deband panograph. Age: 15-8.

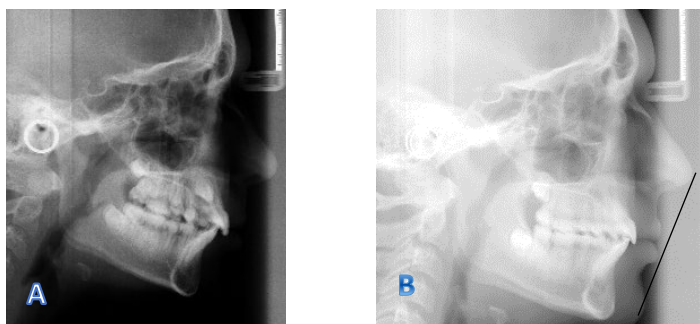


Figure 13. A) Initial cephalogram. B) Final cephalogram that shows a well-balanced facial profile.

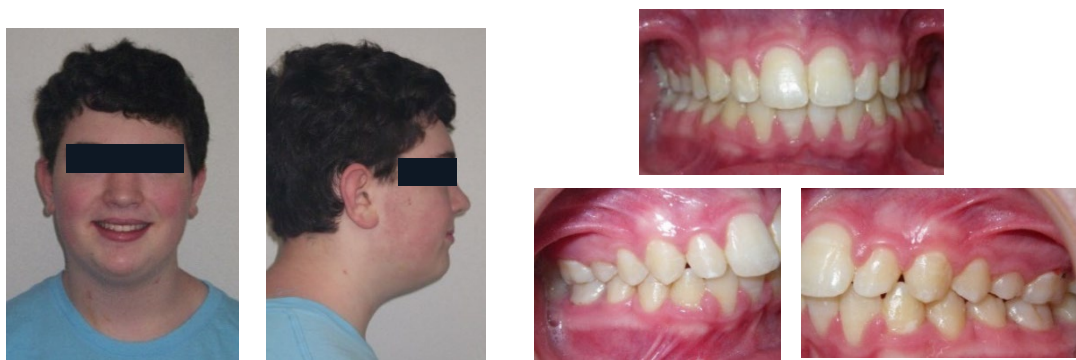

Figure 14. Photographs at deband. After 32 months of treatment, the canines were retrieved and aligned without extractions of premolars or exposure of the canines. Age: 15-8.

Complicating the issue of a unilateral or bilateral impacted maxillary canine is that the resultant space loss often leads to the development of a Class II occlusion on the affected side or sides and a midline deviation. In addition, collapse of the arch with space loss due to an impacted canine can also lead to unilateral or bilateral crossbites. The space management techniques outlined in this article worked well with these issues.

CASE 4: LEFT SIDE CROSSBITE, MIDLINE DEVIATION WITH BILATERAL IMPACTED CANINES

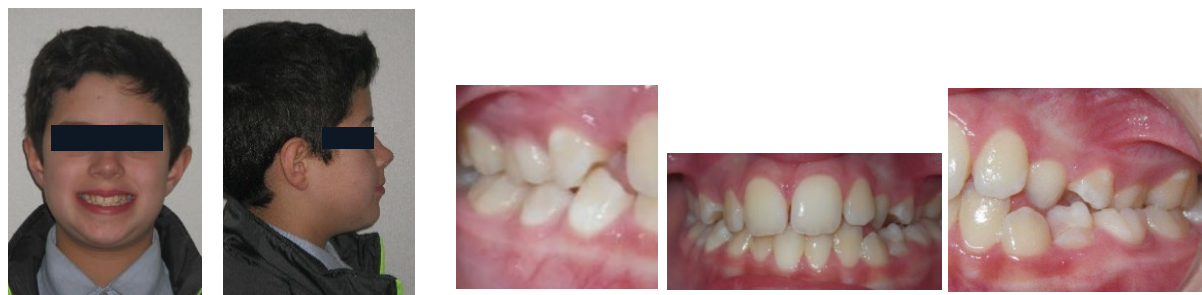

Figure 15. Initial facial and intraoral photographs of a patient with bilateral impacted canines, space loss, midline deviation, and left side crossbite. Age: 11-5.

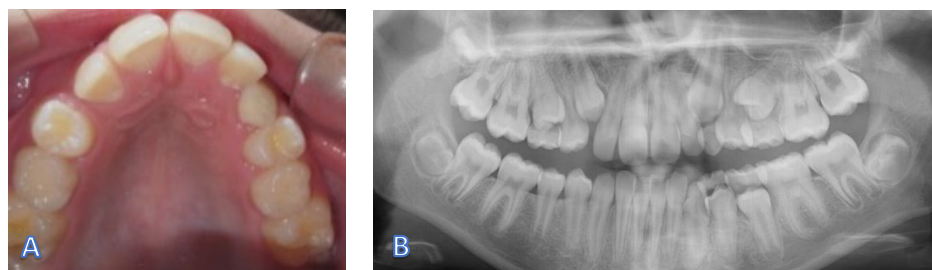


Figure 16. A) Occlusal photograph showing the space loss. B) Initial panograph.

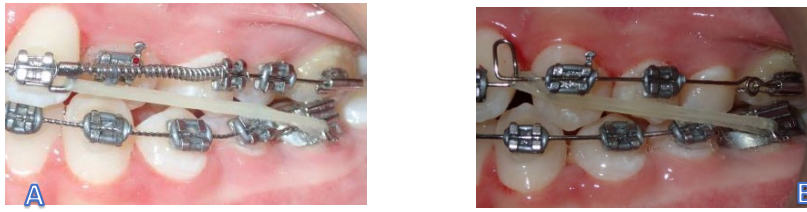

Figure 17. A) Class II elastic to a sliding hook mesial to an open coiled spring. Age: 12-9. B) More space was made than needed to bring the canine into the arch, so a Class II elastic to a closing arch was used to consolidate the excess space.

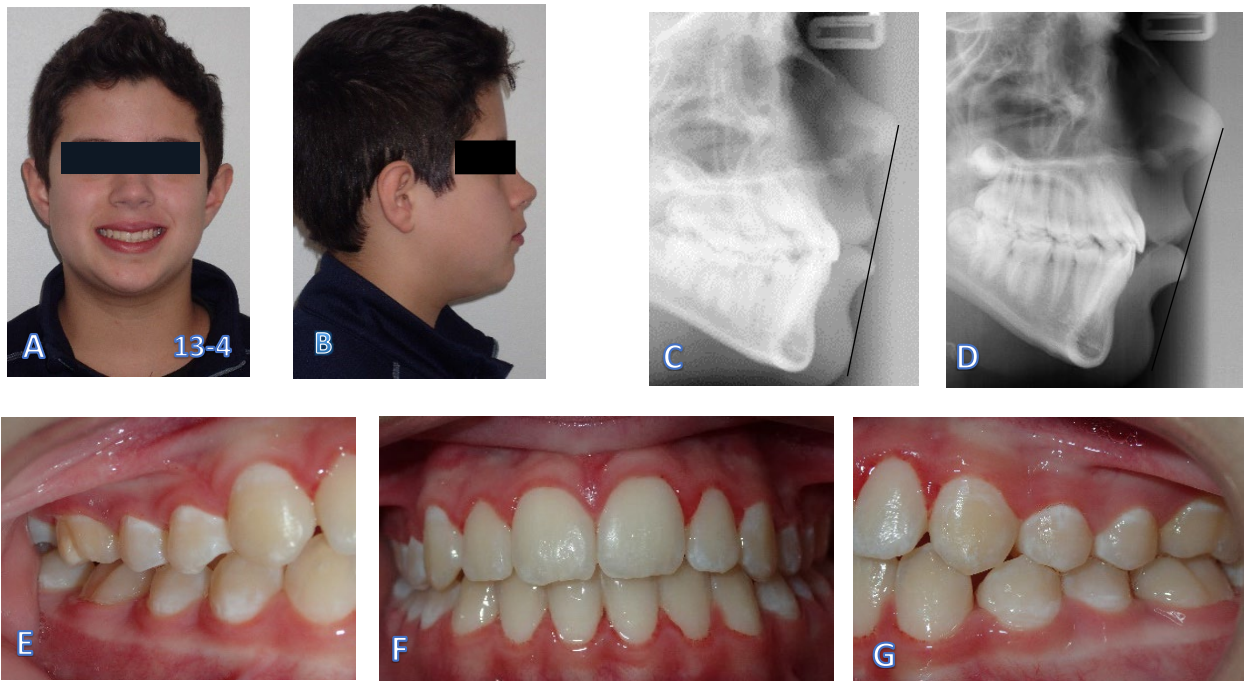


Figure 18. After 23 months of treatment, the canines were retrieved, the left side crossbite and midlines were corrected and there is no evidence of facial protrusion. A & B) Facial photographs at deband. C) Pre-treatment cephalometric x-ray. D) Post-treatment cephalometric x-ray. E, F, & G) Post-treatment occlusion. Age: 13-4.

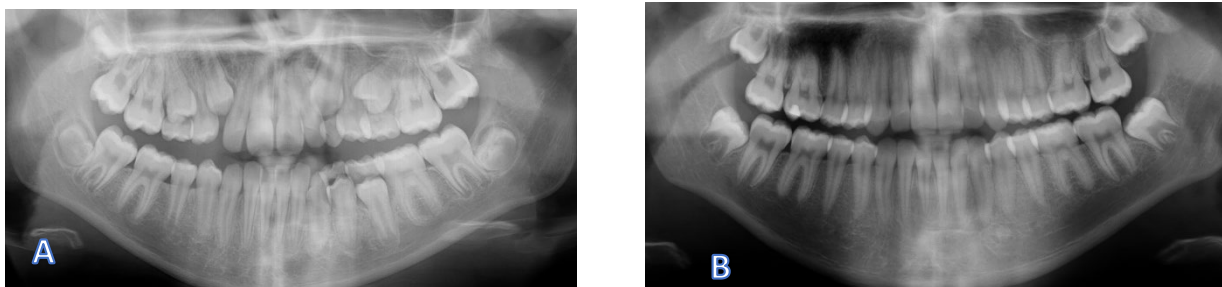


Figure 19. Long term stability. A) Initial panoramic x-ray at 11-5 showing the impacted canines, and B) Panograph at 26 months post deband.

CASE 5: RPE APPLIANCE USED WITH SPACE MANAGEMENT TECHNIQUES - SEVERE CROWDING, ANTERIOR CROSSBITE AND BILATERAL IMPACTED MAXILLARY CANINES

In patients that exhibit severe space loss due to impacted canines where a near or complete maxillary cross bite has developed, a rapid palatal expansion device is used prior to starting space management techniques. In the following case the patient presented in the late mixed dentition exhibiting severe maxillary crowding with total blockage of the maxillary canines. (The maxillary lateral incisors were contacting the maxillary first premolars.) Since he had a mildly deficient upper lip, I felt I by expanding him and correcting the crossbites, I could improve the facial profile. All was dependent on cooperation with the space management techniques.

The treatment objective was to expand the palate with a rapid palatal expansion appliance, then, utilizing the developed maxillary midline diastema and the E spaces, assist the eruption of the impacted canines with space management techniques. Additionally, anterior thru-the-bite elastics were used to help protract the maxillary incisors and correct the anterior crossbite.

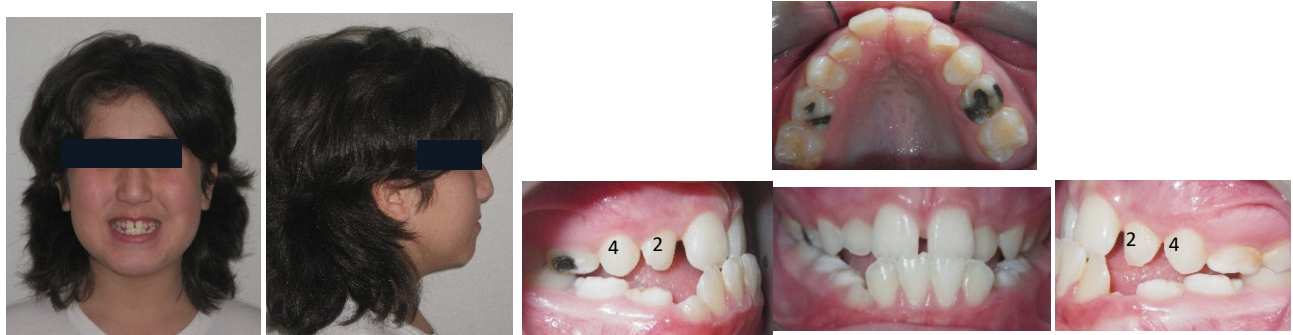


Figure 20. Initial photographs showing complete blockage of the maxillary canines, with total maxillary crossbite. The maxillary permanent lateral incisors are contacting the maxillary first premolars. Age: 11-1.

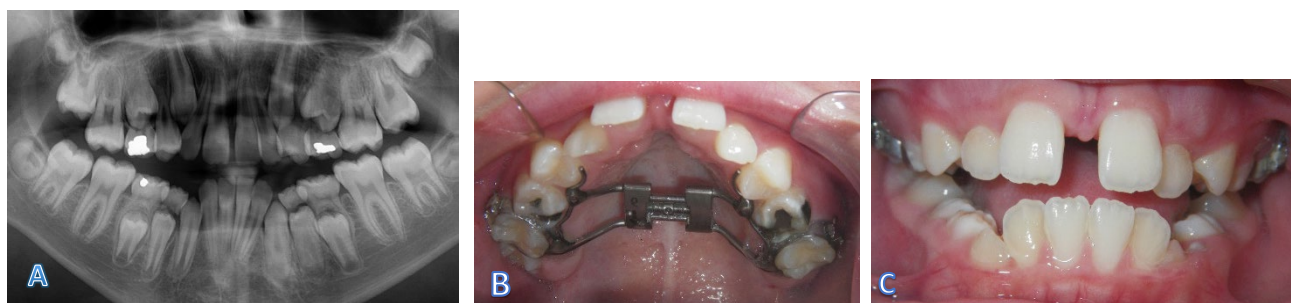

Figure 21. A) Initial panoramic x-ray showing total blockage of the impacted canines. B & C) Following rapid palatal expansion the creation of a midline diastema.

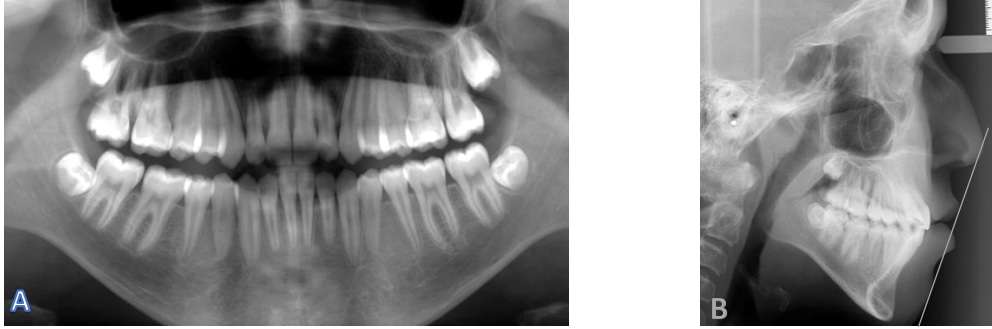

Figure 22. A) Post treatment panoramic x-ray showing the recovered maxillary canines. B) The post treatment cephalogram shows the increase torque of the upper incisors and the correction of the anterior crossbite following the use of anterior thru-the-bite elastics. Facial balance is acceptable.

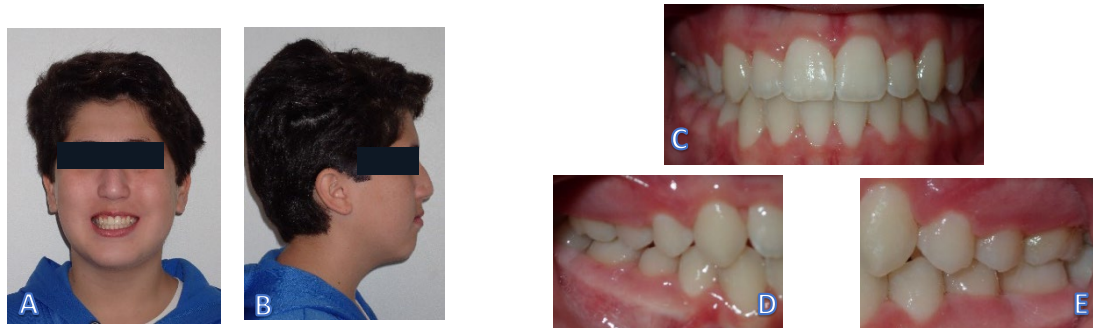


Figure 23. A & B) Post treatment facial photographs. C, D, & E) Post-treatment intra oral photographs. Age: 14-2.

CASE 6: MID-TREATMENT DILEMMA: CONGENITALLY MISSING MAXILLARY LATERAL INCISOR WITH IMPACTED CANINE. CANINE REPLACEMENT OR IMPLANT?

It is not unusual for patients with congenitally missing lateral incisors to have the maxillary canines ectopically erupt into the missing lateral incisor position. Depending on many factors, a decision must be made whether the lateral incisor space should be opened, and implants placed to replace the missing tooth or teeth, or whether canine replacement is used. The following case shows how space management techniques were used to develop and define space for the missing lateral incisor and placement of an implant.

The patient presented clinically with a Class I malocclusion, relatively straight facial profile, and a mild midline deviation. The initial panoramic x-ray showed a congenitally missing maxillary left lateral incisor and a pegged maxillary right lateral incisor. The maxillary right and left canines were erupting ectopically into the lateral incisor positions.

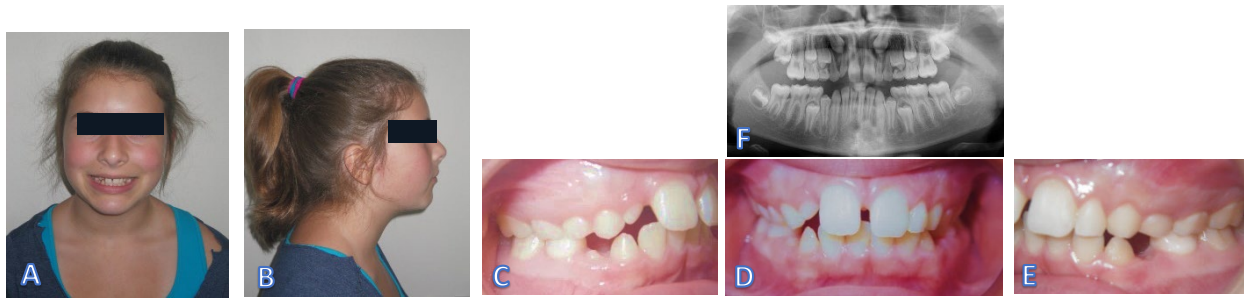


Figure 24. Figures A & B) Initial facial photographs. Figures C, D, & E) Intraoral photographs. Figure F) Initial panoramic x-ray. Age: 11-7.

Because of the following factors: a missing maxillary left lateral incisor, a pegged maxillary right lateral incisor, and the ectopically erupting canines into the lateral incisor positions, my original treatment plan was to eventually extract the right lateral incisor and allow the canines to erupt into the lateral incisor positions as canine replacements. After 10 months of treatment, I was presented with a dilemma. I had not yet extracted the maxillary right lateral incisor or the deciduous lateral incisor or canine on the left side and saw that the canines had uprighted. The right canine looked to be erupting in its normal position (See Figure 25 (A). Since the molars were in a Class I relation, canine replacement was no longer as desirable an option as I did not wish to protract the molars into a Class II and prosthetically alter the left canine. I met with the parents and patient and discussed an alternative plan opening the left lateral incisor space. They were informed that an implant and crown would be necessary, and the orthodontic treatment would be extended for probably one year. They met with their dentist and we decided that cosmetically her smile would be more pleasing without canine replacement treatment.

Open coiled springs between the maxillary left central incisor and first premolar were used to help make space for the missing lateral incisor. The left canine erupted into the lateral incisor position and then distalized opening the space for an implant using springs and elastics.

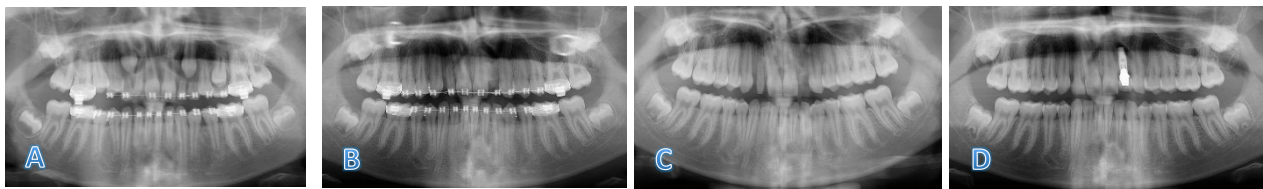


Figure 25. A) Progress at 10 months. The maxillary deciduous teeth have NOT been extracted. Age 12-5. B) The canines erupted, and space management techniques were used to distalize the maxillary left canine and prepare the space for an implant. C) Panograph at deband. Treatment time was 40 months. Age 15-1. D) Panograph after the implant crown was placed. Age 15-9. The implant was placed at 15.2 and the crown was placed at 15.9. A pontic was placed in the Essex retainer while waiting for the crown. The maxillary right pegged lateral was bonded immediately after deband.

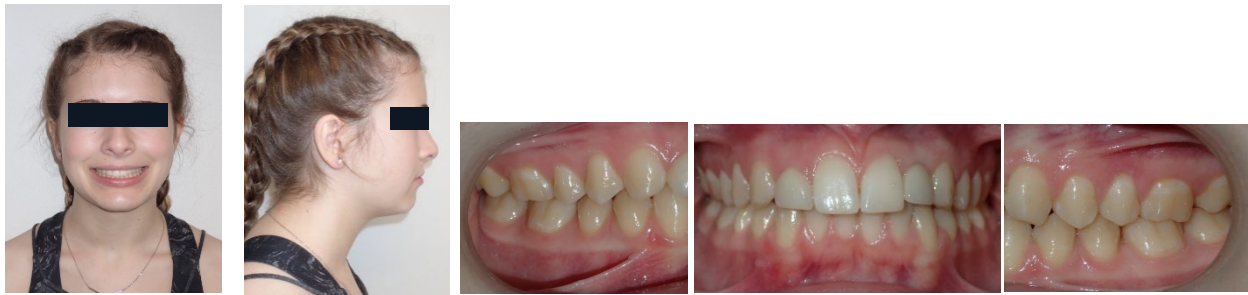

Figure 26. Facial and intraoral photographs taken eight months after deband when the implant crown was placed. Age: 15-9.

CONCLUSIONS

Labially impacted maxillary canines are frequently encountered in the contemporary orthodontic practice. Parents and patients will often request that if non-invasive techniques exist to retrieve the impacted tooth or teeth to try those methods first before a surgical or TAD assisted technique is used. This case series showed that by using space management techniques, many unilateral and bilateral impacted maxillary canines can be retrieved and aligned in the dental arch without creating or enhancing a bialveolar protrusion while producing a pleasing smile.

REFERENCES

1. What is an impacted tooth? In: *Orthodontics: What's trending*. aainfo.org 2018.
2. Bishara SE. Impacted maxillary canines: A review. *Am J of Orthod and Dentofacial Orthop*. 1992;101(2): 159-171.
3. Jacoby H. Etiology of maxillary canine impactions. *Am J Orthod Dentofacial Orthop*. 1983; 84:125-132.
4. Mitchell, L. editor. *An Introduction to Orthodontics*. 3rd ed. New York: Oxford University Press. 2007; 147-156.
5. Litsas G. Clinical Management of the Impacted Maxillary Canines. Review and Report of Cases. *EC Dental Science* 12.4. 2017; 168-178.
6. Ranjit M, ChandraSekhar G, Shubhaker RJ, Haranath R, Medapati R, Sampath A. Impacted Canines: etiology, diagnosis, and orthodontic management. *J Pharm Bioallied Sci*. 2012; 4(Suppl 2):234–238.
7. Kinaia BM, Agarwal K, Bushong B, Kapoor N, Hope K, Ambrosio F, Shah, M. Surgical management of impacted canines: A literature review and case presentations. *J Dent Oral Biol*. 2016; 1(3):1012-1019.
8. Sachan A, Chaturvedi TP. Orthodontic management of buccally erupted ectopic canine with two case reports. *Contemp Clin Dent*. 2012;3(1):123–128.
9. Kokich VG. Surgical and orthodontic management of impacted maxillary canines. *Am J Orthod Dentofacial Orthop*. 2004;126:278-283.
10. Moon Won. Maxillary expansion in skeletally mature patients with TADS. In: Park JH, ed. *Temporary Anchorage Devices in Clinical Orthodontics*. 2020;223-232.

©2021 by the Department of Orthodontics and Pediatric Dentistry,
School of Dentistry, University of Michigan
Ann Arbor, MI 48109