





Implant soft tissue Dehiscence coverage Esthetic Score (IDES): A pilot within- and between-rater analysis of consistency in objective and subjective scores

Giovanni Zucchelli^{1,2} | Shayan Barootchi¹  | Lorenzo Tavelli¹  |
Martina Stefanini²  | Giulio Rasperini³ | Hom-Lay Wang¹ 

¹Department of Periodontics & Oral Medicine, University of Michigan School of Dentistry, Ann Arbor, MI, USA

²Department of Biomedical and Neuromotor Sciences, University of Bologna, Bologna, Italy

³Department of Biomedical, Surgical and Dental Sciences, University of Milan, Foundation IRCCS Ca' Granda Polyclinic, Milan, Italy

Correspondence

Shayan Barootchi, Department of Periodontics and Oral Medicine, University of Michigan School of Dentistry, 1011 North University Avenue, Ann Arbor, MI 48109-1078, USA.

Email: shbaroot@umich.edu

Abstract

Objectives: To introduce an esthetic index for assessing the outcomes of peri-implant soft tissue dehiscence/deficiency (PSTD) coverage and test its within- and between-reviewer reliability.

Materials and Methods: Photographs of 51 single PSTDs at baseline and after treatment were provided to four periodontists from three centers. The examiners were asked to rate each case at two timepoints with the Implant soft tissue Dehiscence/deficiency coverage Esthetic Score (IDES) that involved the evaluation of the post-treatment level of the soft tissue margin, peri-implant papillae height, mucosa color, and mucosa appearance (summing up to a total score of 10). Variance components analysis was conducted using multilevel regression fit in a Bayesian framework for obtaining uncertainty intervals for fractional variance contributions and intraclass correlation values (ICC) of the IDES, and for each of its four clinical variables.

Results: Regression models showed reproducible esthetic evaluation among the examiners (inter-reliability) and negligible intra-reviewer variability (assessment of the same case at different timepoints). The ICC for the variability in the assessment of the overall IDES was 0.86, and for the individual components ranged from 0.78 to 0.87. Additionally, there was a strong similarity between the raters' IDES values, and their subjective esthetic response, by the same raters.

Conclusion: The IDES showed persistent judgment among the 4 reviewers, and only a slight intra-reviewer variability across timepoints. Within its limitations, this study suggests that the proposed novel score can be a reliable tool for evaluating the esthetic outcomes of PSTD coverage, which can aid in standardization of esthetic assessments following the treatment of a PSTD.

KEYWORDS

connective tissue, dental implant, esthetics, evidence-based dentistry, gingival recession, periodontics

1 | INTRODUCTION

Peri-implant soft tissue dehiscence/deficiencies (PSTD) have become an emerging concern in the last decade. While this condition had already been observed in the early 1990s and in the beginning of the 2000s (Bengazi et al., 1996; Small et al., 2001), it is recently patients' esthetic demands have increased such that even a minimal appearance of the grayish color of the implant component or an implant-supported crown that is longer than its homologous contralateral tooth can be considered unacceptable, especially when it comes to the esthetic region (Rocuzzo et al., 2014; Tavelli et al., 2020; Zucchelli et al., 2019). The relatively high and heterogenous incidence of PSTD, ranging from 9% to 64% (Chen & Buser, 2014; Cosyn et al., 2012; Khzam et al., 2015; Mazzotti et al., 2018), is likely due to the large variety of factors that have been suggested to be associated with this condition (Mazzotti et al., 2018; Zucchelli et al., 2019). The bucco-palatal implant position (especially when combined with a thin soft tissue phenotype) can be one of the most significant determinants of a PSTD (Cosyn et al., 2012; Sanz-Martin et al., 2020; Zucchelli et al., 2019), with an odds ratio of 34 as reported by Sanz-Martin et al. (2020).

Several techniques have been proposed for the treatment of PSTDs, including coronally advanced flap (CAF) or tunnel technique in combination with a connective tissue graft (CTG) or other substitutes (Anderson et al., 2014; Burkhardt et al., 2008; Happe et al., 2013), a prosthetic-surgical approach (Zucchelli et al., 2013, 2018; Zucchelli, Mazzotti, Mounssif, Mele, et al., 2013) or soft tissue augmentation with a submerged healing (Chu & Tarnow, 2013; Lai et al., 2010; Stefanini et al., 2020). Nonetheless, most of the available literature includes case reports and case series (Mazzotti et al., 2018; Zucchelli et al., 2019); therefore, a comparison among different techniques, in terms of clinical and esthetic outcomes, is currently not feasible. In addition, the inclusion of different types of PSTDs in the aforementioned studies leads to large heterogeneity in their reporting of the percentage of mean or complete coverage of these defects.

Recently, our group proposed a classification of PSTD for single implant sites in the esthetic zone, with recommendation of the appropriate treatment protocols for each category (Zucchelli et al., 2019). One of the aims behind this classification was to provide a uniform and standardized reporting of PSTDs, to enhance communication among clinicians, improve research, and aid in comparison of the relative efficacy of different surgical approaches (Zucchelli et al., 2019). Nonetheless, as the treatment of PSTDs is mainly carried out with the aim of improving esthetic concerns (Mazzotti et al., 2018), a specific index evaluating the esthetic outcomes following the surgical correction of PSTDs should also be set forward for properly and objectively evaluating its results. Some authors have utilized visual analogue scales (Rocuzzo et al., 2014, 2019; Zucchelli, Mazzotti, Mounssif, Mele, et al., 2013) for evaluating the final esthetic outcomes, while others used previously proposed indices for implant therapy, such as the complex esthetic index (Anderson et al., 2014; Juodzbaly

& Wang, 2010), and the pink, or white esthetic scores (Belser et al., 2009; Furhauser et al., 2005; Zucchelli et al., 2018). These indices, however, have been suggested for evaluating the outcomes of implant therapy, and not the correction of an esthetic complication, such as a PSTD.

In this scenario, the large number of utilized esthetic scores and the lack of consensus and uniformity among the authors indicate the need of introducing a specific Implant soft tissue Dehiscence/deficiency coverage Esthetic Score (IDES). Therefore, the aim of the present study was as follows: (a) to propose a score for evaluating the esthetic outcomes following the treatment for a PSTD at single implant sites in the esthetic area, and (b) to test the intra- and inter-rater reliability/consistency of this rubric among expert periodontists.

2 | MATERIALS AND METHODS

2.1 | Study design

The current study was designed as a preliminary analysis for presentation of a novel esthetic score for the objective evaluation of PTSD coverage, and for testing the reliability of its application among examiners from different centers, and for the same examiners between different timepoints. For this purpose, photographs of 51 previously treated cases of the coverage of a PSTD were utilized.

The inclusion criteria comprised patients with at least 18 years of age with one PSTD in the esthetic zone (from the first right premolar to the first left premolar) that was bounded by two natural teeth. The patients must have been periodontally and systemically healthy without any contraindications for periodontal surgery or under any medication known to interfere with periodontal/peri-implant tissue health or healing. Also, the treated cases must have had a follow-up of at least 6 months. Conversely, patients who had reported smoking more than 10 cigarettes per day were excluded, along with implants that were diagnosed with a peri-implant disease (Berglundh et al., 2018).

All patients had provided their informed consent prior to the study, and the protocol of the study was approved by the University of Michigan Medical School Institutional Review Board (IRBMED, HUM00146261), and in accordance with the Declaration of Helsinki of 1975, revised in Tokyo in 2004. The current manuscript abides by the EQUATOR guidelines Standards for Reporting Qualitative Research (SRQR) (O'Brien et al., 2014).

2.2 | The IDES

The IDES was evaluated at least 6 months following the treatment of a PSTD.

While weighted differently, four individual components give rise to the IDES, which can range from 0 at lowest to 10 which represents the highest esthetic outcome (Table 1):

TABLE 1 Summary of the Implant Soft Tissue Dehiscence/Deficiency coverage Esthetic Score (IDES)

Peri-Implant soft tissue Dehiscence coverage Esthetic Score (IDES)		
Parameter (points)	Condition at least 6 months after treatment	Assigned points
Soft Tissue Margin (STM) (0–5)	No improvement of the PSTD	0
	Partial coverage of the PSTD but the metallic components are still visible	1
	Complete coverage of the metallic components (or abutment) only, but the implant-supported crown is still longer than the homologous tooth	2
	Complete coverage of the metallic components with the mucosal margin at the same level of the homologous tooth	5
Peri-implant papillae height (PPH) (0–3)	Both papillae are more apical than the healthiest papilla tip of the homologous tooth	0
	Only one papilla is at the same level (or more coronal) of the healthiest papilla tip of the homologous tooth	1
	Both papillae are at the same level (or more coronal) of the healthiest papilla tip of the homologous tooth	3
Peri-implant Mucosa Color (PMC) (0–1)	Distinguishable from the adjacent soft tissue	0
	Not distinguishable from the adjacent soft tissue	1
Peri-implant Mucosa Appearance (PMA) (0–1)	Presence of at least one of these conditions: scar tissue, MGJ not-aligned, tissue volume too thin or too thick compared to the adjacent soft tissue or tissue texture not similar to the adjacent soft tissue	0
	Absence of scar tissue, MGJ well aligned, tissue volume in line with the adjacent soft tissue or tissue texture similar to the adjacent soft tissue	1

Abbreviations: MGJ, mucogingival junction; PSTD, peri-implant soft tissue dehiscence.

1. The level of the soft tissue margin (STM).
2. The peri-implant papillae height (PPH).
3. The peri-implant mucosa color (PMC).
4. The peri-implant mucosa appearance (PMA).

The score for the STM ranges between 0 and 5 based on the amount of soft tissue dehiscence coverage of the PSTD that was obtained, compared to the baseline, using the homologous unrestored tooth as the reference (Mazzotti et al., 2018; Zucchelli, Mazzotti, Mounssif, Mele, et al., 2013; Zucchelli et al., 2019). If the surgical treatment after 6 months failed to reduce the vertical depth of the PSTD a score of 0 is assigned, while a situation with a coronal advancement of the STM in a way that the depth of the PSTD is reduced (but a complete coverage of the PSTD is not achieved) is assigned with a score of 1. Treatment resulting in a complete coverage of the metallic components (or abutment) but the implant-supported crown is still longer than the homologous natural tooth is given 2 points. Five points are attributed to situations with complete coverage of the metallic components with the soft tissue margin positioned at the same level of the ideal gingival margin of the homologous natural tooth.

The PPH is assessed by comparing the level of the tip of the papillae to the one at the homologous natural tooth. A clinical situation in which both peri-implant papillae are more apical than the healthiest papilla tip of the homologous tooth is assigned 0 points, while cases with only one peri-implant papilla at the same level (or more coronal) of the healthiest papilla tip of the homologous tooth are given 1 point (Figure 3). When both peri-implant papillae are at the same level (or more coronal) of the healthiest papilla tip of the homologous tooth, 3 points are assigned.

The PMC is evaluated by comparing the color of the peri-implant soft tissue to the adjacent soft tissues. When the PMC is distinguishable from the adjacent soft tissues, 0 is assigned (Figure 1d), while if the PMC is not distinguishable from the adjacent tissues, 1 point is given.

The PMA includes the evaluation of scar tissues, level of the mucogingival junction (MGJ), soft tissue volume, and soft tissue texture using the adjacent teeth as references. Zero point is assigned if any of the following conditions are present: scar tissue, MGJ of the peri-implant soft tissue not aligned with the MGJ of the adjacent teeth, soft tissue volume too thin or thick compared to the adjacent soft tissue or tissue texture not similar to the adjacent soft tissue. When none of these conditions is observed, 1 point is given.

Figure 1 presents the esthetic evaluation of 3 PTSDs with IDES.

2.3 | Assessment of Intra- and inter-rater reliability of IDES

Four periodontists with expertise in periodontal and peri-implant plastic surgery (L.T., M.S., G.R., and HLW) from 3 centers without previous knowledge of the treated cases or patients were asked to participate in the study. Standardized clinical photographs (a single camera; Nikon D7200, Nikon Corporation) and photographer (A.R.), with the same settings, and shooting protocol (perpendicular to the long axis of the treated implant) of all cases at pre-op (prior to the procedure), and at a single follow-up timepoint (at least 6 months post-op) were gathered. All clinical photographs were compiled in a single document (Adobe Acrobat Pro DC for Mac®, version

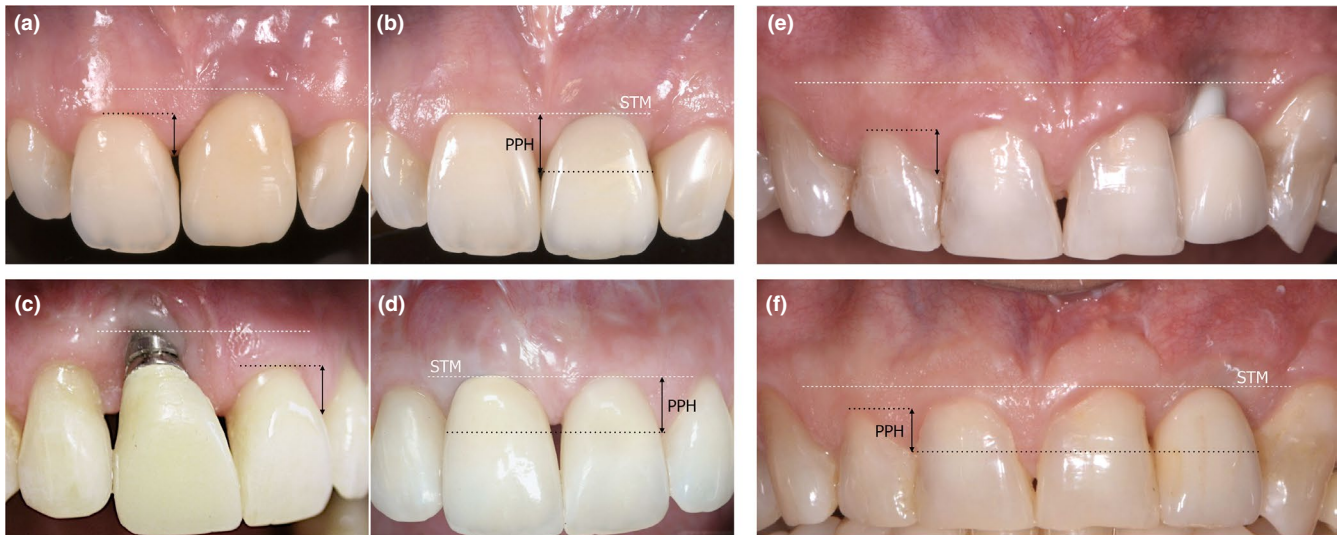


FIGURE 1 Utilization of IDES for esthetic assessment of three PSTDs (a, c, and e) for their 1-year outcomes (b, d, and f). (a) Baseline and (b) follow-up of a case that resulted in complete coverage of the soft tissue dehiscence (STM = 5 points). White dotted lines show the difference in the level of the soft tissue margin compared to the homologous tooth. Black arrows and dotted lines demonstrate the change in the level of the papilla (PPH = 1 point in this case since only one papilla is at the same level of the healthiest papilla tip of the homologous tooth). The peri-implant mucosa appearance and color are not distinguishable from the adjacent soft tissues in terms of color, texture, and volume (PMC = 1, and PMA = 1). (c) Baseline and (d) follow-up of the second case that resulted in a complete coverage of the soft tissue dehiscence (STM = 5 points, white dotted lines show the change in the levels of the soft tissue margin). Both papillae of the implant are more apical to the healthiest papilla tip of the homologous tooth (black arrows) (PPH = 0). The peri-implant mucosa color is distinguishable from the adjacent soft tissue (PMC = 0), and the peri-implant mucosa appearance is different from the adjacent sites in terms of texture and volume (PMA 0 points). (e) Baseline and (f) 1-year results of the third cases in which a partial coverage of the soft tissue dehiscence is obtained relative to the homologous tooth, as the soft tissue margin of the implant site is more apical to the gingival margin of the homologous tooth (dotted white line) (STM = 2 points). The peri-implant papillae are more apical than the healthiest papilla tip of the homologous tooth (black arrows) (PPH = 0 point), while PMC and PMA were not distinguishable from the adjacent sites (1 point each)

2020.009.20067, Adobe Incorporated) with no specific order to present each of the pre- and post-operative images of the treated cases side-by-side in a single slide, with its designated number. Meticulous attention was paid to maintain the original standardized 1:1 ratio of the clinical photographs, without any adjustments to the pictures (change in color, contract, brightness, etc.). The files were checked for any distortion to the images prior to distribution to the raters.

The reviewers were asked to provide their subjective esthetic evaluation (subjective esthetic score, SES) of the PTSD treatment, on a 0 (lowest) to 10 (highest) numeric scale, without any guidance or criteria. To eliminate potential biases no other information was provided to the raters (including the type of surgical approach/technique, or the exact follow-up timepoint [6/12 months]).

Subsequently, the examiners were instructed on the IDES rubric and provided with examples of preliminary cases along with their corresponding IDES values for clarification. Next, they were provided with two specifically designed spreadsheets (Microsoft Excel for Mac®, version 16.23, Microsoft) and were asked to rate the cases according to the IDES criteria at two different occasions (one spreadsheet at a time, and with at least 1 week apart). The raters were provided as much time as they needed to complete this task.

The aim was to assess the reliability and consistency of IDES among different examiners (inter-reliability) and among the same examiner at different timepoints (intra-reliability). Additionally, to

observe for vast differences, or correlations between the IDES-based objective assessment, and the initial SES.

2.4 | Data and statistical analysis

The gathered IDES responses were first descriptively assessed in terms of means per item and overall, and for crude agreement between pairs of raters. Next, we used variance components analysis to decompose the variation in IDES values into variance contributions for cases, examiners, and case by examiner pairs. The analysis was conducted using multilevel regression, fit in a Bayesian framework in order to facilitate construction of uncertainty intervals for fractional variance contributions and intraclass correlation values.

The multilevel regression produces estimates of the variance explained by cases, examiners, case by examiner pairs, and the variance that is unexplained. The case variance reflects true esthetic differences among the cases. The examiner variance reflects systematic differences among the examiners in scale usage, for example, if it is inflated by an examiner who consistently gives higher scores than the others. The case by examiner variance reflects reproducible (across the two repeated assessments) differences in the ratings given by one reviewer to one case, that are not explained by either a systematic behavior of the rater, or by the

true esthetic score for the case. The unexplained variance reflects differences between the two ratings provided by one examiner for one case.

The intraclass correlation coefficient (ICC) was defined by dividing the variance from one source by the variance from that source along with one or more additional sources. Most relevant here is the variance of cases relative to the combined variance from all sources. It is desirable for this ICC to be high (Koo & Li, 2016; Landis & Koch, 1977; Liljequist et al., 2019). Conversely, it is desirable for the case by examiner variance to be small, as this reflects persistent differences in judgments about the esthetics for the same case by different raters. The variance contribution for raters should also be small, as it reflects systematic differences in usage of the rating scale by different raters. All of these fractional variance contributions were presented using a Bayesian approach to obtain 95% credible intervals (CI).

Lastly, a regression approach was used to assess the relationship between the objective esthetic score (IDES as the dependent variable) and the SES (independent variable) for the assessment of the treated PTSDs. Similarly, random effects were included for case, examiner, and case by examiner pairs. The estimated intercept and slope parameters indicate the fitted relationship, and the variance parameters reflect the degree of scatter around the fitted relationship.

All data analysis, distribution of cases and preparations were performed by a separate investigator (S.B) with experience in data management and biostatistics who had not taken part in the examinations. The packages lme4 (Signorell, 2019), lmerTest (Kuznetsova et al., 2017), Rcpp (Eddelbuette, 2013; Eddelbuette & Balamuta, 2017; Eddelbuette & Francois, 2011), brms (Bürkner, 2017, 2018), arm (Wickham & Henry, 2020), tidy (Wickham & Henry, 2020), and tidybayes (Kay, 2020) in Rstudio (Version 1.3.959) were used for the statistical analyses. The plots were produced using the ggplot2 package (Wickham, 2016).

3 | RESULTS

Fifty-one PTSDs were treated in 51 patients. Table 2 describes the characteristics of the included patients and the treated implants. All the interventions were performed by the same experienced operator (G.Z) using CTG either with CAF (14 cases), a combined surgical-prosthetic approach (33 cases), or with a submerged healing (four cases; Mazzotti et al., 2018; Stefanini, Marzadori, et al., 2020; Zucchelli, Mazzotti, Mounssif, Mele, et al., 2013; Zucchelli et al., 2019). Thirteen PTSDs were class II, 22 were class III, and 16 were class IV cases (Zucchelli et al., 2019).

Table 3 and Figure 2 present the mean, median, SD, and range for the evaluated IDES among the four examiners at both evaluation attempts. Overall, only minor discrepancies existed among the raters and between different timepoints for the same rater.

Table 4 shows the absolute and fractional variance contributions of each source in the model, and for the four components of

TABLE 2 Characteristics of the included patients and implant sites at baseline

Characteristic	Value
Age (mean \pm SD) (years)	35.86 \pm 4.45
Females (n)	28
Smokers (less than 10 cigarettes/day) (n)	4
Maxillary sites (n)	43
Mandibular sites (n)	8
Central incisor sites (n)	24
Lateral incisor sites (n)	19
Canine sites (n)	2
First premolar sites (n)	4
Second premolar sites (n)	2
PSTD class II (n)	13
PSTD class III (n)	22
PSTD class IV (n)	16
PSTD subclass a (n)	13
PSTD subclass b (n)	21
PSTD subclass c (n)	17

Abbreviations: n, number; PSTD, peri-implant soft tissue dehiscence/deficiency; SD, standard deviation.

TABLE 3 Average response of the ratings by reviewers according to IDES at each timepoint

Examiner #	Attempt	Mean	SD	Range
1	1	8.27	2.18	2-10
	2	8.16	2.20	2-10
2	1	8.13	2.04	2-10
	2	8.45	2.14	2-10
3	1	8.23	1.96	2-10
	2	8.53	1.98	2-10
4	1	8.63	1.93	3-10
	2	8.48	1.74	3-10

IDES (soft tissue margin, peri-implant papillae height, peri-implant mucosa color, and peri-implant mucosa appearance), as well as the overall IDES. All models presented with a high absolute case variance conveying true esthetic differences among the treated PTSDs, and small examiner, and case by examiner variances demonstrating minor systematic variability among raters, and reproducible esthetic evaluations (persistent judgment) of the observed cases with IDES. Additionally, only a slight intra-reviewer variability between different timepoints was observed across all models (between evaluation attempts 1 and 2). This was demonstrated by a negligible residual (unexplained variance of only 2% of the total variance) that represents the changes between the two repeated measures (examiner scores for the same case). Results of the variability in assessment of IDES in terms of ICC for the evaluated cases are presented in Table 5. As shown, a high level of agreement for evaluation of the PTSDs with IDES was observed among the reviewers.

Lastly, when testing the relationship between the raters' objective and subjective esthetic responses (IDES vs. SES, respectively), results from the regression model showed that the estimated intercept parameter was not significantly different from 0, and the estimated slope parameter, 0.97, was nearly equal to 1, reflecting a near identity in the mean trend relating the two scores. The total unexplained variance was 0.79 ± 0.88 (less than 1 point on the 0–10 rating scale). This unexplained variance was 40.5% attributable to

stable examiner effects, 5.06% attributable to examiner by case interactions, 45.5% attributable to stable case effects, and 8.86% unattributable. Figure 3 plots the reviewers' final IDES evaluation and the SES of the same cases at every observed value of IDES, showing a strong similarity between the two types of scores (both on a 0–10 scale) when provided by the same rater.

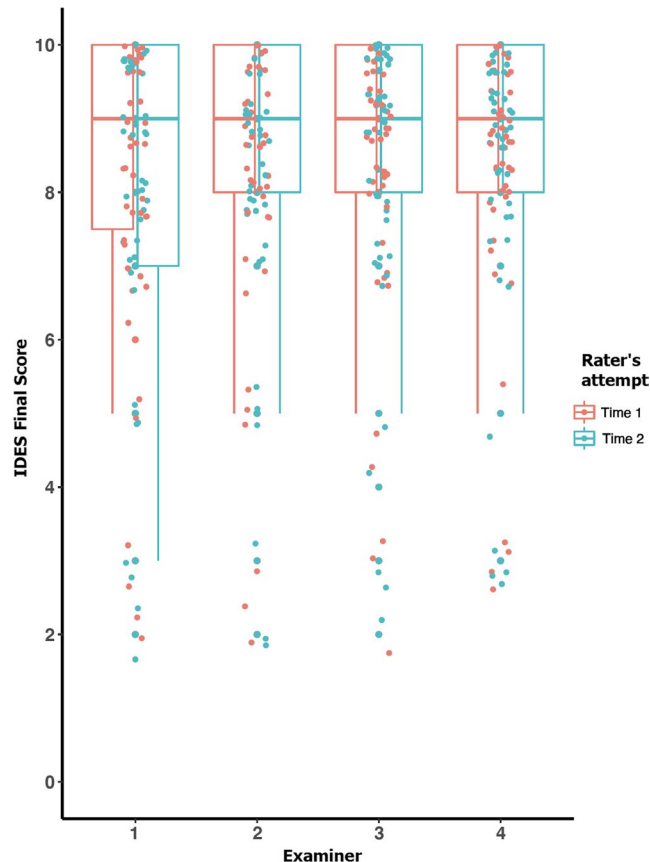


FIGURE 2 Boxplots demonstrating the reviewers' final IDES assessment for the PTSDs at both occasions

4 | DISCUSSION

The importance of incorporating a professional esthetic evaluation in dentistry has been extensively highlighted (Belser et al., 2009; Cairo et al., 2009; Dueled et al., 2009; Furhauser et al., 2005; Meijer et al., 2005; Stefanini et al., 2018). According to Stefanini et al., the main advantages of objective methods for evaluating esthetic outcomes after single tooth-implant rehabilitation in the esthetic area are as follows: (a) the possibility of assessing improvements in patient appearance following implant therapy, (b) education of students and/or technicians for providing certain standard and objective esthetic parameters, and (c) the comparison between different approaches and studies in the literature (Stefanini et al., 2018).

Several esthetic scores have been proposed for evaluating the outcomes of implant therapy, including the papilla index (Jemt, 1999), the Pink Esthetic Score/White Esthetic score (PES/WES) (Belser et al., 2009; Furhauser et al., 2005), the Implant Crown Aesthetic Index (Meijer et al., 2005), the Complex Esthetic Index (Juodzbaly & Wang, 2010), and the Copenhagen Index Score (Dueled et al., 2009). Most of these indices focus on the outcome of implant rehabilitation including the appearance of the implant-supported crown, using the healthy homologous contralateral tooth and/or the adjacent teeth as references (Benic et al., 2012; Stefanini et al., 2018). Interestingly, there is no consensus on the most reproducible or accurate esthetic score for describing the esthetic outcomes after rehabilitation of a single implant site in the esthetic area (Stefanini et al., 2018; Tettamanti et al., 2016).

The present article introduces a new esthetic score specifically for the treatment of PTSDs. Given their rising incidence, and

TABLE 4 The absolute and fractional variance contributions of IDES and the 4 individual constituents of the score

Variable	Absolute variance contributions				Fractional variance contributions			
	Case	Case by examiner	Examiner	Residual	Case	Case by examiner	Examiner	Residual
IDES	1.95	0.66	0.17	0.27	0.86	0.21	0.009	0.002
Soft tissue margin (STM)	1.04	0.26	0.17	0.21	0.87	0.05	0.03	0.03
Peri-implant papilla height (PPH)	0.88	0.45	0.08	0.05	0.78	0.20	0.01	0.002
Peri-implant mucosa color (PMC)	0.89	0.45	0.07	0.05	0.79	0.21	0.009	0.002
Peri-implant mucosa appearance (PMA)	0.88	0.45	0.08	0.05	0.78	0.20	0.013	0.002

Note: Note that the absolute variance contributions are shown as SDs, the fractional contributions are calculated from variances. Abbreviation: IDES, Peri-Implant soft tissue Dehiscence coverage Esthetic Score.

the notion that these esthetic complications are completely different from edentulous sites or hopeless teeth restored with dental implants, the need for a novel and exclusive index can be readily

TABLE 5 ICC results for the variability in the assessment of the overall IDES, and the individual components among the evaluated cases

Variable	ICC	95% CIs (lower-upper bound)
IDES	0.86	0.78–0.91
Soft tissue margin (STM)	0.87	0.68–0.93
Peri-implant papilla height (PPH)	0.78	0.67–0.85
Peri-implant mucosa color (PMC)	0.79	0.68–0.86
Peri-implant mucosa appearance (PMA)	0.78	0.67–0.85

Abbreviations: CI, credible intervals; ICC, intraclass correlation coefficient; IDES, Peri-Implant soft tissue Dehiscence coverage Esthetic Score.

appreciated. Especially considering the lack of a standardized or specifically designed tool for their esthetic assessment has led studies reporting on PTSDs to utilize a large variety of indices with different criteria, hence rendering a direct or indirect comparison among the studies, or the treatments almost impossible (Anderson et al., 2014; Rocuzzo et al., 2014; Zucchelli et al., 2018; Zucchelli, Mazzotti, Mounssif, Mele, et al., 2013).

The IDES is based on the evaluation of the final position of the soft tissue margin compared to the homologous tooth, the height of the peri-implant papillae, the peri-implant mucosa color, and its appearance, as it has been shown that the surgical treatment of PTSDs can improve these parameters (Mazzotti et al., 2018; Zucchelli et al., 2018, 2019; Zucchelli, Mazzotti, Mounssif, Marzadori, et al., 2013; Zucchelli, Mazzotti, Mounssif, Mele, et al., 2013). Our analysis showed that the IDES is an overall objective score for evaluating the esthetic outcomes of PTSD treatment among different operators, with an overall ICC for the final IDES of 0.86, which indicates very high (and almost perfect) agreement (Landis & Koch, 1977). This result is in line with the ICC reported by previous studies in periodontal plastic surgery assessing the reliability of new methods for

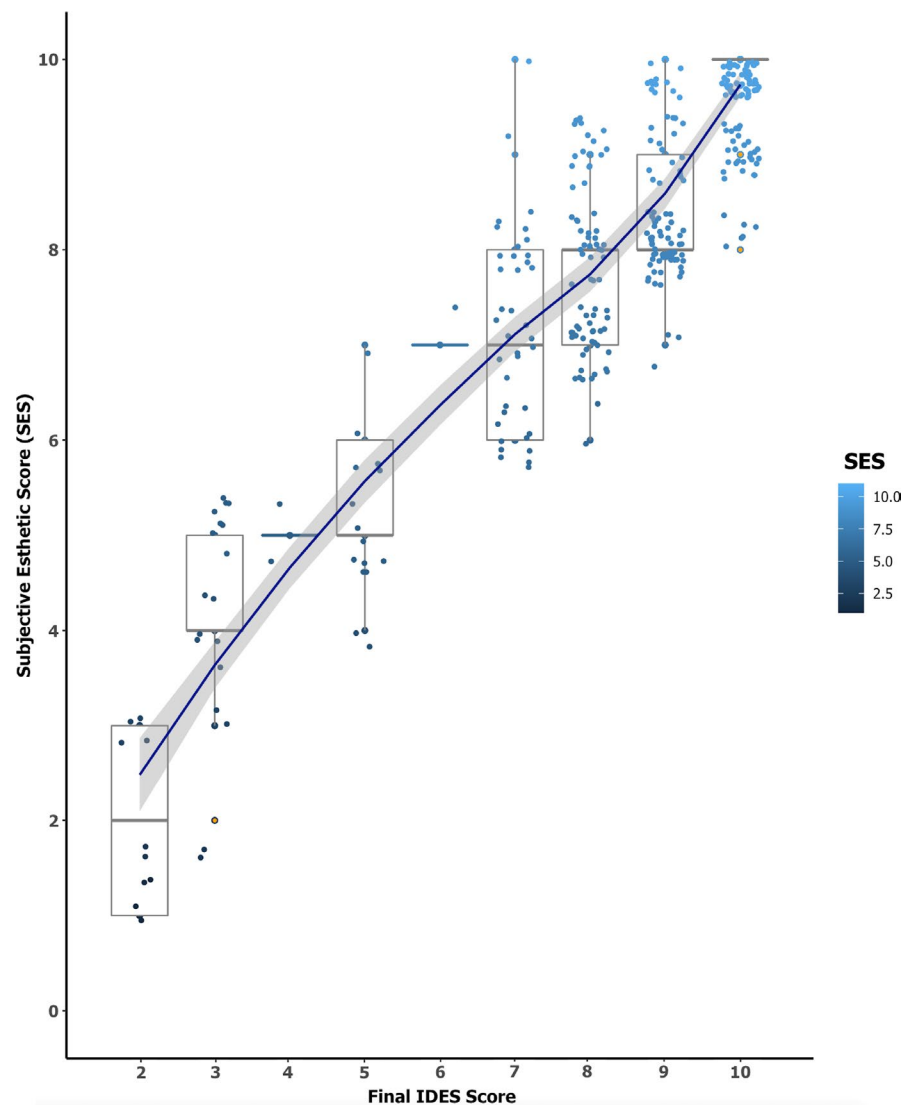


FIGURE 3 Comparison between reviewers' objective evaluation of treated PTSDs with IDES and their subjective esthetic scores (SES) for all cases. The Loess curve (dark blue line) shows the estimated conditional mean relationship between the two scores

classifying gingival recessions (Cairo et al., 2011), or a new index for assessing root coverage esthetic outcomes (Cairo et al., 2010; Isaia et al., 2018).

The highest ICC among the four IDES parameters was obtained by the STM (0.87). It is reasonable to assume that a partial coverage of the PSTD can be easily identifiable, particularly when the metallic component is still visible or with the implant-supported crown still longer than the homologous tooth. Thus, leading to less variability in the assessment of this component and its scoring. Additionally, only a slight intra-reviewer variability between different timepoints was observed among the same examiners, further corroborating the reproducibility of the IDES.

Similar to the root coverage esthetic score for natural teeth (Cairo et al., 2009), the final IDES is largely dependent upon the STM (5 points out of 10). This highlights the negative impact of a partial coverage, and the exposure of the metallic components, or a longer implant-supported crown on the esthetic outcomes of the treatment (Rocuzzo et al., 2014; Zucchelli et al., 2019). Additionally, the present esthetic score emphasizes the importance of the level of the interproximal soft tissues/peri-implant papillae (3 out of 10 points), as shallow papillae that give rise to “black triangles” are frequent findings at implant sites that lead to compromised esthetics (Stefanini, Marzadori, et al., 2020; Urban et al., 2016). It has been shown that during the treatment of a PTSD, along with improvement in the level of the STM, the implant papillae can also be augmented, even at sites with periodontal attachment loss on the adjacent teeth (Stefanini, Marzadori, et al., 2020).

Another important finding from our analysis was the strong correlation between the SES and the final IDES in all examiners. This result suggests that the IDES may be a valid alternative to subjective esthetic assessment among periodontists, with the advantage of providing an esthetic evaluation for each individual parameter of interest at the same time. This can be very beneficial when comparing different surgical techniques or grafting materials.

The present study, despite bearing the advantage of having a large sample of treated cases, and all by a single experienced operator, may inadvertently also carry a limitation as a result of these components. We emphasize that all the treated cases had been performed by an expert clinician and involved the use of a CTG. While the importance of an experienced surgeon in treatment of PTSDs cannot be overstated, with regard to the use of a CTG, indeed its properties of enhancing blood clot, flap stability, increasing keratinized tissue width/soft tissue thickness, and the possibility of creeping attachment (Tavelli et al., 2019, 2020) have rendered it the gold standard for root coverage (Barootchi et al., 2019, 2020; Mazzotti et al., 2018; Zucchelli et al., 2019). Therefore, future studies are needed for further validation of IDES, including different flap designs (e.g., the tunnel approach; Aroca et al., 2013; Tavelli et al., 2018; Zuhr et al., 2014) and grafting materials (e.g., acellular dermal or collagen matrices; Barootchi, Tavelli, Gianfilippo, et al., 2020; Stefanini, Mounssif, et al., 2020), as well as execution by less proficient

clinicians. Also, given the current pilot study design, we deem necessary future investigations with a larger number of examiners, as well as assessments by less experienced audience to test the consistency in ratings with the IDES, and indeed the relationship with a subjective approach.

5 | CONCLUSIONS

The present article introduces a novel esthetic score for evaluating the outcomes of the treatment of PTSDs. A high level of agreement for evaluating the treatment of PTSDs was observed with IDES among examiners, and within the same examiner between different timepoints. These results, together with a strong correlation found between the final IDES and the subjective esthetic assessments, suggest that the proposed IDES is a reliable tool for evaluating the esthetic outcomes of PTSD coverage. This newly introduced system can aid in standardization of esthetic assessments following the treatment of PTSDs and encourage the incorporation of clinical and esthetic outcomes.

ACKNOWLEDGEMENTS

The authors would like to express their gratitude to Prof. Kerby Sheddan (Department of Biostatistics, University of Michigan, Ann Arbor) for his valuable feedback and guidance on the statistical methods, as well as Alexandra Rendon for serving as the photographer in this study, and Claudio Mazzotti for their valued assistance. The authors declare no potential conflict of interest with respect to the publication of this article, or any of the materials utilized throughout the study.

AUTHORS' CONTRIBUTION

G. Z involved in contribution to the study design, provided all clinical aspects of the work, gave final approval of the version to be published with critical manuscript review, and accountable for all aspects of the work. S. B involved in conception and design of the study; analysis and interpretation of data; initial and final drafting of the work; final approval of the version to be published, accountable for all aspects of the work. L. T involved in design of the study, served as an examiner, manuscript preparation and the initial draft, final review of the work, accountable for all aspects of the work. M. S and G. R served as an examiner, manuscript preparation and the initial draft, final review of the work, accountable for all aspects of the work. H-L.W involved in design of the study, critical review of the draft of the manuscript, served as one of the 4 case examiners, final review and approval of the work and accountable for all aspects.

ORCID

Shayan Barootchi  <https://orcid.org/0000-0002-5347-6577>

Lorenzo Tavelli  <https://orcid.org/0000-0003-4864-3964>

Martina Stefanini  <https://orcid.org/0000-0002-9154-637X>

Hom-Lay Wang  <https://orcid.org/0000-0003-4238-1799>

REFERENCES

- Anderson, L. E., Inglehart, M. R., El-Kholy, K., Eber, R., & Wang, H. L. (2014). Implant associated soft tissue defects in the anterior maxilla: A randomized control trial comparing subepithelial connective tissue graft and acellular dermal matrix allograft. *Implant Dentistry*, 23(4), 416–425. <https://doi.org/10.1097/ID.0000000000000122>
- Aroca, S., Molnar, B., Windisch, P., Gera, I., Salvi, G. E., Nikolidakis, D., & Sculean, A. (2013). Treatment of multiple adjacent Miller class I and II gingival recessions with a Modified Coronally Advanced Tunnel (MCAT) technique and a collagen matrix or palatal connective tissue graft: A randomized, controlled clinical trial. *Journal of Clinical Periodontology*, 40(7), 713–720. <https://doi.org/10.1111/jcpe.12112>
- Barootchi, S., Tavelli, L., Di Gianfilippo, R., Byun, H.-Y., Oh, T.-J., Barbato, L., Cairo, F., & Wang, H.-L. (2019). Long term assessment of root coverage stability using connective tissue graft with or without an epithelial collar for gingival recession treatment. A 12-year follow-up from a randomized clinical trial. *Journal of Clinical Periodontology*, 46(11), 1124–1133. <https://doi.org/10.1111/jcpe.13187>
- Barootchi, S., Tavelli, L., Gianfilippo, R. D., Eber, R., Stefanini, M., Zucchelli, G., & Wang, H. L. (2020). Acellular dermal matrix for root coverage procedures: 9-year assessment of treated isolated gingival recessions and their adjacent untreated sites. *Journal of Periodontology*. <https://doi.org/10.1002/JPER.20-0310>
- Barootchi, S., Tavelli, L., Zucchelli, G., Giannobile, W. V., & Wang, H. L. (2020). Gingival phenotype modification therapies on natural teeth: A network meta-analysis. *Journal of Periodontology*, 91(11), 1386–1399. <https://doi.org/10.1002/JPER.19-0715>
- Belser, U. C., Grutter, L., Vailati, F., Bornstein, M. M., Weber, H. P., & Buser, D. (2009). Outcome evaluation of early placed maxillary anterior single-tooth implants using objective esthetic criteria: A cross-sectional, retrospective study in 45 patients with a 2- to 4-year follow-up using pink and white esthetic scores. *Journal of Periodontology*, 80(1), 140–151. <https://doi.org/10.1902/jop.2009.080435>
- Bengazi, F., Wennstrom, J. L., & Lekholm, U. (1996). Recession of the soft tissue margin at oral implants. A 2-year longitudinal prospective study. *Clinical Oral Implants Research*, 7(4), 303–310. <https://doi.org/10.1034/j.1600-0501.1996.070401.x>
- Benic, G. I., Wolleb, K., Sancho-Puchades, M., & Hammerle, C. H. (2012). Systematic review of parameters and methods for the professional assessment of aesthetics in dental implant research. *Journal of Clinical Periodontology*, 39(Suppl. 12), 160–192. <https://doi.org/10.1111/j.1600-051X.2011.01840.x>
- Berglundh, T., Armitage, G., Araujo, M. G., Avila-Ortiz, G., Blanco, J., Camargo, P. M., Chen, S., Cochran, D., Derks, J., Figuero, E., Hämmerle, C. H. F., Heitz-Mayfield, L. J. A., Huynh-Ba, G., Iacono, V., Koo, K.-T., Lambert, F., McCauley, L., Quirynen, M., Renvert, S., Zitzmann, N. (2018). Peri-implant diseases and conditions: Consensus report of workgroup 4 of the 2017 World Workshop on the Classification of Periodontal and Peri-Implant Diseases and Conditions. *Journal of Periodontology*, 89(Suppl. 1), S313–S318. <https://doi.org/10.1002/JPER.17-0739>
- Burkhardt, R., Joss, A., & Lang, N. P. (2008). Soft tissue dehiscence coverage around endosseous implants: A prospective cohort study. *Clinical Oral Implants Research*, 19(5), 451–457. <https://doi.org/10.1111/j.1600-0501.2007.01497.x>
- Bürkner, P. C. (2017). brms: An R package for Bayesian multilevel models using stan. *Journal of Statistical Software*, 80(1), 1–28. <https://doi.org/10.18637/jss.v080.i01>
- Bürkner, P. C. (2018). Advanced Bayesian multilevel modeling with the R package brms. *The R Journal*, 10(1), 395–411. <https://doi.org/10.32614/RJ-2018-017>
- Cairo, F., Nieri, M., Cattabriga, M., Cortellini, P., De Paoli, S., De Sanctis, M., Fonzar, A., Francetti, L., Merli, M., Rasperini, G., Silvestri, M., Trombelli, L., Zucchelli, G., & Pini-Prato, G. P. (2010). Root coverage esthetic score after treatment of gingival recession: An interrater agreement multicenter study. *Journal of Periodontology*, 81(12), 1752–1758. <https://doi.org/10.1902/jop.2010.100278>
- Cairo, F., Nieri, M., Cincinelli, S., Mervelt, J., & Pagliaro, U. (2011). The interproximal clinical attachment level to classify gingival recessions and predict root coverage outcomes: An explorative and reliability study. *Journal of Clinical Periodontology*, 38(7), 661–666. <https://doi.org/10.1111/j.1600-051X.2011.01732.x>
- Cairo, F., Rotundo, R., Miller, P. D., & Pini Prato, G. P. (2009). Root coverage esthetic score: A system to evaluate the esthetic outcome of the treatment of gingival recession through evaluation of clinical cases. *Journal of Periodontology*, 80(4), 705–710. <https://doi.org/10.1902/jop.2009.080565>
- Chen, S. T. & Buser, D. (2014). Esthetic outcomes following immediate and early implant placement in the anterior maxilla—A systematic review. *International Journal of Oral and Maxillofacial Implants*, 29(Suppl), 186–215. <https://doi.org/10.11607/jomi.2014suppl.g3.3>
- Chu, S. J. & Tarnow, D. P. (2013). Managing esthetic challenges with anterior implants. Part 1: Midfacial recession defects from etiology to resolution. *Compendium of Continuing Education in Dentistry*, 34 Spec No 7, 26–31.
- Cosyn, J., Hooghe, N., & De Bruyn, H. (2012). A systematic review on the frequency of advanced recession following single immediate implant treatment. *Journal of Clinical Periodontology*, 39(6), 582–589. <https://doi.org/10.1111/j.1600-051X.2012.01888.x>
- Cosyn, J., Sabzevar, M. M., & De Bruyn, H. (2012). Predictors of inter-proximal and midfacial recession following single implant treatment in the anterior maxilla: A multivariate analysis. *Journal of Clinical Periodontology*, 39(9), 895–903. <https://doi.org/10.1111/j.1600-051X.2012.01921.x>
- Dueled, E., Gotfredsen, K., Trab Damsgaard, M., & Hede, B. (2009). Professional and patient-based evaluation of oral rehabilitation in patients with tooth agenesis. *Clinical Oral Implants Research*, 20(7), 729–736. <https://doi.org/10.1111/j.1600-0501.2008.01698.x>
- Edelbuette, D. (2013). *Seamless R and C++ Integration with Rcpp*. Springer.
- Edelbuettel, D. & Balamuta, J. J. (2017). Extending R with C++: A brief introduction to Rcpp. *PeerJ Preprints*, 5, e3188v3181. <https://doi.org/10.7287/peerj.preprints.3188v1>
- Edelbuettel, D. & François, R. (2011). Rcpp: Seamless R and C++ integration. *Journal of Statistical Software*, 40(8), 1–18. <https://doi.org/10.18637/jss.v040.i08>
- Furhauser, R., Florescu, D., Benesch, T., Haas, R., Mailath, G., & Watzek, G. (2005). Evaluation of soft tissue around single-tooth implant crowns: The pink esthetic score. *Clinical Oral Implants Research*, 16(6), 639–644. <https://doi.org/10.1111/j.1600-0501.2005.01193.x>
- Happe, A., Stimmelmayer, M., Schlee, M., & Rothamel, D. (2013). Surgical management of peri-implant soft tissue color mismatch caused by shine-through effects of restorative materials: One-year follow-up. *The International Journal of Periodontics and Restorative Dentistry*, 33(1), 81–88. <https://doi.org/10.11607/prd.1344>
- Isaia, F., Gyurko, R., Roomian, T. C., & Hawley, C. E. (2018). The root coverage esthetic score: Intra-examiner reliability among dental students and dental faculty. *Journal of Periodontology*, 89(7), 833–839. <https://doi.org/10.1002/JPER.17-0556>
- Jemt, T. (1999). Restoring the gingival contour by means of provisional resin crowns after single-implant treatment. *International Journal of Periodontics Restorative Dentistry*, 19(1), 20–29.
- Juodzbals, G. & Wang, H. L. (2010). Esthetic index for anterior maxillary implant-supported restorations. *Journal of Periodontology*, 81(1), 34–42. <https://doi.org/10.1902/jop.2009.090385>
- Kay, M. (2020). tidybayes: Tidy data and geoms for Bayesian models.
- Khazam, N., Arora, H., Kim, P., Fisher, A., Mattheos, N., & Ivanovski, S. (2015). Systematic review of soft tissue alterations and esthetic outcomes following immediate implant placement and restoration of single implants in the anterior maxilla. *Journal of Periodontology*, 86(12), 1321–1330. <https://doi.org/10.1902/jop.2015.150287>

- Koo, T. K. & Li, M. Y. (2016). A guideline of selecting and reporting intra-class correlation coefficients for reliability research. *Journal of Chiropractic Medicine*, 15(2), 155–163. <https://doi.org/10.1016/j.jcm.2016.02.012>
- Kuznetsova, A., Brockhoff, P. B., & Christensen, R. H. (2017). lmer test package: Tests in linear mixed effects models. *Journal of Statistical Software*, 82(13), 1–26. <https://doi.org/10.18637/jss.v082.i13>
- Lai, Y. L., Chen, H. L., Chang, L. Y., & Lee, S. Y. (2010). Resubmergence technique for the management of soft tissue recession around an implant: Case report. *International Journal of Oral and Maxillofacial Implants*, 25(1), 201–204.
- Landis, J. R., & Koch, G. G. (1977). The measurement of observer agreement for categorical data. *Biometrics*, 33(1), 159–174. <https://doi.org/10.2307/2529310>
- Liljequist, D., Elfving, B., & Skavberg Roaldsen, K. (2019). Intraclass correlation – A discussion and demonstration of basic features. *PLoS One*, 14(7), e0219854. <https://doi.org/10.1371/journal.pone.0219854>
- Mazzotti, C., Stefanini, M., Felice, P., Bentivogli, V., Mounssif, I., & Zucchelli, G. (2018). Soft-tissue dehiscence coverage at peri-implant sites. *Periodontology 2000*, 77(1), 256–272. <https://doi.org/10.1111/prd.12220>
- Meijer, H. J., Stellingsma, K., Meijndert, L., & Raghoobar, G. M. (2005). A new index for rating aesthetics of implant-supported single crowns and adjacent soft tissues—The Implant Crown Aesthetic Index. *Clinical Oral Implants Research*, 16(6), 645–649. <https://doi.org/10.1111/j.1600-0501.2005.01128.x>
- O'Brien, B. C., Harris, I. B., Beckman, T. J., Reed, D. A., & Cook, D. A. (2014). Standards for reporting qualitative research: A synthesis of recommendations. *Academic Medicine*, 89(9), 1245–1251. <https://doi.org/10.1097/ACM.0000000000000388>
- Rocuzzo, M., Dalmasso, P., Pittoni, D., & Rocuzzo, A. (2019). Treatment of buccal soft tissue dehiscence around single implant: 5-year results from a prospective study. *Clinical Oral Investigations*, 23(4), 1977–1983. <https://doi.org/10.1007/s00784-018-2634-4>
- Rocuzzo, M., Gaudio, L., Bunino, M., & Dalmasso, P. (2014). Surgical treatment of buccal soft tissue recessions around single implants: 1-year results from a prospective pilot study. *Clinical Oral Investigations*, 25(6), 641–646. <https://doi.org/10.1111/clr.12149>
- Sanz-Martin, I., Regidor, E., Navarro, J., Sanz-Sanchez, I., Sanz, M., & Ortiz-Vigon, A. (2020). Factors associated with the presence of peri-implant buccal soft tissue dehiscences: A case-control study. *Journal of Periodontology*, <https://doi.org/10.1002/JPER.19-0490>
- Signorell, A. (2019). DescTools: Tools for descriptive statistics.
- Small, P. N., Tarnow, D. P., & Cho, S. C. (2001). Gingival recession around wide-diameter versus standard-diameter implants: A 3- to 5-year longitudinal prospective study. *Pract Proced Aesthet Dent*, 13(2), 143–146.
- Stefanini, M., Felice, P., Mazzotti, C., Mounssif, I., Marzadori, M., & Zucchelli, G. (2018). Esthetic evaluation and patient-centered outcomes in single-tooth implant rehabilitation in the esthetic area. *Periodontology 2000*, 77(1), 150–164. <https://doi.org/10.1111/prd.12215>
- Stefanini, M., Marzadori, M., Tavelli, L., Bellone, P., & Zucchelli, G. (2020). Peri-implant papillae reconstruction at an esthetically failing implant. *The International Journal of Periodontics & Restorative Dentistry*, 40(2), 213–222. <https://doi.org/10.11607/prd.4296>
- Stefanini, M., Mounssif, I., Barootchi, S., Tavelli, L., Wang, H. L., & Zucchelli, G. (2020). An exploratory clinical study evaluating safety and performance of a volume-stable collagen matrix with coronally advanced flap for single gingival recession treatment. *Clinical Oral Investigations*, 24(9), 3181–3191. <https://doi.org/10.1007/s00784-019-03192-5>
- Tavelli, L., Barootchi, S., Avila-Ortiz, G., Urban, I. A., Giannobile, W. V., & Wang, H. L. (2020). Peri-implant soft tissue phenotype modification and its impact on peri-implant health: A systematic review and network meta-analysis. *Journal of Periodontology*. <https://doi.org/10.1002/JPER.19-0716>
- Tavelli, L., Barootchi, S., Cairo, F., Rasperini, G., Shedden, K., & Wang, H. L. (2019). The effect of time on root coverage outcomes: A network meta-analysis. *Journal of Dental Research*, 98(11), 1195–1203. <https://doi.org/10.1177/0022034519867071>
- Tavelli, L., Barootchi, S., Nguyen, T. V. N., Tattan, M., Ravida, A., & Wang, H. L. (2018). Efficacy of tunnel technique in the treatment of localized and multiple gingival recessions: A systematic review and meta-analysis. *Journal of Periodontology*, 89(9), 1075–1090. <https://doi.org/10.1002/JPER.18-0066>
- Tettamanti, S., Millen, C., Gavric, J., Buser, D., Belser, U. C., Bragger, U., & Wittneben, J. G. (2016). Esthetic evaluation of implant crowns and peri-implant soft tissue in the anterior Maxilla: Comparison and reproducibility of three different indices. *Clinical Implant Dentistry and Related Research*, 18(3), 517–526. <https://doi.org/10.1111/cid.12306>
- Urban, I. A., Klokkevold, P. R., & Takei, H. H. (2016). Abutment-supported papilla: A combined surgical and prosthetic approach to papilla reformation. *The International Journal of Periodontics & Restorative Dentistry*, 36(5), 665–671. <https://doi.org/10.11607/prd.2817>
- Wickham, H. (2016). Ggplot2: Elegant graphics for data analysis.
- Wickham, H. & Henry, L. (2020). tidy: Tidy messy data.
- Zucchelli, G., Felice, P., Mazzotti, C., Marzadori, M., Mounssif, I., Monaco, C., & Stefanini, M. (2018). 5-year outcomes after coverage of soft tissue dehiscence around single implants: A prospective cohort study. *European Journal of Oral Implantology*, 11(2), 215–224.
- Zucchelli, G., Mazzotti, C., Mounssif, I., Marzadori, M., & Stefanini, M. (2013). Esthetic treatment of peri-implant soft tissue defects: A case report of a modified surgical-prosthetic approach. *The International Journal of Periodontics and Restorative Dentistry*, 33(3), 327–335. <https://doi.org/10.11607/prd.1632>
- Zucchelli, G., Mazzotti, C., Mounssif, I., Mele, M., Stefanini, M., & Montebugnoli, L. (2013). A novel surgical-prosthetic approach for soft tissue dehiscence coverage around single implant. *Clinical Oral Implants Research*, 24(9), 957–962. <https://doi.org/10.1111/clr.12003>
- Zucchelli, G., Tavelli, L., Stefanini, M., Barootchi, S., Mazzotti, C., Gori, G., & Wang, H. L. (2019). Classification of facial peri-implant soft tissue dehiscence/deficiencies at single implant sites in the esthetic zone. *Journal of Periodontology*, 90(10), 1116–1124. <https://doi.org/10.1002/JPER.18-0616>
- Zuhr, O., Rebele, S. F., Schneider, D., Jung, R. E., & Hurzeler, M. B. (2014). Tunnel technique with connective tissue graft versus coronally advanced flap with enamel matrix derivative for root coverage: A RCT using 3D digital measuring methods. Part I. Clinical and patient-centered outcomes. *Journal of Clinical Periodontology*, 41(6), 582–592. <https://doi.org/10.1111/jcpe.12178>

SUPPORTING INFORMATION

Additional supporting information may be found online in the Supporting Information section.

How to cite this article: Zucchelli G, Barootchi S, Tavelli L, Stefanini M, Rasperini G, Wang H-L. Implant soft tissue Dehiscence coverage Esthetic Score (IDES): A pilot within- and between-rater analysis of consistency in objective and subjective scores. *Clin Oral Impl Res*. 2021;32:349–358. <https://doi.org/10.1111/clr.13706>