

# Chicago Classification Update (v4.0): Technical review on diagnostic criteria for hypercontractile esophagus

Joan W. Chen<sup>1</sup>  | Edoardo Savarino<sup>2</sup> | André Smout<sup>3</sup> | Yinglian Xiao<sup>4</sup> | Nicola de Bortoli<sup>5</sup>  | Rena Yadlapati<sup>6</sup>  | Charles Cock<sup>7</sup> 

<sup>1</sup>Division of Gastroenterology & Hepatology, University of Michigan, Ann Arbor, MI, USA

<sup>2</sup>Department of Surgery, Oncology and Gastroenterology, University of Padua, Padua, Italy

<sup>3</sup>Department of Gastroenterology & Hepatology, Amsterdam University Medical Center, Amsterdam, the Netherlands

<sup>4</sup>Department of Gastroenterology, The First Affiliated Hospital, Sun Yat-Sen University, Guangzhou, China

<sup>5</sup>Department of Translational Research and New Technologies in Medicine and Surgery, University of Pisa, Pisa, Italy

<sup>6</sup>Division of Gastroenterology & Hepatology, Center for Esophageal Diseases, University of California San Diego, La Jolla, CA, USA

<sup>7</sup>Department of Gastroenterology & Hepatology, Flinders University, Adelaide, SA, Australia

## Correspondence

Joan W. Chen, Division of Gastroenterology & Hepatology, University of Michigan, 1500 E, Medical Center Dr., SPC 5362, Ann Arbor, MI 48109, USA  
Email: chenjoan@med.umich.edu

## Abstract

Hypercontractile esophagus (HE), defined by the Chicago Classification version 3.0 (CCv3.0) as 20% or more hypercontractile peristalsis (Distal Contractile Integral >8000 mmHg-s-cm) on high-resolution manometry (HRM), is a heterogeneous disorder with variable clinical presentations and natural course, leading to management challenges. An update on the diagnostic criteria for clinically relevant HE was needed. Literature on HE was extensively reviewed by the HE subgroup of the Chicago Classification version 4.0 (CCv4.0) Working Group and statements relating to the diagnosis of HE were ranked according to the RAND UCLA Appropriateness methodology by the Working Group, and the quality of evidence was rated using the Grading of Recommendations Assessment, Development, and Evaluation (GRADE) framework. An overall emphasis of the CCv4.0 is on clinically relevant esophageal dysmotility, and thus it is recommended that an HE diagnosis requires both conclusive manometric diagnosis and clinically relevant symptoms of dysphagia and non-cardiac chest pain. The Working Group also recognized the subtypes of HE, including single-peaked, multi-peaked contractions (Jackhammer esophagus), and hypercontractile lower esophageal sphincter. However, there are no compelling data currently for formally subdividing HE to these subgroups in clinical practice.

## KEYWORDS

Chicago Classification, dysphagia, hypercontractile esophagus, jackhammer esophagus, non-cardiac chest pain

## 1 | INTRODUCTION

The Chicago Classification system established a common language for gastroenterologists evaluating esophageal dysmotility using high-resolution manometry (HRM). The last iteration of the Chicago Classification, version 3.0 (CCv3.0), was published in 2015.<sup>1</sup> Since then, there has been a plethora of data using new metrics and provocation maneuvers and the introduction of novel diagnostic tools, prompting the initiation to update the diagnostic criteria. The recently published Chicago Classification version 4.0 (CCv4.0) was developed with the help of 52 international HRM Working Group members utilizing formally validated methodologies.<sup>2</sup> The Working Group members were assigned, depending on their areas of expertise, to seven subgroups—the protocol, achalasia, esophagogastric outflow obstruction (EGJOO), diffuse esophageal spasm (DES), hypercontractile esophagus (HE), ineffective esophageal motility (IEM), and esophagogastric junction barrier subgroups. In this technical review, the HE subgroup describes the process of developing initial statements and assessing agreement for the statements, reviewing statements that reached agreement and were included in the final CCv4.0 as well as concepts that did not reach agreement or did not meet criteria as formal recommendations. Further, using the updated criteria and current clinical data, the HE subgroup proposes a diagnostic algorithm, management considerations, and therapeutic options for HE.

## 2 | METHODS

In the CCv4.0 process, one working group consisting of seven members was dedicated to HE. This working group, led by two co-chairs, was tasked with developing statements regarding a conclusive clinical and manometric definition of HE, and describing further testing supporting a clinical diagnosis of HE based on literature review and expert consensus. As detailed in the main CCv4.0 document, each proposed statement underwent two rounds of independent ranking by the entire CCv4.0 Working Group according to the RAND UCLA Appropriateness Methodology to determine appropriateness of each statement. Statements with  $\geq 85\%$  agreement as appropriate were considered strong recommendations, while those with 80 to 85% agreement as appropriate were considered conditional recommendations. Statements nearly meeting criteria and/or those generating controversy were discussed at working group meetings. Additionally, statements that met criteria for inclusion in the final CCv4.0 underwent further independent evaluation to assess the level of supportive evidence, using the Grading of Recommendations Assessment, Development, and Evaluation (GRADE) process, when possible.<sup>3</sup> Two experts external to the working subgroups independently evaluated the supportive literature provided by the subgroups. Some statements were not amenable to the GRADE process, either because of the structure of the statement or lack of available evidence. This technical review reports the statements raised by a

### Key Points

- Clinically relevant symptoms (dysphagia, non-cardiac chest pain) are now required for a diagnosis of hypercontractile esophagus.
- Recognition of various HE contractile morphologies (single-peaked, multi-peaked/Jackhammer, and vigorous LES after-contraction) although formal HE subtype is not currently recommended.

group of experts assigned by the CCv4.0 Working Group to update the definition of HE.

## 3 | RESULTS

### 3.1 | Statements with agreement

Recommended statements regarding Hypercontractile esophagus (HE) that yielded high levels of agreement from the CCv4.0 Working Group are listed in Table 1.

**Statement 1.** *Hypercontractile esophagus describes a distinct manometric abnormality defined by excessive peristaltic vigor, which may include excessive lower esophageal sphincter (LES) after-contraction, not associated with a mechanical obstruction. (84% Appropriate, conditional recommendation, very low-grade evidence).*

Hypercontractile esophagus, initially coined nutcracker esophagus in the era of conventional manometry, describes a disorder associated with non-cardiac chest pain or dysphagia and characterized by high amplitude but normally propagated peristaltic contractions.<sup>4</sup> The pathophysiology is thought to involve excessive cholinergic stimulation. The threshold for a manometric diagnosis of HE has evolved; however, the term continues to describe excessive peristaltic vigor found in a symptomatic patient in the absence of esophageal obstruction. The exclusion of a mechanical obstruction is critical as distal esophageal obstruction can induce an esophageal body hypercontractile response. For instance, esophageal hypercontraction has been demonstrated in the setting of a tight laparoscopic gastric band that normalized after deflation of the band.<sup>5</sup>

**Statement 2.** *A hypercontractile esophageal contraction is defined as a DCI  $>8000$  mmHg-s-cm (84% Appropriate, conditional recommendation, low-grade evidence).*

In the era of HRM and esophageal pressure topography (EPT), the Distal Contractile Integral (DCI) is used as the summary metric reflecting the vigor of the distal esophageal contraction. Initially, a DCI of 5000 mmHg-s-cm, which approximately corresponds to nutcracker esophagus in conventional manometry, was used as the cutoff for hypertensive peristalsis.<sup>6,7</sup> However, using this threshold value, hypertensive peristalsis was seen in up to 5% of an asymptomatic control population. In a study by Roman et al, a maximum DCI of 7732 mmHg-s-cm was seen in control subjects, and a DCI of  $>8000$  mmHg-s-cm was never seen.<sup>7,8</sup> Thus, an extreme phenotype

TABLE 1 Hypercontractile esophagus: accepted recommendations

Recommended statement	Percent agreement (%)	Strength of recommendation	Level of evidence
Hypercontractile esophagus describes a distinct manometric abnormality defined by excessive peristaltic vigor, which may include excessive LES after-contraction, not associated with a mechanical obstruction	84	Conditional	Very Low
A hypercontractile esophageal contraction is defined as a DCI >8,000 mmHg·s·cm	84	Conditional	Low
A clinically relevant diagnosis of hypercontractile esophagus requires both clinically relevant symptoms and a conclusive manometric diagnosis of hypercontractile esophagus	90	Strong	Very Low
A conclusive manometric diagnosis of hypercontractile esophagus is defined as 20% or more hypercontractile supine swallows	80	Conditional	Very Low
Clinically relevant symptoms of hypercontractile esophagus include dysphagia and non-cardiac chest pain	95	Strong	Very Low
A diagnosis of hypercontractile esophagus can only be made when criteria for achalasia or distal esophageal spasm are not met and a mechanical obstruction has been carefully ruled out	98	Strong	Very Low

of hypertensive contractions was described based on the occurrence of a contraction with DCI greater than 8000 mmHg·s·cm.<sup>7,9</sup> This extreme phenotype is thought to be more clinically relevant than nutcracker esophagus.

The Medtronic (Given/Sierra) ManoScan system with 36 circumferential solid-state pressure sensors, spaced at 1 cm, was used for the original cut-offs used in the Chicago Classification.<sup>6</sup> The 95th percentile for contractility during supine liquid swallowing was 5000 mmHg·s·cm. Subsequent investigations using the Sandhill-Unisensor solid-state pressure sensor system,<sup>10,11</sup> and Laborie-MMS-Unisensor solid-state pressure system identified similar or lower cut-offs for the DCI 95th percentile, even when other pressure cut-offs (eg, the 4 s-Integrated Relaxation Pressure) were higher for the MMS system.<sup>12</sup> A Japanese study using the Starlet system coupled with Unisensor catheter showed higher DCI values compared to the ManoScan system, but again the highest individual value did not exceed 8000 mmHg·s·cm.<sup>13</sup> Therefore, the 8000 mmHg·s·cm threshold was retained for all manometry systems in the CCv4.0.

**Statement 3.** *A clinically relevant diagnosis of hypercontractile esophagus requires both clinically relevant symptoms and a conclusive manometric diagnosis of hypercontractile esophagus. (90% Appropriate, strong recommendation, very low-grade evidence).*

A new emphasis of the CCv4.0 is the clinical context in which the motility pattern is observed. A portion of patients with manometric HE does not exhibit symptoms attributable to the manometric finding, and HE patients frequently will have symptom resolution without medical or procedural interventions.<sup>9,14-16</sup> Given the heterogeneity of HE, the Working Group recommends using symptom data to distinguish clinically relevant HE. In other words, a clinically relevant diagnosis of HE requires both conclusive manometric diagnosis and symptoms, in particular, dysphagia and non-cardiac chest pain.

**Statement 4.** *Clinically relevant symptoms of hypercontractile esophagus include dysphagia and non-cardiac chest pain. (95% Appropriate, strong recommendation, very low-grade evidence).*

Patients with manometric findings of HE frequently will have symptoms of dysphagia and non-cardiac chest pain.<sup>9,14-16</sup> Dysphagia was associated with the DCI of the hypercontractile swallows and with intrabolus pressure.<sup>9,16</sup> Symptom persistence at follow-up in patients with HE was predicted by the complaint of dysphagia at presentation and maximum DCI; thus, HE patients with dysphagia and high maximum DCI may define a more clinically relevant subgroup of HE.<sup>15</sup> Dividing each swallow into a prepeak and a postpeak phase, abnormalities in contractile integral of the postpeak phase were more significant in HE with higher dysphagia scores.<sup>17</sup> However, a distal or postpeak contractile integral threshold has not been established to delineate clinically significant HE.

**Statement 5.** *A conclusive manometric diagnosis of hypercontractile esophagus is defined as 20% or more hypercontractile supine swallows. (80% Appropriate, conditional recommendation, very low level of evidence).*

Two or more hypercontractile supine swallows remain required for the manometric definition of HE in the CCv4.0. The Working Group of the CC v3.0 increased the threshold of HE from the occurrence of a single ( $\geq 10\%$ ) hypercontractile contraction to two ( $\geq 20\%$ ) due to the recognition that the disorder is heterogeneous and might occur along with other abnormalities such as EGJ outflow obstruction, gastroesophageal reflux disease (GERD), or eosinophilic esophagitis, and the threshold of a single swallow meeting the criterion was deemed insufficient and of uncertain relevance.<sup>1</sup>

**Statement 6.** *A diagnosis of Hypercontractile Esophagus can only be made when criteria for a manometric diagnosis of achalasia or distal esophageal spasm are not met. (98% Appropriate, strong recommendation, very low level of evidence).*

Distal esophageal or EGJ obstruction can induce a hypercontractile response, and it is therefore crucial to rule out obstruction before a diagnosis of HE is considered. The group recommends that the diagnosis of HE can only be made when criteria for a manometric diagnosis of achalasia or distal esophageal spasm are not met.

### 3.2 | Statements and concepts not meeting criteria for agreement

The HE Working Group proposed the following statements and concepts that did not meet criteria for agreement and thus are not formal recommendations in the CCv4.0.

- Hypercontractile esophagus should remain a major disorder of peristalsis and not be degraded to a minor disorder of peristalsis. (65% Appropriate)

The Working Group discussed whether HE may represent a minor disorder or should be removed from the Chicago Classification. In the end, the group concluded that HE should be retained as a motility disorder for the following reasons: (1) Hypercontractile contractions, as defined, never occur in controls<sup>6,7</sup>; (2) HE is commonly associated with symptoms (dysphagia or chest pain),<sup>18</sup> and (3) There are reports of therapeutic response to several interventions, including medications,<sup>19,20</sup> dilatation,<sup>21</sup> botulinum toxin (BTX) injections,<sup>21,22</sup> POEM or surgery.<sup>23,24</sup> On the other hand, such therapeutic response occurred mainly in observational or uncontrolled trials, and when HE was observed over time, symptoms resolved in most cases whether treated or untreated.<sup>15,25</sup> Whether to include HE as a major or minor disorder of peristalsis became irrelevant as the CCv4.0 has eliminated the use of major and minor motility disorders to distinguish esophageal motility disorders.

- It is recommended that high-resolution manometry is combined with impedance measurement for optimal identification of intrabolus pressure, incomplete bolus clearance and bolus flow through the esophagus and EGJ. (67% Appropriate)

High-resolution manometry combined with impedance can be used to identify intrabolus pressure, bolus clearance, and bolus flow time through the esophagogastric junction. These impedance metrics can theoretically help differentiate those with clinically significant HE affecting bolus transit. However, few studies report on impedance-based bolus transit in HE. A single-center study by Sloan et al. reported successful liquid and viscous bolus transit in 15 out of 17 patients (88%) patients with hypercontractility.<sup>26</sup> It could be questioned whether hypercontractility represents an augmented contractile response to facilitate bolus transit. More work is needed to clarify this aspect, potentially relating to the pathophysiology of HE and the assessment of HE in the context of solid bolus transit and provocative testing.<sup>27</sup>

- The term “Jackhammer Esophagus” is not synonymous with Hypercontractile Esophagus, because repetitive contractions do not form part of the definition of Hypercontractile Esophagus. (76% Appropriate)

Jackhammer esophagus describes a pattern of esophageal hypercontraction in which vigorous and multi-peaked contractions are

seen. Although this pattern is frequently observed in HE, it is not required for the diagnosis. In the CC4.0, it is recognized as a subgroup of HE, and the use of the term “Jackhammer Esophagus” as a synonym for HE is discouraged.

- A manometric diagnosis of Hypercontractile Esophagus is supported by increased intrabolus pressure. (Appropriate 60%)

There are not enough data to indicate that abnormal intrabolus pressure (IBP) would support the diagnosis of HE. Quader et al showed that elevated IBP predicts the presence of structural EGJ processes even when IRP is normal, despite suboptimal correlation with the symptom of dysphagia. More than 50% of patients of functional EGJ had a persistent barium column during timed barium esophagogram (TBE).<sup>28</sup> Similarly, Hoscheit et al<sup>29</sup> showed that patients with abnormal TBE were found to have significantly elevated IBP. An IBP >24 mmHg was predictive of abnormal TBE independently from the IRP value in EGJ. IBP, therefore, might be of value in phenotyping HE patients for a subset with poor esophageal bolus clearance. Nevertheless, there is inadequate data to support the use of IBP for manometric diagnosis of HE. Future studies including clinical correlation of IBP and TBE in patients meeting manometric criteria for HE are needed to better clarify the clinical value of IBP in HE diagnosis.

- A manometric diagnosis of Hypercontractile Esophagus is supported by an abnormal rapid drink challenge. (Appropriate in 53%)

Rapid drink challenge (RDC) consists of rapidly drinking 100–200 ml of water in the upright position during esophageal HRM. In healthy subjects, rapid drinking induces complete inhibition of esophageal body contraction and a complete LES relaxation; at the end of the test, a peristaltic wave is seen in 50%–70% in healthy/functional subjects.<sup>30,31</sup> In patients with HE, a brief hyper-pressurized pattern has been observed, in contrast to a prolonged hyper-pressurized pattern in achalasia.<sup>32</sup> Presence of one of the following: >2 pressurizations at >20 mmHg, >8% of time above 20 mmHg, or an EGJ gradient of >4 mmHg discriminated the hyper-pressurized pattern with a sensitivity of 80% and a specificity of 93%.<sup>32</sup> Other authors described specific patterns during RDC, including esophageal shortening and panesophageal pressurization (PEP), which predicted more severe dysphagia in EGJ<sup>33,34</sup> and was seen in half of HE patients, possibly related to thickened esophageal muscle in HE.<sup>35</sup> Despite abnormal patterns described during RDC in patients with HE, there is currently a lack of consensus on how to use the RDC findings consistently to aid HE diagnosis.

- A manometric diagnosis of Hypercontractile Esophagus is supported by absence of contraction reserve on multiple rapid swallows. (56% Appropriate)

Another provocation maneuver during HRM, the multiple rapid swallows (MRS), consists of five swallows of 2 ml of water at 2–3 s

intervals, repeated three times for improving accuracy, and has demonstrated usefulness in investigating inhibitory and excitatory neural pathways.<sup>36</sup> In the two published series of healthy subjects, MRS induced complete inhibition in 76%–95% and augmentation of contractile vigor after MRS compared to single water swallows, termed contraction reserve, in 80%.<sup>30,37</sup> A recent multicenter study demonstrated that HE, HE with obstruction and type III achalasia, have a common pathophysiological thread combining incomplete inhibition and exaggerated excitation with absence of contraction reserve in many patients regardless of the presence or absence of abnormal LES function.<sup>38</sup> However, similar to the RDC, use of MRS consistently in HE diagnosis is limited at the current time. Examples of abnormal RDC and MRS in patients with HE are shown in Figure 1.

- A positive response to pharmacologic treatment (nitrates, calcium antagonists, BTX, etc.) lends support to the diagnosis of Hypercontractile Esophagus. (51% Appropriate)

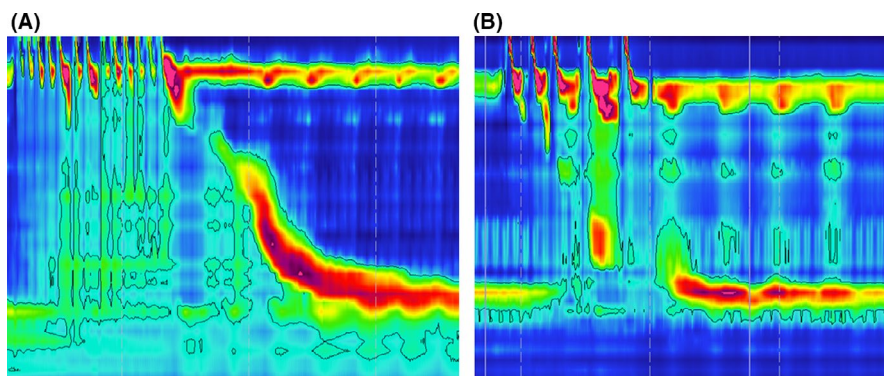
Calcium channel blockers, nitrates, and phosphodiesterase inhibitors have been utilized to reduce contraction vigor. Calcium channel antagonists inhibit intracellular calcium uptake, with ability to reduce esophageal contraction vigor and LES pressures.<sup>39</sup> Richter et al compared nifedipine vs. placebo in a small-scaled double-blind crossover study. Nifedipine significantly decreased distal esophageal contraction amplitude and LES pressure.<sup>40</sup> Nifedipine, however, was no better than placebo in improving chest pain perception. Phosphodiesterase-5 inhibitors block the degradation of nitric oxide resulting in a more prolonged esophageal smooth muscle relaxation. Bortolotti et al showed that sildenafil inhibits the contractile activity of the esophageal musculature of patients with achalasia, decreasing LES tone and residual pressure as well as contraction amplitude.<sup>41</sup> Eherer et al<sup>42</sup> observed that sildenafil was able to reduce LES pressure and propulsive forces in healthy subjects as well as in patients with nutcracker esophagus, hypertensive LES, and achalasia.

Despite the observations that pharmacologic agents can be used to reduce contractile vigor, the lack of consistency in translation to symptom improvement limits the use of a positive response a pharmacologic trial in the diagnosis of HE.

### 3.3 | Concepts regarding hypercontractile LES

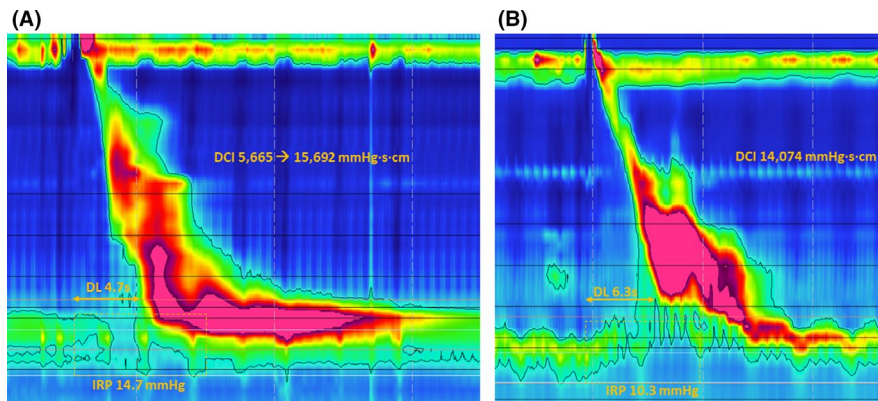
- There are no compelling arguments for subdividing Hypercontractile Esophagus into “LES-independent” and “LES-dependent” subgroups. (67% Appropriate)
- When the criterion of at least 2 swallows with an esophageal body DCI >8000 mmHg·s·cm is not met but vigorous contractions involving the LES are seen, the LES should be included in the DCI calculation. (58% Appropriate)
- When the DCI is calculated for the manometric diagnosis of Hypercontractile Esophagus the LES should consistently be EXCLUDED. (35% Appropriate)
- When the DCI is calculated for the manometric diagnosis of Hypercontractile Esophagus the LES should consistently be INCLUDED. (37% Appropriate)

An HE variant involving a vigorous LES after-contraction has been described. The CCv3.0 recognized that esophageal hypercontraction is not limited to the esophageal body but rather can also include, or even be localized to, the LES.<sup>1</sup> With the analysis window of a swallow limited to 2 s prior to swallow initiation and 10 s after the contractile deceleration point, and the DCI analysis box extending from the transition zone to the upper or lower margin of the LES, a diagnosis of HE is achieved either with or without LES involvement. The variation based on LES involvement has been termed “LES-independent” for HE that reached the threshold DCI without LES inclusion versus “LES-dependent” hypercontraction that required LES in the calculation of DCI to reach the diagnostic threshold (Figure 2). The clinical significance of LES involvement in patients diagnosed with HE remains uncertain, however. Whereas Herregods et al. observed that dysphagia was invariably present in patients with “LES-dependent” HE, a recent study found no difference in symptoms and outcome between patients with LES-dependent and LES-independent HE.<sup>9,25</sup> Therefore, although the CCv4.0 recognizes a subtype of HE that involves a vigorous LES after-contraction, there is currently no compelling evidence for subdividing HE based on LES involvement in clinical practice, and the Working Group does not recommend consistently excluding or including the LES in the DCI calculation.



**FIGURE 1** Examples of rapid drink challenge (RDC) and multiple rapid swallows (MRS) in hypercontractile esophagus (HE). (A) shows an example of esophageal pressurization during RDC in a patient with HE. (B) shows abnormal MRS with abnormal deglutitive inhibition and pressurization in another patient with HE





**FIGURE 2** Lower esophageal sphincter (LES) ES-dependent versus LES-independent hypercontractile esophagus (HE). (A) demonstrates the LES-dependent variant of HE where the DCI falls in the hypercontractile range only after including the LES in the DCI box (5665 mmHg-s-cm excluding LES to 15,692 mmHg-s-cm including LES). (B) shows an example of LES-independent HE, where the DCI is in the hypercontractile range without inclusion of the LES

### 3.4 | Clinical considerations and therapeutic options

Symptomatic HE might call for therapeutic intervention; however, a portion of patients with HE present without relevant symptoms, prompting conservative measures with close follow-up. Subtle EGJOO underlying HE or alternative pathophysiology, especially opioid use, should also be excluded prior to considering intervention. In symptomatic HE patients, the relevance between symptoms and manometric abnormalities should be assessed through subsequent technical evaluation including timed barium esophagogram and/or EndoFLIP, if available.

Hypercontractile esophagus is a heterogeneous disorder with potential etiologic factors including GERD and the use of opioids, which should be corrected or controlled for. Although the prevalence of GERD in HE was found to be high, response rate to proton pump inhibitors (PPIs) in HE patients with GERD was reported at only 6.3% to 20.4%.<sup>14,43</sup> Other potential medical therapies of HE include calcium channel blockers, nitrates, and antidepressants.<sup>16,44</sup> However, the efficacy of medical therapy in HE has not been confirmed as only small-sample observational studies or case reports are available. The complete and partial response rate of HE to medical treatment in a French cohort was 49%.<sup>16</sup> According to the meta-analysis by Roman et al., the pooled clinical response rate of medical treatment (including calcium channel blockers, nitrates, PPIs, peppermint oil, and antidepressants) was 62.6% (95% CI: 46.5%–78.7%).<sup>45</sup>

Some HE patients might benefit from endoscopic procedures including pneumatic dilation, botulinum toxin (BTX) injection, and per-oral endoscopic myotomy (POEM). In a French retrospective cohort, 57.1% of recurrence rate was observed in HE patients who underwent dilation, compared to 31.2% after BTX injection at the last visit.<sup>16</sup> A prospective controlled study from Belgium assessed the effect of BTX injection in the treatment of non-achalasia primary esophageal motility disorders, including 22 dysphagia patients with either distal esophageal spasm or nutcracker esophagus who were randomized into BTX or saline injection. 50% of the patients

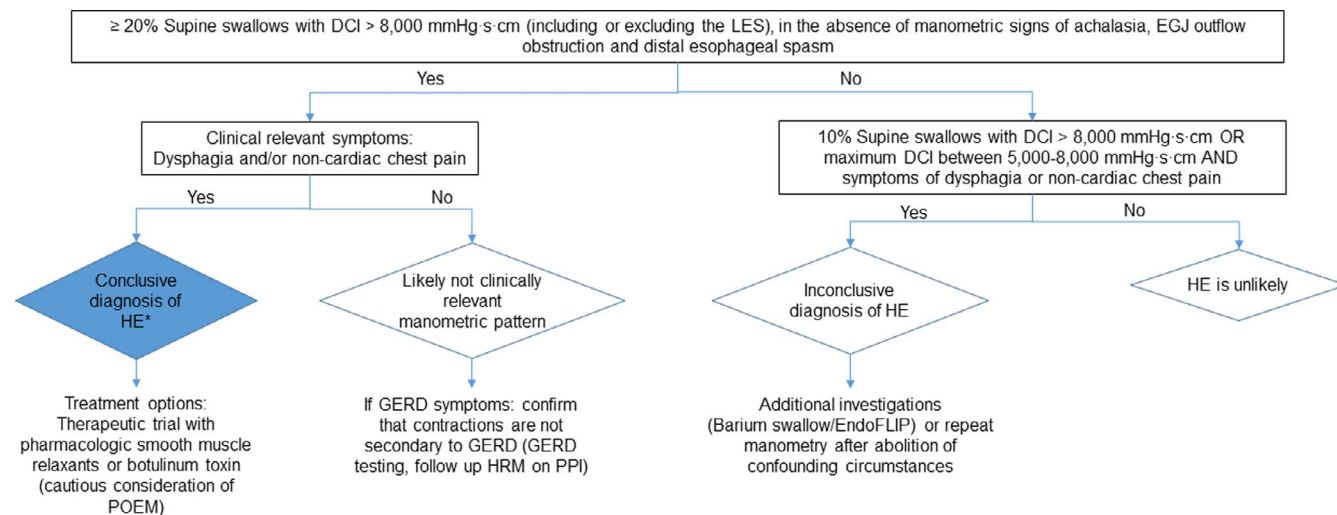
achieved symptom resolution in the BTX group after 1 month compared with only 10% in the saline group.<sup>46</sup> However, another double-blind randomized sham-control randomized trial by Mion et al.<sup>22</sup> failed to prove the superiority of BTX injection to placebo in patients with HE.

Per-oral endoscopic myotomy has been shown to be superior to other endoscopic procedures in reducing esophageal body contractility. Bernardot et al. reported the efficacy of POEM in therapy of patients with non-achalasia esophageal motility disorders including 13 HE and 4 nutcracker esophagus patients. The response rate of POEM in this mixed groups after 6 months was 63.2%.<sup>47</sup> An even higher response rate of 85.7% was observed in the study by Albers et al., where patients with non-cardiac chest pain and HE were included with an average follow-up of more than 12 months. The pooled response rate of POEM in HE reported by Roman et al was 82.3% (95% CI: 75.0%–89.7%).<sup>45</sup> Data on long-term response to POEM in HE patients are scarce. In one observational study assessing the long-term effect of POEM in HE patients, 6 out of 7 HE patients still remained symptom-free after 5 years on follow-up.<sup>48</sup>

Importantly, spontaneous symptom resolution has been shown in a portion of HE patients. Schupack et al. reported that in a cohort of 40 HE patients, 73% of them had symptom improvement despite only a minority of received treatment during a mean follow-up of 132 weeks.<sup>15</sup> Similar observations have been made in small case series and reports. Given this, and the heterogeneity seen in HE, it is recommended that conservative management with follow-up should be strongly considered in patients with HE, and invasive and irreversible interventions should be considered only after careful evaluation and ruling out clinically irrelevant HE.

## 4 | DISCUSSION

Using a rigorous methodology with the expertise of 52 international Working Group members, the diagnostic criteria for HE have



\* If patient is on opiates at the time of HRM, opiates-related hypercontraction might be considered

FIGURE 3 Diagnostic algorithm for Hypercontractile Esophagus based on the CCv4.0

been updated in the CCv4.0 to include clinical symptoms, typically consisting of dysphagia or non-cardiac chest pain. The manometric diagnostic threshold remains at 20% or more swallows with DCI >8000 mmHg·s·cm, after ruling out for achalasia, diffuse esophageal spasm, and an EGJ outflow obstruction. Although not required as part of the diagnostic algorithm, the HE Working Group also recognizes the subtypes of HE including single- versus multi-peaked esophageal body contractions (Jackhammer esophagus) and a subtype involving vigorous LES after-contraction. The Working Group discourages the use of the term “Jackhammer esophagus” as a synonym for HE in general. And since there is no evidence showing clinical differences between the LES-dependent and LES-independent subtypes, the Working Group currently does not recommend formally subdividing HE based on LES involvement. A proposed diagnostic algorithm for patients with suspected HE based on the CCv4.0 is shown in Figure 3. Treatment recommendations for HE are based on scarce evidence. Due to the heterogeneous nature of HE, the CCv4.0 recommends a conservative approach with invasive therapies offered only in those with persistent symptoms and after careful consideration.

Despite the new wave of data, the etiology, pathophysiology, natural history, and symptom generation of HE remain incompletely understood. From diagnosis standpoint, future studies to correlate symptoms with novel HRM metrics are needed for identification of clinically relevant HE. As the range of proposed treatment for HE include watchful waiting, medication, to more invasive treatment options of BTX injection and esophagomyotomy, and current treatment data are limited to small observational studies, well-designed therapeutic trials with long-term follow-up data are needed before invasive and irreversible treatment interventions should be uniformly offered to patients with HE. Future trials should also take into consideration the phenotypes of HE including the body contractile pattern and LES contribution to hypercontraction.

## 5 | WHAT IS NEW SINCE THE CCV3.0

- Clinically relevant symptoms (dysphagia, non-cardiac chest pain) are now required for a diagnosis of hypercontractile esophagus.
- Recognition of various HE contractile morphologies (single-peaked, multi-peaked/Jackhammer, and vigorous LES aftercontraction) although formal HE subtype is not currently recommended

### CONFLICT OF INTERESTS

ES: Consulting: Unifarco; Speaker: Medtronic, Reckitt Benckiser, Takeda, Abbvie, Novartis, Sandoz, Sofar, Malesci, Janssen, Grifols, Aurora Pharma, Innovamedica, Johnson&Johnson, SILA, Alfasigma, Shire, EG Stada Group| Advisory Board: Merck & Co, Bristol-Myers Squibb, Amgen, Fresenius Kabi; Research Grant: Sofar. RY: institutional Consulting Agreement: Medtronic, Ironwood Pharmaceuticals, Diversatek; Research support: Ironwood Pharmaceuticals; Advisory Board: Phathom Pharmaceuticals. All other authors have no competing interests to declare.

### AUTHOR CONTRIBUTIONS

JC, ES, AS, YX, and CC performed research. RHY and NB analyzed data. JC, ES, AS, YX, and CC drafted the manuscript. JC, ES, AS, YX, RY, NB, and CC critically reviewed and approved the final manuscript.

### DATA AVAILABILITY STATEMENT

The data that support the findings of this study are available from the corresponding author upon reasonable request.

### ORCID

Joan W. Chen <https://orcid.org/0000-0001-9425-3209>

Nicola de Bortoli <https://orcid.org/0000-0003-1995-1060>

Rena Yadlapati <https://orcid.org/0000-0002-7872-2033>

Charles Cock <https://orcid.org/0000-0003-3578-1137>

## REFERENCES

- Kahrilas PJ, Bredenoord AJ, Fox M, et al. The Chicago Classification of esophageal motility disorders, v3.0. *Neurogastroenterol Motil.* 2015;27(2):160-174.
- Yadlapati R, Kahrilas PJ, Fox MR, et al. Esophageal motility disorders on high-resolution manometry: Chicago classification version 4.0((c)). *Neurogastroenterology and motility : the official journal of the European Gastrointestinal Motility. Society.* 2021;33(1):e14058.
- Balshem H, Helfand M, Schunemann HJ, et al. GRADE guidelines: 3. Rating the quality of evidence. *J Clin Epidemiol.* 2011;64(4):401-406.
- Benjamin SB, Gerhardt DC, Castell DO. High amplitude, peristaltic esophageal contractions associated with chest pain and/or dysphagia. *Gastroenterology.* 1979;77(3):478-483.
- Woo M, Andrews CN, Buresi M. Reversible Jackhammer esophagus in a patient with a gastric band. *Neurogastroenterol Motil.* 2019;31(4):e13572.
- Pandolfino JE, Ghosh SK, Rice J, Clarke JO, Kwiatek MA, Kahrilas PJ. Classifying esophageal motility by pressure topography characteristics: a study of 400 patients and 75 controls. *Am J Gastroenterol.* 2008;103(1):27-37.
- Roman S, Tutuian R. Esophageal hypertensive peristaltic disorders. *Neurogastroenterol Motil.* 2012;24(Suppl 1):32-39.
- Bredenoord AJ, Fox M, Kahrilas PJ, et al. Chicago classification criteria of esophageal motility disorders defined in high resolution esophageal pressure topography. *Neurogastroenterol Motil.* 2012;24(Suppl 1):57-65.
- Herregods TV, Smout AJ, Ooi JL, Sifrim D, Bredenoord AJ. Jackhammer esophagus: observations on a European cohort. *Neurogastroenterol Motil Soc.* 2017;29(4). <https://doi.org/10.1111/nmo.12975>. [Epub Ahead of Print].
- do Carmo GC, Jafari J, Sifrim D, de Oliveira RB. Normal esophageal pressure topography metrics for data derived from the Sandhill-Unisensor high-resolution manometry assembly in supine and sitting positions. *Neurogastroenterol Motil.* 2015;27(2):285-292.
- Shi Y, Xiao Y, Peng S, Lin X, Xiong L, Chen M. Normative data of high-resolution impedance manometry in the Chinese population. *J Gastroenterol Hepatol.* 2013;28(10):1611-1615.
- Bogte A, Bredenoord AJ, Oors J, Siersema PD, Smout AJ. Normal values for esophageal high-resolution manometry. *Neurogastroenterol Motil.* 2013;25(9):762-e579.
- Kuribayashi S, Iwakiri K, Shinozaki T, et al. Clinical impact of different cut-off values in high-resolution manometry systems on diagnosing esophageal motility disorders. *J Gastroenterol.* 2019;54(12):1078-1082.
- Kristo I, Schwameis K, Paireder M, Jomrich G, Kainz A, Schoppmann SF. Dysphagia severity is related to the amplitude of distal contractile integral in patients with Jackhammer esophagus. *Neurogastroenterol Motil.* 2018;30(5):e13276.
- Schupack D, Katzka DA, Geno DM, Ravi K. The clinical significance of esophagogastric junction outflow obstruction and hypercontractile esophagus in high resolution esophageal manometry. *Neurogastroenterol Motil.* 2017;29(10):1-9.
- Philonenko S, Roman S, Zerbib F, et al. Jackhammer esophagus: Clinical presentation, manometric diagnosis, and therapeutic results-Results from a multicenter French cohort. *Neurogastroenterol Motil.* 2020;32(11):e13918.
- Xiao Y, Carlson DA, Lin Z, Alhalel N, Pandolfino JE. Jackhammer esophagus: Assessing the balance between prepeak and postpeak contractile integral. *Neurogastroenterol Motil.* 2018;30(5):e13262.
- Savarino E, Smout A. The hypercontractile esophagus: Still a tough nut to crack. *Neurogastroenterol Motil.* 2020;32(11):e14010.
- Roman S, Kahrilas PJ. Management of spastic disorders of the esophagus. *Gastroenterol Clin North Am.* 2013;42(1):27-43.
- Babaei A, Shad S, Massey BT. Esophageal hypercontractility is abolished by cholinergic blockade. *Neurogastroenterol Motil.* 2020:e14017. <https://doi.org/10.1111/nmo.14017>. [Epub Ahead of Print].
- Al-Qaisi MT, Siddiki HA, Crowell MD, et al. The clinical significance of hypercontractile peristalsis: comparison of high-resolution manometric features, demographics, symptom presentation, and response to therapy in patients with Jackhammer esophagus versus Nutcracker esophagus. *Dis Esophagus.* 2017;30(12):1-7.
- Mion F, Marjoux S, Subtil F, et al. Botulinum toxin for the treatment of hypercontractile esophagus: Results of a double-blind randomized sham-controlled study. *Neurogastroenterol Motil.* 2019;31(5):e13587.
- Khashab MA, Messallam AA, Onimaru M, et al. International multicenter experience with peroral endoscopic myotomy for the treatment of spastic esophageal disorders refractory to medical therapy (with video). *Gastrointest Endosc.* 2015;81(5):1170-1177.
- Khan MA, Kumbhari V, Ngamruengphong S, et al. Is POEM the answer for management of spastic esophageal disorders? A systematic review and meta-analysis. *Dig Dis Sci.* 2017;62(1):35-44.
- Kahn A, Al-Qaisi MT, Obeid RA, et al. Clinical features and long-term outcomes of lower esophageal sphincter-dependent and lower esophageal sphincter-independent jackhammer esophagus. *Neurogastroenterol Motil.* 2019;31(2):e13507.
- Sloan JA, Mulki R, Sandhu N, Samuel S, Katz PO. Jackhammer esophagus: symptom presentation, associated distal contractile integral, and assessment of bolus transit. *J Clin Gastroenterol.* 2019;53(4):295-297.
- Mauro A, Quader F, Tolone S, et al. Provocative testing in patients with jackhammer esophagus: evidence for altered neural control. *Am J Physiol Gastrointest Liver Physiol.* 2019;316(3):G397-G403.
- Quader F, Reddy C, Patel A, Gyawali CP. Elevated intrabolus pressure identifies obstructive processes when integrated relaxation pressure is normal on esophageal high-resolution manometry. *Am J Physiol Gastrointest Liver Physiol.* 2017;313(1):G73-G79.
- Hoscheit M, Gabbard S. Elevated intrabolus pressure predicts abnormal timed barium esophagram in esophagogastric junction outflow obstruction. *J Neurogastroenterol Motil.* 2019;25(4):521-524.
- Elvevi A, Mauro A, Pugliese D, et al. Usefulness of low- and high-volume multiple rapid swallowing during high-resolution manometry. *Dig Liver Dis.* 2015;47(2):103-107.
- Marin I, Cisternas D, Abrao L, et al. Normal values of esophageal pressure responses to a rapid drink challenge test in healthy subjects: results of a multicenter study. *Neurogastroenterol Motil.* 2017;29(6). <https://doi.org/10.1111/nmo.13021>. [Epub Ahead of Print].
- Marin I, Serra J. Patterns of esophageal pressure responses to a rapid drink challenge test in patients with esophageal motility disorders. *Neurogastroenterol Motil.* 2016;28(4):543-553.
- Ang D, Hollenstein M, Misselwitz B, et al. Rapid Drink Challenge in high-resolution manometry: an adjunctive test for detection of esophageal motility disorders. *Neurogastroenterol Motil.* 2017;29(1). <https://doi.org/10.1111/nmo.12902>. [Epub Ahead of Print].
- Biasutto D, Mion F, Garros A, Roman S. Rapid drink challenge test during esophageal high resolution manometry in patients with esophago-gastric junction outflow obstruction. *Neurogastroenterol Motil.* 2018;30(6):e13293.
- Biasutto D, Roman S, Garros A, Mion F. Esophageal shortening after rapid drink test during esophageal high-resolution manometry: A relevant finding? *United Eur Gastroenterol J.* 2018;6(9):1323-1330.
- Mauro A, Savarino E, De Bortoli N, et al. Optimal number of multiple rapid swallows needed during high-resolution esophageal manometry for accurate prediction of contraction reserve. *Neurogastroenterol Motil.* 2018;30(4):e13253.



37. Shaker A, Stoikes N, Drapekin J, Kushnir V, Brunt LM, Gyawali CP. Multiple rapid swallow responses during esophageal high-resolution manometry reflect esophageal body peristaltic reserve. *Am J Gastroenterol*. 2013;108(11):1706-1712.
38. Quader F, Mauro A, Savarino E, et al. Jackhammer esophagus with and without esophagogastric junction outflow obstruction demonstrates altered neural control resembling type 3 achalasia. *Neurogastroenterol Motil*. 2019;31(9):e13678.
39. Yoshida K, Furuta K, Adachi K, et al. Effects of anti-hypertensive drugs on esophageal body contraction. *World J Gastroenterol*. 2010;16(8):987-991.
40. Richter JE, Dalton CB, Bradley LA, Castell DO. Oral nifedipine in the treatment of noncardiac chest pain in patients with the nutcracker esophagus. *Gastroenterology*. 1987;93(1):21-28.
41. Bortolotti M, Mari C, Lopilato C, Porrazzo G, Miglioli M. Effects of sildenafil on esophageal motility of patients with idiopathic achalasia. *Gastroenterology*. 2000;118(2):253-257.
42. Eherer AJ, Schwetz I, Hammer HF, et al. Effect of sildenafil on oesophageal motor function in healthy subjects and patients with oesophageal motor disorders. *Gut*. 2002;50(6):758-764.
43. Mallet A-L, Ropert A, Bouguen G, et al. Prevalence and characteristics of acid gastro-oesophageal reflux disease in Jackhammer oesophagus. *Dig Liver Dis*. 2016;48(10):1136-1141.
44. Li JY, Zhang WH, Huang CL, Huang D, Zuo GW, Liang LX. Deanxit relieves symptoms in a patient with jackhammer esophagus: A case report. *World J Gastrointest Endosc*. 2017;9(12):590-593.
45. Wahba G, Bouin M. Jackhammer esophagus: a meta-analysis of patient demographics, disease presentation, high-resolution manometry data, and treatment outcomes. *Neurogastroenterol Motil*. 2020;32(11):e13870.
46. Vanuytsel T, Bisschops R, Farre R, et al. Botulinum toxin reduces Dysphagia in patients with nonachalasia primary esophageal motility disorders. *Clin gastroenterol Hepatol*. 2013;11(9):1115-1121.e2.
47. Bernardot L, Roman S, Barret M, et al. Efficacy of per-oral endoscopic myotomy for the treatment of non-achalasia esophageal motor disorders. *Surg Endosc*. 2020;34(12):5508-5515.
48. Nabi Z, Chavan R, Ramchandani M, et al. Long-term outcomes of per-oral endoscopic myotomy in spastic esophageal motility disorders: a large, single-center study. *J Clin Gastroenterol*. 2020. <https://doi.org/10.1097/MCG.0000000000001395>. [Epub Ahead of Print].

**How to cite this article:** Chen JW, Savarino E, Smout A, et al.

Chicago Classification Update (v4.0): Technical review on diagnostic criteria for hypercontractile esophagus.

*Neurogastroenterology & Motility*. 2021;33:e14115. <https://doi.org/10.1111/nmo.14115>