

Supplemental Table S1

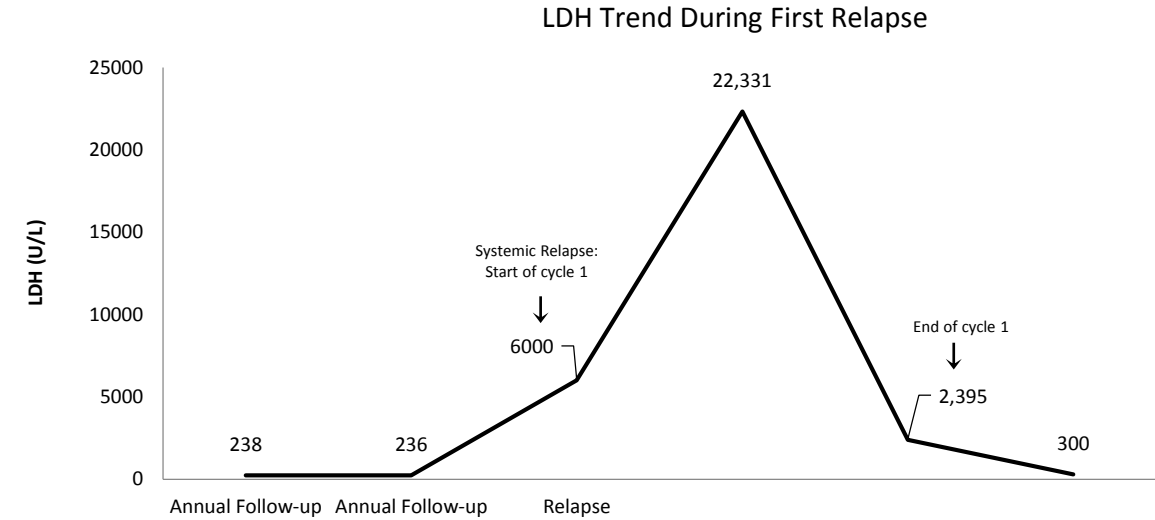
Genetic Mutations at Diagnosis and Relapse with their corresponding PolyPhen Score

	Gene Involved	Chromosomal Location (GRCh37)	Mutation	PolyPhen-2 Score
Germline	RB1	chr13:49033822	NM_000321.2: c.1961-2A>G	
	FANCD2	chr3:1010547	NM_033084.4: c.1829T>G, p.Val610Gly	0.996
Eye	NR3C1	chr5:142689683	NM_000176.2: c.1447C>G, p.Gln483Glu	0.989
	SKP2	chr5:36163803	NM_005983.3: c.337T>C, p.Cys113Arg	0.799
Bone Marrow	CYP21A2	chr6:31973557	NM_000500.7: c.92T>C, p.Leu31Pro	0.990
Brain	CD276	chr15:73996733	NM_025240.2: c.635_636delTGinsAT, p.Leu212His	0.995
	PRSS3	chr9:33750687	NM_007343.3: c.173C>G, p.Ala58Gly	0.000
	FANCD2	chr3:10105477	NM_033084.4: c.1829T>G, p.Val610Gly	0.996
	PKHD1	chr6:51712632	NM_138694.3: c.8048G>A, p.Gly2683Asp	0.128
	TAF1L	chr9:32631644	NM_153809.2: c.3934G>A, p.Val1312Ile	Unable to Predict

Supplemental Table S2: Children’s Hospital of Michigan Relapsed Retinoblastoma Cases over the past 25 Years

Patient	Age at Diagnosis	Disease	Initial Therapy	Histopathology Features of Enucleated Eye(s)	Time to relapse from diagnosis	Site of relapse	Outcome
1	10 months	Bilateral Retinoblastoma	Carboplatin/Etoposide/ Thermo laser followed by enucleation one eye	Exophytic tumor involving the retina and extending to both sides of the iris and ciliary body including the peripheral angles of the anterior chamber, Schlemm's canal and the posterior chamber. No tumor involving the optic nerve, choroid or sclera.	2 years	Bone Marrow	Alive post SCT
2	3 years	Unilateral Retinoblastoma	Enucleation followed by Carboplatin/Cyclophosphamide/ Vincristine	Involvement of the anterior chamber and extension into the optic nerve	3 months	Bone Marrow	DOD
3	2 years	Unilateral Retinoblastoma	Enucleation followed by Carboplatin/Etoposide	Predominantly endophytic growth with extensive tumor filling the entire vitreous cavity with complete retinal detachment. Prelaminar invasion of the optic nerve with no involvement of the anterior chamber.	8 months	Systemic + Orbit	DOD
4	2 years	Bilateral Retinoblastoma	Enucleation followed by Carboplatin/Etoposide/ Vincristine/Cyclophosphamide followed by second enucleation	Left eye: Exophytic and endophytic tumors involving the retina with retinal detachment. Tumor extended into the optic nerve and into the vitreous. No invasion of the choroid or anterior segment. Right eye: Exophytic and endophytic tumor involving the optic nerve with retinal detachment. Invasion into the choroid and destruction of the ciliary body.	1 year	Orbit	Alive post salvage chemotherapy + radiotherapy
Current patient	2 months	Bilateral Retinoblastoma	Carboplatin/Vincristine/ Thermo Laser followed by enucleation one eye	No involvement of the anterior chamber, choroid or optic nerve	8 years	Systemic	DOD

Supplement Figure S1



Supplemental Figure S2

