

Diagnosis of Stage III Periodontitis and Ambiguities of the “Gray Zones” in Between Stage III and Stage IV

Benyapha Sirinirund,* Riccardo Di Gianfilippo,* Shan-Huey Yu,* Hom-Lay Wang* and Kenneth S. Kornman*

Introduction: How to best classify the Stage III and IV periodontitis cases that share common features of the most severe clinical attachment loss and the most severe radiographic bone loss?

Case Presentation: Two patients presented features of generalized periodontitis, with severe probing depth and clinical attachment loss that would meet inclusion in both Stage III and IV. The cases retained all teeth but were further complicated by teeth drifting and secondary occlusal trauma. Appropriate disease classification required clinical judgement and led to the final classification of Stage III, Grade C for both cases.

Conclusion: Patient-based clinical judgement, aiming for long-term preservation of natural dentition, drives the final assignment of staging when the case falls in the “gray zone” that focuses on major differences in Stage III and IV periodontitis. *Clin Adv Periodontics* 2021;11:111–115.

Key Words: Disease progression; periodontal attachment loss; periodontitis; prognosis; risk factors; tooth loss.

Background

Medical classifications are utilized to transform clinical data into diagnostic categories that guide the diagnosis for a specific patient, assist treatment planning, and estimate short- and long-term prognosis. The classification of periodontal diseases evolved over the decades to reflect our knowledge and understanding of the disease pathogenesis. The 1999 World Workshop on the Classification of Periodontal Diseases and Conditions emphasized the distinction between chronic and aggressive periodontitis, which dominated clinical practices and much of periodontal research for two decades.¹ The 2017 World Workshop joined experts from the American Academy of Periodontology (AAP) and the European Federation of Periodontology (EFP), and recognized periodontitis as one disease entity with a broad range of clinical presentations, that is phenotypes. The staging and grading system was adopted to bring multiple dimensions to help classify different clinical phenotypes to distinguish approaches to guide management of cases that require more advanced knowledge.² The newly developed classification matrix for periodontitis evaluates the severity and extent of the past destruction, the complexity of treatment, and potential risk for further progression. The periodontal community is undergoing the process of adaptation to the new system and exploration of “gray zone” cases that may produce uncertain clinical scenarios in need of thoughtful clinical judgement.³ A call for sharing experience and rationale on how to interpret the “gray zone” is needed and narratives have been published to guide

clinicians on their interpretation and dissemination of the new classification.^{4,5} Therefore, the aim of this article is to present two “gray-zone” cases that fall within Stage III and IV, and illustrates the decision-making process and the clinical judgment that was used to differentiate Stage III and Stage IV cases.

Clinical Presentation

Patients were received at the Department of Periodontics and Oral Medicine, University of Michigan School of Dentistry. Both patients have electronically signed an informed consent for periodontal examination and treatment, and gave oral consent for the use of clinical, radiographic and photographic data for research purposes.

Case 1

Case 1 is a 46-year-old Caucasian female who presented to the Department of Periodontics of the University of Michigan for consultation. Medical history revealed uncontrolled Type 2 diabetes mellitus (T2DM; HbA1c: 9.4%) and morbid obesity (body mass index [BMI]: 50.6 kg/m²). Medications at the time of first examinations were glargine insulin[†], dulaglutide[‡], and empagliflozin[§]. The patient was a former smoker who used to smoke 10 cigarettes/day for 5 years and quit 20 years ago. Clinical photos (Figure 1(A)) show the patient’s deep overbite along with tooth drifting/flaring in the upper anterior sextant. Additionally, the patient had no missing teeth.

The severity component of staging a case is based on the greatest interdental clinical attachment loss (AL) and

*Department of Periodontics and Oral Medicine, School of Dentistry, University of Michigan, Ann Arbor, MI

Received November 13, 2020; accepted February 26, 2021

doi: 10.1002/cap.10153

[†]Basaglar, Eli Lilly and Company, IN, USA.

[‡]Trulicity, Eli Lilly and Company, IN, USA.

[§]Jardiance, Boehringer Ingelheim Pharmaceuticals, Inc., CT, USA.

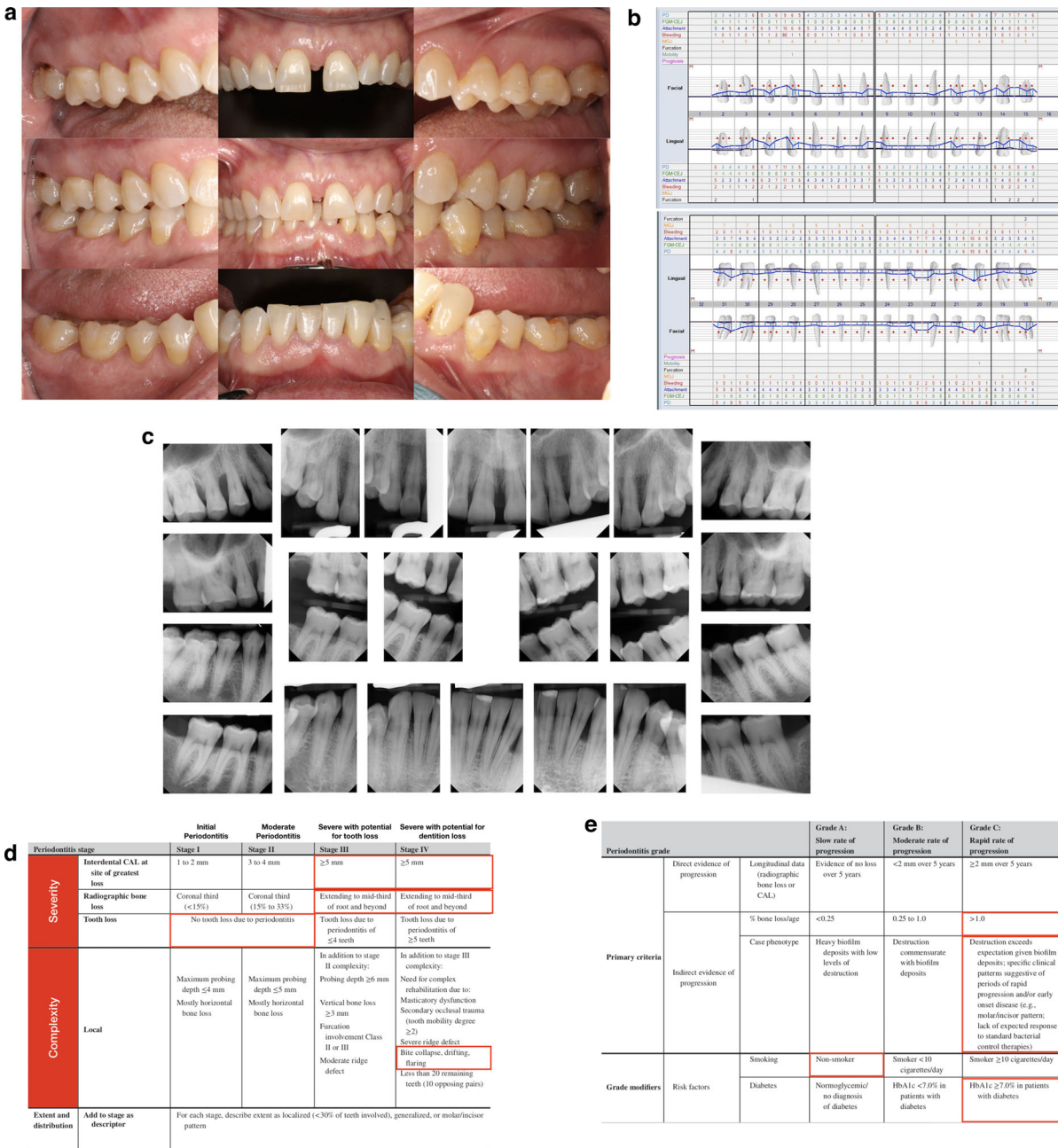


FIGURE 1 Case 1 clinical presentation and classification decision making. (A) Facial intraoral view divided by sextants. (B) Initial maxillary and mandibular periodontal chart. Abbreviations. PD, probing depth; FMJ-CEJ, distance from the free gingival margin to the cemento-enamel junction; MGJ, distance from the mucogingival junction to the free gingival margin. (C) Full set of intraoral periapical and bitewing radiographs. (D) Staging matrix as officially reported in the 2017 World Workshop². (E) Grading matrix as officially reported in the 2017 World Workshop.² **Figure can be enlarged in online version of this article.**

radiographic bone loss (RBL). The notable periodontal (Figure 1(B)) and radiographic (Figure 1(C)) findings include: probing depths (PD) and AL up to 11 mm (#5), and RBL to mid-third of root length or beyond, both of which qualify this patient for being classified as either Stage III or IV based on severity. In this case with no history of any tooth loss, the current severity based on AL and RBL is not underestimated due to prior removal of any severely affected teeth. In cases where teeth have been removed, the remaining teeth often do not adequately

represent the maximum severity of past destruction of periodontal supporting tissues.

Since the severity factors for this case differentiate Stage III and IV from Stage I and II, the primary challenge then becomes how to differentiate Stage III from Stage IV cases.

Stage III and Stage IV cases often include probing depths that exceed 5 mm, vertical bone loss of 3 mm or greater, and class II or III furcation involvement. Stage IV cases, however, are substantially more challenging to treat and often require interdisciplinary approach to

reconstruct masticatory function and lost support for vertical dimension. The Stage IV cases often have fewer than 20 remaining teeth positioned as 10 opposing pairs and may have substantial tooth mobility of degree 2 and greater.

This case does have some drifting and flaring of maxillary anterior teeth but does not exhibit substantial loss of vertical dimension, substantial mobility, or masticatory dysfunction.

Although severe periodontitis is evident in this case, there is no clear indication of teeth having a hopeless status that would suggest periodontitis-driven tooth removal during the initial phase of therapy. Considering that the patient did not lose any teeth due to periodontitis and considering the current efficacy of periodontal regeneration for infrabony defects, this case is more consistent with a Stage III than a Stage IV case (Figure 1(D)). Approximately, 46% of this patient's teeth have AL of 6–11 mm and >30% of teeth have severe RBL, indicating that the extent of severity and complexity of this case should be considered generalized Stage III.

Case management. The Grade for this case was derived primarily from the maximum RBL of approximately 60% of root length/age $46 = 1.3$ ratio, indicating a relatively rapid past progression of bone and connective tissue destruction. The severe inflammatory tissue reaction despite the relatively low levels of plaque and calculus buildup, together with the uncontrolled T2DM (HbA1c: 9.4%) and severe obesity, which further supports a Grade C (Figure 1(E)), that identifies the patient as less likely to respond predictably to standard principles of periodontitis therapy and maintenance. All of the observations noted above lead to a final periodontitis classification for this case of generalized stage III Grade C periodontitis.

Case 2

Case 2, a 34-year-old Caucasian female, presented at the University of Michigan for Periodontal consultation. Medical history was negative for any significant diseases or conditions except for obesity (BMI: 39.2 kg/m²). The patient is a nonsmoker. Currently, she takes no medication but claimed that she occasionally took the following supplements or medications: probiotics to better her immune system, Sertraline HCL^{||} for her anxiety, Lansoprazole[¶] for gastroesophageal reflux disease (GERD), melatonin to help her sleep, and Oxybutynin[#] for frequent urination. Clinical pictures (Figure 2(A)) showed no tooth loss and significant recession of the lower left central incisor (#24). Periodontal evaluations (Figure 2(B)) revealed PD and AL from 5 to 11mm, and radiographic bone loss (Figure 2(C))

extended to the mid-third of root and beyond, with vertical bony defects extending up to the apical third of the root (#24), generalized mobility with localized secondary occlusal trauma (#24, #25).

The clinical severity component of this case would qualify for Stage III or Stage IV periodontitis based on AL level and RBL extending to mid-third of the root and beyond (Figure 2(D)). Stage IV generally is differentiated from Stage III based on a sufficient number of missing teeth such that there is a loss of support for vertical dimension and substantial tooth mobility, drifting, or flaring. Other factors that include probing depths that exceed 5 mm, vertical bone loss of 3 mm or greater, and class II or III furcation involvement do not differentiate Stage III or Stage IV.

Case management. Approximately 78% of the teeth exhibited AL ≥ 5 mm, which contributes to a diagnosis of generalized periodontitis. Regarding the risk of progression, the high ratio of bone loss/age of 1.94 put this patient in the Grade C category. After careful evaluation, the final periodontal diagnosis was determined to be generalized Stage III Grade C periodontitis. Despite the absence of either of the grade modifiers diabetes and smoking, it was interesting to notice the significant inflammation characterizing the patient's periodontium (Figure 2(E)).

Discussion

The primary goal of periodontal treatment is the preservation of natural dentition in health, comfort, function, and esthetics,⁵ and is best achieved through an accurate diagnosis, treatment planning, regular maintenance, and long-term follow-up. The staging and grading system offers a guide for clinicians to highlight the important differentiating features of severe periodontitis cases that may have a major impact on treatment, monitoring, and efforts to identify systemic factors that may influence the patient's response to therapy. Solely considering the severity of disease presentation, both patients mentioned in this manuscript could be classified as either Stage III or IV. Despite the local factors that could affect the complexity of the cases (teeth drifting for Case 1 and secondary occlusal trauma for Case 2) neither patient is likely to lose the whole dentition if properly treated with periodontal etiologic and corrective therapy. An additional factor that complicates the staging diagnosis is the patient's perspective towards an extensive multidisciplinary plan. Despite that Case 1 experienced significant facial drifting of the whole anterior maxillary complex, the patient was not interested to start any orthodontic therapy to improve the occlusal scheme and reestablish a physiological overbite/protrusion. As the patient was considered not at risk of dentition loss without multidisciplinary care, the diagnosis was finalized as Stage III Periodontitis. However, if the patient

^{||}Zoloft, Pfizer Inc., NY, USA.

[¶]Prevacid, Takeda Pharmaceuticals U.S.A., Inc., MA, USA.

[#]Ditropan, Janssen Pharmaceuticals, Inc., NJ, USA.

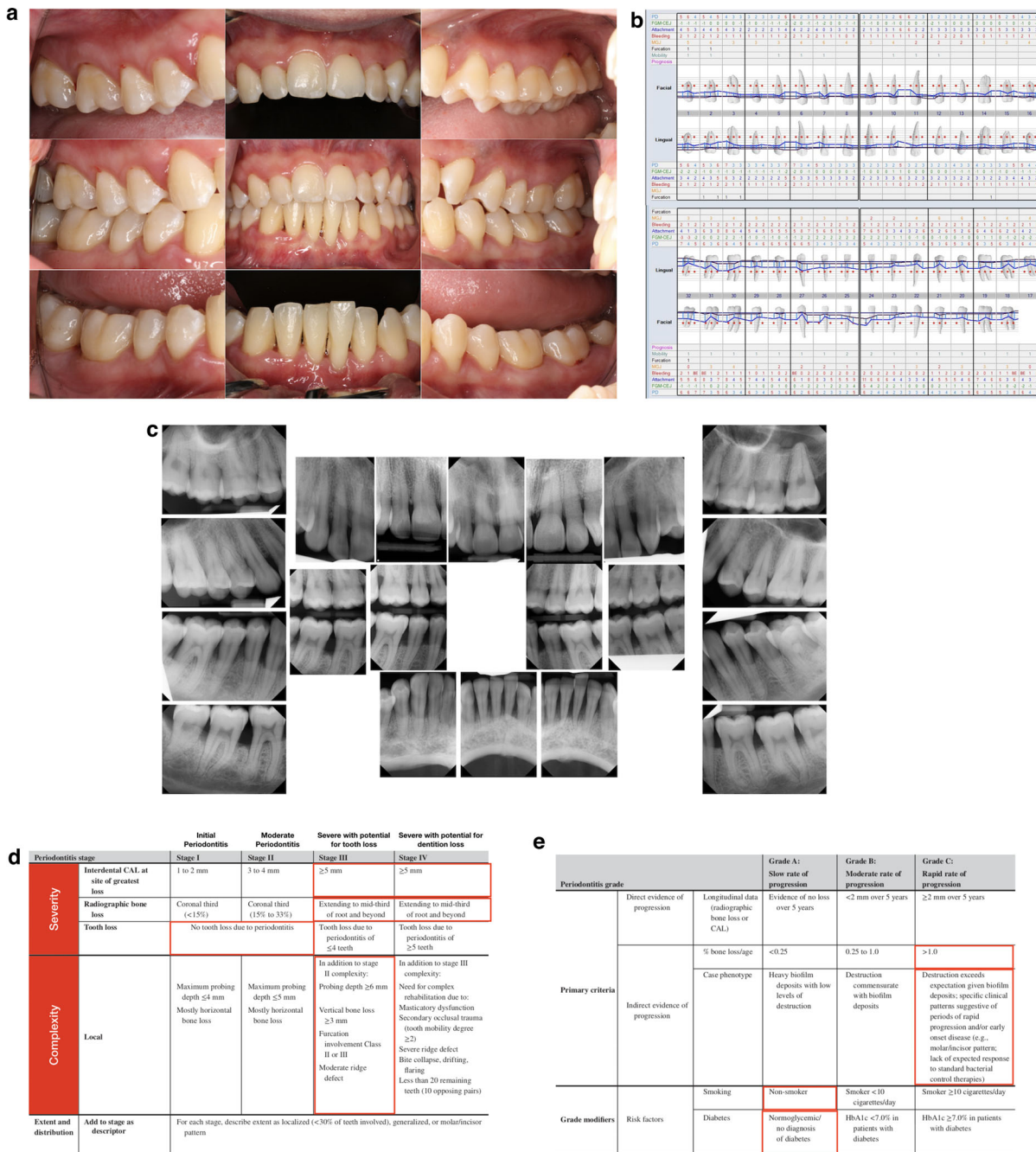


FIGURE 2 Case 2 clinical presentation and classification decision making. (A) Facial intraoral view divided by sextants. (B) Initial maxillary and mandibular chart. Abbreviations. PD, probing depth; FMJ-CEJ, distance from the free gingival margin to the cemento-enamel junction; MGJ, distance from the mucogingival junction to the free gingival margin. (C) Full set of intraoral periapical and bitewing radiographs. (D) Staging matrix as officially reported in the 2017 World Workshop². (E) Grading matrix as officially reported in the 2017 World Workshop.² Figure can be enlarged in online version of this article.

had been interested to undergo orthodontic treatment, further intervention would have been needed and the patient’s diagnosis would then change to Stage IV due to the increased complexity of the overall multidisciplinary rehabilitation. Assigning Grade C for both patients entails additional evaluations in collaboration with the patient’s physician to more accurately identify other risk factors that may influence other chronic inflammatory diseases that may be more predictive of progression of periodontitis. Uncontrolled diabetes mellitus of Case 1 significantly contributed to the imbalance between host immune

response and the local resident microflora. Given current information on these patients, we will assume that the hyper-reactive tissue response featured by high inflammatory appearance despite a low quantity of bacterial debris was the main driver of progressive attachment loss. Case 2 did not present grade modifiers such as smoking and diabetes, and more in-depth evaluations of genetic susceptibility, underlying systemic inflammation, and levels of C-reactive protein were suggested to better understand the origin of her increased susceptibility to rapid periodontal breakdown.

While in some cases it seems obvious from a clinical and patient perspective that a tooth needs extraction, in scenarios of generalized questionable periodontal prognosis clinicians and patients face the dilemma of whether keeping or replacing a tooth will dramatically affect the overall periodontal-occlusal conditions. In these cases, defining a definitive prognosis as well as the best treatment plan appear a subtle task. It is important to keep in mind how the definition of periodontally hopeless tooth changed multiple times over the decades to reflect the advances in periodontal therapy, and how treatment for the preservation of natural dentition still remains the primary goal of periodontology.⁵ In this line of thought, periodontal treatment of generalized Stage III/IV Grade C periodontitis requires significant clinical judgment to best determine the projected tooth prognosis,

and the full-mouth implications that tooth preservation or extraction would provide to the patient seeking care at the periodontal office.

In conclusion, two cases were presented to guide the clinician to better diagnose periodontitis when the clinical appearance would clearly distinguish both cases as being Stage III or IV, but not Stage I or II. It was less clear, however, how one should clarify the distinctions in each of the two cases to guide a Stage III periodontitis classification. The strong distinction between Stage III and Stage IV involves clinical judgment on the implications of prior tooth loss and the near-term risk of losing additional teeth, while the rate of past progression together with grade modifiers guide the best estimate as to how the patient may respond to periodontal therapy based on standard principles of treatment and maintenance care. ■

Summary

Why are these cases new information?	<ul style="list-style-type: none"> ■ The present cases guide an accurate differentiation between Stage III and IV periodontitis, which greatly influences the treatment plan and is crucial for the long-term success of periodontal therapy.
What are the keys for successful management of these cases?	<ul style="list-style-type: none"> ■ Accurate staging of a patient based on the following criteria: ■ The risk to lose more than four teeth, up to the whole dentition. ■ The need for complex multidisciplinary treatment plans for functional rehabilitation.
What are the primary limitations to success in such cases?	<ul style="list-style-type: none"> ■ The distinction between Stage III and IV periodontitis and an accurate assessment of Grade rely on the subjective evaluation of tooth prognosis, which might be biased by operator personal experience, training, knowledge and a patient's overall health orientation.

Conflict of Interest

The authors do not have any financial interests, either directly or indirectly, with the information included in the paper. All the authors report no conflicts of interest related to this case report.

Author Contributions

BS, RDG, SHY, HLW, and KSK: Case documentation, manuscript preparation, and final approval of the manuscript.

Acknowledgments

This paper was partially supported by the University of Michigan Periodontal Graduate Student Research Fund.

CORRESPONDENCE

Hom-Lay Wang, Department of Periodontics and Oral Medicine, University of Michigan School of Dentistry 1011 North University Avenue Ann Arbor, Michigan 48109-1078, USA. Email: homlay@umich.edu

References

1. Armitage GC. Development of a classification system for periodontal diseases and conditions. *Ann Periodontol*. 1999;4:1-6.
2. Papapanou PN, Sanz M, Buduneli N, et al. Periodontitis: consensus report of workgroup 2 of the 2017 World Workshop on the Classification of Periodontal and Peri-Implant Diseases and Conditions. *J Periodontol*. 2018;89(Suppl 1):S173-S182.
3. Kornman KS, Papapanou PN. Clinical application of the new classification of periodontal diseases: ground rules, clarifications and "gray zones". *J Periodontol*. 2020;91:352-360.
4. Sanz M, Papapanou PN, Tonetti MS, Greenwell H, Kornman K. Guest editorial: clarifications on the use of the new classification of periodontitis. *J Periodontol*. 2020;91:1385.
5. Pini Prato GP, Di Gianfilippo R, Wang HL. Success in periodontology: an evolutive concept. *J Clin Periodontol*. 2019;46:840-845.