



# Interproximal attachment gain: The challenge of periodontal regeneration

Giulio Rasperini<sup>1,2</sup> | Lorenzo Tavelli<sup>2</sup> | Shayan Barootchi<sup>2</sup> |  
Michael K. McGuire<sup>2,3,4</sup> | Giovanni Zucchelli<sup>2,5</sup> | Giorgio Pagni<sup>1</sup> |  
Martina Stefanini<sup>5</sup> | Hom-Lay Wang<sup>2</sup> | William V. Giannobile<sup>6</sup>

<sup>1</sup> Department of Biomedical, Surgical and Dental Sciences, University of Milan, Foundation IRCCS Ca' Granda Policlinic, Milan, Italy

<sup>2</sup> Department of Periodontics & Oral Medicine, University of Michigan School of Dentistry, Ann Arbor, MI, USA

<sup>3</sup> Private practice, Houston, TX, USA

<sup>4</sup> Department of Periodontics, Dental Branch Houston and Health Science Center at San Antonio, University of Texas, San Antonio, TX, USA

<sup>5</sup> Department of Biomedical and Neuromotor Sciences, University of Bologna, Bologna, Italy

<sup>6</sup> Harvard School of Dental Medicine, Harvard University, Boston, MA, USA

## Correspondence

Dr. Giulio Rasperini, Department of Biomedical, Surgical and Dental Sciences, University of Milan, Foundation IRCCS Ca' Granda Polyclinic, Via della Commenda 12, 20122 Milan, Italy.  
Email: [giulio.rasperini@unimi.it](mailto:giulio.rasperini@unimi.it)

## Abstract

The new classification of periodontal diseases recognizes the key role of the interdental clinical attachment for defining the periodontal status and the extent of disease severity. Regenerating interdental clinical attachment not only improves the prognosis of the tooth, but it also lessens the severity of the disease condition. This manuscript provides a state-of-the-art review on surgical reconstructive approaches for treating papillary deficiency associated with soft and hard tissue interproximal defects. Combination therapy of papilla preservation, connective tissue grafting, and coronally advanced flaps may result in regeneration of the intrabony defect coupled with root coverage. Future research highlighted here may have the potential, especially in combination approaches, to repair challenging interproximal soft and hard tissue deficiencies.

## KEYWORDS

connective tissue graft(s), gingival recession, growth factors, periodontal regeneration, plastic periodontal surgery

## 1 | INTRODUCTION

Success is a dynamic concept in periodontology.<sup>1</sup> It has been suggested that it should be defined as an effort toward preservation of natural dentition associated with patients' well-being.<sup>1</sup> In particular, the new classification of periodontal diseases recognizes the key role of interdental clinical attachment level (CAL) for defining the periodontal status of and the severity (stage) of the periodontal disease.<sup>2</sup> It is therefore reasonable to assume that the prognosis (and the stage) of periodontal disease can be improved by gaining interdental clinical attachment. The interdental attachment is composed of the

supracrestal attachment, which is measured from the cemento-enamel junction (CEJ) to the base of the pocket in the interproximal area. Interproximal bone loss can occur horizontally and/or vertically, with the interdental soft tissue receding apically. This pattern of interdental bone and attachment loss has a major esthetic impact and also influences the outcomes of regenerating the lost periodontium. In addition, patients' esthetic demands have increased to a point that even a shallow midfacial or interproximal recession following periodontal surgery may be considered unacceptable.<sup>3-5</sup> The presence of open interproximal spaces/black triangles has been considered one of the most troubling dilemmas in dentistry due to



the negative impact on esthetics, phonetics, and food impaction.<sup>6–8</sup> Although several attempts have been made for treating these conditions, limited evidence is currently available regarding the techniques and materials that should be recommended for regenerating the lost interproximal attachment. With this concept in mind, this review presents the available evidence on interproximal attachment gain in healthy and diseased dentitions.

### 1.1 | Factors associated with presence of papilla and clinical implications

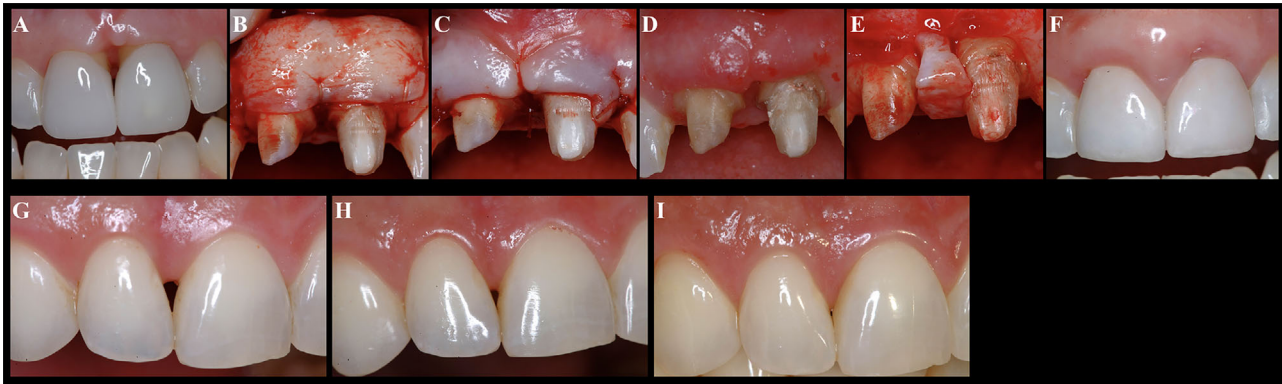Papilla height around teeth is dictated by several factors, such as the distance from the bone crest to the interproximal CEJ, interproximal soft tissue thickness, the degree of inflammation, probing depth of the adjacent teeth, fibrous or edematous nature of the tissue, tooth location, and history of previous non-surgical/surgical therapy, to name a few.<sup>9–12</sup> Nordland and Tarnow described a classification system for the loss of papillary height based on the interdental contact point, facial apical extent of the CEJ, and the interproximal coronal extent of the CEJ.<sup>13</sup> Tarnow et al. found that when the distance between the bone crest and the contact point was  $\leq 5$  mm, the papilla was present in 98% of the cases; this incidence dropped to 56% and 27% when the distance from the bone crest and the contact point became 6 and 7 mm, respectively.<sup>12</sup> In particular, the distance from the bone crest to the contact points ( $\leq 5$  mm), and the interproximal thickness of the gingiva ( $\geq 1.5$  mm), strongly influence the presentation of an interdental papilla (requirements of an ideal case).<sup>14</sup> However, increasing age has been significantly associated with a decrease in the papilla height (0.012 mm decrease in height for every year of increase in age).<sup>14</sup> This study is consistent with the report of Billings et al. that found interproximal sites to be increasingly affected by recessions as age increased, while probing depths remained relatively stable.<sup>15</sup> In addition, it has been shown that tooth form/shape and the curvature of the marginal gingiva (“gingival angle”) can also play a significant role in the presence or the form of papilla.<sup>16</sup>

The patient’s desire for a full papilla is one of the main indications for the treatment of papillae loss or deficient papillae. When this condition is combined with a midfacial gingival recession, the potential of achieving complete root coverage are significantly reduced.<sup>17,18</sup> In a recent commentary, Zucchelli et al. identified four different clinical scenarios in relation to the presence of the papilla and the supporting periodontium: 1) partially missing papilla without clinical attachment/bone loss, 2) partially missing papilla associated with interdental attachment/bone loss, 3) intact papilla with clinical attachment/bone loss, and 4) intact papilla without clinical attachment/bone loss.<sup>18</sup>

### 1.2 | Treatment of papillary deficiency in healthy dentition

It is crucial to distinguish papilla deficiency between healthy versus diseased periodontia. In the case of a healthy periodontium, deficient papillae may be surgically reconstructed using soft tissue grafts, may be regenerated with orthodontic treatment, or may be improved by modifying the restoration(s) with longer contact points.<sup>14,19</sup>

The techniques that have been described for attempting reconstructing of the interproximal attachment loss have merely focused on the soft tissue component. Papilla reconstruction has been described with the use of soft tissue grafts or substitutes (connective tissue graft [CTG] or acellular dermal matrix),<sup>6,20,21</sup> hyaluronic acid,<sup>22,23</sup> platelet-rich fibrin,<sup>24,25</sup> cultured and expanded autogenous fibroblast injections,<sup>8</sup> stem cell therapy,<sup>26</sup> and photobiomodulation therapy (Fig. 1).<sup>27</sup> While some authors have reported promising results for papilla gain and reduction of the open interproximal spaces, these studies are largely case reports or case series with a limited number of patients (Table 1). The only randomized clinical trial to treat interdental papilla insufficiency was conducted by McGuire and Scheyer who evaluated the efficacy and safety of autologous fibroblast injections versus placebo in combination with a minimally invasive papilla augmentation technique.<sup>8</sup> In the study, each patient contributed two sites that were randomized to either receive injections of fibroblasts or placebo. Autogenous fibroblasts were collected with punch biopsies from the maxillary tuberosity and cultured and expanded in the laboratory. At 5 to 7 days before the injection of the fibroblasts or placebo, the papilla received a controlled surgical injury aimed at inducing an acute inflammatory response. The first injection occurred 5 to 7 days after the papilla priming procedure, the second treatment 7 to 14 days later, and the third 7 to 14 days after the second injection. A significant increase in papillary height was observed in the test group after 2 months, while no significant differences were noted between the two groups at 3 or 4 months. Interestingly, in some cases following the completion of the study, the authors observed a continuing improvement overtime after the last administration.<sup>8</sup> Esthetic evaluation (visual analogue scale) administered by the masked investigator and the subjects showed statistically significant improvements in the test sites, corroborating the efficacy of autologous fibroblast injections in treating papilla insufficiency. In addition, the treatment was found to be safe with no infections, rejections, granuloma formation, or other complications. Furthermore, the histological analysis showing the delivered



**FIGURE 1** **A through F)** Papilla augmentation with connective tissue graft. A) Baseline. B) Crowns were removed, and a connective tissue graft (CTG) was placed facial to central incisors to thicken the phenotype. This tissue will later be advanced into the papillary region. C) Partial thickness flap advanced over the GTG. D) Six weeks healing following CTG. E) Interpositional CTG harvested from tuberosity and placed interproximal to central incisors. A partial thickness flap released and elevated over the interpositional graft. F) One-year post-op demonstrating the reconstructed interproximal papilla. **G through I)** Expanded autologous fibroblasts injections for the treatment of interdenal papillary insufficiency. G) Baseline. H) Four months after autologous fibroblasts injections. I) 5-year recall

fibroblasts incorporated into the dermal architecture.<sup>8</sup> Nevertheless, more studies with long-term follow-up are encouraged to further evaluate the efficacy of this approach.

Contrastingly, it is worth mentioning that a recent controlled study evaluating the efficacy of hyaluronan injection for augmenting papilla volume at implant sites reported two cases with adverse reactions out of the 11 treated patients.<sup>28,29</sup> Both patients presented with swelling and extreme tenderness with a burning sensation on the lip next to the treated side. In one patient, a skin discoloration was also observed.<sup>29</sup> The symptoms lasted for up to 7 days, with no permanent consequences. The authors speculated that the signs and symptoms were likely suggestive of water attraction by the hyaluronan with progressive vascular compression rather than an infection or allergic reaction.<sup>29</sup>

The treatment approaches that have been proposed for reconstruction of insufficient interproximal attachment/papillae have been summarized in Table 1.

### 1.3 | Interproximal attachment gain in the presence of periodontal disease

Periodontal disease is a multifactorial condition characterized by bacterial biofilm dysbiosis in a susceptible host.<sup>2</sup> The first phase of periodontal treatment involves the identification of risk and contributing factors that led to the condition. Periodontal non-surgical therapy including oral hygiene instruction, patient motivation, and mechanical therapy aims at removing etiological and contributing factors such as biofilm, calculus, and inflammation while

improving patient compliance.<sup>1,30,31</sup> The importance of a strict oral hygiene regimen on tooth retention has been largely demonstrated.<sup>32,33</sup> In particular, minimally invasive non-surgical therapy has been shown to be effective in removing the biofilm and reducing the probing depth without causing a significant shrinkage of the soft tissues in periodontal intrabony defects<sup>34,35</sup> (see Supplementary Figure 1 in online *Journal of Periodontology*). It has been suggested that soft tissue healing and maturation may take up to 9 to 12 months after the non-surgical procedure.<sup>36,37</sup> Therefore, it is recommended to allow for an adequate time period following non-surgical therapy before performing a periodontal regenerative surgery.

Clinical and histological evidence supports the efficacy of periodontal regenerative procedures in regenerating the lost periodontium over previously diseased sites, with a significant CAL) gain and probing depth reduction that can change the prognosis of a hopeless tooth.<sup>38–40</sup>

Starting from the first report demonstrating periodontal regeneration in humans,<sup>41</sup> there is no doubt that the progressive evolution of the surgical techniques and biomaterials have highly contributed to the success and predictability of this procedure.<sup>42–44</sup> The introduction of papilla preservation techniques<sup>45–47</sup> has had a positive impact on the stability of the wound and on the possibilities of achieving healing by primary intention,<sup>42,43,48</sup> which has been shown to be crucial for the outcomes of guided tissue regeneration.<sup>49,50</sup> Later on, with the concomitant evolution of biomaterials, minimally invasive and microsurgical approaches have been described.<sup>42,43,48</sup> These techniques involved a reduction in flap extensions and the use of bone grafts and/or biologics, such as enamel

TABLE 1 Strategies for papilla augmentation in healthy dentition

Graft/ Scaffold/ cells	Publication	Study design	Patient/ Sites/ follow-up	Surgical technique	Reported outcomes	Conclusion
Connective tissue graft	Carnio, 2004 <sup>6</sup>	Case report	1/1/4 years	Semilunar buccal incision, detachment of the soft tissue with the Orban knife, insertion of the CTG. Two other similar surgical procedure were performed in the same area over time	Complete papilla reconstruction	This technique may be used to regenerate a lost interdental papilla
	Carnio and Carnio, 2018 <sup>85</sup>	Case report	1/1/10 years	Interdisciplinary (periodontic-orthodontic-restorative) approach. Two surgeries were performed with the following approach: split-thickness semilunar incision 2 mm coronal to the MGJ and intrasulcular incision with fully preservation of the papilla. A buccal/palatal void was created and filled with CTG harvested from the palate/tuberosity	PD change: 2 mm for tooth #7 and no change for tooth #8 REC reduction: 4 mm KT gain: 2 mm for tooth #7, 1 mm for tooth #8	The patient's esthetic expectations were met in the initial phase of the treatment. Some rebound was observed in the long-term
	Feuillet et al., 2018 <sup>20</sup>	Case series	3/3/2 years	Full thickness tunnel technique with parallel releasing incisions made on the palatal side (and split-thickness flap). CTG trimmed and inserted into the flap and papilla coronally advanced	Improved in papilla height in all the treated cases	These preliminary results obtained with this technique for the reconstruction of the interdental papilla are promising
	Kaushik et al., 2014 <sup>86</sup>	Case series	10/15/6 months	Semilunar buccal incision, detachment of the soft tissue with the Orban knife, insertion of the CTG	Mean distance from contact point to the gingival margin significantly decreased*	This technique has the potential to reconstruct papilla loss that occurs solely due to soft-tissue damage
	Sharma et al., 2017 <sup>87</sup>	Case series	11/11/6 months	Partial thickness flap with two vertical incisions away from the line angles of the involved teeth, coronal displacement of the papillary unit. CTG harvested from the palate was stabilized in the created void between the soft tissue and the bone. Periodontal dressing applied	PD changes: 0.27 mm* CAL gain: 0.41 mm† Reduction in VC: 37.01%† Reduction in HC: 37.66%† Area of black triangle reduction: 60.26%†	A significant improvement was observed in the treated sites in term of reduction of the area of the black triangle and CAL gain. However, complete regeneration of interdental papilla was not achieved

(Continues)



TABLE 1 (Continued)

Graft/ Scaffold/ cells	Publication	Study design	Patient/ Sites/ follow-up	Surgical technique	Reported outcomes	Conclusion
Acellular dermal matrix	Geurs et al., 2012 <sup>21</sup>	Case series	12/38/5 months	Vertical incision for access, extending apically from the mucogingival junction with facial and palatal intrasulcular incisions. Detachment of the flap and insertion of micronized dermal graft in the space created to support the papilla	Significant decrease in gingival recession <sup>†</sup> and papillary index. † Trend towards a decrease in probing depth	This technique showed promised results for papillary reconstruction
Hyaluronic acid gel injections	Awartani and Tatakis, 2016 <sup>22</sup>	Case series	9/17/6 months	Injection of hyaluronic acid followed by gentle massage of the area. Injection repeated at 21 and 42 days	41% ± 37% reduction of interdental papilla loss <sup>†</sup>	Use of hyaluronic acid gel to treat interdental papilla loss resulted in significant improvement at 6 months
	Lee et al., 2016 <sup>88</sup>	Case series	10/43/6 months	Injection of hyaluronic acid up to five times during the first 3 weeks	Reduction in the black triangle height and width	Injectable hyaluronic acid gel may be a promising treatment for enhancing papillary esthetics
Hyaluronic acid dermal filler	Spano et al., 2020 <sup>23</sup>	Case series	3/4/6 months	Horizontal incisions at the level of the alveolar mucosa, a subperiosteal tunnel was created. Hyaluronic acid dermal filler administered with a needle into the papilla. Cyanoacrylate used to seal the soft tissue surrounding the papilla	Mean papilla fill of 1.75 mm Patients' perception of papilla fill (VAS): 59.76–62.46%	
Platelet-rich fibrin	Ahila et al., 2018 <sup>89</sup>	Case series	25/25/6 months	Semilunar buccal incision, detachment of the soft tissue with the Orban knife, platelet-rich fibrin was inserted in the interproximal void	Baseline distance from the contact point to the tip of the papilla: 4.38 ± 0.36 mm, while at 6-month follow-up it was 0.36 ± 0.64 mm <sup>†</sup>	The augmentation of the papilla using platelet-rich fibrin in the new position was stable when reviewed at 3 and 6 months postoperatively
	Arunachalam et al., 2012 <sup>24</sup>	Case report	1/1/6 months	Semilunar incision in the alveolar mucosa, split-thickness flap preparation to create a pouch in the interdental area. Gingivopapillary unit coronally displaced. Platelet-rich fibrin inserted into the pouch and pushed coronally	The interdental papilla filled the interproximal embrasure to the same level as in the proximal teeth	Use of platelet-rich fibrin may be a valid option for interdental papilla augmentation

(Continues)



TABLE 1 (Continued)

Graft/ Scaffold/ cells	Publication	Study design	Patient/ Sites/ follow-up	Surgical technique	Reported outcomes	Conclusion
Cultured and expanded autologous fibroblast injections	McGuire and Scheyer, 2007 <sup>8</sup>	RCT	20/20/4 months	Autogenous fibroblasts were collected with punch biopsies from the maxillary tuberosity and cultured and expanded in the laboratory. Five to seven days before the injection of the fibroblasts or placebo, the papilla received a controlled surgical insult aimed at inducing an acute inflammatory response. The first injection occurred 5 to 7 days after the papilla priming procedure, the second treatment 7 to 14 days later, and the third treatment 7 to 14 days after the second injection	A significant increase in papillary height was observed in the test group after 2 months (compared with placebo), while no significant differences were noted between the two groups at 3 and 4 months. Professional and patient esthetic evaluation showed statistically significant improvement in the test sites (fibroblasts injections)	This technique is safe and may be effective for treating papillary insufficiency
Tissue-engineered papilla injections	Yamada et al., 2015 <sup>26</sup>	Case series	5/5/69 months	Injectable tissue-engineered papilla (hyaluronidic acid as scaffold, stem cells, platelet rich plasma as growth factor)	Improved black triangle: 2.26 ± 0.7 mm	This technique was able to provide esthetic improvement of black triangles
Photobiomodulation therapy with diode laser	Zanin et al., 2018 <sup>27</sup>	Case report	3/3/5 years	Gingival bleeding caused by gently stimulating the gingival sulcus with a probe. Photobiomodulation therapy with 660 nm diode laser, punctual, contact mode before bleeding and also immediately after bleeding. The same procedures were performed after 1 week	All three patients showed improvement in the size of the papilla	This approach seems to be an innovative non-invasive therapy to fill in black spaces, improving esthetics and restoring the function of papilla in patients with black spaces

CAL, clinical attachment level; HC, horizontal component of the black triangle, measured at line angles of adjacent teeth at the gingival margin; KT, keratinized tissue; MGI, mucogingival junction; PD, probing depth; REC, recession; VAS, visual analogue scale; VC, vertical component of the black triangle. Distance from the apical point of the contact area to the gingival margin. \* $P < 0.05$ . † $P < 0.001$ .

matrix derivative (EMD), platelet-derived growth factor (PDGF), or fibroblast growth factor-2 (FGF-2) instead of using barrier membranes<sup>51–57</sup> (Table 2). Microsurgical approaches have been advocated due to their ability for improving illumination and magnification of the surgical field, atraumatically manipulating the flap, carrying out high precision debridement, and precise placement of the biomaterials and securing the flap.<sup>42,51</sup> Nonetheless, the occurrence of gingival recessions or the increase in recession depth following periodontal regeneration is not a rare finding<sup>5,58–60</sup> In a meta-analysis of randomized controlled trials, Graziani et al. reported that an increase in recession depth of 1.15 mm at 12 months and of 1.78 mm for longer follow-ups should be expected after flap surgeries for the treatment of intrabony defects.<sup>60</sup> In particular, bone defects with non-supporting anatomy and thin soft tissue phenotypes were found to be risk factors for an increased recession depth.<sup>61</sup> Gingival recessions may also negatively impair patients' esthetics and satisfaction of the treatment, especially if the treated tooth is in the anterior area.<sup>3–5,62</sup>

Therefore, it is not surprising that some authors have proposed the use of periodontal plastic surgery techniques when treating intrabony defects to maintain, or coronally advanced the level of the gingival margin.<sup>3,4,62–64</sup>

Zucchelli and De Sanctis proposed a modified approach for the treatment of intrabony defects (with EMD), that involved the use of an envelope coronally advanced flap,<sup>3</sup> as described previously in root coverage procedures.<sup>65</sup> The buccal flap was released, coronally advanced, and anchored to the defect's de-epithelialized adjacent papillae. The authors claimed that this approach could reduce the risk for supracrestal soft tissue collapse inside the intrabony component, and also increase the space for regeneration.<sup>3</sup> Rasperini et al. proposed the "soft tissue wall technique" for the regenerative treatment of non-contained intrabony defects in which the papilla preservation technique was combined with the trapezoidal coronally advanced flap followed by sling sutures for its coronal stabilization, and an internal mattress suture for achieving primary intention healing and closure of the papilla.<sup>4</sup> After 12 months, the authors observed a significant improvement in interdental CAL gain ( $7.1 \pm 1$  mm), with a mean recession reduction of  $1 \pm 0.4$  mm.<sup>4</sup>

Based on the claimed advantages of the tunnel technique for root coverage (high esthetic outcomes, blood supply, graft nutrition, and quick healing<sup>66,67</sup>), the "entire papilla preservation" technique was introduced for treating intrabony defect by combining the tunnel approach with the papilla preservation to avoid any opening on the papillae.<sup>68</sup> This approach can limit the risk of wound sloughing or papillae exposure during early healing,

securing the biomaterials and enhancing the esthetic outcomes.<sup>63,68</sup> Indeed, in a recent randomized controlled trial, the authors showed that the entire papilla preservation technique resulted in a 100% primary wound closure, with a significant CAL gain and a negligible increase in recession depth (0.2–0.36 mm).<sup>69</sup>

Other approaches avoiding incisions at the level of the papilla have been described, such as the modified vestibular incision subperiosteal tunnel access (M-VISTA)<sup>64</sup> and the "non-incised papillae surgical approach" (NIPSA).<sup>70</sup> According to Moreno Rodriguez et al., the NIPSA achieved similar outcomes to a traditional minimally invasive papilla preservation technique, with a significantly lower recession at the tip of the interdental papilla (increased recession depth 0.2 versus 0.73 mm 1 year after, respectively).<sup>70</sup> In the following study, the same authors found that NIPSA was able to provide not only a significant improvement in CAL but also a significant recession reduction ( $0.25 \pm 0.44$  mm) and a coronal advancement of the tip of the papillae after 1 year ( $0.4 \pm 0.5$  mm).<sup>71</sup>

In an attempt to further enhance the amount of root coverage when treating intrabony defects, connective tissue graft (CTG)-based techniques have been proposed<sup>5,62,72</sup> (Fig. 2). Indeed, CTG can act as a biological filler enhancing flap stability and wound strength.<sup>73–75</sup> The firm adaptation of CTG to the root surface can also promote a stable coagulation cascade and protect the maturing fibrin clot.<sup>73</sup> In addition, CTG results in a significant gingival tissue thickness gain, which has been positively related to an improved likelihood for achieving complete root coverage.<sup>74,76</sup> The increase in soft tissue volume and creeping attachment associated with CTG,<sup>75,76</sup> also positively influence the esthetic outcomes following periodontal regenerative therapy.

In a comparative clinical study, Trombelli et al. observed that the addition of CTG to the single flap approach resulted in reduced recession depth, reduced residual defects with a clinically detectable apical displacement of the gingival margin, and an increase in gingival tissue volume.<sup>5</sup> Similarly, the addition of CTG has been described for the NIPSA as well, with an improvement in the marginal soft tissue and a significant CAL gain observed in all the treated cases.<sup>72</sup>

Additionally, CTG can also be used as a mechanical barrier in clinical scenarios with intrabony defects, a narrow soft tissue isthmus, buccal and interproximal recessions and a lack of a buccal bone wall.<sup>62</sup> The "connective tissue graft wall" technique was introduced by Zucchelli et al. for improving root coverage and CAL in RT3 gingival recessions<sup>77</sup> and was adapted for the treatment of intrabony defects.<sup>62</sup> The technique uses a palatal incision to gain access to the bone defect, with a split-full-split

**TABLE 2** Evolution of surgical technique and biomaterials for the regeneration of intrabony defects, categorized according to the type of periodontal regenerative procedures: I) papilla preservation techniques, ii) mucogingival flaps, and iii) mucogingival flaps + connective tissue grafts

Technique	Publication	Study design	Patient/Sites/ follow-up	Flap design	Bone graft/ biomaterials	CAL gain (mean $\pm$ SD) (mm)	PD reduction (mean $\pm$ SD) (mm)	REC change (mean $\pm$ SD) (mm)
PPT	Takei et al. 1985 <sup>47</sup>	Case series	NR	Semilunar incision perpendicular to the outer surface at palatal aspect. Incision must be at least 3 mm away from the margin of interproximal bony defect	With or without bone graft	NR	NR	NR
MPPT	Cortellini et al. 1995 <sup>45</sup>	Case series	15/15/6 weeks	Horizontal incision at the base of the papilla on the facial aspect. The papilla is reflected toward palatal aspect	Titanium-reinforced teflon membranes	NR	NR	NR
SPPT	Cortellini et al. 1999 <sup>46</sup>	Case series	18/18/ 12 months	Oblique incision from line angle to midpoint of the adjacent tooth, the blade angulation is kept parallel to the long axis of the tooth	Bioresorbable barrier membrane	4.9 $\pm$ 1.8	5.8 $\pm$ 2.5	0.8 $\pm$ 1.6
Surgical technique with EMD	Rasperini et al. 1999 <sup>90</sup>	Case report	3/3/12-18 months	Intrasulcular incisions, PPT in the interproximal area, beveled vertical releasing incisions mesial and distal to the surgical sites	EMD	NR	NR	NR
Microsurgical flap	Wachtel et al. 2003 <sup>35</sup>	RCT	11/11/12 months	Buccal and lingual sulcular incisions with microsurgical blades, MPPT in the interproximal area	EMD	3.6 $\pm$ 1.6	3.9 $\pm$ 1.4	0.3 $\pm$ 0.8
Regenerative approach with rhPDGF-BB	Nevins et al. 2005 <sup>54</sup>	RCT	11/11/12 months	Full thickness buccal and lingual flaps reflection	None	1.7 $\pm$ 1.4	2.1 $\pm$ 1.1	0.4 $\pm$ 0.9
MIST	Cortellini and Tonetti 2007 <sup>52</sup>	Case series	13/13/12 months	MPPT or SPPT based on the dimension of the interproximal area. Reflection of the defect-associated interdental papilla only. Full-thickness flap elevation just to expose 1-2 mm bone crest, no extension beyond mucogingival junction	EMD 1 mg/mL rhPDGF-BB + $\beta$ TCP	3.8 $\pm$ 0.4	NR	NR
					EMD	3.7 $\pm$ 0.4	NR	NR
					EMD	4.8 $\pm$ 1.9	4.8 $\pm$ 1.8	-0.1 $\pm$ 0.9

(Continues)





TABLE 2 (Continued)

Technique	Publication	Study design	Patient/Sites/ follow-up	Flap design	Bone graft/ biomaterials	CAL gain (mean ± SD) (mm)	PD reduction (mean ± SD) (mm)	REC change (mean ± SD) (mm)
M-MIST	Cortellini and Tonetti 2009 <sup>53</sup>	Case series	15/15/12 months	Same as described MIST, but the incisions and flap elevation are performed only on the buccal aspect	EMD	4.5 ± 1.4	4.6 ± 1.5	0.07 ± 0.3
SFA	Trombelli et al. 2009 <sup>91</sup>	Case series	10/10/10 months	Flap elevation only on one side (either buccal or palatal). Intrasulcular incision with limited mesio-distal extension of the envelop flap. Horizontal or oblique interproximal incision based on the defect profile.	Collagen membrane + HA bone graft	4.8 ± 2.7	5.2 ± 2.6	0.4 ± 1.5
MPPT/SPPT + rhFGF-2	Saito et al. 2019 <sup>36</sup>	RCT	16/22/6 months	MPPT or SPPT	rhFGF-2	2.78 ± NR	3.29 ± NR	0.16 ± NR
eCAF + EMD	Zuchelli and De Sanctis 2008 <sup>3</sup>	Case series	15/15/12 months	eCAF as described in mucogingival surgery for the treatment of multiple gingival recessions. Flaps extended to the neighboring teeth in both facial and lingual/palatal aspects. SPPT in the interproximal areas. Buccal flap raised split-full-split. Anatomical papillae de-epithelialized and the flap was coronally advanced	rhFGF-2 + DBBM EMD	3.16 ± NR 5.9 ± 1.4	3.55 ± NR 6 ± 0.8	0.39 ± NR 0.1 ± 1
Soft tissue wall technique	Rasperini et al. 2013 <sup>4</sup>	Case series	9/9/12 months	PPT combined with the trapezoidal CAF and sling suture to stabilize it coronally and an internal mattress suture to close the papilla for primary intention	EMD	7.1 ± 1	6.3 ± 2	-1 ± 0.4
EPP	Aslan et al. 2017 <sup>63</sup>	Case series	12/12/12 months	Tunnel-like approach to the defect-associated interdental papillae with a buccal sulcular incision and a vertical releasing incision made in the facial aspect of the neighboring interdental space	DBBM + EMD	6.8 ± 2.5	7 ± 2.8	0.2 ± 0.4
	Aslan et al. 2020 <sup>69</sup>	RCT	30/30/12 months	Same as described above	DBBM + EMD	6.3 ± 2.5	6.5 ± 2.7	0.2 ± 0.3
					None	5.8 ± 1.1	6.2 ± 1.3	0.4 ± 0.5 (Continues)



TABLE 2 (Continued)

Technique	Publication	Study design	Patient/Sites/ follow-up	Flap design	Bone graft/ biomaterials	CAL gain (mean $\pm$ SD) (mm)	PD reduction (mean $\pm$ SD) (mm)	REC change (mean $\pm$ SD) (mm)
M-VISTA	Najafi et al. 2018 <sup>64</sup>	Case report	2/2/18 months	Two vertical incisions in the alveolar mucosa, gentle subperiosteal tunnel elevation, degranulation and biomaterials insertion.	DFDBA + EMD	NR	NR	NR
NIPSA	Moreno Rodriguez et al. 2019 <sup>71</sup>	Case series	20/20/12 months	Apical oblique or horizontal incision in the buccal aspect of the alveolar mucosa placed on cortical healthy bone. After debridement, the papillary structure was pulled coronally with a micro-papillae elevator. Biomaterials were then applied, and flap sutured.	DBBM + EMD	5.9 $\pm$ 2.38	5.6 $\pm$ 2.48	-0.3 $\pm$ 0.44
CTG wall technique + EMD	Zucchelli et al. 2014 <sup>77</sup>	Case-control study	30/30/6 months	Palatal/lingual flap not elevated. CTG sutured below a coronally advanced flap acting as a buccal soft tissue wall. EMD applied into the bony defect.	EMD	3.8 $\pm$ 2.4	2.75 $\pm$ 2.8	-1 $\pm$ 0.8
SFA + CTG	Trombelli et al. 2017 <sup>5</sup>	Case-control study	30/30/6 months	Sulcular incision with an oblique or horizontal butt-joint incision at the level of the interdental papilla. A buccal mucoperiosteal envelope flap was elevated, leaving the interdental supracrestal soft tissue undetached. CTG was fixed to the envelope flap or to the inner portion of the connective tissue of the interdental papillae. CTG was completely covered by the flap or slightly exposed in its coronal aspect.	DBBM + EMD	3.2 $\pm$ 1.5	4.3 $\pm$ 1.8	0.4 $\pm$ 1.2

(Continues)



TABLE 2 (Continued)

Technique	Publication	Study design	Patient/Sites/ follow-up	Flap design	Bone graft/ biomaterials	CAL gain (mean ± SD) (mm)	PD reduction (mean ± SD) (mm)	REC change (mean ± SD) (mm)
NIPSA + CTG	Moreno Rodriguez et al. 2019 <sup>72</sup>	Case report	4/4/12 months	NIPSA technique with the only difference that the supra-alveolar soft tissue was pushed coronally before using EMD, bovine bone and CTG	DBBM + EMD	5.8 ± 1.3	5.3 ± 0.5	-0.8 ± 0.5
Modified CTG wall technique + EMD	Zuchelli et al. 2017 <sup>62</sup>	Case report	2/2/12 months	Palatal incision to gain access to the bony defect. eCAF in the buccal side. CTG stabilized and sutured on the buccal side. EMD applied in the bony defect. Flap coronally advanced and sutured.	EMD	6.5 ± 1.4	5.7 ± 1.6	-1.7 ± 1.2

Note that a positive value for REC change means an increasing of recession depth, while a negative value a recession reduction.

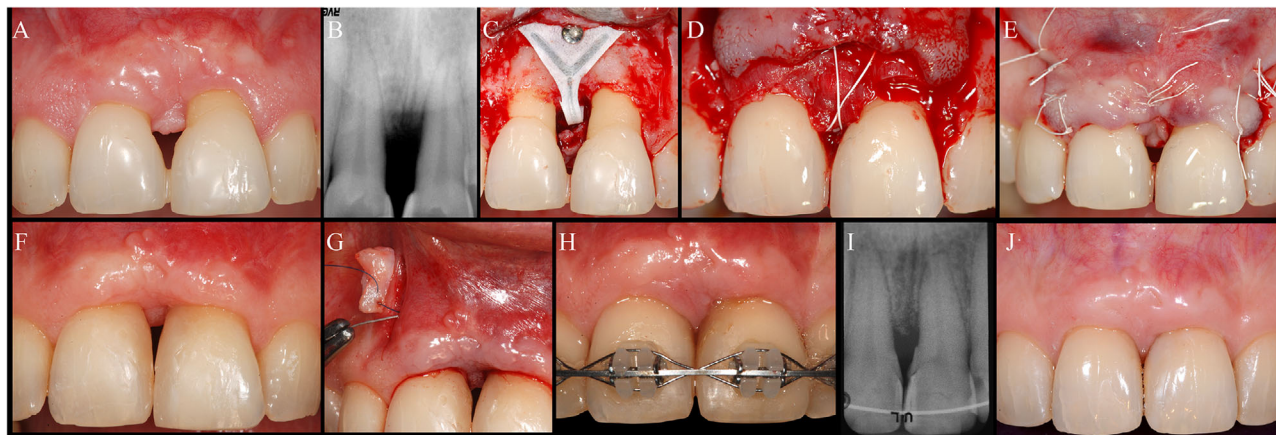
Abbreviations: βTCP, beta tricalcium phosphate; CTG, connective tissue graft; eCAF, envelope coronally advanced flap; DBBM, deproteinized bovine bone matrix; DFDBA, demineralized freeze-dried bone allograft; EMD, enamel matrix derivative; EPP, entire papilla preservation; HA, hydroxyapatite; MIST, minimally invasive surgical technique; M-MIST, modified minimally invasive surgical technique; MPPT, modified papilla preservation technique; M-VISTA, modified vestibular incision subperiosteal tunnel access; NIPSA, nonincised papillae surgical approach; NR, not reported; PPT, papilla preservation technique; RCT, randomized controlled trial; rhFGF-2, recombinant human fibroblast growth factor-2; rhPDGF-BB, recombinant human platelet-derived growth factor-BB; SEA, single flap approach; SPPT, simplified papilla preservation technique.

envelope coronally advanced flap performed on the buccal side. CTG obtained from the de-epithelialization of a free gingival graft is sutured coronally at the base of the de-epithelialized papillae of the adjacent teeth neighboring the bony defect, while apically it is secured at the periosteum apical to the bone defect. The technique includes the application of EMD into the intrabony defect. According to the authors, this approach may enhance the complete resolution of deep intrabony defects while improving the buccal and interproximal soft tissue.<sup>62</sup> Interestingly, the above-mentioned techniques used the CTG obtained from the de-epithelialization of a free gingival graft, used as a barrier for the treatment of intrabony defects. Indeed, it has been suggested that the quality and the handling of a CTG obtaining from the most superficial lamina propria of the palate is superior to the properties of a subepithelial CTG harvested from the deep palate,<sup>75,78</sup> which may also have an impact on the regenerative outcomes. In particular, in the presence of defects lacking buccal bone, with a high suprabony component and thin phenotype, using a dense CTG sutured at the level of the CEJ promotes the stabilization of the blood clot in both infra and suprabony components, allowing periodontal regeneration and new connective tissue formation in the suprabony component (Fig. 3).

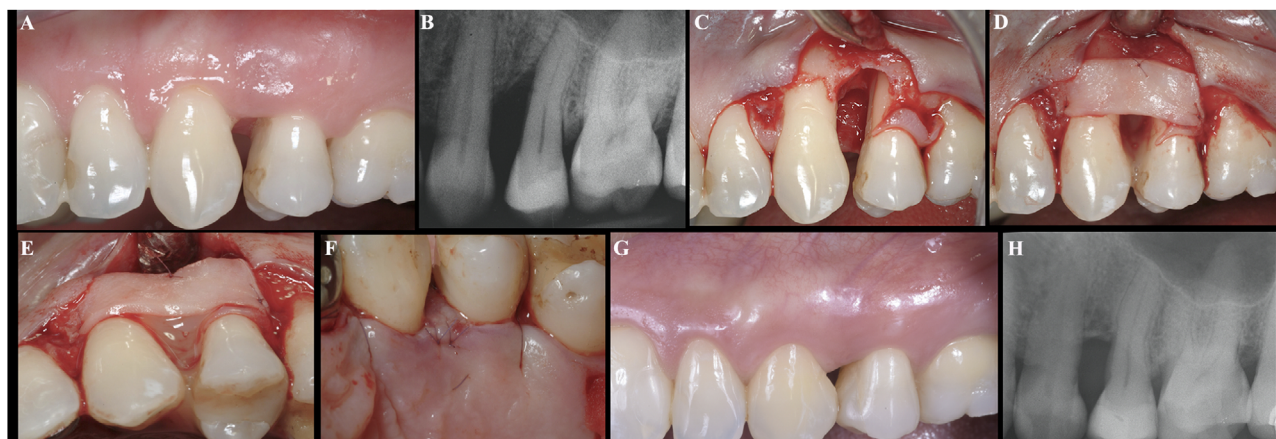
Shallow intrabony defects or horizontal bone loss in the labial area represent another challenging clinical scenario. The lack of a 3 mm infrabony component limits the predictability of periodontal regeneration and the need to preserve esthetics is a contraindication for osseous resective surgery. A conservative approach, combining palatal incisions in the interproximal area to get access to the bone defects with connective tissue graft sutured at the buccal aspect, may be used also to treat of these defects, in particular at sites with a thin phenotype (Fig. 4) (Table 2).

### 1.4 | Future directions

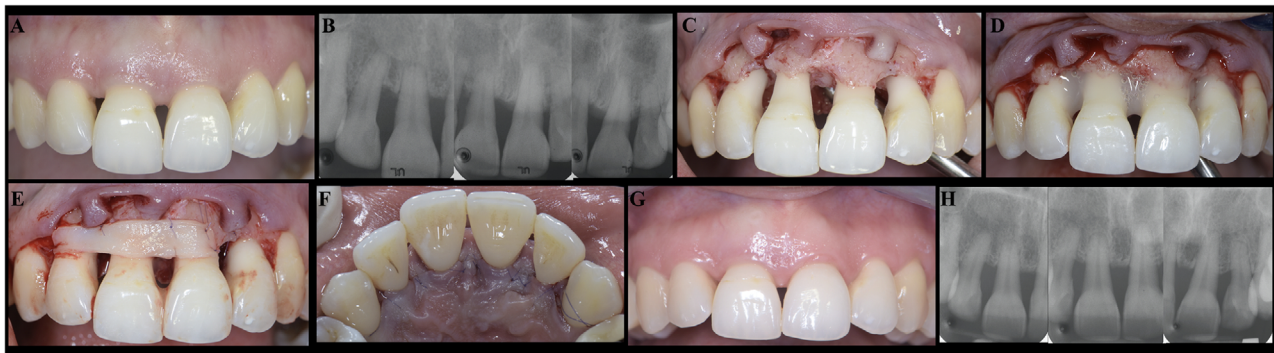
Interproximal attachment gain and papilla reconstruction are considered one of the major challenges in periodontics. The applications of protein and peptide therapy, cell-based therapy, gene therapy, or scaffolds are emerging tissue-engineering approaches<sup>79,80</sup> that may improve the predictability of current techniques in improving/regenerating the interproximal attachment. The possibility of customizing bioresorbable scaffolds to the desired size, configuration, and architecture in combination with a controlled growth factors delivery<sup>81-83</sup> may represent the future direction for simultaneous hard and soft tissue regeneration of interproximal defects.



**FIGURE 2** **A and B)** A 42-year-old female patient was referred after multiple attempts of periodontal treatment between the two central incisors that resulted in interproximal attachment loss. The teeth were vital, with interproximal composite added to close the diastema. **C)** Considering the horizontal bone loss and the distance between the bone and the contact point<sup>12</sup> and the distance between the roots, a titanium-reinforced membrane was adapted with a palatal and buccal pin to provide support to the graft and the flap. **D)** Emdogain (Straumann, Switzerland) and xenogeneic bone graft (BioOss, Geistlich, Switzerland) were mixed and positioned inside the defect. A collagen membrane (BioGide, Geistlich, Switzerland) was adapted to the site and positioned above the graft. The flap was coronally advanced and sutured with a crossed internal mattress suture, as described for the modified papilla preservation technique.<sup>45</sup> **E)** After de-epithelialization of the mesial and distal papillae, the flap was coronally stabilized without tension by means of additional mattress and simple sutures. **F)** The titanium-reinforced membrane and the pins were removed 2 months later. A significant interproximal and buccal clinical attachment level gain was observed after 6 months, but the interproximal soft tissue was still missing. **G)** The VISTA technique<sup>84</sup> in combination with CTG harvested from the maxillary tuberosity was performed to augment the papilla. The graft was stabilized with a palatal mattress suture under the papilla. EMD was added from the sulcus. **H)** Removal of the composite after 4 months, with the diastema that was closed with orthodontic treatment. **I and J)** Outcomes at the 24-month recall, with the patient showing her natural vital teeth with complete interdental clinical attachment level gain



**FIGURE 3** Connective tissue graft wall technique. **A)** Baseline clinical situation with papilla loss and interdental soft tissue crater. **B)** X-ray showing a bone defect with deep infrabony component and high suprabony component. **C)** Palatal incision to preserve the supracrestal soft tissue and buccal flap elevation. **D)** CTG extended in apico-coronal direction from the CEJ of the canine up to the buccal bone. **E)** The CTG replaced the missing buccal bone creating a contained defect in which EMD can be applied. **F)** Palatal flap closure. **G)** Soft tissue healing with interproximal tissue regrowth and papilla reconstruction. **H)** X-rays showing the healing of the intrabony component at 5 years



**FIGURE 4** Novel conservative approach for the treatment of intrabony defect associated with papilla loss. **A)** Baseline clinical situation with loss of interproximal clinical attachment loss. **B)** X-rays showing horizontal bony defects with shallow intrabony components. **C)** Palatal incisions at the level of the interproximal tissues that allowed to maintain the supracrestal soft tissue within the buccal flap. **D)** Application of the amelogenin above the instrumented root surfaces. **E)** CTG application and suturing. **F)** Flap closure aiming at promoting healing by primary intention. **G)** Soft tissue healing with interproximal tissue regrowth. **H)** X-rays demonstrating the healing of the shallow intrabony components and the increased radiopacity of the bone crest 12 months

## 2 | CONCLUSIONS

Several techniques and biomaterials have shown promising results for papilla reconstruction in healthy dentitions in terms of reduction of black triangles and esthetic improvements. The combination of papilla preservation techniques with connective tissue grafts and coronal advancement of the flap can result in regeneration of the intrabony defect with simultaneous interproximal root coverage and papillae reconstruction. Nevertheless, most of the evidence available in the literature is based on case series or case reports, mainly with short-term data. Randomized clinical trials are needed to validate the efficacy of these approaches in regenerating the supracrestal attachment in healthy and diseased natural dentitions. Future directions for interproximal attachment regeneration may involve the application of tissue-engineering approaches with customizing bioresorbable scaffolds delivering growth factors or cell-based therapies via minimally-invasive techniques.

### ACKNOWLEDGMENTS

The authors do not have any financial interests, either directly or indirectly, in the products or information enclosed in the paper. The authors report no conflicts of interest related to this editorial.

### AUTHOR CONTRIBUTIONS

**G. Rasperini:** Design of the article, manuscript preparation and the initial draft, contribution with clinical cases, final review of the work; accountable for all aspects of the work. **L. Tavelli:** Design of the article, acquisition

and interpretation of data from the literature, manuscript preparation and the initial draft, final review of the work; accountable for all aspects of the work. **S. Barootchi:** Design of the article, acquisition and interpretation of data from the literature, manuscript preparation and the initial draft, final review of the work; accountable for all aspects of the work. **M.K. McGuire:** Contribution to manuscript writing, contribution with clinical cases, critical review of the final draft, accountable for all aspects of the work. **G. Zucchelli:** Contribution to manuscript writing, contribution with clinical cases, critical review of the final draft, accountable for all aspects of the work. **G. Pagni:** Design of the article, contribution to manuscript writing, critical review of the final draft, accountable for all aspects of the work. **M. Stefanini:** Contribution to manuscript writing, contribution with clinical cases, critical review of the final draft, accountable for all aspects of the work. **H-L Wang:** Critical review of the draft and contribution to the writing of the manuscript; final approval of the version to be published and accountable to the accuracy or integrity of the work. **W. V. Giannobile:** Design of the article; critical review of the draft and contribution to the writing of the manuscript; final approval of the version to be published and accountable to the accuracy or integrity of the work.

### ORCID

Giulio Rasperini  <https://orcid.org/0000-0003-3836-147X>

Lorenzo Tavelli  <https://orcid.org/0000-0003-4864-3964>

Shayan Barootchi  <https://orcid.org/0000-0002-5347-6577>

Hom-Lay Wang  <https://orcid.org/0000-0003-4238-1799>

William V. Giannobile  <https://orcid.org/0000-0002-7102-9746>



## REFERENCES

1. Pini Prato GP, Di Gianfilippo R, Wang HL. Success in periodontology: an evolutive concept. *J Clin Periodontol.* 2019;46:840-845.
2. Tonetti MS, Greenwell H, Kornman KS. Staging and grading of periodontitis: framework and proposal of a new classification and case definition. *J Periodontol.* 2018;89(Suppl 1):S159-S172.
3. Zucchelli G, De Sanctis M. A novel approach to minimizing gingival recession in the treatment of vertical bony defects. *J Periodontol.* 2008;79:567-574.
4. Rasperini G, Acunzo R, Barnett A, Pagni G. The soft tissue wall technique for the regenerative treatment of non-contained infrabony defects: a case series. *Int J Periodontics Restorative Dent.* 2013;33:e79-87.
5. Trombelli L, Simonelli A, Minenna L, Rasperini G, Farina R. Effect of a connective tissue graft in combination with a single flap approach in the regenerative treatment of intraosseous defects. *J Periodontol.* 2017;88:348-356.
6. Carnio J. Surgical reconstruction of interdental papilla using an interposed subepithelial connective tissue graft: a case report. *Int J Periodontics Restorative Dent.* 2004;24:31-37.
7. McGuire MK. Periodontal plastic surgery. *Dent Clin North Am.* 1998;42:411-465.
8. McGuire MK, Scheyer ET. A randomized, double-blind, placebo-controlled study to determine the safety and efficacy of cultured and expanded autologous fibroblast injections for the treatment of interdental papillary insufficiency associated with the papilla priming procedure. *J Periodontol.* 2007;78:4-17.
9. Chang LC. Assessment of parameters affecting the presence of the central papilla using a non-invasive radiographic method. *J Periodontol.* 2008;79:603-609.
10. Perez F, Martins Segalla JC, Ferreira PM, Pereira Lauris JR, Rabelo Ribeiro JG. Clinical and radiographic evaluation of factors influencing the presence or absence of interproximal gingival papillae. *Int J Periodontics Restorative Dent.* 2012;32:e68-74.
11. Chen MC, Liao YF, Chan CP, Ku YC, Pan WL, Tu YK. Factors influencing the presence of interproximal dental papillae between maxillary anterior teeth. *J Periodontol.* 2010;81:318-324.
12. Tarnow DP, Magner AW, Fletcher P. The effect of the distance from the contact point to the crest of bone on the presence or absence of the interproximal dental papilla. *J Periodontol.* 1992;63:995-996.
13. Nordland WP, Tarnow DP. A classification system for loss of papillary height. *J Periodontol.* 1998;69:1124-1126.
14. Chow YC, Eber RM, Tsao YP, Shotwell JL, Wang HL. Factors associated with the appearance of gingival papillae. *J Clin Periodontol.* 2010;37:719-727.
15. Billings M, Holtfreter B, Papapanou PN, Mitnik GL, Kocher T, Dye BA. Age-dependent distribution of periodontitis in two countries: findings from NHANES 2009 to 2014 and SHIP-TREND 2008 to 2012. *J Periodontol.* 2018;89(Suppl 1):S140-S158.
16. Joshi K, Baiju CS, Khashu H, Bansal S, Maheswari IB. Clinical assessment of interdental papilla competency parameters in the esthetic zone. *J Esthet Restor Dent.* 2017;29:270-275.
17. Aroca S, Barbieri A, Clementini M, Renouard F, de Sanctis M. Treatment of class III multiple gingival recessions: prognostic factors for achieving a complete root coverage. *J Clin Periodontol.* 2018;45:861-868.
18. Zucchelli G, Tavelli L, Barootchi S, Stefanini M, Wang HL, Cortellini P. Clinical remarks on the significance of tooth malposition and papillae dimension to the prediction of root coverage. *Int J Periodont Rest.* 2020.
19. Zetu L, Wang HL. Management of inter-dental/inter-implant papilla. *J Clin Periodontol.* 2005;32:831-839.
20. Feuillet D, Keller JF, Agossa K. Interproximal tunneling with a customized connective tissue graft: a microsurgical technique for interdental papilla reconstruction. *Int J Periodontics Restorative Dent.* 2018;38:833-839.
21. Geurs NC, Romanos AH, Vassilopoulos PJ, Reddy MS. Efficacy of micronized acellular dermal graft for use in interproximal papillae regeneration. *Int J Periodontics Restorative Dent.* 2012;32:49-58.
22. Awartani FA, Tatakis DN. Interdental papilla loss: treatment by hyaluronic acid gel injection: a case series. *Clin Oral Investig.* 2016;20:1775-1780.
23. Spano SJ, Ghilzon R, Lam DK, Goldberg MB, Tenenbaum HC. Subperiosteal papilla augmentation with a non-animal-derived hyaluronic acid overlay technique. *Clin Adv Periodontics.* 2020;10:4-9.
24. Arunachalam LT, Merugu S, Sudhakar U. A novel surgical procedure for papilla reconstruction using platelet rich fibrin. *Contemp Clin Dent.* 2012;3:467-470.
25. Kumari A, Yokota Y, Li L, Bradley RM, Mistretta CM. Species generalization and differences in Hedgehog pathway regulation of fungiform and circumvallate papilla taste function and somatosensation demonstrated with sonidegib. *Sci Rep.* 2018;8:16150.
26. Yamada Y, Nakamura S, Ueda M, Ito K. Papilla regeneration by injectable stem cell therapy with regenerative medicine: long-term clinical prognosis. *J Tissue Eng Regen Med.* 2015;9:305-309.
27. Zanin F, Moreira MS, Pedroni ACF, et al. Hemolasertherapy: a novel procedure for gingival papilla regeneration-case report. *Photomed Laser Surg.* 2018;36:221-226.
28. Bertl K, Gotfredsen K, Jensen SS, Bruckmann C, Stavropoulos A. Can hyaluronan injections augment deficient papillae at implant-supported crowns in the anterior maxilla? A randomized controlled clinical trial with 6 months follow-up. *Clin Oral Implants Res.* 2017;28:1054-1061.
29. Bertl K, Gotfredsen K, Jensen SS, Bruckmann C, Stavropoulos A. Adverse reaction after hyaluronan injection for minimally invasive papilla volume augmentation. A report on two cases. *Clin Oral Implants Res.* 2017;28:871-876.
30. Preus HR, Al-Lami Q, Baelum V. Oral hygiene revisited. The clinical effect of a prolonged oral hygiene phase prior to periodontal therapy in periodontitis patients. A randomized clinical study. *J Clin Periodontol.* 2020;47:36-42.
31. Tonetti MS, Eickholz P, Loos BG, et al. Principles in prevention of periodontal diseases: consensus report of group 1 of the 11th European Workshop on Periodontology on effective prevention of periodontal and peri-implant diseases. *J Clin Periodontol.* 2015;42(Suppl 16):S5-11.
32. Chambrone LA, Chambrone L. Results of a 20-year oral hygiene and prevention programme on caries and periodontal disease in children attended at a private periodontal practice. *Int J Dent Hyg.* 2011;9:155-158.
33. Roscher T, Rosing CK, Gjermo P, Aass AM. Effect of instruction and motivation in the use of electric and manual tooth-

- brushes in periodontal patients. A comparative study. *Braz Oral Res.* 2004;18:296-300.
34. Nibali L, Pometti D, Chen TT, Tu YK. Minimally invasive non-surgical approach for the treatment of periodontal intrabony defects: a retrospective analysis. *J Clin Periodontol.* 2015;42:853-859.
  35. Barbato L, Selvaggi F, Kalemaj Z, et al. Clinical efficacy of minimally invasive surgical (MIS) and non-surgical (MINST) treatments of periodontal intra-bony defect. A systematic review and network meta-analysis of RCT's. *Clin Oral Investig.* 2020;24:1125-1135.
  36. Cobb CM. Clinical significance of non-surgical periodontal therapy: an evidence-based perspective of scaling and root planing. *J Clin Periodontol.* 2002;29(Suppl 2):6-16.
  37. Claffey N, Polyzois I, Ziaka P. An overview of nonsurgical and surgical therapy. *Periodontol 2000.* 2004;36:35-44.
  38. Reynolds MA, Kao RT, Camargo PM, et al. Periodontal regeneration – intrabony defects: a consensus report from the AAP Regeneration Workshop. *J Periodontol.* 2015;86:S105-107.
  39. Kao RT, Nares S, Reynolds MA. Periodontal regeneration – intrabony defects: a systematic review from the AAP Regeneration Workshop. *J Periodontol.* 2015;86:S77-104.
  40. Cortellini P, Stalpers G, Mollo A, Tonetti MS. Periodontal regeneration versus extraction and dental implant or prosthetic replacement of teeth severely compromised by attachment loss to the apex: a randomized controlled clinical trial reporting 10-year outcomes, survival analysis and mean cumulative cost of recurrence. *J Clin Periodontol.* 2020;47(6):768-776.
  41. Nyman S, Lindhe J, Karring T, Rylander H. New attachment following surgical treatment of human periodontal disease. *J Clin Periodontol.* 1982;9:290-296.
  42. Cortellini P, Tonetti MS. Clinical concepts for regenerative therapy in intrabony defects. *Periodontol 2000.* 2015;68:282-307.
  43. Ausenda F, Rasperini G, Acunzo R, Gorbunkova A, Pagni G. New perspectives in the use of biomaterials for periodontal regeneration. *Materials (Basel).* 2019.
  44. Giannobile WV. Commentary: treatment of periodontitis: destroyed periodontal tissues can be regenerated under certain conditions. *J Periodontol.* 2014;85:1151-1154.
  45. Cortellini P, Prato GP, Tonetti MS. The modified papilla preservation technique. A new surgical approach for interproximal regenerative procedures. *J Periodontol.* 1995;66:261-266.
  46. Cortellini P, Prato GP, Tonetti MS. The simplified papilla preservation flap. A novel surgical approach for the management of soft tissues in regenerative procedures. *Int J Periodontics Restorative Dent.* 1999;19:589-599.
  47. Takei HH, Han TJ, Carranza FA Jr, Kenney EB, Lekovic V. Flap technique for periodontal bone implants. Papilla preservation technique. *J Periodontol.* 1985;56:204-210.
  48. Susin C, Wikesjo UM. Regenerative periodontal therapy: 30 years of lessons learned and unlearned. *Periodontol 2000.* 2013;62:232-242.
  49. Trombelli L, Kim CK, Zimmerman GJ, Wikesjo UM. Retrospective analysis of factors related to clinical outcome of guided tissue regeneration procedures in intrabony defects. *J Clin Periodontol.* 1997;24:366-371.
  50. Majzoub J, Barootchi S, Tavelli L, Wang CW, Travan S, Wang HL. Treatment effect of guided tissue regeneration on the horizontal and vertical components of furcation defects: a retrospective study. *J Periodontol.* 2020. <https://doi.org/10.1002/JPER.19-0529>.
  51. Cortellini P, Tonetti MS. Microsurgical approach to periodontal regeneration. Initial evaluation in a case cohort. *J Periodontol.* 2001;72:559-569.
  52. Cortellini P, Tonetti MS. A minimally invasive surgical technique with an enamel matrix derivative in the regenerative treatment of intra-bony defects: a novel approach to limit morbidity. *J Clin Periodontol.* 2007;34:87-93.
  53. Cortellini P, Tonetti MS. Improved wound stability with a modified minimally invasive surgical technique in the regenerative treatment of isolated interdental intrabony defects. *J Clin Periodontol.* 2009;36:157-163.
  54. Nevins M, Giannobile WV, McGuire MK, et al. Platelet-derived growth factor stimulates bone fill and rate of attachment level gain: results of a large multicenter randomized controlled trial. *J Periodontol.* 2005;76:2205-2215.
  55. Wachtel H, Schenk G, Bohm S, Weng D, Zuhr O, Hurzeler MB. Microsurgical access flap and enamel matrix derivative for the treatment of periodontal intrabony defects: a controlled clinical study. *J Clin Periodontol.* 2003;30:496-504.
  56. Saito A, Bizenjima T, Takeuchi T, et al. Treatment of intrabony periodontal defects using rhFGF-2 in combination with deproteinized bovine bone mineral or rhFGF-2 alone: a 6-month randomized controlled trial. *J Clin Periodontol.* 2019;46:332-341.
  57. Tavelli L, Ravidia A, Barootchi S, Chambrone L, Giannobile WV. Recombinant human platelet-derived growth factor: a systematic review of clinical findings in oral regenerative procedures. *JDR Clin Trans Res.* 2020. 2380084420921353.
  58. Cortellini P, Tonetti MS. Clinical performance of a regenerative strategy for intrabony defects: scientific evidence and clinical experience. *J Periodontol.* 2005;76:341-350.
  59. Iorio-Siciliano V, Andreuccetti G, Blasi A, Matarasso M, Sculean A, Salvi GE. Clinical outcomes following regenerative therapy of non-contained intrabony defects using a deproteinized bovine bone mineral combined with either enamel matrix derivative or collagen membrane. *J Periodontol.* 2014;85:1342-1350.
  60. Graziani F, Gennai S, Cei S, et al. Clinical performance of access flap surgery in the treatment of the intrabony defect. A systematic review and meta-analysis of randomized clinical trials. *J Clin Periodontol.* 2012;39:145-156.
  61. Cosyn J, Cleymaet R, Hanselaer L, De Bruyn H. Regenerative periodontal therapy of infrabony defects using minimally invasive surgery and a collagen-enriched bovine-derived xenograft: a 1-year prospective study on clinical and aesthetic outcome. *J Clin Periodontol.* 2012;39:979-986.
  62. Zucchelli G, Mounssif I, Marzadori M, Mazzotti C, Felice P, Stefanini M. Connective tissue graft wall technique and enamel matrix derivative for the treatment of infrabony defects: case reports. *Int J Periodontics Restorative Dent.* 2017;37:673-681.
  63. Aslan S, Buduneli N, Cortellini P. Entire papilla preservation technique in the regenerative treatment of deep intrabony defects: 1-Year results. *J Clin Periodontol.* 2017;44:926-932.
  64. Najafi B, Kheirieh P, Torabi A, Cappetta EG. Periodontal Regenerative treatment of intrabony defects in the esthetic zone using Modified Vestibular Incision Subperiosteal Tunnel Access (M-VISTA). *Int J Periodontics Restorative Dent.* 2018;38:e9-e16.
  65. Zucchelli G, De Sanctis M. Treatment of multiple recession-type defects in patients with esthetic demands. *J Periodontol.* 2000;71:1506-1514.



66. Tavelli L, Barootchi S, Nguyen TVN, Tattan M, Ravidia A, Wang HL. Efficacy of tunnel technique in the treatment of localized and multiple gingival recessions: a systematic review and meta-analysis. *J Periodontol*. 2018;89:1075-1090.
67. Zuhr O, Rebele SF, Schneider D, Jung RE, Hurzeler MB. Tunnel technique with connective tissue graft versus coronally advanced flap with enamel matrix derivative for root coverage: a RCT using 3D digital measuring methods. Part I. Clinical and patient-centred outcomes. *J Clin Periodontol*. 2014;41:582-592.
68. Aslan S, Buduneli N, Cortellini P. Entire papilla preservation technique: a novel surgical approach for regenerative treatment of deep and wide intrabony defects. *Int J Periodontics Restorative Dent*. 2017;37:227-233.
69. Aslan S, Buduneli N, Cortellini P. Clinical outcomes of the entire papilla preservation technique with and without biomaterials in the treatment of isolated intrabony defects: a randomized controlled clinical trial. *J Clin Periodontol*. 2020;47:470-478.
70. Moreno Rodriguez JA, Ortiz Ruiz AJ, Caffesse RG. Periodontal reconstructive surgery of deep intraosseous defects using an apical approach. Non-incised papillae surgical approach (NIPSA): a retrospective cohort study. *J Periodontol*. 2019;90:454-464.
71. Moreno Rodriguez JA, Ortiz Ruiz AJ, Caffesse RG. Supra-alveolar attachment gain in the treatment of combined intra-suprabony periodontal defects by non-incised papillae surgical approach. *J Clin Periodontol*. 2019;46:927-936.
72. Moreno Rodriguez JA, Ortiz Ruiz AJ, Zamora GP, Pecci-Lloret M, Caffesse RG. Connective tissue grafts with nonincised papillae surgical approach for periodontal reconstruction in noncontained defects. *Int J Periodontics Restorative Dent*. 2019;39:781-787.
73. Burkhardt R, Ruiz Magaz V, Hammerle CH, Lang NP. Research Group on Oral Soft Tissue B, Wound H. Interposition of a connective tissue graft or a collagen matrix to enhance wound stability – an experimental study in dogs. *J Clin Periodontol*. 2016;43:366-373.
74. Tavelli L, Barootchi S, Cairo F, Rasperini G, Shedden K, Wang HL. The effect of time on root coverage outcomes: a network meta-analysis. *J Dent Res*. 2019;98:1195-1203.
75. Zucchelli G, Tavelli L, McGuire MK, et al. Autogenous soft tissue grafting for periodontal and peri-implant plastic surgical reconstruction. *J Periodontol*. 2020;91:9-16.
76. Rebele SF, Zuhr O, Schneider D, Jung RE, Hurzeler MB. Tunnel technique with connective tissue graft versus coronally advanced flap with enamel matrix derivative for root coverage: a RCT using 3D digital measuring methods. Part II. Volumetric studies on healing dynamics and gingival dimensions. *J Clin Periodontol*. 2014;41:593-603.
77. Zucchelli G, Mazzotti C, Tirone F, Mele M, Bellone P, Mounssif I. The connective tissue graft wall technique and enamel matrix derivative to improve root coverage and clinical attachment levels in Miller Class IV gingival recession. *Int J Periodontics Restorative Dent*. 2014;34:601-609.
78. Tavelli L, Barootchi S, Namazi SS, et al. The influence of palatal harvesting technique on the donor site vascular injury: a split-mouth comparative cadaver study. *J Periodontol*. 2020;91:83-92.
79. Rios HF, Bashutski JD, McAllister BS, et al. Emerging regenerative approaches for periodontal reconstruction: practical applications from the aap regeneration workshop. *Clin Adv Periodontics*. 2015;5:40-46.
80. Cochran DL, Cobb CM, Bashutski JD, et al. Emerging regenerative approaches for periodontal reconstruction: a consensus report from the AAP Regeneration Workshop. *J Periodontol*. 2015;86:S153-156.
81. Yu N, Nguyen T, Cho YD, Kavanagh NM, Ghassib I, Giannobile WV. Personalized scaffolding technologies for alveolar bone regenerative medicine. *Orthod Craniofac Res*. 2019;22(Suppl 1):69-75.
82. Rasperini G, Pilipchuk SP, Flanagan CL, et al. 3D-printed bioresorbable scaffold for periodontal repair. *J Dent Res*. 2015;94:153S-157S.
83. Asa'ad F, Pagni G, Pilipchuk SP, Gianni AB, Giannobile WV, Rasperini G. 3D-printed scaffolds and biomaterials: review of alveolar bone augmentation and periodontal regeneration applications. *Int J Dent*. 2016;2016:1239842.
84. Zadeh HH. Minimally invasive treatment of maxillary anterior gingival recession defects by vestibular incision subperiosteal tunnel access and platelet-derived growth factor BB. *Int J Periodontics Restorative Dent*. 2011;31:653-660.
85. Carnio J, Carnio AT. Papilla reconstruction: interdisciplinary consideration for clinical success. *J Esthet Restor Dent*. 2018;30:484-491.
86. Kaushik A, Pk P, Jhamb K, et al. Clinical evaluation of papilla reconstruction using subepithelial connective tissue graft. *J Clin Diagn Res*. 2014;8:ZC77-81.
87. Sharma E, Sharma A, Singh K. The role of subepithelial connective tissue graft for reconstruction of interdental papilla: clinical study. *Singapore Dent J*. 2017;38:27-38.
88. Lee WP, Kim HJ, Yu SJ, Kim BO. Six month clinical evaluation of interdental papilla reconstruction with injectable hyaluronic acid gel using an image analysis system. *J Esthet Restor Dent*. 2016;28:221-230.
89. Ahila E, Saravana Kumar R, Reddy VK, Pratebha B, Jananni M, Priyadharshini V. Augmentation of interdental papilla with platelet-rich fibrin. *Contemp Clin Dent*. 2018;9:213-217.
90. Rasperini G, Ricci G, Silvestri M. Surgical technique for treatment of infrabony defects with enamel matrix derivative (Emdogain): 3 case reports. *Int J Periodontics Restorative Dent*. 1999;19:578-587.
91. Trombelli L, Farina R, Franceschetti G, Calura G. Single-flap approach with buccal access in periodontal reconstructive procedures. *J Periodontol*. 2009;80:353-360.

## SUPPORTING INFORMATION

Additional supporting information may be found online in the Supporting Information section at the end of the article.

**How to cite this article:** Rasperini G, Tavelli L, Barootchi S, et al. Interproximal attachment gain: The challenge of periodontal regeneration. *J Periodontol*. 2021;92:931-946.  
<https://doi.org/10.1002/JPER.20-0354>