

RESEARCH ARTICLE

The feasibility of ultrasound-assisted endovascular laser thrombolysis in an acute rabbit thrombosis model

Rohit Singh¹ | Janggun Jo^{2,3} | Matthew Riegel⁴ | M. Laird Forrest⁵ | Xinmai Yang¹

¹Institute for Bioengineering Research and Department of Mechanical Engineering, University of Kansas, Lawrence, Kansas, USA

²Department of Biomedical Engineering, University of Michigan, Ann Arbor, Michigan, USA

³Vesarex LLC, Lawrence, Kansas, USA

⁴Animal Care Unit, University of Kansas, Lawrence, Kansas, USA

⁵Department of Pharmaceutical Chemistry, University of Kansas, Lawrence, Kansas 66045, USA

Correspondence

Xinmai Yang, Institute for Bioengineering Research and Department of Mechanical Engineering, University of Kansas, Lawrence, Kansas, USA.
Email: xmyang@ku.edu

Funding information

NIH, Grant/Award Number: 1R43HL147783-01

Abstract

Purpose: This study aimed to test the feasibility of combined ultrasound and laser technique, namely, ultrasound-assisted endovascular laser thrombolysis (USELT), for thrombolysis by conducting in vivo tests in a rabbit thrombosis model.

Materials and methods: An acute thrombus was created in the right jugular vein of rabbit and then was treated with ultrasound only, laser only, and USELT to dissolve the blood clot. A total of 20 rabbits were used. Out of which, the first three rabbits were used to titrate the laser and ultrasound parameters. Then, five rabbits were treated with ultrasound only, five rabbits were treated with laser only, and seven rabbits were treated with USELT. During USELT, 532-nm laser pulses were delivered endovascularly directly to the clot through a fiber optic, and 0.5 MHz ultrasound pulses were applied noninvasively to the same region. A laser fluence of 4 to 12 mJ/cm² and ultrasound amplitude of 1 to 2 MPa were used. Recanalization of the jugular vein was assessed by performing ultrasound Doppler imaging immediately after the treatment. The maximum blood flow speed after the treatment as compared to its value before the treatment was used to calculate the blood flow recovery in vessel.

Results: The blood flow was fully recovered (100%) in three rabbits, partially recovered in two rabbits (more than 50% and less than 100%) with mean percentage recovery of 69.73% and poorly recovered in two rabbits (<50%) with mean percentage recovery of 6.2% in the USELT group. In contrast, the treatment group with ultrasound or laser alone did not show recanalization of vein in any case, all the five rabbits were poorly/not recovered with a mean percentage recovery of 0%.

Conclusions: The USELT technology was shown to effectively dissolve the blood clots in an acute rabbit jugular vein thrombosis model.

KEYWORDS

cavitation, endovascular laser thrombolysis, noninvasive ultrasound thrombolysis, rabbit thrombosis model

Rohit Singh and Janggun Jo authors contributed equally to the study

© 2021 American Association of Physicists in Medicine

1 | INTRODUCTION

Venous thromboembolism (VTE), a condition in which a blood clot (a thrombus) forms in a vein, is a major disease affecting more than 10 million people worldwide each year.¹ VTE can lead to a myriad of complications, including swelling, erythema, neurovascular compromise, tissue necrosis or limb loss, acute respiratory symptoms, pulmonary hypertension, cardiovascular collapse, thromboembolism, and death. A venous thrombus most commonly occurs in the deep veins of the legs or pelvis; this is then called a deep vein thrombosis (DVT). A pulmonary embolism (PE) occurs when a clot breaks loose and travels through the bloodstream to the lungs. PE is an acute life-threatening complication, causing as many as 100,000 deaths annually in the United States. Post-thrombotic syndrome, develops in 30–75% of patients with DVT, which is a costly chronic condition often causing lengthy disability.^{2–4} Overall, the annual medical costs are \$7 to \$10 billion for VTE in the United States. Worldwide, the total cost can be as high as \$69 billion annually.⁵

Thrombosis is both an expensive and complicated condition to address. Treatment requires dissolving the blood clots in the blood vessels, referred to as thrombolysis. The treatment approaches are diverse. First-line therapy is to give patients direct oral anticoagulants.^{6,7} This medication prevents the formation of clotting factors. However, anticoagulant medications are not efficient because they do not dissolve the clot and recanalize vessels.⁸ Another approach is thrombolytic therapy, which is undertaken by injecting a clot-dissolving medication. The limitations of the treatment include the need for hospitalization due to risks of bleeding and low effectiveness for totally occluded veins.⁹

Ultrasound-based treatment techniques have been evaluated as methods to induce effective thrombolysis.^{10–16} The advantage of ultrasound-based techniques is that they can dissolve blood clots quickly and recanalize vessels noninvasively through cavitation. But, these techniques require high acoustic peak negative pressure (as high as 19 MPa¹⁷) at relatively low ultrasound frequencies of 500 kHz or 1 MHz. In order to achieve high pressure and deliver treatment to a blood clot, focused ultrasound must be employed. However, at low ultrasound frequencies such as 0.5 MHz, the focal spot of the ultrasound field is usually larger than 10 mm in length, which is larger than the diameters of most veins. As a result, damages can be induced in the surrounding tissue and vessel walls.¹⁷ This could be especially problematic in areas with delicate structures that have limited surgical options, such as retina vein occlusions, renal vein thrombus, and stroke. Although the size of the focal zone could be reduced by using transducers with small f-numbers, this has a trade-off with the reduced treatment depth, and also is limited by the available

acoustic window.¹⁸ Alternatively, high-intensity focused ultrasound (HIFU) with higher frequency may be used to produce a smaller focal size, but it will reduce the efficiency of thrombolysis because it is generally more difficult to produce cavitation at a higher frequency.¹⁹ To increase the efficiency and safety of ultrasound-based thrombolysis, microbubbles can be used²⁰; however, requires an additional systemic injection of the microbubbles and may cause unwanted vascular and tissue damages at high dosages^{21–23}

Laser thrombolysis is an interventional procedure to recanalize occluded vessels.^{24–29} Laser thrombolysis utilizes a light wavelength that is highly absorptive to the blood clots. Laser light generally is directed to the blood clot through a thin laser fiber, which induces heating of the clot, and cavitation can occur in the blood clot through vaporization. Then, similar to ultrasound thrombolysis, the expansion and collapse of a vapor cavity can also break up the blood clot. The advantages of laser thrombolysis include low cost, a shorten recovery time, and generally high safety. Laser thrombolysis can precisely induce cavitation in blood clots due to the high optical absorption of blood clots at certain wavelength (like 308 nm,²⁶ 480 nm,²⁹ and 577 nm²⁸) compared to the surrounding tissue and structures. However, the produced cavitation expansion and collapse cannot be controlled and often are not strong enough to efficiently break up the clot. As a result, laser thrombolysis often cannot completely clear thrombotic occlusions in the blood vessels, typically leaving residual thrombus on the blood vessel walls.²⁸ Its efficiency is also questionable in removing blood clots with high calcium contents.

We have developed a novel hybrid technology, based on the combination of light and ultrasound, namely ultrasound-assisted endovascular laser thrombolysis (USELT), to safely and efficiently dissolve the blood clots in the vein. The USELT system is based on our earlier developed photo-mediated ultrasound therapy (PUT) technology.^{30–33} Both technologies use combination of ultrasound and laser to generate enhanced cavitation. In PUT, both laser and ultrasound are applied noninvasively,^{34–39} whereas in USELT the laser is delivered directly to the clot using an endovascular laser catheter. Due to noninvasive laser in PUT, only certain wavelength with good transparency in the intervening tissues can be used. Whereas in USELT, any laser wavelength that maximize absorptive heating of the blood clot can be used. In USELT, the laser is applied through catheter and noninvasive ultrasound energy is applied from outside the body to the blood clot to drive the generated cavitation bubbles and achieve the best thrombolysis outcomes. As a result, the advantages of laser and ultrasound treatment can be combined, and blood clots can be dissolved rapidly. In a previous study,⁴⁰ we initially characterized the feasibility of the USELT system with an in vitro blood flow

system, and demonstrated the efficiency of thrombolysis as a function of ultrasound pressures and laser fluences. In the current study, we tested the feasibility of the USELT system in an acute in vivo rabbit thrombosis model. The translation potential of USELT is demonstrated, although further development will be needed to optimize the treatment before clinical use.

2 | MATERIALS AND METHODS

2.1 | Experimental setup

A detailed schematic of the USELT system is shown in Figure 1. This system is a combination of an endovascular laser thrombolysis system and a high-intensity focused ultrasound system. The laser system uses a Q-switched diode pumped solid-state laser (Elforlight Model SPOT-10-200-532, Bozeman, MT) to produce 532-nm wavelength light. The laser pulse duration and energy was 2-ns and 0–20 uJ, respectively. The laser light was delivered to the desired treatment region using an optical fiber and fiber optic cannula. The produced laser light was first passed to a long optical fiber to carry it near to the vein. Near the vein, the optical fiber was connected to a fiber optic cannula of 400 μm (CFMLC14 U-20, Thorlabs, Newton, NJ) to produce a laser fluence of 4 to 12 mJ/cm^2 . The laser

power was adjusted to the desired level using an optical power meter (S425C, Thorlabs, Newton, NJ) before each treatment. The laser system was triggered by a delay/pulse generator (DG535, Stanford Research Systems, Sunnyvale, CA, USA) to give a pulse repetition frequency of 10 kHz. The same delay/pulse generator was used to trigger ultrasound with a fixed delay in the ultrasound pulse. The delay was set such as to provide desired synchronization between two systems such that the concurrent laser and ultrasound pulses were applied on the treatment region.

For the ultrasound system, the delay/pulse generator triggered a function generator (33250A, Agilent Technologies, Santa Clara, CA) to produce a 0.5 MHz signal. The signal was first amplified by 50 dB in RF amplifier (2100L, ENI, Rochester, NY) and then passed to a matching network (Impedance Matching Network H-107, Sonic Concepts) before being sent to the transducer. The high-intensity focused ultrasound transducer (H-107, Sonic Concepts, Bothell, WA) has a central frequency of 0.5 MHz with focal distance, focal depth, and focal width of 63.2, 21.42, and 3.02 mm, respectively. The front face of the transducer was placed inside a conical plastic cone such that its focal point was present near the small opening on the vertex of the cone. The focal peak negative pressure on the cone vertex opening was measured using a standard needle hydrophone (SN-1462, 0.5 mm, Precision Acoustics

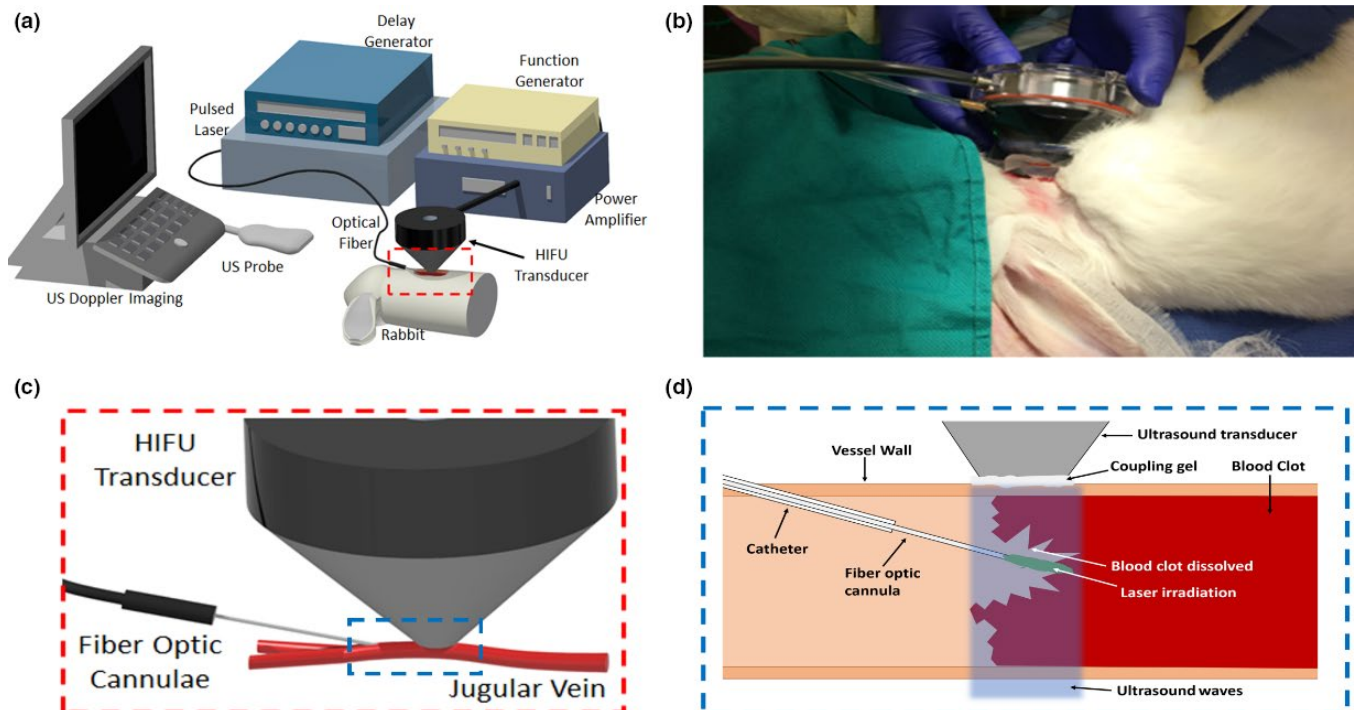


FIGURE 1 (a) Detailed schematic of the integrated endovascular laser thrombolysis system with high-intensity focused ultrasound system for the treatment. (b) Photograph of the rabbit's jugular vein being treated. (c) Schematic of the rabbit vein irradiation with laser (fiber optic cannula) and ultrasound (HIFU transducer), which is the boxed region in (a). (d) Detailed schematic of the combined ultrasound and laser irradiation inside rabbit vein resulting in blood clot dissolution, which is boxed region in (c)

Ltd, UK). For each trigger, the function generator generated a 5-cycle ultrasound pulse, resulting in a 10% duty cycle for an ultrasound burst.

2.2 | Animal model

All the animal handling procedures were carried out in compliance with a protocol approved by the institutional animal care and use committee (IACUC) at the University of Kansas, protocol numbers AUS 188–11, PI Xinmai Yang, with strict adherence to the National Institutes of Health guidelines. Specifically, a thrombus was induced in the right jugular vein of a New Zealand rabbit (male or female, weight ranging from 2.2 to 2.8 kg). To induce the thrombus, a rabbit was first anesthetized with a mixture of ketamine (40 mg/kg) and xylazine (5 mg/kg). Once the rabbit was sufficiently anesthetized, the hair near the neck region was shaved with an electric clipper. The rabbit was then shifted to the isoflurane anesthesia, and respiratory rate, blood oxygenation and heart rate were monitored. After the condition of the rabbit became stable, it was moved to the surgical room before inducing the blood clot. The right jugular vein was exposed and isolated from nearby tissues by making an opening in the shaved neck region. In the isolated jugular vein, blood flow was confirmed by ultrasound Doppler imaging. Then two vascular clips were placed on the jugular vein approximately 1 cm apart to create a segment of blood vessel without flow. After restricting the blood flow, 0.02 ml of blood was drawn from the clipped area and was mixed with 0.02 ml of thrombin solution. The thrombin solution was made by dissolving 1000 units of thrombin (EMD Millipore Sigma, 605157-1KU) in 0.5 ml of bacteriostatic water. Within few minutes, 0.03 ± 0.005 ml of this mixture of thrombin solution and blood was injected back to the restricted vein section. The upstream clip was removed 15 min after the thrombin administration and the other clip was removed after an additional 5 min. The blood clot was allowed to further mature over the

next 30 min, and then ultrasound Doppler imaging was repeated to measure the blood flow and confirm the blood clot formation. Figure 2 shows a picture of the region where the clot was created, and a Doppler image of blood flow.

2.3 | Treatment procedure

After the successful creation of a blood clot in the right jugular vein, the USELT system shown in Figure 1 was used to recanalize the jugular vein. A 22G catheter was inserted into the vein from an upstream location to the blood clot region and the laser optic cannula was further passed through the catheter, such that its tip reached the blood clot inside the vein. The cone containing transducer was placed directly on the vein surface such that its focal zone covered the entire vein cross-section. Ultrasound gel was used for providing coupling between the cone tip and tissue. The cannula tip placed inside vein was directly under the transducer focal zone. For treatment, the ultrasound cone and cannula were placed at one position for 1 min and then were moved to the next position. The entire blood clot was treated for 3.5 to 4.5 min depending upon the length of the blood clot (5–7 mm). The image of the treatment has been shown in Figure 1b. After completing the treatment, ultrasound Doppler imaging was performed at an upstream location to observe the blood flow and confirm recanalization of the vessel. During the entire procedure, the respiratory rate and heart rate of rabbit were noted after every 15 min to ensure the normal physiological functioning. The laser catheter was then removed, and rabbit was observed for over 30 min for any unusual changes to respiratory rate and heart rate due to treatment. The rabbit was then euthanized by intravenously injecting pentobarbital, and the treated jugular vein was collected. Histology on the collected veins was performed with hematoxylin and eosin (H&E) stain to assess the vessel for damage and to observe the amount of blood clot dissolved.

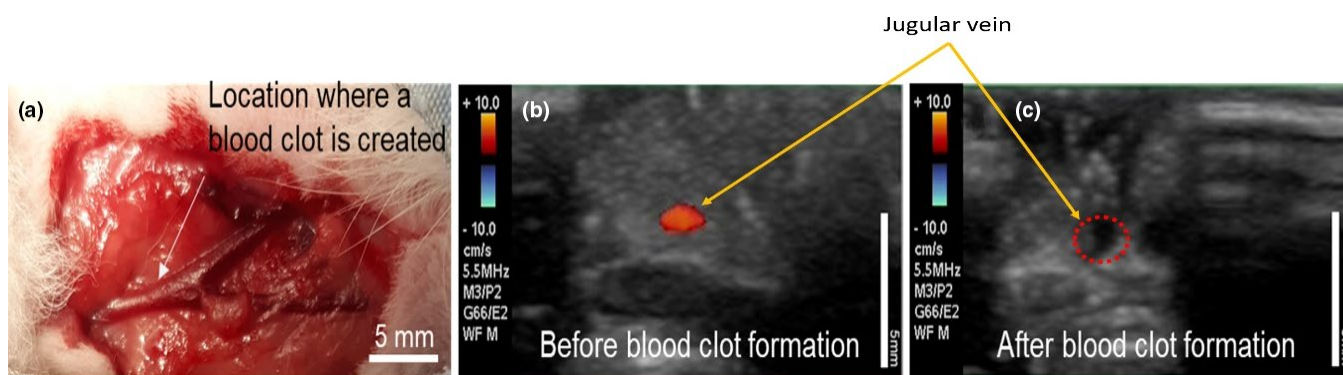


FIGURE 2 (a) Location of the blood clot in the isolated rabbit's right jugular vein. (b) Ultrasound Doppler imaging before formation of blood clot in jugular vein. (c) Ultrasound Doppler imaging after formation of blood clot in jugular vein

For the control groups, the exact same procedure was performed, but only therapeutic ultrasound energy was applied for the ultrasound-only group, and only laser energy was applied for the laser-only group.

The blood flow in the vein was observed using the Doppler mode of an ultrasound imaging unit (Z. One PRO, Mindray, Mahwah, NJ, USA) connected to a linear probe (L14-5W, Mindray). It was used with a pulse repetition frequency of 1500 Hz and a continuous Doppler frequency of 5.5 MHz. The ultrasound Doppler imaging was performed three times during the experiment. It was performed first time to confirm the blood flow in jugular vein right after it was exposed. The ultrasound Doppler imaging was done second time after the clot formation in vein. A final ultrasound Doppler imaging was performed on vein after the completion of the treatment to observe if blood flow was resumed or not.

2.4 | Treatment and control groups

The study included 20 rabbits with body weights ranging from 2.2 to 2.8 kg. The first rabbit was used to test the experimental procedure and was not included in the results data. The second and third rabbits were used to titrate the applied ultrasound pressure and laser fluence, wherein one rabbit was treated with a peak negative ultrasound pressure (P-) of 1 MPa and laser fluence of 12 mJ/cm² and the other was treated with a P- of 2 MPa and laser fluence of 4 mJ/cm² (Table S1). The remaining 17 rabbits were divided into three treatment groups (Table 1). In the first group, the rabbits were treated with USELT using a P- of 1.3 MPa and laser fluence of 8 mJ/cm², respectively. In the second group, the rabbits were treated with only ultrasound using a P- of 1.3 or 2 MPa. In the third group, the rabbits were treated with only laser using a laser fluence of 8 mJ/cm². Seven, five, and five rabbits were treated in each group, respectively. The earlier studies have also used ultrasound only and laser only for thrombolysis, but a very high peak negative ultrasound pressure

(as high as 19 MPa¹⁷) and very high laser fluence (as high as 4500 mJ/cm²,²⁶) was used. The laser assisted thrombolysis^{26,29} has been used in clinics but ultrasound thrombolysis is not yet used in clinics.

3 | RESULTS

Based on the maximum blood flow speed in the rabbit's vein before the clot formation and after the treatment, the outcomes were divided into three categories. In the first category, the rabbit's vein which has 100% maximum blood flow speed after treatment as compared to its value before clot formation were considered as full recovery. Similarly, in the second and third category, the rabbit's vein with maximum blood flow speed recovery in range of 50–99% and less than 50% are considered as partial recovery and poor/no recovery, respectively. Figure 3 shows the total number of rabbits with full recovery, partial recovery, and poor/no recovery in the maximum blood flow speed in the jugular vein after treatment with USELT (group I), ultrasound-only (group II), and laser-only (group III). The ultrasound-only and laser-only control groups were included because thrombolysis may be achieved by ultrasound only or by laser only. However, due to the low energy levels used during the USELT, ultrasound-only and laser-only control groups did not show recanalization. Figure 4 shows the mean percentage recovery for the full recovery, partial recovery, and poor/no recovery veins within each treatment group.

In group I treated with USELT, out of the seven treated rabbits, three rabbits (rabbit No. 4, 8, and 11) were fully recovered, two (rabbit No. 9 and 12) were partially recovered, and other two (rabbit No. 7 and 10) were poorly recovered. Whereas, in group II and group III, none of the five rabbits were fully or partially recovered. All the veins in group II and group III have a mean percentage recovery of 0 (no recovery) as shown in Figure 4, which means no recovery took place with ultrasound-only and laser-only treatment. Whereas, in group I, the poorly recovered vein has a

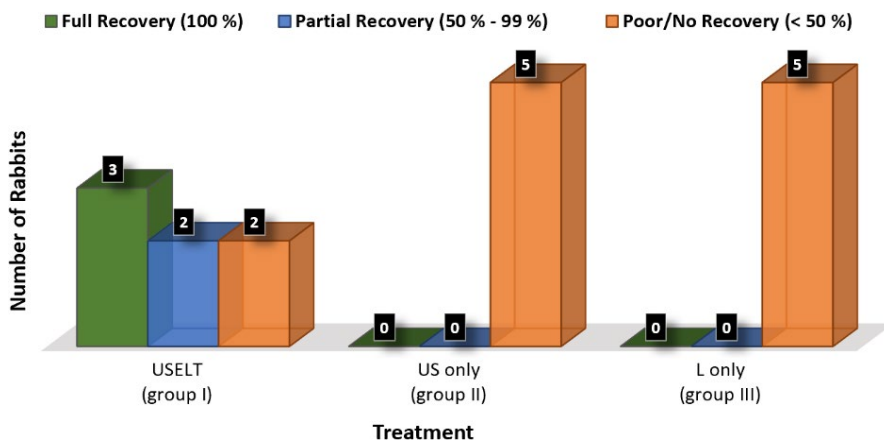


FIGURE 3 Total number of rabbits for full recovery, partial recovery and poorly/no recovery within each treatment group. Number placed above the column bar shows the total number of rabbits. This figure includes data from all the three groups (I, II, and III). L, laser; US, ultrasound; USELT, ultrasound-assisted endovascular laser thrombolysis

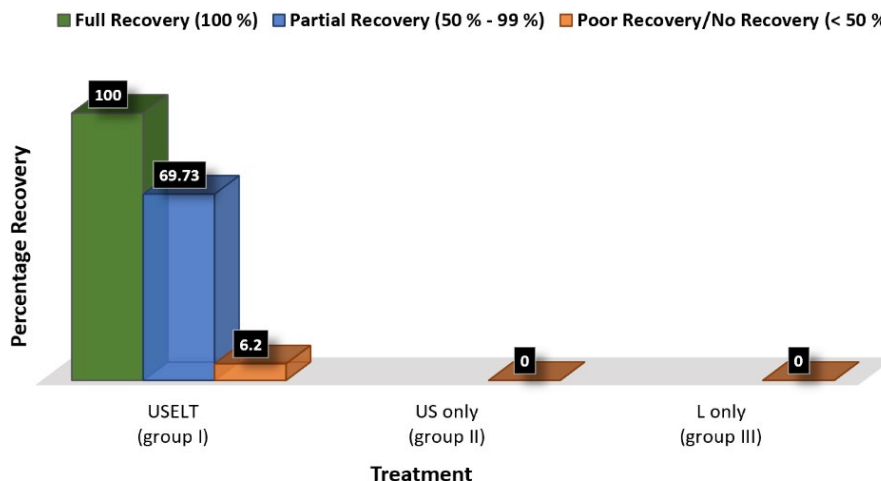


FIGURE 4 Percentage of the maximum blood flow speed recovered in full recovery, partial recovery, and poor/no recovery groups that were shown in Figure 3 within each treatment group. Number placed above the column bar shows the mean blood flow recovery after the treatment. This figure includes data from all the three groups (I, II, and III). L, laser; US, ultrasound; USELT, ultrasound-assisted endovascular laser thrombolysis

TABLE 1 Treatment data of entire experiment containing seventeen rabbits using different ultrasound and laser parameters. Rabbit 1,2 and 3 are not included in the data

Group	No. of rabbits	Rabbit number	Peak negative ultrasound pressure (MPa)	Laser fluence (mJ/cm ²)
I	7	4, 7, 8, 9, 10, 11, 12	1.3	8
II	5	5, 17, 19, 13, 14	1.3 or 2	0
III	5	6, 15, 16, 18, 20	0	8

mean percentage recovery of 6.2%. Also, in group I, the mean percentage recovery was 100% and 69.73% in full recovery and partial recovery group.

A Fisher's exact test was performed using a two-by-two contingency table to observe the association between the treatment (USELT, ultrasound-only/laser-only) and the result of the treatment (vein recovered or not). All the full and partial recovery veins were consolidated into the recovery group and poor/no recovery veins were placed in no recovery group. Accordingly, in group I, five veins were considered as recovery and two as no recovery, while in group II and III, all five veins were considered as no recovery. A p-value of 0.0278 was obtained, which shows the statically significance between the treatments and its result. A relative risk of 0.2857 for treatment failure was obtained, which means USELT has a failure chance of only 28.57% as compared to ultrasound-only or laser-only treatment (100% failure).

Figure 5 shows the ultrasound Doppler imaging of three rabbit's jugular veins treated with USELT, ultrasound only, and laser only. The ultrasound Doppler imaging of the right jugular vein of rabbit No. 8 treated with USELT is shown in Figure 5a-c. Blood flow is normal immediately after isolating the vein (Figure 5a), but no flow was observed due to total occlusion of vein after injecting thrombin (Figure 5b). Figure 5c shows the ultrasound Doppler imaging of the same jugular vein after the blood

clot was treated with USELT using P- of 1.3 MPa and laser fluence of 8 mJ/cm². The red dot in Figure 5c, at a depth of around 4–5 mm from the scanner surface, is at the same location as in Figure 5a, confirming resumption of blood flow in the vein. Similarly, Figure 5d-f show the ultrasound Doppler imaging of rabbit No. 5 treated with ultrasound only using a P- of 1.3 MPa and Figure 5g-i show rabbit No. 6 treated with laser only using a laser fluence of 8 mJ/cm². Of note, blood flow recovered completely in the USELT-treated vein, Figure 5c, but there was no recovery of blood flow in the ultrasound-only or laser-only treated veins, Figure 5f,i, respectively, indicating the monotherapies were unable to dissolve the clots.

Figure 6 shows the maximum blood flow velocity in the jugular vein of rabbits (Group I, II, and III) obtained using ultrasound Doppler imaging before and after the formation of a blood clot, and after the treatment (USELT, ultrasound-only, and laser-only). Before formation of a blood clot, normal blood flow was observed in all the 17 rabbit's veins with a mean maximum blood flow velocity of 2.85 cm/s (standard deviation of 1.2 cm/s). In all cases, thrombin treatment successfully formed a clot that completely occluded the vein and stopped blood flow. In group I, which was treated with USELT using a P- of 1.3 MPa and laser fluence of 8 mJ/cm², the mean maximum blood flow velocity from all seven rabbits was 2.26 cm/s with a standard deviation of 1.72 cm/s. In group

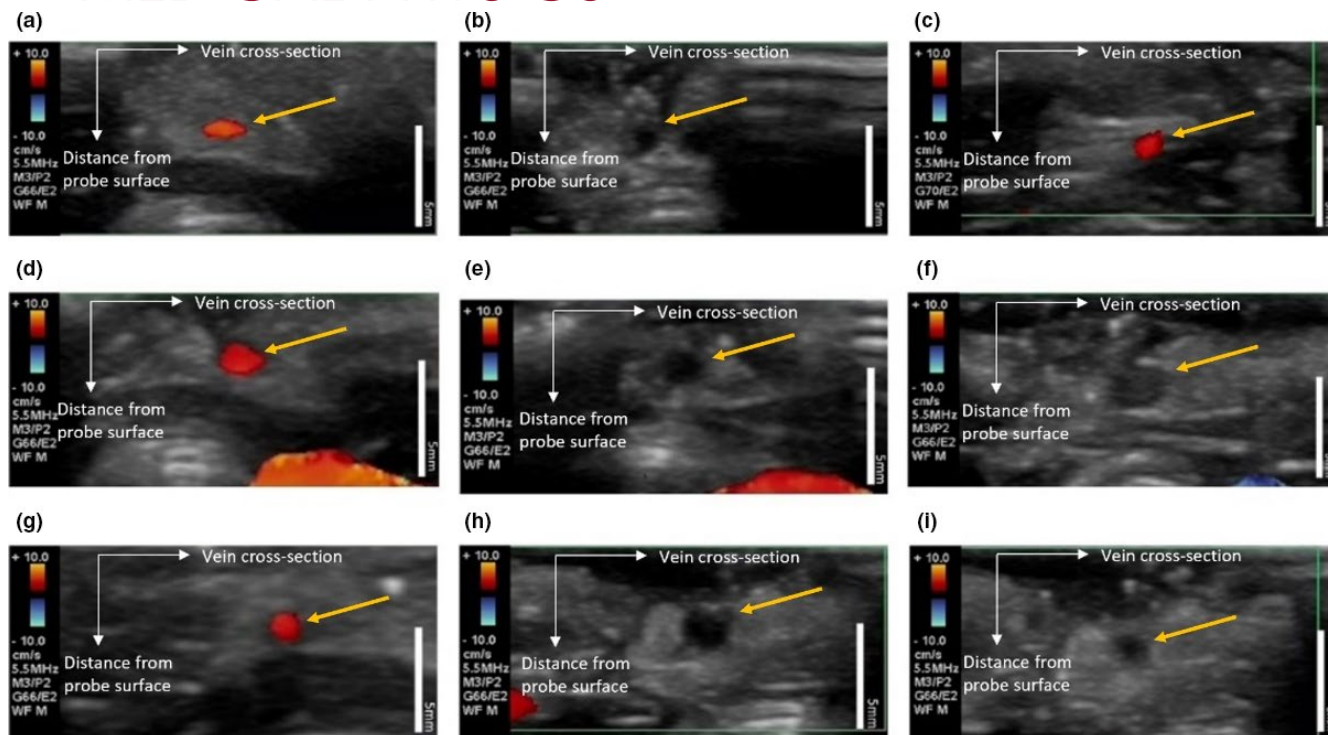


FIGURE 5 Ultrasound Doppler imaging of the treated jugular vein, jugular vein is marked by arrow. (a), (b), (c) are from rabbit No. 8, which was treated by USELT. (d), (e), (f) are from rabbit No. 5, which was treated by ultrasound only, and (g), (h), (i) are from rabbit No. 6, which was treated by laser only. (a), (d), (g) Ultrasound Doppler imaging before formation of blood clot in jugular vein. (b), (e), (h) Ultrasound Doppler imaging after formation of blood clot. (c) Ultrasound Doppler imaging after treatment with USELT using P- of 1.3 MPa and laser fluence of 8 mJ/cm². (f) Ultrasound Doppler imaging after treatment with ultrasound only using P- of 1.3 MPa. (i) Ultrasound Doppler imaging after treatment with laser only using laser fluence of 8 mJ/cm². P- = peak negative ultrasound pressure. Scale bar = 5mm

II, there was no restoration of blood flow (0 cm/s) in the five rabbits treated with ultrasound only using a P- of 1.3 or 2 MPa. Likewise, treatment with the laser only using a laser fluence of 8 mJ/cm² failed to restore blood flow (0 cm/s) in any of the five rabbits in group III. The maximum blood flow velocity after treatment between group I (USELT) and group II/III (ultrasound-only/laser-only) was statistically significant ($p = 0.028$), and before treatment and after treatment with USELT was not statistically significant ($p = 0.33$). Also, the maximum blood flow velocity, before blood clot formation and after blood clot formation was statistically significant ($p < 0.001$), after blood clot formation and after treatment with USELT was statistically significant ($p < 0.001$).

Figure 7 shows the sections of a treated rabbit vein, stained with hematoxylin and eosin (H&E). Figure 7a is an H&E stained vessel cross-section from a rabbit which was treated with ultrasound only using P- of 1.3 MPa. The entire blood clot is intact and clearly visible in Figure 7a. Figure 7b-e shows different H&E stained vessel cross-sections of a partially recovered vein that was treated with USELT using a P- of 1 MPa and laser fluence of 12 mJ/cm². A large part of the clot is dissolved due to USELT treatment in the sections shown in Figure 7b-e, image processing was also done on the sections shown in Figure 7b-d using MATLAB

2019a. It was found that around 58%, 49%, and 54% of the clot area was dissolved in the sections shown in Figure 7b-d, respectively, with the treatment of combined ultrasound and laser. In this calculation, the entire vessel lumen area in the imaging was used as the initial blood clot size because there was no blood flow after the blood clot formation. The vessel wall adjacent to the dissolved clot area can be seen intact in all the sections in Figure 7b-e. Figure 7e is magnified image of the vessel wall highlighted in Figure 7c. Some residues of the blood clot can be seen adjacent to the vessel wall; however, there is no visible damage to the vessel wall after treatment. Moreover, no major changes in heart rate (HR) and respiratory rate (RR) were observed during and after the treatment indicating the normal physiological functioning of rabbit. The HR and RR data for each rabbit in group I, which was treated with USELT, are attached as Figures S1 and S2 in supplementary materials. The blood oxygenation remained 98% or above throughout the experiment for all rabbits.

4 | DISCUSSION

The USELT device combines the advantages of both ultrasound-based and laser-based thrombolysis. The

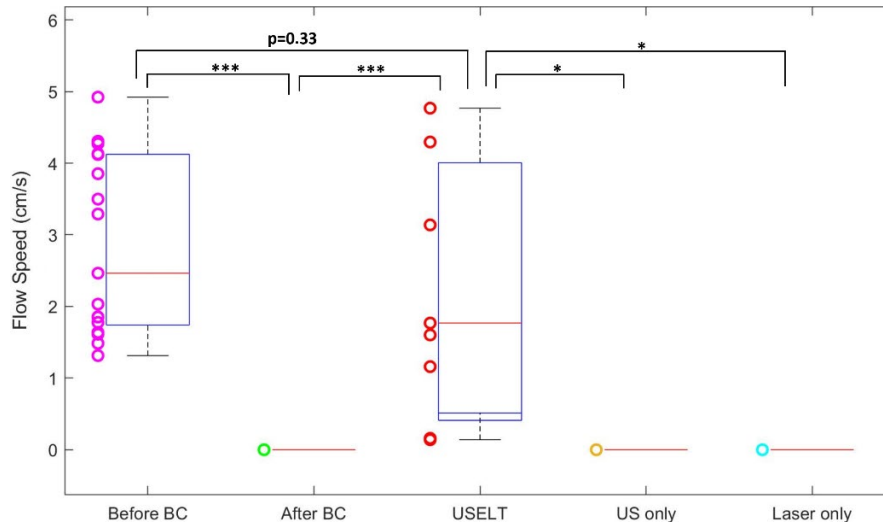
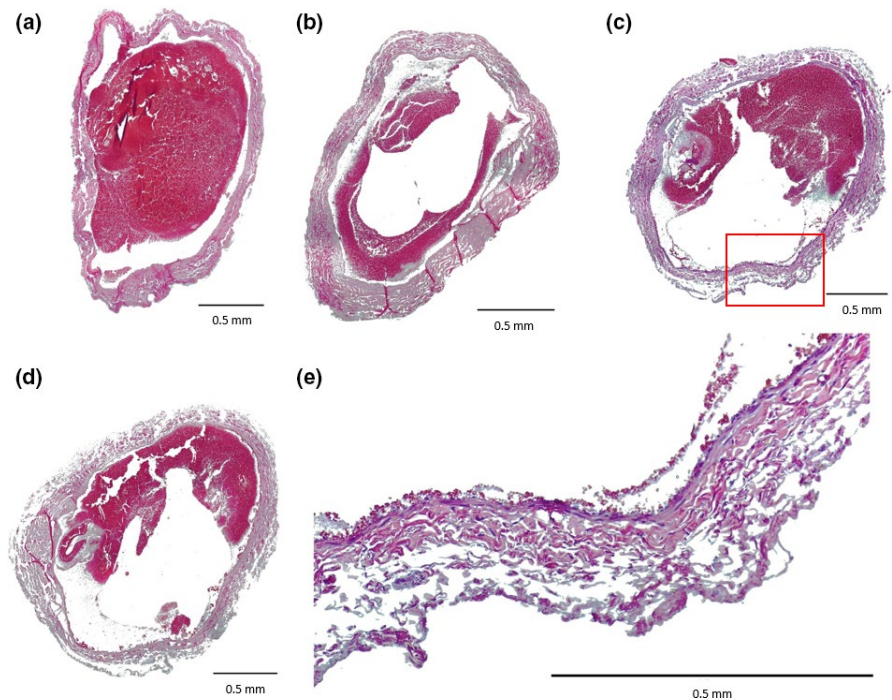


FIGURE 6 Maximum blood flow speed in rabbit jugular vein measured with ultrasound Doppler imaging before blood clot formation, after blood clot formation, after treatment with USELT using P- of 1.3 MPa and laser fluence of 8 mJ/cm², after treatment with ultrasound only using P- of 1.3 or 2 MPa and after treatment with laser only using laser fluence of 8 mJ/cm². Maximum blood flow speed before BC and after BC was significant ($p < 0.001$); After BC and USELT was significant ($p < 0.001$); USELT and US only was significant ($p < 0.05$); USELT and laser only was significant ($p < 0.05$); USELT and before BC was not significant ($p < 0.33$). BC, blood clot; P-, peak negative ultrasound pressure; US, ultrasound

FIGURE 7 (a) Histology image (hematoxylin and eosin stain) of vein section treated with ultrasound only using P- of 1.3 MPa. (b), (c), (d) Histology images (hematoxylin and eosin stain) of vein sections treated with USELT using P- of 1 MPa and laser fluence of 12 mJ/cm². (e) Magnified image of the highlighted area in the red box in (c). P-, peak negative ultrasound pressure



first potential advantage is that USELT can dissolve blood clots based on optical absorption at low ultrasound and laser energy levels. By taking advantage of the high intrinsic contrast in optical absorption between blood clots and other tissues, the treatment effect is limited to blood clots, and unwanted damage to the surrounding tissues can be minimized (shown in Figure 7). The blood vessel wall, which has a significantly lower

optical absorption than the blood clot at the laser's wavelength, is unlikely to be harmed during USELT treatment. Note that USELT is based on the synergistic effect between the light pulse and the ultrasound burst. Strong cavitation will only be induced at the location where laser and ultrasound energy overlap and are properly synchronized.³⁰ Due to the low applied ultrasound energy intensity, ultrasound alone is not capable

of producing cavitation on the vessel wall and surrounding tissues (shown in Figure 3, ultrasound only; Figure 4, ultrasound only; Figure 5d-f; Figure 6, ultrasound only; Figure 7a). On the other hand, due to the high optical absorption and scattering of blood, laser energy cannot effectively penetrate the entire blood clots to damage the vessel wall or surrounding tissues when the catheter is properly placed. As a result, the induced cavitation will be limited to the blood clots. It gives USELT the potential to be highly selective, precise, and safe. The USELT is based on our earlier developed PUT technology. The high selectivity, precision, and safety of PUT technology have been demonstrated in our previous studies.³⁰⁻³³ Our current *in vivo* study demonstrated that USELT utilizing laser pulses with a fluence of 8 mJ/cm² at 532-nm wavelength and ultrasound bursts with a peak negative pressure of 1.3 MPa at 0.5 MHz were effective for thrombolysis (shown in Figures 3, 5 and 6). The 8 mJ/cm² fluence is extremely low compared to the laser fluence used in traditional laser therapy which generally requires laser fluence greater than 1 J/cm².⁴¹ The 1.3-MPa ultrasound at 0.5 MHz is also far below the cavitation threshold (~4 MPa) reported in the literature,⁴² and results in a mechanical index of 1.8, which is below the FDA safety limit of 1.9 for ultrasound imaging.

The second potential advantage is that USELT dissolves blood clots through the mechanical effect of cavitation with minimal temperature rise. The cavitation in USELT is from the pulsed laser-induced photoacoustic (PA) effect.^{33,43-45} We have selected short duration ultrasound pulses (5 cycles) and laser pulses (2-ns) to minimize temperature increase and maximize the mechanical effect of cavitation. Unlike thermal-based therapy, which can produce damage in surrounding tissue due to thermal diffusion, the mechanical effect of cavitation is precisely localized. Only the tissues next to the produced cavitation are affected, while no surrounding tissue is damaged (shown in Figure 7).⁴⁶⁻⁵⁰

The third potential advantage is that USELT is highly efficient by combining the advantages of ultrasound and laser thrombolysis techniques. Laser thrombolysis can easily induce cavitation but the collapse of cavitation is not sufficiently strong because of the lack of driving force, whereas ultrasound can induce strong collapse of cavitation but requires strong power to initiate cavitation. Combination of laser and ultrasound can easily produce cavitation in the blood clot and the collapse of cavitation will be driven by ultrasound to achieve highly efficient thrombolysis.

Technically, USELT also dissolves a blood clot through mechanical force. The mechanical force is produced by the induced micro- or nanosize bubbles in the blood clot. A big advantage of USELT is that the produced mechanical force is not necessary to be exerted on the blood vessel wall. Hence the damage to the blood vessel wall is minimized. Many traditional mechanical thrombectomy devices generally exert a force

on the inside of the blood vessel wall to “scrape” a blood clot off. The inside surface of a vein has venous valves to prevent the backflow of blood. Scaping off a blood clot inside a vein always has the potential to damage the venous valvular function. With USELT, the mechanical force produced by cavitation is based on optical absorption of the blood clot. One can always select an optical wavelength that is highly absorbed by the blood clot, but less absorbed by the venous valve and vessel wall during USELT to minimize the unwanted damage.

A serious limitation of noninvasive PUT was that laser wavelengths were limited to those with adequate transparency in the tissues between the emitter and the clot, and due to high scattering and non-targeted absorbance, treatments were limited to tissue depths of a few millimeters. USELT retains the advantages of endovascular laser thrombolysis. During USELT, laser light can be delivered to the blood clot using an optical fiber as the same matter for endovascular laser therapy, while ultrasound can be applied noninvasively. One major advantage of endovascular laser thrombolysis is that the size of a laser fiber can be very small, for example, 100 μm in diameter (as shown in Figure 1c,d). This small size provides great flexibility for endovascular laser therapy and allows it to be used to recanalize small blood vessels, a huge advantage when it is used to dissolve blood clots during stroke therapy. On the other hand, if needed, multiple laser fibers can be bundled together to treat blood clots in large size vessels. Since laser energy is delivered via the laser fiber and not by transmission through intervening tissues, USELT treatment sites are limited only by endovascular catheter access.

Although the initial outcome is promising, the USELT technology needs further improvement. One important next step is to incorporate an imaging technique with USELT for image-guided intervention. Our current study showed blood clot residuals in blood vessels. The reason for these residuals is more likely because the blood clot was not treated completely during USELT. An imaging technique that can precisely locate blood clot and assess the size of blood clot residuals after USELT could significantly improve the effectiveness of USELT. Potential imaging modalities for guiding USELT include ultrasound imaging and photoacoustic imaging, two imaging modalities that are complementary to each other and can potentially share same equipment with USELT.³⁴

In addition, as a key step toward future commercialization success, detailed efficacy and safety studies should be performed beyond the current feasibility study. Particularly, vessel injury, persisting thrombotic attachments to the wall and possible complications need to be further investigated. We believe a large animal model such as a porcine model will be better suitable for such future study given its similar size to human. Upon the completion of safety and efficacy

studies, comparisons can be made between USELT and established thrombectomy devices such as AngioJet to demonstrate the pros and cons of USELT's potential in the clinics.

In summary, the combination of different but complementary therapeutic techniques represents a major trend in recent biomedical research. The combined treatment is likely to overcome the limitations associated with individual techniques and, therefore, has a better chance to achieve improved treatment outcomes. The current study is the first attempt to combine laser and ultrasound for removing blood clots in vivo. It is an excellent example of combined therapy, considering that the two energy types are different but complementary in the cavitation mechanism. By synergistically combining laser and ultrasound, optimized ablation with reduced side effects becomes possible, shedding new light on clinical management of DVT and stroke.

5 | CONCLUSION

This current study demonstrated that USELT was effective in treating thrombolysis, whereas the low-fluence laser alone or low-pressure ultrasound alone was not able to dissolve blood clots in an in vivo rabbit model. Hence the feasibility of the USELT technology was demonstrated. In short, USELT have the potential to treat the DVT with high efficiency and with minimal effect on nearby tissues. In future, image-guided USELT should be developed to further improve the efficiency and facilitate clinical translation for thrombolysis.

ACKNOWLEDGMENTS

The authors are extremely grateful to Dr. Eduardo Rosa-Molinar at Microscopy and Analytical Imaging, University of Kansas for sectioning vein tissue. This study is supported in part by NIH 1R43HL147783-01.

CONFLICT OF INTEREST

The authors have no conflict of statement to disclose.

DATA AVAILABILITY STATEMENT

The data that support the findings of this study are available from the corresponding author upon reasonable request.

REFERENCES

- Jha AK, Larizgoitia I, Audera-Lopez C, Prasopa-Plaizier N, Waters H, Bates DW. The global burden of unsafe medical care: analytic modelling of observational studies. *BMJ Q. Safety*. 2013;22(10):809-815.
- Augustinos P, Ouriel K. Invasive approaches to treatment of venous thromboembolism. *Circulation*. 2004;110(9):127-134.
- Johnson BF, Manzo RA, Bergelin RO, Strandness DE. Relationship between changes in the deep venous system and

the development of the postthrombotic-syndrome after an acute episode of lower-limb deep-vein thrombosis - a one-year to 6-year follow-up. *J Vasc Surg*. 1995;21(2):307-313.

- Kahn SR, Ginsberg JS. Relationship between deep venous thrombosis and the postthrombotic syndrome. *Arch Intern Med*. 2004;164(1):17-26.
- Grosse SD, Nelson RE, Nyarko KA, Richardson LC, Raskob GE. The economic burden of incident venous thromboembolism in the United States: a review of estimated attributable healthcare costs. *Thromb Res*. 2016;137:3-10.
- Kearon C, Akl EA, Ornelas J, et al. Antithrombotic therapy for VTE disease: CHEST guideline and expert panel report. *Chest*. 2016;149(2):315-352.
- Mazzolai L, Aboyans V, Ageno W, et al. Diagnosis and management of acute deep vein thrombosis: a joint consensus document from the European Society of Cardiology working groups of aorta and peripheral vascular diseases and pulmonary circulation and right ventricular function. *Eur Heart J*. 2018;39(47):4208-4218.
- Bose G, Graveline J, Yogendrakumar V, Fergusson D, Dowlatshahi D. Direct oral anticoagulants in treatment of cerebral venous thrombosis: a systematic review protocol. *Syst Rev*. 2019;8(1):99.
- Daley MJ, Murthy MS, Peterson EJ. Bleeding risk with systemic thrombolytic therapy for pulmonary embolism: scope of the problem. *Therap Adv Drug Safety*. 2015;6(2):57-66.
- Luo H, Steffen W, Cercek B, Arunasalam S, Maurer G, Siegel RJ. Enhancement of thrombolysis by external ultrasound. *Am Heart J*. 1993;125(6):1564-1569.
- Wright C, Hynynen K, Goertz D. In vitro and in vivo high-intensity focused ultrasound thrombolysis. *Invest Radiol*. 2012;47(4):217-225.
- Stone MJ, Frenkel V, Dromi S, et al. Pulsed-high intensity focused ultrasound enhanced tPA mediated thrombolysis in a novel in vivo clot model, a pilot study. *Thromb Res*. 2007;121(2):193-202.
- Tachibana K, Tachibana S. Th echo-contrast material as an enhancer for ultrasound accelerated thrombolysis. *Circulation*. 1995;92(5):1148-1150.
- Unger EC, Matsunaga TO, McCreery T, Schumann P, Sweitzer R, Quigley R. Therapeutic applications of microbubbles. *Eur J Radiol*. 2002;42(2):160-168.
- Parikh S, Motarjeme A, McNamara T, et al. Ultrasound-accelerated thrombolysis for the treatment of deep vein thrombosis: initial clinical experience. *J Vasc Interv Radiol*. 2008;19(4):521-528.
- Ter Haar G. Therapeutic ultrasound. *Eur J Ultrasound*. 1999;9(1):3-9.
- Maxwell AD, Owens G, Gurm HS, Ives K, Myers DD, Xu Z. Noninvasive treatment of deep venous thrombosis using pulsed ultrasound cavitation therapy (Histotripsy) in a porcine model. *J Vasc Interv Radiol*. 2011;22(3):369-377.
- Rosnitskiy PB, Yuldashev PV, Sapozhnikov OA, et al. Design of HIFU transducers for generating specified nonlinear ultrasound fields. *IEEE Trans Ultrason Ferroelectr Freq Control*. 2017;64(2):374-390.
- Sponer J. Dependence of the cavitation threshold on the ultrasonic frequency. *Czech J Phys*. 1990;40(10):1123-1132.
- Datta S, Coussics C-C, Ammi AY, Mast TD, de Courten-Myers GM, Holland CK. Ultrasound-enhanced thrombolysis using Definity (R) as a cavitation nucleation agent. *Ultrasound Med Biol*. 2008;34(9):1421-1433.
- Khumri TM, Main ML. Safety and risk-benefit profile of microbubble contrast agents in echocardiography. *Asia Pacif Cardiol*. 2008;2(1):47-49.
- Paradossi G, Oddo L, Cerroni B, et al. In vivo toxicity study of engineered lipid microbubbles in rodents. *ACS Omega*. 2019;4(3):5526-5533.

23. Chang EH. An introduction to contrast-enhanced ultrasound for nephrologists. *Nephron*. 2018;138(3):176-185.
24. Nogueira RG, Schwamm LH, Hirsch JA. Endovascular approaches to acute stroke, part 1: drugs, devices, and data. *Am J Neuroradiol*. 2009;30(4):649-661.
25. Berlis A, Lutsep H, Barnwell S, et al. Mechanical thrombolysis in acute ischemic stroke with endovascular photoacoustic recanalization. *Stroke*. 2004;35(5):1112-1116.
26. Shah R, Martin RE, Topaz O. Laser angioplasty and laser-induced thrombolysis in revascularization of anomalous coronary arteries. *The J Invasive Cardiol*. 2002;14(4):180-186.
27. Topaz O, Vetrovec G. Laser for optical thrombolysis and facilitation of balloon angioplasty in acute myocardial infarction following failed pharmacologic thrombolysis. *Cathet Cardiovasc Diagn*. 1995;36(1):38-42.
28. Shangquan HQ, Gregory KW, Casperson LW, Prah SA. Enhanced laser thrombolysis with photomechanical drug delivery: an in vitro study. *Lasers Surg Med*. 1998;23(3):151-160.
29. Denheijer P, Vandijk RB, Pentinga ML, Hillege HL, Lie KI. Laser thrombolysis in acute myocardial infarction: results of a clinical feasibility study. *J Interv Cardiol*. 1994;7(6):525-534.
30. Hazlewood D, Yang X. Enhanced laser surface ablation with an integrated photoacoustic imaging and high intensity focused ultrasound system. *Lasers Surg Med*. 2019;51(7):616-624.
31. Zhang H, Xie X, Li J, et al. Removal of choroidal vasculature using concurrently applied ultrasound bursts and nanosecond laser pulses. *Sci Rep*. 2018;8(1):12848.
32. Li S, Qin Y, Wang X, Yang X. Bubble growth in cylindrically-shaped optical absorbers during photo-mediated ultrasound therapy [published online ahead of print 2018/05/26]. *Phys Med Biol*. 2018;63(12):125017.
33. Hu Z, Zhang H, Mordovanakis A, et al. High-precision, non-invasive anti-microvascular approach via concurrent ultrasound and laser irradiation. *Sci Rep*. 2017;7:40243.
34. Cui H, Staley J, Yang X. Integration of photoacoustic imaging and high-intensity focused ultrasound. *J Biomed Optics*. 2010;15(2):021312.
35. Cui H, Yang X. Real-time monitoring of high-intensity focused ultrasound ablations with photoacoustic technique: an in vitro study [published online ahead of print 2011/10/14]. *Med Phys*. 2011;38(10):5345-5350.
36. Cui H, Yang X. Enhanced-heating effect during photoacoustic imaging-guided high-intensity focused ultrasound. *Appl Phys Lett*. 2011;99(23):231113.
37. Cui H, Yang X. Laser enhanced high-intensity focused ultrasound thrombolysis: an in vitro study. *J Acoust Soc Am*. 2013;133(2):E1123-128.
38. Cui H, Zhang T, Yang X. Laser-enhanced cavitation during high intensity focused ultrasound: an in vivo study. *Appl Phys Lett*. 2013;102(13):133702.
39. Hazlewood D, Yang X. Enhanced cavitation activity in a slab-shaped optical absorber during photo-mediated ultrasound therapy. *Phys Med Biol*. 2020;65(5):055006.
40. Jo J, Forrest ML, Yang X. Ultrasound-assisted laser thrombolysis with endovascular laser and high-intensity focused ultrasound. *Med Phys*. 2020;48(2):579-586. <https://doi.org/10.1002/mp.14636>
41. Paulus YM, Jain AT, Gariano RF, et al. Healing of retinal photocoagulation lesions. *Invest Ophthalmol Vis Sci*. 2008;49(12):5540-5545.
42. Church CC. Spontaneous homogeneous nucleation, inertial cavitation and the safety of diagnostic ultrasound. *Ultrasound Med Biol*. 2002;28(10):1349-1364.
43. Jo J, Yang X. Laser-enhanced high-intensity focused ultrasound heating in an in vivo small animal model. *Appl Phys Lett*. 2016;109(21):213702.
44. Hoffman HJ, Telfair WB. Photospallation: a new theory and mechanism for mid-infrared corneal ablations. *J Refract Surg*. 2000;16(1):90-94.
45. Vogel A, Venugopalan V. Mechanisms of pulsed laser ablation of biological tissues. *Chem Rev*. 2003;103(2):577-644.
46. Arnal B, Wei C-W, Perez C, et al. Sono-photoacoustic imaging of gold nanoemulsions: part II. Real time imaging. *Photoacoustics*. 2015;3(1):11-19.
47. Arnal B, Perez C, Wei C-W, et al. Sono-photoacoustic imaging of gold nanoemulsions: part I. Exposure thresholds. *Photoacoustics*. 2015;3(1):3-10.
48. Fanny CH, Wu TM, Holt RG, Murray TW, Roy RA. Nucleating cavitation from laser-illuminated nano-particles. *Acoust Res Lett Online-Arlo*. 2005;6(3):138-143.
49. McLaughlan JR, Roy RA, Ju H, Murray TW. Ultrasonic enhancement of photoacoustic emissions by nanoparticle-targeted cavitation. *Opt Lett*. 2010;35(13):2127-2129.
50. Ju H, Roy RA, Murray TW. Gold nanoparticle targeted photoacoustic cavitation for potential deep tissue imaging and therapy. *Biomed Optics Exp*. 2013;4(1):66-76.

SUPPORTING INFORMATION

Additional supporting information may be found online in the Supporting Information section.

How to cite this article: Singh R, Jo J, Riegel M, Forrest ML, Yang X. The feasibility of ultrasound-assisted endovascular laser thrombolysis in an acute rabbit thrombosis model. *Med Phys*. 2021;48:4128–4138. <https://doi.org/10.1002/mp.15068>