Received: 17 May 2021 | Revised: 26 June 2021 | Accepted: 12 July 2021

DOI: 10.1111/1756-185X.14184

INVITED REVIEW

International Journal of Rheumatic Diseases

WILEY

Will rheumatologists ever pick up the arthroscope again?

Robert W. Ike[1] | Kenneth C. Kalunian[2]

[1]Department of Internal Medicine, Division of Rheumatology, University of Michigan Health System, Ann Arbor, MI, USA

[2]Department of Medicine, Division of Rheumatology, Allergy and Immunology, University of California at San Diego, San Diego, CA, USA

Correspondence
Robert W. Ike, Department of Internal Medicine, Division of Rheumatology, University of Michigan Health System, 1611 Harbal Dr, Ann Arbor MI, USA.
Email: scopydoc52@yahoo.com

Abstract

Conditions prompting physicians and surgeons first adapting endoscopes to peer into joints were mainly the sort of synovial conditions that would concern today's rheumatologists. Rheumatologists were among the pre-World War II pioneers developing and documenting arthroscopy. The post-War father of modern arthroscopy, Watanabe, found rheumatologists among his early students, who took back the technique to their home countries, teaching orthopedists and rheumatologists alike. Rheumatologists described and analyzed the intra-articular features of their common diseases in the '60s and '70s. A groundswell of interest from academic rheumatologists in adapting arthroscopy grew considerably in the '90s with development of "needle scopes" that could be used in an office setting. Rheumatologists helped conduct the very trials the findings of which reduced demand for their arthroscopic services by questioning the efficacy of arthroscopic debridement in osteoarthritis (OA) and also developing biological compounds that greatly reduced the call for any resective intervention in inflammatory arthropathies. The arthroscope has proven an excellent tool for viewing and sampling synovium and continues to serve this purpose at several international research centers. While cartilage is now imaged mainly by magnetic resonance imaging, some OA features – such as a high prevalence of visible calcinosis – beg further arthroscopy-directed investigation. A new generation of "needle scopes" with far superior optics awaits future investigators, should they develop interest.

KEYWORDS

arthroscopy, calcinosis, lavage, synovial biopsy, synovium

1 | INTRODUCTION

We authors were the first American rheumatologists to learn arthroscopy from another rheumatologist and apply it exclusively to arthritis patients, including operative interventions. Our mentor Bill Arnold learned the technique in a cooperative venture with orthopedist David Stulberg of Northwestern University beginning in '81, then taught RWI in '85 and KCK in '88, who each subsequently worked with orthopedists before embarking on independent practice at their home institutions. We appreciated from the beginning the tremendous potential for arthroscopy as a tool not only for direct therapy, but for both clinical and research assessment. We've seen the surge of interest among rheumatologists fade into the new century, with arthroscopy employed as a research tool in only a handful of institutions, all outside the USA. Tools for basic assessment of the synovium have grown much more powerful, and arthroscopes themselves have been transformed into tiny inexpensive items ready

We dedicate this work to our mentor, Bill Arnold, who showed us the way.

© 2021 Asia Pacific League of Associations for Rheumatology and John Wiley & Sons Australia, Ltd.

for in-office use. We hypothesize that this combination of factors should be leading to another surge of interest in arthroscopy among rheumatologists. To describe the arc that got us here, and where we might go next, we undertook this review.

2 | SEARCH STRATEGY

We searched literature employing PubMed, Scopus, and Web of Science using search terms "arthroscopy AND rheumatology" plus "arthroscopy AND (synovitis OR synovium)" to find references to supplement our own personal libraries and recollections.

3 | BEGINNINGS

Rheumatologists have had an interest in arthroscopy since its inception. Most of the conditions which the early arthroscopists examined were chronic synovial conditions of the sort that modern rheumatologists would nowadays have a role in managing.[1,2] Those orthopedists who used the scope to evaluate internal derangements, which would make arthroscopy so popular with later generations of orthopedists, eventually abandoned the technique for lack of interest from their peers.[1,3] The first book on arthroscopy was written by German rheumatologist Ernst Vaubel.[4]

World War II paused all investigation into arthroscopy. After the War, Makei Watanabe refined the arthroscope, documented and recorded (with drawing, camera and movie) mechanical and synovial conditions of the knee, and performed the first resective procedures under arthroscopic guidance.[5] Among his many students were rheumatologists from several countries, who took their skills home and trained others.[6-10] Rheumatologists were the main arthroscopists in France[11] and Cuba[12] into the 21st century. Watanabe's most famous student, Canadian orthopedist Bob Jackson, became the prime developer of arthroscopic surgery in North America.[13] He welcomed interest from rheumatologists and helped train Roy Altman (University of Miami) in the '60s, plus Joe Combs (Mayo) and Nathan Wei (Frederick MD) in the '80s.

British,[14,15] Spanish,[16] French,[10] American,[17] Canadian,[18] Mexican[6] and Australian[19] rheumatologists described the arthroscopic features of the chronic conditions they were facing in the '60s and '70s. A Watanabe-trained rheumatologist in Mexico City became the first to use an arthroscope to judge treatment effects, assessing the effect of azathioprine on rheumatoid synovitis.[20] Fiberoptic illumination of the arthroscopic view, replacement of the eyeball with a video camera for capture and recording of that view,[21] and the suction-assisted motorized shaver made arthroscopy a less dangerous and demanding procedure.[22] Explosion of growth in orthopedics was accompanied by growing interest among rheumatologists. Bill Kelley, in his 1987 presidential address to the American Rheumatism Association (ARA: now American College of Rheumatology) outlining ways forward to enhance what he saw as weak interest in rheumatology among students and trainees, stated, "I believe we need to expand the specialty of rheumatology to cover some of the peripheral areas which now are largely ignored and sometimes poorly handled. This would include *…the use of certain technical procedures which are appropriate to our specialty*" (our emphasis).[23] The ARA Board of Directors in June '86 approved guidelines for performance of arthroscopy by rheumatologists.[24] Arthroscopy Association of North America (AANA) guidelines were not published till '93[25] but did include a path for non-orthopedists to perform non-operative arthroscopy and were published in every issue of *Arthroscopy* until January 2019.

Students of the synovium assessed further basic appearances of rheumatologic conditions,[26,27] made correlations between macroscopic and microscopic appearances,[28] including the development of grading scales,[29,30] and described unique characteristics of certain conditions, such as psoriatic arthritis,[31] Behçet's,[32] sarcoidosis,[33] polymyalgia rheumatica,[34] familial Mediterranean fever,[35] and amyloidosis revealing myeloma.[36] Advances in arthroscopic technology that led the procedure out of the operating room into the procedure suite and office made evident the role the arthroscope could play in assessment of synovial disorders. Arthroscopic assessment proved critical in judgment of responses to treatment, both systemic[37,38] and intra-articular[37,39-41] and in further basic investigations of the synovium in various disorders,[42-44] including comparison with imaging modalities.[45,46]

Much of the volume driving use of arthroscopy by rheumatologists in the '80s and '90s concerned use in knee osteoarthritis (OA). Although some basic assessment studies were conducted,[47-49] the major focus was on treatment. The first of many controlled trials questioning the utility of arthroscopy in knee OA came from rheumatologists,[50] as did investigations showing the joint lavage so often ascribed to arthritis improvement following arthroscopy was no more than a placebo effect.[51] Additional investigations sowing the same doubt quelled any use of arthroscopy in OA by rheumatologists but have not yet completely permeated orthopedic practice.[52] Use of arthroscopy in knee OA has shown that magnetic resonance imaging (MRI) assessment is equivalent to direct assessment,[53] and that directed physical exam can predict cartilage abnormalities disclosed at arthroscopy.[54]

4 | THE 21ST CENTURY

In a frank turn-of-the-century discussion of the skills a rheumatologist might possess to face the future, arthroscopy was mentioned at some length.[55] Yet, use of arthroscopy faded among American rheumatologists. RWI did his last case in '01, Bill Arnold in '03 and KCK in '09.[56] However, the new millennium saw an explosion of publications from European and Australian centers using the arthroscope to study synovium, mainly of the idiopathic inflammatory arthropathies. Progress was enhanced by development of mini-arthroscopes capable of examining small joints,[57] establishment of systems to score the macroscopic synovial appearance,[58] and appreciation of the variability of synovial characteristics within any joint,[59] and efficient methods of assessing synovial tissue.[60]

5 | SYNOVIAL DISORDERS

Macroscopic,[61-66] microscopic,[67-73] and molecular[74-82] features of synovium were characterized, with a particular interest in early disease states,[83-96] including pre-clinical[97-100] and even normal synovium.[101] Differences between various disease states were discerned.[102-116] The arthroscope was used extensively to assess effects of various treatments, both intra-articular[117] and systemic.[56,118-159] While orthopedists focused on arthroscopy in infectious arthritis as a treatment modality,[160] rheumatologists utilized the arthroscope to diagnose and monitor Whipples' disease[161] and to characterize features of patients with parvovirus B19 in their synovium.[162]

6 | OA

While use of the arthroscope to treat OA fell out of favor early in the century, it was used to characterize synovium[163,164] and cartilage,[163] including correlation with MRI findings.[164] It was shown that a Jamshidi needle can be applied to sample cartilage at arthroscopy for outcome studies,[165] and that calcinosis is a remarkably prevalent arthroscopic finding in knee OA, even absent radiographic chondrocalcinosis.[166] Synovitis was identified as predictive of cartilage loss.[167] Grading systems for cartilage damage were validated.[168] Two trials comparing intra-articular hyaluronates with corticosteroids demonstrated at arthroscopy that the 2 compounds had equivalent effects on synovitis,[169,170] while progression of cartilage damage was less in hyaluronate-treated knees.[170] A report from Bulgaria described positive effects of arthroscopic debridement and washout in knee OA 2 years after publication of results from controlled trials discrediting these interventions.[171] A recent commentary described positive findings regarding joint washout appearing since the trials which seemingly discredited the procedure, suggesting that washout should be reconsidered as a treatment modality for knee OA.[172] A recent report describing isolation from arthroscopic washout fluid of mesenchymal stem cells that can be encapsulated in a cross-linked hydrogel which can then generate new cartilage matrix in an animal model suggests the therapeutic effect of joint washout may someday extend beyond the immediate effect on the joint.[173]

7 | IMAGING

Arthroscopy served as a gold standard to which MRI[174,175] and ultrasound[176-179] were compared, including descriptions of simultaneous use of ultrasound and arthroscopy to assess synovitis.[180,181] An example of another arthroscopy-directed assessment that cannot be duplicated by an ultrasound-guided procedure, the oxygenation state of the synovial membrane was measured using the Lidox probe, developed to assess brain tissue.[72,152,156,182-184]

TABLE 1 Institutions where a rheumatologist is performing arthroscopy

City	Institution	Arthroscopist	Chief of section	Recent reference(s)	Accepting trainees?	Email
Adelaide	Flinders Medical Centre	Mihir D Wechalekar	Michael Shanahan	75,97	Yes	Mihir.Wechalekar@sa.gov.au
Amsterdam	Amsterdam University Medical Center	Marleen van de Sande	Sander Tas	101	Yes	s.w.tas@amsterdamumc.nl
Barcelona	Hospital Clinic and IDIBAPS	Juan D Cañete	José Alfredo Gómez Puerta	116,117	Yes	JCANETE@clinic.cat
Dublin	St. Vincent's Hospital	Doug Veale	Gerry Wilson	83,192,214	Yes	Douglas.veale@ucd.ie
Leeds	Leeds Institute Rheumatic and Musculoskeletal Medicine University Leeds	Ahmed Zayat* *left Leeds April 2020	Paul Emery		Yes	P.Emery@leeds.ac.uk
Lisbon	Hospital da Santa Maria, CHULN, Instituto de Medicina Molecular Universidade de Lisboa	Elsa Vieira-Sousa	João Eurico Cabral da Fonseca	188-190	Yes	Elsa-sousa@hotmail.com
Louvain	Cliniques Universitaires Saint-Luc Université catholique de Louvain	Adrien Nzeusseu Toukap	Frédéric Houssiau		No	Adrien.Nzeusseu@uclouvain.be
Milan	Niguarda Ca' Granda Hospital	Oscar Masimilliano Epis		183	No	oscar.epis@ospedaleniguarda.it
New Delhi	Army Hospital (Research and Referral) Delhi Cantt	Ved Chaturvedi	Lalit Duggal		No	Ved.chaturvedi@gmail.com
Stockholm	Karolinska Hospital	Erik Af Klint	Marie Wahren-Herlenius		No	erik.af.klint@ki.se

8 | CURRENT STATUS OF INVESTIGATION OF SYNOVIUM

Use of arthroscopy in investigation of synovial disorders has persisted in several international centers (Table 1). While ultrasound-directed biopsy has become popular for obtaining synovium for study,[185] a retrospective review found that patient-related outcomes were no worse following arthroscopic biopsy than the simpler ultrasound-guided procedure.[186] A multicenter retrospective analysis evaluating performance of blind, ultrasound-guided and arthroscopic synovial biopsy techniques in patients with inflammatory arthritis found the amount and quality of tissue procured under ultrasound was as satisfactory as that from arthroscopy, although no small joints were arthroscoped and sublining macrophage number – a marker for the synovial lining layer and thus an indicator of the quality of the specimen – was greater in arthroscopy samples[187] Add to this the capabilities of arthroscopy to provide a larger volume of tissue, assess macroscopic characteristics of tissue, and obtain tissue from joint areas not accessible from ultrasound, and the attractions of arthroscopy become obvious, judged the "gold standard" for synovial biopsy by a panel convened to assess biopsy procedures.[188] Veale, one of the pioneers of modern rheumatologic arthroscopy in Europe, recently re-emphasized the critical role the arthroscope plays in investigations of the synovium.[189] Synovial biopsies and their interpretation will also be augmented by increased use and would evolve the field of synovial histopathology as well. And arthroscopic biopsy may not be without benefit to the patient, with the washout accompanying the procedure conferring benefit,[190] with larger the volume the better,[191] especially if capped with a corticosteroid injection.[192]

While blind, closed synovial biopsy has been possible since the '50s, the procedure never was widely applied.[193] Ultrasound-guided synovial biopsy has become very popular, drawing in many former rheumatologist-arthroscopists. Access is possible in a clinic room, and no operating room politics are involved. However, without being able to visualize the tissue being sampled or obtain fairly large volumes of tissue from such areas, ultrasound-guided biopsy can hardly be considered a comparable substitute for an arthroscopic biopsy. Further, such critical areas in the joint where the synovium may have an important relationship with intra-articular structures, such as the meniscus, the cruciate ligament, and the cartilage-pannus junction[194] are simply out of the reach of any ultrasound-guided procedure.

Chaturvedi et al. recently posited that the very terminology rheumatologists use in describing their use of arthroscopy may be a hindrance to wider acceptance by peers, patients, other physicians and surgeons, and the general public.[195] He proposed we call what we do "medical arthroscopy" to distinguish it from the surgical and operative interventions favored by orthopedists and still perceived by some who wonder what we're doing, and why (Table 2). Moving the procedure fully out of the operating room hasn't been enough, it seems. Mundane administrative factors can impair use of arthroscopy by rheumatologists. For example, while in the US rheumatologists and orthopedists employ the same CPT (Current Procedural Terminology) codes when billing for arthroscopic procedures, in Australia there is an item number for orthopedic procedures associated with renumeration whereas there is no such item number for "medical arthroscopy" and therefore no funding for the procedure.

9 | NEW ARTHROSCOPES

Technological advances in arthroscopy have produced a new generation of "scopes" even more suited to the office environment than their predecessors (Figure 1).[196] Each has combined small size with modern image processing power of the sort that has made your cell phone camera the equivalent of an SLR. The old dark blurry needle scope images of the '90s have been replaced with images worthy of a 4.0 mm glass lens operating room scope. The images are projected to the equivalent of a tablet, so the whole unit is much more compact and much cheaper than an old office unit or operating room setup. These "scopes" are primarily promoted as diagnostic instruments, although one of the manufacturers has developed a line of hand-operated and motorized instruments for tissue resection suitable for use with the new small scope.[197] These arthroscopes beg to be deployed in rheumatology offices, but the interest has yet to develop. Orthopedists are taking notice.[198]

10 | WAYS FORWARD

It has recently been written that orthopedists "are falling out of love with arthroscopy",[199] as commonly performed arthroscopic surgical procedures fall victim to the scrutiny of prospective controlled trials. Use of arthroscopic surgery is truly falling off.[200]

TABLE 2 Summary of indications for and benefits of medical arthroscopy (from reference 195, with permission)

Indication for arthroscopy	Benefits of arthroscopy
Does the patient have synovial inflammation?	Distinguishing inflammatory arthritis, eg, psoriatic arthritis from osteoarthritis. Investigation of persistent swelling of one joint with otherwise well-controlled inflammatory arthritis
What is the etiology of synovial inflammation?	Diagnostic histopathology: sarcoidosis, crystal arthritis, atypical infections, eg, mycobacterial, fungal, parasitic
Research	Using histopathologic features to stratify therapeutic choice, eg, use of rituximab in rheumatoid arthritis

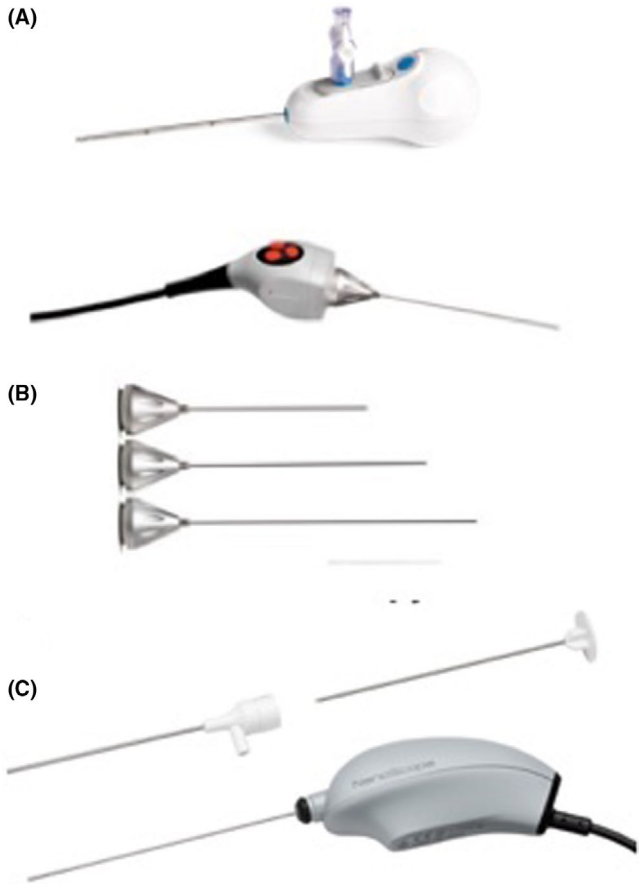

FIGURE 1 Needle arthroscopes for in-office use. (A) MiEye 2 (Trice Medical, Malvern, PA, USA), 1.9 mm disposable scope and camera with 2.2 mm inflow cannula and 120^0 field of view. https://tricemedical.com/mi-eye/. (B) VisionScope (VisionScope Technologies, Littleion, MA, USA), 1.4 mm reusable scope available in 4 lengths (60 mm, 95 mm, 125 mm, and 160 mm). Utilizes 1.9 mm disposable cannula and reusable camera. https://visionscope-tech.com/. (C) NanoScope (Arthrex, Inc Naples, FL, USA), 1.9 mm disposable scope and camera with 2.2 mm inflow cannula and 120° field of view. https://www.arthrex.com/what-surgeons-are-talking-about/78CC3845-4F4A-4F8A-A867-016B995DFC52. Images of arthroscopes obtained directly from their respective manufacturers, who also granted permission to use the images in this publication

Rheumatologists fell into a similar pit, after first seeing their procedure as a help with OA or an intervention for rheumatoid arthritis (where biologics have made it unnecessary). Yet the utility of arthroscopy as a tool to assess synovium remains incredibly underutilized. Tools to evaluate synovial tissue have become ever more powerful.[201] Rheumatologists have not entirely put the arthroscope down. There are many reasons for them to pick it up again. Access to arthroscopy is easier and cheaper than ever. Learning how to do it is admittedly a challenge. Not everyone has the unique set of psychomotor skills necessary to manipulate the scope and instruments in 3 dimensions. Some will never get it, even as some orthopedists find out.[202] Apparently, it helps if you're good at video games.[203] Virtual reality-based arthroscopy simulators have been developed[204-206] and have been used successfully in orthopedic surgery training programs.[207] The range of skills required for the uses a rheumatologist might have for an arthroscope are not as broad as those required to perform arthroscopic surgery. Use of a simulator could accelerate the rate at which an interested rheumatologist might acquire those skills. And applying those skills can certainly add to job satisfaction. There is joy in the successful application of hand-eye coordination that comes with doing arthroscopy, and in seeing directly the pathologies about which one had only been inferring for years; while too serious to be called a game, those who do it always get a big kick out of it, every time. And is there something bad about bringing some fun to the practice of medicine?[208,209]

11 | CONCLUSIONS

In part due to lessons learned from arthroscopy, rheumatology stands on the brink of true "precision medicine", with treatments tailored to specific individual characteristics of each patient.[210,211] It remains generally accepted that arthroscopy is the gold standard for assessing and obtaining the synovium that would guide such therapy,[212,213] particularly since the variability in synovial characteristics cannot be accounted for by externally guided sampling.[214] Means to assess synovial tissue are about to take another quantum leap.[215] The future for treatment of inflammatory joint disorders looks bright, with arthroscopy possibly a very big part of that future. Barriers to performance of this procedure have been broken down by newly available instruments. It's time for rheumatologists to pick up the arthroscope again.

CONFLICT OF INTEREST

The authors have no conflicts of interest to disclose, including any with the arthroscope manufacturers.

ORCID

Robert W. Ike https://orcid.org/0000-0003-4715-4384
Kenneth C. Kalunian https://orcid.org/0000-0003-0261-3102

REFERENCES

1. Jackson RW. A history of arthroscopy. *Arthroscopy*. 2010;26(1):91-103. https://doi.org/10.1016/j.arthro.2009.10.005
2. Ike RW, Arnold WJ, Kalunian KC. Arthroscopy in rheumatology: where have we been? Where might we go? *Rheumatology*. 2021;60(2):518-528. https://doi.org/10.1093/rheumatology/keaa560
3. Burnam MS. Arthroscopy or direct visualization of joints. *J Bone Joint Surg*. 1931;13:669-695.
4. Kieser C. [Ernst Vaubel M. D. German pioneer in the field of arthroscopy 1902-1989]. *Unfallchirurg*. 103(1):93-97. [in German]. https://doi.org/10.1007/s001130050018
5. Watanabe M. Memories of the early days of arthroscopy. *Arthroscopy*. 1986;2(4):209-214. https://doi.org/10.1016/s0749-8063(86)80073-1
6. Gil JR, Katona G. Arthroscopy as a means of diagnosis and research: review of 80 arthroscopies. Proceedings of the Fourth Pan

American Congress of Rheumatology, Mexico City. *Excerpta Med Intern Congress*. 165:209-215.
7. Marqués J, Santamaría A, Gómez Martínez G, Barceló P. Arthroscopy. *Rev Esp Reum Enferm Osteoartic*. 1971;14(1):47-58. [in Spanish].
8. Andersen RB, Rossel I. Arthroscopy of the knee joint in rheumatic diseases. *Ugeskr Laeger*. 1973;135(2):71-73. [in Danish].
9. Torres-Moya R. La artroscopia en Cuba, sus inicios en el Servicio de reumatología del Hospital Docente Clínico Quirúrgico 10 de Octubre [Arthroscopy in Cuba, its beginnings in the Rheumatology Service of the Teaching Clinical Surgical Hospital October 10]. *Revista Cubana de Reumatología*. 2013;13:1-3. [in Spanish].
10. Dorfman H, de Seze S. Nouvelles observations sur l'arthroscopie du genou. Resultat d'une experience personelle. [New observations on knee arthroscopy. Result of a personal experience]. *Sem Hop*. 1972;48:3011-3019. [In French].
11. Ayral X, Bonvarlet JP, Simonnet J, Amor B, Dougados M. Arthroscopy-assisted synovectomy in the treatment of chronic synovitis of the knee. *Rev Rhum Engl Ed*. 1997;64(4):215-226.
12. Reyes Llerena GA, Toledano MG, Martinez AH. Rheumatology and care for the rheumatic diseases in Cuba. *J Clin Rheumatol*. 1995;15(5):289-292. https://doi.org/10.1097/00124743-199910000-00010
13. Jackson RW. Memories of the early days of arthroscopy: 1965–1975: The formative years. *Arthroscopy*. 1987;1:1-3. https://doi.org/10.1016/s0749-8063(87)80002-6
14. Jayson MIV, Dixon AS. Arthroscopy of the knee in rheumatic diseases. *Ann Rheum Dis*. 1968;27:503-511. https://doi.org/10.1136/ard.27.6.503
15. Yates DB, Scott JT. Rheumatoid synovitis and joint disease. *Ann Rheum Dis*. 1975;34:1-6.
16. Marqués J, Barcelóy GP. *La artroscopia [The arthroscopy]*. Pher Laboratories; 1977. [in Spanish].
17. Altman RD. Arthroscopic findings of the knee in patients with pseudogout. *Arthritis Rheum*. 1978;19:286-292.
18. Camerlain M. Arthroscopy in rheumatological perspectives [L'arthroscopie et ses perspectives rhumatologiques]. *Union Med Can*. 1974;103(7):1262-1265. [in French].
19. Henderson DRF, Tribe CR, Dixon ASJ. Synovitis in polymyalgia rheumatica. *Rheumatol Rehab*. 1975;14(4):244-250. https://doi.org/10.1093/rheumatology/14.4.244
20. Katona G, Larraza O, Isai M. Objective evaluation of an anti-inflammatory effect of azathioprine in rheumatoid arthritis. *Eur J Rheum Inflamm*. 1978;1(3):232-236.
21. Jackson DW. Videoarthroscopy: a permanent medical record. *Am J Sports Med*. 1978;6(5):213-216. https://doi.org/10.1177/036354657800600501
22. Johnson LL. *Arthroscopic Surgery: Principles and Practice*. C. V. Moseby; 1986.
23. Kelley WN. A new role for the ARA in guiding our destiny. *Arthritis Rheum*. 1987;30(11):1201-1204. https://doi.org/10.1002/art.1780301101
24. Arnold WJ, Kalunian K. Arthroscopic synovectomy by rheumatologists: time for a new look. *Arthritis Rheum*. 1989;32(1):109-111. https://doi.org/10.1002/anr.1780320120
25. Morris AH, Jennings JE, Stone RG, Katz JA, Garroway RY, Hendler RC. Guidelines for privileges in arthroscopic surgery. *Arthroscopy*. 1993;9(1):125-127.
26. Frassica FJ, Combs JJ. Sim FH (1985) Synovial proliferative disorders: differential diagnosis. *Arthroscopy*. 1985;1(3):183-189.
27. Myers SL, Brandt KD, Ehlich JW, et al. Synovial inflammation in patients with early osteoarthritis of the knee. *J Rheumatol*. 1990;12:1662-1669.
28. Lindblad S, Hedfors E. Intraarticular variation in synovitis. Local macroscopic and microscopic signs of inflammatory activity are significantly correlated. *Arthritis Rheum*. 1985;28(9):977-986. https://doi.org/10.1002/art.1780280904
29. Lindblad S. Recent progress in the study of synovitis by macroscopic and microscopic examination – a review. *Scand J Rheumatol Suppl*. 1988;76:27-32. https://doi.org/10.3109/03009748809102949
30. Ayral X, Mayoux-Benhamou A, Dougados M. Proposed scoring system for assessing synovial membrane abnormalities at arthroscopy in knee osteoarthritis. *Br J Rheumatol*. 1996;35(Suppl 3):14-17. https://doi.org/10.1093/rheumatology/35.suppl_3.14
31. Reece RJ, Canete JD, Parsons WJ, Emery P, Veale DJ. Distinct vascular patterns of early synovitis in psoriatic, reactive, and rheumatoid arthritis. *Arthritis Rheum*. 1999;42(7):1481-1484.
32. Moll C, Bogas M, Gómez-Puerta JA, et al. Macroscopic features of knee synovitis in early untreated Behçet disease and psoriatic arthritis. *Clin Rheumatol*. 2009;28(9):1053-1057. https://doi.org/10.1007/s10067-009-1205-0
33. Scott DG, Porto LO, Lovell CR, Thomas GO. Chronic sarcoid synovitis in the Caucasian: an arthroscopic and histological study. *Ann Rheum Dis*. 1981;40:121-123. https://doi.org/10.1136/ard.40.2.121
34. Douglas WAC, Martin BA, Morris JH. Polymyalgia rheumatica: An arthroscopic study of the shoulder joint. *Ann Rheum Dis*. 1983;42(3):311-316. https://doi.org/10.1136/ard.42.3.311
35. Langer HE, Huth F, Behar S, Zeidler H. Synovitis of familial Mediterranean fever [Die synovitis des familiaren mittelmeerfiebers]. *Deutsche Med Wochen*. 1985;110(44):1695-1700. [in German]. https://doi.org/10.1055/s-2008-1069072
36. Krause E, Argiles A, Bataille R, et al. Synovial amyloidosis revealing a myeloma. Clinical arthroscopic and immunochemical aspects. *Rev Rhum*. 1988;55(9):689-692.
37. Veale DJ, Reece RJ, Parsons W, et al. Intra-articular primatised anti-CD4: efficacy in resistant rheumatoid knees. A study of combined arthroscopy, magnetic resonance imaging, and histology. *Ann Rheum Dis*. 1999;58(6):342-349. https://doi.org/10.1136/ard.58.6.342
38. Smeets TJ, Kraan MC, Versendaal J, Breedveld FC, Tak P. Analysis of serial synovial biopsies in patients with rheumatoid arthritis: description of a control group without clinical improvement after treatment with interleukin 10 or placebo. *J Rheumatol*. 1999;26(10):2089-2093.
39. Yates DB, Scott JT, Ramsey N. Double-blind trial of ^{90}Y for chronic inflammatory synovitis of the knee. *Rheumatology*. 1979;XVIII(suppl):46-47. https://doi.org/10.1093/rheumatology/xviii.suppl.46
40. Lindblad S, Hedfors E, Malmborg A-S. Rifamycin SV in local treatment of synovitis. A clinical, arthroscopic and pharmacologic evaluation. *J Rheumatol*. 1985;12(5):900-903.
41. Oliunin IA, Manuĭlova LS. The clinico-morphological assessment of the efficacy of local radiation therapy in rheumatoid arthritis | [Kliniko-morfologicheskaia otsenka éffektivnosti lokal'noĭ luchevoĭ terapii pri revmatoidnom artrite.]. *Ter Arkh*. 1991;63(11):122-125. [in Russian].
42. Frizziero L, Georgountzos A, Zizzi F, Focherini MC. Microarthroscopic study of the morphologic features of normal and pathological synovial membrane. *Arthroscopy*. 1992;8(4):504-509. https://doi.org/10.1016/0749-8063(92)90016-5
43. Benerbaum F, Rajzbaum G, Amor B, Toubert A. Evidence for GM-CSF receptor expression in synovial tissue – an analysis by semiquantitative polymerase chain reaction on rheumatoid arthritis and osteoarthritis synovial biopsies. *European Cytokine Net*. 1994;5(1):43-46.
44. Youssef P, Roth J, Frosch M, et al. Expression of myeloid related proteins (MRP) 8 and 14 and the MRP 8/14 heterodimer in rheumatoid arthritis synovial membrane. *J Rheumatol*. 1999;26(12):2523-2528.

45. Rubaltelli L, Fiocco U, Cozzi L, et al. Prospective sonographic and arthroscopic evaluation of proliferative knee joint synovitis. *J Ultrasound Med*. 1994;13(11):855-862. https://doi.org/10.7863/jum.1994.13.11.855
46. Nielsen P, Volck B, Jensen CH, Lorenzen IB. Magnetic resonance imaging-determined synovial membrane and joint effusion volumes in rheumatoid arthritis and osteoarthritis - Comparison with the macroscopic and microscopic appearance of the synovium. *Arthritis Rheum*. 1997;40(10):1856-1867. https://doi.org/10.1002/art.1780401020
47. Frizziero L, Zizzi F. Arthroscopic and microarthroscopic study of the synovial membrane in osteoarthrosis. *Min Ortop Traum*. 1988;39(7):497-500.
48. Fernandez-Madrid F, Karkoven RL, Teitge RA, Miller PR, An T, Negendank WG. Synovial thickening detected my MR imaging in osteoarthritis confirmed by biopsy as synovitis. *Mag Reson Imag*. 1995;13(2):177-183. https://doi.org/10.1016/0730-725X(94)00119-N
49. Smith MD, Triantafillou S, Parker A, Youssef PP. Coleman M (1997) Synovial membrane inflammation and cytokine production in patients with early osteoarthritis. *J Rheumatol*. 1997;24(2):365-371.
50. Chang RW, Falconer J, David Stulberg S, Arnold WJ, Manheim LM, Dyer AR. A randomized, controlled trial of arthroscopic surgery versus closed-needle joint lavage for patients with osteoarthritis of the knee. *Arthritis Rheum*. 1993;36(3):289-296. https://doi.org/10.1002/art.1780360302
51. Bradley JD, Heilman DK, Katz B, Gsell P, Wallick JE, Brandt KD. Tidal irrigation as treatment for knee osteoarthritis: a sham-controlled, randomized, double-blinded evaluation. *Arthritis Rheum*. 2002;46:100-108.
52. Katz JN, Brownlee SA, Jones MH. The role of arthroscopy in the management of knee osteoarthritis. *Best Pract Res Clin Rheumatol*. 2014;28:143-156. https://doi.org/10.1016/j.berh.2014.01.008
53. Brodenick LS, Turner DA, Renfrew DL, Schnitzer TJ, Huff JP, Harris C. Severity of articular cartilage abnormality in patients with osteoarthritis: Evaluation with fast spin-echo MR vs arthroscopy. *Am J Roentgen*. 1994;162(1):99-103. https://doi.org/10.2214/ajr.162.1.8273700
54. Ike RW, O'Rourke KS. Compartment directed physical exam of the knee can predict articular cartilage abnormalities disclosed by needle arthroscopy. *Arthritis Rheum*. 1995;38:917-925. https://doi.org/10.1002/art.1780380707
55. Fraser A, Veale DJ. What practical skills do rheumatologists of the future need? *Best Pract Res Clin Rheumatol*. 2000;14(4):635-648.
56. Rosengren S, Wei N, Kalunian KC, Kavanaugh A, Boyle DL. CXCL13: a novel biomarker of B-cell return following rituximab treatment and synovitis in patients with rheumatoid arthritis. *Rheumatology (Oxford)*. 2011;50:603-610. https://doi.org/10.1093/rheumatology/keq337
57. Ostendorf B, Dann P, Wedekind F, et al. Miniarthroscopy of metacarpophalangeal joints in rheumatoid arthritis. Rating of diagnostic value in synovitis staging and efficiency of synovial biopsy. *J Rheumatol*. 1999;26(9):1901-1908.
58. af Klint E, Catrina AI, Matt P, et al. Evaluation of arthroscopy and macroscopic scoring. *Arthritis Res Ther*. 2009;11(3):R81. https://doi.org/10.1186/ar2714
59. Lindberg J, Af Klint E, Ulfgren A-K, et al. Variability in synovial inflammation in rheumatoid arthritis investigated by microarray technology. *Arthritis Res Ther*. 2006;8(2):R47. https://doi.org/10.1186/ar1903
60. Kraan MC, Haringman JJ, Ahern MJ, Breedveld FC, Smith MD, Tak PP. Quantification of the cell infiltrate in synovial tissue by digital image analysis. *Rheumatol*. 2000;39(1):43-49. https://doi.org/10.1093/rheumatology/39.1.43
61. Fiocco U, Cozzi L, Chieco-Bianci F, et al. Vascular changes in psoriatic knee joint synovitis. *J Rheumatol*. 2001;28(11):2480-2486.
62. Van den Bosch F, Baeten D, Kruithof E, De Keyser F, Veys EM. Characteristic macro- and microscopic aspect of the synovial membrane in crystal induced arthritis. *J Rheumatol*. 2001;28(2):392-393.
63. Kuzmanova SI, Zaprianov ZN, Solakov P. Correlations between arthroscopic findings and synovial membrane histology in patients with rheumatoid synovitis of the knee joint. *Folia Medica (Plovdiv)*. 2003;45(3):60-65.
64. Salvador G, Sanmartí R, Gil-Torregrosa B, García Peiró A, Rodríguez-Cros JR, Cañete JD. Synovial vascular patterns and angiogenic factors expression in synovial tissue and serum of patients with rheumatoid arthritis. *Rheumatology (Oxford)*. 2006;45(8):966-971. https://doi.org/10.1093/rheumatology/kel043
65. Moll C, Bogas M, Gomez-Puerta CR, et al. Macroscopic features of knee synovitis in early untreated Behçet disease and psoriatic arthritis. *Clin Rheumato*. 2009;28(9):1053-1077. https://doi.org/10.1007/s10067-009-1205-0
66. Vordenbaeumen S, Sewerin P, Loegters T, et al. Inflammation and vascularization markers of arthroscopically-guided finger joint synovial biopsies reflect global disease activity in rheumatoid arthritis. *Clin Exp Rheumatol*. 2014;32(1):117-120.
67. Smeets TJM, Kraan MC, Galjaard S, Youssef PP, Smith MD, Tak PP. Analysis of the cell infiltrate and expression of matrix metalloproteinases and granzyme B in paired synovial biopsy specimens from the cartilage-pannus junction in patients with RA. *Ann Rheum Dis*. 2001;60(6):561-565. https://doi.org/10.1136/ard.60.6.561
68. Van Kuijk AWR, Reinders-Blankert P, Smeets TJM, Dijkmans B, Tak PP. Detailed analysis of the cell infiltrate and the expression of mediators of synovial inflammation and joint destruction in the synovium of patients with psoriatic arthritis: Implications for treatment. *Ann Rheum Dis*. 2006;65(12):1551-1557. https://doi.org/10.1136/ard.2005.050963
69. Thuerlings RM, Wijbrandt CA, Mebius RE, et al. Synovial lymphoid neogenesis does not define a specific clinical rheumatoid arthritis phenotype. *Arthritis Rheum*. 2008;58(6):1582-1589. https://doi.org/10.1002/art.23505
70. Jones E, Churchman SM, English A, et al. Mesenchymal stem cells in rheumatoid synovium: Enumeration and functional assessment in relation to synovial inflammation level. *Ann Rheum Dis*. 2001;69(2):450-457. https://doi.org/10.1136/ard.2008.106435
71. Moran EM, Heydrich R, Ng CT, et al. IL-17A Expression Is Localised to Both Mononuclear and Polymorphonuclear Synovial Cell Infiltrates. *PLoS One*. 2011;6(8):e24048. https://doi.org/10.1371/journal.pone.0024048
72. Benham H, Norris P, Goodall J, et al. Th17 and Th22 cells in psoriatic arthritis and psoriasis. *Arthritis Res Ther*. 2013;15(5):R136. https://doi.org/10.1186/ar4317
73. Musters A, Klarenbeek PL, Doorenspleet ME, et al. In rheumatoid arthritis, synovitis at different inflammatory sites is dominated by shared but patient-specific T cell clones. *J Immunol*. 2018;201(2):417-422. https://doi.org/10.4049/jimmunol.1800421
74. Murray-Brown W, Wilsdon TD, Weedon H, et al. Nivolumab-induced synovitis is characterized by florid T cell infiltration and rapid resolution with synovial biopsy-guided therapy. *J ImmunoTher Cancer*. 2020;8:e000281. https://doi.org/10.1136/jitc-2019-000281
75. Chen S, Noordenbos T, Blijdorp I, et al. Histologic evidence that mast cells contribute to local tissue inflammation in peripheral spondyloarthritis by regulating interleukin-17A content. *Rheumatology (Oxford)*. 2019;58(4):617-627. https://doi.org/10.1093/rheumatology/key331
76. Baeten D, Peene I, Union A, et al. Specific presence of intracellular citrullinated proteins in rheumatoid arthritis synovium:

Relevance to antifilaggrin autoantibodies. *Arthritis Rheum*. 2001;44(10):2255-2262.
77. Lories RJU, Derese I, Ceuppens JL, Luyten FP. Bone morphogenetic proteins 2 and 6, expressed in arthritic synovium, are regulated by proinflammatory cytokines and differentially modulate fibroblast-like synoviocyte apoptosis. *Arthritis Rheum*. 2003;48(10):2807-2818. https://doi.org/10.1002/art.11389
78. Kane D, Roth J, Frosch M, Vogl T, Bresnihan B, FitzGerald O. Increased perivascular synovial membrane expression of myeloid-related proteins in psoriatic arthritis. *Arthritis Rheum*. 2003;48(6):1676-1685. https://doi.org/10.1002/art.10988
79. Bresnihan B, Gogarty M, FitzGerald O, Dayer J-M, Burger D. Apolipoprotein A-I infiltration in rheumatoid arthritis synovial tissue: a control mechanism of cytokine production? *Arthritis Res Ther*. 2004;6:R563-R566. https://doi.org/10.1186/ar1443
80. Roelofs MF, Weninck MH, Brentano F, et al. Type I interferons might form the link between Toll-like receptor (TLR) 3/7 and TLR4-mediated synovial inflammation in rheumatoid arthritis (RA). *Ann Rheum Dis*. 2009;68(9):1486-1493. https://doi.org/10.1136/ard.2007.086421
81. Guo Y, Walsh AM, Canavan M, et al. Immune checkpoint inhibitor PD-1 pathway is down-regulated in synovium at various stages of rheumatoid arthritis disease progression. *PLoS One*. 2018;13(2):e0192704. https://doi.org/10.1371/journal.pone.0192704
82. Canavan M, Marzaoil V, McGarry T, et al. Rheumatoid arthritis synovial microenvironment induces metabolic and functional adaptations in dendritic cells. *Clin Exp Immunol*. 2020;202(2):226-238. https://doi.org/10.1111/cei.13479
83. Tajik N, Frech M, Schulz O, et al. Targeting zonulin and intestinal epithelial barrier function to prevent onset of arthritis. *Nat Commun*. 2020;11(1):1995. https://doi.org/10.1038/s41467-020-15831-7
84. Cunnane G, FitzGerald O, Hummel KM, Gay RE, Gay S, Bresnihan B. Collagenase, cathepsin B and cathepsin L gene expression in the synovial membrane of patients with early inflammatory arthritis. *Rheumatology*. 1999;38(1):34-42. https://doi.org/10.1093/rheumatology/38.1.34
85. Cunnane G, Fitzgerald O, Hummel KM, et al. Synovial tissue protease gene expression and joint erosions in early rheumatoid arthritis. *Arthritis Rheum*. 2001;44(8):1744-1753.
86. Fraser A, Fearon U, Reece R, Emery P, Veale DJ. Matrix metalloproteinase 9, apoptosis, and vascular morphology in early arthritis. *Arthritis Rheum*. 2001;44(9):2024-2028.
87. Fearon U, Griosios K, Fraser A, Emery P, Veale DJ. Angiopoietins, growth factors, and vascular morphology in early arthritis. *J Rheumatol*. 2003;30(2):260-268.
88. Ali M, Veale DJ, Reece R, et al. Overexpression of transcripts containing LINE-1 in the synovia of patients with rheumatoid arthritis. *Ann Rheum Dis*. 2003;62(7):663-666. https://doi.org/10.1136/ard.62.7.663
89. Fraser A, Fearon U, Billinghurst RC, et al. Turnover of type II collagen and aggrecan in cartilage matrix at the onset of inflammatory arthritis in humans - Relationship to mediators of systemic and local inflammation. *Arthritis Rheum*. 2003;48(11):3085-3095. https://doi.org/10.1002/art.11331
90. Steenvoorden MMC, Tolboom TCA, van der Pluijm G, et al. Transition of healthy to diseased synovial tissue in rheumatoid arthritis is associated with gain of mesenchymal/fibrotic characteristics. *Arthritis Res Ther*. 2006;8(6):R165. https://doi.org/10.1186/ar2073
91. Walker JG, Ahern MJ, Coleman M, et al. Characterisation of a dendritic cell subset in synovial tissue which strongly expresses Jak/STAT transcription factors from patients with rheumatoid arthritis. *Ann Rheum Dis*. 2007;66(8):992-999. https://doi.org/10.1136/ard.2006.060822
92. Wenink MH, Brentano F, Abdollahi-Roodsaz S, et al. Type I interferons might form the link between Toll-like receptor (TLR) 3/7 and TLR4-mediated synovial inflammation in rheumatoid arthritis (RA). *Ann Rheum Dis*. 2009;68(9):1486-1493. https://doi.org/10.1136/ard.2007.086421
93. Rosu A, Ciurea P, Simionescu C, et al. The study of angiogenesis in early rheumatoid arthritis–clinical, immunohistochemical and immunological correlations. *J Med Life*. 2008;1(3):287-294.
94. Dubikov AI, Kalinichenko SG. Small molecules regulating apoptosis in the synovium of rheumatoid arthritis. *Scan J Rheum*. 2010;39(5):368-372. https://doi.org/10.3109/03009741003742771
95. de Hair MJH, Harty LC, Gerlag DM, Pitzalis C, Veale DJ, Tak PP. Synovial tissue analysis for the discovery of diagnostic and prognostic biomarkers in patients with early arthritis. *J Rheumatol*. 2011;38(9):2068-2072. https://doi.org/10.3899/jrheum.110426
96. Wang JJ, Lee AYS, Colella AD, Chataway TK, Gordon TP, Wechalekar MD. Proteomic mapping of rheumatoid factors in early rheumatoid arthritis. *Arthritis Rheumatol*. 2020;72(12):2159-2161. https://doi.org/10.1002/art.41446
97. Maijer KI, Noort AR, De Hair MJH, et al. Nuclear factor-κB-inducing kinase is expressed in synovial endothelial cells in patients with early arthritis and correlates with markers of inflammation: A prospective cohort study. *J Rheumatol*. 2015;42(9):1573-1581. https://doi.org/10.3899/jrheum.150245
98. De Hair MJH, Leclerc P, Newsum EC, et al. Expression of prostaglandin E_2 enzymes in the synovium of arthralgia patients at risk of developing rheumatoid arthritis and in early arthritis patients. *PLoS One*. 2015;10(7):e0133669. https://doi.org/10.1371/journal.pone.0133669
99. Maijer KI, Neumann E, Mäller-Ladner U, et al. Serum vaspin levels are associated with the development of clinically manifest arthritis in autoantibody-positive individuals. *PLoS One*. 2015;10(12):e0144932. https://doi.org/10.1371/journal.pone.0144932
100. De Hair MJH, Van De Sande MGH, Ranwahadoede R, et al. Features of the synovium of individuals at risk of developing rheumatoid arthritis : Implications for understanding preclinical rheumatoid arthritis. *Arthritis Rheum*. 2014;66(3):513-522. https://doi.org/10.1002/art.38273
101. Smith MD, Barg E, Weedon H, et al. Microarchitecture and protective mechanisms in synovial tissue from clinically and arthroscopically normal knee joints. *Ann Rheum Dis*. 2003;62(4):303-307. https://doi.org/10.1136/ard.62.4.303
102. Baeten D, De Keyser F, Demetter P, et al. Comparative study of the synovial histology in rheumatoid arthritis, spondyloarthropathy, and osteoarthritis: Influence of disease duration and activity. *Ann Rheum Dis*. 2000;59(12):945-953. https://doi.org/10.1136/ard.59.12.945
103. Smeets TJM, Barg EC, Kraan MC, Smith MD, Breedveld FC, Tak PP. Analysis of the cell infiltrate and expression of proinflammatory cytokines and matrix metalloproteinases in arthroscopic synovial biopsies: comparison with synovial samples from patients with end stage, destructive rheumatoid arthritis. *Ann Rheum Dis*. 2003;62:635-638. https://doi.org/10.1136/ard.62.7.635
104. Haynes DR. Osteoprotegerin expression in synovial tissue from patients with rheumatoid arthritis, spondyloarthropathies and osteoarthritis and normal controls. *Rheumatology*. 2003;42(1):123-134. https://doi.org/10.1093/rheumatology/keg047
105. Baeten D, Kruithof E, De Rycke L, et al. Diagnostic classification of spondylarthropathy and rheumatoid arthritis by synovial histopathology: A prospective study in 154 consecutive patients.

Arthritis Rheum. 2004;50(9):2931-2941. https://doi.org/10.1002/art.20476
106. Kane D, Jensen L, Grehan S, Whitehead AS, Bresnihan B, Fitzgerald O. Quantitation of metalloproteinase gene expression in rheumatoid and psoriatic arthritis synovial tissue distal and proximal to the cartilage-pannus junction. *J Rheumatol*. 2004;31(7):1274-1280.
107. Salvador G, Sanmarti R, Garcia-Peiró A, Rodríguez-Cros JR, Muñoz-Gómez J, Cañete JD. p53 expression in rheumatoid and psoriatic arthritis synovial tissue and association with joint damage. *Ann Rheum Dis*. 2005;4(2):183-187. https://doi.org/10.1136/ard.2004.024430
108. Tilleman K, Van Beneden K, Dhondt A, et al. Chronically inflamed synovium from spondyloarthropathy and rheumatoid arthritis investigated by protein expression profiling followed by tandem mass spectrometry. *Proteonomics*. 2005;5(8):2247-2257. https://doi.org/10.1002/pmic.200401109
109. Van Holten J, Smeets TJM, Blankert P, Tak P-P. Expression of interferon β in synovial tissue from patients with rheumatoid arthritis: Comparison with patients with osteoarthritis and reactive arthritis. *Ann Rheum Dis*. 2005;64(12):1780-1782. https://doi.org/10.1136/ard.2005.040477CD55
110. Chapuy-Regaud S, Sebbag M, Baeten D, et al. Fibrin deimination in synovial tissue is not specific for rheumatoid arthritis but commonly occurs during synovitides. *J Immunol*. 2005;174(8):5057-5064. https://doi.org/10.4049/jimmunol.174.8.5057
111. Nzeusseu Toukap A, Galante C, Theate I, et al. Identification of distinct gene expression profiles in the synovium of patients with systemic lupus erythematosus. *Arthritis Rheum*. 2007;56(5):1579-1588. https://doi.org/10.1002/art.22578
112. Van Oosterhout M, Bajema I, Levahrt EWN, Toes REM, Huizinga TWJ, Van Laar JM. Differences in synovial tissue infiltrates between anti–cyclic citrullinated peptide–positive rheumatoid arthritis and anti–cyclic citrullinated peptide–negative rheumatoid arthritis. *Arthritis Rheum*. 2008;58(1):53-60. https://doi.org/10.1002/art.23148
113. Cañete JD, Celis R, Noordenbos T, et al. Distinct synovial immunopathology in Behçet disease and psoriatic arthritis. *Arthritis Res Ther*. 2009;11(1):R17. https://doi.org/10.1186/ar2608
114. Gómez-Puerta JA, Celis R, Hernández MV, et al. Differences in synovial fluid cytokine levels but not in synovial tissue cell infiltrate between anti-citrullinated peptide/protein antibody-positive and -negative rheumatoid arthritis patients. *Arthritis Res Ther*. 2013;15(6):R182. https://doi.org/10.1186/ar4372
115. Celis R, Cuervo A, Ramírez J, Cañete JD. Psoriatic Synovitis: Singularity and Potential Clinical Implications. *Front Med*. 2019;6:1-7. https://doi.org/10.3389/fmed.2019.00014
116. Cuervo A, Celis R, Julià A, et al. Synovial Immunohistological Biomarkers of the Classification of Undifferentiated Arthritis Evolving to Rheumatoid or Psoriatic Arthritis. *Front Ed (Lausanne)*. 2021;8:1-8. https://doi.org/10.3389/fmed.2021.656667
117. Af Klint E, Grundtman C, Engström CAI, et al. Intraarticular glucocorticoid treatment reduces inflammation in synovial cell infiltrations more efficiently than in synovial blood vessels. *Arthritis Rheum*. 2005;52(12):3880-3889. https://doi.org/10.1002/art.21488
118. Kraan MC, Reece RJ, Barg E, et al. Modulation of inflammation and metalloproteinase expression in synovial tissue by leflunomide and methotrexate in patients with active rheumatoid arthritis: Findings in a prospective, randomized, double-blind, parallel-design clinical trial in thirty-nine patients at two centers. *Arthritis Rheum*. 2000;43(8):1820-1830.
119. Smith MD, Kraan MC, Slavotinek J, et al. Treatment-induced remission in rheumatoid arthritis patients is characterized by a reduction in macrophage content of synovial biopsies. *Rheumatology (Oxford)*. 2001;40(4):367-374.
120. Wong PKK, Cuello C, Bertouch J, et al. Effects of pulse methylprednisolone on macrophage chemotactic protein-1 and macrophage inflammatory protein-1α in rheumatoid synovium. *J Rheumatol*. 2001;28(12):2634-2636.
121. Bingham S, Veale D, Fearon U, et al. High-dose cyclophosphamide with stem cell rescue for severe rheumatoid arthritis: Short-term efficacy correlates with reduction of macroscopic and histologic synovitis. *Arthritis Rheum*. 2002;46(3):837-839. https://doi.org/10.1002/art.10093
122. Kraan MC, van Kuijk AWR, Dinant HJ, et al. Alefacept treatment in psoriatic arthritis: Reduction of the effector T cell population in peripheral blood and synovial tissue is associated with improvement of clinical signs of arthritis. *Arthritis Rheum*. 2002;46(10):2776-2784. https://doi.org/10.1093/rheumatology/40.4.367
123. Haringman JJ, Kraan MC, Smeets TJM, Zwinderman KH, Tak PP. Chemokine blockade and chronic inflammatory disease: Proof of concept in patients with rheumatoid arthritis. *Ann Rheum Dis*. 2003;62(8):715-721. https://doi.org/10.1136/ard.62.8.715
124. Smeets TJM, Kraan MC, Van Loon ME, Tal P-P. Tumor necrosis factor α blockade reduces the synovial cell infiltrate early after initiation of treatment, but apparently not by induction of apoptosis in synovial tissue. *Arthritis Rheum*. 2003;48(8):2155-2162. https://doi.org/10.1002/art.11098
125. Buch MH, Conaghan PG, Bingham SJ, Veale D, Emery P. True infliximab resistance in rheumatoid arthritis: A role for lymphotoxin α? *Ann Rheum Dis*. 2004;63(10):1344-1346. https://doi.org/10.1136/ard.2003.014878
126. Cañete JD, Pablos JL, Sanmarti MC, et al. Antiangiogenic effects of anti-tumor necrosis factor a therapy with infliximab in psoriatic arthritis. *Arthritis Rheum*. 2004;50(5):1636-1641. https://doi.org/10.1002/art.20181
127. Kane D, Gogarty M, O'Leary J, et al. Reduction of synovial sublining layer inflammation and proinflammatory cytokine expression in psoriatic arthritis treated with methotrexate. *Arthritis Rheum*. 2004;50(10):3286-3295. https://doi.org/10.1002/art.20518
128. Gerlag DM, Haringman JJ, Smeets TJM, et al. Effects of oral prednisolone on biomarkers in synovial tissue and clinical improvement in rheumatoid arthritis. *Arthritis Rheum*. 2004;50(12):3783-3791. https://doi.org/10.1002/art.20664
129. Haringman JJ, Gerlag DM, Zwinderman AH, et al. Synovial tissue macrophages: A sensitive biomarker for response to treatment in patients with rheumatoid arthritis. *Ann Rheum Dis*. 2005;64(6):834-838. https://doi.org/10.1136/ard.2004.029751
130. Van Holten J, Pavelka K, Vencovsky J, et al. A multicentre, randomised, double blind, placebo controlled phase II study of subcutaneous interferon beta-1a in the treatment of patients with active rheumatoid arthritis. *Ann Rheum Dis*. 2005;64(1):64-69. https://doi.org/10.1136/ard.2003.020347
131. Van Oosterhaut M, Levarht EWN, Sont JK, Huizinga TWJ, Toes REM, Van Laar JM. Clinical efficacy of infliximab plus methotrexate in DMARD naive and DMARD refractory rheumatoid arthritis is associated with decreased synovial expression of TNFα and IL18 but not CXCL12. *Ann Rheum Dis*. 2005;64(4):537-543. https://doi.org/10.1136/ard.2004.024927
132. Baeten D, Houbiers J, Kruithof E, et al. Synovial inflammation does not change in the absence of effective treatment: Implications for the use of synovial histopathology as biomarker in early phase clinical trials in rheumatoid arthritis. *Ann Rheum Dis*. 2006;65(8):990-997. https://doi.org/10.1136/ard.2005.047852
133. Ernestam S, Klint EA, Catrina AI, et al. Synovial expression of IL-15 in rheumatoid arthritis is not influenced by blockade of tumour necrosis factor. *Arthritis Res Ther*. 2006;8(1):R18.
134. Lindberg J, af Klint E, Catrina AL, et al. Effect of infliximab on mRNA expression profiles in synovial tissue of rheumatoid

arthritis patients. *Arthritis Res Ther*. 2006;8(6):R179. https://doi.org/10.1186/ar2090

135. Vergunst CE, Gerlag DM, Dinant H, et al. Blocking the receptor for C5a in patients with rheumatoid arthritis does not reduce synovial inflammation. *Rheumatology (Oxford)*. 2007;46(12):1773-1778.
136. Haynes D, Crotti T, Weedon H, et al. Modulation of RANKL and osteoprotegerin expression in synovial tissue from patients with rheumatoid arthritis in response to disease-modifying antirheumatic drug treatment and correlation with radiologic outcome. *Arthritis Care Res*. 2008;59(7):911-920. https://doi.org/10.1002/art.23818
137. Lebre MC, Jongbloed SL, Tas SW, Smeets TJM, McInnes IB, Tak PP. Rheumatoid arthritis synovium contains two subsets of CD83 ˉDC-LAMPˉ dendritic cells with distinct cytokine profiles. *Am J Clin Path*. 2008;172(4):940-950. https://doi.org/10.2353/ajpath.2008.070703
138. Lories RJU, Derese I, Luyten FP, de Vlam K. Activation of nuclear factor kappa B and mitogen activated protein kinases in psoriatic arthritis before and after etanercept treatment. *Clin Exp Rheumatol*. 2008;26(1):96-102.
139. Sundberg E, Grundtman C, af Klint E, et al. Systemic TNF blockade does not modulate synovial expression of the pro-inflammatory mediator HMGB1 in rheumatoid arthritis patients – a prospective clinical study. *Arthritis Res Ther*. 2008;10:R33. https://doi.org/10.1186/ar2387
140. Kavanaugh A, Rosengren S, Lee S, et al. Assessment of rituximab's immunomodulatory synovial effects (ARISE trial). 1: clinical and synovial biomarker results. *Ann Rheum Dis*. 2008;67(3):402-408. https://doi.org/10.1136/ard.2007.074229
141. Van Der Pouw Kraan TCM, Wijbrandts CA, Van Baarsen LG, et al. Responsiveness to anti-tumour necrosis factor α therapy is related to pre-treatment tissue inflammation levels in rheumatoid arthritis patients. *Ann Rheum Dis*. 2008;67(4):563-566. https://doi.org/10.1136/ard.2007.081950
142. Walsh CAE, Fearon U, FitzGerald O, Veale DJ, Bresnihan B. Decreased CD20 expression in rheumatoid arthritis synovium following 8 weeks of rituximab therapy. *Clin Exp Rheumatol*. 2008;26(4):656-658.
143. Rosengren S, Wei N, Kalunian KC, Zvaifler NJ, Kavanaugh A, Boyle D. Elevated autoantibody content in rheumatoid arthritis synovia with lymphoid aggregates and the effect of rituximab. *Arthritis Res Ther*. 2008;10:R105. https://doi.org/10.1186/ar2497
144. Vergunst CE, Gerlag DM, Lopantinskaya L, et al. Modulation of CCR2 in rheumatoid arthritis: A double-blind, randomized, placebo-controlled clinical trial. *Arthritis Rheum*. 2008;58(7):1931-1939. https://doi.org/10.1002/art.23591
145. Bresnihan B, Pontifex E, Thurlings RM, et al. Synovial tissue sublining CD68 expression is a biomarker of therapeutic response in rheumatoid arthritis clinical trials: Consistency across centers (Conference Paper). *J Rheumatol*. 2009;36(8):1800-1802. https://doi.org/10.3899/jrheum.090348
146. Van Kuijk AWR, Gerlag DM, Vos K, et al. A prospective, randomised, placebo-controlled study to identify biomarkers associated with active treatment in psoriatic arthritis: Effects of adalimumab treatment on synovial tissue. *Ann Rheum Dis*. 2009;68(8):1303-1309. https://doi.org/10.1136/ard.2008.091389
147. Lindberg J, Wijbrandts CA, van Baarsen LG, et al. The gene expression profile in the synovium as a predictor of the clinical response to infliximab treatment in rheumatoid arthritis. *PLoS One*. 2010;5(6):e11310. https://doi.org/10.1371/journal.pone.0011310
148. Roone T, Roux-Lombard P, Veale DJ, FitzGerald O, Dayer J-M, Bresnihan B. Synovial tissue and serum biomarkers of disease activity, therapeutic response and radiographic progression: analysis of a proof-of-concept randomised clinical trial of cytokine blockade. *Ann Rheum Dis*. 2010;69(4):706-714. https://doi.org/10.1136/ard.2009.108324
149. Smith MD, Weedon H, Papangelis V, et al. Apoptosis in the rheumatoid arthritis synovial membrane: modulation by disease-modifying anti-rheumatic drug treatment. *Rheumatology (Oxford)*. 2010;49(5):862-887. https://doi.org/10.1093/rheumatology/kep467
150. Cañete JD, Celis R, Hernández V, Pablos JL, Sanmartí R. Synovial immunopathologic changes associated with successful abatacept therapy in a case of severe refractory psoriatic arthritis. *Ann Rheum Dis*. 2011;69(5):935-936. https://doi.org/10.1136/ard.2009.113233
151. Pontifex EK, Gerlag DM, Gogarty M, et al. Change in CD3 positive T-cell expression in psoriatic arthritis synovium correlates with change in DAS28 and magnetic resonance imaging synovitis scores following initiation of biologic therapy - a single centre, open-label study. *Arthritis Res Ther*. 2011;13(1):R7. https://doi.org/10.1186/ar3228
152. Kennedy A, Teck Ng C, Cheng Chang T, et al. Tumor necrosis factor blocking therapy alters joint inflammation and hypoxia. *Arthritis Rheum*. 2011;63(4):923-932. https://doi.org/10.1002/art.30221
153. Revu S, Neregård P, af Klint E, Korotkova M, Catrina A. Synovial membrane immunohistology in early-untreated rheumatoid arthritis reveals high expression of catabolic bone markers that is modulated by methotrexate. *Arthritis Res Ther*. 2013;15(6):R205. https://doi.org/10.1186/ar4398
154. Neregard P, Krishnamurthy A, Revu S, Engström M, Af Klint E, Catrina AI. Etanercept decreases synovial expression of tumour necrosis factor-α and lymphotoxin-α in rheumatoid arthritis. *Scan J Rheum*. 2014;43(2):85-90. https://doi.org/10.3109/03009742.2013.834964
155. De Groof A, Ducreux J, Humby F, et al. Higher expression of TNFα-induced genes in the synovium of patients with early rheumatoid arthritis correlates with disease activity, and predicts absence of response to first line therapy. *Arthritis Res Ther*. 2016;18:19. https://doi.org/10.1186/s13075-016-0919-z
156. Fisher BA, Donatien P, Filer A, et al. Decrease in articular hypoxia and synovial blood flow at early time points following infliximab and etanercept treatment in rheumatoid arthritis. *Clin Exp Rheum*. 2016;34(6):1072-1076.
157. Szentpetery A, Heffernan E, Gogarty M, et al. Abatacept reduces synovial regulatory T-cell expression in patients with psoriatic arthritis. *Arthritis Res Ther*. 2017;19:158. https://doi.org/10.1186/s13075-017-1364-3
158. Walsh AM, Wechalekar MD, Guo Y, et al. Triple DMARD treatment in early rheumatoid arthritis modulates synovial T cell activation and plasmablast/plasma cell differentiation pathways. *PLoS One*. 2017;12(9):e0183928. https://doi.org/10.1371/journal.pone.0183928
159. Humby F, Durez P, Buch MH, et al. Rituximab versus tocilizumab in anti-TNF inadequate responder patients with rheumatoid arthritis (R4RA): 16-week outcomes of a stratified, biopsy-driven, multicentre, open-label, phase 4 randomised controlled trial. *Lancet*. 2021;397(10271):305-317. https://doi.org/10.1016/S0140-6736(20)32341-2
160. Peres LR, Marchitto RO, Pereira GS, Yoshino FS, Fernandes MDC, Matsumoto MH. Arthrotomy versus arthroscopy in the treatment of septic arthritis of the knee in adults: a randomized clinical trial. *Knee Surg Sports Traumatol Arthrosc*. 2016;24(10):3155-3162. https://doi.org/10.1007/s00167-015-3918-8
161. Brühlmann P, Michel BA, Altwegg M. Diagnosis and therapy monitoring of Whipple's arthritis by polymerase chain reaction. *Rheumatology (Oxford)*. 2000;39(12):1427-1428. https://doi.org/10.1093/rheumatology/39.12.1427

162. Schmid S, Bossart W, Michel BA, Brühlmann P. Outcome of patients with arthritis and parvovirus B19 DNA in synovial membranes. *Rheumatol Int*. 2007;27(8):747-751. https://doi.org/10.1007/s00296-007-0337-2
163. Frizziero L. Arthroscopic study of joint cartilage damage and synovial membrane in osteoarthritis of the knee | [Valutazione artroscopica della sofferenza cartilaginea e della membrana sinoviale nell'artrosi del ginocchio]. *Prog Reumatol*. 2003;4(2):193-202. [in Italian].
164. Loueuille D, Chary-Valckenaere I, Champignuelle J. Macroscopic and microscopic features of synovial membrane inflammation in the osteoarthritic knee: Correlating magnetic resonance imaging findings with disease severity. *Arthritis Rheum*. 2005;52(11):3492-3501. https://doi.org/10.1002/art.21373
165. Wei N, Johnson LL, Seeley BL, Delauter SK. Arthroscopically guided Jamshidi biopsy of articular cartilage: potential in the evaluation of disease-modifying osteoarthritis drugs (DMOADS). *J Appl Res*. 2003;3(3):329-338.
166. Ike R, Baskaran A, Chao J, et al. Prevalence of crystalline disease in knee osteoarthritis: experience from patients undergoing arthroscopic procedures. *J Clin Rheumatol*. 25(1):51-53.
167. Ayral X, Pickering EH, Woodworth TG. Synovitis: A potential predictive factor of structural progression of medial tibiofemoral knee osteoarthritis - Results of a 1 year longitudinal arthroscopic study in 422 patients. *Osteoarthritis Cartilage*. 2005;13(5):361-367.
168. Wu CW, Morrell MR, Heinze E, et al. Validation of American College of Rheumatology classification criteria for knee osteoarthritis using arthroscopically defined cartilage damage scores. *Semin Arthritis Rheum*. 2005;35(3):197-201. https://doi.org/10.1016/j.semarthrit.2005.06.0
169. Pasquali Ronchetti I, Guerra D, et al. Morphological analysis of knee synovial membrane biopsies from a randomized controlled clinical study comparing the effects of sodium hyaluronate (Hyalgan®) and methylprednisolone acetate (Depomedrol®) in osteoarthritis. *Rheumatology*. 2001;40(2):158-169. https://doi.org/10.1093/rheumatology/40.2.158
170. Frizziero L, Pasquali Ronchetti I. Intra-articular treatment of osteoarthritis of the knee: An arthroscopic and clinical comparison between sodium hyaluronate (500–730 kDa) and methylprednisolone acetate. *J Orthop Traumatol*. 2002;3(2):89-96.
171. Kuzmanova S, Andrees S, Atanassov A, Batalov A, Solakov P. Arthroscopic synovectomy, debridement and tidal lavage of the knee joint in osteoarthritis - long term results. *Revmatologiia*. 2004;12(4):42-47.
172. Ike RW, Kalunian KC, Arnold WJ (2021) Why not wash out the OA knee? *J Clin Rheumatol*. 27(2):43-45.
173. Li J, Huang Y, Song J, et al. Cartilage regeneration using arthroscopic flushing fluid-derived mesenchymal stem cells encapsulated in a one-step rapid cross-linked hydrogel. *Acta Biomater*. 2018;79:202-215. https://doi.org/10.1016/j.actbio.2018.08.029
174. Ostendorf B, Peters R, Dann P, et al. Magnetic resonance imaging and miniarthroscopy of metacarpophalangeal joints - Sensitive detection of morphologic changes in rheumatoid arthritis. *Arthritis Rheum*. 2001;44(11):2492-2502.
175. Coumbaras M, Le Hir P, Sautet A, Jomaah N, Tubiana JM, Arrivé L. Reactive synovitis: MRI features with arthroscopic correlation [Synovites réactionnelles: Aspects en IRM et corrélations arthroscopiques]. *J Radiologie*. 2005;86(5):481-486. https://doi.org/10.1016/S0221-0363(05)81393-9
176. Ostergaard M, Stoltenberg M, Lovgreen FU, et al. Contrast medium in power Doppler ultrasound for assessment of synovial vascularity: Comparison with arthroscopy. *J Rheumatol*. 2003;30(10):2170-2176.
177. Karim Z, Wakefield RJ, Quinn M, et al. Top of validation and reproducibility of ultrasonography in the detection of synovitis in the knee - A comparison with arthroscopy and clinical examination. *Arthritis Rheum*. 2004;50(2):387-394. https://doi.org/10.1002/art.20054
178. Komarova EB. Correlation between joint ultrasound data and clinical, laboratory and instrumental indices in patients with rheumatoid arthritis. *Sov Tehn Med*. 2017;9(1):92-96. https://doi.org/10.17691/stm2017.9.1.11
179. Najm A, Orr C, Gallagher L, et al. Knee joint synovitis: Study of correlations and diagnostic performances of ultrasonography compared with histopathology. *RMD Open*. 2018;4(1):e000616. https://doi.org/10.1136/rmdopen-2017-000616
180. De Lucia O, Paresce E, Murgo A, et al. Simultaneous ultrasonography and arthroscopy for the study of the joint environment: Indications and limits | [Ecografia e artroscopia in contemporanea per lo studio dell'ambiente articolare: Indicazioni e limiti]. *Reumatismo*. 2007;59(2):146-152. [in Italian].
181. Paresce E, De Lucia O, Bruschi E, Giacomelli L, Epis OM. Use of ultrasound-assisted arthroscopy in rheumatology: an experience in 11 patients with different rheumatic diseases. *Expert Opin Med Diagn*. 2013;7(4):309-312. https://doi.org/10.1517/17530059.2013.79413
182. Ng CT, Binieka M, Kennedy A, et al. Synovial tissue hypoxia and inflammation in vivo. *Ann Rheum Dis*. 2010;69(7):1389-1395. https://doi.org/10.1136/ard.2009.119776
183. Kennedy A, Ng CT, Binieka M, et al. Angiogenesis and blood vessel stability in inflammatory arthritis. *Arthritis Rheum*. 2010;62(3):711-721. https://doi.org/10.1002/art.27287
184. Binieka M, Fox E, Gao W, et al. Hypoxia induces mitochondrial mutagenesis and dysfunction in inflammatory arthritis. *Arthritis Rheum*. 2011;63(8):2172-2182. https://doi.org/10.1002/art.30395
185. Romão VC, Polido-Pereira J, Barros R, et al. Efficacy, Safety, and Sample Quality of Ultrasound-Guided Synovial Needle Biopsy in Clinical Practice and Research: A Prospective Observational Study. *Arthritis Care Res (Hoboken)*. 2020;72(10):1497-1505. https://doi.org/10.1002/acr.24050
186. Just SA, Humby F, Lindegaard H, et al. Patient-reported outcomes and safety in patients undergoing synovial biopsy: comparison of ultrasound-guided needle biopsy, ultrasound-guided portal and forceps and arthroscopic-guided synovial biopsy techniques in five centres across Europe. *RMD Open*. 2018;4(2):e000799. https://doi.org/10.1136/rmdopen-2018-000799
187. Humby F, Romão VC, Manzo A, et al. A Multicenter Retrospective Analysis Evaluating Performance of Synovial Biopsy Techniques in Patients With Inflammatory Arthritis. *Arthritis Rheumatol*. 2018;70(5):702-710. https://doi.org/10.1002/art.40433
188. van de Sande MGH, Gerlag DM, Lodde BM, et al. Evaluating antirheumatic treatments using synovial biopsy: a recommendation for standardisation to be used in clinical trials. *Ann Rheum Dis*. 2011;70(3):423-427. https://doi.org/10.1136/ard.2010.139550
189. Veale DJ. Synovial tissue biopsy research. *Front Med*. 2019;6:1-4. https://doi.org/10.3389/fmed.2019.00072
190. Sharma A, Baethge BA, Acebes JC, Lisse JR. Arthroscopic lavage treatment in rheumatoid arthritis of the knee. *J Rheumatol*. 1996;11:1872-1874.
191. Tanaka N, Sakahashi H, Hirose K, Ishima T, Ishii S. Volume of a wash and the other conditions for maximum therapeutic effect of arthroscopic lavage in rheumatoid knees. *Clin Rheumatol*. 2006;25(1):65-69. https://doi.org/10.1007/s10067-005-1143-4
192. van Oosterhout M, Sont JK, Bajema IM, Breedveld FC, van Laar JM. Comparison of efficacy of arthroscopic lavage plus administration of corticosteroids, arthroscopic lavage plus administration of placebo, and joint aspiration plus administration of corticosteroids in arthritis of the knee: A randomized controlled trial. *Arthritis Rheum*. 2006;55(6):964-970. https://doi.org/10.1002/art.22340

193. Johnsson H, Najm A. Synovial biopsies in clinical practice and research: current developments and perspectives. *Clin Rheumatol*. 2021;40:2593-2600. https://doi.org/10.1007/s10067-020-05512-7
194. Youssef PP, Kraan M, Breedveld F, et al. Quantitative microscopic analysis of inflammation in rheumatoid arthritis synovial membrane samples selected at arthroscopy compared with samples obtained blindly by needle biopsy. *Arthritis Rheum*. 1998;41(4):663-669.
195. Chaturvedi V, Thabah MM, Ravindran V, Kiely PD. Medical arthroscopy: A tool for diagnosis and research in rheumatology. *Int J Rheum Dis*. 2017;20:145-153. https://doi.org/10.1111/1756-185X.12951
196. McMillan S, Saini S, Alyea E, Ford E. Office-based needle arthroscopy: a standardized diagnostic approach to the knee. *Arthroscop Tech*. 2017;6(4):e1119-e1124. https://doi.org/10.1016/j.eats.2017.03.031
197. https://www.arthrex.com/knee/nano-arthroscopic-instruments
198. Zhang K, Crum RJ, Samuelsson K, Cadet E, Ayeni OR, de Sa D. In-office needle arthroscopy: a systematic review of indications and clinical utility. *Arthroscopy*. 2019;9:2709-2721.
199. Teppo LN, Järvinen N, Guyatt GH. Falling out of love with knee arthroscopy. *Nature Rev Rheumatol*. 2017;13(9):515-516. https://doi.org/10.1038/nrrheum.2017.106
200. Howard DH. Trends in the use of knee arthroscopy in adults. *JAMA Intern Med*. 2018;178(11):1557-1558. https://doi.org/10.1001/jamainternmed.2018.4175
201. Orr C, Vieira-Sousa E, Boyle DL, et al. Synovial tissue research: a state-of-the-art review. *Nat Rev Rheumatol*. 2017;13(8):463-475.
202. Alvand A, Auplish S, Gill H, Rees J. Innate arthroscopic skills in medical students and variation in learning curves. *J Bone Joint Surg Am*. 2011;93(19):1-9. https://doi.org/10.2106/JBJS.K.00199
203. Cychosz CC, Tofte JN, Johnson A, Carender C, Gao Y, Phisitkul P. Factors impacting initial arthroscopy performance and skill progression in novice trainees. *Iowa Orthop J*. 2019;39(1):7-13.
204. https://www.toltech.net/medical-simulators/products/arthrosim-arthroscopy-simulator
205. https://www.virtamed.com/en/medical-training-simulators/arthros/
206. https://simbionix.com/simulators/arthro-mentor/
207. Vaughan N, Dubey VN, Wainwright TW, Middleton RG. A review of virtual reality based training simulators for orthopaedic surgery. *Med Eng Phys*. 2016;38(2):59-71. https://doi.org/10.1016/j.medengphy.2015.11.021
208. Guze SB. Can the practice of medicine be fun for a lifetime? *JAMA*. 1979;241(19):2021-2023. https://doi.org/10.1001/jama.1979.03290450019016
209. Colaianni CA. Fun. *N Engl J Med*. 2020;382(5):402-403. https://doi.org/10.1056/NEJMp1909360
210. Traille C, Lauwery BR. Synovial tissue: turning the page to precision medicine in arthritis. *Front Med (Lausanne)*. 2019;6:46. https://doi.org/10.3389/fmed.2019.00046
211. Small A, Wechalekar MD. Synovial biopsies in inflammatory arthritis: precision medicine in rheumatoid arthritis. *Exp Rev Mol Diagnostic*. 2020;20(3):315-325. https://doi.org/10.1080/14737159.2020.1707671
212. Humby FC. Synovial tissue sampling in rheumatological practice-past developments and future perspectives. *Front Med (Lausanne)*. 2019;6:4. https://doi.org/10.3389/fmed.2019.00004
213. Orr CK, Vieira-Sousa E, Fonseca JE, Veale D. Arthroscopic Guided Synovial Biopsies. *Front Med*. 2021;7:1-7. https://doi.org/10.3389/fmed.2020.604582
214. Ouboussad L, Burska AN, Melville A. Synovial tissue heterogeneity in rheumatoid arthritis and changes with biologic and targeted synthetic therapies to inform stratified therapy [Mini Review]. *Front Med (Lausanne)*. 2019;6:45. https://doi.org/10.3389/fmed.2019.00045
215. Veale DJ, Fearon U. Next-generation analysis of synovial tissue architecture. *Nat Rev Rheumatol*. 2019;16(2):67-69. https://doi.org/10.1038/s41584-019-0357-9

How to cite this article: Ike RW, Kalunian KC. Will rheumatologists ever pick up the arthroscope again? *Int J Rheum Dis*. 2021;24:1235–1246. https://doi.org/10.1111/1756-185X.14184