

Craniofacial and airway morphology of individuals with oculoauriculovertebral spectrum

Craniofacial/airway morphology in OAVS

Julianna de Oliveira Lima Parizotto¹, Adriano Porto Peixoto², Karina Tostes Borsato¹, Jonas Bianchi^{1,3,4}, Siulan Vendramini Pittoli⁵, Cristiano Tonello⁶, João Roberto Gonçalves¹.

- 1- Department of Pediatric Dentistry, São Paulo State University (Unesp), School of Dentistry, Araraquara, São Paulo, Brazil.
- 2- Department of Orthodontics, University of São Paulo (USP), Hospital for Rehabilitation of Craniofacial Anomalies, Bauru, São Paulo, Brazil.
- 3- Department of Orthodontics Dentistry, University of Michigan, School of Dentistry, Ann Arbor, Michigan, United States.
- 4- Department of Orthodontics, University of the Pacific, Arthur A. Dugoni School of Dentistry, San Francisco, CA, United States.
- 5- Department of Clinical Genetics, University of São Paulo (USP), Hospital for Rehabilitation of Craniofacial Anomalies, Bauru, São Paulo, Brazil.
- 6- Hospital for Rehabilitation of Craniofacial Anomalies, University of São Paulo (USP), Bauru, São Paulo, Brazil.

This study was approved by the Ethical Review Board (3.486.247).

This is the author manuscript accepted for publication and has undergone full peer review but has not been through the copyediting, typesetting, pagination and proofreading process, which may lead to differences between this version and the [Version of Record](#). Please cite this article as [doi: 10.1111/OCR.12483](https://doi.org/10.1111/OCR.12483)

This article is protected by copyright. All rights reserved

Craniofacial and airway morphology of individuals with oculoauriculovertebral spectrum

ABSTRACT

Objectives: The objectives of this study were to characterize the craniofacial and airway morphology of Oculo-Auriculo-Vertebral Spectrum (OAVS) individuals using Computed Tomography (CT) exam.

Setting and Sample Population: This sample included individuals in the age range from 5 to 14 years, consisted of a group of 18 OAVS individuals (12 females, 6 males), Pruzansky-Kaban¹ IIB and III and by a paired Control group matched by age and sex for comparison of morphometric and airway variables.

Materials and Methods: Through the CT exam, airway analysis was performed using Dolphin Imaging® Software and seven morphometric measurements were performed to evaluate craniofacial morphology by Materialize Mimics® Software. To compare airway and morphometric variables, the Control group was used. The Student's t-test and Mann-Whitney U test were performed to compare differences between the groups.

Results: Statistically significant differences were showed between the Control and OAVS groups for the variables: total airway (TA) area, volume and MAA, RP area, RP volume, RP MAA, RG volume, RG MAA, total posterior height diff, Md incl and y-axis asymmetry. Pearson and Spearman's correlation showed mostly moderate correlations between Mand Occlusal canting AS with TA area and RP volume, Ax-Gn with TA area and Hy-C3 with TA volume.

Conclusions: The OAVS's airway was altered and worse than the control group. Our results suggest that the contralateral side of OAVS individuals is unaffected, however, longitudinal assessments are needed to confirm it. Hyoid bone and postural measures play an important role in interpreting airway features of individuals with and without OAVS.

Keywords: Goldenhar syndrome; CBCT; oculo-auriculo-vertebral spectrum; airway.

Author Manuscript

MRS. JULIANNA PARIZOTTO (Orcid ID : 0000-0001-5557-4333)

Article type : Original Article

Corresponding author mail id:- julianna.parizotto@unesp.br

Craniofacial and airway morphology of individuals with oculo-auriculo-vertebral spectrum

ABSTRACT

Objectives: The objectives of this study were to characterize the craniofacial and airway morphology of Oculo-Auriculo-Vertebral Spectrum (OAVS) individuals using Computed Tomography (CT) exam.

Setting and Sample Population: This sample included individuals in the age range from 5 to 14 years, consisted of a group of 18 OAVS individuals (12 females, 6 males), Pruzansky-Kaban¹ IIB and III and by a paired Control group matched by age and sex for comparison of morphometric and airway variables.

Materials and Methods: Through the CT exam, airway analysis was performed using Dolphin Imaging® Software and seven morphometric measurements were performed to evaluate craniofacial morphology by Materialize Mimics® Software. To compare airway and morphometric variables, the Control group was used. The Student's t-test and Mann-Whitney U test were performed to compare differences between the groups.

Results: Statistically significant differences were showed between the Control and OAVS groups for the variables: total airway (TA) area, volume and MAA, RP area, RP volume, RP MAA, RG volume, RG MAA, total posterior height diff, Md incl and y-axis asymmetry. Pearson and Spearman's correlation showed mostly moderate correlations

This article is protected by copyright. All rights reserved

between Mand Occlusal canting AS with TA area and RP volume, Ax-Gn with TA area and Hy-C3 with TA volume.

Conclusions: The OAVS's airway was altered and worse than the control group. Our results suggest that the contralateral side of OAVS individuals is unaffected, however, longitudinal assessments are needed to confirm it. Hyoid bone and postural measures play an important role in interpreting airway features of individuals with and without OAVS.

Keywords: Goldenhar syndrome; CBCT; oculo-auriculo-vertebral spectrum; airway.

Data Availability Statement

The data that support the findings of this study are available from the corresponding author upon request.

INTRODUCTION

The Oculo-Auriculo-Vertebral Spectrum (OAVS), (OMIM 144210), also known as Goldenhar Syndrome, is a disorder in craniofacial morphogenesis of heterogeneous etiology and variable phenotype, with prevalence ranging from 1: 3,500 to 1: 5,600 live births, according to the minimal criteria considered by authors^{2,3}. Craniofacial malformation is usually unilateral^{4,5}. This condition involves anomalies of structures derived from the 1st and 2nd pharyngeal arches, such as mandible, maxillary, and external and/or middle ear anomalies. Due to the wide clinical variability of the OAVS, other craniofacial anomalies such as epibulbar dermoid, ano-phththalmia/microphthalmia, eyelid, iris and retinal coloboma, and rarely atypical facial clefts were described in this condition, in addition to extracranial alterations: cardiac, renal and neurological⁴. To date, there were no diagnostic criteria established. Some authors consider the preauricular skin tags as a minimal clinical signs for the diagnoses^{4,5}. Considering the etiology, most cases are sporadic, however familial cases with autosomal dominant

inheritance as far as autosomal recessive inheritance has been described⁶. Several chromosomal anomalies are described in cases with a clinical diagnosis of OAVS; however, there are no typical chromosomal anomalies for this condition^{2,7}. The same teratogens have been associated with OAVS, mainly with the exposure to misoprostol and to isotretinoin⁸.

Individuals with OAVS may have an increased prevalence and severity of airway obstruction due to their anatomical features such as mandibular hypoplasia and glossoptosis. Obstructive Sleep Apnea (OSA) and hypoventilation are more recurrent in these individuals compared to the general population, as well as the need for tracheostomy.^{9,10} The Cone Beam Computed Tomography (CBCT) exam allows the evaluation of the upper airway, assisting in the diagnosis of possible obstructions^{11,12}.

Volumetric CBCT reconstructions are extremely important for the diagnosis of these cases, where the clinician can observe more anatomical details, without distortion and from different angles, assessing possible anatomical deviations with more reliability¹³. The literature highlights the need for research on OAVS with larger and homogeneous samples. The assessment of craniofacial morphology in the OAVS by CBCT allows a better analysis of skeletal asymmetry without overlapping structures.

Most of the scientific evidence is limited to case reports, intubation difficulties and anesthetic protocols¹⁴. There are also numerous case reports regarding different treatments for these patients, such as Temporomandibular Joint (TMJ) rehabilitation and osteogenic distraction^{15,16} and, studies with larger sample have addressed only phenotypic descriptions or genetics^{5,7}. In addition, those studies are limited by including individuals with unilateral, bilateral, mild, moderate and severe involvement in the same sample. To our knowledge, there is no research on the three-dimensional assessment of airway and craniofacial morphology of OAVS individuals, comparing with a Control group. Thus, the aim of this study was to evaluate the airway and craniofacial morphology of patients with OAVS using Computed Tomography (CT) exam.

MATERIAL AND METHODS

This sample included individuals in the age range from five to 14 years. The inclusion criteria were as following: having a confirmed diagnosis of OAVS, performed previous CT exam with the full head field of view for medical/dental purposes, presenting mandibular anomalies without previous orthodontic or surgical treatment. This article is protected by copyright. All rights reserved

Exclusion criteria were as following: undefined diagnosis of OAVS; individuals with absence of CT exam or one of inadequate quality; and presence of orthodontic treatment. The selected individuals were re-evaluated by the team of clinical genetics of the *Hospital de Reabilitação de Anomalias Craniofaciais – Universidade de São Paulo* (HRAC – USP) to confirm the diagnosis through genetic assessment and to assess the presence of other associated anomalies.

The sample consisted of a group of 18 OAVS individuals, retrospectively selected from the HRAC – USP, classified as Pruzansky-Kaban¹ IIB and III, and by a paired Control group matched by age and sex for comparison of morphometric and airway variables. The Control group was retrospectively selected from a database containing de-identified CT exams of patients from different centers in the Dental and Craniofacial Bionetwork for Image Analysis of the University of Michigan, following the ALADA (as low as diagnostically acceptable) principles¹⁷. The inclusion criteria were as following: the absence of skeletal deformities or syndromes and previous CT for medical/dental purposes; and SNA and SNB angle measurements within the normal parameters (SNA: $82^\circ (\pm 2^\circ)$; SNA: $80^\circ (\pm 2^\circ)$).

Tomographic exams

The CBCT exams were performed on the i-CAT® tomograph (Imaging Sciences, Hartfield PA, USA), according to the following protocol 120kVp, 8mA and examination time of 8.9 seconds with extended-field-of-view scanning technique. The subjects were positioned in the device and the head position was standardized in which the Camper's plane was perpendicular to the median sagittal plane and parallel to the ground. The dimensions of the voxel were from 0.30 mm^3 to 0.40 mm^3 . The images were transformed into Digital Imaging and Communications in Medicine (DICOM) files and exported to specific software (*Dolphin Imaging®*). The CT was performed in only two patients instead of CBCT.

Spatial Orientation of the Skull

The DICOM files were imported into the Dolphin Imaging® (Dolphin Imaging and Management Solutions, Chatsworth, Calif), as well as the three-dimensional image of the patient's head was positioned in a common orientation¹⁸ using the head positioning tool. Regarding the coronal view, the median sagittal plane is oriented according to the patient's midline, considering the alignment of the *crista galli* and anterior nasal spine. In sagittal view, the conventional Frankfurt Plane is unsuitable for these patients as they

may have altered craniometric points (Porium (Po)). So, for this study, it was used a Frankfurt Plane from the SN line, which according to the literature is SN - 7 degrees. Still in a sagittal view, it is certified that there is no rotation of the patient's head, which could compromise the marking of other planes.

Cephalometric analysis:

A lateral telerradiograph was created using the "Build X-rays" tool of the Dolphin software. Cephalometric analysis consists of two linear measurements and seven angular measurements. The linear measurements are: MP-HY, distance between the mandibular plane and the hyoid bone; and HY-C3, distance between Hyoid Bone and C3 vertebra (C3). The angular measurements are: SNA, angle formed between the point A (A) and the Sella-Nasion (SN) line; SNB, angle formed between point B (B) and the SN line; OPSN, angle formed between the Occlusal Plane (OP) and the SN line, OPT-SN, angle formed between the tangent line at C2 and the SN line; CVT-SN, angle formed by the intersection of the tangent line to the Cervical Vertebra Tangent (CVT) and the SN line, and MP-SN, angle formed between the Mandibular Plane (MP) and the SN line¹⁹.

Airway analysis:

An airway analysis tool from the Dolphin Imaging® program was used to determine the variables, such as: volume; area; and minimal axial area of retropalatal and retroglossal airway. In sagittal view, the upper boundary was determined by a line parallel to the tangent of Frankfurt Plane that is tangent to the Basion (Ba) point and lower boundary by a tangent line to the tip of the epiglottis on a plane parallel to the Frankfurt Plane. The lateral and posterior limits consist of the margins of the airway wall and the anterior limit, of soft palate, tongue base and anterior wall of the extremity (Fig. 1A). After delimitation of the upper airway, the "threshold and seed" points were delimited to include the largest possible volume. The software automatically calculated the volume, a minimum axial area of the upper airway (Fig. 1B)²⁰.

Delimitation and calculation of the Minimum Retropalatal and Retroglossal Axial Area

- Limits of the retropalatal area:
 - Upper Limit - the line parallel to the tangent of Frankfurt Plane to the Basion (Ba) point;
 - Anterior and posterior soft palate boundaries and pharyngeal wall margins, respectively;

- Lower Limit: line formed by the lower tip of the uvula parallel to the Frankfurt Plane. Minimal retropalatal axial area: shorter distance between soft palate and Posterior Pharyngeal Wall (PPW).
- Limits of the retroglossal area:
 - Upper limit: lower limit of the retropalatal space;
 - Anterior and posterior limits: the base of the tongue and the inferior pharyngeal wall, respectively;
 - Lower limit: line tangent to the tip of the epiglottis and parallel to the Frankfurt Plane. Minimal retroglossal axial area: the shortest distance between the base of the tongue and the PPW (Figure 2)²¹.

After delimitation of the retropalatal and retroglossal areas, the threshold and seed points were determined to include the largest possible volume. The software automatically calculated the minimum axial area of both regions.

Craniofacial morphology evaluation

The DICOM files with the previously orientation of the head in the Dolphin Imaging® program were exported to Materialize Mimics® Software. For three-dimensional evaluation, using the "Segmentation" tab, the best thresholding was chosen for surface model segmentation (.stl). Once segmentation was done, seven measurements were recommended by Stoustrup et al.²², adding a Y-axis measure. There were three measures of linear or angular differences between the sides (Fig.3 A – C), three of plane angles (Fig.3 D – F), one of the mean ratio of Anterior Facial Height (AFH) and Posterior Facial Height (PFH) (Fig.3 G) and one of the Y-axis asymmetry (Fig.3 H).

Regarding the differences between the sides, the Affected Side (AS) was defined as the side with the lowest total posterior height of the mandible. Measurements for the AS were subtracted from the contralateral (larger) side (Unaffected Side – US). The following morphometric variables were analyzed: A- Total posterior mandibular height; B- Maxillary occlusal canting; C- Mandibular occlusal canting; D- Mandibular axial angle; E- Mandibular inclination; F- Mandibular occlusal inclination; G- Anterior/posterior lower face height ratio; and H- Y-axis asymmetry.

Statistical Analysis

To assess the reliability of the measurement method, the intraclass correlation coefficient was used. Measurements were performed in 50% of the sample, randomly selected at two different times, with a one-week interval. Shapiro-Wilk test was performed to assess the normal distribution of the variables. For comparison between

the Control and OAVS groups, the Student *t*-test was used for the variables that presented normal distribution, and the nonparametric Mann-Whitney U test for those without normal distribution. Pearson and Spearman coefficients were used to evaluate correlations among the variables and groups.

RESULTS

Regarding the descriptive and demographic distribution of the sample, the mean age for the Control Group was 9.43 years and for the OAVS Group was 9.63. The groups were paired by age and sex, so they had the same number of male ($n=6$) and female ($n=12$) individuals.

The result of the Intraclass Correlation Coefficient (ICC) was excellent, greater than or equal to 0.922 for all variables, except for RP area that was 0.811.

For comparison between the Control and OAVS groups, the Student *t*-test was used for the variables that presented normal distribution, and the nonparametric Mann-Whitney U test for those without normal distribution. In one patient from the OAVS group, the variables MP-Hy, Hy-C3, CVT-SN and OPT-SN could not be measured owing to the limited field of view of the CT. The same occurred for the CVT-SN and OPT-SN variables for three patients in the control group, and then variables were considered missing data.

The following measurements were compared between the right and left sides by the *t*-test as following: total posterior height; Mx occlusal canting; Md occlusal canting md; and Ax-Go of the Control group (table 1). As there was no statistically significant difference among them, regarding the comparison between the Control and OAVS groups, the mean values from the right and left sides were used.

Table 2 shows the comparison between the Control and OAVS groups for morphometric measurements and most variables had a statistically significant difference, except for the US variables, as well as for the cephalometric variables, such as: MP-Hy; Hy-C3; and CVT-SN.

In the comparison between Control and OAVS groups for airway measurements, Table 3 shows that all variables were statistically significant except for the RG Area (retroglossal area) variable.

A post-hoc test was performed to analyze the test power for the main variables of the study and the statistical power for each of them are: Total Airway Area (60% power), Total Airway Volume (92%), Total MMA (85%), RP Area (62%), RP volume (95%), RP

MAA (81%), RG volume (49%), RG MAA (93%), Total Posterior Height Diff. (100%), Md Incl (100%), Y-axis ass (100%), MP-SN (99%) and OPT-SN (55%).

For comparisons within each group, the *t*-test showed that the AS and US in the OAVS group was statistically significant different for all bilateral variables (Total Posterior height, Max occlusal canting, Md occlusal canting and Ax-Go).

Pearson and Spearman coefficients were used to evaluate correlations among the variables and groups. The correlation between morphometric and airway measurements in the Control group were moderate between the variables as following: Total posterior height and RP volume; Max occlusal canting and RG volume; Md occlusal canting and RG volume; Md Axial Ang and RG MAA; Md Axial Ang and Total MAA; Ax-Gn and RG volume; HY-C3 and Total MAA, RP volume; RP MAA and RG volume; CVT-SN and RG MAA; and OPT-SN and RG MAA. In addition, it could be noted strong correlations between the variables, such as: Max occlusal canting and Total airway volume; Max occlusal canting and RP volume; Md occlusal canting and Total airway volume; Md occlusal canting and RP volume; Ax-Gn and Total airway volume; Ax-Gn and RP volume; HY-C3 and RG MAA (table 1).

The correlation between morphometric and airway measurements in the OAVS group were moderate between the variables as following: Total posterior height Diff. and RG Area; Max occlusal canting AS and RP area; Md occlusal canting AS and Total airway volume, RP area, RP volume; Md occlusal canting US and RP Area; Ax-Gn and Total airway volume, RP area, RP volume. The other correlations were considered weak.

DISCUSSION

The OAVS individuals can be classified as 'unilateral' when the craniofacial involvement is present only on one side, or 'bilateral', when both sides of the cranium are involved (in different magnitudes), even if it is only found a preauricular skin tag among individuals. However, most of the literature does not separate the sample according to the severity of the mandibular deformity^{23,24}. It is also common to present the AS and US for the characterization of these individuals²⁴ and use the US as a control for measurement comparison. However, it was unsure, until now, whether the contralateral side of unilateral OAVS was in fact unaffected or just less affected, as there was no previous study with this statement. In this study, the OAVS group was evaluated by a clinical genetic team and consisted exclusively of unilateral Pruzansky IIB and III individuals. When comparing the morphometric measurements of the Control group with the OAVS group (table 2), it was observed that all measurements of the US

had no significant difference when compared with the Control group. From this result, it is stated that the contralateral side of unilateral OAVS individuals is actually unaffected and may be compared with individual without skeletal deformities. Thus, it could be possible to derive this observation since a Control group paired by age and sex was used.

For individuals without syndromes, the airway may vary for different facial patterns. El H. and Palomo JM.²⁵ stated that the mandibular position related to the cranial base affects the volume of the oropharynx airway, but Di Carlo et al.²⁶ found no statistical significant relationships between dimension and morphology of upper airways and skeletal malocclusion. In table 2, the SNB variable for the OAVS individuals was statistically lower than the Control group. However, it's not just the volume that showed different. All airway variables, except the RG Area, were significantly different between the groups, with the lowest values for the OAVS group (table 3). Changes in the airway of these individuals has been reported before^{10,27}; however, this is the first study to compare tridimensional airway differences of the OAVS group with a Control group matched by age and sex, as well as providing accurate information about these differences. The largest differences were observed in RP volume and RG MAA. Future studies should investigate these differences between individual's airway and use of Computational Fluid Dynamics (CFD)²⁸ in order to offer even more valuable information.

Despite airway analysis method with Dolphin Imaging® software is being widely used in the literature, caution is needed in the interpretation of data. Our group recently²⁹ compared the pharyngeal airway measurements of two CBCT scans of each patient of the sample with a time interval of 4-6 months without intervention (test-retest study). Indeed, we showed that different CBCT scans with the same examination and patient positioning protocol could produce distinct measurements. Therefore, it is essential to interpret the results and know when the differences may be influenced by random errors inherited from the method. The average difference regarding total oropharyngeal volume between the Control group and the OAVS group in this study was 3812.72mm³, that is, values beyond the random method error reported by Ryan et al.²⁹ (2851.64 mm³) and therefore, real differences were presented. As the variation between the average difference of this study and the random method error reported²⁹ is of approximately 1000 mm³, which is smaller than the standard deviation, clinical relevance should be interpreted with caution. A polysomnography exam could improve the airway analysis, but this data was not available for the individuals of this study.

The correlations between the morphometric and airway variables in both groups were calculated to investigate if there were any morphometric variables that had greater influence on the individuals' airway. In the Control group, among the moderate and strong correlations³⁰, the most clinically significant were as following: HY-C3 and MAA RG; CVT-SN and MAA RG; OPT-SN; and MAA-RG (Supplementary file, table 4). Regarding the correlation HY-C3 and MAA RG, our result corroborates with previous research that reported a positive correlation between hyoid bone position and airway³¹. The CVT-SN and OPT-SN measurements described by Solow et al.¹⁹, are postural variables and characterize the cervical curvature and the position of the head in relation to the column, respectively. The positive correlation of these variables with the minimal retroglossal area is consistent with anesthesiology studies, such as: head posture has an essential effect on airway collapsibility; and collapse site³². Head extension improves airway volume, permeability and decreases airway resistance³³.

For the OAVS group, the correlations ranged mostly from moderate to low³⁰, with only one strong correlation Ax-Gn- Total airway area($r=0.7$) (Supplementary file, table 5). This finding is in opposition to previous studies that showed a negative relation between anterior facial height and airway area and volume³⁴.

There is already a consensus that OAVS patients need tracheostomy more frequently, suggesting alterations in their airways^{9,10}. This hypothesis was confirmed in this study. The negative correlation of the difference in mandibular posterior height of the AS and US with the airway shows that the bigger the imbalance between the sides is, the smaller the retroglossal area will be. In addition, the Y axis asymmetry was negatively correlated with the RP MAA, so, it may be stated that the greater the mandible deviation from the sagittal plane is, the smaller the retropalatal minimal axial area will be.

Hyoid bone is an important factor to be evaluated with the airway,³¹ and the positive correlations found between the variable Hy-C3 and the volume, area and minimum total axial area in both Control and OAVS group reinforce this statement. It is suggested that values of hyoid cephalometrics are valuable for predicting retroglossal obstruction severity³⁵ and changes in the hyoid bone may lead to changes in the airway. Therefore, it is important to study these two variables and their associations³¹. The change in the hyoid bone position is directly related to the activity of the supra and infrahyoid muscles, which are also responsible for deglutition. Indeed, it is noted that the OAVS individuals have skeletal malformations that may affect the hyoid bone and

muscles as well as having their origin in the mandible and styloid process. Thus, changes in hyoid bone-related measurements may be expected in OAVS patients.

The vertebral anomaly, present in the triad of the name OAVS, is one of the most important characteristics that compose the phenotype of these individuals, since these alterations can develop cervical instability³⁶. The cause between the malformation of craniofacial structures and cervical vertebrae is still uncertain, but signaling during early embryogenesis among notochord, para-axial mesoderm, neural tube and neural crest is believed to be important for this connection³⁷. The most common types of vertebral malformations in OAVS individuals are: fusion of cervical vertebrae; presence of hemivertebra or hypoplasia of cervical, thoracic or lumbar vertebrae^{5,38}. Differently from the Control group's results (Supplementary file, table 4), the OAVS group did not show a correlation of cervical curvature and head position related to the column variables (OPT-SN and CVT-SN) with the airway (Supplementary file, table 5). This result demonstrates that for an individual without OAVS, an increase in the cervical curvature angle or a larger head extension improves the airway. However, for the OAVS individuals, this characteristic is not observed. One of the probable answers is that this head extension movement is difficult for the OAVS patients due to their vertebral anomalies being difficult to improve airway patency by extending head posture. In addition, the previous research³⁹ demonstrated that 46.2% of the individuals with OSA of this study, it could be noticed a Fused Cervical Vertebrae (FCV). This corroborates, even more, with the importance of studying postural relations associated with the airway features.

A limitation of the present study consisted of three individuals from the OAVS group that had multi-slice CT scans in supine position instead of CBCT scans in sitting position. That might have influenced head extension and curvature⁴⁰, although the variability of these measurements was similar between the two groups. Another limitation of this study was the absence of information about the specific clinical purpose of the CBCTs from the Control Group, the only information was medical/dental indication. The lack of information about the imaging centers that performed the tomography exams was also a limitation. We have standardized the data for having the same voxel size, however, other parameters could not be assessed, such as brand of the CBCT machine, kV and mA used, scanning time and others.

Further studies with larger and homogeneous samples are encouraged to understand OAVS individuals and also provide more individualized and accurate

interdisciplinary treatment. In addition, adding polysomnography and dynamic x-ray of the cervical column exams as variables may offer even more valuable insights.

CONCLUSION

In conclusion, the OAVS's airway was altered and worse than the control group. Our results suggest that the contralateral side of OAVS individuals is unaffected, however, longitudinal assessments are needed to confirm it. Hyoid bone and postural measures play an important role in interpreting airway features of individuals with and without OAVS.

Author Contributions

J.P. designed the study, collected the data, performed the measurements and wrote the paper; A.P.P contributed to the design and implementation of the research, revised the paper; K.T.B. assisted with the measurements and data collection; J.B. collected data and revised the paper; S.V.P. collected data and contributed to the analysis of the results; C.T. collected data, contributed to the analysis of the results and revised the paper ; J.R.G. contributed to the design and implementation of the research, to the analysis of the results, supervised and revised the paper.

Conflict of Interest Statement

The authors of this article certify that they have NO affiliations with or involvement in any organization or entity with any financial interest or non-financial interest in the subject matter or materials discussed in this manuscript.

REFERENCES

1. Kaban LB, Padwa BL, Mulliken JB. Surgical correction of mandibular hypoplasia in hemifacial microsomia: the case for treatment in early childhood. *J Oral Maxillofac Surg.* 1998;56(5):628–38.
2. Beleza-Meireles A, Clayton-Smith J, Saraiva JM, Tassabehji M. Oculo-auriculo-vertebral spectrum: a review of the literature and genetic update. *J Med Genet.* 2014;51(10):635–45.
3. Gorli RJ, Jue KL, Jacobsen U, Goldschmidt E. OCULO-AURICULO-VERTEBRAL

- DYSPLASIA. *J Pediatr*. 1963;63:991–9.
4. Cohen MM, Rollnick BR, Kaye CI. Oculoauriculovertebral spectrum: an updated critique. *Cleft Palate J*. 1989;26(4):276–86.
 5. Rollnick BR, Kaye CI, Nagatoshi K, Hauck W, Martin AO, Reynolds JF. Oculoauriculovertebral dysplasia and variants: phenotypic characteristics of 294 patients. *Am J Med Genet*. 1987;26(2):361–75.
 6. Vendramini-Pittoli S, Kokitsu-Nakata NM. Oculoauriculovertebral spectrum: Report of nine familial cases with evidence of autosomal dominant inheritance and review of the literature. *Clin Dysmorphol*. 2009;18(2):67–77.
 7. Beleza-Meireles A, Hart R, Clayton-Smith J, Oliveira R, Reis CF, Venâncio M, et al. Oculo-auriculo-vertebral spectrum: Clinical and molecular analysis of 51 patients. *Eur J Med Genet*. 2015;58(9):455–65.
 8. Vendramini-Pittoli S, Guion-Almeida ML, Richieri-Costa A, Santos JM, Kokitsu-Nakata NM. Clinical findings in children with congenital anomalies and misoprostol intrauterine exposure: A study of 38 cases. *J Pediatr Genet*. 2013;2(4):173–80.
 9. Baugh AD, Wooten W, Chapman B, Drake AF, Vaughn B V. Sleep characteristics in Goldenhar Syndrome. *Int J Pediatr Otorhinolaryngol*. 2015;79(3):356–8.
 10. Sculerati N, Gottlieb MD, Zimble MS, Chibbaro PD, McCarthy JG. Airway management in children with major craniofacial anomalies. *Laryngoscope*. 1998;108(12):1806–12.
 11. Lenza MG, Lenza MMDO, Dalstra M, Melsen B, Cattaneo PM. An analysis of different approaches to the assessment of upper airway morphology: a CBCT study. *Orthod Craniofac Res*. 2010;13(2):96–105.
 12. Guijarro-Martínez R, Swennen GRJ. Three-dimensional cone beam computed tomography definition of the anatomical subregions of the upper airway: A validation study. *Int J Oral Maxillofac Surg*. 2013;42(9):1140–9.
 13. Harrell WE, Hatcher DC, Bolt RL. In search of anatomic truth: 3-Dimensional digital modeling and the future of orthodontics. *Am J Orthod Dentofac Orthop*. 2002;122(3):325–30.
 14. Sun Y-H, Zhu B, Ji B-Y, Zhang X-H. Airway Management in a Child with Goldenhar Syndrome. *Chin Med J (Engl)*. 2017;130(23):2881.
 15. Sahni N, Bhatia N. Successful management of difficult airway in an adult patient of Goldenhar syndrome. *Saudi J Anaesth*. 2014;8(Suppl 1):S98–100.
 16. Farzad P. Reconstruction of nongrowing hemifacial microsomia patient with

- custom-made unilateral temporomandibular joint total joint prosthesis and orthognathic surgery. *J Oral Biol Craniofacial Res.* 2017;7(1):62–6.
17. Jaju PP, Jaju SP. Cone-beam computed tomography: Time to move from ALARA to ALADA. *Imaging Sci Dent.* 2015;45(4):263–5.
 18. Ruellas ACDO, Tonello C, Gomes LR, Yatabe MS, MacRon L, Lopinto J, et al. Common 3-dimensional coordinate system for assessment of directional changes. *Am J Orthod Dentofac Orthop.* 2016;149(5):645–56.
 19. Solow B, Tallgren A. Head posture and craniofacial morphology. *Am J Phys Anthropol.* 1976;44(3):417–35.
 20. Haskell JA, McCrillis J, Haskell BS, Scheetz JP, Scarfe WC, Farman AG. Effects of Mandibular Advancement Device (MAD) on Airway Dimensions Assessed With Cone-Beam Computed Tomography. *Semin Orthod.* 2009;15(2):132–58.
 21. Goncalves JR, Buschang PH, Goncalves DG, Wolford LM. Postsurgical Stability of Oropharyngeal Airway Changes Following Counter-Clockwise Maxillo-Mandibular Advancement Surgery. *J Oral Maxillofac Surg.* 2006;64(5):755–62.
 22. Stoustrup P, Iversen CK, Kristensen KD, Resnick M, Verna C, Erik S, et al. Assessment of dentofacial growth deviation in juvenile idiopathic arthritis: Reliability and validity of three-dimensional morphometric measures. *PLoS ONE* 2018;13(3):1–18.
 23. Manara R, Schifano G, Brotto D, Mardari R, Ghiselli S, Gerunda A, et al. Facial asymmetry quantitative evaluation in oculoauriculovertebral spectrum. *Clin Oral Invest.* 2016;20:219–225.
 24. Nardi C, De Falco L, Selvi V, Lorini C, Calistri L, Colagrande S. Role of cone-beam computed tomography with a large field of view in Goldenhar syndrome. *Am J Orthod Dentofac Orthop.* 2018;153(2):269–77.
 25. El H, Palomo JM. Airway volume for different dentofacial skeletal patterns. *Am J Orthod Dentofac Orthop.* 2011;139(6):e511–21.
 26. Di Carlo G, Polimeni A, Melsen B, Cattaneo PM. The relationship between upper airways and craniofacial morphology studied in 3D. A CBCT study. *Orthod Craniofacial Res.* 2015;18(1):1–11.
 27. Molins G, Valls A, Guijarro R, Hernández-Alfaro F. Mandibular hypoplasia and narrow airway in goldenhar syndrome: Anticipation of difficult intubation with cone-beam computed tomography. *J Clin Anesth.* 2016;34:1–2.
 28. Leong SC, Chen XB, Lee HP, Wang DY. A review of the implications of computational fluid dynamic studies on nasal airflow and physiology. *Rhinology.*

- 2010 Jun;48(2):139-45.
29. Ryan DP, Bianchi J, Ignacio J, Wolford LM, Gonçalves JR. Cone-beam computed tomography airway measurements: Can we trust them? *Am J Orthod Dentofac Orthop.* 2019;156(1):53–60.
 30. Hinkle, D. E., Wiersma, W., & Jurs SG (2003). *Applied statistics for the behavioral sciences.* 6th ed. Boston, Mass: Houghton Mifflin; 2003.
 31. Jiang Y. Correlation between hyoid bone position and airway dimensions in Chinese adolescents by cone beam computed tomography analysis. *Int J Oral Maxillofac Surg.* 2016;45(7):914-21.
 32. Walsh JH, Maddison KJ, Platt PR, Hillman DR, Eastwood PR. Influence of Head Extension, Flexion, and Rotation on Collapsibility of the Passive Upper Airway. *Sleep.* 2008 Oct;31(10):1440-7
 33. Wei Wei HS, Chen L, Qi Y, Qiu Y, Li S. Air flow behavior changes in upper airway caused by different head and neck positions : Comparison by computational fluid dynamics. *Journal of Biomechanics.* 2017;52(8):89–94.
 34. Joseph AA, Elbaum J, Cisneros GJ, Eisig SB. A cephalometric comparative study of the soft tissue airway dimensions in persons with hyperdivergent and normodivergent facial patterns. *J Oral Maxillofac Surg.* 1998;56(2):135–9.
 35. Hei RY, Qin J, Li SH. Predictive value of hyoid cephalometrics for retroglossal obstruction in patients with obstructive sleep apnoea hypopnea syndrome. *J Laryngol Otol.* 2019;133(2):119–24.
 36. Senosian EA, Téllez-zenteno JF, García-Ramos G, Corona R. Síndrome de Klippel-Feil. Imágenes por tomografía en tercera dimensión. *Gac. méd. Méx.* 2001;137(6):609–11.
 37. Sonnesen L, Pedersen CE, Kjær I. Cervical column morphology related to head posture , cranial base angle , and condylar malformation. *Eur J Orthod.* 2007;29(4):398–403.
 38. Gorlin RJ. Branchial arch and oro-acral disorders. In: Gorlin RJ, Cohen MM, Hennekam RC, editors. *Syndromes of the head and neck.* London: *Oxford University Press*; 2001. p. 790–7.
 39. Sonnesen L, Petri N, Kjær I, Svanholt P. Cervical column morphology in adult patients with obstructive sleep apnoea. *Eur J Orthod.* 2008;30(5):521-6.
 40. Gurani SF, Di Carlo G, Cattaneo PM, Thorn JJ, Pinhol EM. Effect of Head and Tongue Posture on the Pharyngeal Airway Dimensions and Morphology in Three-Dimensional Imaging: a Systematic Review. *J Oral Maxillofac Res.* 2016;7(1): e1.

Table 1 – Definition of abbreviations.

Abbreviation	Definition
AS	Affected Side
US	Unaffected Side
RP	Retropalatal
RG	Retroglossal
MA	Minimum Axial Area
Max occlusal canting	Maxillary occlusal canting
Md occlusal canting	Mandibular occlusal canting
Diff.	Difference
Md Axial Ang	Mandibular Axial Angle
Md Incl	Mandibular Inclination
Occl Md Incl	Occlusal Mandibular Inclination
Ax-Go	Distance between Axial Plane and the Gonium Point
Ax-Gn	Distance between Axial Plane and the Gnathion Point
Y-axis ass	Y-axis asymmetry

Table 2 - Comparison between Control and OAVS groups for morphometric measurements.

Measures	Control (n=18)		OAVS (n=18)		diff.	p
	mean	sd	mean	sd		
Total posterior height AS	51.04	4.26	30.56	7.33	-20.48	<0.001*
Total posterior height US	51.04	4.26	52.35	4.84	1.31	0.395
Total posterior height Diff.	0.44	1.34	-21.78	6.67	-22.23	<0.001*
Max occlusal canting AS	54.96	4.36	49.39	3.53	-5.58	<0.001*
Max occlusal canting US	54.96	4.36	55.98	4.03	1.01	0.475
Max occlusal canting Diff.	0.37	1.35	-6.59	3.47	-6.96	<0.001#
Md occlusal canting AS	55.44	4.46	50.30	3.79	-5.13	0.001*
Md occlusal canting US	55.44	4.46	57.38	4.56	1.94	0.205
Md occlusal canting Diff.	0.60	1.33	-7.07	3.66	-7.68	<0.001*
Md Axial Ang	0.80	0.60	5.76	3.51	4.96	<0.001*
Md Incl	31.89	5.16	47.91	5.18	16.02	<0.001*
Occl Md Incl	19.83	4.09	33.00	4.61	13.16	<0.001*
Ax-Go AS	61.93	6.08	54.23	6.14	-7.70	0.001*
Ax-Go US	61.93	6.08	60.52	6.29	-1.41	0.500
Ax-Go US Diff.	0.47	1.34	-6.29	6.60	-6.77	<0.001*
Ax-Gn	95.83	5.61	92.62	4.36	-3.20	0.064

Ant/post lower facial height ratio	0.65	0.05	0.62	0.05	-0.03	0.113
Y-axis ass	1.09	0.90	13.24	6.29	12.15	<0.001#
MP-SN	32.94	3.44	43.01	5.99	10.06	<0.001#
SNA	82.42	3.01	78.73	3.35	-3.69	0.001*
SNB	78.71	3.34	70.57	4.70	-8.14	<0.001*
OP-SN	17.89	3.31	22.18	6.40	4.29	0.016*
MP-Hy	10.32	3.84	8.06 [†]	4.73	-2.26	0.130
HY-C3	30.37	4.26	28.19 [†]	3.27	-2.18	0.062
CVT-SN	103.80 ^{††}	10.61	107.45 [†]	8.67	3.65	0.217
OPT-SN	98.64 ^{††}	10.52	106.58 [†]	9.72	7.94	0.014 [#]

* - statistically significant difference (*t* test).

- statistically significant difference (Mann-Whitney U test).

[†]n=17; ^{††}n=15; AS: Affected Side; US: Unaffected Side.

Table 3 - Comparison between Control and OAVS groups for airway measurements.

Measure	Control (n=18)		OAVS (n=18)		diff.	<i>p</i>
	mean	sd	mean	sd		
Total airway area	449.33	86.60	385.61	75.86	-63.72	0.037 [#]
Total airway volume	11319.94	3787.12	7507.22	2473.29	-3812.72	0.001 [#]
Total MAA	182.17	86.16	106.56	52.01	-75.61	0.001 [#]
RP area	306.00	62.32	256.33	64.30	-49.67	0.025*
RP volume	8310.33	2997.40	5118.06	1918.56	-3192.28	<0.001 [#]
RP MAA	200.39	88.12	129.67	51.65	-70.72	0.006*
RG area	165.44	53.48	138.06	45.48	-27.39	0.064
RG volume	3197.33	1312.52	2328.17	1222.36	-869.17	0.019 [#]
RG MAA	202.94	91.42	111.06	52.28	-91.89	<0.001 [#]

* - statistically significant difference (*t* test)

- statistically significant difference (Mann-Whitney U test)

sd: Standard Deviation.; RG: retroglossal; MAA: Minimal Axial Area; RP: retropalatal

Figure Legends:

Figure 1 - A) Airway delimitation following the defined limits (green lines). Airway to be analyzed according to the pink boundary. Seed sensitivity points in yellow. **B)** Volume and airway area values calculated by the software according to the delimited area.

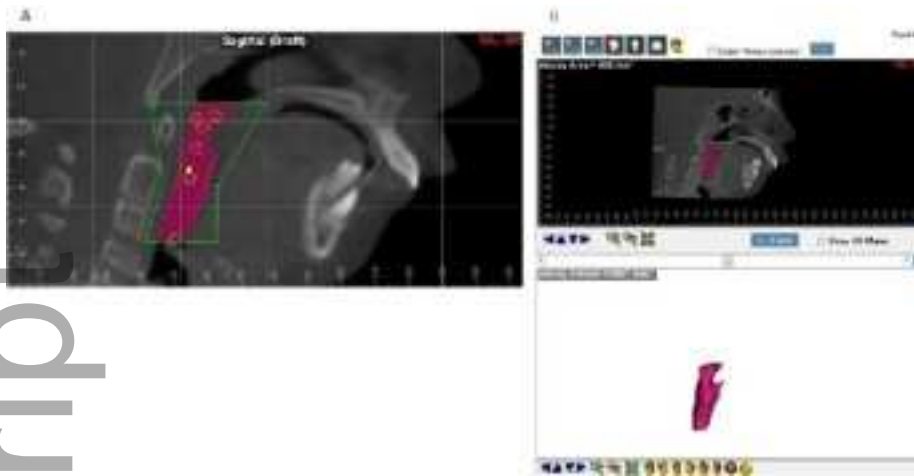Figure 2 - Delimitation of retropalatal **(A)** and retroglossal **(B)** areas.

Figure 3 - Morphometric measures. **A)** Total posterior height, **B)** Maxillary occlusal canting, **C)** Mandibular occlusal canting, **D)** Mandibular axial angle, **E)** Mandibular


inclination, **F)** Mandibular occlusal inclination, **G)** Anterior/posterior lower facial height ratio and **H)** Y-axis asymmetry.

Modified from: Stoustrup et al, 2018²².

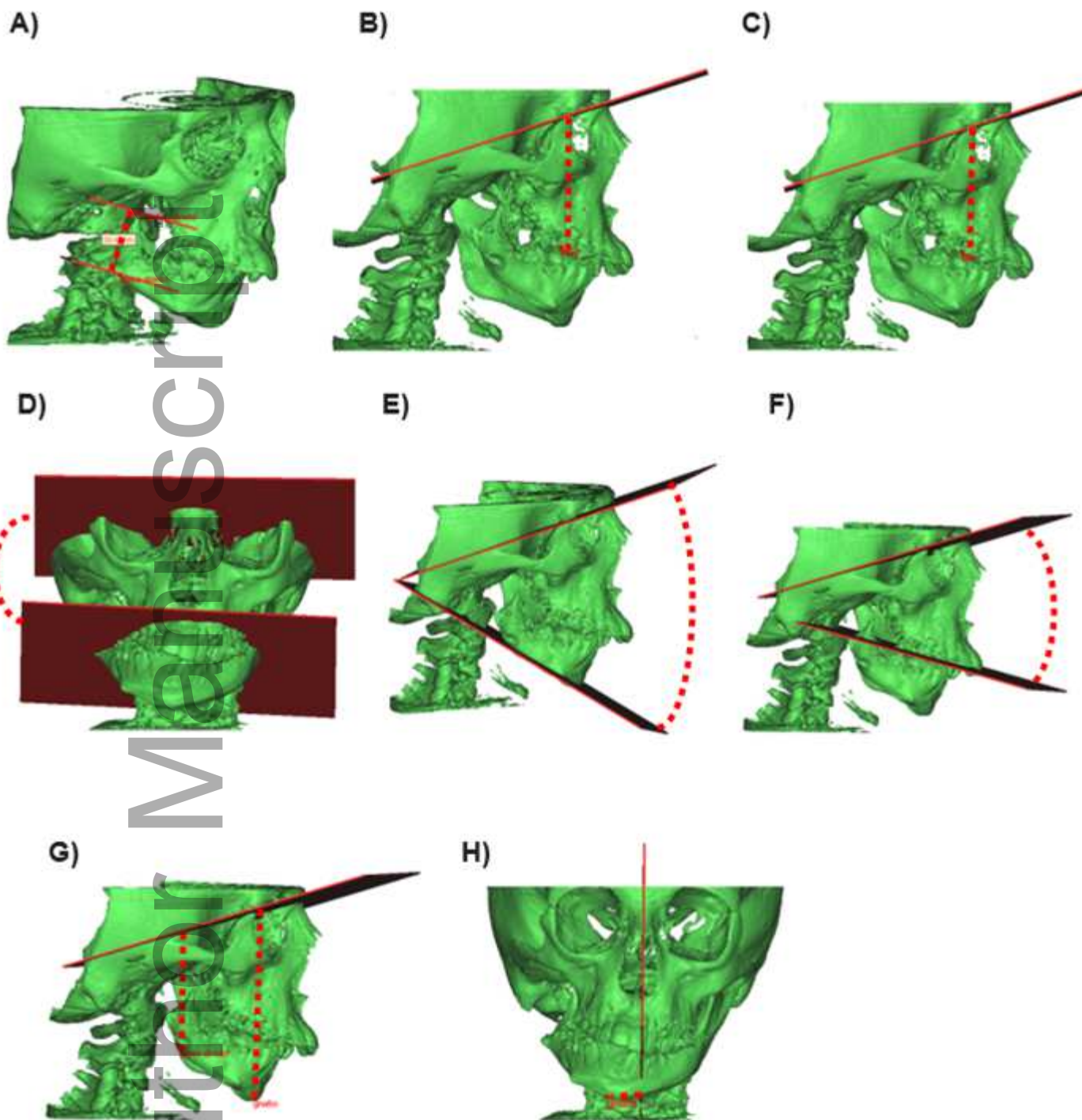
Author Manuscript



ocr_12483_f1.tif



ocr_12483_f2.tif



ocr_12483_f3.tif