

Title Page

Adjuvant Radiation and Cetuximab Improves Local Control in Head and Neck Cutaneous Squamous Cell Carcinoma: A Phase II Study

Short Title: Adjuvant radiation with Cetuximab increases control

Paul J. Kreinbrink, MD¹; Michelle L. Mierzwa, MD²; Brad Huth, MD¹; Kevin. P. Redmond, MD¹; Trisha M. Wise-Draper, MD, PhD³; Keith Casper, MD⁴; Junan Li, PhD⁵; and Vinita Takiar, MD, PhD^{1,6}

University of Cincinnati, ¹Department of Radiation Oncology, ³Division of Hematology/Oncology; University of Michigan Departments of ²Radiation Oncology, ⁴Otolaryngology, ⁵The Ohio State University College of Pharmacy, ⁶Cincinnati VA Medical Center

Corresponding Author:

Vinita Takiar, MD, PhD
University of Cincinnati Medical Center
234 Goodman Street, ML 0757
Cincinnati, OH, 45267, USA
Fax: 513-584-4007 | Tel: 513-584-1450
E-mail: takiarva@ucmail.uc.edu

Funding: United States Department of Veterans Affairs Biomedical Laboratory Research and Development Service Career Development Award BX004360 to V.T.

Conflict of interest: P.K., M.M., B.H., K.R., K.C., J.L. declare no conflicts of interest. T.W.D. reports grants from Merck, grants from BMS, grants from Tesaro/GSK, grants from AstraZeneca, personal fees from Shattuck Labs, personal fees from Rakuten outside the submitted work. V.T. reports grants from VA Medical Center, during the conduct of the study; grants from Merck, outside the submitted work.

Meeting Information:

Originally presented at ASTRO Annual Meeting 2020; Chicago, IL, USA. October 26, 2020.

Acknowledgements: V.T. acknowledges support from the United States Department of Veterans Affairs Biomedical Laboratory Research and Development Service [IK2 BX004360]. Eric Smith provided editorial review.

Author Contributions: P.K.: Investigation, Data Curation, Writing-Original Draft and Editing. M.M., B.H., K.P.R., and K.C.: Conceptualization, Methodology, Investigation, Writing-Review and Editing. T.W.D.: Investigation, Writing – Review and Editing. J.L.: Formal Analysis and Visualization. V.T.: Investigation, Writing-Review and Editing, Project Administration, Funding Acquisition

This is the author manuscript accepted for publication and has undergone full peer review but has not been through the copyediting, typesetting, pagination and proofreading process, which may lead to differences between this version and the Version of Record. Please cite this article as doi: 10.1002/hed.26835

Adjuvant Radiation and Cetuximab Improves Local Control in Head and Neck Cutaneous Squamous Cell Carcinoma: A Phase II Study

Abstract

Background: Cutaneous squamous cell carcinoma of the head/neck (CSCCHN) is common due to chronic sun exposure. As CSCCHN highly expresses EGFR, we prospectively studied post-operative concurrent cetuximab with radiotherapy for locally-advanced CSCCHN (LA-CSCCHN).

Materials/Methods: Single-institutional phase II trial of LA-CSCCHN (NCT XXXX). Adjuvant radiation was given with concurrent cetuximab. Primary endpoint of 2-year LRC and secondary objectives of 2-year disease-free survival (DFS) and 2-year OS were assessed by Kaplan-Meier analysis.

Results: 24 patients ages 47–88 (median 71yrs) were treated from 2014-2017. 14 patients had T3/4 disease, 5 had N1 disease and 7 were N2/3. At median follow-up of 42 months, Median OS and DFS was not reached and 64 months. 2-year OS was 75%, 2-year DFS was 70.8%. LRC was 91.1% at 2 years. All grade 3 adverse events were related to skin toxicity (12.5% radiation related dermatitis, 16.7% cetuximab-related rash).

Conclusions: LRC compares favorably to historical data examining postoperative radiation alone but requires further investigation.

Keywords

Cetuximab; Carcinoma, Squamous Cell; Radiotherapy, Adjuvant; Prospective Studies; Head and Neck Squamous Cell Carcinoma

Pages: Text Pages: 12. Tables: 4. Figures: 2.

Introduction

Skin cancer is the most common malignancy diagnosed in the United States, with more than 5 million cases diagnosed in 3 million patients annually, and 1 in 5 Americans developing a form of skin cancer by age 70¹. Of these cases, over 1 million cases are squamous cell carcinoma (SCC)². Nearly 90% of cases of cutaneous SCC are related to ultraviolet light³. Immunosuppression is associated with increased incidence as well as earlier metastatic spread noted in transplant patients⁴. Although the vast majority of non-melanomatous skin cancers are locally controlled via surgery, radiation, or topical medications, there remains a higher-risk subset of patients who require more intensive therapy.

Approximately 3% of all cutaneous SCC cases progress to nodal metastases⁵. Of cutaneous SCCs of the head and neck (CSCCHNs), 60-70% of metastatic nodes present in the parotid gland, the drainage basin for many high-risk sites around the ear, scalp, cheek, and temple⁶. Worse prognosis for patients with CSCCHN has been associated with involvement of the parotid gland, cervical nodal metastases, immunosuppression, and bony invasion^{7,8}. In retrospective series, overall survival (OS) at 2 years is significantly worse with advanced nodal disease, with 70-80% OS for N1 parotid and/or neck involvement, and only 25-50% for N2-3 patients^{7,8}. While these patients are usually treated aggressively with resection and adjuvant radiation, there remains no standard of care for systemic therapy in the adjuvant setting. In the only large randomized study evaluating the addition of systemic therapy (carboplatin) to postoperative radiation in these patients, no local control or survival benefit was observed⁹.

Epidermal growth factor receptor (EGFR) is a transmembrane tyrosine kinase, which is activated by epidermal growth factor and transforming growth factor (TGF α), and promotes cell proliferation, angiogenesis, and inhibition of apoptosis through the Ras signaling pathway¹⁰. EGFR is constitutively expressed in normal epithelial tissues, including the skin. Overexpression of this receptor has been detected in many human cancers, including SCC. Furthermore, there is data to suggest that EGFR overexpression is associated with nodal progression, recurrence, and proliferation in cutaneous SCC^{11,12}. Cetuximab is a monoclonal chimeric IgG1 antibody that binds and blocks EGFR¹⁰. Cetuximab has previously been tested in large randomized phase III trials for non-cutaneous squamous cell carcinomas of the head and neck with mixed results¹³⁻¹⁵. Although promising, all currently existing data on radiation with concurrent cetuximab in cutaneous SCC is noted to derive from small retrospective studies^{16,17}.

The favorable toxicity profile of cetuximab and high expression of EGFR in CSCCHN provided rationale for intensified adjuvant therapy in LA-CSCCHN. Despite early closure due to slow accrual, the current study presents the only prospective data evaluating concurrent cetuximab with adjuvant radiation to date. The goal of this trial was to establish the 2-year locoregional control rate with the addition of concurrent cetuximab to radiotherapy for LA-CSCCHN in the post-operative setting.

Materials and Methods

We conducted a single-institutional IRB-approved Phase II clinical trial (NCT XXX) of patients with high-risk CSCCHN treated with adjuvant radiotherapy and concurrent cetuximab.

Patient Selection and Inclusion/Exclusion Criteria

Patients were enrolled into a single cohort after obtaining informed consent. Eligible patients included those with pathologically proven cutaneous SCC of the head and/or neck with either invasion of skeletal muscle, cartilage, or bone (T3-4), or positive lymph nodes (\geq N1).

While the presence of immunosuppression as a risk factor was allowed and recorded, immunosuppressed patients still needed to meet pathologic criteria in order to be eligible.

Patients must have undergone gross total resection of disease with curative intent, with R0 or R1 resection allowed. Patients with recurrent CSCCHN were allowed if they had not received prior radiation. Computed tomography of the chest or positron emission tomography was required within 8 weeks prior to registration. Patients were required to be examined by a head and neck surgeon, as well as either a medical or radiation oncologist within 2 weeks of registration. Other eligibility criteria included Zubrod performance status of 0-2, age >18 , and adequate hematologic, hepatic, and renal function. Patients were ineligible if they had a history of prior invasive malignancy unless disease free for the previous 3 years (previous cutaneous BCC and SCC allowed). Patients were also excluded if they had received previous systemic chemotherapy or anti-EGFR therapy, or for prior radiation to the region of interest. There were no screen fails or early withdrawals after consent.

Treatment Planning and Delivery

All patients underwent radiotherapy with concurrent cetuximab after definitive resection. Patients were enrolled within 9 weeks of surgery. Radiation was delivered using megavoltage photons, and electron therapy and both 3D conformal or intensity-modulated radiation therapy (IMRT) were allowed. The primary tumor bed and postoperative neck plus a

1.5 – 2.0 cm margin were treated to 60 Gy in 30 fractions. Lower risk volumes were treated to 56 Gy in 1.85 – 2.0 Gy per day fractions. Areas with close surgical margins or nodal extracapsular extension, were boosted to 66 Gy in daily fractions of 2.0 – 2.2 Gy per day at the discretion of the treating physician. Perineural invasion of named nerves was treated to base of skull as per institutional and consensus guidelines with microscopic PNI treated to 54-60 Gy and positive margins along nerves treated to 60-66 Gy¹⁸.

Cetuximab was given on day 1 as an initial loading dose of 400 mg/m² one week prior to starting radiation therapy. During radiation, patients were given weekly infusions of cetuximab at 250 mg/ m² for 6-7 doses.

Follow-up

After completing combined adjuvant therapy, patients were seen in follow-up at 1- and 3-months post-radiation, then every 3 months for the first 2 years, every 6 months during the third year, and then annually for a total of 5 years. Biopsy and/or imaging of any lesion(s) suspicious for tumor recurrence was recommended but left to the discretion of the treating physician. Adverse events resulting from treatment were graded by the revised NCI Common Terminology Criteria for Adverse Events (CTCAE), version 4.03.

Study Endpoints and Statistical Considerations

The primary endpoint of this study was 2-year locoregional control (LRC), defined as no evidence of recurrent cancer in the tumor bed and/or neck as assessed via clinical exam and imaging. Secondary endpoints included 2-year disease-free survival (DFS), which was the absence of locoregional recurrence or metastatic disease (biopsied when possible). 2- and 5-

year overall survival (OS) defined as the absence of death from any cause during those respective time periods was also recorded. All time-based endpoints were recorded from the date of consent until last follow-up or death. Death was recorded via the electronic medical record, local and regional obituaries, and/or the Social Security Death Index.

The original patient accrual goal was for 110 patients, however due to lower than anticipated numbers of eligible patients and slow accrual the trial was recommended for closure in March 2018, and the data was allowed to mature. Loco-regional control and overall survival were estimated by the Kaplan-Meier method. Based on institutional historical data, the null hypothesis was for 65% LRC at 2 years. Kaplan-Meier survival data and curves were generated using SPSS version 26 (International Business Machines Corp., Armonk, NY). Toxicity data were tabulated and presented using descriptive statistics.

Results

Patient Population

From 2014 – 2017, 24 patients diagnosed with CSCCHN were treated with adjuvant cetuximab and radiation. Median patient age was 71 years (47–88 years). Of the 24 patients, 22 (91.7%) completed the full course of radiation and 21 (87.5%) received all 6-7 cetuximab infusions. Fourteen patients presented with advanced tumor classification (T3-4), while 7 patients had no evidence of a primary tumor on their pre-enrollment resection (Tx). Lesions ranged in size from 1–9.9 cm and were most often resected from the cheek or nose region (9 patients) or temple and scalp (6 patients). Twelve patients presented with node positive disease, including 7

patients staged as N2-3. Over half of the patients in this cohort were found to have perineural invasion (PNI, 13 patients), 4 of which had named nerve involvement, while invasion of the lymphovascular space was recorded in 6 patients. Disease was considered to be recurrent in 4 of the 24 patients. Two patients were on immunosuppression regimens at enrollment. **Table 1** contains the complete descriptive statistics for the cohort.

Locoregional and Distant Recurrence

Median follow-up was 42 months. LRC was 91.1% at 2 years and 85.4% at 5 years. At the time of last follow-up, 6 of 24 patients had progressed: 2 locally, 3 distantly, and 1 patient who failed both locally and distantly. 5 of the 6 patients with recurrence were noted to have PNI, and both patients who failed locally were noted to have PNI. Of the four patients with involvement of a named nerve, only one had recurrence, and on retrospective review of the radiation plan, this nerve was inadequately covered in target volumes.

Overall and Disease-Free Survival

The median OS for our patient cohort was not reached after a median follow-up of 42 months. At the cutoff point for data collection, nine patients had died and five of these were without evidence of disease progression while four had died with progression. The 2-year OS was 75%, and 5-year OS was 63.6% (**Figure 1**). Median DFS for this group was 64 months. Overall, 2-year DFS was 70.8%, and 5-year DFS was 56.1% (**Figure 2**). Of the two immunosuppressed patients, one died without evidence of disease 39 months later, while the other developed dural recurrence at 6 months post-treatment and died at 14 months. Patient outcomes are detailed in **Table 2**.

Toxicity

There were no grade 4-5 toxicities. Overall, 8 grade 3 toxicities were recorded in 7 patients (29.2%). 4 (16.7%) were attributable to cetuximab-related acneiform rash, 3 (12.5%) due to radiation dermatitis, and 1 instance of grade 3 mucositis was recorded. Grade 2 radiation-related skin effects were observed in 37.5% of patients, grade 2 cetuximab-related rash was observed in 45.8% of patients, while grade 2 mucositis was recorded in 37.5%, and xerostomia in 16.7% of patients. Full toxicity data is presented in **Table 4**.

Discussion

In this prospective single-institution/single-arm trial of adjuvant radiation combined with weekly cetuximab for locally advanced CSCCHN, the addition of cetuximab resulted in a 91.1% 2-year LRC rate. Our 2-year LRC as well as disease-free survival of 70.8% also compared favorably to historical data examining adjuvant radiation alone, which reports control rates of 70-80% and DFS of 50-70%^{7,8,16}. As the first reported prospective data on the use of adjuvant cetuximab with concurrent radiation for CSCCHN, this treatment regimen holds promise for the treatment of CSCCHN patients at high risk for disease recurrence.

While the vast majority of CSCCHN lesions are cured with surgical, radiotherapeutic, or topical approaches, control of these lesions diminishes with advanced tumor stage. In a cohort of 994 SCC and 712 BCC T1-2 lesions treated with 35 Gy in 5-7 fractions using 80 kV photons, the 5-year local recurrence rate was ~5-6%¹⁹. However, with more invasive T3 and T4 lesions, the 5-year local control falls to 72-83% for T3 tumors and 29-54% for T4 tumors with radical

radiation therapy alone²⁰. Increasing nodal involvement also portends a worse prognosis, with retrospective data demonstrating 70-80% 2-year OS for N1 parotid and/or neck involvement, and 25-50% for N2-3 patients^{7,8}.

Despite the rising incidence of LA-CSCCHN, there remains no consensus standard of care for optimal post-operative systemic therapy. While large randomized trials have evaluated the use of adjuvant chemoradiotherapy in mucosal HNSCC, the evidence supporting the use of postoperative concurrent therapy in cutaneous SCC is limited and largely retrospective¹⁶. TROG 05.01 sought to determine whether the addition of concurrent carboplatin (AUC 2) to post-operative radiation improves LRC in high-risk CSCCHN⁹. Of 321 patients, 77% had high-risk nodal features while 19% had an advanced primary (remaining 4% had both). The authors found no significant improvement of local control, DFS, or OS with the addition of systemic carboplatin at 5 years. Despite our cohort having a much higher rate of advanced primaries, our 2-year locoregional control rate of 91.1% is comparable to TROG 05.01, which reported 88%. Given the high rates of control with radiation alone, the population of TROG 05.01 may represent a lower-risk group than is classically seen in this population as 68 patients on the RT arm had nodal disease limited to the parotid gland without cervical lymphadenopathy. Toxicity was also significantly higher in the TROG population than in our current study.

Elsewhere in the literature, retrospective data examining the use of concurrent systemic therapy shows promise, but is limited by sample size. A retrospective study of 61 patients who received adjuvant radiation or chemoradiation with cisplatin or carboplatin noted no OS benefit to the addition of chemotherapy. Median recurrence-free survival was extended from 15 to 40 months, largely due to improved locoregional control¹⁷. Another retrospective study examined

23 patients with LA-CSCCHN treated with cetuximab or platinum-based chemoradiation in either the definitive or adjuvant setting. Although the difference was not significant, cetuximab demonstrated a numerically higher 2-year DFS (50% vs 30%) and OS (73% vs 40%)²¹. Given the lack of robust phase III randomized data in the LA-CSCCHN setting, there is currently no category 1/2A recommendations by the National Comprehensive Cancer Network (NCCN) for adjuvant chemoradiotherapy²².

While carboplatin was not found to improve survival or locoregional control in LA-CSCCHN, cetuximab, the EGFR antagonist, may offer some benefits in improving disease control. EGFR is constitutively expressed in normal skin tissues. Overexpression of this receptor has been detected in SCCs and there is data to suggest that EGFR overexpression is associated with nodal progression, stage progression, and proliferation in CSCC^{11,12}.

The use of EGFR-targeted therapy was previously examined in a single-arm phase II study using single-agent cetuximab in unresectable or metastatic CSCC of any site. 69% of patients were noted to have stable or improved disease at 6 weeks, and 28% of all patients eventually had a partial or complete response. Interestingly, tumor EGFR levels were not found to be associated with response or survival²⁸. While this trial did not include patients undergoing radiotherapy for comparison, over a quarter of patients did respond to cetuximab-based treatment alone. In another retrospective study of 68 patients by Palmer et al with LA-CSCCHN utilizing a propensity-matched analysis, 2-year freedom from local recurrence (FFLR) was found to be 74% in patients treated with radiotherapy and 83% in those treated with radiation and cetuximab¹⁶. 2- and 5-year PFS rates were 53% and 29% with radiation alone, and these improved to 72% and 66% in the cetuximab arm. While the overall cohort contained only a

quarter of patients with T3-4 tumors, there did appear to be a benefit in those patients receiving cetuximab, despite the cetuximab cohort having significantly higher rates of nodal involvement and positive margins¹⁶. Our prospective data corroborates and slightly improves upon the results of Palmer et al in a cohort with more advanced primary tumors, noting a 2-year LRC of 91.1% compared to 83% in their review, as well as a similar disease or progression-free survival at 2 years of 71-72%. Given the incremental improvements seen in disease control with cetuximab, radiation, and the combination of both over either therapy alone, concurrent radiation with cetuximab appears to be a reasonable option in resected LA-CSCCHN.

Recent randomized evidence has also shown promise for the use of anti-PD-1 immunotherapy. Cemiplimab and pembrolizumab are recommended in cases where curative surgery and radiation are not feasible, or in metastatic disease. Although early data appears to be promising in CSCC^{29,30}, non-PD-1 approaches remain essential for instances when patients require immunosuppression for history of solid organ transplant or autoimmune disease, or have other contraindications to immunotherapy. The role of cemiplimab in the adjuvant setting for high risk CSCC (NCT03969004) is still being explored but as above, will have limitations.

This study is prospective, but is a single-institution, single-arm investigation. There was also a smaller than expected sample size. Although median follow up approaches 4.5 years, it is also limited by significant mortality in our cohort unrelated to CSCCHN, as 5 of 9 deceased patients had died without evidence of disease progression. Given the generally advanced age of patients on this trial with a median age of 71, this may not be totally unexpected. Regardless of these limitations, our data provides evidence that the addition of cetuximab to adjuvant radiation may improve LRC in CSCCHN as compared to adjuvant radiation alone.

Conclusions

In this prospective trial of adjuvant cetuximab and radiation for locally advanced cutaneous squamous cell carcinoma of the head and neck, LRC, OS, and DFS compare favorably to historical retrospective data which utilized adjuvant radiation alone^{7,8,16,31}. Cetuximab-based radiation was well-tolerated with a low rate of grade 3 effects and no grade 4-5 toxicities. Despite a median age of 71, 87.5% of patients completed all cycles of cetuximab. Based on these results, as well as previous data suggesting high rates of EGFR expression in CSCC, adjuvant radiation with concurrent cetuximab should be explored further in a larger randomized study.

References

1. Rogers HW, Weinstock MA, Feldman SR, Coldiron BM. Incidence Estimate of Nonmelanoma Skin Cancer (Keratinocyte Carcinomas) in the U.S. Population, 2012. *JAMA dermatology*. 2015;151(10):1081-1086. doi:10.1001/jamadermatol.2015.1187
2. American Cancer Society. Cancer Facts and Figures 2020. Annual Cancer Facts and Figures. Published 2020. Accessed April 23, 2020. <https://www.cancer.org/content/dam/cancer-org/research/cancer-facts-and-statistics/annual-cancer-facts-and-figures/2020/cancer-facts-and-figures-2020.pdf>
3. Koh HK, Geller AC, Miller DR, Grossbart TA, Lew RA. Prevention and early detection strategies for melanoma and skin cancer. Current status. *Arch Dermatol*. 1996;132(4):436-443.
4. Martinez J-C, Otley CC, Stasko T, et al. Defining the clinical course of metastatic skin cancer in organ transplant recipients: a multicenter collaborative study. *Arch Dermatol*. 2003;139(3):301-306. doi:10.1001/archderm.139.3.301
5. Karia PS, Han J, Schmults CD. Cutaneous squamous cell carcinoma: estimated incidence of disease, nodal metastasis, and deaths from disease in the United States, 2012. *J Am Acad Dermatol*. 2013;68(6):957-966. doi:10.1016/j.jaad.2012.11.037
6. O'Brien CJ. The parotid gland as a metastatic basin for cutaneous cancer. *Arch Otolaryngol Head Neck Surg*. 2005;131(7):551-555. doi:10.1001/archotol.131.7.551
7. O'Brien CJ, McNeil EB, McMahon JD, Pathak I, Lauer CS, Jackson MA. Significance of clinical stage, extent of surgery, and pathologic findings in metastatic cutaneous squamous carcinoma of the parotid gland. *Head Neck*. 2002;24(5):417-422. doi:10.1002/hed.10063

8. Audet N, Palme CE, Gullane PJ, et al. Cutaneous metastatic squamous cell carcinoma to the parotid gland: analysis and outcome. *Head Neck*. 2004;26(8):727-732. doi:10.1002/hed.20048
9. Porceddu SV, Bressel M, Poulsen MG, et al. Postoperative Concurrent Chemoradiotherapy Versus Postoperative Radiotherapy in High-Risk Cutaneous Squamous Cell Carcinoma of the Head and Neck: The Randomized Phase III TROG 05.01 Trial. *J Clin Oncol Off J Am Soc Clin Oncol*. 2018;36(13):1275-1283. doi:10.1200/JCO.2017.77.0941
10. Vincenzi B, Schiavon G, Silletta M, Santini D, Tonini G. The biological properties of cetuximab. *Crit Rev Oncol Hematol*. 2008;68(2):93-106. doi:10.1016/j.critrevonc.2008.07.006
11. Chung CH, Ely K, McGavran L, et al. Increased epidermal growth factor receptor gene copy number is associated with poor prognosis in head and neck squamous cell carcinomas. *J Clin Oncol Off J Am Soc Clin Oncol*. 2006;24(25):4170-4176. doi:10.1200/JCO.2006.07.2587
12. Cañueto J, Cardeñoso E, García JL, et al. Epidermal growth factor receptor expression is associated with poor outcome in cutaneous squamous cell carcinoma. *Br J Dermatol*. 2017;176(5):1279-1287. doi:10.1111/bjd.14936
13. Bonner JA, Harari PM, Giralt J, et al. Radiotherapy plus cetuximab for squamous-cell carcinoma of the head and neck. *N Engl J Med*. 2006;354(6):567-578. doi:10.1056/NEJMoa053422
14. Bonner JA, Harari PM, Giralt J, et al. Radiotherapy plus cetuximab for locoregionally advanced head and neck cancer: 5-year survival data from a phase 3 randomised trial, and relation between cetuximab-induced rash and survival. *Lancet Oncol*. 2010;11(1):21-28. doi:10.1016/S1470-2045(09)70311-0
15. Gillison ML, Trotti AM, Harris J, et al. Radiotherapy plus cetuximab or cisplatin in human papillomavirus-positive oropharyngeal cancer (NRG Oncology RTOG 1016): a randomised,

- multicentre, non-inferiority trial. *Lancet (London, England)*. 2019;393(10166):40-50.
doi:10.1016/S0140-6736(18)32779-X
16. Palmer JD, Schneider CJ, Hockstein N, et al. Combination of post-operative radiotherapy and cetuximab for high-risk cutaneous squamous cell cancer of the head and neck: A propensity score analysis. *Oral Oncol*. 2018;78:102-107. doi:10.1016/j.oraloncology.2018.01.015
17. Tanvetyanon T, Padhya T, McCaffrey J, et al. Postoperative concurrent chemotherapy and radiotherapy for high-risk cutaneous squamous cell carcinoma of the head and neck. *Head Neck*. 2015;37(6):840-845. doi:10.1002/hed.23684
18. Bakst RL, Glastonbury CM, Parvathaneni U, Katabi N, Hu KS, Yom SS. Perineural Invasion and Perineural Tumor Spread in Head and Neck Cancer. *Int J Radiat Oncol Biol Phys*. 2019;103(5):1109-1124. doi:10.1016/j.ijrobp.2018.12.009
19. Cognetta AB, Howard BM, Heaton HP, Stoddard ER, Hong HG, Green WH. Superficial x-ray in the treatment of basal and squamous cell carcinomas: a viable option in select patients. *J Am Acad Dermatol*. 2012;67(6):1235-1241. doi:10.1016/j.jaad.2012.06.001
20. Mendenhall WM, Parsons JT, Mendenhall NP, Million RR. T2-T4 carcinoma of the skin of the head and neck treated with radical irradiation. *Int J Radiat Oncol Biol Phys*. 1987;13(7):975-981.
doi:10.1016/0360-3016(87)90034-4
21. Lu SM, Lien WW. Concurrent Radiotherapy With Cetuximab or Platinum-based Chemotherapy for Locally Advanced Cutaneous Squamous Cell Carcinoma of the Head and Neck. *Am J Clin Oncol*. 2018;41(1):95-99. doi:10.1097/COC.0000000000000228
22. National Comprehensive Cancer Network. *Squamous Cell Skin Cancer NCCN Evidence Blocks*.; 2020. https://www.nccn.org/professionals/physician_gls/pdf/squamous_blocks.pdf

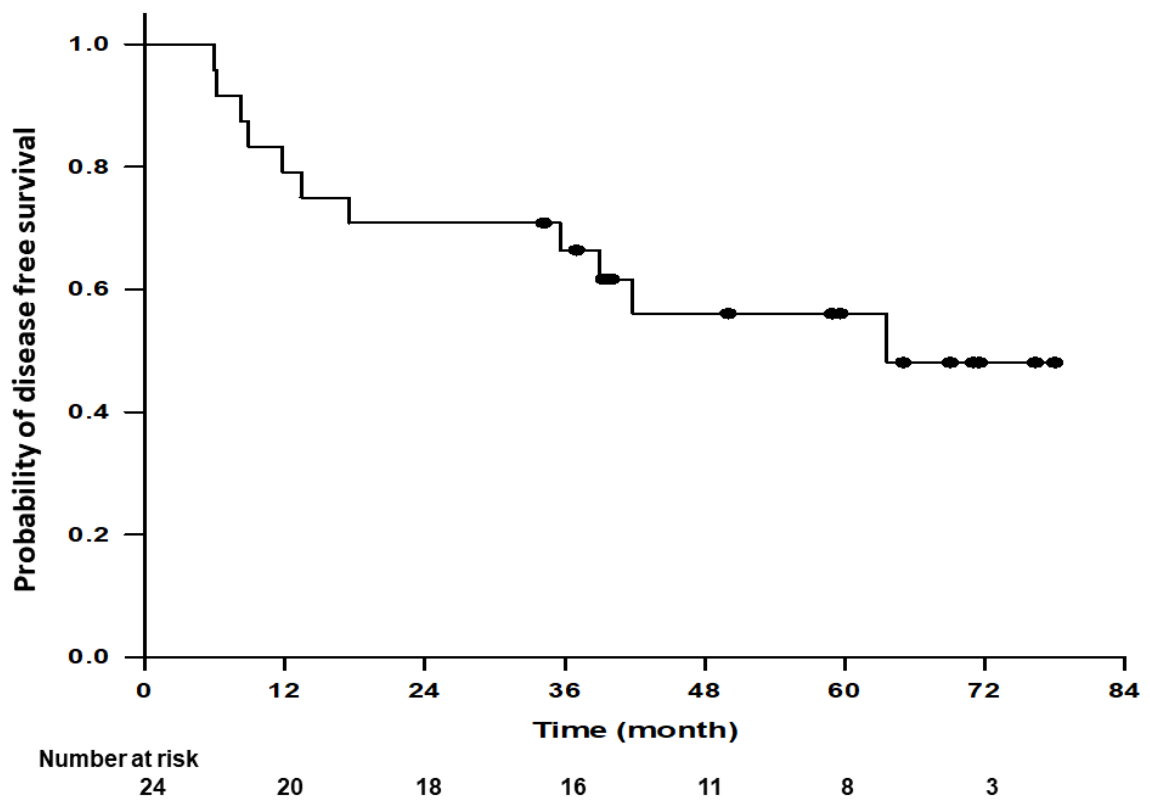
23. Fei J, Hong A, Dobbins TA, et al. Prognostic significance of vascular endothelial growth factor in squamous cell carcinomas of the tonsil in relation to human papillomavirus status and epidermal growth factor receptor. *Ann Surg Oncol*. 2009;16(10):2908-2917. doi:10.1245/s10434-009-0579-1
24. Kim S-H, Koo B-S, Kang S, et al. HPV integration begins in the tonsillar crypt and leads to the alteration of p16, EGFR and c-myc during tumor formation. *Int J cancer*. 2007;120(7):1418-1425. doi:10.1002/ijc.22464
25. Reimers N, Kasper HU, Weissenborn SJ, et al. Combined analysis of HPV-DNA, p16 and EGFR expression to predict prognosis in oropharyngeal cancer. *Int J cancer*. 2007;120(8):1731-1738. doi:10.1002/ijc.22355
26. El-Abaseri TB, Putta S, Hansen LA. Ultraviolet irradiation induces keratinocyte proliferation and epidermal hyperplasia through the activation of the epidermal growth factor receptor. *Carcinogenesis*. 2006;27(2):225-231. doi:10.1093/carcin/bgi220
27. Jedlinski A, Garvin S, Johansson A-C, Edqvist P-H, Ponten F, Roberg K. Cetuximab sensitivity of head and neck squamous cell carcinoma xenografts is associated with treatment-induced reduction in EGFR, pEGFR, and pSrc. *J oral Pathol Med Off Publ Int Assoc Oral Pathol Am Acad Oral Pathol*. 2017;46(9):717-724. doi:10.1111/jop.12545
28. Maubec E, Petrow P, Scheer-Senyarich I, et al. Phase II study of cetuximab as first-line single-drug therapy in patients with unresectable squamous cell carcinoma of the skin. *J Clin Oncol Off J Am Soc Clin Oncol*. 2011;29(25):3419-3426. doi:10.1200/JCO.2010.34.1735
29. Migden MR, Rischin D, Schmults CD, et al. PD-1 Blockade with Cemiplimab in Advanced Cutaneous Squamous-Cell Carcinoma. *N Engl J Med*. 2018;379(4):341-351. doi:10.1056/NEJMoa1805131

30. Migden MR, Khushalani NI, Chang ALS, et al. Cemiplimab in locally advanced cutaneous squamous cell carcinoma: results from an open-label, phase 2, single-arm trial. *Lancet Oncol.* 2020;21(2):294-305. doi:10.1016/S1470-2045(19)30728-4
31. Samstein RM, Ho AL, Lee NY, Barker CA. Locally advanced and unresectable cutaneous squamous cell carcinoma: outcomes of concurrent cetuximab and radiotherapy. *J Skin Cancer.* 2014;2014:284582. doi:10.1155/2014/284582

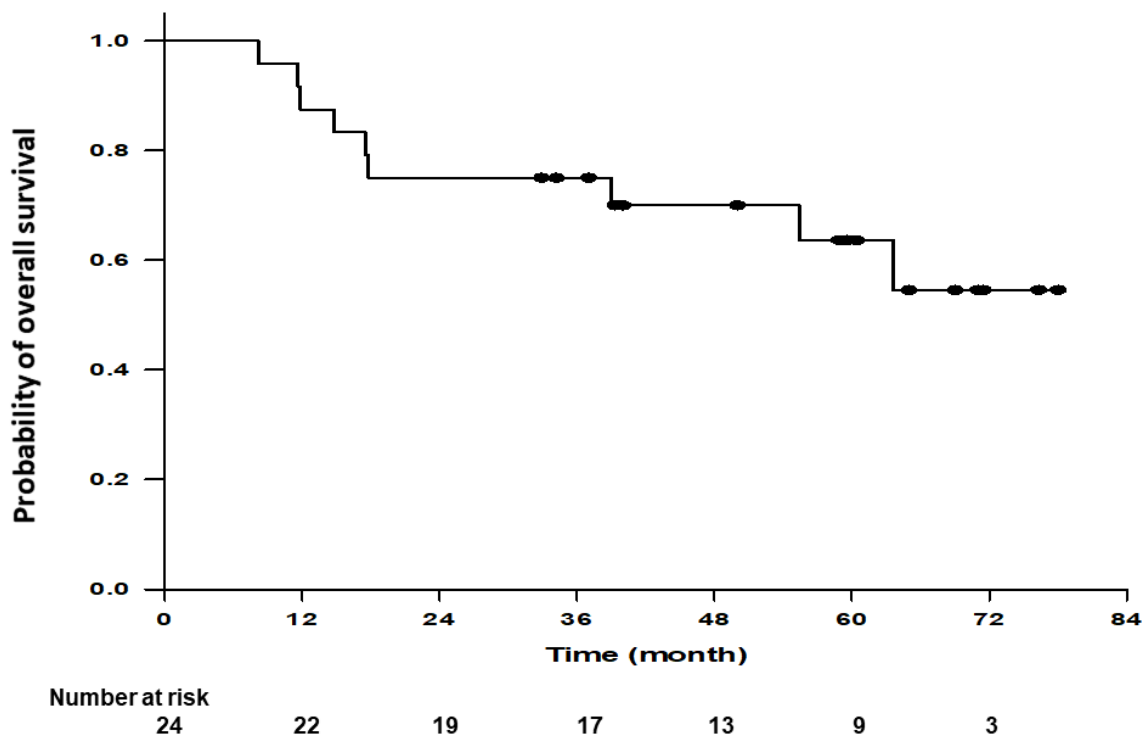
Figure Legends

Figure 1: Kaplan-Meier curve of overall survival in all patients receiving radiation and concurrent cetuximab.

Figure 2: Kaplan-Meier curve of disease-free survival in all patients receiving radiation and concurrent cetuximab.



HED_26835_UCCI1291_DFS_FigureX.tif



HED_26835_UCCI1291_OS_FigureX.tif

Table 1 – Patient Characteristics

	<i>Subcategory</i>	<i>Patients (n = 24)</i>	<i>%</i>
<i>Gender</i>	Male	22	91.7%
	Female	2	8.3%
<i>Age</i>		Mean = 69.1 Median = 71.6 Range: 47 – 88 years	
<i>Lesion Size</i>		Mean = 3.67 cm Median = 3.2 cm Range: 1.0 – 9.9cm	
<i># of lesions</i>	1	17	70.8%
	2	6	25%
	3	1	4.2%
<i>Primary Site</i>	Parotid or Neck Recurrence	4	16.7%
	Cheek/Nose	9	37.5%
	Neck	2	8.3%
	Scalp/Temple	6	25.0%
	Ear	3	12.5%
<i>Recurrent Disease</i>	No	20	83.3%
	Yes	4	16.7%
<i>Tumor Stage</i>	1-2	3	12.5%
	3	6	25.0%
	4	8	33.3%
	x	7*	29.2%
<i>Nodal Stage</i>	0	11	45.8%
	1	5	20.8%
	2-3	7	29.2%
	x	1	4.2%
<i>Margins</i>	Clear by >1mm	6	25%
	Close (\leq 1mm)	9	37.5%
	Involved	6	25%
	Unknown	3	12.5%
<i>Lymphovascular Space Invasion</i>	Absent	12	50%
	Present	6	25%
	Unknown	6	25%
<i>Perineural Invasion</i>	Absent	6	25.0%
	Present	13	54.2%
	Named Nerve Involvement	4	16.7%
	Unknown	5	20.8%
<i>Tumor Grade</i>	Well-Differentiated	1	4.2%
	Moderately-Differentiated	8	33.3%
	Poorly-Differentiated	9	37.5%
	Unknown	6	25%

*Note: Tx lesions and unknown primary sites may not match up in cases where a primary was removed and subsequently developed nodal metastases which required a second surgery

Table 2: Patient Outcomes

RESULTS	LRC	OS	DFS
2-Year	91.1% (80% - 100%)*	75.0% (59.5% - 94.5%)	70.8% (54.8% - 91.6%)
5-Year	85.4% (71.3% - 100%)	63.6% (45.9% - 88.2%)	56.1% (38.7% - 81.3%)
Median	Not Reached	Not Reached	63.6 months

*95% confidence interval (CI). LRC: Locoregional Control; OS: Overall Survival; DFS: Disease-Free Survival

Table 3: Comparison to Historical Data

	Current Study Cetux + RT (24pts)	Palmer et al RT alone (39 pts)	Palmer et al Cetux + RT (29 pts)¹⁷	Samstein et al Cetux + RT (12 pts)³¹	TROG 05.01 RT alone (157 pts)	TROG 05.01 CarboP + RT (153 pts)
2-Year PFS	70.8% (DFS)	53%	72%	Not reported	78% (DFS)	83% (DFS)
5-Year PFS	56.1% (DFS)	29%	66%	Med PFS 6.4mo	67% (DFS)	73% (DFS)
2-Year OS	75%	73%	80%	40%	88%	88%
5-Year OS	63.6%	61%	80%	Med OS 8.0mos	76%	79%
2-yr LRC	91.1%	74% (FFLR)	83% (FFLR)	91% (DCR)	88% (FFLRR)	89% (FFLRR)
5-yr LRC	85.4%	54% (FFLR)	77% (FFLR)		83% (FFLRR)	87% (FFLRR)
	Prospective	Retrospective	Retrospective	Retrospective	Prospective	Prospective

*PFS: Progression-Free Survival; OS: Overall Survival; DFS: Disease-Free Survival; FFLR: Freedom from Local Recurrence; FFLRR: Freedom from Locoregional Recurrence; DCR: Disease Control Rate; CarboP: Carboplatin

Table 4: Acute toxicities of Treatment

	<i>Grade 1</i>	<i>Grade 2</i>	<i>Grade 3</i>	<i>Grade 4</i>	<i>Grade 5</i>
<i>Radiation Dermatitis</i>	12	9	3	0	0
<i>Acneiform Rash</i>	7	11	4	0	0
<i>Mucositis</i>	4	9	1	0	0
<i>Dysphagia</i>	4	3	0	0	0
<i>Xerostomia</i>	7	4	0	0	0
<i>Odynophagia</i>	7	1	0	0	0
<i>Eye</i>	5	1	0	0	0
<i>Nausea</i>	3	1	0	0	0