







TIMELY REVIEW

Impact of mobile devices on cancer diagnosis in cytology

Nicola Santonicco MD¹ | Stefano Marletta MD¹  | Liron Pantanowitz MD²  |
 Guido Fadda MD³  | Giancarlo Troncone MD⁴  | Matteo Brunelli MD¹ |
 Claudio Ghimenton MD⁵ | Pietro Antonini MD¹ | Gaetano Paolino MD¹ |
 Ilaria Girolami MD⁶  | Albino Eccher MD⁵ 

¹Department of Diagnostics and Public Health, Section of Pathology, University and Hospital Trust of Verona, Verona, Italy

²Department of Pathology & Clinical Labs, University of Michigan, Ann Arbor, Michigan, USA

³Department of Human Pathology of the Adulthood and of the Developing Age "Gaetano Barresi", University of Messina Faculty of Medicine and Surgery, Messina, Italy

⁴Department of Public Health, University of Naples Federico II, Naples, Italy

⁵Department of Pathology and Diagnostics, University and Hospital Trust of Verona, Verona, Italy

⁶Division of Pathology, Central Hospital Bolzano, Bolzano, Italy

Correspondence

Albino Eccher, Department of Pathology and Diagnostics, University and Hospital Trust of Verona, P.le Stefani n. 1, 37126 Verona, Italy.
 Email: albino.eccher@aovr.veneto.it

Abstract

Background: Digital pathology has widened pathologists' opportunities to examine both surgical and cytological samples. Recently, portable mobile devices like tablets and smartphones have been tested for application with digital technologies including static, dynamic, and more recently whole slide imaging. This study aimed to review the published literature on the impact of mobile devices on cancer diagnoses in cytology. This analysis focused on their diagnostic potential, technical details, critical issues and pitfalls, and economical aspects.

Methods: A systematic search was carried out in the electronic databases Embase and PubMed. Studies dealing with the application of mobile devices for diagnosing cancer on cytological specimens were included. The quality of studies was assessed with the QUADAS-2 tool. The main themes addressed were the comparison of manual examination with light microscopy and the use of mobile tools for primary diagnosis. The technical features of different models of smartphones and tablets, software, and adapters were also studied in terms of feasibility and costs-analysis.

Results: Of 2458 retrieved articles, 18 were included. Concordance with light microscopy was good and diagnostic performance comparable with an expert pathologist's diagnosis. The mobile devices studied differed, sometimes significantly, in terms of speed and cost. The utility was improved by employing specifically designed adapters. Image acquisition and transmission represent the main critical points in almost all studies.

Conclusion: The use of mobile devices demonstrated promising results regarding the digital evaluation of cytological samples. Widespread adoption even in underserved areas is anticipated following validation studies, technology improvements, and reduction in the costs.

KEYWORDS

adapters, diagnostic concordance, digital cytology, mobile devices, smartphones, tablets, WSI

Abbreviations: AI, artificial intelligence; ANN, artificial neural networks; FNA, fine-needle aspiration; HTA, health technology assessment; LIS, laboratory information system; MMS, multimedia messaging service; ROI, region of interest; ROSE, rapid onset evaluation; sWSI, scalable whole slide imaging; WSI, whole slide imaging.

1 | INTRODUCTION

Digital pathology is a disruptive technology that consists of viewing, manipulating and/or analyzing a digitized (virtual) version of glass slides on a computer monitor. Transmitting a digital slide via

telepathology to a pathologist can allowing them to remotely render a pathology diagnosis.¹ Other benefits of digital pathology when compared to conventional light microscopy include the ability to quickly reach a second opinion via teleconsultation, address workload, deliver care to resource-limited areas, and facilitate archiving and retrieval of slides. Moreover, digital slides enable the use of artificial intelligence systems in pathology.²⁻⁴ Digital pathology has also been widely employed for education.⁵

Techniques to acquire, transmit, and save digital images have evolved. Initially, digital pathology dealt primarily with static images (e.g., microphotographs of a field of view on a slide) and subsequently dynamic images (e.g., video transmission of images in real-time, with or without robotic microscopy support). More recent applications of digital pathology concern whole slide imaging (WSI), which refers to the digitization (scanning) of an entire glass slide with a whole slide scanning device to create a virtual version of the slide that simulates routine light microscopy when a digital slide is examined on a computer monitor, permitting end users to pan around in the x- and y-axis as well as zoom up and down the z-axis.⁶⁻⁸

Compared to digital surgical pathology, digital cytology faces unique technical issues and consequently the validation studies for the same applications are more recent and less numerous.^{9,10} Indeed, with cytology specimen preparation, cellular material may not always uniformly distribute across a slide, causing cells to cluster in three-dimensions (3D) within direct smears and infrequently in liquid-based preparations. Thus, unlike conventional light microscopy, when acquiring static digital cytology images, it is not always possible to accurately focus on all of the cellular details visible at different focal point levels. Using WSI acquired using Z-stacking permits cellular material to be captured at different focal planes, albeit this requires longer scanning times and leads to larger digital file sizes. For these reasons, the routine use of digital cytology tools has been impeded.¹¹

In recent years, mobile devices such as smartphones and tablets have become ubiquitous and cheaper (Figure 1) and more widely applied in many medical fields.^{12,13} Technological advances of these

devices (e.g., better cameras, increasing computing power, displays with higher pixel density, and rapid connectivity to networks and the cloud) have created innovative opportunities to use these mobile devices in image-centric healthcare fields, including microscopy. One specific area of interest pertains to microbiology, especially in resource-limited countries, where parasitic diseases are rife but trained laboratory staff to identify parasites is limited.¹⁴⁻¹⁷ Similarly, mobile devices may be utilized in cytopathology to assist with screening programs or facilitate telecytology to perform rapid onsite evaluation (ROSE) of fine-needle aspiration (FNA)-derived material. To date, while there have been several studies reporting the use of mobile devices in cytology there has not been a systematic review of these papers to determine their benefits and pitfalls for this purpose.

This study aimed to therefore systematically review the published literature regarding the use of mobile devices in the field of cytopathology evaluating their diagnostic feasibility for diagnosing neoplasia. This review also focused on mobile device technology, cost-analysis, limitations, emerging developments, and future directions.

2 | MATERIALS AND METHODS

This study was structured according to the preferred reporting items for systematic reviews and meta-analysis (PRISMA) guidelines.¹⁸ A systematic review restricted to English-written studies was conducted in the electronic databases PubMed-Medline and Embase until March 7, 2021 and all retrieved items were screened with the aid of Rayyan QCRI reference manager web application.¹⁹ The search string was as follows: (cytology OR cytological OR cytopathology OR cellblock OR cell-block OR smear OR brush OR fine-needle OR FNA OR liquid-based OR LC OR Pap) AND (mobile OR smartphone OR tablet OR phone OR iPhone OR Android OR app OR apps). Inclusion criteria were as follows: studies regarding oncologic cytology and the use of mobile devices to capture and/or read cytological images, regardless of mobile device model, type of studies, organ/apparatus, and specimen preparation techniques. Papers dealing with



FIGURE 1 Telecytology in action with two different types of microscope adapters for cell phones. Left, Skylight adapter. Right, Magnifi adapter [Color figure can be viewed at wileyonlinelibrary.com]

surgical pathology or with digital cytology not using mobile devices were excluded, as were those focusing on non-neoplastic cytology, parasitology and microbiology, hematology, and semen. Abstracts with adequate study details were included. Full text of articles fulfilling initial screening criteria were acquired and reviewed against the eligibility criteria. Any disagreement concerning inclusion was resolved by consensus. Data from included articles were extracted using a standardized form and included: title, author(s), publication year, the aim of the study, type of the study (full text or abstract), image type, device models, study population, image acquirement method, main results, and limitations of the study. Furthermore, when available, data regarding concordance and accuracy rates, sensitivity, specificity, positive and negative predictive values, and kappa coefficients were collected. When illustrating concordance results with kappa values, we referred to Landis and Koch's interpretation of Cohen's kappa value with kappa >0.81 almost perfect, 0.61–0.80 substantial, 0.41–0.60 moderate, 0.21–0.40 fair, and 0.00–0.20 slight concordance.²⁰ Given that most of the studies were likely to present a comparison among mobile devices and/or standard light microscopy with the evaluation of diagnostic and/or concordance performance, the quality of studies was assessed with a modified version of QUADAS-2 tool.²¹

3 | QUALITY ASSESSMENT

Quality of studies was assessed by two authors (SM, IG) and disagreements were resolved by consultation of a third reviewer (AE) according to a modified version of QUADAS-2 tool or, in case of descriptive studies with no formal comparison, to standardized checklist for quality assessment of patient reports and patient series²² (Supplementary Table S1). The items of the checklist were modified and tailored to the use of mobile devices in cytology. Considering that a noteworthy percentage of the included studies were either abstract or poster and that some of them mainly focused on technical aspects of the considered electronic instrument, the checklist comprised descriptions of the following, if applicable: clear patients inclusion criteria and consecutive inclusion of patients, accuracy of evaluation of cytological specimens with mobile devices and description of the tool employed, reference to conventional microscopy as a widely recognized gold-standard method, appropriate washout period of participants (taken as a minimum of two weeks, as for the College of American Pathologists' WSI validation guideline paper²³) and complete and proper testing of samples with both index and reference method, if applicable.

4 | RESULTS

4.1 | Literature search

A total of 2458 papers were retrieved after removal of duplicates, 2393 of which were excluded after title and abstract screening. The remaining 65 studies were identified as potentially relevant to the review. After full-text assessment, 18 studies were included. A flow

diagram of the screening and exclusion of all articles is shown in Figure 2.²⁴

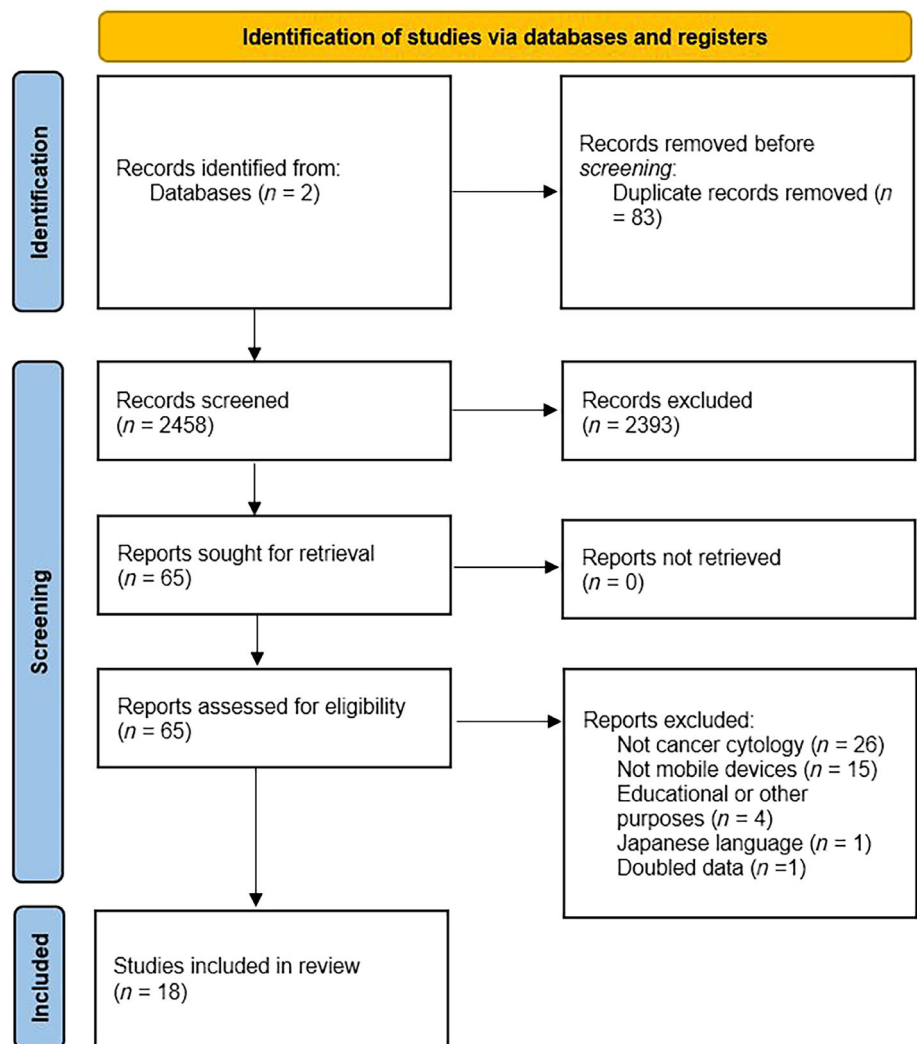
4.2 | Included studies, topic of interest, and type of devices

The 18 included studies comprised 11 full-text articles^{25–35} and 7 abstracts/posters.^{36–42} They were published in the time span 2012–2020 and were geographically distributed as follows: 10 from North America,^{25,28,31,33,36–41} four from Asia,^{26,27,32,35} two from Europe,^{29,34} one from South America³⁰; one non stated.⁴² These studies involved a total of 684 patients, with the number of subjects per study ranging from 20 to 172.^{40,34} Taking into account that some of these studies dealt with more than one topic, for practical purposes they were analyzed according to these topics and accordingly separately considered in the section below. The studies herein considered investigating the diagnostic performance of mobile devices for cytological specimens are discussed. Mobile devices in these studies were employed either for screening programs (e.g., Pap tests, oral samples) or for interpreting FNA-derived material. Two studies focused on urinary cytology,^{26,34} five dealt with cervical cytology,^{31,32,34,40,42} and another two with oral cancer screening.^{27,35} Several kinds of smartphones and tablets were used in these works including a Samsung Galaxy Note II, A7, S7, and M20 (Samsung Electronics, Seoul, South Korea), an iPhone 4S with a SkyLight adapter (Apple Inc., Cupertino, CA, USA), an iPhone 6 and 7 (Apple Inc., Cupertino, CA, USA), a Huawei Mate 8 (Huawei Technologies Co. Ltd., Shenzhen, Guangdong, China), a Xiaomi 5S (Xiaomi Inc, Beijing, China), and an iPad Mini 2 (Apple Inc., Cupertino, CA, USA) which were mainly employed for acquiring static images,^{26,31,32,34,35,40,42} but also for creating scalable whole slide imaging (sWSI)³² and analyzing them with artificial neural networks (ANN).²⁷ Other six papers focused on the utility of mobile devices for ROSE of FNA cytological specimens,^{25,26,30,34,36} relying on static or dynamic images generated by iOS (iPhone 5, iPad) and Android (Samsung Galaxy s7) supported devices and remotely transmitted via applications such as Facetime (Apple Inc., Cupertino, CA, USA) and WhatsApp (Facebook Inc., Menlo Park, CA, USA).³⁷

4.3 | Quality appraisal

A graphic display of quality assessment is shown in Supplementary figure S1. The quality of reporting was overall moderate, with 30% of cases providing clear information on 75% of the applicable items or more and thus permitting judgment. Detailed information about of evaluation of cytological specimens with mobile devices and of the tool employed (Index test domain) were present in 83% of the applicable studies (15/18), and for reference standard in the 67% of the publications (12/18) reference to conventional microscopy was detailed provided, while appropriate flow and timing data was present in 28% of them (5/18). The domain with a higher or unclear risk of bias was

FIGURE 2 Search flow diagram. The diagram was designed according to the template of the PRISMA flow diagram from Page et al.,²⁴ available at the PRISMA website (www.prisma-statement.org) [Color figure can be viewed at wileyonlinelibrary.com]



the patient selection, with missing information or with a high risk of bias for either of the items in 56% of the papers (10/18). Statistical analysis was available in 43% of the articles (7/16) and was considered appropriate in 86% of them (6/7).

5 | DIAGNOSTIC CONCORDANCE

5.1 | Screening

This category regarded studies that focused on urine cytology, Pap tests for cervical cancer screening, and oral cancer screening. Urine cytology evaluation via mobile devices was evaluated in two studies, both examining static images. Sahin et al.³⁴ reported 27 urine cytology cases. These authors reported a 22.22% light microscope versus smartphone discordance. The specific kappa value concordance rate was substantial (0.665). In the other article concerning urine cytology, Dixit et al.²⁶ studied 10 urine cases and reported a concordance rate of 90%. Five studies evaluated cervical cytology screening with Wimmer et al.⁴⁰ comparing telecytology of 100 static images captured by a smartphone and by a digital camera from 10 gynecological Pap

tests and 10 non-gynecological Papanicolaou-stained slides. Overall agreement with the original diagnosis for both iPhone and camera was 67%, while partial agreement and disagreement were respectively 16% versus 20% and 17% versus 13%. Another study by Sahin et al.³⁴ dealt with 44 cervical cytology cases on an overall amount of 172 cases. Using static images, the discordance percentage by smartphone and light microscope was 20.44% with a kappa concordance value of 0.855 (almost perfect). Huang et al.³² assessed cervical cytology cases using sWSI, creating virtual slides with smartphones from 100 ThinPrep cervical samples. The average accuracy reported by these investigators was 85% for a trained pathologist which reached 92% for a senior pathologist, with a kappa value of 0.70 and 0.82 respectively. Comparing Android and iOS with sWSI, both systems were satisfactory, with a nonsignificantly different kappa value (average kappa value for Android: 0.70; average kappa value for iOS: 0.72). Naqvi et al.³¹ examined the performance and agreement of a Samsung S7 smartphone coupled with a paper-based microscope (FoldScope, developed by Manu Prakash, Stanford, CA, USA). The 40 cases of this study were comprised of 10 normal samples, 10 low-grade squamous intraepithelial lesion (L-SIL), 10 high-grade squamous intraepithelial lesion (H-SIL), and 10 malignant Pap smears. The

TABLE 1 Characteristics of the included studies

Author, year (Country)	Type of study and aim	Study population	Image type	Devices	Main results	Main limits
Agarwal et al., 2015 (USA) ²²	Diagnostic assessment Evaluation of ROSE in FNA with iPhone/iPad and Facetime	39 patients	Dynamic	iPhone 5 (capturing) iPad (reading) Magnifi (adapter)	Phase 1: concordance onsite-remote: 88% (22/25) Time of acquisition: 10 s. ~2 min Phase 2/testing: concordance onsite remote 86 (12/14) Time of acquisition: 10 s ~2 min 30 s	Focusing and connectivity problems Problems with software and voice communication Defects in ocular alignment and fluctuations in view
Bifalco et al., 2015 (USA) ³³	Diagnostic assessment Evaluation of Facetime use to support EUS-FNA	25 patients	Dynamic	iPhone 5 (capturing) Magnifi (adapter)	CT can communicate with CP via Facetime to driving slides for adequacy assessment Magnifi was easy to use	Apple products required for using Facetime No data about diagnostic accuracy
Bocklage et al., 2020 (USA) ³⁴	Diagnostic assessment Evaluation of using Facetime for touch preparation of specimens from a biobank	195 cytological samples	Dynamic	iPhone 5 (capturing)	Tumor presence: accuracy 90%, sensitivity 50%, specificity 98% Detecting <50% necrosis: accuracy 88%, sensitivity 100%, specificity 88%	Devices only tested for biobanking
Cox et al., 2017 (USA) ³⁵	Tool design Development of a 3D-printed adapter for iPhone	Not reported	Not reported	iPhone adapter	Inexpensive apparatus (<20\$) Effectiveness in remote adequacy cytology, remote frozen section, and slide scanning with iPhone	No comparison with other models
Dixit et al., 2020 (India) ²³	Diagnostic assessment Evaluation of cytological images transmitted via Whatsapp for diagnosis	151 FNA samples (68 neck lymph nodes, 2 salivary glands, 24 breast, 57 miscellaneous), 10 urines	Static	Samsung galaxy A7 (capturing) Samsung Galaxy M20 (reading)	Total concordance 95.6% (154/161) Higher concordance in miscellaneous – 100% (57/57) Lower concordance in urines – 90% (9/10)	Image pixilation (image reduction by WhatsApp) No 3D planes on static images
Dudas et al., 2014 (USA) ²⁵	Cost and performance analysis Analysis of 3 low-cost systems to perform telecytology	Not reported	Dynamic	Raspberry Pi model B iPhone 4S with Magnifi adapter and Facetime or ipCam	Total cost Raspberry Pi system: \$ 85.55 Total cost iPhone with Facetime-ipCam: \$624–\$626 Latency Raspberry Pi (970 x 720 pixels): 6.8 + -0.9 (y axes) and 5.4 +/- 1.7 s (x axes) Latency iPhone (ipCam) (1080 x 810): 2.06 + -0.75 s (y axes) and 2.86 + -0.84 s (x axes)	Lack of flexibility for parameters with iPhone Unclear why Raspberry Pi is 2x slower than iPhone at similar parameters Ethernet connection of Raspberry Pi more reliable than wireless (more secure) Apple products required for using Facetime
Giansanti et al., 2014 (Italy) ²⁶	Health technology assessment Design of an HTA to assess tablets in cytology	Six cervical cytology samples	WSI	LG Optimum Dual, Nokia C6, iPhone 4S (wearable); Asus EeePad, iPad 2, iPad 3 (portable); Epson Xdesk (nonportable)	Good results in terms of performance and acceptance for all investigated dimensions (basic information, subjective quality, virtual navigation, ICT features, diagnostic power) Diagnostic power investigated only for nonportable tablet; time to reach diagnosis was lower by 13% mean (statistically significant difference)	Bad quality of some chromatins details Occasional refresh problems with navigation

TABLE 1 (Continued)

Author, year (Country)	Type of study and aim	Study population	Image type	Devices	Main results	Main limits
Howard et al., 2017 (USA) ³⁸	Adapters comparison Compare microscope-phone adapters for telecytology immediate assessment	Not reported	Dynamic	iDu LabScan (for iPhone 5-7) SnapZoom (universally) Gosky (universally) Tested with iPhone 7 communication with an iPad Mini 4 via Facetime	iDu was the best adapter due to imagine stability, setup time and transferability Much expensive (\$249) Only for iPhone 5-7. Needs rubber band to keep phone secure	No data about diagnostic accuracy High cost of iDu adapter
Huang et al., 2018 (China) ²⁹	Diagnostic assessment Technical analysis of Android smartphone models in sWSI on Android smartphones	100 thin-prep cervical samples	sWSI	Test on 200 Android models (technical assessment) Huawei Mate 8 and Xiaomi 5S (Android) iPhone 6 and iPhone 7 (iOS) (diagnostic assessment)	sWSI-light microscope: average accuracy 85%-92%, sensitivity 71%-83%, specificity 77%-93%, kappa value 0.70-0.82 sWSI Android-iOS: average accuracy 87%-88%, sensitivity 75%-77%, specificity 79%-83%, kappa value 0.70, 0.72 Only 3% (6/200) of analyzed models supported standards on high-resolution capturing images (1500 x 2000 pixels, no trimming slides, no mismatching, or padding data sizes) Higher CPU frequencies led to a faster processing speed, but it's model-dependent	Necessity of adequate sample preparation Diagnostic errors due to reviewer bias can underrate quality of sWSI Possibility to face uneven brightness and misalignment problems
Kewlani et al., 2012 ³⁹	Diagnostic assessment Accuracy of cervical smear reporting by MMS transmitted digital cytological images	100 pap-test cervical samples	Static	Not reported	Sensitivity 85.7% Specificity 100% Positive predictive value 100% Negative predictive value 99.9%	Lack of data regarding models of devices used
Machado et al., 2019 (Brazil) ²⁷	Diagnostic assessment Evaluation of ROSE in EUS-FNA on solid pancreatic masses via Whatsapp	23 patients	Static	Samsung Galaxy S7 (capturing)	Adequate sample in 69.6% (16/23) Kappa coefficient negative/positive: 0.56 Specificity-sensitivity: 100%	Only one cytopathologist and one EUS-FNA team No archived material available
Naqvi et al., 2020 (USA) ²⁸	Diagnostic assessment Evaluation of Foldscope with smartphone in cervical cytology	40 cervical cytology samples (10 normal cervical cytology, 10 L-SIL, 10 H-SIL, 10 malignant)	Static	Samsung Galaxy S7 (capturing) Foldscope	Agreement: 75% Weighted kappa: 0.68 Accuracy: 80% H-SIL/malignancy: 85% sens-90% spec L-SIL: 80 sens-83.3% spec Normal: 70% sens-96.7% spec	Small visual field Focusing problems Impossibility to fine movements on the slide

(Continues)

TABLE 1 (Continued)

Author, year (Country)	Type of study and aim	Study population	Image type	Devices	Main results	Main limits
Pantanowitz et al., 2015 (USA) ³⁶	Technical evaluation of two models of tablets Exploring use of tablets in cytology practice	Not reported	Not reported	9.7" iPad 4 with retina display 7" Nexus 7	Preferred Nexus because of smaller size and fast connection speed. Images quality was satisfactory	Difficulty in navigating the LIS via tablet with touch gestures Missing of reliable information technology infrastructure (e.g., Wi-Fi connectivity)
Roy et al., 2014 (USA) ³⁰	Comparison of three smartphones adapters	Not reported	Static	Magnifi (for iPhones) Skylight Snapzoom	All adapters facilitated images acquisition Magnifi had best ease of use and stability, only for iPhones Snapzoom had good results (for various smartphones)	Variable image quality (depending on smartphones models) Utilization of adapters widened time to preview case (to mount and dismount the device between viewing slides and capturing images)
Sahin et al., 2017 (Turkey) ³¹	Diagnostic assessment Evaluation of concordance between smartphones and microscope cytological diagnoses	172 patients (44 cervical, 27 urine, 52 thyroid FNA, 23 EUS-FNA, 26 other)	Static	Samsung Galaxy Note II (capturing) iPhone 5 (reading)	Total concordance 85.3% (145/172) Kappa value between 1 (EUS-FNA) and 0.665 (urine) Discordancy between 0% (EUS-FNA) and 22.22% (urine)	Issues to view nuclear and cytoplasmatic details In thyroid smears critical details not seen at maximum zoom Lack of cytological details in tubal metaplastic cells (cilia and terminal bar)
Skandarajah et al., 2017 (India) ³²	Diagnostic assessment Evaluation of tablet-based Cellscope for oral cancer screening	32 patients	Static	iPad Mini 2 and Cellscope (capturing)	Cellscope versus histology: specificity 100%–100%, sensitivity 47%–63% Cellscope versus cytology: specificity 100%–100%, sensitivity 67%–90% Kappa value between 2 pathologists: 0.695	Need to scan areas with adequate cellularity
Sunny et al., 2019 (India) ²⁴	Diagnostic assessment Evaluation of tablet-based Cellscope with convolute neural network in oral cancer screening	82 total patients	Static	iPad Mini 2 and Cellscope (capturing)	Agreement: 75% Weighted kappa value: 0.68 SMV's specificity 88%, sensitivity 93%	Low sensitivity of telecytology and traditional cytology to diagnose LGD and HGD
Wimmer et al., 2012 (USA) ³⁷	Diagnostic assessment Comparison of cytological images taken with a digital camera and with a smartphone using an adapter	20 patients (10 pap-test and 10 non-gynecological)	Static	iPhone 4S (capturing) Skylight adapter	Accuracy of both camera and smartphone: 67% Intraobserver agreement smartphone-camera: 93%	Low accuracy of static images

Abbreviations: HTA, health technology assessment; FNA, fine-needle aspiration; ROSE, rapid onset evaluation; sWSI, scalable whole slide imaging.

^aAbstract/poster.

agreement percentage of FoldScope with conventional microscopy was 75%, with a weighted kappa of 0.68. FoldScope revealed a sensitivity of 85% for H-SIL/malignant, 80% for L-SIL and 70% for normal/benign categories while specificity results showed 90% for H-SIL/malignant, 83.3% for L-SIL and 96.7% for the normal/benign category. Furthermore, Kewlani et al.⁴² evaluated the accuracy of multimedia messaging services (MMS) transmitted static images of Pap smears versus a conventional light microscope. These authors found 85.7% for sensitivity and 100% for specificity for the mobile-based method, resulting in a positive predictive value of 100% and a negative predictive value of 99.9%. Mobile devices were also employed for screening of oral cancer. In 2017, Skandarajah et al.³⁵ evaluated an automated tablet-based mobile microscope (CellScope, CellScope Inc., Berkeley, CA, USA) associated with an iPad Mini 2 in a cohort composed of oral brush samples of 32 patients with suspicious oral squamous lesions performed by two pathologists. When compared to conventional cytology, the CellScope demonstrated 67%–90% sensitivity, with a specificity rate of 100% for both pathologists. In addition, when compared to histology results the CellScope's specificity was 100% for both pathologists, while sensitivity ranged from 47% to 63%. Two years later, this work was further corroborated²⁷ by the same group that aimed to build a risk-stratification model for potential malignant oral lesions or oral cancer based on an ANN involving 82 patients. In this setting, the CellScope compared to conventional cytology showed an overall average sensitivity of 81% and an overall average specificity of 90% to detect atypical cells, with a positive predictive value of 90% and negative predictive value of 82%. After development, and validation of the stratification-risk model with 252 images of normal cells and 250 images of atypical cells, the final accuracy of the proposed ANN was 90%, with a sensitivity of 89% and a specificity of 100%, increasing overall accuracy by 30% compared to the manual method.

5.2 | FNA cytology

FNA samples in the setting of ROSE were studied in six publications. Agarwal et al.²⁵ investigated mobile video streaming (dynamic imaging) using Facetime for remote adequacy assessment of cytological samples. The agreement of adequacy assessment was 88%; while three cases showed significant disagreement between onsite evaluation and remote assessment (two pancreatic lesions and one cervical lymph node). The utility of Facetime for dynamic remote primary assessment of FNA specimens in real-time using an iPhone 5 with an adapter was also investigated by Bifalco et al.³⁶ The main result of this latter study was that real-time assessment of FNA via mobile technology was feasible and appropriately permitted cases to be triaged for ancillary tests. The evaluation of FNA samples (e.g., thyroid, lung, breast, lymph nodes) using mobile devices was also studied by Sahin et al.³⁴ in which they employed static images in a large cohort of 172 cases. Discordance between microscope versus smartphone assessment varied from 21.15% for thyroid FNA to 0% for FNA cases obtained by endoscopic ultrasound (EUS), with kappa values in the range of substantial or almost perfect for all sample categories.

Machado et al.³⁰ evaluated ROSE telecytology in solid pancreatic lesions relying on static images acquired with a Samsung Galaxy S7 and transmitted via WhatsApp to a remote pathologist. Overall, remote ROSE examination showed an adequate accuracy of 69.6%, reaching substantial concordance rates with conventional microscopy (kappa value of 0.6) and with only two discordant cancer cases (reported as suspicious with ROSE telecytology). The use of WhatsApp to transmit static images and obtain a second opinion was studied by Dixit et al.²⁶ Among 161 total cases in this study, 151 were FNA cases. Concordance between the first and second pathologist's opinion was 92.9% for head and neck lesions, 95.8% for breast specimens and 100% for miscellaneous cases. Concerning head and neck cases, the lowest concordance was reported for squamous cell carcinoma (73.3%), while high concordance (100%) was seen for tubercular lymphadenitis, reactive lymphadenitis, poorly differentiated carcinoma, fibroadenoma, epidermal cyst, ganglion, and lipoma.

5.3 | Miscellaneous use cases

Bocklage et al.³⁷ used dynamic images transmitted via Facetime with an iPhone to assess touch preparations or direct smears prepared from specimens to be archived in a biobank for investigating the presence/absence of tumor and the presence/absence of necrosis. Real-time assessment proved to be accurate and specific. For 195 smears obtained from gross specimens, the reported accuracy for the presence of tumor and necrosis were 90% and 88%, respectively. Specificity and sensitivity for detection of tumor were 98% and 50%, and for identifying necrosis were 88% and 100%, respectively.

An overview of the included studies is provided in Table 1.

6 | DISCUSSION

Digital pathology has progressively improved with the evolution from static to dynamic images, and more recently with WSI. The benefits of leveraging this technology for various applications have been enriched by simultaneously employing mobile devices such as smartphones and tablets. Most of the studies in our analysis dealt with static images.^{26,27,30,31,34,35,40,42} Three studies evaluated the live transmission of dynamic images^{25,36,37} and only one assessed WSI.³² Static images are relatively easy to transmit whereas dynamic images often demand more bandwidth. Nevertheless, both modes of imaging can be supported using commercial applications such as FaceTime and WhatsApp. While WSI may be acquired with higher resolution, these larger image files may be harder to manage and navigate based upon different smartphone models.³² No major differences emerged regarding rendering diagnoses between Android and iOS devices. Despite their heterogeneity, all of the studies included in this review showed good concordance between mobile digital and traditional light microscopic evaluation of cytology cases.

Concerning the utility of mobile devices for screening purposes, urine cytology showed good concordance between glass versus digital

slide, albeit lower than that of nonurinary samples. For countries with low resources and a high prevalence of bladder tumors, this may offer a cost-effective urine cytology screening solution.⁴³ Similarly, when mobile devices were evaluated for screening cervical cytology^{31,32,34,40,42} they overall showed promising results. The main limitation was reliably assessing chromatin and cytoplasmic features, especially when dealing with static images. Other reported limitations included technical limitations (e.g., slow scanning time, focus, and navigation issues). Mobile-based screening cytology was also employed for detecting oral cancer, where the use of a tablet-based mobile microscope showed good results.

In the setting of FNA, digital cytology supported by mobile devices was principally used for ROSE⁴⁴ and/or for rendering a primary diagnosis. Cytology samples were procured from various anatomic locations. Overall, included studies showed good concordance results, with lower rates reported for squamous cells carcinoma²⁶ and thyroid lesions, most likely explained by the difficulty in adequately identifying on static digital images nuclear details including nuclear grooves, powdery chromatin, intranuclear cytoplasmic inclusions and irregular nuclear membranes.^{34,45} Technical problems noted were concerned with focusing, difficulties in communication between devices, malalignment of phone cameras and microscope adapters, occasionally voice communication problems,²⁵ and pixilation of images due to WhatsApp images compression.^{26,30}

Most of the studies evaluated the potential role of mobile devices for diagnostic purposes. Very few of the studies characterized the technology utilized and related issues including image acquisition, quality of virtual slides, and computer screens. This aspect was investigated by Giansanti et al.,²⁹ who employed a Health Technology Assessment tool (HTA) to assess tablet technology handling of cytology virtual slides. Tablets were classified into wearable (e.g., smartphones), portable or nonportable devices. Seven devices were selected: three wearables (LG Optimum Dual [LG Corporation, Seoul, South Korea], Nokia c6 [Nokia Corporation, Espoo, Finland], and iPhone 4s [Apple Inc., Cupertino, CA, USA]), three portable (Asus EeePad [ASUSTek Computer Inc., Taipei, Taiwan], iPad 2, iPad 3 [Apple Inc., Cupertino, CA, USA]) and one nonportable (Epson Xdesk, Epson, Nagano, Japan). These tools were tested with six cervicovaginal e-slides digitized using an Aperio (Leica Biosystems, Nussloch, Germany) whole slide scanner. The HTA form evaluated 5 parameters: basic information (list of digital cytology systems, tablets, details of e-slides), subjective quality (questions about perceived quality), virtual navigation (questions about the perceived performance of virtual navigation), information and communication technology features (detailed description), and diagnostic power (only for the nonportable tablet). The tested tablets showed good results for all of the aforementioned parameters, which encourages their use in digital cytology for multiple use cases (e-learning, teleconsulting, and diagnosis). However, the findings indicate that the quality of nuclear image resolution needs to be improved and, occasionally refresh problems impaired virtual navigation of e-slides, depending on network traffic. Similar results using tablets were also reported by Pantanowitz et al.,³⁹ who tested two tablets (iPad 4 with retina display iOS 8 [Apple

Inc., Cupertino, CA, USA] and Nexus 7 Android OS 5.0.2 [Google Inc., Mountain View, CA, USA]) for evaluation of cytology images. Users preferred the Nexus 7 because of its smaller size and faster connection speed. These mobile devices allowed cytopathologists to remotely review cytology images anywhere in the hospital. Connectivity problems were again the most relevant issues encountered, largely due to dead or weak Wi-Fi zones. Huang et al.³² investigated the ability of Android smartphones to capture and manage sWSI. While 200 different Android smartphones were tested, only 3% of the models were found to be suitable. The remaining 97% of examined smartphones required additional time to process high-resolution images. Compared to iOS, the Android system was limited by the computation of images.

Economics represents an additional barrier to the widespread adoption of digital pathology, especially in developing areas. In comparison to whole slide scanners, smartphones and tablets are much cheaper devices. Dudas et al.²⁸ performed a cost-analysis of three inexpensive systems for dynamic cytology including a Raspberry Pi with a webcam (Raspberry Pi Ltd., Cambridge, UK), iPhone 4S with Facetime, and iPhone 4S with ipCam. Raspberry Pi was the cheapest system. These devices were tested for latency (difference between time required for a microscope to focus on an object and that needed to let the remote viewer see the same object in focus) at different resolutions, evaluated by moving a microscope slide of thyroid papillary carcinoma 1 mm on the x- and y-axis and measuring the time between the end of the movement and stabilization of the image on a remote screen. As for the Raspberry Pi, the latency was most pronounced with higher resolution images: for example, at 960×720 pixels with 7 and 15 frames per second of transmission frequency, the latency for the y-axis was 6.8 and 7.1 s, respectively, and 5.4 and 7.7 s for x-axis. iPhone 4S with ipCam showed a latency of 2.06 s on y-axis and 2.86 s on x-axis. Performances were less reproducible with the iPhone and Facetime with 40% coefficient of variance, which was 4-fold higher than the coefficient of variance of the Raspberry Pi. The main disadvantage of the Raspberry Pi system was high latency, while the main issue regarding Facetime and the ipCam was the inability to control the frame rate for transmission. Similarly, Naqvi et al.³¹ used a smartphone attached to a very low-cost paper-based microscope (FoldScope) that cost only \$1, previously tested to detect parasites,⁴⁶ to acquire static images of cervical cytology. Apart from portability, the low cost of this setup makes this instrument very interesting for low-resource settings.

In this view, several adapters were tested that allow smartphones to be attached to optical microscopes by holding them on the eye-pieces. Three different models of such adapters (Gosky [Gosky Optics, USA], SnapZoom [SnapZoom, Honolulu, HI, USA], iDu [iDu Optics, Detroit, MI, USA]), used with an iPhone 7 communicating with an iPad Mini 4 via Facetime, have been compared by Howard et al.⁴¹ and Roy et al.³³ iDu was the best adapter for image stability, setup time and transferability; however, it was only suitable for iPhone 5–7 and needed rubber bands to keep the smartphone secure. The other adapters were universally compatible, but they presented many difficulties to set up, adjust and to use the on/off button. iDu was

noticeably more expensive. Three other adapters were compared by Roy et al. (Magnifi [Arcturus Labs, Kansas, USA], SnapZoom [SnapZoom, Honolulu, HI, USA], and SkyLight [SkyLight Healthcare Systems Inc., San Diego, CA, USA]) and all facilitated acquisition of digital images, with Magnifi providing the best performance in terms of ease of use and stability of the adapter. However, it could only be utilized with an iPhone; the Snapzoom adapter could instead be coupled with other smartphones. Interestingly, Cox et al.³⁸ developed a relatively cheap 3D-printed adapter for the iPhone.

6.1 | Limitations

Due to the relatively recent advent and spread of smartphones and tablets, their adoption in cytopathology has been investigated by only a limited number of studies. Although the most important results were reported for all the studies, 7 out of the 18 papers included in this review were abstracts/posters, with no corresponding published full-text. This obviously represents a limitation for completely evaluating evidence concerning the performance of mobile devices and their potential critical issues, given that only minimal information is available. The papers included principally focused on the diagnostic assessment of mobile-based digital cytology, showing heterogeneous outcomes with accuracy rates variably reported by percentage or weighted/unweighted kappa value or both. Moreover, other relevant parameters including sensitivity, specificity, predictive values, and percentage of disagreement were not reported in all the papers. Finally, while the included studies spanned a time period from 2012 to 2020, older devices likely did not perform as well as more recent technology, potentially impacting reported accuracy and quality results.

7 | CONCLUSION

Leveraging mobile devices to apply digital imaging in cytology has to date demonstrated effective diagnostic results for both screening and ROSE, allowing quick, remote, and reliable evaluations with reasonable costs compared to classic telecytology systems. Published studies indicate an overall substantial concordance between diagnoses rendered with mobile devices and conventional light microscopy, with promising results in terms of accuracy in specific areas (e.g., cervical screening, EUS-FNA collected samples). Moreover, they also offer a cautionary note for other areas of cytopathology such as thyroid, pancreas, oral, and urine cytology. Interestingly, the critical points raised in these areas are similar to those noted with conventional light microscopy, which include difficulty in the evaluation of subtle nuclear details and cytoplasmic hue, which may be modified in mobile device-acquired images. An important issue common to almost all studies is the technical challenge with good quality image acquisition and transmission. For example, use of adapters may hinder image acquisition. Also, latency and image lag problems due to suboptimal internet connection were constantly cited as a likely cause. Future developments in the area of mobile healthcare technology are anticipated that will

likely support more widespread adoption of these affordable mobile tools, especially in resource-limited settings.

CONFLICT OF INTEREST

The authors have no conflicts of interest or financial disclosures.

AUTHOR CONTRIBUTION

Conceptualization: Nicola Santoniccos and Albino Eccher. *Methodology:* Ilaria Girolami and Guido Fadda. *Investigation:* Gaetano Paolino, Ilaria Girolami, and Stefano Marletta. *Supervision:* Claudio Ghimenton and Matteo Brunelli. *Writing:* Nicola Santonicco, Pietro Antonini, and Stefano Marletta. *Revision of the Manuscript:* Albino Eccher, Liron Pantanowitz, and Giancarlo Troncone

DATA AVAILABILITY STATEMENT

Data sharing not applicable to this article as no datasets were generated or analysed during the current study.

ORCID

Stefano Marletta  <https://orcid.org/0000-0001-7881-8767>

Liron Pantanowitz  <https://orcid.org/0000-0001-8182-5503>

Guido Fadda  <https://orcid.org/0000-0001-9736-0544>

Giancarlo Troncone  <https://orcid.org/0000-0003-1630-5805>

Ilaria Girolami  <https://orcid.org/0000-0003-3537-4929>

Albino Eccher  <https://orcid.org/0000-0002-9992-5550>

REFERENCES

- Pallua JD, Brunner A, Zelger B, Schirmer M, Haybaeck J. The future of pathology is digital. *Pathol Res Pract.* 2020;216(9):153040. doi:10.1016/j.prp.2020.153040
- Jahn SW, Plass M, Moinfar F. Digital pathology: advantages, limitations and emerging perspectives. *J Clin Med.* 2020;9(11):3697. doi:10.3390/jcm9113697.
- Pantanowitz L, Hornish M, Goulart R. The impact of digital imaging in the field of cytopathology. *Cytojournal.* 2009;6(1):6. doi:10.4103/1742-6413.48606
- Khalbuss WE, Pantanowitz L, Parwani AV. Digital imaging in cytopathology. *Patholog Res Int.* 2011;2011:264683. doi:10.4061/2011/264683
- Hamilton PW, Wang Y, McCullough SJ. Virtual microscopy and digital pathology in training and education. *Apmis.* 2012;120(4):305-315. doi:10.1111/j.1600-0463.2011.02869.x
- Weinstein RS, Descour MR, Liang C, et al. Telepathology overview: from concept to implementation. *Hum Pathol.* 2001;32(12):1283-1299. doi:10.1053/hupa.2001.29643
- Zarella MD, Bowman D, Aeffner F, et al. A practical guide to whole slide imaging: a white paper from the digital pathology association. *Arch Pathol Lab Med.* 2019;143(2):222-234. doi:10.5858/arpa.2018-0343-RA
- Girolami I, Pantanowitz L, Marletta S, et al. Diagnostic concordance between whole slide imaging and conventional light microscopy in cytopathology: A systematic review. *Cancer Cytopathol.* 2020;128(1):17-28. doi:10.1002/cncy.22195
- Eccher A, Girolami I. Current state of whole slide imaging use in cytopathology: pros and pitfalls. *Cytopathology.* 2020;31(5):372-378. doi:10.1111/cyt.12806
- Salama AM, Hanna MG, Giri D, et al. Digital validation of breast biomarkers (ER, PR, AR, and HER2) in cytology specimens using three

- different scanners. *Mod Pathol.* 2021;13. doi:10.1038/s41379-021-00908-5. Online ahead of print.
11. Capitanio A, Dina RE, Treanor D. Digital cytology: a short review of technical and methodological approaches and applications. *Cytopathology.* 2018;29(4):317-325. doi:10.1111/cyt.12554
 12. Asgary R, Cole H, Adongo P, et al. Acceptability and implementation challenges of smartphone-based training of community health nurses for visual inspection with acetic acid in Ghana: mHealth and cervical cancer screening. *BMJ Open.* 2019;9(7):e030528. doi:10.1136/bmjopen-2019-030528.
 13. Furdova A, Furdova A, Krcmery V. Our experience with smartphone and spherical lens for the eye fundus examination during humanitarian project in Africa. *Int J Ophthalmol.* 2017;10(1):157-160. doi:10.18240/ijo.2017.01.25
 14. Coulibaly JT, Ouattara M, D'Ambrosio MV, et al. Accuracy of mobile phone and handheld light microscopy for the diagnosis of schistosomiasis and intestinal protozoa infections in Côte d'Ivoire. *PLoS Negl Trop Dis.* 2016;10(6):1-10. doi:10.1371/journal.pntd.0004768
 15. Bogoch II, Andrews JR, Speich B, et al. Short report: mobile phone microscopy for the diagnosis of soil-transmitted helminth infections: a proof-of-concept study. *Am J Trop Med Hyg.* 2013;88(4):626-629. doi:10.4269/ajtmh.12-0742
 16. Yu H, Yang F, Rajaraman S, et al. Malaria Screener: a smartphone application for automated malaria screening. *BMC Infect Dis.* 2020;20(1):825. doi:10.1186/s12879-020-05453-1
 17. Breslauer DN, Maamari RN, Switz NA, Lam WA, Fletcher DA. Mobile phone based clinical microscopy for global health applications. *PLoS One.* 2009;4(7):1-7. doi:10.1371/journal.pone.0006320
 18. Liberati A, Altman DG, Tetzlaff J, et al. The PRISMA statement for reporting systematic reviews and meta-analyses of studies that evaluate healthcare interventions: explanation and elaboration. *BMJ.* 2009;339:b2700-b2700. doi:10.1136/bmj.b2700
 19. Ouzzani M, Hammady H, Fedorowicz Z, Elmagarmid A. Rayyan—a web and mobile app for systematic reviews. *Syst Rev.* 2016;5(1):210. doi:10.1186/s13643-016-0384-4
 20. Landis JR, Koch GG. The measurement of observer agreement for categorical data. *Biometrics.* 1977;33(1):159-174. <http://www.ncbi.nlm.nih.gov/pubmed/843571>
 21. Whiting PF, Rutjes AWS, Westwood ME, et al. QUADAS-2: a revised tool for the quality assessment of diagnostic accuracy studies. *Ann Intern Med.* 2011;155(8):529-536. doi:10.7326/0003-4819-155-8-201110180-00009
 22. Munn Z, Barker TH, Moola S, et al. Methodological quality of case series studies: an introduction to the JBI critical appraisal tool. *JBI Evid Synth.* 2020;18(10):2127-2133. doi:10.11124/JBISRIR-D-19-00099
 23. Evans AJ, Brown RW, Bui MM, et al. Validating whole slide imaging systems for diagnostic purposes in pathology: guideline update from the College of American Pathologists in collaboration with the American Society for Clinical Pathology and the Association for Pathology Informatics. *Arch Pathol Lab Med.* 2021;18. doi:10.5858/arpa.2020-0723-CP. Online ahead of print.
 24. Page MJ, McKenzie JE, Bossuyt PM, et al. The PRISMA 2020 statement: an updated guideline for reporting systematic reviews. *BMJ.* 2021;372:n71. doi:10.1136/bmj.n71
 25. Agarwal S, Zhao L, Zhang R, Hassell L. Facetime validation study: low-cost streaming video for cytology adequacy assessment. *Cancer Cytopathol.* 2016;124(3):213-220. doi:10.1002/cncy.21636
 26. Dixit S, Tanveer N, Kumar H, Diwan H. Smartphone-assisted telecytopathology: an intraobserver concordance study. *Acta Cytol.* 2020;64(5):399-405. doi:10.1159/000506145
 27. Sunny S, Baby A, James BL, et al. A smart tele-cytology point-of-care platform for oral cancer screening. *PLoS One.* 2019;14(11):e0224885. doi:10.1371/journal.pone.0224885
 28. Dudas R, VandenBussche C, Baras A, Ali SZ, Olson MT. Inexpensive telecytology solutions that use the Raspberry Pi and the iPhone. *J Am Soc Cytopathol.* 2014;3(1):49-55. doi:10.1016/j.jasc.2013.09.005
 29. Giansanti D, Pochini M, Giovagnoli MR. Integration of tablet technologies in the e-laboratory of cytology: a health technology assessment. *Telemed J e-Health Off J Am Telemed Assoc.* 2014;20(10):909-915. doi:10.1089/tmj.2013.0235
 30. Machado RS, Richa R, Callegari F, et al. Instant messenger smartphone application for endosonographer/cytopathologist real-time interaction at a distance in EUS-FNA for solid pancreatic lesions. *Endosc Int Open.* 2019;07(08):E1027-E1030. doi:10.1055/a-0965-6631
 31. Naqvi A, Manglik N, Dudrey E, Perry C, Mulla ZD, Cervantes JL. Evaluating the performance of a low-cost mobile phone attachable microscope in cervical cytology. *BMC Womens Health.* 2020;20(1):60. doi:10.1186/s12905-020-00902-0
 32. Huang YN, Peng XC, Ma S, et al. Development of whole slide imaging on smartphones and evaluation with thinprep cytology test samples: follow-up study. *JMIR mHealth uHealth.* 2018;6(4):1-13. doi:10.2196/mhealth.9518
 33. Roy S, Hartman D, Pantanowitz L, et al. Smartphone adapters for digital photomicrography. *J Pathol Inform.* 2014;5(1):24. doi:10.4103/2153-3539.137728
 34. Sahin D, Hacisalihoglu UP, Kirimlioglu SH. Telecytology: is it possible with smartphone images? *Diagn Cytopathol.* 2018;46(1):40-46. doi:10.1002/dc.23851
 35. Skandarajah A, Sunny SP, Gurpur P, et al. Mobile microscopy as a screening tool for oral cancer in India: a pilot study. *PLoS One.* 2017;12(11):e0188440. doi:10.1371/journal.pone.0188440
 36. Bifalco K, Zarka M, Spiczka AW, et al. Facetime validation studies in an Academic Medical Center: applicable considerations for patient safety, IT security and workflow optimization. *J Am Soc Cytopathol.* 2015;4(6):S7-S7. doi:10.1016/j.jasc.2015.09.016
 37. Bocklage D, Napier D, Hallahan B, Sims L. TJ NFeasibility of assessing fresh tumor quality by real-time remote digital viewing via iPhones: a study of 195 cases. *Biopreservation Biobanking.* 2020;18(3):A8-A9.
 38. Cox J, Lintel N, Braun AL, Lazenby AJ. Design and development of a 3D-printed apparatus to hold a smartphone for histologic examination and associated applications. *Lab Invest.* 2017;97(suppl 1):395A-395A.
 39. Pantanowitz L, Ahmed I, Cuda J, Parwani A, Monaco S. "Cyto on the go": can tablet devices support the mobility of cytology services. *J Am Soc Cytopathol.* 2015;4(6):S65-S65. doi:10.1016/j.jasc.2015.09.160
 40. Wimmer J, Dhurandhar B, Fairley T, et al. A novel smartphone-microscope camera adapter: an option for cytology consultation in low-resource environments. *J Am Soc Cytopathol.* 2012;1(1):S124-S125. doi:10.1016/j.jasc.2012.08.268
 41. Howard J, Richards D. Comparison of newer microscope phone adapters for telecytology immediate assessment in an academic center. *J Am Soc Cytopathol.* 2017;6(5):S53-S54. doi:10.1016/j.jasc.2017.06.135
 42. Kewlani S, Deepti JAP. Diagnostic accuracy of papanicolaou (PAP) smear reporting by MMS transmitted digitalised images versus conventional light microscopy. *Australas Med J.* 2012;5(1):102-103.
 43. Miyazaki J, Nishiyama H. Epidemiology of urothelial carcinoma. *Int J Urol.* 2017;24(10):730-734. doi:10.1111/iju.13376
 44. Kothari K, Tummid S. This "rose" has no thorns—diagnostic utility of "rapid on-site evaluation" (rose) in fine needle aspiration cytology. *Indian J Surg Oncol.* 2019;10(December):688-698. doi:10.1007/s13193-019-00981-y
 45. Nardi F, Basolo F, Crescenzi A, et al. Italian consensus for the classification and reporting of thyroid cytology. *J Endocrinol Invest.* 2014;37(6):593-599. doi:10.1007/s40618-014-0062-0

46. Rajchgot J, Coulibaly JT, Keiser J, et al. Mobile-phone and handheld microscopy for neglected tropical diseases. *PLoS Negl Trop Dis*. 2017;11(7):4-7.

SUPPORTING INFORMATION

Additional supporting information may be found in the online version of the article at the publisher's website.

How to cite this article: Santonicco N, Marletta S, Pantanowitz L, et al. Impact of mobile devices on cancer diagnosis in cytology. *Diagnostic Cytopathology*. 2022;50(1):34-45. doi:10.1002/dc.24890