

OPERATIVE TECHNIQUES**Lateral border and scapular tip free flaps: Old school versus new school**

Allen L. Feng MD¹ | **Hassan B. Nasser MD²** | **Keith A. Casper MD²** |
Kelly M. Malloy MD² | **Chaz L. Stucken MD²** | **Mark E. Prince MD²** |
Andrew J. Rosko MD² | **Steven B. Chinn MD MPH²** | **Matthew E. Spector MD²**

¹Department of Otolaryngology—Head and Neck Surgery, Massachusetts Eye and Ear, Harvard Medical School, Boston, Massachusetts, USA

²Department of Otolaryngology—Head and Neck Surgery, University of Michigan, Ann Arbor, Michigan, USA

Correspondence

Allen L. Feng, Department of Otolaryngology—Head and Neck Surgery, Massachusetts Eye and Ear, Harvard Medical School, 243 Charles Street, Boston, MA 02114, USA.
 Email: allen_feng@mei.harvard.edu

Matthew E. Spector, Department of Otolaryngology—Head and Neck Surgery, University of Michigan, 1500 E. Medical Center Dr., Ann Arbor, MI 48109, USA.
 Email: mspector@med.umich.edu

Section Editor: Neil Gross

Abstract

Free tissue transfer from the subscapular system provides a wide array of options for both soft tissue and bony reconstruction. When bone stock is required for head and neck reconstruction, both the lateral scapular border free flap (LSBFF), supplied by the circumflex scapular artery, and the scapular tip free flap (STFF), supplied by the angular artery, are excellent options. Issues with positioning had previously prevented the widespread use of these bony subscapular system flaps. However, through the use of a Spider Limb Positioner, current clinical practice patterns allow for two team approaches in both of these free flaps. The following pictorial essay compares and contrasts the specific positioning and harvesting technique used for both the LSBFF and STFF, while discussing the clinical advantages and drawbacks of each. Both the lateral border scapula and scapular tip free flaps provide excellent bone stock for head and neck reconstruction. By positioning with currently available technology, both of these free flaps can be harvested through a two team approach.

KEYWORDS

head and neck reconstruction, lateral scapular border free flap, scapular tip free flap, spider limb, subscapular flap

1 | INTRODUCTION

The subscapular system is an important anatomic network for free tissue transfer to the head and neck. Since its first descriptions over 35 years ago, several institutions have used free tissue from this area as a primary means of performing osseous reconstruction.^{1,2} Since its inception, the majority of studies focused on the lateral scapular border free flap (LSBFF), supplied primarily from the periosteal perforators of the circumflex scapular artery.³ Subsequent investigations have described the angular artery as an independent vascular supply to the scapular tip.^{4,5} Although this was initially used in some cases to augment

the blood supply of the bone stock, the majority of recent reconstructive literature has focused on the scapular tip free flap (STFF) supplied solely by the angular artery.^{6,7}

After the adoption of the fibula free flap, the LSBFF was supplanted as the reconstructive option of choice for bony defects. This was largely due to the issues surrounding short pedicle length, limited mobility of the soft tissue component, and need for intraoperative repositioning. The introduction of the STFF eliminated many of these issues by leveraging the thoracodorsal system to provide a much longer pedicle and independently mobile soft tissue components.⁷ However, questions remained surrounding optimal positioning and the ability to perform a

simultaneous two team approach. Early descriptions for harvest of the subscapular system required sequential surgery with intraoperative repositioning.⁸ However, current positioning systems allow for two team approaches to the harvest of both LSBFF and STFF.^{9,10} The following pictorial essay describes the positioning pearls, operative technique, and clinical considerations for each of these free flaps. Institutional approval for this study was provided through the University of Michigan with informed consent obtained from all depicted patients.

2 | POSITIONING

First described by Stevens et al.,⁹ the use of the Spider Limb Positioner (Smith and Nephew, Andover, MA, USA) for harvest of the subscapular system has been adopted at many institutions. This has allowed for two team approaches for a variety of free flaps from this system. However, the majority of these studies do not distinguish between the optimal harvesting position for the LSBFF and STFF. Both require the patient to be on a bean bag in a semi-decubitus position, but differ in terms of the arm positioning used by the Spider Limb.

2.1 | Lateral scapular border

When harvesting the LSBFF, the extent of the semi-decubitus position is dependent on the laxity of the scapula. For younger patients with more skin laxity, the scapular border is generally more easily palpable. Figure 1A demonstrates the position of the arm during retraction with the Spider Limb Positioner. The forearm and upper arm are extended in parallel, while the entire arm is held approximately 30° above the horizontal plane of the patient's body. The thumb is pointed toward the patient to help avoid brachial plexus injury. There is ample room for the ablative team to perform concurrent surgery on the contralateral side of the head and neck. With slight alterations in arm positioning, concurrent surgery on the ipsilateral side is also possible; however, this may create some limitations during the posterior cuts of the harvest. Figure 2A demonstrates the vantage point of the reconstructive surgeon. The scapular border should be easily palpable in this position. The initial anterior incision is integrated into a vertical parascapular skin paddle, along the posterior border of the latissimus dorsi muscle, encompassing the triangular fossa at its superior aspect.

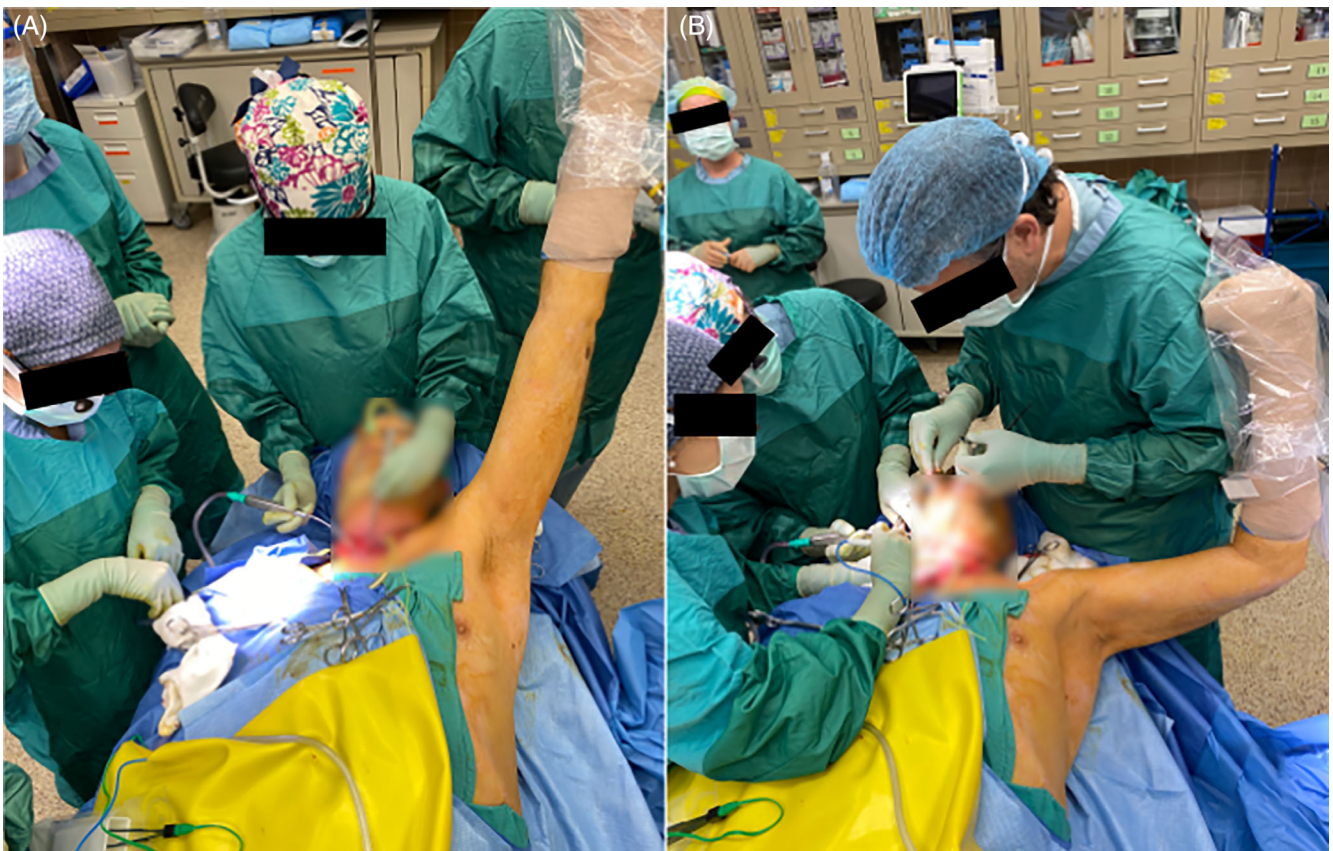

FIGURE 1 Spider Limb positioning for harvest of lateral scapular border or parascapular free flap (A) versus scapular tip free flap (B) as seen from overhead [Color figure can be viewed at [wileyonlinelibrary.com](https://onlinelibrary.wiley.com)]

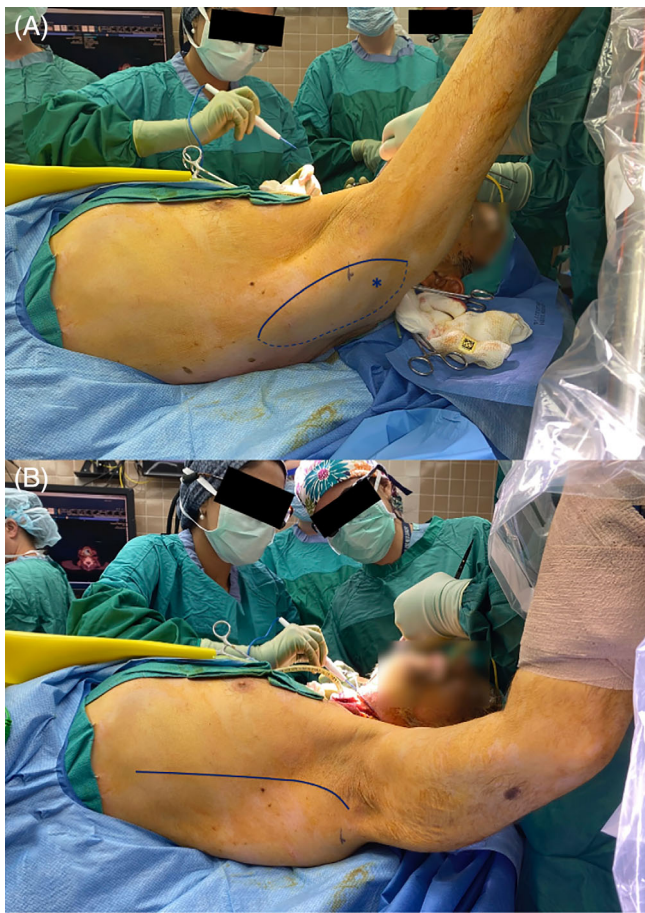


FIGURE 2 Positioning as seen from the reconstructive surgeon's point of view for harvest of lateral scapular border or parascapular free flap (A) where the solid line represents the initial anterior cut, dashed line represents the back cut, and (*) denotes the triangular fossa. This is contrasted to the positioning of the scapular tip free flap (B) where the solid line represents the initial anterior cut [Color figure can be viewed at wileyonlinelibrary.com]

2.2 | Scapular tip

The position of the arm during harvest of the STFF is shown in Figure 1B. Using the Spider Limb Positioner, the arm is abducted 90° from the patient's flank. The forearm is bent at a 90° angle relative to the upper arm while being held in a straight vertical position. Here, the thumb is also pointed toward the patient to avoid a brachial plexus injury. This configuration provides the ablative team more space at the resection site compared to the optimal LSBFF harvest position. Here, concurrent surgery can be performed on the ipsilateral side of the head and neck without impediment. Figure 2B demonstrates the reconstructive surgeon's point of view. The scapular tip should be easily palpable in this position along with the anterior border of the latissimus dorsi muscle. The initial incision is designed along the anterior border of

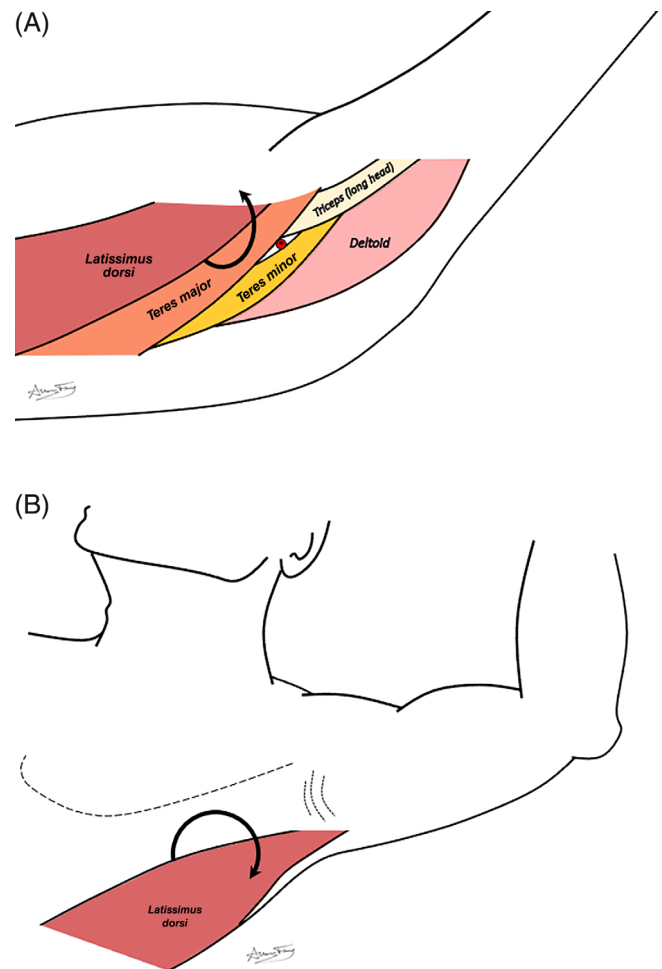


FIGURE 3 Depiction of the underlying musculature and initial steps for exposure of the lateral scapular border free flap (A) where the posterior border of the latissimus dorsi is reflected anteriorly, and scapular tip free flap (B) where the anterior border of the latissimus dorsi is reflected posteriorly [Color figure can be viewed at wileyonlinelibrary.com]

the latissimus dorsi muscle to allow posterior retraction of the muscle and subsequent exposure of the thoracodorsal system.

3 | OPERATIVE TECHNIQUE

3.1 | Lateral scapular border

First, the triangular fossa, located at the junction between the long head of the triceps muscle, teres major, and teres minor, is palpated and marked. As shown in Figure 2A, a vertical parascapular skin paddle is designed, overlying the scapular border, the teres major muscle, and encompassing the triangular fossa at its superior aspect. This ensures that the descending cutaneous branch of the circumflex artery, which travels inferiorly from the

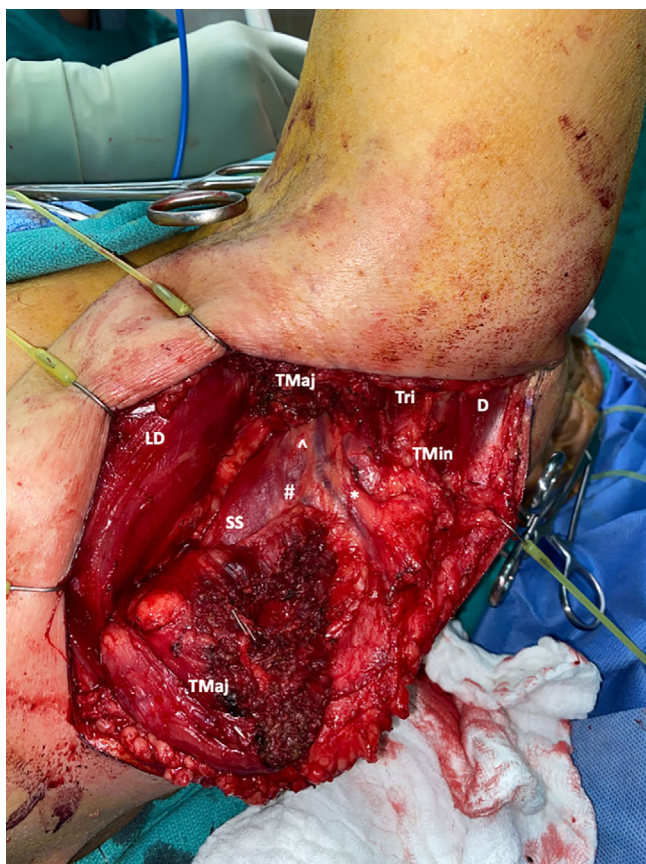

FIGURE 4 In vivo depiction of exposure seen during lateral scapula border harvest with overlying parascapular skin paddle. # = descending scapular branch; * = descending cutaneous branch; ^ = circumflex vessels; D = deltoid; LD = latissimus dorsi; SS = subscapularis; TMaj = teres major; TMin = teres minor; Tri = long head of triceps [Color figure can be viewed at wileyonlinelibrary.com]

triangular fossa, is captured within the skin paddle. A vertically oriented paddle is easier to harvest in this position, as the horizontal branch goes quite medial and the exposure is limited. Figure 3A demonstrates the relationship of the underlying muscles seen during the parascapular skin paddle elevation. Once the initial anterior skin incision is made, dissection to the underlying muscle is done to identify the latissimus dorsi and teres major muscles. After identifying the posterior border of the latissimus dorsi, it is reflected anteriorly to reveal the entirety of the teres major muscle and the scapular border. Dissection posteriorly along the teres major reveals the descending cutaneous branch of the circumflex vessels. This is done in a subfascial plane to protect the descending branch and ensure it remains within the overlying soft tissue of the parascapular skin paddle (which is elevated as an axial flap). Once the vascular pedicle of the skin paddle is identified, blunt dissection over the pedicle and into the triangular fossa is

done to isolate the teres major muscle and divide it. Remnant teres major muscle at the inferior aspect can be thinned and removed as needed. This provides access to the lateral border of the scapula bone, as seen in Figure 4. When soft tissue is desired, back cuts on the parascapular skin paddle can then be made, freeing it off the deltoid, triceps, and teres minor muscles. Small periosteal perforators superior to the junction of the descending cutaneous branch and descending scapular branch of the circumflex vessels are then clipped to free the scapula for bony cuts. Once the desired bone stock is measured, the soft tissue overlying the bone cuts (subscapularis, infraspinatus, and teres minor) is dissected away from the lateral scapula border. Bone cuts are then made with a reciprocating saw.

3.2 | Scapular tip

The anterior border of the latissimus dorsi muscle is first palpated, approximating the location of the initial anterior incision (Figure 2B). Once this incision is created, the anterior border of the latissimus muscle is identified and separated from the underlying serratus anterior muscle and chest wall. Once on its medial aspect, the latissimus dorsi muscle is reflected posteriorly (Figure 3B). An avascular plane between the latissimus dorsi and the chest wall allows for blunt dissection and quick identification of the thoracodorsal artery. The latissimus branch of the thoracodorsal artery is then traced proximally to isolate the angular branch that travels to the scapular tip. Continued pedicle dissection reveals the circumflex and subscapular vessels. With this full exposure (seen in Figure 5), soft tissue cuts are made to partially transect the teres major at the proximal portion of the desired bone stock. Similarly, distal cuts to separate the serratus anterior at the scapular tip are performed. Medially, soft tissue cuts through the subscapularis are also created down to the medial edge of the desired bone. Once the appropriate bone stock is isolated from the surrounding soft tissue, the bone is freed using the reciprocating saw. If a soft tissue component is desired, back cuts can be made through the latissimus dorsi and its overlying skin. Less commonly, the circumflex scapular branches can be traced, and a parascapular paddle can also be elevated.

4 | DISCUSSION

The ability to harvest bone from the subscapular system has made it an important tool in the reconstructive armamentarium. Although there are subtle differences in

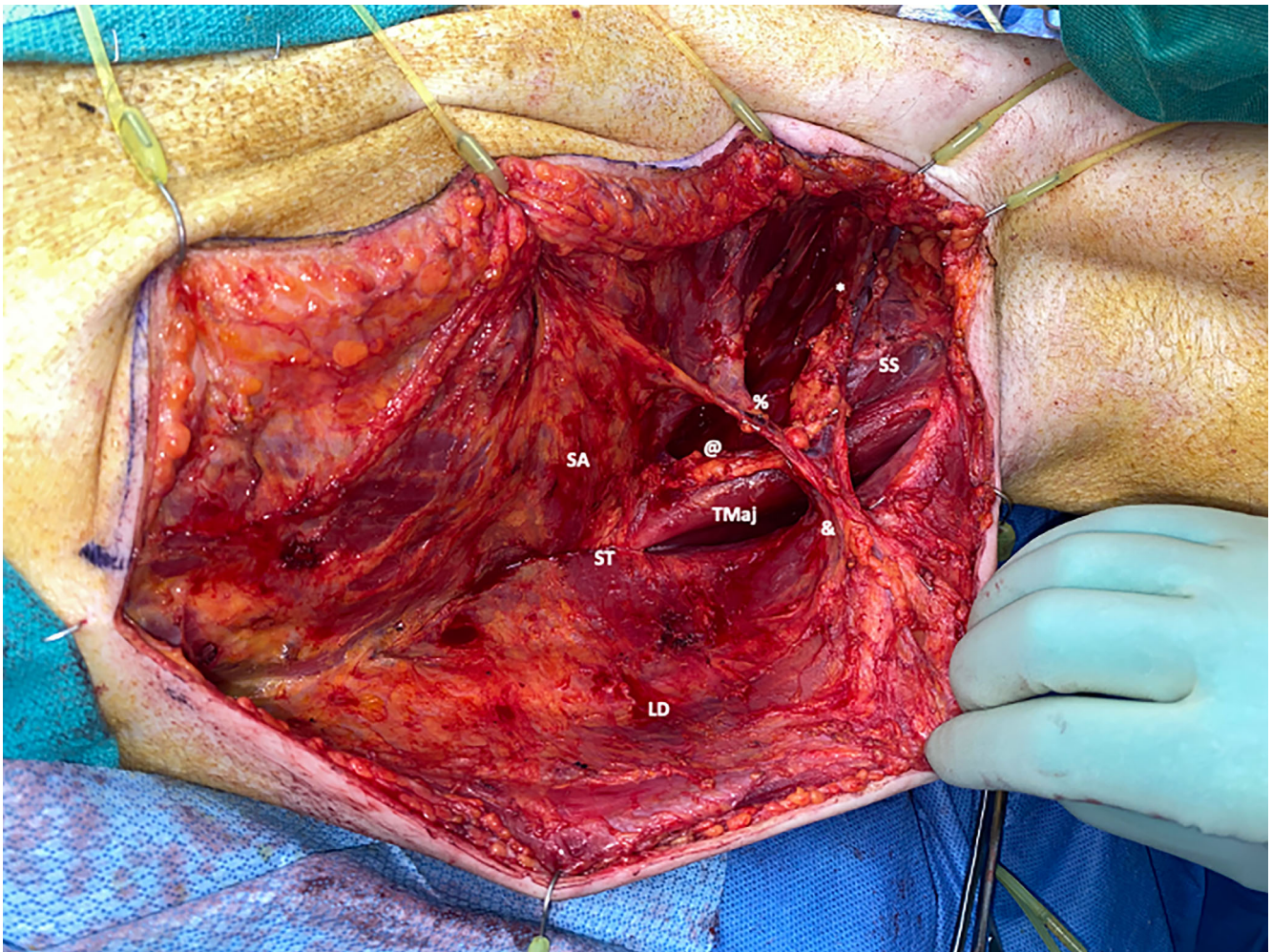


FIGURE 5 In vivo depiction of exposure seen during scapular tip harvest with latissimus dorsi soft tissue paddle. % = serratus anterior branch; & = latissimus dorsi branch; * = thoracodorsal vessels; @ = angular branch; LD = latissimus dorsi; SA = serratus anterior; SS = subscapularis; ST = scapular tip; TMaj = teres major [Color figure can be viewed at wileyonlinelibrary.com]

positioning between the LSBFF and STFF, simultaneous two-team approaches are possible in both cases with the Spider Limb Positioner. The orthogonal positioning of the arm during STFF harvest provides the ablative team with ample room on the ipsilateral side of the neck. In contrast, the more posterior access that is needed for the LSBFF is achieved by holding the arm in a more extended and medial position. Although this limits access to the ipsilateral neck, concurrent surgery for a majority of the case is still possible. However, the slight curvature of the LSBFF and orientation of the pedicle make it ideally suited to reconstruct the contralateral mandibular body.¹¹ This allows full access to the operative field for the ablative team during harvest.

Our group has consistently adopted the Spider Arm for both the LSBFF and STFF and provides a number of advantages, including the ability to finely reposition, elimination of an assistant to hold the arm, and a two team approach to improve surgical efficiency.⁹

Disadvantages include both the cost of the Spider Arm and need to learn new instrumentation, although many institutions already employ this device for orthopedic surgery. Traditional lateral decubitus and semi-lateral approaches using a Mayo stand have been well described in the literature,^{2,8,12} and these positioning techniques have no associated device cost. However, these approaches do not allow for a full two team approach while also requiring an assistant to hold the patient during the majority of the dissection. Importantly, it may also require a second prep and draping of the patient during repositioning.

Positioning aside, there are important clinical considerations when using the LSBFF or STFF. Two of the major limitations of the LSBFF are the short pedicle length and difficult geometry when used in conjunction with a separate skin paddle. The periosteal perforators of the descending scapular branch and axial pattern of the descending cutaneous branch limit orientation options

for the parascapular skin paddle. In comparison, the STFF has a much more independent soft tissue paddle and a pedicle length that routinely reaches 15 cm.^{6,7} However, the thickness of the STFF skin paddle can be limiting in patients with increased body mass index. In these cases, the musculofasciocutaneous latissimus dorsi segment may be too thick to resurface certain oral cavity defects. Thinning these segments is also difficult due to the random location of cutaneous perforators from the latissimus dorsi muscle to overlying skin. The parascapular skin paddle of LSBFF is often thinner and more easily shaped to a given defect. When considering functional outcomes, both the LSBFF and STFF harvest result in some objective limitations to shoulder movement. However, there is no significant difference between the two sites, and in most cases, subjective morbidity is limited.¹³

5 | CONCLUSIONS

The LSBFF and STFF are important options for bony reconstruction. The bone stock of the LSBFF may be more robust, but the increased pedicle length and improved soft tissue mobility of the STFF have made it the bony option of choice in the subscapular system. In both cases, widespread adoption had historically been limited by positioning issues. However, recent advancements have allowed both of these free flaps to be harvested using two-team approaches.

AUTHOR CONTRIBUTIONS

All the authors contributed to the study conceptualization. Allen L. Feng contributed to manuscript preparation, study design, and writing. Allen L. Feng and Matthew E. Spector contributed to the critical manuscript review and editing. All illustrations were created by Allen L. Feng.


DATA AVAILABILITY STATEMENT

Data sharing not applicable - no new data generated.

ORCID

Allen L. Feng  <https://orcid.org/0000-0002-8040-5299>

Mark E. Prince  <https://orcid.org/0000-0002-1120-9008>

Matthew E. Spector  <https://orcid.org/0000-0001-7646-6075>

REFERENCES

1. Teot L, Bosse JP, Moufarrege R, Papillon J, Beaugard G. The scapular crest pedicled bone graft. *Int J Microsurg*. 1981;3: 257-262.
2. Swartz WM, Banis JC, Newton ED, Ramasastry SS, Jones NF, Acland R. The osteocutaneous scapular flap for mandibular and maxillary reconstruction. *Plast Reconstr Surg*. 1986;77: 530-545.
3. Urken ML, Bridger AG, Zur KB, Genden EM. The scapular osteofasciocutaneous flap: a 12-year experience. *Arch Otolaryngol Head Neck Surg*. 2001;127:862-869.
4. Van Thienen CE, Deraemaeker R. The serratus anterior scapular flap - a new osteomuscular unit. *Eur J Plast Surg*. 1988;11: 151-161.
5. Coleman JJ 3rd, Sultan MR. The bipedicled osteocutaneous scapula flap: a new subscapular system free flap. *Plast Reconstr Surg*. 1991;87:682-692.
6. Yoo J, Dowthwaite SA, Fung K, Franklin J, Nichols A. A new angle to mandibular reconstruction: the scapular tip free flap. *Head Neck*. 2013;35:980-986.
7. Chepeha DB, Khariwala SS, Chanowski EJ, et al. Thoracodorsal artery scapular tip autogenous transplant: vascularized bone with a long pedicle and flexible soft tissue. *Arch Otolaryngol Head Neck Surg*. 2010;136:958-964.
8. Urken ML, Sullivan MJ. Scapular and parascapular fasciocutaneous and osteofasciocutaneous. In: Urken ML, Sullivan MJ, eds. *Atlas of Regional and Free Flaps for Head and Neck Reconstruction*. Raven Press; 1995:217-236.
9. Stevens JR, Rosko AJ, Marchiano E, et al. The Spider Limb Positioner in subscapular system free flaps. *Oral Oncol*. 2018; 85:24-28.
10. Feng AL, Nasser HB, Rosko AJ, et al. Revisiting pedicled latissimus dorsi flaps in head and neck reconstruction: contrasting shoulder morbidities across myofascial flaps. *Plast Aesthet Res*. 2021;8. doi:10.20517/2347-9264.2021.03
11. Tran KL, Wang E, Fels S, Hodgson A, Prisman E. Versatility of a single piece scapular tip and lateral border free flap for mandibular reconstruction: a virtual study on angle correspondence. *Oral Oncol*. 2021;121:105379.
12. Eskander A, Kang SY, Ozer E, et al. Supine positioning for the subscapular system of flaps: a pictorial essay. *Head Neck*. 2018; 40:1068-1072.
13. Patel KB, Low TH, Partridge A, et al. Assessment of shoulder function following scapular free flap. *Head Neck*. 2020;42:224-229.

How to cite this article: Feng AL, Nasser HB, Casper KA, et al. Lateral border and scapular tip free flaps: Old school versus new school. *Head & Neck*. 2022;44(2):576-581. doi:10.1002/hed.26905