

Resolution of Peri-implantitis by means of Implantoplasty as adjunct to Surgical Therapy: A Retrospective Study

Alberto Monje, DDS, MS, PhD*†‡, Ramón Pons, DDS, MS*, Ettore Amerio, DDS, MS*, Hom-Lay Wang, DDS, MS, PhD†, José Nart, DDS, PhD*

* Department of Periodontology, Universidad Internacional de Catalunya, Barcelona, Spain

† Department of Periodontology, School of Dental Medicine, University of Michigan, Ann Arbor, USA

‡ Private practice, Division of Periodontics, Centro de Implantología Cirugía Oral y Maxilofacial (CICOM), Badajoz, Spain

Corresponding author:

Alberto Monje, DDS, MS, PhD

Department of Periodontology Universitat Internacional de Catalunya

C/ Josep Trueta s/n, 08195

Sant Cugat del Vallès, Barcelona, Spain. Tel: 0034 93 504 20 00

E-mail address: amonjec@umich.edu

Telephone: +34924203045

Word account: 3692

Running title: Surgical therapy of peri-implantitis

Summary: Implantoplasty as adjunct to the surgical managed of peri-implantitis proved effectiveness in resolving inflammation

This is the author manuscript accepted for publication and has undergone full peer review but has not been through the copyediting, typesetting, pagination and proofreading process, which may lead to differences between this version and the [Version of Record](#). Please cite this article as [doi: 10.1002/adfm.10772](#).

This article is protected by copyright. All rights reserved.

Conflict of interest: The authors declare no direct conflict of interest.

Sources of funding for the study: None

MeSH keywords: peri-implantitis; peri-implant endosseous healing; dental implantation; dental implant; alveolar bone loss

Author contribution: Dr. Alberto Monje designed the study protocol, obtained the sample data and wrote the manuscript. Ettore Amerio contributed to the statistical analysis. Dr. Ramón Pons analyzed the data. Dr. Dr. José Nart and Hom-Lay Wang participated in interpretation of the data and critically reviewed the manuscript.

Abstract

Background: There is a paucity of data on the effectiveness of implantoplasty as adjunct to the surgical management of peri-implantitis.

Purpose: To evaluate the resolution of peri-implantitis by means of implantoplasty as adjunct to surgical resective (RES) and reconstructive (REC) therapies and supportive maintenance.

Material and methods: Patients that underwent surgical therapy to manage peri-implantitis with a follow-up of ≥ 12 months enrolled in a regular peri-implant supportive care were recruited. RES group consisted of two interventions that comprehended osseous recontouring and apically position flap (APF) and soft tissue conditioning (STC). REC was performed in the infra-osseous compartment of combined defects. Implant survival rate was recorded. Clinical and radiographic parameters were evaluated to define a “dogmatic” (case definition #1) and a “flexible” (case definition #2) therapeutic success. Univariate and multivariate multilevel backward logistic regression were applied for statistical analysis.

Results: Overall, 43 patients ($n_{\text{implants}}=135$) were retrospectively assessed. Mean observational period was ~ 24 months. Implant survival rate was 97.8%, being significantly higher for APF, STC and APF + STC (RES) when compared to REC ($p=0.01$) therapy, in particular for advanced lesions ($>50\%$ of bone loss). The overall therapeutic success rate at implant-level was 66% and 79.5% for case definition #1

and #2, respectively. APF group displayed more efficient disease resolution when considered success definition #1 (72%). Contrarily, when the data was adhered to success definition #2, STC group proved slightly more disease resolution rate (87%). For RES group, location, favoring anterior ($p=0.04$) and defect type, favoring class II ($p=0.02$) displayed statistical significance for therapeutic success. For REC group, implants exhibiting wider band of keratinized mucosa demonstrated higher therapeutic success ($p=0.008$).

Conclusion: Implantoplasty as adjunct to surgical therapy resulted effective in terms of disease resolution and implant survival rate. Implant location, defect morphology as well as the buccal width of keratinized mucosa are indicators of therapeutic success.

Introduction

Peri-implantitis, regarded as an inflammatory disease evoked by pathogenic bacteria,¹ can potentially compromise implant longevity.² Epidemiological reports suggest a prevalence of ~2 out of 10 implant carriers.³ Few elements, such as history of periodontitis and poor self-performed/professionally-administered plaque control have been identified as risk factors.⁴ Others, instead, have been named as predisposing (i.e., lack of keratinized mucosa, poor surgical performance, and inadequate prosthetic design), precipitating (i.e., residual submucosal cement and residual dental floss) and acceleratory (i.e., surface topographic characteristics) factors.⁵ It is crucial to remark that these factors have to be controlled for the effective primary prevention of peri-implantitis.⁶ Alike, these contributors have to be identified and addressed for the efficient management of the disorder.

With the growing burden of peri-implantitis around the globe, interest has flourished on the management of this pathology.³ Nevertheless, lack of consensus exists in the pursuit of a predictable therapy.⁷ Different therapeutic modalities have been

advocated. Non-surgical therapy as a sole modality is often insufficient to resolve inflammation.^{8, 9} Surgical interventions have demonstrated more favorable outcomes.¹⁰ Amongst these, evidence supported the application of resective,^{11, 12} reconstructive,^{13, 14} or combined^{15, 16} approaches to limit progressive bone loss and achieve soft tissue health. Nevertheless, up to date, the most suitable modality remains unknown and the decision-making process derives from the understanding acquired from the management of periodontitis.

One critical element regarded to successfully resolve peri-implantitis is to efficiently detoxify the contaminated implant surface. Mechanical, pharmacological and chemical strategies have been proposed to eliminate bacterial plaque and remnants from the implant surface.¹⁷ However, evidence has not demonstrated superiority of a given detoxification agent/strategy.¹⁷ In fact, surface detoxification is often inefficient and limited by implant surface characteristics and surface geometry.¹⁸ Implantoplasty was proposed as a mechanical method to smoothen the implant threads while detoxify the implant surface.^{11, 19} Under the hypothesis that surface contamination may occur subsequent to the therapy of peri-implantitis, topographic and geometric (i.e., implant threads) features are modified using rotatory instruments and/or polishing stones.

The purpose of the present retrospective study was to assess the resolution rate of peri-implantitis following implantoplasty as an adjunct to surgical therapy and supportive care for ≥ 12 months.

Material and methods

A retrospective cohort study was conducted in accordance with the Helsinki declaration of human studies and received approval from the ethics committee of the Gerencia del Area de Salud de Badajoz. The manuscript is reported according to the STROBE statement.²⁰

Study sample

Patients that received surgical therapy to manage peri-implantitis from October 2017 up to January 2020 with a follow-up of ≥ 12 months enrolled in a regular peri-implant supportive care were eligible. The following criteria were applied: all patients in age of 18 to 80, non-smokers, implants >3.7 mm in diameter,²¹ with no presence of infectious diseases at the time of implant placement or during the maintenance program, with no presence of systemic disease or medication known to alter bone metabolism, and partial/complete edentulous patients that had no active periodontal disease. Subjects were excluded due to pregnancy or lactation, former (<10 years) or current smoking and uncontrolled medical conditions. Few of the patients analyzed for other 12-month studies published elsewhere^{13, 22} were further recruited for this study to report the outcomes with longer follow-up.

Case definition of peri-implantitis

Peri-implantitis was defined according to the 2017 Word Workshop of Periodontal and Peri-implant diseases.¹ Hence, the case definition applied was as follows: presence of bleeding and/or suppuration on gentle probing (~ 0.2 N), probing pocket depths of ≥ 6 mm, bone levels ≥ 3 mm apical of the most coronal portion of the intraosseous part of the implant based on periapical x-ray. If the examiner deemed unsuitable access, the prosthesis was retrieved for accurate diagnosis.

Clinical assessment

The following clinical parameters and indices were recorded at the latest check-up:

- Probing pocket depth (PPD) recorded in millimeter using a North Carolina Probe
- Modified sulcular bleeding index (mBI) that scored 0-3 according to the extensiveness and severity of bleeding on probing (BOP).²³

- Modified plaque index (mPI) that score 0-3 according to the visibility and severity of plaque accumulation.²³
- Mucosal recession (MR) was defined as the distance in mm from the implant-abutment connection as a steady mark and the mucosal margin
- Keratinized mucosa (KM) around dental implants, measured from free mucosal margin to mucogingival junction at mid-buccal position, to the nearest millimeter using a North Carolina Probe.
- Suppuration (SUP) index around implants applied according to the grade of SUP: grade 0=no SUP or non-suppurative exudate; grade 1=SUP manifesting ≥ 15 seconds after gentle probing or SUP at a single spot (dot); grade 2=SUP manifesting < 15 seconds after gentle probing or profuse SUP (drop or line) forming a confluent line; grade 3=spontaneous SUP manifesting through the peri-implant sulcus upon palpation/compression of the peri-implant soft tissues.²⁴

Definition of disease resolution

Successful treatment was evaluated at the latest evaluation. Peri-implantitis was considered "resolved" if the following "dogmatic" case definition was (definition#1):

- Lack of bleeding and/or suppuration on gentle probing ($\sim 0.2N$)
- Probing pocket depths of $\leq 5\text{mm}$
- No radiographic progressive bone loss within the standard error $\geq 1\text{mm}$ ²⁵

An alternative and more "flexible" case definition was proposed (definition#2):

- ≤ 2 dots of light bleeding on gentle probing ($\sim 0.2N$)
- Lack of suppuration on gentle probing ($\sim 0.2N$)
- Probing pocket depths of $\leq 5\text{mm}$
- No radiographic progressive bone loss within the standard error $\geq 1\text{mm}$ ²⁵

Radiographic assessment

The peri-implant radiographic bone loss (MBL) was determined at T_B (baseline) and at latest follow-up examination T_F (final) by taking linear measurements from the most mesial and distal point of the implant platform to the crestal bone on each peri-apical radiograph, corrected according to the known implant pitch.

Peri-implantitis bone defect morphology and severity

Characterization of the peri-implantitis defects was based on defect morphology (Classes I-III) and severity (grades S-M-A), as proposed elsewhere.²⁶ Briefly, according to the morphology was classified as follows: Class I: infra-osseous defect (Class Ia: buccal dehiscence, Class Ib: 2-to 3-wall defect), Class II: supra-crestal /horizontal defect, and Class III: combined defect (Class IIIa: buccal dehiscence + horizontal bone loss, Class IIIb: 2- to 3-wall defects + horizontal bone loss, Class IIIc: circumferential defect + horizontal bone loss). Regarding severity, implants were graded as: Slight (S): 3 to 4 mm/<25% of the implant length, moderate (M): 4 to 5 mm/ \geq 25% to 50% of the implant length, and advanced(A):>6 mm/>50% of the implant length.

Non-surgical therapy phase

Oral hygiene instructions were taught as part of the diagnostic phase. All eligible patients diagnosed with peri-implantitis underwent non-surgical therapy at least 6 weeks prior to the surgical reconstructive phase by one operator (AM). Briefly, ultrasonic debridement using a metal tip*, a “mini-five” curette† and site-specific Gracey curettes‡ were used for scaling and debridement of the peri-implant sulcus.

* # 100 Universal, Hu-Friedy, Chicago, IL, USA

† Hu-Friedy, Chicago, IL, USA

‡ Hu-Friedy, Chicago, IL, USA

Sub-mucosal irrigation was profusely applied with chlorhexidine 0.12%[§]. Cover screws for implants candidate to reconstructive therapy and healing abutments for those implants that were candidate to resective modalities were placed >2 weeks before the surgical phase.

Decision-making process for the surgical modality

Two different therapeutic modalities were applied according to the clinical scenario (Figure 1).

- *Surgical resective modality: Indicated for class Ia, II or IIIa.*

A partial thickness flap was raised to have sufficient access on the buccal site of the diseased implants. The surgical approach was tailored to the scenario. As such, resective therapy, concerning soft tissue resection and osseous recontouring, was performed with the goal of achieving a flat architecture and reducing peri-implant pathogenic pockets (>5mm). Moreover, on the buccal aspect, the mucosal flap was apically repositioned (APF group). Implantoplasty was performed with a special tungsten carbide bur** and an Arkansas bur†† (Figure 2). In cases exhibiting insufficient keratinized mucosa (<2mm) at the buccal aspect, simultaneous soft tissue grafting by means of free epithelial graft was performed (STC group). These were harvested from the palate. The extension was calculated according to the number of implants to be treated using a 15C blade. The graft was then soaked in saline solution and sutured using Nylon 5.0†† and/or 6.0^{§§}. Surgical cyanoacrylate*** was applied thereafter to protect the donor wound.

- *Surgical reconstructive modality: Indicated for class Ib, IIIb or IIIc.*

[§] Perioaid, Dentaid, Barcelona, Spain

^{**} Meisinger LLC, Nauss, Germany

^{††} Meisinger LLC, Nauss, Germany

^{‡‡} Resorba® Sutures, Osteogenics Biomedical, Lubbock, TX, USA

^{§§} Vycril®, Ethicon Inc, New Jersey, USA

^{***} Peryacril® 90HV, Glustitch Inc, Delta, Canada

A full-thickness flap was raised to have sufficient access. Debridement of granulation tissue was conducted subsequently using a “mini-five” curette^{†††}, site-specific Gracey curettes^{†††} and NiTi brushes^{§§§}. The surgical approach was tailored to the scenario. As such, implantoplasty was performed for supra-crestal defects^{****}. Surface detoxification was performed with hydrogen peroxide (3%) for 2 minutes and irrigation with chlorhexidine 0.12%. The intra-osseous compartment was grafted using either autogenous particulate graft harvested from the neighboring of the recipient site mixed with xenogeneic particulate graft^{††††} in an equal ratio or a mixture of cortical: cancellous mineralized bone^{††††}. Both bone mixtures were applied under similar indications and conditions. The graft was compartmentalized with a collagen porcine absorbable membrane^{§§§§} adapted to the defect morphology (REC group). Whenever possible, the membrane was stabilized with tacks^{****}. Nylon 5.0^{†††††} was used for suturing ensuring primary wound closure (Figure 2 and 3).

Post-operative care

Patients were prescribed to apply 3 times a day chlorhexidine gel in the area for 2 weeks^{†††††}, and systemic amoxicillin 750mg 2 tablets a day for 7 days was also prescribed. Moreover, anti-inflammatory medication (Ibuprofen, 600mg, 1table every 5-6 hours for 5 days) was prescribed. In 2-3 weeks, the sutures were removed, and oral hygiene resumed. Implants were exposed via minimally invasive approach

††† Hu-Friedy, Chicago, IL, USA

††† Hu-Friedy, Chicago, IL, USA

§§§ Hans Korea Co., Gyeonggi-do, Korea

**** Meisinger LLC, Naus, Germany

†††† Bio-Oss®, Geistlich Pharma, Wolhusen, CH

†††† LifeNet Health, Virginia, USA

§§§§ Creoss TM xenoprotect, Nobel BioCare Services AG, Zurich, CH

**** Meisinger LLC, Naus, Germany

††††† Resorba® Sutures, Osteogenics Biomedical, Lubbock, TX, USA

††††† Lacer MucoRepair®, Lacer, Barcelona, Spain

mobilizing >2mm towards the buccal aspect. The FPDs were placed on the implants ≥ 8 weeks after the surgical intervention.

Recall program

During the first 2 months, patients were appointed on a 2-week basis after suture removal for professional-administered oral hygiene measures in the grafted area. If proper oral hygiene was precluded by the faulty restorative access with interproximal brushes, modification of the prosthesis design was made until the access was satisfying. All the patients enrolled in the present study adhered thereafter to a 3-month recall peri-implant maintenance therapy program supervised by the principal investigator during the first year after surgery. A 6-month recall was scheduled thereafter.

Statistical analysis

Categorical variables were reported as mean and standard deviation (SD), relative and percentage frequencies were used to describe quantitative variables. Differences between groups were tested using Chi-squared test or Fisher's exact test (if at least one cell was ≤ 5) for categorical variables and parametric or non-parametric tests were employed for continuous variables, after testing the normality of the distribution (Shapiro-Wilk test). In order to identify the factors associated with implant success, a univariate multilevel logistic (patient, implant) regression analysis was implemented employing generalized estimating equations (GEE). Success definition 2 was used as dependent variable and age, gender, follow-up, soft tissue conditioning, implant position, severity of peri-implantitis, keratinized mucosa, number of plaque positive sites, presence of an infra-osseous component (i.e., class I and class III defects vs. class II defects) and mean angle were used as independent variables. Only variables that presented a p -value ≤ 0.10 in the univariate analysis were introduced in the multivariate model that consisted of a multivariate multilevel backward logistic regression. Level of significance was set at 0.05. A statistical software IBM SPSS Statistics 26 was used for all calculations.

Results

Demographic data

Overall, 53 patients were eligible. Of these, 8 were excluded from analysis as they were erratic or non-compliers (overall compliance rate= 84.4%), one was excluded as the patient was referred to another dentist to supportive maintenance due to the geographic distance to our practice and one patient deceased in February 2020. Overall, 43 patients ($n_{\text{implants}}=135$) were retrospectively assessed. Demographic data at patient- and implant-level are presented in table 1. Overall, 79% were female with a mean age of 61.4 ± 10.2 years. Mean follow-up was 23.4 ± 8.9 months (range=12-40 months). Mean number of peri-implantitis implants per patient was 3.14 ± 2.15 (range=1-8). The majority of the peri-implantitis analyzed were in maxillary (61%) and posterior (72%) implants. None of the patient-level or peri-implantitis-related variables displayed significance between groups, with the exception of type defect ($p < 0.001$). The vast majority of peri-implantitis were managed by means of APF (43%) followed by APF + STC (34%) and REC (23%).

Peri-implantitis defect morphology and severity

Mean baseline $MBL_{\text{(mesial)}}$ and $MBL_{\text{(distal)}}$ were 4.79 ± 1.78 mm and 4.90 ± 1.82 mm, respectively. Mean baseline defect angle_(mesial) and defect angle_(distal) were $53.94 \pm 19.65^\circ$ and $52.16 \pm 19.30^\circ$, respectively. Class II was the dominant defect morphology, representing 39% of the overall study sample. Furthermore, 21%, 11%, 14%, 5% and 10%, were classified as class Ia, Ib, IIIa, IIIb and IIIc peri-implantitis defects, respectively. Concerning severity, 21%, 38% and 41% were S, M and A, respectively (Table 1).

Implant survival rate

Overall, implant survival rate at patient-level was 95.3%. At implant-level, survival rate was 97.8%, being significantly higher for APF and APF + STC (RES) when compared to REC ($p=0.01$) (Table 1)(Figure 3). Implant failure occurred only in A peri-implantitis implants.

Therapeutic success at patient-level

The overall therapeutic success rate at patient level was 35% and 58% for case definition #1 and #2, respectively. None of the interventions evaluated resulted in a statistically significant higher success rate when compared to others (success definition #1: $p=0.14$; success definition #2: $p=0.92$). REC group displayed more efficient disease resolution when considered success definition #1 (50%). Contrarily, when the data was adhered to success definition #2, STC group proved higher disease resolution rate (75%).

Therapeutic success at implant-level

The overall therapeutic success rate at implant-level was 66% and 79.5% for case definition #1 and #2, respectively. None of the interventions evaluated resulted in a statistically significant higher success rate when compared to others success definition #1: $p=0.29$; success definition #2: $p=0.18$). APF group displayed the most efficient disease resolution when considered success definition #1 (72%). When the data was adhered to success definition #2, STC group proved higher disease resolution rate (87%) compared to other groups (Table 1)(Figure 3).

Indicators of therapeutic success

For RES (APF+STC) group, at the univariate level analysis, follow-up displayed statistical significance favoring for shorter-term evaluations ($p=0.02$). Alike, the GEE at multivariate multilevel analysis demonstrated statistically significant lower therapeutic success for peri-implantitis in posterior implants (OR=0.1; $p=0.04$) and significantly higher success rate for class II defects (OR=3.7; $p=0.02$) (Figure 4). For REC group, implants exhibiting wider band of KM demonstrated higher therapeutic success (OR=2.2; $P=0.008$) (Figure 5). The GEE at multivariate multilevel analysis validated this finding (OR=5.9; $p=0.001$).

Comparison clinical and radiographic parameters

None of the clinical parameters yielded statistical significance when compared the different therapeutic modalities. On the other side, radiographic bone level significantly favored for REC when compared to APF ($p < 0.001$) and SCT ($p = 0.008$).

Discussion

Main findings

The basis for the therapy of peri-implantitis falls in surface detoxification and debridement given its infectious nature. Emerging evidence has proven that this is a challenging task by mechanical, chemical or pharmacological means.²⁷ Implantoplasty, on the other side, seems to be effective to eliminate the surface toxins at the expense of modifying implant macro-geometry. The findings indicate that implantoplasty as adjunct to surgical RES (APF/STC) or REC modalities is effective in terms of implant survival and disease resolution, in particular when adhering therapeutic success to a "flexible" definition. Furthermore, findings from this retrospective study pointed out that implant location, defect morphology as well as the buccal width of KM are indicators of therapeutic success.

Agreements and disagreements with previous studies

Up to 15 years ago, only 1 case report was published advocating "implantoplasty" as surface detoxification method.²⁸ In December 2020, 14 articles were yielded,²⁹⁻⁴² where *in-vitro* studies are dominant. Thereupon, it seems that there is a growing interest of this approach as adjunctive therapy to peri-implantitis; nonetheless, yet, evidence is sparse.

Up to date, two randomized clinical trials have been published,^{11, 19, 41} one of them showing short-term (6-month follow-up) outcomes. Romeo et al. (2005-2007) documented the effectiveness of resective therapy + implantoplasty when compared with resective approach alone. At 3-year follow-up, bone stability was

noted with seldom progressive bone loss with greater PPD reduction, while bone level at the control group progressed ~1.5mm and exhibited significantly deeper pockets. This resulted in a difference of ~12% in terms of survival rate.^{11, 19} Recently, Lasserre et al. (2020), in a 6-month follow-up, showed that implantoplasty and glycine air abrasion yielded similar clinical outcomes in the surgical non-augmentative management of peri-implantitis.⁴¹

Case series and case-control studies have further inquired on the clinical effectiveness of implantoplasty as adjunct to surgical therapeutic modalities. Pommer et al. (2016) in a comparative study of surgical modalities for the management of peri-implantitis yielded a 9-year cumulative survival rate of ~87%.⁴³ Englezos et al. (2018) reported the 2-year follow-up data on resective approach combined with implantoplasty. Overall, 100% survival implant rate and ~92% stable bone levels were reported with a mean PPD reduction of ~5mm.¹² Bianchini et al. (2019) in a 3-year follow-up case series demonstrated stable bone levels at 87% analyzed implants after implantoplasty combined with resective therapy.⁴⁴ Findings from the same group (2019) supported bone stability and PPD reduction when compared to other surgical interventions to manage peri-implantitis over 3 years.⁴² Ravidà et al. (2020) in a retrospective comparative study analyzed implant survival and clinical/radiographic outcomes of peri-implantitis cases managed via resective therapy with (test) or without (control) adjunct implantoplasty. Interestingly, implants in the test group responded more favorably considering the higher survival rate (90% vs. 81.6%) over a mean ~3-year period, although not reaching statistical significance.³⁴ In addition, this study pointed out that the probability of implant failure was largely influenced by the MBL at baseline. For example, implants exhibiting advanced (>50%) and moderate (25-50%) bone loss were 18.6x and 8.86x more likely to fail, respectively when compared to <25% MBL. More importantly, the clinical improvement of these clinical parameters was positively correlated to the number of supportive peri-implant therapy that patient received.³⁴ In this context, our findings in compliers with supportive maintenance therapy are in partial agreement with aforementioned data. In particular, the RES group achieved a survival rate of 100%, being APF the most successful therapeutic modality when adhered to the “dogmatic” definition.

Other authors have reported implantoplasty as adjunct to a combined therapeutic approach (so-called combined approach). Schwarz et al. (2011) described the protocol for the combined surgical resective and reconstructive approach using implantoplasty for the implant area within the supra-crestal component (i.e., horizontal pattern of bone loss).⁴⁵ Schwarz et al. (2013) demonstrated in a 4-year report in advanced peri-implantitis that regardless of surface detoxification at the infra-osseous compartment, BOP tended to reduce ~78% from baseline and clinical attachment level to increase ~1.4mm.⁴⁶ Years later, the 7-year follow-up corroborated the stability of the outcomes.⁴⁷ Schwarz et al. (2014) showed that the combined approach in conjunction with soft tissue volume augmentation procedures was effective in reducing BOP (~75%), PPD (~2.5mm) and in gaining clinical attachment (~2mm).¹⁵ Effectiveness of this approach was further documented by others.^{13, 33, 48, 49} Results from the present study are congruent with previous. In terms of implant survival, the rate yielded was 90%, being significantly lower when compared to RES group. Disease resolution was 74% when the “flexible” definition of success was embraced. In addition, the width of KM at the buccal aspect was found to be indicator of therapeutic success. This is contrary to previous findings on implantoplasty as adjunct to surgical resective therapy as KM was shown to be a negligible factor on therapeutic success.⁵⁰

What are the limitations of implantoplasty?

Several *in-vitro* studies have pointed out shortcomings associated to implantoplasty.^{21, 35, 51} Firstly, it is technically demanding and time consuming. In particular, access to the interproximal areas is often limited, which negatively impact upon the efficacy of the procedure. Moreover, it has been suggested that the mean time to achieve a smooth surface ($S_a = 0.1\mu\text{m}$) is ~10 minutes.⁵² Secondly, largest concerns of implantoplasty arise from the biomechanical perspective. Chan et al. (2013) demonstrated that the mean bending strength of narrow implants (3.75mm) was significantly reduced by implantoplasty (511.4 ± 55.9 N versus 613.9 ± 42.8 N), while implantoplasty did not affect the strength of wide implants (4.7mm).²¹

Hence, cautiousness should be exercised when applying implantoplasty on narrower, freestanding implants that are subject to greater occlusal force. Gehrke et al. (2016) showed that mean fracture strength was significantly reduced for internal hexagon (40% reduction) compared to external hexagon (37% reduction) and morse taper (20% reduction) implants after implantoplasty.⁵¹ Camps-Font et al. (2020) further shed light on the increased risk to fracture of internal hexagon and conical connection implants.³⁵ Recent evidence noted that implantoplasty significantly reduces the fracture resistance of implants with a 2.5:1 crown-to-implant ratio.²⁹ Nevertheless, Stavropoulos et al. (2019) in a systematic review underlined the sparse clinical evidence of these limitations.⁵³

Last but not least, implant/bone overheating was speculated as a potential threat of implants that undergo implantoplasty.^{54, 55} Notwithstanding, heat production analyses suggested that minimal thermal changes occur at the implant surface and also at the surrounding hard and soft tissues. Anyways, this is slightly reduced by using tungsten carbide (~1°C).⁵⁴ Due to the clinical nature of our study and the exclusion of <3.75mm diameter implants these issues could not be explored. Nevertheless, it must be stated that the reported failed implants were due to disease progression rather than to technical complications linked to implant weakening.

Limitations and recommendations for future research

Shortcomings inherent to study design must be disclosed. First, due to the nature of the study, clinical baseline parameters were omitted as many of them were documented at 4 sites per implant. Second, owing to the length (mean≈ 2 years), and nature (retrospective case series) of the study, results extracted from this analysis must be interpreted with cautiousness. It must be stressed out that the long-term effectiveness is still unknown. Moreover, it must be kept in mind that it was not tested the effectiveness of the same procedures to manage peri-implantitis without the mechanical adjunct of implantoplasty.

Into the bargain, it must be noted that the presence of ions released to the medium from the implant surface during implantoplasty represents a subject of concern for

many clinicians considering the potential cytotoxicity of nano-sized metal particles.⁵⁶ An in-vitro mock model showed that implantoplasty results in the release of particles irregular in shape and of various sizes of titanium, aluminum, vanadium, carbon, amongst others in lesser quantity.³¹ Some of these metal ions were demonstrated to have a detrimental effect on the viability of human gingival fibroblast cells.^{57, 58} Fretwurst et al. (2016) showed that macrophages (M1) and lymphocytes are identified in the tissue surrounding to titanium particles released from dental implants.⁵⁹ Furthermore, Suarez-Lopez del Amo et al. (2017) demonstrated particles released from implants containing phosphate-enriched titanium oxide are able to activate CHK2 and trigger the recruitment of BRCA1 in oral epithelial cells.⁶⁰ CHK2 and BRCA1 are markers of DNA damage and genomic instability. In particular, BRCA1 is a human gene responsible for producing tumor suppressor proteins.⁶¹ Thus, although emerging evidence link metal ions with a detrimental cellular response, the question remains unaddressed on whether particles released from implantoplasty procedures may solely or, in interaction with the presence of periodontal pathogens, lead to disease recurrence.

Conclusion

Implantoplasty as adjunct to surgical therapy resulted effective in terms of disease resolution and implant survival rate. Implant location, defect morphology as well as the buccal width of keratinized mucosa are indicators of therapeutic success.

Acknowledgement

The authors thank Mrs. Mamen Tomé and Rosa Cruz (Clinica CICOM, Badajoz) for their assistance in collecting data during this study.

Bibliography

1. Berglundh T, Armitage G, Araujo MG, et al. Peri-implant diseases and conditions: Consensus report of workgroup 4 of the 2017 World Workshop on the Classification of Periodontal and Peri-Implant Diseases and Conditions. *J Periodontol* 2018;89 Suppl 1:S313-S318.
2. Gargallo-Albiol J, Tavelli L, Barootchi S, Monje A, Wang HL. Clinical sequelae and patients' perception of dental implant removal: A cross-sectional study. *J Periodontol* 2020.
3. Rakic M, Galindo-Moreno P, Monje A, et al. How frequent does peri-implantitis occur? A systematic review and meta-analysis. *Clin Oral Investig* 2018;22:1805-1816.
4. Schwarz F, Derks J, Monje A, Wang HL. Peri-implantitis. *J Periodontol* 2018;89 Suppl 1:S267-S290.
5. Monje A, Insua A, Wang HL. Understanding Peri-Implantitis as a Plaque-Associated and Site-Specific Entity: On the Local Predisposing Factors. *J Clin Med* 2019;8.
6. Heitz-Mayfield LJA, Heitz F, Lang NP. Implant Disease Risk Assessment IDRA-a tool for preventing peri-implant disease. *Clin Oral Implants Res* 2020;31:397-403.
7. Figuero E, Graziani F, Sanz I, Herrera D, Sanz M. Management of peri-implant mucositis and peri-implantitis. *Periodontol 2000* 2014;66:255-273.
8. Sahm N, Becker J, Santel T, Schwarz F. Non-surgical treatment of peri-implantitis using an air-abrasive device or mechanical debridement and local application of chlorhexidine: a prospective, randomized, controlled clinical study. *J Clin Periodontol* 2011;38:872-878.
9. Schwarz F, John G, Hegewald A, Becker J. Non-surgical treatment of peri-implant mucositis and peri-implantitis at zirconia implants: a prospective case series. *J Clin Periodontol* 2015;42:783-788.
10. Rocuzzo M, Bonino F, Bonino L, Dalmaso P. Surgical therapy of peri-implantitis lesions by means of a bovine-derived xenograft: comparative results of a prospective study on two different implant surfaces. *J Clin Periodontol* 2011;38:738-745.
11. Romeo E, Lops D, Chiapasco M, Ghisolfi M, Vogel G. Therapy of peri-implantitis with resective surgery. A 3-year clinical trial on rough screw-shaped oral implants. Part II: radiographic outcome. *Clin Oral Implants Res* 2007;18:179-187.
12. Englezos E, Cosyn J, Koole S, Jacquet W, De Bruyn H. Resective Treatment of Peri-implantitis: Clinical and Radiographic Outcomes After 2 Years. *Int J Periodontics Restorative Dent* 2018;38:729-735.

13. Monje A, Pons R, Rocuzzo A, Salvi GE, Nart J. Reconstructive therapy for the management of peri-implantitis via submerged guided bone regeneration: A prospective case series. *Clin Implant Dent Relat Res* 2020;22:342-350.
14. Rocuzzo M, Gaudioso L, Lungo M, Dalmaso P. Surgical therapy of single peri-implantitis intrabony defects, by means of deproteinized bovine bone mineral with 10% collagen. *J Clin Periodontol* 2016;43:311-318.
15. Schwarz F, Sahm N, Becker J. Combined surgical therapy of advanced peri-implantitis lesions with concomitant soft tissue volume augmentation. A case series. *Clin Oral Implants Res* 2014;25:132-136.
16. Schwarz F, John G, Mainusch S, Sahm N, Becker J. Combined surgical therapy of peri-implantitis evaluating two methods of surface debridement and decontamination. A two-year clinical follow up report. *J Clin Periodontol* 2012;39:789-797.
17. Suarez F, Monje A, Galindo-Moreno P, Wang HL. Implant surface detoxification: a comprehensive review. *Implant Dent* 2013;22:465-473.
18. Valderrama P, Wilson TG, Jr. Detoxification of implant surfaces affected by peri-implant disease: an overview of surgical methods. *Int J Dent* 2013;2013:740680.
19. Romeo E, Ghisolfi M, Murgolo N, Chiapasco M, Lops D, Vogel G. Therapy of peri-implantitis with resective surgery. A 3-year clinical trial on rough screw-shaped oral implants. Part I: clinical outcome. *Clin Oral Implants Res* 2005;16:9-18.
20. von Elm E, Altman DG, Egger M, et al. The Strengthening the Reporting of Observational Studies in Epidemiology (STROBE) Statement: guidelines for reporting observational studies. *Int J Surg* 2014;12:1495-1499.
21. Chan HL, Oh WS, Ong HS, et al. Impact of implantoplasty on strength of the implant-abutment complex. *Int J Oral Maxillofac Implants* 2013;28:1530-1535.
22. Monje A, Blasi G, Nart J, Urban IA, Nevins M, Wang HL. Soft Tissue Conditioning for the Surgical Therapy of Peri-implantitis: A Prospective 12-Month Study. *Int J Periodontics Restorative Dent* 2020;40:899-906.
23. Mombelli A, van Oosten MA, Schurch E, Jr., Land NP. The microbiota associated with successful or failing osseointegrated titanium implants. *Oral Microbiol Immunol* 1987;2:145-151.
24. Monje A, Vera M, Munoz-Sanz A, Wang HL, Nart J. Suppuration as diagnostic criterium of peri-implantitis. *J Periodontol* 2020.
25. Serino G, Sato H, Holmes P, Turri A. Intra-surgical vs. radiographic bone level assessments in measuring peri-implant bone loss. *Clin Oral Implants Res* 2017;28:1396-1400.
26. Monje A, Pons R, Insua A, Nart J, Wang HL, Schwarz F. Morphology and severity of peri-implantitis bone defects. *Clin Implant Dent Relat Res* 2019;21:635-643.

27. Koo KT, Khoury F, Keeve PL, et al. Implant Surface Decontamination by Surgical Treatment of Periimplantitis: A Literature Review. *Implant Dent* 2019;28:173-176.
28. Suh JJ, Simon Z, Jeon YS, Choi BG, Kim CK. The use of implantoplasty and guided bone regeneration in the treatment of peri-implantitis: two case reports. *Implant Dent* 2003;12:277-282.
29. Leitao-Almeida B, Camps-Font O, Correia A, Mir-Mari J, Figueiredo R, Valmaseda-Castellon E. Effect of crown to implant ratio and implantoplasty on the fracture resistance of narrow dental implants with marginal bone loss: an in vitro study. *BMC Oral Health* 2020;20:329.
30. Stuani VT, Kim DM, Nagai M, Chen CY, Sant Ana ACP. Effectiveness and surface changes of different decontamination protocols at smooth and minimally rough titanium surfaces. *J Periodontol* 2020.
31. Barrak FN, Li S, Muntane AM, Jones JR. Particle release from implantoplasty of dental implants and impact on cells. *Int J Implant Dent* 2020;6:50.
32. Bertl K, Isidor F, von Steyern PV, Stavropoulos A. Does implantoplasty affect the failure strength of narrow and regular diameter implants? A laboratory study. *Clin Oral Investig* 2021;25:2203-2211.
33. Wang CW, Ashnagar S, Gianflippo RD, Arnett M, Kinney J, Wang HL. Laser-assisted regenerative surgical therapy for peri-implantitis: A randomized controlled clinical trial. *J Periodontol* 2020.
34. Ravida A, Siqueira R, Saleh I, Saleh MHA, Giannobile A, Wang HL. Lack of Clinical Benefit of Implantoplasty to Improve Implant Survival Rate. *J Dent Res* 2020;99:1348-1355.
35. Camps-Font O, Gonzalez-Barnadas A, Mir-Mari J, Figueiredo R, Gay-Escoda C, Valmaseda-Castellon E. Fracture resistance after implantoplasty in three implant-abutment connection designs. *Med Oral Patol Oral Cir Bucal* 2020;25:e691-e699.
36. Galarraga-Vinueza ME, Obreja K, Magini R, Sculean A, Sader R, Schwarz F. Volumetric assessment of tissue changes following combined surgical therapy of peri-implantitis: A pilot study. *J Clin Periodontol* 2020;47:1159-1168.
37. Azzola E, Ionescu AC, Ottobelli M, et al. Biofilm Formation on Dental Implant Surface Treated by Implantoplasty: An In Situ Study. *Dent J (Basel)* 2020;8.
38. El Chaar E, Almogahwi M, Abdalkader K, Alshehri A, Cruz S, Ricci J. Decontamination of the Infected Implant Surface: A Scanning Electron Microscope Study. *Int J Periodontics Restorative Dent* 2020;40:395-401.
39. Aljohani M, Yong SL, Bin Rahmah A. The effect of surgical regenerative treatment for peri-implantitis: A systematic review. *Saudi Dent J* 2020;32:109-119.
40. Beheshti Maal M, Aanerod Ellingsen S, Reseland JE, Verket A. Experimental implantoplasty outcomes correlate with fibroblast growth in vitro. *BMC Oral Health* 2020;20:25.

41. Lasserre JF, Brex MC, Toma S. Implantoplasty Versus Glycine Air Abrasion for the Surgical Treatment of Peri-implantitis: A Randomized Clinical Trial. *Int J Oral Maxillofac Implants* 2020;35:197-206.
42. Bianchini MA, Galarraga-Vinueza ME, Bedoya KA, Correa BB, de Souza Magini R, Schwarz F. Implantoplasty Enhancing Peri-implant Bone Stability Over a 3-Year Follow-up: A Case Series. *Int J Periodontics Restorative Dent* 2020;40:e1-e8.
43. Pommer B, Haas R, Mailath-Pokorny G, et al. Periimplantitis Treatment: Long-Term Comparison of Laser Decontamination and Implantoplasty Surgery. *Implant Dent* 2016;25:646-649.
44. Bianchini MA, Galarraga-Vinueza ME, Apaza-Bedoya K, De Souza JM, Magini R, Schwarz F. Two to six-year disease resolution and marginal bone stability rates of a modified resective-implantoplasty therapy in 32 peri-implantitis cases. *Clin Implant Dent Relat Res* 2019;21:758-765.
45. Schwarz F, Sahm N, Iglhaut G, Becker J. Impact of the method of surface debridement and decontamination on the clinical outcome following combined surgical therapy of peri-implantitis: a randomized controlled clinical study. *J Clin Periodontol* 2011;38:276-284.
46. Schwarz F, Hegewald A, John G, Sahm N, Becker J. Four-year follow-up of combined surgical therapy of advanced peri-implantitis evaluating two methods of surface decontamination. *J Clin Periodontol* 2013;40:962-967.
47. Schwarz F, John G, Schmucker A, Sahm N, Becker J. Combined surgical therapy of advanced peri-implantitis evaluating two methods of surface decontamination: a 7-year follow-up observation. *J Clin Periodontol* 2017;44:337-342.
48. Nart J, de Tapia B, Pujol A, Pascual A, Valles C. Vancomycin and tobramycin impregnated mineralized allograft for the surgical regenerative treatment of peri-implantitis: a 1-year follow-up case series. *Clin Oral Investig* 2018;22:2199-2207.
49. Ramanauskaitė A, Becker K, Juodzbaly G, Schwarz F. Clinical outcomes following surgical treatment of peri-implantitis at grafted and non-grafted implant sites: a retrospective analysis. *Int J Implant Dent* 2018;4:27.
50. Rávida A, Saleh I, Siqueira R, et al. Influence of keratinized mucosa on the surgical therapeutical outcomes of peri-implantitis. *J Clin Periodontol* 2020;47:529-539.
51. Gehrke SA, Aramburu Junior JS, Dedavid BA, Shibli JA. Analysis of Implant Strength After Implantoplasty in Three Implant-Abutment Connection Designs: An In Vitro Study. *Int J Oral Maxillofac Implants* 2016;31:e65-70.
52. Costa-Berenguer X, Garcia-Garcia M, Sanchez-Torres A, Sanz-Alonso M, Figueiredo R, Valmaseda-Castellon E. Effect of implantoplasty on fracture resistance and surface roughness of standard diameter dental implants. *Clin Oral Implants Res* 2018;29:46-54.

53. Stavropoulos A, Bertl K, Eren S, Gotfredsen K. Mechanical and biological complications after implantoplasty-A systematic review. *Clin Oral Implants Res* 2019;30:833-848.
54. de Souza Junior JM, Oliveira de Souza JG, Pereira Neto AL, Iaculli F, Piattelli A, Bianchini MA. Analysis of Effectiveness of Different Rotational Instruments in Implantoplasty: An In Vitro Study. *Implant Dent* 2016;25:341-347.
55. Sharon E, Shapira L, Wilensky A, Abu-Hatoum R, Smidt A. Efficiency and thermal changes during implantoplasty in relation to bur type. *Clin Implant Dent Relat Res* 2013;15:292-296.
56. Suarez-Lopez Del Amo F, Garaicoa-Pazmino C, Fretwurst T, Castilho RM, Squarize CH. Dental implants-associated release of titanium particles: A systematic review. *Clin Oral Implants Res* 2018;29:1085-1100.
57. Costa BC, Tokuhara CK, Rocha LA, Oliveira RC, Lisboa-Filho PN, Costa Pessoa J. Vanadium ionic species from degradation of Ti-6Al-4V metallic implants: In vitro cytotoxicity and speciation evaluation. *Mater Sci Eng C Mater Biol Appl* 2019;96:730-739.
58. Hallab NJ, Mikecz K, Vermes C, Skipor A, Jacobs JJ. Orthopaedic implant related metal toxicity in terms of human lymphocyte reactivity to metal-protein complexes produced from cobalt-base and titanium-base implant alloy degradation. *Mol Cell Biochem* 2001;222:127-136.
59. Fretwurst T, Buzanich G, Nahles S, Woelber JP, Riesemeier H, Nelson K. Metal elements in tissue with dental peri-implantitis: a pilot study. *Clin Oral Implants Res* 2016;27:1178-1186.
60. Suarez-Lopez Del Amo F, Rudek I, Wagner VP, et al. Titanium Activates the DNA Damage Response Pathway in Oral Epithelial Cells: A Pilot Study. *Int J Oral Maxillofac Implants* 2017;32:1413-1420.
61. Lainchbury M, Collins I. Checkpoint kinase inhibitors: a patent review (2009 - 2010). *Expert Opin Ther Pat* 2011;21:1191-1210.

Figure legends

Figure 1. Step-by-step approach on the adjunct use of implantoplasty to resective and reconstructive surgical management of peri-implantitis

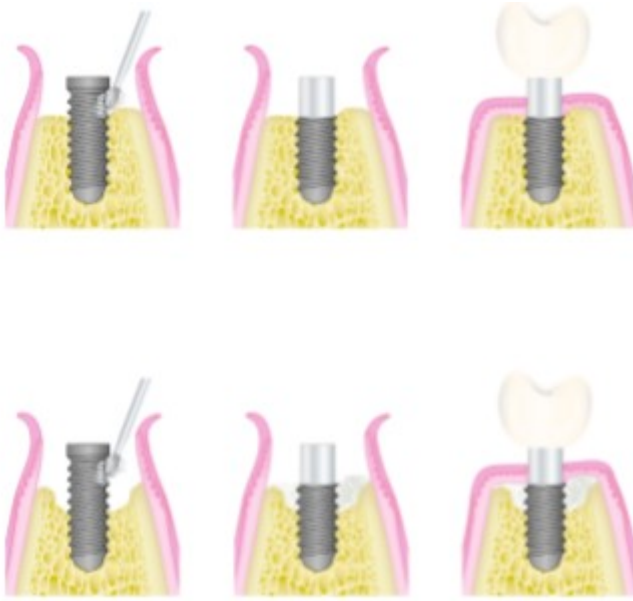
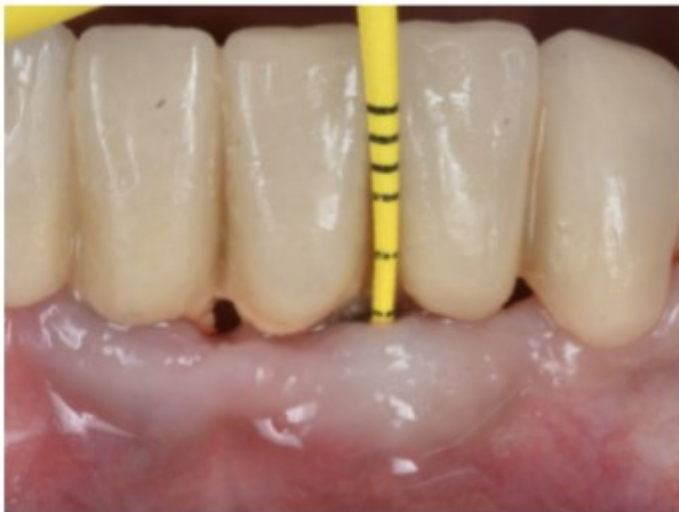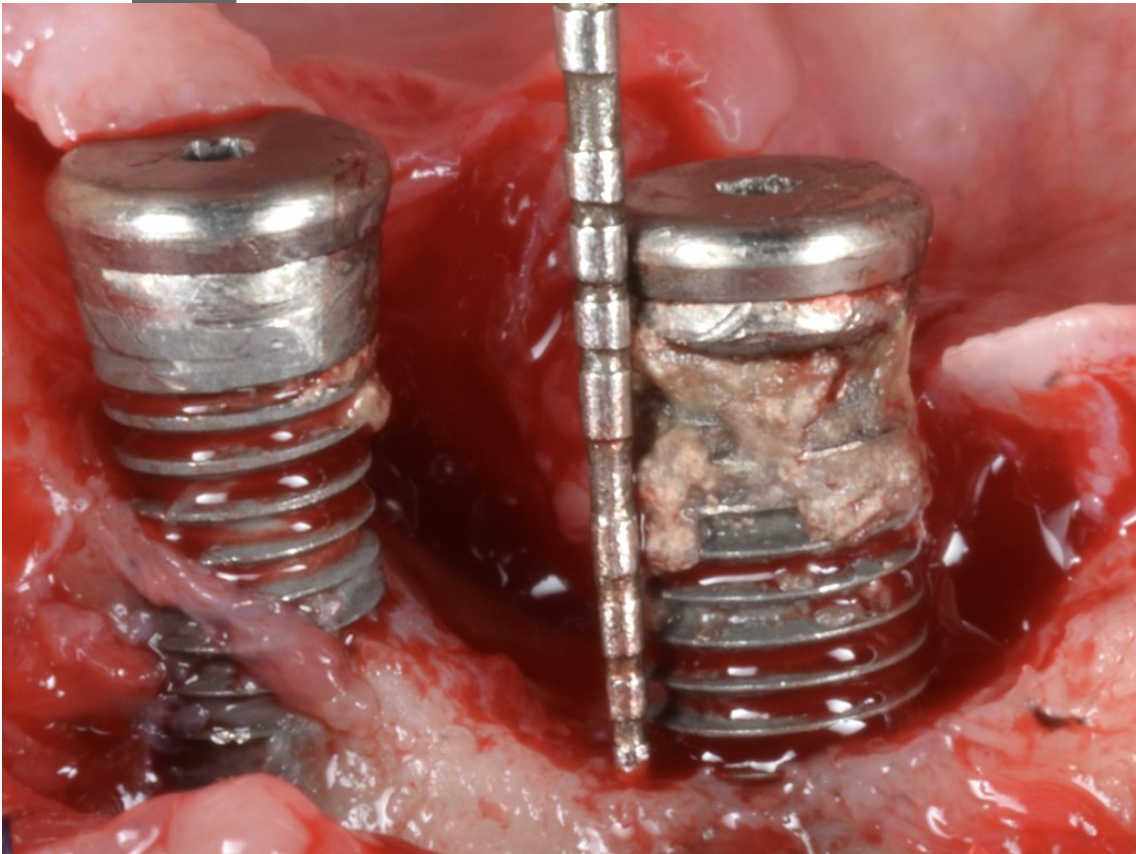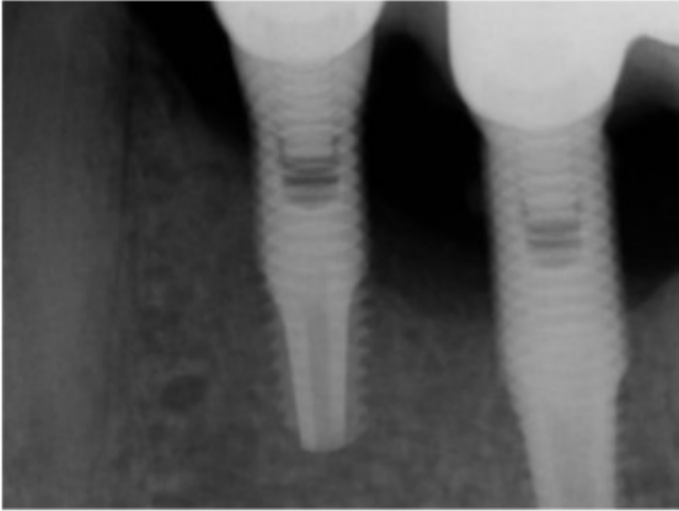
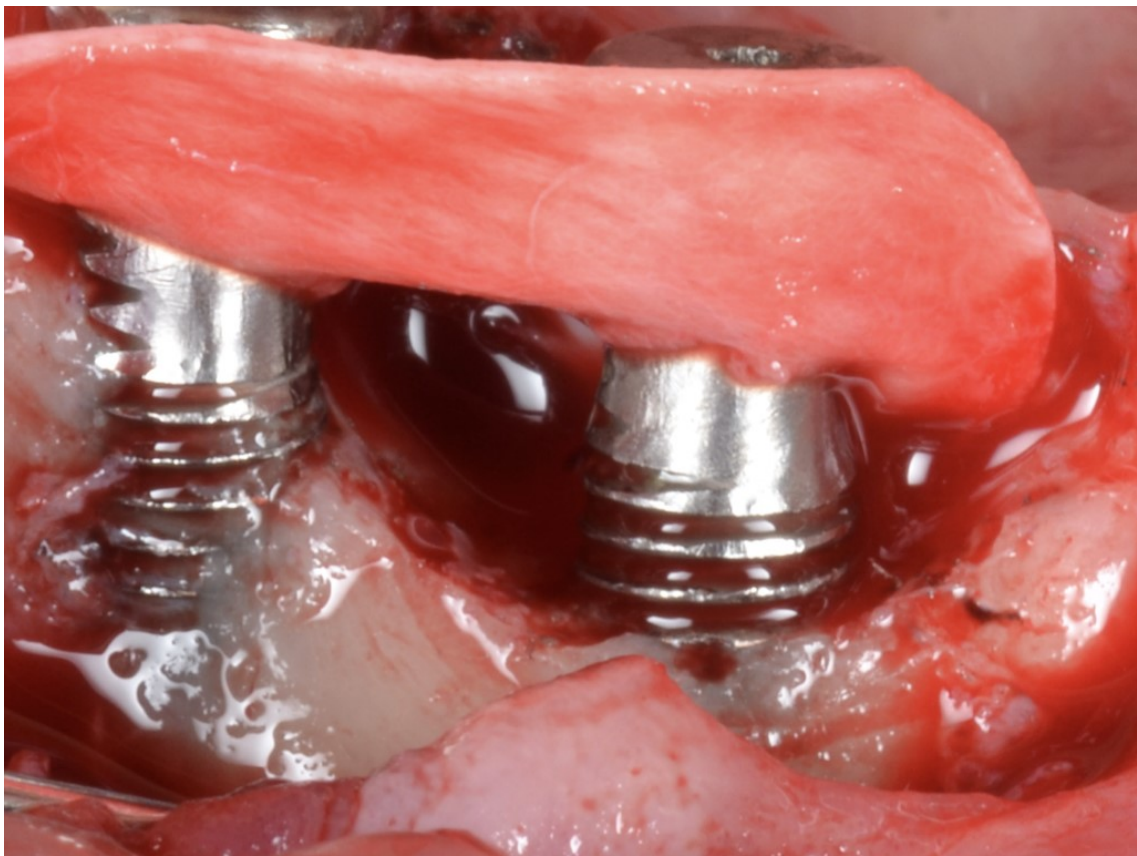
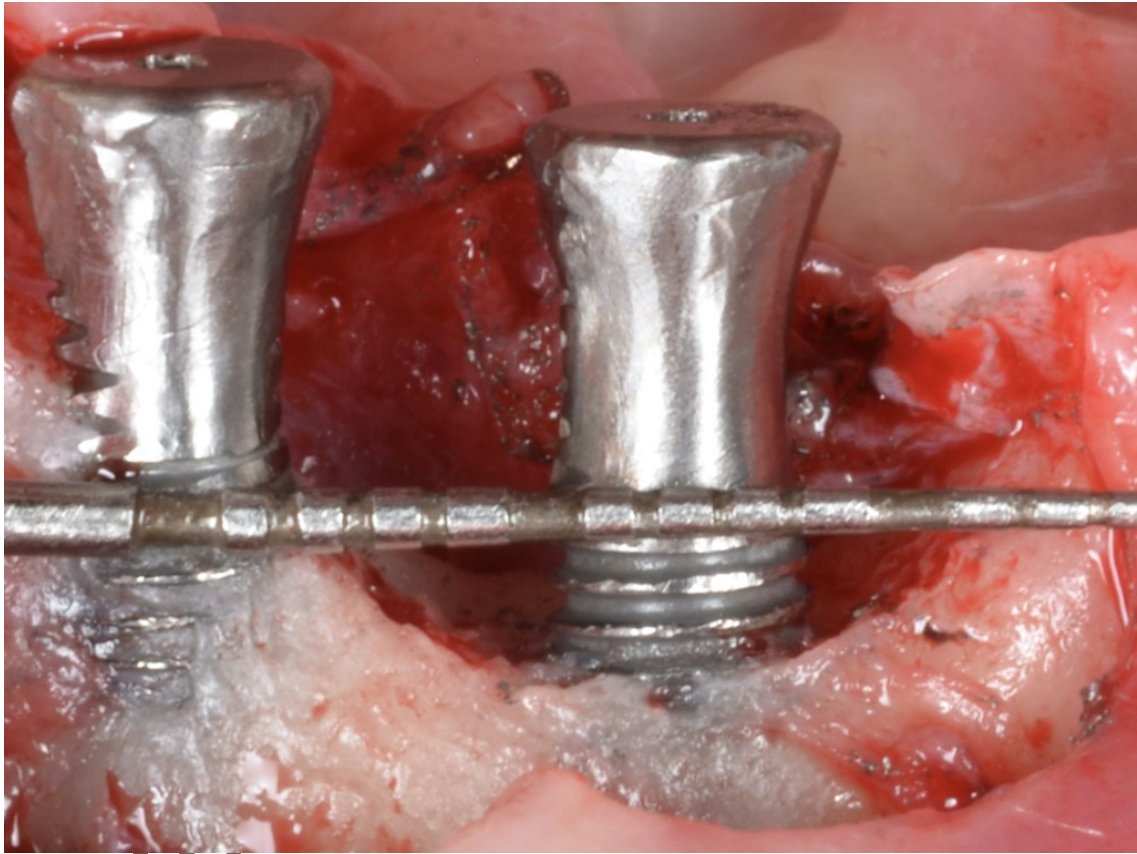


Figure 2. Anterior mandibular implants exhibiting moderate peri-implantitis (a) frontal view, (b) peri-apical x-ray, (c) intra-operative view demonstrating moderate severity of a two-wall bone defect, (d) implantoplasty was performed for the area below the reparative potential outlined by the probe, (e) membrane stability is achieved through the implant body as a “poncho”, (f) a mixture of anorganic bovine bone and autogenous bone is used for bone grafting, (g) membranes are stabilized to guarantee occlusivity, (h) periapical x-ray demonstrating radiographic bone gain at the infra-osseous compartment, (i) 24-month follow-up clinical examination showing soft tissue health with substantial mucosal recession, (j) mucosal recession often favors adequate access for self-performed oral health measures





Au



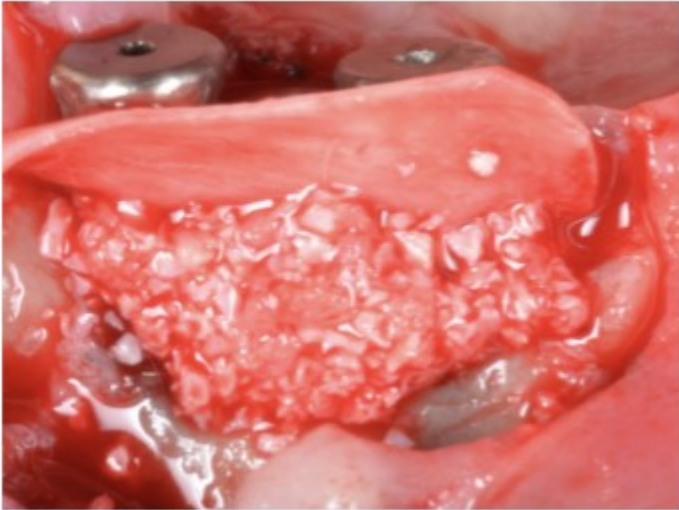


Figure 1

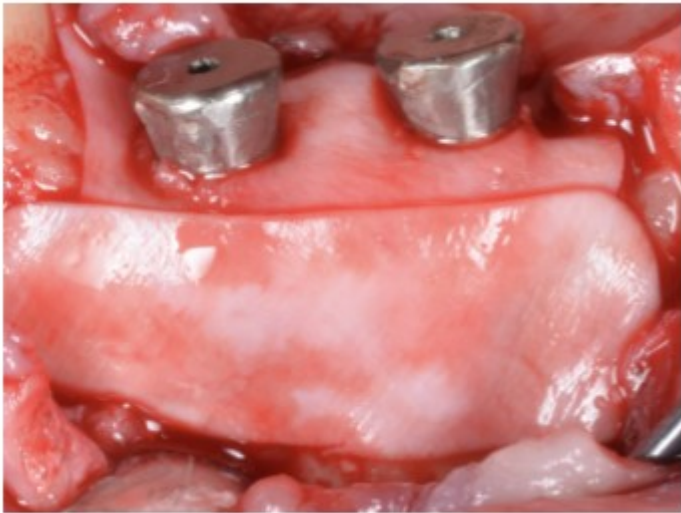


Figure 2



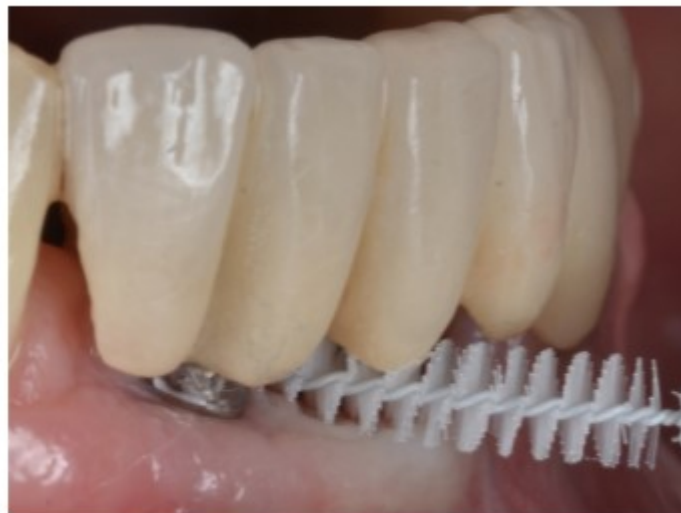
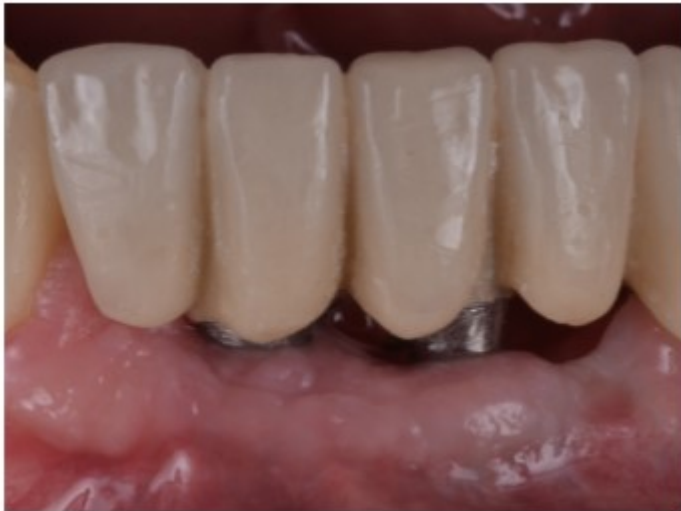

Figure 3. Percentage of implants displaying: 1) therapeutic success #1; 2) therapeutic success #2; 3) survival. REC: Reconstructive; RES: Resective; APF: Apically positioned flap; STC: Soft-tissue conditioning.

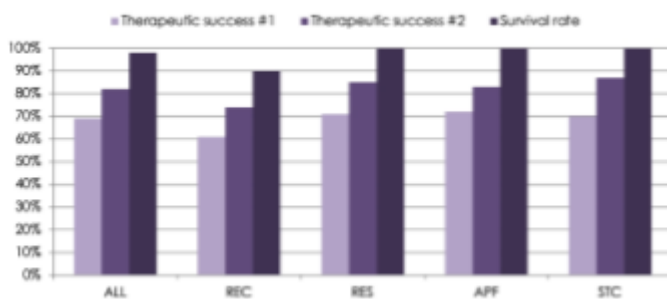


Figure 4. Percentage of implants exhibiting therapeutic success #1 (a) and therapeutic success #2 (b) in the resective group. Comparison between: 1) anterior vs. posterior implants and 2) Class I-III vs. Class II peri-implant defects. Ant: Anterior; Post: Posterior.

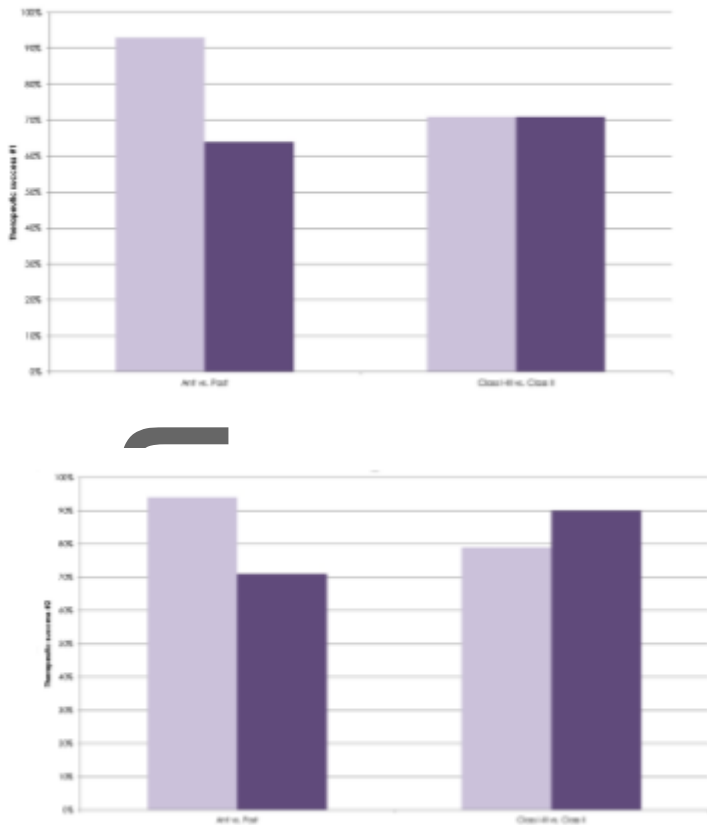


Figure 5. Percentage of implants exhibiting therapeutic success #1 (a) and therapeutic success #2 (b) in the reconstructive group. Comparison between: 1) implants with ≤ 2 mm KM vs implants with ≥ 2 mm KM. KM: Keratinized mucosa

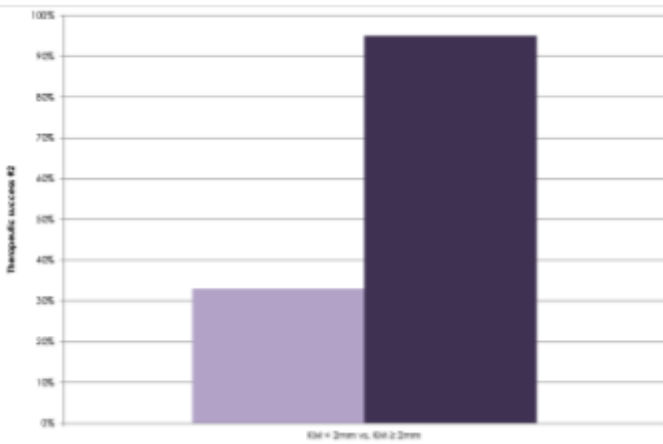
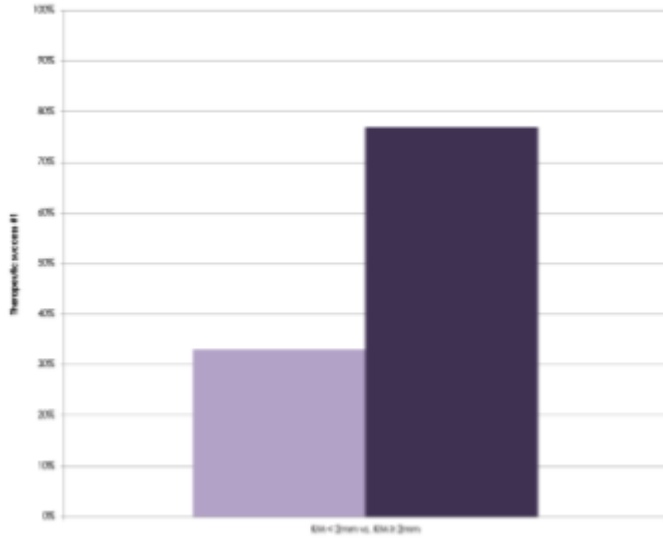


Table 1. Descriptive statistic implant level variables.

Variable	N	%
Severity of PI		
Slight	28	21%
Moderate	51	38%
Advanced	56	41%
Type of intervention		
REC	31	23%
RES	104	77%

	APF	58	43%
	STC	46	34%
Type of defect			
Ia		29	21%
Ib		15	11%
Ic		0	0%
II		52	39%
IIIa		19	14%
IIIb		7	5%
IIIc		13	10%
Arch			
Mandible		52	39%
Maxilla		83	61%
Implant position			
Anterior		38	28%
Posterior		97	72%
Therapeutic success #1			
REC		19	61%
RES		74	71%
	APF	42	72%
	STC	32	70%
Therapeutic success #2			
REC		23	74%
RES		88	85%
	APF	48	83%
	STC	40	87%
Survival rate			
REC		28	90%
RES		104	100%
	APF	58	100%
	STC	46	100%

	Mean	SD
KM (T1)*	2,39	1,37
RC (T1)*	1,68	1,34
N of Plaque sites (T1)*	0,2	0,76
Mean PPD (T1)*	2,86	0,81
Deepest PPD (T1)*	3,45	1,21
Mean mSBI (T1)*	0,11	0,26
Mean SUP index (T1)*	0,06	0,38

*Implants that failed were excluded (N=132); PI: peri-implantitis; PPD: Probing pocket depth; SUP: suppuration; KM: keratinized mucosa; RC: recession; mSBI: modified sulcular bleeding index; T1: reevaluation; REC: reconstructive; RES: resective; APF: apically positioned flap; STC: soft tissue conditioning