

Runge John S. (Orcid ID: 0000-0001-6489-8575)
Lowe Lori (Orcid ID: 0000-0002-2359-8426)
Hristov Alexandra Cappiello (Orcid ID: 0000-0002-1836-6591)

Patch/plaque mycosis-fungoides-like presentations of *DUSP22*-translocated T-cell lymphomas

John S. Runge, Ph.D.¹, Madison L. Novice, B.A.¹, Naomi Briones, M.D.², Kiyanna Williams, M.D.², Lori Lowe, M.D.^{2,3}, Daniel F. Boyer, M.D., Ph.D.³, Ryan A. Wilcox, M.D., Ph.D.⁴, Trilokraj Tejasvi, M.D.², Alexandra C. Hristov, M.D.^{2,3}

¹ Medical School, University of Michigan, Ann Arbor, MI

² Department of Dermatology, University of Michigan, Ann Arbor, MI

³ Department of Pathology, University of Michigan, Ann Arbor, MI

⁴ Department of Internal Medicine, Hematology/Oncology Division, University of Michigan, Ann Arbor, MI

Key Words: mycosis fungoides, *DUSP22*, T-cell lymphoma, CD30, anaplastic large cell lymphoma

Running Title: mycosis fungoides-like *DUSP22*-positive T-cell lymphoma

The authors have no conflicts of interest to declare.

Corresponding Author:

Alexandra C. Hristov

Associate Professor

Departments of Pathology and Dermatology

2800 Plymouth Road, Building 35

Ann Arbor, MI 48109-2800

Phone: 734-764-4460

Fax: 734-764-4690

This is the author manuscript accepted for publication and has undergone full peer review but has not been through the copyediting, typesetting, pagination and proofreading process, which may lead to differences between this version and the [Version of Record](#). Please cite this article as doi: [10.1111/cup.14156](https://doi.org/10.1111/cup.14156)

This article is protected by copyright. All rights reserved.

Email: ahristov@med.umich.edu

Abstract

The *DUSP22-IRF4* gene rearrangement results in down-regulation of *DUSP22*, a presumed tumor suppressor in T-cell lymphomagenesis. It has been described in some cases of primary cutaneous and systemic anaplastic large cell lymphoma, lymphomatoid papulosis and transformed mycosis fungoides. Here we describe 2 patients with clinical lesions resembling patch/plaque mycosis fungoides that did not meet WHO criteria for large cell transformation on histopathology yet demonstrated a *DUSP22* translocation. One patient who had a history of systemic anaplastic large cell lymphoma with *DUSP22* translocation presented with cutaneous involvement by his systemic lymphoma along with lymphomatoid papulosis and mycosis-fungoides-like lesions, all demonstrating an identical immunophenotype and T-cell clone. These cases expand the spectrum of *DUSP22*-rearranged lymphomas to include mycosis-fungoides-like presentations without large cell transformation.

Key Words: mycosis fungoides, *DUSP22*, T-cell lymphoma, CD30, anaplastic large cell lymphoma

Introduction:

Mycosis fungoides (MF) is the most common cutaneous lymphoma, constituting approximately 50% of cases.¹ Primary cutaneous CD30-positive T-cell lymphoproliferative disorders, including lymphomatoid papulosis (LyP) and primary cutaneous anaplastic large cell lymphoma (cALCL) are the second and third most common cutaneous lymphoproliferative disorder/lymphoma, making up 12% and 8% of cases, respectively.¹ While these disorders are common among cutaneous lymphomas, they are challenging to diagnose and classify. Fortunately, our understanding of the genetic background of these lymphomas is expanding.

MF has been associated with mutations in several genes, including those involved in the T-cell receptor and interleukin 2 pathways, T-helper 2 differentiation, TGF-beta-mediated growth suppression, tumor necrosis factor receptor superfamily and FAS-ligand mediated apoptosis, RAG-mediated recombination, JAK-STAT pathways, and suppression of p16, RB1, PTEN, PD-1, ATM and p53 (as reviewed by Elenitoba-Johnson et al.²). In contrast, LyP and cALCL have been associated with *NPM1-TYK2* gene fusions, *DUSP22-IRF4* rearrangements, and, rarely, *TP63* rearrangements.³⁻⁶ *DUSP22-IRF4* rearrangements have also been uncommonly reported in transformed MF and are seen in a subset of systemic anaplastic large cell lymphoma (sALCL).^{5,7-9}

Here, we report two patients with *DUSP22-IRF4* rearranged lymphomas/lymphoproliferative disorders who presented with patch/plaque MF-like lesions without definitive large cell transformation (LCT). Both cases clinically displayed long-standing patches and/or plaques and an epitheliotropic small CD30+ T-cell population. These findings suggest that a subset of *DUSP22-IRF4* rearranged lymphomas may show clinical and pathologic features that overlap with patch/plaque MF and do not meet WHO criteria for large cell transformation. Additional studies may help further clarify the histopathologic features and clinical significance of *DUSP22* rearrangement in MF-like lesions without LCT.

Case 1

A 73-year-old woman presented with a one-year history of spreading, pruritic, erythematous papules and plaques. Occasional lesions would spontaneously resolve, while most persisted (Figure 1, Table 1). Positron emission tomography/computed tomography (PET/CT) demonstrated multifocal, hypermetabolic areas of skin thickening at sites of known cutaneous disease without lymphadenopathy. Flow cytometry did not reveal peripheral blood involvement and lactate dehydrogenase was within normal limits.

Biopsy of the left breast, right inguinal fold and right posterior lower leg showed similar findings with an epitheliotropic lymphoid infiltrate composed of slightly enlarged lymphoid cells that also demonstrate a superficial perivascular distribution in the dermis (Figure 2A, B). There was a small component of larger lymphoid cells in the dermis of the right posterior leg biopsy specimen (<25%, Figure 2C). Both populations were CD30+, CD3+, CD2+ and CD4-, CD8-, CD5-, and CD7- (Figure 2D-F). PCR-based gene rearrangement studies demonstrated a monoclonal T-cell population with identical TCR gamma and beta base pair peaks in all biopsy specimens. In addition, the right posterior lower leg was positive for a *DUSP22* rearrangement. PD-1 and ICOS were negative in the left breast lesion.

Case 2

A 27-year-old man with a history of *DUSP22*-rearranged and ALK-negative sALCL without *TP63* rearrangement (Figure 3, Table 1) presented with several new cutaneous lesions. His sALCL was diagnosed in single epitrochlear lymph node that had been slowly enlarging over one year. Bone marrow biopsy was negative and PET/CT revealed findings compatible with involvement of the distal left spine of his scapula, but no other nodal disease. He was treated with 6 cycles of cyclophosphamide, doxorubicin hydrochloride (hydroxydaunorubicin), vincristine sulfate (Oncovin), and prednisone (CHOP) with resolution of his disease on PET/CT and he declined autotransplant. He presented one year later with several new cutaneous lesions and an enlarged left inguinal lymph node. His cutaneous lesions included xerotic patches with an MF-like appearance on his shoulder, persistent papulonodules compatible with cutaneous involvement by his sALCL, and resolving papules clinically behaving as LyP. He was treated with brentuximab and achieved a rapid complete response, but again declined autotransplant. Two years later, he presented with persistent cutaneous nodules and enlarged right inguinal lymph nodes. Over the next year, he reported progressive right inguinal lymphadenopathy and clavicular and back pain. PET/CT showed lymph node, soft tissue and osseous disease. He has recently restarted brentuximab.

All biopsy specimens revealed a CD30+ T-cell population with a similar immunophenotype (CD3+, CD2+, CD4-, CD8-, CD7-, CD5 weak to -). His inguinal lymph node and persistent papulonodules (Figure 4) were composed of sheets of large CD30+ T-cells. Other persistent nodules and his resolving papules included both slightly enlarged epitheliotropic CD30+ T-cells and dermal nodules of large CD30+ T-cells (Figure 5). An MF-like lesion demonstrated an infiltrate of slightly-enlarged, CD30+ lymphoid cells that showed folliculotropism, yet failed to meet criteria for LCT (Figure 6). PD-1 and ICOS were negative in a persistent nodule.

Molecular studies demonstrated identical T-cell receptor gamma and beta gene rearrangements in all biopsy specimens, including the patient's original sALCL. In addition, a *DUSP22* rearrangement was identified in the patient's original lymph node biopsy specimen and three persistent cutaneous nodules, as well as his LyP. While insufficient material remained in his block to test the biopsy specimen of his MF-like lesions for a *DUSP22* rearrangement, the identical immunophenotype and TCR gene rearrangements in all specimens as well as the presence of a *DUSP22* rearrangement in all other tested specimens support the presence of a *DUSP22* gene rearrangement in his MF-like lesions.

DISCUSSION:

The *DUSP22* gene is located on chromosome 6p25 and is thought to be a tumor suppressor in T-cell neoplasms.^{5,10} It encodes a phosphatase that acts on several mitogen-activated protein kinases, though the proteins affected seem to vary depending on the cell type and context.⁵ Initially, *DUSP22* rearrangements were attributed to the neighboring *IRF4* locus;^{6,11} however, translocation of this region result in downregulation of *DUSP22*.^{8,10}

While translocations of 6p25 were at first thought to be specific for cALCL,⁶ subsequent studies have demonstrated that translocation of *DUSP22* affects approximately a third of cases of sALCL and cALCL.^{5,7-9,12} They may also be seen in a small subset of MF with large cell transformation, often with significant CD30 expression,^{7,12} and in LyP. While having no prognostic significance in LyP or cALCL, *DUSP22* translocations are associated with a favorable prognosis in sALCL.^{5,9,13} Notably, *DUSP22* translocations in both cALCL and LyP have been associated with a dual population of CD30-positive cells: small to medium-sized epitheliotropic cells and dermal nodules of large cells.^{3,4} While case 2 had a similar pattern in her lesions, the clinical presentation was not that of LyP or cALCL.

The patients presented here are unusual in that they displayed lesions clinically appearing as patch/plaque MF with small epitheliotropic T cells along with translocation of *DUSP22*. Neither patient met the WHO criteria for LCT; namely more than 25% of large cells (at least 4 times the size of a normal lymphocyte).¹⁴ While Case 1 displayed small aggregates of large cells, these larger cells did not form a “tumorous mass of large transformed cells” as originally described by Salhany et al.¹⁵ Moreover, the *DUSP22*-rearrangement was seen in small, epitheliotropic lymphoid cells that were not transformed. Case 2 also demonstrated lesions that clinically behaved as LyP, while others were compatible with cutaneous involvement by his known sALCL. While prior studies have demonstrated a clonal relationship between MF, LyP and/or ALCL in a single patient,¹⁶⁻²¹ our patients demonstrated a clonal T-cell population with identical base pair peaks, an identical immunophenotype, and a *DUSP22* rearrangement in all tested specimens.

Both patients in this report showed a similar morphology and immunophenotype. Specifically, both patients displayed epitheliotropic small neoplastic T-cells and both patients had a component of large cells in at least some biopsies. Moreover, the neoplastic T-cells expressed CD3 and CD30 and lacked expression of CD4, CD8, CD5, and CD7. These findings suggest that patients with MF-like lesions and *DUSP22* rearrangement may have a recognizable immunophenotype and morphology. Interestingly, we identified 3 biopsy specimens from 2 separate patients with patch/plaque MF and a similar immunophenotype (CD3+/CD30+/CD4-/CD8-/CD5-/CD7-); however, none demonstrated a *DUSP22* translocation. One patient showed extra copies of the *DUSP22* locus in one biopsy, a finding that has been reported previously in MF.¹²

The clinical significance of the observations reported here is uncertain; however, these findings expand the spectrum of *DUSP22* lymphomagenesis and suggest that a subset of patients with *DUSP22* translocations may meet clinical and histopathologic criteria for patch/plaque MF without meeting WHO criteria for large cell transformation. In addition, this report highlights that a single patient may demonstrate considerable phenotypic heterogeneity of lesions including lesions that clinically appear as sALCL with cutaneous involvement, MF, and LyP. Finally, similar patients may share morphologic and immunophenotypic features. In summary, these cases enhance our understanding of the clinical and pathologic features of *DUSP22*-rearranged lymphomas. As similar cases are identified, we will hopefully

gain a deeper understanding of this finding, its prognostic significance, and how it relates to any associated LyP or ALCL.

REFERENCES:

1. Willemze R, Cerroni L, Kempf W, et al. The 2018 update of the WHO-EORTC classification for primary cutaneous lymphomas. *Blood*. 2019;133(16):1703-1714. *Blood*. 2019;134(13):1112.
2. Elenitoba-Johnson KS, Wilcox R. A new molecular paradigm in mycosis fungoides and Sezary syndrome. *Semin Diagn Pathol*. 2017;34(1):15-21.
3. Onaindia A, Montes-Moreno S, Rodriguez-Pinilla SM, et al. Primary cutaneous anaplastic large cell lymphomas with 6p25.3 rearrangement exhibit particular histological features. *Histopathology*. 2015;66(6):846-855.
4. Karai LJ, Kadin ME, Hsi ED, et al. Chromosomal rearrangements of 6p25.3 define a new subtype of lymphomatoid papulosis. *Am J Surg Pathol*. 2013;37(8):1173-1181.
5. Xing X, Feldman AL. Anaplastic large cell lymphomas: ALK positive, ALK negative, and primary cutaneous. *Adv Anat Pathol*. 2015;22(1):29-49.
6. Wada DA, Law ME, Hsi ED, et al. Specificity of IRF4 translocations for primary cutaneous anaplastic large cell lymphoma: a multicenter study of 204 skin biopsies. *Mod Pathol*. 2011;24(4):596-605.
7. Fauconneau A, Pham-Ledard A, Cappellen D, et al. Assessment of diagnostic criteria between primary cutaneous anaplastic large-cell lymphoma and CD30-rich transformed mycosis fungoides; a study of 66 cases. *Br J Dermatol*. 2015;172(6):1547-1554.
8. Feldman AL, Dogan A, Smith DI, et al. Discovery of recurrent t(6;7)(p25.3;q32.3) translocations in ALK-negative anaplastic large cell lymphomas by massively parallel genomic sequencing. *Blood*. 2011;117(3):915-919.
9. Parrilla Castellar ER, Jaffe ES, Said JW, et al. ALK-negative anaplastic large cell lymphoma is a genetically heterogeneous disease with widely disparate clinical outcomes. *Blood*. 2014;124(9):1473-1480.
10. Csikesz CR, Knudson RA, Greipp PT, Feldman AL, Kadin M. Primary cutaneous CD30-positive T-cell lymphoproliferative disorders with biallelic rearrangements of DUSP22. *J Invest Dermatol*. 2013;133(6):1680-1682.
11. Feldman AL, Law M, Remstein ED, et al. Recurrent translocations involving the IRF4 oncogene locus in peripheral T-cell lymphomas. *Leukemia*. 2009;23(3):574-580.
12. Pham-Ledard A, Prochazkova-Carlotti M, Laharanne E, et al. IRF4 gene rearrangements define a subgroup of CD30-positive cutaneous T-cell lymphoma: a study of 54 cases. *J Invest Dermatol*. 2010;130(3):816-825.
13. Pedersen MB, Hamilton-Dutoit SJ, Bendix K, et al. DUSP22 and TP63 rearrangements predict outcome of ALK-negative anaplastic large cell lymphoma: a Danish cohort study. *Blood*. 2017;130(4):554-557.
14. Swerdlow SH, Campo E, Harris NL, et al., eds. *WHO Classification of Tumours of Haematopoietic and Lymphoid Tissues*. Lyon, France: IARC; 2017.
15. Salhany KE, Cousar JB, Greer JP, Casey TT, Fields JP, Collins RD. Transformation of cutaneous T cell lymphoma to large cell lymphoma. A clinicopathologic and immunologic study. *Am J Pathol*. 1988;132(2):265-277.
16. Wood GS, Crooks CF, Uluer AZ. Lymphomatoid papulosis and associated cutaneous lymphoproliferative disorders exhibit a common clonal origin. *J Invest Dermatol*. 1995;105(1):51-55.
17. Stowman AM, Hsia LL, Kanner WA, Mahadevan MS, Bullock GC, Patterson JW. Multiple cutaneous lymphoproliferative disorders showing a retained tumor clone by T-cell receptor gene

- rearrangement analysis: a case series of four patients and review of the literature. *Int J Dermatol*. 2016;55(2):e62-71.
18. Gallardo F, Costa C, Bellosillo B, et al. Lymphomatoid papulosis associated with mycosis fungoides: clinicopathological and molecular studies of 12 cases. *Acta Derm Venereol*. 2004;84(6):463-468.
 19. Zackheim HS, Jones C, Leboit PE, Kashani-Sabet M, McCalmont TH, Zehnder J. Lymphomatoid papulosis associated with mycosis fungoides: a study of 21 patients including analyses for clonality. *J Am Acad Dermatol*. 2003;49(4):620-623.
 20. Basarab T, Fraser-Andrews EA, Orchard G, Whittaker S, Russel-Jones R. Lymphomatoid papulosis in association with mycosis fungoides: a study of 15 cases. *Br J Dermatol*. 1998;139(4):630-638.
 21. Chott A, Vonderheid EC, Olbricht S, Miao NN, Balk SP, Kadin ME. The dominant T cell clone is present in multiple regressing skin lesions and associated T cell lymphomas of patients with lymphomatoid papulosis. *J Invest Dermatol*. 1996;106(4):696-700.

Author Manuscript

Table 1: Summary of Clinical, Histopathologic and Genetic Findings

	Clinical Findings	BSA /mSWAT	CD30	CD3	CD4	CD8	CD2	CD5	CD7	<i>TP63</i> Rearrangement	<i>DUSP22</i> Rearrangement	TCR clone
Case 1	spreading, pruritic, erythematous papules and plaques	5%/10	+	+	-	-	+	-	-	Not Done	+	+ Identical base pair peaks in all biopsies
Case 2	xerotic patches with an MF-like appearance, persistent papulonodules, and resolving papules	3%/2	+	+	-	-	+	Weak to -	-	-	+	+ Identical base pair peaks in all biopsies

Figure Legends:

Figure 1: MF-like lesions with *DUSP22* rearrangement (Case 1). A-B. The patient presented with a 1-year history of erythematous, pruritic plaques.

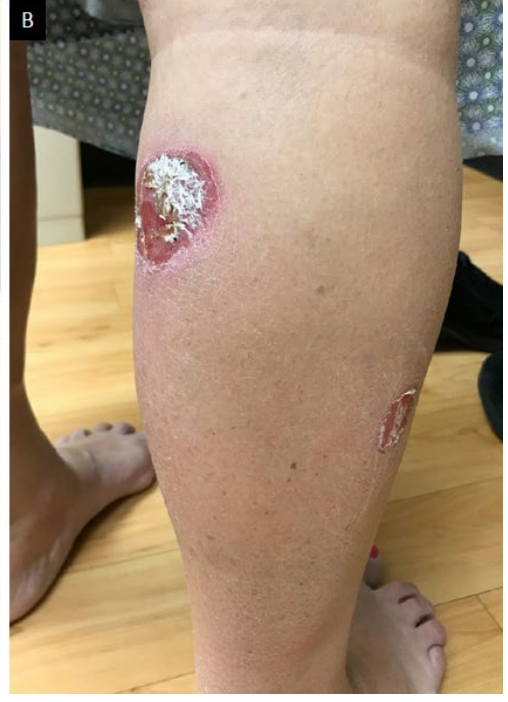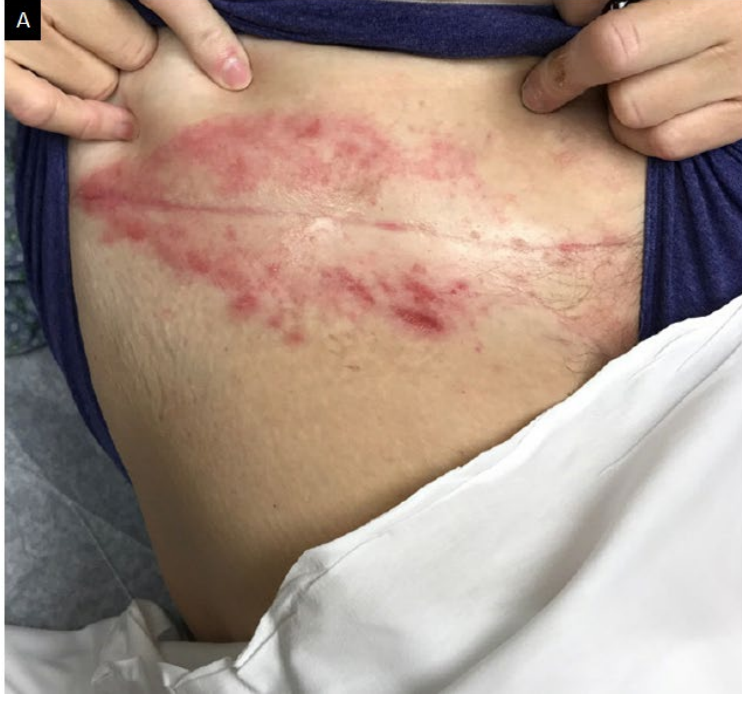Figure 2: MF-like lesions with *DUSP22* rearrangement (Case 1). A-B. Biopsy demonstrated epidermotropic and adnexotropic slightly enlarged lymphoid cells (original magnification x 100, x 200). C. There were occasional small aggregates of larger lymphoid cells (original magnification x 200). D-I. The atypical lymphoid cells are CD3+, CD30+, CD4-, CD8-, CD5- and CD7- (original magnification x 200).

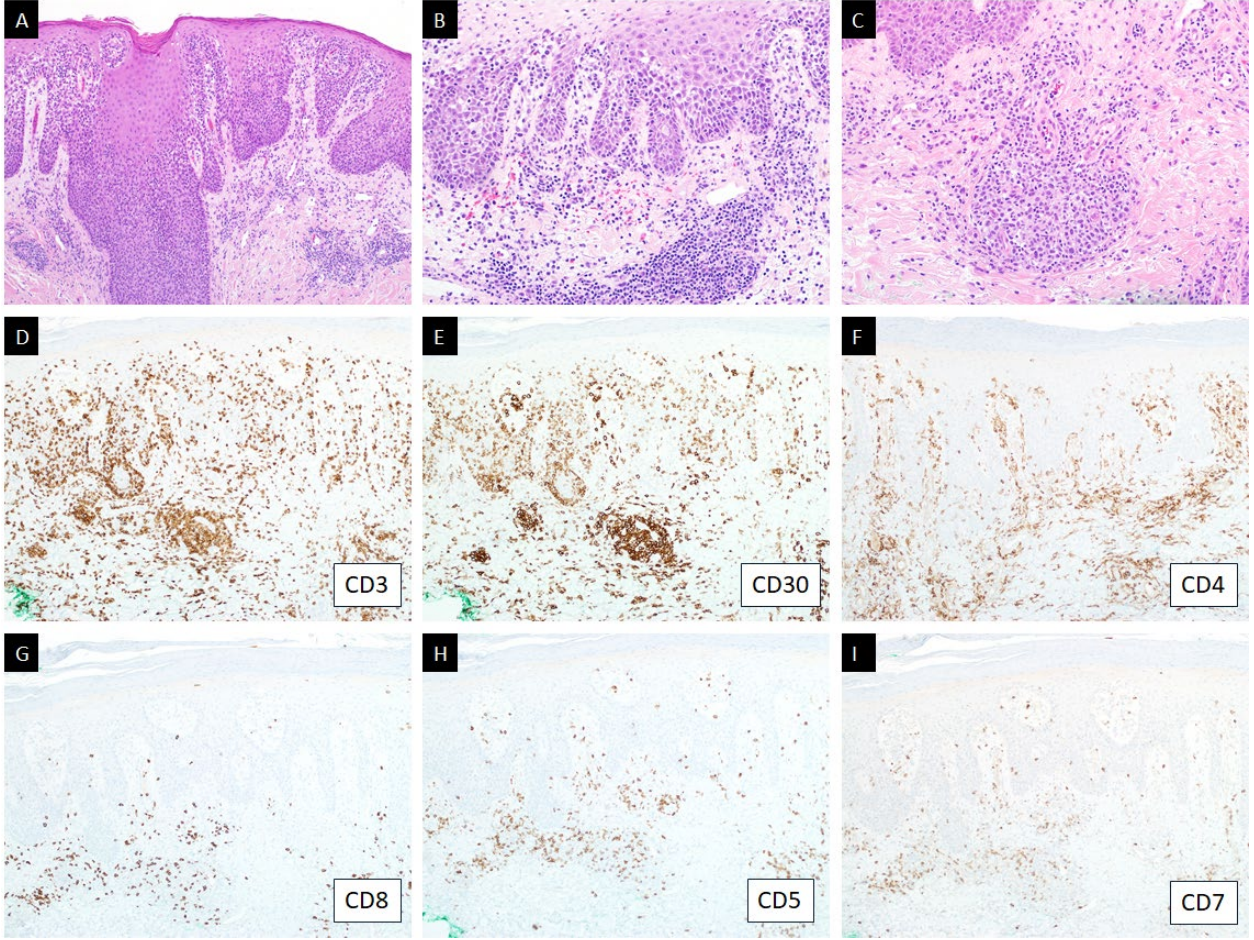
Figure 3: Systemic anaplastic large cell lymphoma with *DUSP22* rearrangement (Case 2). A, B. The lymph node is effaced by a population of large atypical lymphoid cells (original magnification x 20, x 600). C-H. These cells are CD30+, CD3+, CD4-, CD8-, CD5- and CD7- (original magnification x 400).

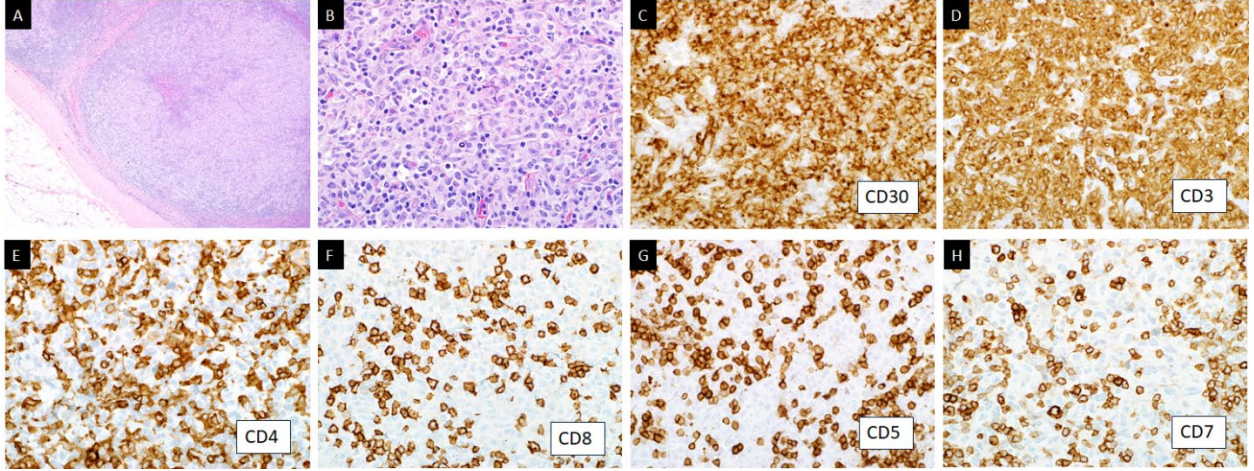
Figure 4: Cutaneous involvement by systemic anaplastic large cell lymphoma with *DUSP22* rearrangement (Case 2). A-C. A persistent nodule (A) revealed sheets of large lymphoid cells that replaced the dermis (original magnification x 40, x400). D-I. The atypical lymphoid cells are CD30+, CD3+, CD4-, CD8-, CD5- and CD7- (original magnification x 400).

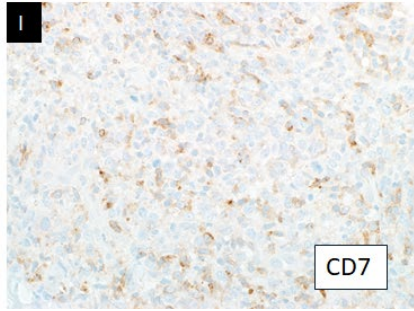
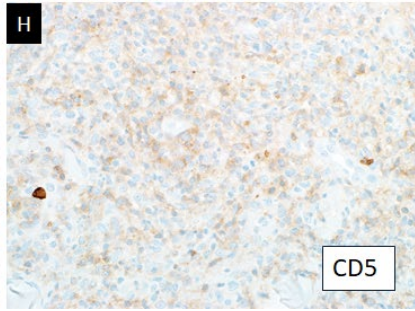
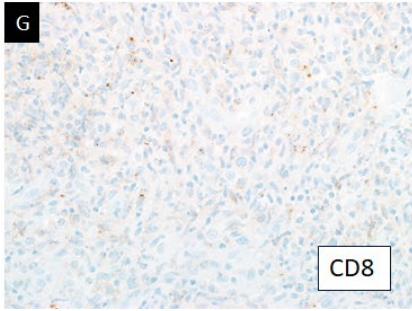
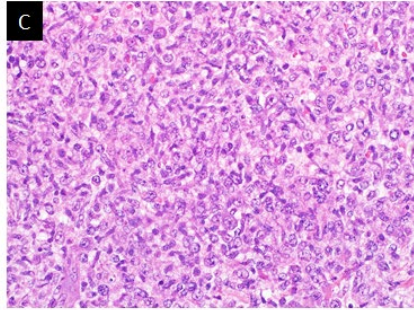
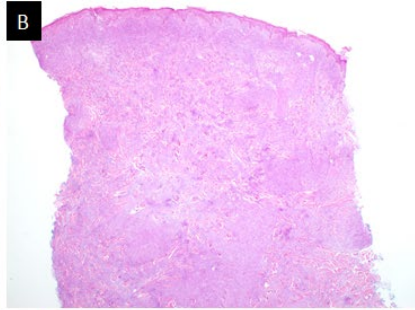
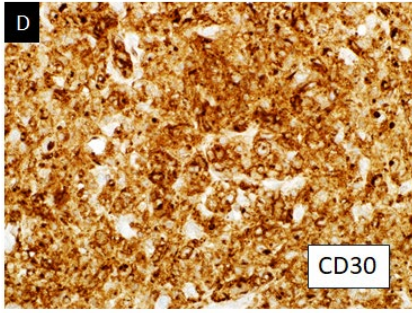
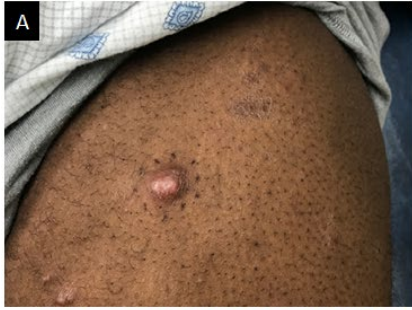Figure 5: LyP-like lesion in a patient with systemic anaplastic large cell lymphoma with *DUSP22* rearrangement (Case 2). A. The patient had multiple regressing papules under his arm. B. Biopsy showed a dense dermal infiltrate of small and large cells. Large cells formed nodules in the dermis (inset). (original magnification x 100, x 400). C. Small cells infiltrated adnexal structures and the epidermis (original magnification x 20). D-I. Both large and smaller atypical lymphoid cells are CD30+, CD3+, CD4-, CD8-, CD5 weak and CD7- (original magnification x 200).

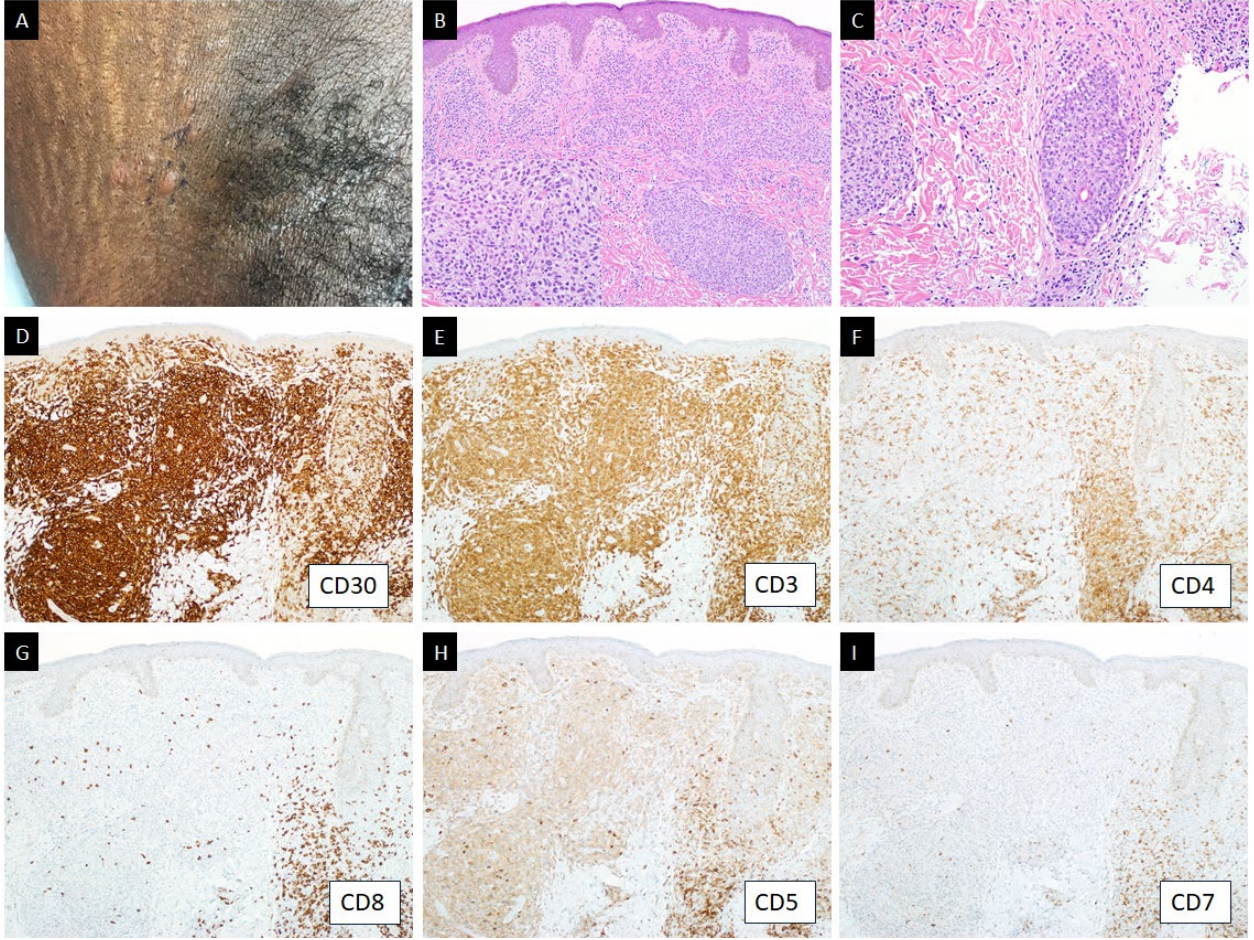
Figure 6: MF-like lesion in a patient with systemic anaplastic large cell lymphoma with *DUSP22* rearrangement (Case 2). A. The patient had xerotic patches on his back and shoulder. B-C. Biopsy revealed a folliculotropic infiltrate of slightly enlarged lymphoid cells that also surround superficial vessels (original magnification x 40, x 200). The atypical lymphoid cells are CD30+, CD3+, CD4-, CD8-, CD5- and CD7- (original magnification x 200).











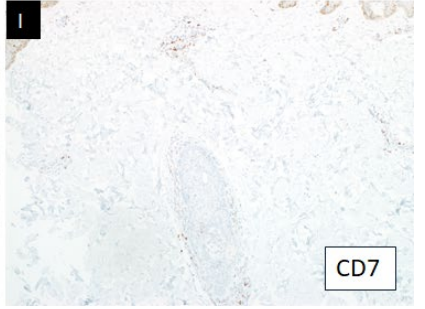
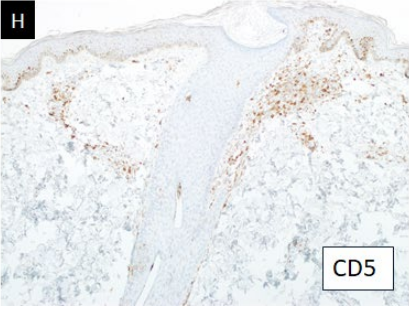
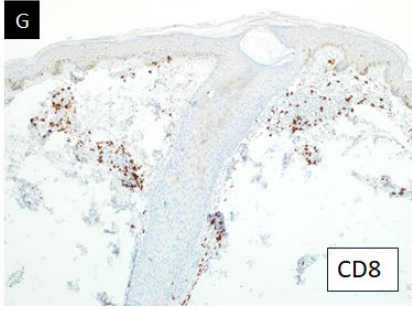
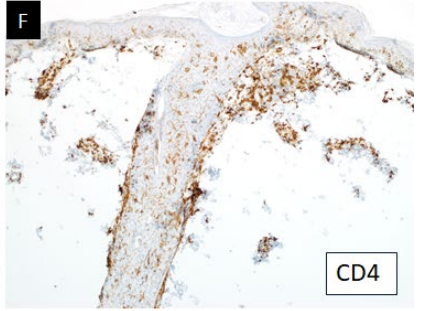
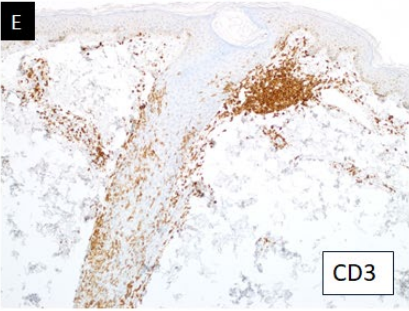
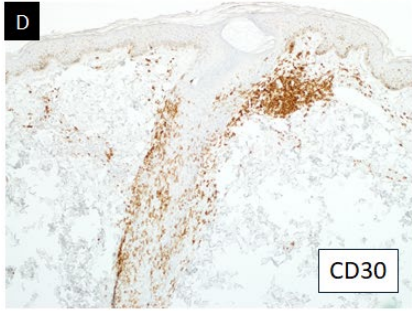
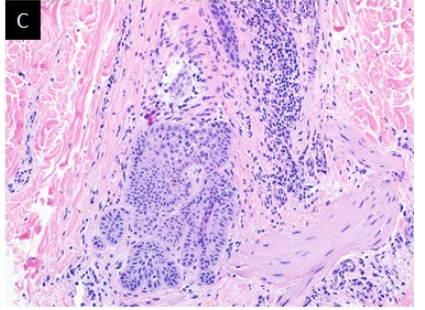
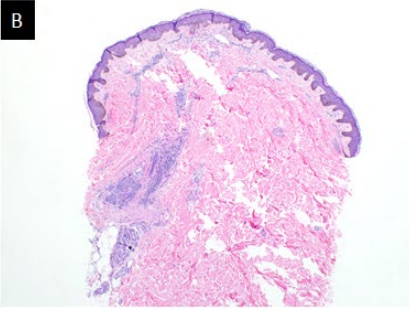
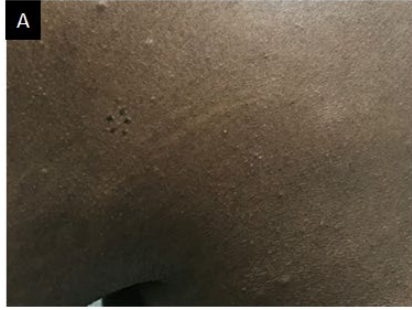
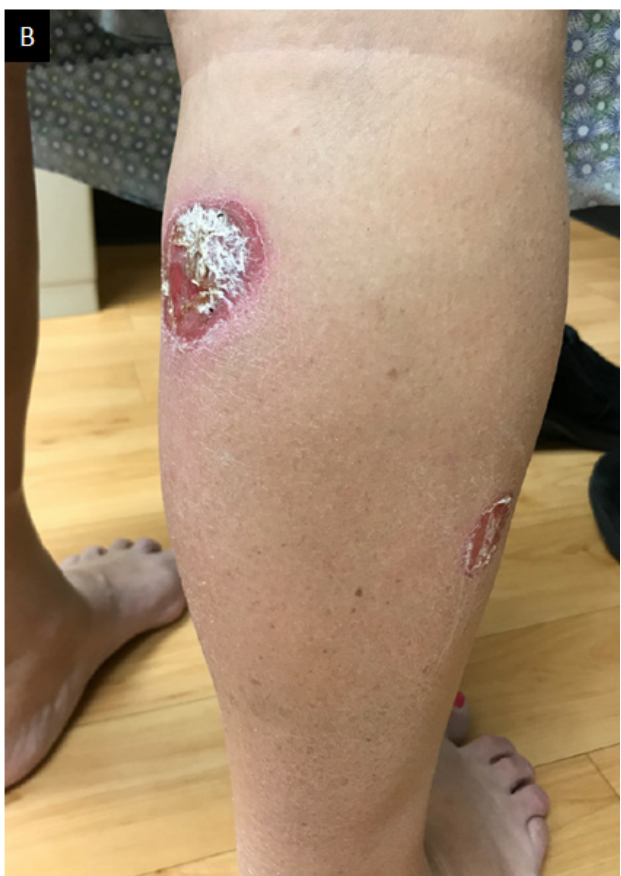
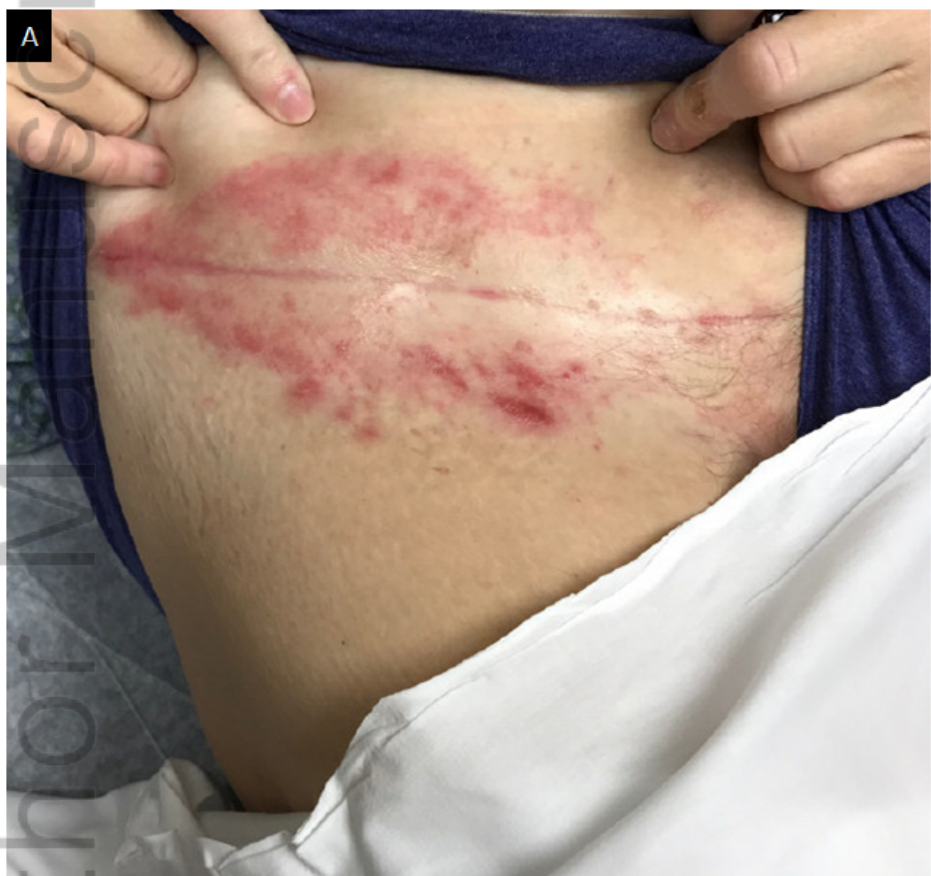Table 1: Summary of Clinical, Histopathologic and Genetic Findings

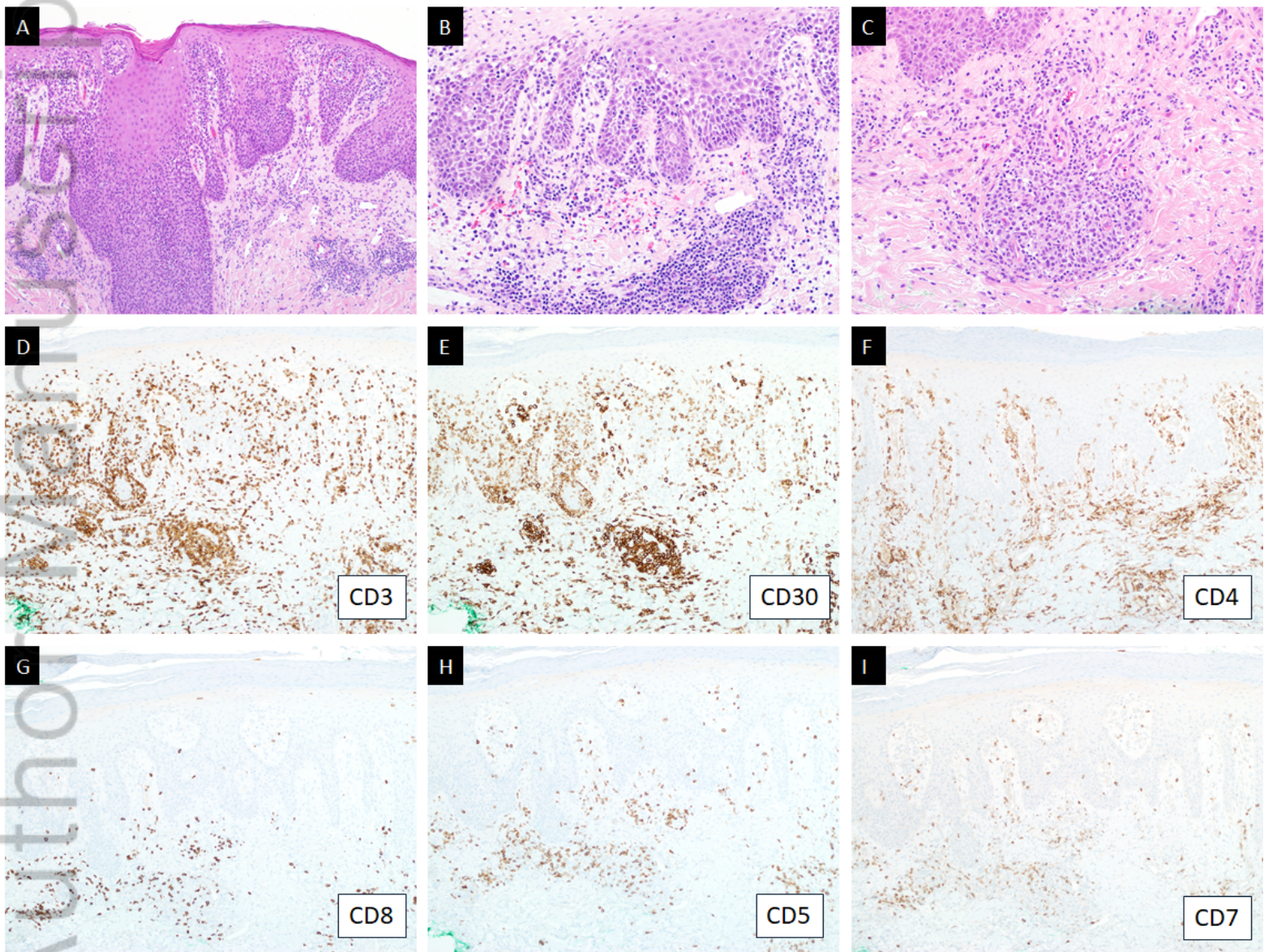
	Cutaneous Findings	BSA /mSWAT	CD30	CD3	CD4	CD8	CD2	CD5	CD7	<i>TP63</i> Rearrangement	<i>DUSP22</i> Rearrangement	TCR clone
Case 1	spreading, pruritic, erythematous papules and plaques	5%/10	+	+	-	-	+	-	-	Not Done	+	+ Identical base pair peaks in all biopsies
Case 2	xerotic patches with an MF-like appearance, persistent papulonodules, and resolving papules	3%/2	+	+	-	-	+	Weak to -	-	-	+	+ Identical base pair peaks in all biopsies

Author Manuscript

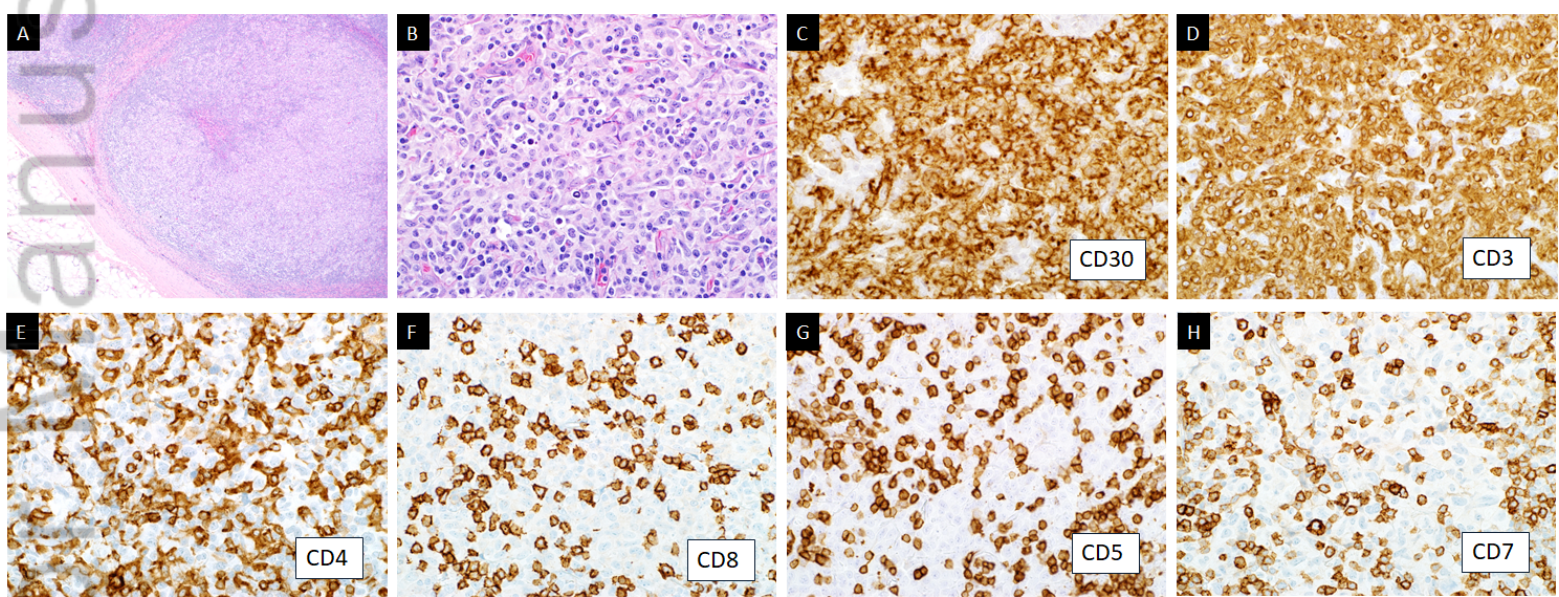


CUP_14156_Figure 1.tif

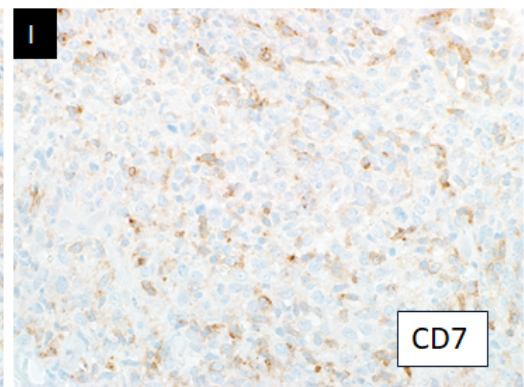
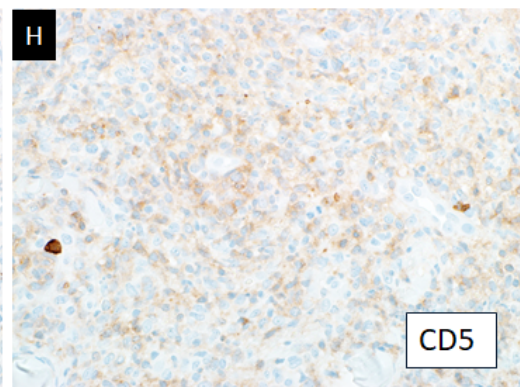
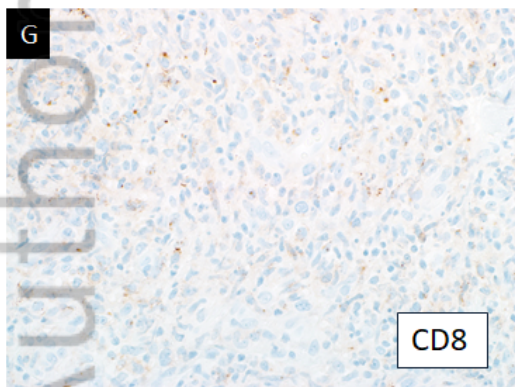
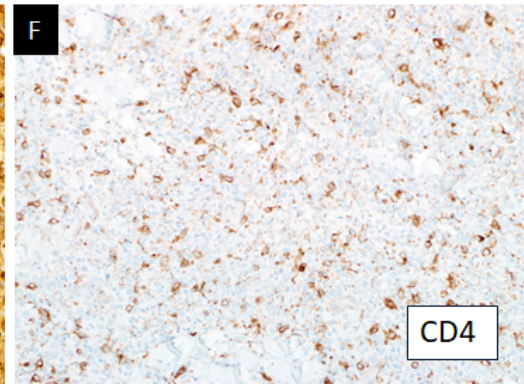
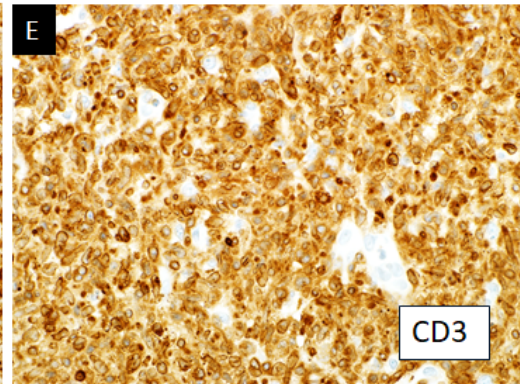
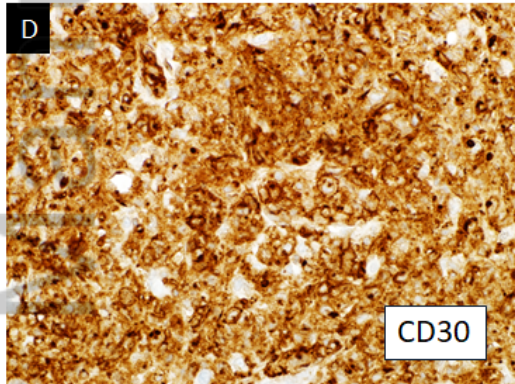
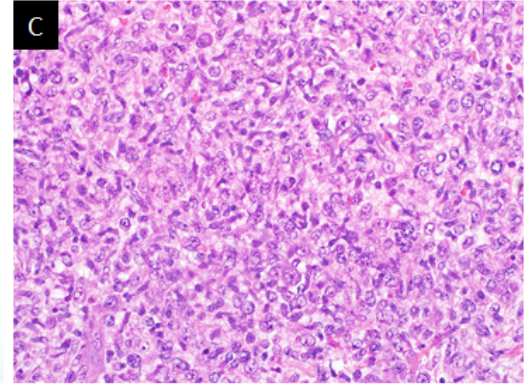
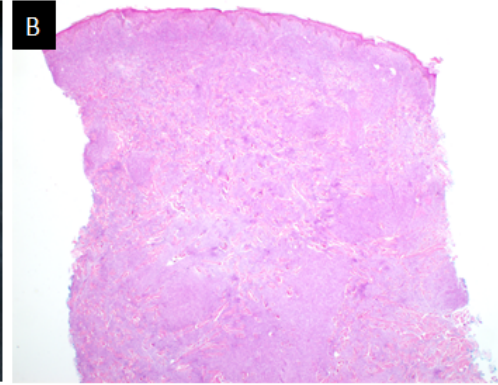
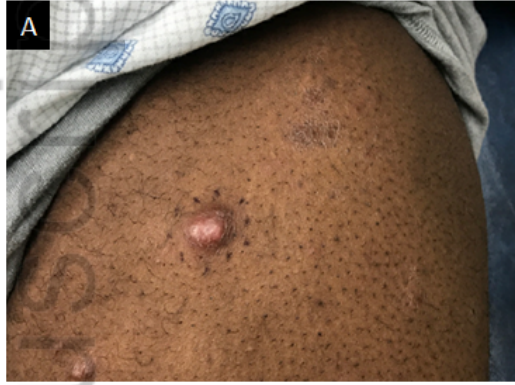Author Manuscript




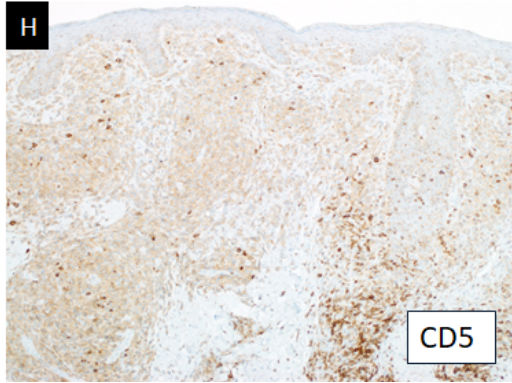

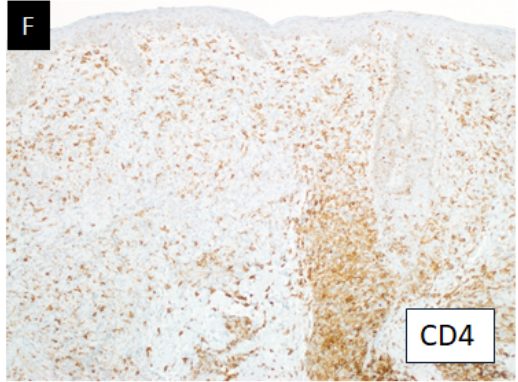
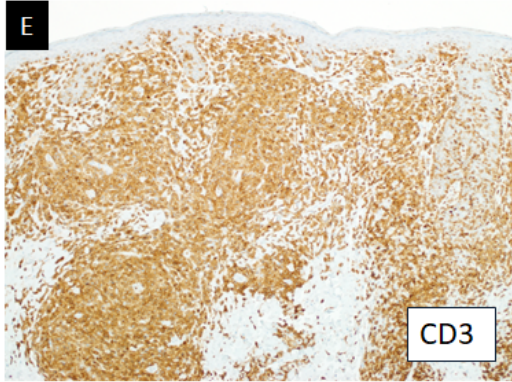

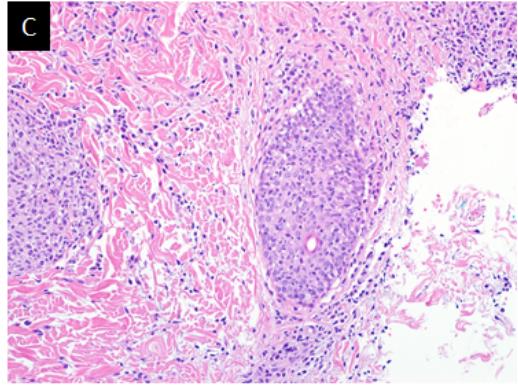
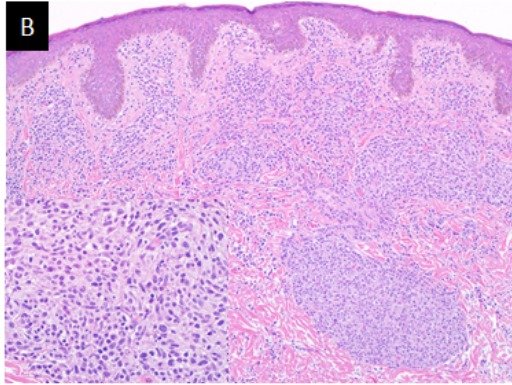
CUP_14156_Figure 2.tif



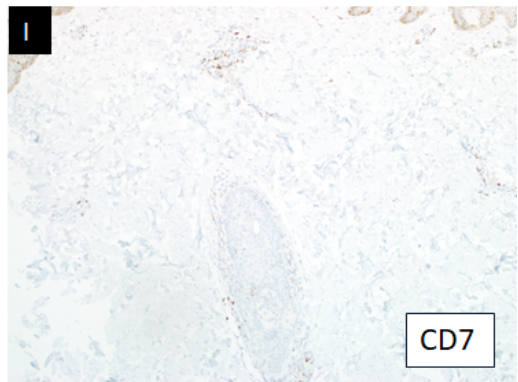
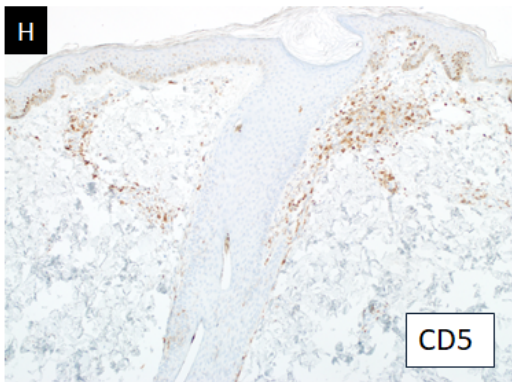
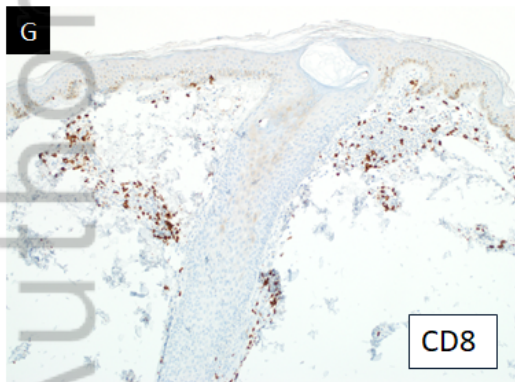
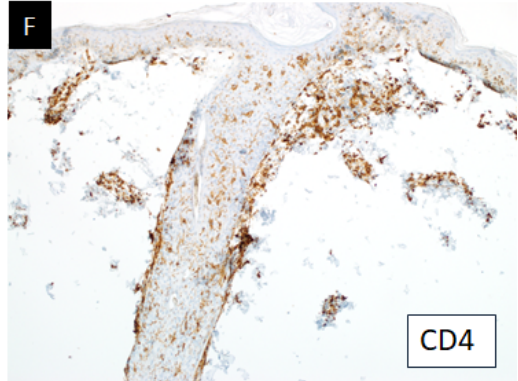
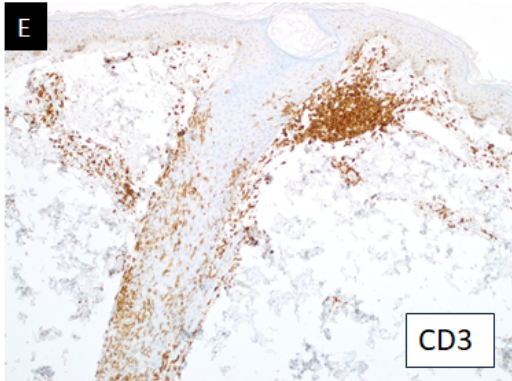
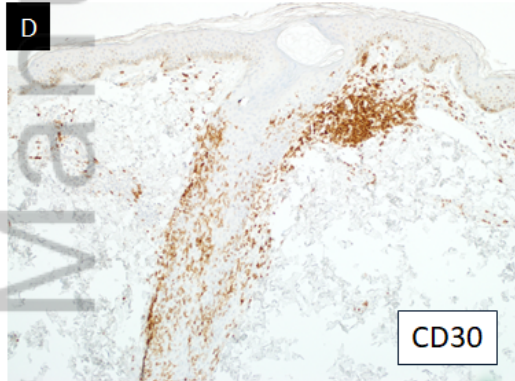
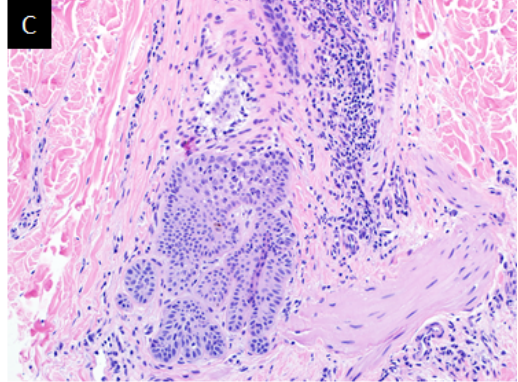
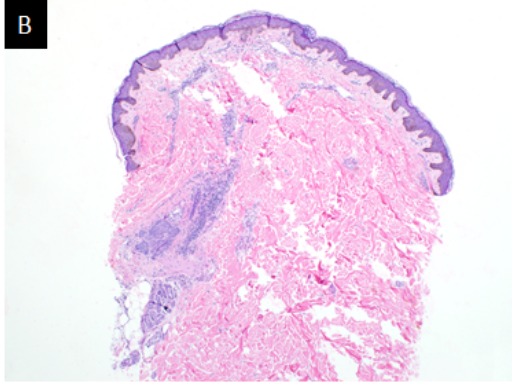
CUP_14156_Figure 3.tif



CUP_14156_Figure 4.tif



CUP_14156_Figure 5.tif



CUP_14156_Figure 6.tif