

Horizontal guided bone regeneration on knife-edge ridges: A retrospective case-control pilot study comparing two surgical techniques

Short running title: Horizontal GBR on knife-edge ridges

Authors

Helene M. ARNAL
Charles D. ANGIANI
Frederick GAULTIER
Renaud URBINELLI
Istvan A. URBAN

Affiliations

Helene M. ARNAL DDS, MSD

Department of Oral Medicine and Oral Surgery, APHP Henri Mondor Hospital, University of Paris, France
Private practice, Paris, France

Charles D. ANGIANI DDS, MSD

Department of Periodontics, APHP Henri Mondor Hospital, University of Paris, France
Private practice, Paris, France

Frederick GAULTIER DDS, PhD

Department of Oral Medicine and Oral Surgery, APHP Henri Mondor Hospital, University of Paris, France

Renaud URBINELLI

Clin-experts Paris

Istvan A. URBAN DMD MD PhD

Department of Periodontics and Oral Medicine, University of Michigan School of Dentistry, Ann Arbor, MI, USA
Prof. (Hon), University of Szeged, School of dentistry, Hungary
Urban Regeneration Institute, Budapest, Hungary

Corresponding author

Helene M. ARNAL
100 avenue de Villiers, 75017 PARIS
helenearnal@me.com

This is the author manuscript accepted for publication and has undergone full peer review but has not been through the copyediting, typesetting, pagination and proofreading process, which may lead to differences between this version and the [Version of Record](#). Please cite this article as doi: [10.1111/cid.13073](https://doi.org/10.1111/cid.13073)

Conflicts of interest:

Dr URBAN received honorarium for speaking for Geistlich Pharma
Dr ARNAL received honorarium for speaking for Geistlich Pharma
The other co-authors do not have any financial interests neither directly nor indirectly in the companies whose materials were evaluated in this study.

Author contributions

ARNAL, H. M.

Concept/design, data collection/analysis, drafting and approval of the manuscript.

ANGIONI, C.D.

Data collection, critical revision, and approval of manuscript.

GAULTIER, F.

Study design, critical revision, and approval of manuscript.

URBINELLI R.

Statistics, critical revision, and approval of manuscript.

URBAN I. A.

Surgical technique development, data interpretation, critical revision, and approval of manuscript.

Acknowledgments: The authors would like to thank Marc Marty for his availability and contribution to the design of the methods. The authors would like to thank François Petitgirard for the digital drawings.

Funding: The authors have not received any institutional, private, or corporate financial support for this study.

Data availability statement

Data available upon request from the authors.

ORCID

Helene M. ARNAL: <https://orcid.org/0000-0003-1069-7908>

Charles D. ANGIONI : <https://orcid.org/0000-0002-4857-3014>

Frederick GAULTIER: <https://orcid.org/0000-0003-3595-4464>

Renaud URBINELLI: <https://orcid.org/0000-0001-9661-6755>

Istvan A. URBAN: <https://orcid.org/0000-0002-9368-4047>

Summary Box

What is known:

Guided bone regeneration techniques using resorbable membranes with staged approaches sometimes fall short of the recommended peri-implant bone volume criteria. A recently-reported technique results in increased horizontal bone gains. In addition, few studies have reported bone resorption during the healing process.

What this study adds:

This is the first study to directly compare a conventional guided bone regeneration technique and the Sausage Technique™ via bone measurements. The bone gain and the bone resorption has been measured and analyzed for both techniques.

ABSTRACT

Introduction

Studies evaluating guided bone regeneration (GBR) on knife-edge ridges using absorbable membranes with staged approaches have reported various horizontal bone gains.

This study compared the horizontal bone gain obtained via a conventional technique of GBR and a recently-reported technique. Bone loss during the healing process was also measured.

Methods

Consecutive patients who underwent GBR on knife-edge ridges via a conventional technique (control group) or the Sausage Technique™ (test group) were included in this study. GBR was performed using a collagen membrane and deproteinized bovine bone mineral combined with an autogenous graft at a 1:1 ratio. Cone beam computed tomography (CBCT) was performed preoperatively, postoperatively, and after the patient healed. Horizontal bone width was measured on CBCT images two millimetres apical from the top of the crest. The preoperative CBCT and post-healing CBCT were superimposed to calculate the bone gain after healing, and the preoperative and postoperative CBCT scans were superimposed to calculate the bone gain after surgery. Bone loss during healing was calculated by subtracting the width of the ridge after healing from the postoperative width.

Results

The mean horizontal bone gain was significantly lower in the control group (2.7 ± 1.8 mm; 83.2%) than in the test group (5.3 ± 2.3 mm; 216.8%) ($p = 0.003$). The average horizontal bone loss between regeneration and implant placement was 0.9 mm in the control group (27.9%) and 2.1 mm in the test group (29.4%). While the absolute bone loss was significantly different ($p = 0.012$), the percentage of bone resorption was not ($p = 0.608$).

Conclusions

The new technique resulted in significantly more bone gain than a conventional GBR technique. The rate of graft resorption during healing was stable regardless of the amount of grafted material.

KEYWORDS Biomaterials, Bone gain, Bone resorption, Guided bone regeneration, Horizontal ridge augmentation, Resorbable membrane, Sausage Technique™

Bone augmentation, bone regeneration, Guided Bone Regeneration, bone grafting, bone substitute, bone resorption, bone loss

INTRODUCTION

Several studies have reported that thin peri-implant bone walls lead to more vertical bone resorption following implant placement.¹⁻³ Therefore, a peripheral peri-implant bone volume of two millimetres is recommended to allow for long-term dimensional stability of the tissues.^{1,3-6} As the diameter of a standard implant is approximately four millimetres, the preferred ridge width is approximately eight millimetres. Thin ridges (< 4 mm) do not allow for simultaneous implant placement in the bony envelope with the correct prosthetic axis⁴ (class IV of Cawood and Howell's descriptive classification⁷, class 4 of Benic's bone defect classification⁸, and class 3 of Chiapasco's bone defect classification⁴). The thickness of these ridges can be increased via blocks,^{4,8} using guided bone regeneration (GBR) with titanium-reinforced non-resorbable membranes,^{5,8} titanium meshes,⁹ absorbable membranes¹⁰ or using a combination of blocks and GBR.^{11,12} In similar indications, the alveolar ridge-splitting/expansion technique allows clinicians to perform one-step surgical procedures and to shorten the treatment time.¹³

Several studies regarding GBR for horizontal augmentations¹⁴ have reported reproducible results with implant success rates comparable to those obtained in native bone.^{8,14,15} While non-absorbable polytetrafluoroethylene (PTFE) membranes were used traditionally, resorbable membranes are easier to use and have more manageable complications.^{16,17}

In 2011, Urban et al.¹⁷ reported that a 100% autogenous bone mixture did not result in more favourable outcomes than a 1:1 mixture of autogenous bone and deproteinized bovine bone mineral (DBBM) for horizontal class IV regenerations. A mixture of particulate autogenous bone and DBBM is now commonly used, and the resulting bone quality has been confirmed histologically.^{15,17-20} The particulate structure of this mixture allows for rapid vascularization, increases the exposure to growth factors, increases the osteoconduction surface area (compared

to that of a block), and naturally adapts to the shape of the ridge.^{4,17,18,21-23} This use of this mixture allows for the combination the complementary properties of the two materials.

Studies evaluating bone regeneration on knife-edge ridges using absorbable membranes with staged approaches (bone regeneration followed by implant placement) have reported horizontal gains of 1.5 - 3.8 mm, allowing for the achievement of a ridge width of 4.9 - 6.9 mm.^{8,24-39} One systematic review reported an average horizontal gain of 3.3 mm, resulting in a final ridge width of 6.2 mm.⁴⁰ Techniques using a combination of autogenous blocks and GBR with a collagen membrane were also applied successfully and made it possible to obtain 4.6mm bone width.^{11,12,41}

In a recent meta-analysis, Naenni et al.⁴² reported that 6/25 studies were required to use complementary bone augmentation on the day of implant placement or an implant with a narrower diameter than originally planned, suggesting that the horizontal augmentation techniques used in these studies may not completely restore sufficient bone volume.

A technique using a collagen membrane that can lead to greater bone gain than other GBR techniques using only particulate grafts, has recently been reported.^{14,43} Horizontal gains of 5.56 - 7 mm resulting in final ridge widths of 7.68 - 9.14 mm have been achieved using this technique.^{17,18,23} The purpose of this retrospective study was to evaluate the horizontal bone gain obtained with two different GBR techniques: a conventional technique and the Sausage Technique™ developed by Urban et al.^{17,18,23} This study also measured the bone loss during healing between bone regeneration and implant placement.

MATERIALS & METHODS

Study design

This retrospective study was a non-interventional, single-centre, case-control study. All GBR procedures were performed by the same surgeon (HA) with over 15 years of experience in oral surgery. All patients were informed of the research, and all procedures performed in this study were in accordance with the ethical standards of the national research committee and with the 1964 Helsinki declaration and its later amendments or comparable ethical standards. The study complies with the Reference Methodology MR-004 of the National Commission for Information Technology and Civil Liberties (CNIL) and is validated under the registration number 2222406v0. The study was registered on the Health Data Hub under the number F20210610083138.

Patients

Patients with a horizontal bone defect with a thin ridge (< 4 mm wide at the top of the ridge) measured on preoperative cone beam computed tomography (CBCT) who underwent GBR via the conventional or the new technique were included in this study. Patients who underwent GBR via the conventional technique between May 2015 and June 2018 were included in the control group, and those who underwent GBR via the new technique between December 2018 and January 2020 were included in the test group. At least one preoperative CBCT scan and one post-healing CBCT scan (six months after GBR) were obtained for each patient. All patients were followed-up at least once after prosthetic rehabilitation.

Patients with conventional surgical contraindications or uncontrolled general pathologies, those receiving bisphosphonate treatments, those who consumed > 10 cigarettes per day, and those who were non-compliant to restore his or her oral health prior to GBR were excluded from the study.

Clinical procedures

All patients were administered eight days of antibiotic treatment (2 g/day of amoxicillin and clavulanic acid or 600 mg/day clindamycin with 1.5 g/day metronidazole in patients with allergies or intolerance to amoxicillin and/or clavulanic acid). Ketoprofen and/or paracetamol (codeine) were administered in patients with who complained of pain. Chlorhexidine mouthwashes were prescribed for ten days, starting 24 hours postoperatively.

Surgical technique

All surgeries were conducted using local anaesthesia.

Control group:

In conventional GBR, a full-thickness flap was elevated using vertical vestibular incisions away from the surgical site. Cortical perforations were made, and a reticulated resorbable membrane (OsseoGuard® CE mark, Zimmer Biomet, Indiana, USA) was fixed using lingual/palatal pins (Geistlich Titan-fix set® CE mark, Geistlich Pharma, AG, Wolhusen Switzerland) that were impacted in bone with a pin holder and a mallet. A 1:1 mixture of particulate autograft and DBBM (Bio-Oss® CE mark, Geistlich Pharma, AG, Wolhusen Switzerland) was placed on the defect, and the membrane was folded over the mixture then fixed using pins (Figure 1, C1 to C3, Figure 3, C0). The autogenous bone was collected near the site using a bone scraper. Buccal flap advancement in the control group was performed using a classical periosteal releasing incision connecting the two vertical incisions.

The flap was sutured in two layers: horizontal mattress sutures, then single interrupted sutures.

Test group:

The surgical technique has been described previously.^{17,18,44} Briefly, a full-thickness flap was elevated using vestibular vertical incisions made two teeth from the surgical site and a mesio-lingual or mesio-palatal vertical incision at the mesial tooth bordering the surgical site. Cortical perforations were made, and a resorbable collagenous membrane (Bio-Gide® CE mark, Geistlich Pharma, AG, Wolhusen Switzerland) was fixed with lingual/palatal pins (mostly Master-Pin-Control® CE mark, Hager and Meisinger GmbH, Neuss Germany) that were impacted in bone with a pin holder and a mallet. A 1:1 mixture of particulate autograft and DBBM (Bio-Oss® CE mark, Geistlich Pharma, AG, Wolhusen Switzerland) was placed on the defect. The membrane was pulled back over the mixture, stretched, and held in place using buccal pins. After placing a pin at the distal buccal part, a second pin was placed by stretching the membrane at the buccal mesial part. (Figure 2, T1 to T3, Figure 3, T0). Care was taken to position and immobilize the graft by stretching and fixating the membrane with additional titanium pins until complete crestal stability of the graft was achieved. The elasticity of the membrane was key in the successful immobilization of the bone graft. Once the membrane had been secured with all the pins, a blunt periosteal instrument was used to evaluate the compaction: the construction should feel as dense as possible.

Autogenous bone was collected near the site or from the retromolar mandibular area. A bone scraper or trephines and a bone mill (Bone management Master-Core® and Master-Mill® CE mark, Hager and Meisinger GmbH, Neuss Germany) were used depending on the patient's anatomy.

Buccal flap advancement was performed using the periosteal-elastic technique which has been described previously.^{45,44} Briefly, a gentle periosteal incision connecting the vertical incision was done. Then the periosteal cross bundles underneath were carefully cut with sweeping incisions. The last step was the elastic fiber separation, completed using a blunt periosteal instrument in a coronal pushing motion.

On mandibular cases, a lingual flap advancement was also done in the test group using the modified lingual flap advancement technique.⁴⁶

The flap was sutured in two layers: first, horizontal mattress sutures placed 5 mm from the crestal incision, every 5 mm. Then, single interrupted sutures were used to finalize the closure. This creates a 5 mm connective tissue barrier that protects the graft from exposure.

Data collection

Patient age, sex, health status, periodontal condition, history of bone defects, and GBR healing times were recorded. CBCT images were performed preoperatively, immediately after GBR surgery, and post-healing. Post-healing CBCT scans were obtained at least six months after GBR at the time of implant placement. All CBCT images were obtained using Planmeca ProMax® 3D (PLANMECA OY, Helsinki, Finland). Measurements were obtained by two independent examiners (HA and CA), including one who was blinded to the patient group allocations and not involved in the treatment of patients (CA). If a difference of more than 0.6 mm was observed between the observers' measurements, the measurements were repeated. The ridge width was measured two millimetres apical to the top of the crest^{17,18,24–26,47–49} and perpendicular to the major axis of the ridge.^{25,26,33,38,50–52}

Endpoints

The study's primary endpoint was bone gain obtained after the GBR healed. The preoperative CBCT and post-healing CBCT images were superimposed using Planmeca Romexis® software (PLANMECA OY)^{51,53–55} (Figure 1, C8; Figure 2, T8).

The secondary endpoints were bone gain and bone loss. Bone gain after surgery was measured by superimposing the preoperative CBCT and postoperative CBCT images using Planmeca Romexis® software (PLANMECA OY) (Figure 1, C7; Figure 2, T7).

Bone loss was measured between the day of surgery and after healing by subtracting the width of the ridge after healing from the postoperative width. The mean bone loss was also calculated for two subgroups within the test group: patients who underwent GBR at anterior sites (incisors and canines) and those who underwent GBR at posterior sites (premolars and molars).

Statistical analysis

Non-parametric Wilcoxon rank tests were conducted to compare non-normal data. The average of the measurements obtained by two observers was used for all analyses. The mean bone gain ratios were calculated as percentages. The mean bone loss ratios between the day of surgery and healing were also calculated as percentages. The Strengthening the Reporting of Observational Studies in Epidemiology (STROBE) guidelines⁵⁶ were followed during the preparation of this manuscript.

RESULTS

Enrolment and clinical course

A total of 15 patients (16 defects and 30 implants; 60% men) were included in the control group, and 16 patients (16 defects and 25 implants; 37.5% men) were included in the test group. One patient in the test group was lost to follow-up and was excluded from the study.

Patients

The mean patient age was 57.6 years (standard deviation (SD) = 13.8 years) in the control group and 56.2 years (SD = 14.4 years) in the test group (Table 1). Three patients in the control group had a systemic disease, including one with stabilised thyroid disease, one with sickle cell disease, and one with stabilised hypertension. The test group also included three patients with systemic diseases, including one with stabilised coronary heart disease, one with stabilised

thyroid disease, and one with a stabilised psychiatric disorder. Four patients (26%) in the control group and three (18.7%) in the test group had stabilised early or moderate chronic periodontal disease. The causes of the bone defects included alveolar resorption following extraction > 5 years prior to the study (13 sites), implant failure (3 sites), and dental pathology (trauma, infection, or inflammatory pathologies) (10 sites). In six cases, the teeth were extracted by an outside provider and no data regarding the cause was provided. The implant sites are shown in Table 2.

Control group

The average healing time in the control group was 9.2 months (SD = 3.3 months). The osseointegration of the implants (Tapered Screw-Vent® CE mark, Zimmer Biomet, Indiana, USA) was tested at least two months after insertion (mean duration: 3.5 months, SD = 1.1 months). Some patients have had very little post-operative discomfort, including oedema, pain, and/or bruising, though no discomfort lasted longer than two weeks. One patient had a wound dehiscence after one month. Two implants failed and were removed. They were not replaced as prosthetic rehabilitation was possible on the remaining implants.

Test group

The average healing time in the test group was 8.1 months (SD = 1.7 months). The osseointegration of the implants (Tapered Screw-Vent® CE mark, Zimmer Biomet, Indiana, USA) was tested at least two months after insertion (mean duration: 4 months; SD, 2 months). Some patients have had very little post-operative discomfort, including oedema, pain, and/or bruising, though no discomfort lasted longer than two weeks. One patient presented with paraesthesia that lasted six months.

Primary endpoint

The mean horizontal bone gain obtained after healing was 2.7 mm (SD = 1.8 mm; 83.2%) in the control group and 5.3 mm (SD = 2.3 mm; 216.8%) in the test group ($p = 0.003$) (Tables 3 and 4).

Secondary endpoints

Data regarding the width of the ridge on the day of surgery was available for 12 patients in the control group and 15 patients in the test group (Table 4). The mean bone loss between the day of surgery and post-healing was 0.9 mm (SD = 0.8 mm) in the control group and 2.1 mm (SD = 1.6 mm) in the test group ($p = 0.012$). The rate of bone resorption was 27.9% in the control group and 29.4% in the test group ($p = 0.608$).

Among patients who underwent GBR using the new technique for posterior sites ($n = 10$), the mean bone loss was 1.7 mm (SD = 1.7mm), and that among patients who underwent GBR using the new technique for anterior sites ($n = 5$) was 2.9 mm (SD = 1.1mm), ($p = 0.126$) (Table 5).

DISCUSSION

The mean horizontal bone gain obtained after healing was significantly greater with the new technique than with the conventional technique.

Horizontal gain

The average horizontal gain obtained via the conventional GBR technique in this study is consistent with previously published results regarding atrophic ridges treated with similar techniques (bone regeneration with particulate graft and resorbable membrane) which reported horizontal gains from 1.5 mm to 3.8 mm.^{10,24-40,57} The average horizontal gain obtained via the

new technique in this study is also consistent with previously-reported results of studies using, or inspired by this technique which reported horizontal gains of 5.03mm to 7mm.^{17,18,47-49}

The mean ridge width was significantly different between the groups in this study. This may be due to the fact that the conventional GBR technique used in this study did not allow for sufficient volume gains, and excessively atrophic ridges were treated via autogenous blocks. In a meta-analysis by Naenni et al.,⁴² the thinnest ridges were associated with a slightly greater newwidth gain (0.35 mm of difference per millimeter of ridge width). The authors of the meta-analysis assumed that larger grafts were performed on the thinnest ridges or that the resorption pattern tended to follow the original anatomy of the ridge.

It is difficult to achieve mechanically-stable grafts of large volumes using the conventional technique. In the control group the membrane used was a non-stretchable reticulated membrane. The bone graft was positioned under but could not be packed. As a consequence, the graft volume placed was limited. Some studies have reported relatively high bone loss during healing, which may be related to the non-space-maintaining nature of some defects.³⁵ However, when the new technique is used, the volume can be maintained by itself, without the use of a form-stable device, even in non-space-maintaining defects. In the test group the membrane used was a stretchable collagen membrane. This property allowed the graft material to be compressed and to add more graft volume under the membrane.

In this study, the postoperative ridge width obtained using the new technique was significantly higher than that obtained using the conventional technique, and there was also a non-significant tendency for a greater final crest width in patients who underwent GBR via the new technique.

The new technique allowed for the treatment of thinner ridges and resulted in twice the final bone gain after healing.

Horizontal bone loss between surgery and implant placement

The average horizontal bone loss between regeneration and implant placement was higher in the test group in this study. Previous studies using particulate allografts or xenografts (alone or in combination with particulate autogenous bone) reported a wide range of bone loss (0.54 mm to 3.1 mm).^{28-30,33-35,42,47,58} A systematic review⁴³ noted that the greatest bone gains were reported by Urban¹⁸ and Gultekin,⁴⁷ and theorized that these bone gains were due to the composition of the particulate grafts used in these studies (1:1 mixture of particulate autograft and DBBM), as xenografts slow the resorption of autogenous bone,^{15,19,20} promoting volume gain. A meta-analysis⁴² also reported a lower resorption (-11.6%) for augmentations using xenografts compared to augmentations involving only autogenous bone. However, studies using xenografts obtained different values of bone gains, as in this study. Therefore, the grafting technique must be considered to improve bone gain.

Bone loss may be due to the resorption of particles and clots, soft tissue pressure, or displacement of graft material.^{33,35,59,60} Soft tissue and muscle pressure may have led to greater bone loss at the single anterior sites in this study. Pressure from the orbicularis muscle at the beginning of the healing process may promote anterior graft resorption.

The postoperative bone gain and post-healing bone loss were greater among patients who underwent new GBR in this study. However, the percentage of bone resorption was not significantly different between the two groups. Amorfini⁵⁴ reported a positive correlation between the grafted volume and the percentage of bone resorption at one year in dehiscence defects that had been treated with GBR (resorbable membranes and 1:1 mixture of particulate

autograft and DBBM). Gultekin⁴⁷ reported an overall bone volume loss of 12.48% in the GBR group (1:1 mixture of particulate autograft and DBBM) and a positive correlation between the postoperative graft volume and the graft resorption rate. However, these findings are not consistent with another study that did not report a correlation between the grafted volume and the percentage of graft material resorbed during healing.³⁵ According to the results of this study, the resorption rate may be stable regardless of the amount of grafted material.

Technique

Following the principles of the Sausage Technique™ the bone grafts of the test group were well condensed in this study. Several studies have demonstrated the benefits of better compaction on the bone quality. A previous study compared the compaction of particulate grafts in rabbits at a pressure of 4.1 g on one side and 8.2 g on the contralateral side.⁶¹ Histomorphometry examination revealed a higher amount of newly formed bone, greater bone density, and higher proportion of defect filling on the side compacted with 8.2 g, suggesting the importance of compacting grafts well and using a membrane to compress them. A study regarding socket preservation in dogs reported that greater compaction forces of the particles resulted in greater quantities of newly formed bone.⁶² Similar results have been reported in humans in a histological study regarding alveolar ridge preservations with Geistlich Bio Oss® Collagen with a force of 5 N or 30 N. Approximately twice as much bone formed in the 30 N group compared to the 5 N group at four months.⁶³ These previous results indicate that the compressive forces may allow for more intimate contact between the particles, resulting in easier bony bridging. These forces also allowed for better stabilisation of the particles. It is theorized that compression accelerates bone formation by stimulating angiogenesis and the expression of genes involved in cell proliferation.⁶³ However, these results are not consistent with another previous study that did not observe histological differences between groups with different compressive forces.⁶⁴ In

the field of orthopaedics, studies regarding the placement of acetabular cup prostheses have shown that the impaction of particulate bone grafts in the acetabulum has positive effects on the quality and kinetics of bone formation and on particle stabilization.⁶⁵ Therefore, the benefits of compacting have now been reported histologically in these recent studies, except for one.

Limitations

There is however a limitation to the GBR techniques described here: the staged approach and the need for a prolonged treatment time when compared to ridge-split technique with simultaneous approach. Positive results have been reported with this technique.¹³

This study is not without limitations. First, measurements were made only radiologically, not clinically. There is a possibility that radiographs showing bone ossification were misread, although clinical observations made at the time of implant placement support ossification. The relative precision of clinical and radiological measurements is controversial, and CBCT measurements are sometimes preferred.^{35,42} This study is also limited by its retrospective nature and small sample size.

In addition, as this is the first series conducted with this technique, the procedures were conducted within the operator's learning curve, and greater precision in the compaction of the mixture and the tension of the membrane would likely provide more homogeneous results and less bone loss. It was observed that much better results can be achieved using the new technique than with the conventional technique, even at the beginning of the learning curve. To the best of our knowledge, this study is the first study to directly compare the new technique to a classic GBR technique. Further prospective studies are needed to verify the outcomes achieved using this technique.

CONCLUSION

The new technique resulted in superior bone gain compared to the conventional GBR technique. In this study, the rate of graft resorption during healing was stable regardless of the amount of grafted material. The use of the Sausage Technique™ allows for a more predictable treatment of horizontal bone defects by meeting the current criteria for required peri-implant bone volume. In addition, this technique does not require space-maintaining defects or form-stable devices. Further studies are needed to confirm these results in the long term.

REFERENCES

1. Spray JR, Black CG, Morris HF, Ochi S. The influence of bone thickness on facial marginal bone response: stage 1 placement through stage 2 uncovering. *Ann Periodontol.* 2000;5(1):119-128. doi:10.1902/annals.2000.5.1.119
2. Wennström JL, Ekestubbe A, Gröndahl K, Karlsson S, Lindhe J. Oral rehabilitation with implant-supported fixed partial dentures in periodontitis-susceptible subjects. A 5-year prospective study. *J Clin Periodontol.* 2004;31(9):713-724. doi:10.1111/j.1600-051X.2004.00568.x
3. Monje A, Chappuis V, Monje F, et al. The Critical Peri-implant Buccal Bone Wall Thickness Revisited: An Experimental Study in the Beagle Dog. *Int J Oral Maxillofac Implants.* 2019;34(6):1328-1336. doi:10.11607/jomi.7657
4. Chiapasco M, Casentini P. Horizontal bone-augmentation procedures in implant dentistry: prosthetically guided regeneration. *Periodontol 2000.* 2018;77(1):213-240. doi:10.1111/prd.12219
5. Grunder U. *Implants in the Esthetic Zone.* Quintessence Publishing; 2016.
6. Buser D, Chappuis V, Bornstein MM, Wittneben JG, Frei M, Belser UC. Long-term stability of contour augmentation with early implant placement following single tooth extraction in the esthetic zone: a prospective, cross-sectional study in 41 patients with a 5- to 9-year follow-up. *J Periodontol.* 2013;84(11):1517-1527. doi:10.1902/jop.2013.120635
7. Cawood JI, Howell RA. Reconstructive preprosthetic surgery. I. Anatomical considerations. *Int J Oral Maxillofac Surg.* 1991;20(2):75-82. doi:10.1016/s0901-5027(05)80711-8
8. Benic GI, Hämmerle CHF. Horizontal bone augmentation by means of guided bone regeneration. *Periodontol 2000.* 2014;66(1):13-40. doi:10.1111/prd.12039
9. Chiapasco M, Casentini P, Tommasato G, Dellavia C, Del Fabbro M. Customized CAD/CAM titanium meshes for the guided bone regeneration of severe alveolar ridge defects: Preliminary results of a retrospective clinical study in humans. *Clin Oral Implants Res.* 2021;32(4):498-510. doi:10.1111/clr.13720
10. Hämmerle CHF, Jung RE, Yaman D, Lang NP. Ridge augmentation by applying bioresorbable membranes and deproteinized bovine bone mineral: a report of twelve consecutive cases. *Clin Oral Implants Res.* 2008;19(1):19-25. doi:10.1111/j.1600-0501.2007.01407.x
11. Proussaefs P, Lozada J. The use of resorbable collagen membrane in conjunction with autogenous bone graft and inorganic bovine mineral for buccal/labial alveolar ridge augmentation: a pilot study. *J Prosthet Dent.* 2003;90(6):530-538. doi:10.1016/s0022-3913(03)00521-3
12. von Arx T, Buser D. Horizontal ridge augmentation using autogenous block grafts and the guided bone regeneration technique with collagen membranes: a clinical study with 42 patients. *Clin Oral Implants Res.* 2006;17(4):359-366. doi:10.1111/j.1600-0501.2005.01234.x
13. Crespi R, Toti P, Covani U, Crespi G, Menchini-Fabris GB. Maxillary and Mandibular Split Crest Technique with Immediate Implant Placement: A 5-Year Cone Beam Retrospective Study. *Int J Oral Maxillofac Implants.* 2021;36(5):999-1007. doi:10.11607/jomi.8572
14. Sanz-Sánchez I, Ortiz-Vigón A, Sanz-Martín I, Figuero E, Sanz M. Effectiveness of Lateral Bone Augmentation on the Alveolar Crest Dimension: A Systematic Review and Meta-analysis. *J Dent Res.* 2015;94(9 Suppl):128S-42S. doi:10.1177/0022034515594780
15. Jensen SS, Terheyden H. Bone augmentation procedures in localized defects in the

- alveolar ridge: clinical results with different bone grafts and bone-substitute materials. *Int J Oral Maxillofac Implants*. 2009;24 Suppl:218-236.
16. Friedmann A, Strietzel FP, Maretzki B, Pitaru S, Bernimoulin JP. Histological assessment of augmented jaw bone utilizing a new collagen barrier membrane compared to a standard barrier membrane to protect a granular bone substitute material. *Clin Oral Implants Res*. 2002;13(6):587-594. doi:10.1034/j.1600-0501.2002.130603.x
 17. Urban IA, Nagursky H, Lozada JL. Horizontal ridge augmentation with a resorbable membrane and particulated autogenous bone with or without anorganic bovine bone-derived mineral: a prospective case series in 22 patients. *Int J Oral Maxillofac Implants*. 2011;26(2):404-414.
 18. Urban IA, Nagursky H, Lozada JL, Nagy K. Horizontal ridge augmentation with a collagen membrane and a combination of particulated autogenous bone and anorganic bovine bone-derived mineral: a prospective case series in 25 patients. *Int J Periodontics Restorative Dent*. 2013;33(3):299-307. doi:10.11607/prd.1407
 19. Jensen SS, Brogгинi N, Hjørting-Hansen E, Schenk R, Buser D. Bone healing and graft resorption of autograft, anorganic bovine bone and beta-tricalcium phosphate. A histologic and histomorphometric study in the mandibles of minipigs. *Clin Oral Implants Res*. 2006;17(3):237-243. doi:10.1111/j.1600-0501.2005.01257.x
 20. Jensen SS, Bosshardt DD, Gruber R, Buser D. Long-term stability of contour augmentation in the esthetic zone: histologic and histomorphometric evaluation of 12 human biopsies 14 to 80 months after augmentation. *J Periodontol*. 2014;85(11):1549-1556. doi:10.1902/jop.2014.140182
 21. Urban IA, Jovanovic SA, Lozada JL. Vertical ridge augmentation using guided bone regeneration (GBR) in three clinical scenarios prior to implant placement: a retrospective study of 35 patients 12 to 72 months after loading. *Int J Oral Maxillofac Implants*. 2009;24(3):502-510.
 22. Urban IA, Lozada JL, Jovanovic SA, Nagursky H, Nagy K. Vertical ridge augmentation with titanium-reinforced, dense-PTFE membranes and a combination of particulated autogenous bone and anorganic bovine bone-derived mineral: a prospective case series in 19 patients. *Int J Oral Maxillofac Implants*. 2014;29(1):185-193. doi:10.11607/jomi.3346
 23. Urban IA, Monje A, Lozada JL, Wang HL. Long-term Evaluation of Peri-implant Bone Level after Reconstruction of Severely Atrophic Edentulous Maxilla via Vertical and Horizontal Guided Bone Regeneration in Combination with Sinus Augmentation: A Case Series with 1 to 15 Years of Loading. *Clin Implant Dent Relat Res*. 2017;19(1):46-55. doi:10.1111/cid.12431
 24. Mazzocco F, Nart J, Cheung WS, Griffin TJ. Prospective evaluation of the use of motorized ridge expanders in guided bone regeneration for future implant sites. *Int J Periodontics Restorative Dent*. 2011;31(5):547-554.
 25. de Freitas RM, Susin C, Spin-Neto R, et al. Horizontal ridge augmentation of the atrophic anterior maxilla using rhBMP-2/ACS or autogenous bone grafts: a proof-of-concept randomized clinical trial. *J Clin Periodontol*. 2013;40(10):968-975. doi:10.1111/jcpe.12148
 26. de Freitas RM, Susin C, Tamashiro WM da SC, et al. Histological analysis and gene expression profile following augmentation of the anterior maxilla using rhBMP-2/ACS versus autogenous bone graft. *J Clin Periodontol*. 2016;43(12):1200-1207. doi:10.1111/jcpe.12601
 27. Geurs NC, Korostoff JM, Vassilopoulos PJ, et al. Clinical and histologic assessment of lateral alveolar ridge augmentation using a synthetic long-term bioabsorbable membrane and an allograft. *J Periodontol*. 2008;79(7):1133-1140. doi:10.1902/jop.2008.070595
 28. Eskan MA, Greenwell H, Hill M, et al. Platelet-rich plasma-assisted guided bone

- regeneration for ridge augmentation: a randomized, controlled clinical trial. *J Periodontol*. 2014;85(5):661-668. doi:10.1902/jop.2013.130260
29. Eskan MA, Girouard ME, Morton D, Greenwell H. The effect of membrane exposure on lateral ridge augmentation: a case-controlled study. *Int J Implant Dent*. 2017;3(1):26. doi:10.1186/s40729-017-0089-z
 30. Caldwell GR, Mills MP, Finlayson R, Mealey BL. Lateral alveolar ridge augmentation using tenting screws, acellular dermal matrix, and freeze-dried bone allograft alone or with particulate autogenous bone. *Int J Periodontics Restorative Dent*. 2015;35(1):75-83. doi:10.11607/prd.2260
 31. Patel A, Greenwell H, Hill M, Shumway B, Radmall A. Ridge Augmentation Comparing an Allograft Plus Autogenous Bone Chips to an Osteoinductive Demineralized Bone Matrix: A Clinical and Histologic Study in Humans. *Implant Dent*. 2019;28(6):613-620. doi:10.1097/ID.0000000000000925
 32. Meijndert L, Raghoobar GM, Schüpbach P, Meijer HJA, Vissink A. Bone quality at the implant site after reconstruction of a local defect of the maxillary anterior ridge with chin bone or deproteinised cancellous bovine bone. *Int J Oral Maxillofac Surg*. 2005;34(8):877-884. doi:10.1016/j.ijom.2005.04.017
 33. Mordenfeld A, Johansson CB, Albrektsson T, Hallman M. A randomized and controlled clinical trial of two different compositions of deproteinized bovine bone and autogenous bone used for lateral ridge augmentation. *Clin Oral Implants Res*. 2014;25(3):310-320. doi:10.1111/clr.12143
 34. Block MS, Ducote CW, Mercante DE. Horizontal augmentation of thin maxillary ridge with bovine particulate xenograft is stable during 500 days of follow-up: preliminary results of 12 consecutive patients. *J Oral Maxillofac Surg*. 2012;70(6):1321-1330. doi:10.1016/j.joms.2012.01.026
 35. Sterio TW, Katancik JA, Blanchard SB, Xenoudi P, Mealey BL. A prospective, multicenter study of bovine pericardium membrane with cancellous particulate allograft for localized alveolar ridge augmentation. *Int J Periodontics Restorative Dent*. 2013;33(4):499-507. doi:10.11607/prd.1704
 36. Pelegrine AA, Teixeira ML, Sperandio M, et al. Can bone marrow aspirate concentrate change the mineralization pattern of the anterior maxilla treated with xenografts? A preliminary study. *Contemp Clin Dent*. 2016;7(1):21-26. doi:10.4103/0976-237X.177112
 37. Pagliani L, Andersson P, Lanza M, et al. A collagenated porcine bone substitute for augmentation at Neoss implant sites: a prospective 1-year multicenter case series study with histology. *Clin Implant Dent Relat Res*. 2012;14(5):746-758. doi:10.1111/j.1708-8208.2010.00314.x
 38. Steigmann M. Pericardium membrane and xenograft particulate grafting materials for horizontal alveolar ridge defects. *Implant Dent*. 2006;15(2):186-191. doi:10.1097/01.id.0000202481.96644.f4
 39. Deeb JG, Reichert A, Carrico CK, Laskin DM, Deeb GR. Effect of biologic materials on the outcomes of horizontal alveolar ridge augmentation: A retrospective study. *Clin Exp Dent Res*. 2021;7(2):147-155. doi:10.1002/cre2.343
 40. Milinkovic I, Cordaro L. Are there specific indications for the different alveolar bone augmentation procedures for implant placement? A systematic review. *Int J Oral Maxillofac Surg*. 2014;43(5):606-625. doi:10.1016/j.ijom.2013.12.004
 41. Chappuis V, Cavusoglu Y, Buser D, von Arx T. Lateral Ridge Augmentation Using Autogenous Block Grafts and Guided Bone Regeneration: A 10-Year Prospective Case Series Study. *Clin Implant Dent Relat Res*. 2017;19(1):85-96. doi:10.1111/cid.12438
 42. Naenni N, Lim HC, Papageorgiou SN, Hämmerle CHF. Efficacy of lateral bone augmentation prior to implant placement: A systematic review and meta-analysis. *J Clin*

- Periodontol.* 2019;46 Suppl 21:287-306. doi:10.1111/jcpe.13052
43. de Azambuja Carvalho PH, Dos Santos Trento G, Moura LB, Cunha G, Gabrielli MAC, Pereira-Filho VA. Horizontal ridge augmentation using xenogenous bone graft-systematic review. *Oral Maxillofac Surg.* 2019;23(3):271-279. doi:10.1007/s10006-019-00777-y
 44. Urban I. *Vertical and Horizontal Ridge Augmentation New perspectives.* Quintessence Publishing; 2017.
 45. Urban IA, Monje A, Lozada J, Wang HL. Principles for Vertical Ridge Augmentation in the Atrophic Posterior Mandible: A Technical Review. *Int J Periodontics Restorative Dent.* 2017;37(5):639-645. doi:10.11607/prd.3200
 46. Urban I, Traxler H, Romero-Bustillos M, et al. Effectiveness of Two Different Lingual Flap Advancing Techniques for Vertical Bone Augmentation in the Posterior Mandible: A Comparative, Split-Mouth Cadaver Study. *Int J Periodontics Restorative Dent.* 2018;38(1):35-40. doi:10.11607/prd.3227
 47. Gultekin BA, Bedeloglu E, Kose TE, Mijiritsky E. Comparison of Bone Resorption Rates after Intraoral Block Bone and Guided Bone Regeneration Augmentation for the Reconstruction of Horizontally Deficient Maxillary Alveolar Ridges. *Biomed Res Int.* 2016;2016:4987437. doi:10.1155/2016/4987437
 48. Meloni SM, Jovanovic SA, Urban I, Canullo L, Pisano M, Tallarico M. Horizontal Ridge Augmentation using GBR with a Native Collagen Membrane and 1:1 Ratio of Particulated Xenograft and Autologous Bone: A 1-Year Prospective Clinical Study. *Clin Implant Dent Relat Res.* 2017;19(1):38-45. doi:10.1111/cid.12429
 49. Meloni SM, Jovanovic SA, Urban I, Baldoni E, Pisano M, Tallarico M. Horizontal ridge augmentation using GBR with a native collagen membrane and 1:1 ratio of particulate xenograft and autologous bone: A 3-year after final loading prospective clinical study. *Clin Implant Dent Relat Res.* 2019;21(4):669-677. doi:10.1111/cid.12808
 50. Pieri F, Corinaldesi G, Fini M, Aldini NN, Giardino R, Marchetti C. Alveolar ridge augmentation with titanium mesh and a combination of autogenous bone and anorganic bovine bone: a 2-year prospective study. *J Periodontol.* 2008;79(11):2093-2103. doi:10.1902/jop.2008.080061
 51. César Neto JB, Cavalcanti MC, Sapata VM, et al. The positive effect of tenting screws for primary horizontal guided bone regeneration: A retrospective study based on cone-beam computed tomography data. *Clin Oral Implants Res.* 2020;31(9):846-855. doi:10.1111/clr.13630
 52. Amaral Valladão CA, Freitas Monteiro M, Joly JC. Guided bone regeneration in staged vertical and horizontal bone augmentation using platelet-rich fibrin associated with bone grafts: a retrospective clinical study. *Int J Implant Dent.* 2020;6(1):72. doi:10.1186/s40729-020-00266-y
 53. Shalash MA, Rahman HA, Azim AA, Neemat AH, Hawary HE, Nasry SA. Evaluation of horizontal ridge augmentation using beta tricalcium phosphate and demineralized bone matrix: A comparative study. *J Clin Exp Dent.* 2013;5(5):e253-259. doi:10.4317/jced.51244
 54. Amorfini L, Migliorati M, Signori A, Silvestrini-Biavati A, Benedicenti S. Block allograft technique versus standard guided bone regeneration: a randomized clinical trial. *Clin Implant Dent Relat Res.* 2014;16(5):655-667. doi:10.1111/cid.12040
 55. Lim HC, Jung UW, You H, Lee JS. Randomized clinical trial of ridge preservation using porcine bone/cross-linked collagen vs. bovine bone/non-cross-linked collagen: cone beam computed tomographic analysis. *Clin Oral Implants Res.* 2017;28(12):1492-1500. doi:10.1111/clr.13017
 56. von Elm E, Altman DG, Egger M, et al. The Strengthening the Reporting of Observational Studies in Epidemiology (STROBE) statement: guidelines for reporting observational

- studies. *Ann Intern Med.* 2007;147(8):573-577. doi:10.7326/0003-4819-147-8-200710160-00010
57. Amoian B, Moudi E, Majidi MS, Ali Tabatabaei SM. A histologic, histomorphometric, and radiographic comparison between two complexes of CenoBoen/CenoMembrane and Bio-Oss/Bio-Gide in lateral ridge augmentation: A clinical trial. *Dent Res J (Isfahan)*. 2016;13(5):446-453. doi:10.4103/1735-3327.192304
58. Schneider D, Weber FE, Grunder U, Andreoni C, Burkhardt R, Jung RE. A randomized controlled clinical multicenter trial comparing the clinical and histological performance of a new, modified polylactide-co-glycolide acid membrane to an expanded polytetrafluorethylene membrane in guided bone regeneration procedures. *Clin Oral Implants Res.* 2014;25(2):150-158. doi:10.1111/clr.12132
59. Garaicoa C, Suarez F, Fu JH, et al. Using Cone Beam Computed Tomography Angle for Predicting the Outcome of Horizontal Bone Augmentation. *Clin Implant Dent Relat Res.* 2015;17(4):717-723. doi:10.1111/cid.12174
60. Park SH, Lee K won, Oh TJ, Misch CE, Shotwell J, Wang HL. Effect of absorbable membranes on sandwich bone augmentation. *Clin Oral Implants Res.* 2008;19(1):32-41. doi:10.1111/j.1600-0501.2007.01408.x
61. Romanos GE, Delgado-Ruiz RA, Gómez-Moreno G, López-López PJ, Mate Sanchez de Val JE, Calvo-Guirado JL. Role of mechanical compression on bone regeneration around a particulate bone graft material: an experimental study in rabbit calvaria. *Clin Oral Implants Res.* 2018;29(6):612-619. doi:10.1111/clr.12592
62. Delgado-Ruiz R, Romanos GE, Alexandre Gerhke S, Gomez-Moreno G, Maté-Sánchez de Val JE, Calvo-Guirado JL. Biological effects of compressive forces exerted on particulate bone grafts during socket preservation: animal study. *Clin Oral Implants Res.* 2018;29(7):792-801. doi:10.1111/clr.12942
63. Cho IW, Park JC, Shin HS. A comparison of different compressive forces on graft materials during alveolar ridge preservation. *J Periodontal Implant Sci.* 2017;47(1):51-63. doi:10.5051/jpis.2017.47.1.51
64. Lee SJ, Kang DY, Cho IW, et al. Histological comparison of different compressive forces on particulate grafts during alveolar ridge preservation: a prospective proof-of-concept study. *J Periodontal Implant Sci.* 2020;50(3):197-206. doi:10.5051/jpis.2020.50.3.197
65. Gerhardt DMJM, De Visser E, Hendrickx BW, Schreurs BW, Van Susante JLC. Bone mineral density changes in the graft after acetabular impaction bone grafting in primary and revision hip surgery. *Acta Orthop.* 2018;89(3):302-307. doi:10.1080/17453674.2018.1460776

TABLES

Table 1. Patient demographics

| | control group n=15 | test group n=16 |
|-------------|------------------------|------------------------|
| Age (years) | 57.6 (13.8), 27.0-73.0 | 56.2 (14.4), 20.0-70.0 |
| Female | 7 (43.8%) | 10 (62.5%) |

Data are shown as mean (standard deviation), minimum-maximum or number and percentage.
Abbreviation: GBR- guided bone regeneration

Table 2. Implant sites

| Implant site | control group n=16 | test group n=16 |
|--------------|-----------------------|--------------------|
| Incisors | 3 (18.75%) | 5 (31.25%) |
| Canines | 3 (18.75%) | 1 (6.25%) |
| Premolars | 8 (50.0%) | 3 (18.75%) |
| Molars | 2 (12.5%) | 7 (43.75%) |
| Lower jaw | 2 (12.5%) | 4 (25.0%) |
| Upper jaw | 14 (87.5%) | 12 (75.0%) |

Data are presented as number (percentage).

Abbreviations: GBR- guided bone regeneration

Table 3. Ridge width

| | control group | | test group | | p value |
|---------------|---------------|--------------------------|------------|---------------------------|---------|
| | N | Ridge width (mm) | N | Ridge width (mm) | |
| Preoperative | 16 | 4.5 (1.8), 1.9 - 7.6 | 16 | 3.1 (1.3), 1.4 - 5.7 | 0.017 |
| Postoperative | 12 | 8.1 (2.0), 4.3 - 12.7 | 15 | 10.5 (1.4), 8.0 - 12.7 | 0.002 |
| Post-healing | 16 | 7.2 (1.9), 4.5 - 11.3 | 16 | 8.4 (2.0), 4.4 - 11.9 | 0,169 |

Ridge width is measured two millimetres apical from the top of the crest on cone beam computed tomography

P values are determined using the Wilcoxon rank-sum test with continuity correction.

Data are shown as mean (standard deviation), minimum-maximum values.

Abbreviations: GBR- guided bone regeneration

Table 4. Bone gain and loss

| | | control group | | test group | | p value |
|--------------------|-----------------------------|---------------|-------------------------------|------------|-------------------------------|---------|
| | | N | Bone change | N | Bone change | |
| Post-healing (mm) | Bone gain | 16 | 2.7 (1.8), -0.3 - 6.0 | 16 | 5.3 (2.3), 0.8 - 9.0 | 0.003 |
| Postoperative (mm) | bone gain | 12 | 3.5 (1.6), 1.3 - 6.4 | 15 | 7.4 (2.0), 4.6 - 10.7 | <0.001 |
| | Post-healing bone loss (mm) | 12 | -0.9 (0.8), -2.8 - -0.2 | 15 | -2.1 (1.6), -4.2 - 1.3 | 0.012 |
| | Post-healing bone loss (%) | 12 | -27.9 (25.8), -99.9 - -5.7 | 15 | -29.4 (26.7), -84.5 - 24.5 | 0.608 |

Bone gain and loss are measured two millimetres apical from the top of the crest on cone beam computed tomography

P values are determined using the Wilcoxon rank-sum test with continuity correction.

Data are shown as mean (standard deviation), minimum-maximum values.

Abbreviations: GBR- guided bone regeneration

Table 5. Post-healing bone loss in anterior and posterior sites

| | Test group anterior sites (n = 5) | Test group posterior sites (n = 10) | p value |
|--------------------------------|--------------------------------------|--|--------------|
| Post healing bone loss (mm) | -2.9 (1.1), -4.2 - -1.7 | -1.7 -4.2 - 1.3 | (1.7), 0.126 |

Bone loss is measured two millimetres apical from the top of the crest on cone beam computed tomography

The p values is determined using the Wilcoxon rank-sum test with continuity correction.

Data are shown as mean (standard deviation), minimum-maximum values.

Author Manuscript

Figure legends

Figure 1 Representative case treated with a conventional GBR technique

Images of a representative case from the control group are shown. C1. Preoperative view. C2. View of the horizontal defect under the sinus access window. C3. Classical guided bone regeneration technique using a reticulated collagen membrane and deproteinized bovine bone mineral combined with autogenous graft at a 1:1 ratio. C4. View of the ridge after six months of healing. C5. Implant placement. C6. Intraoral radiograph of prosthetic rehabilitation. C7. Superimposition of cone beam computed tomography (CBCT) images obtained pre- and postoperatively. C8. Superimposition of the CBCT images obtained preoperatively and post-healing.


Figure 2 Representative case treated with the Sausage Technique™

Images of a representative case from the test group are shown. T1. Clinical view of the horizontal defect. T2. Placement of the particulate graft containing deproteinized bovine bone mineral combined with autogenous graft at a 1:1 ratio. T3. Collagen membrane fixation. T4. View of the ridge after six months of healing. T5. Implant placement. T6. Intraoral radiograph of prosthetic rehabilitation. T7. Superimposition of cone beam computed tomography (CBCT) images obtained pre- and postoperatively. T8. Superimposition of CBCT images obtained preoperatively and post-healing.

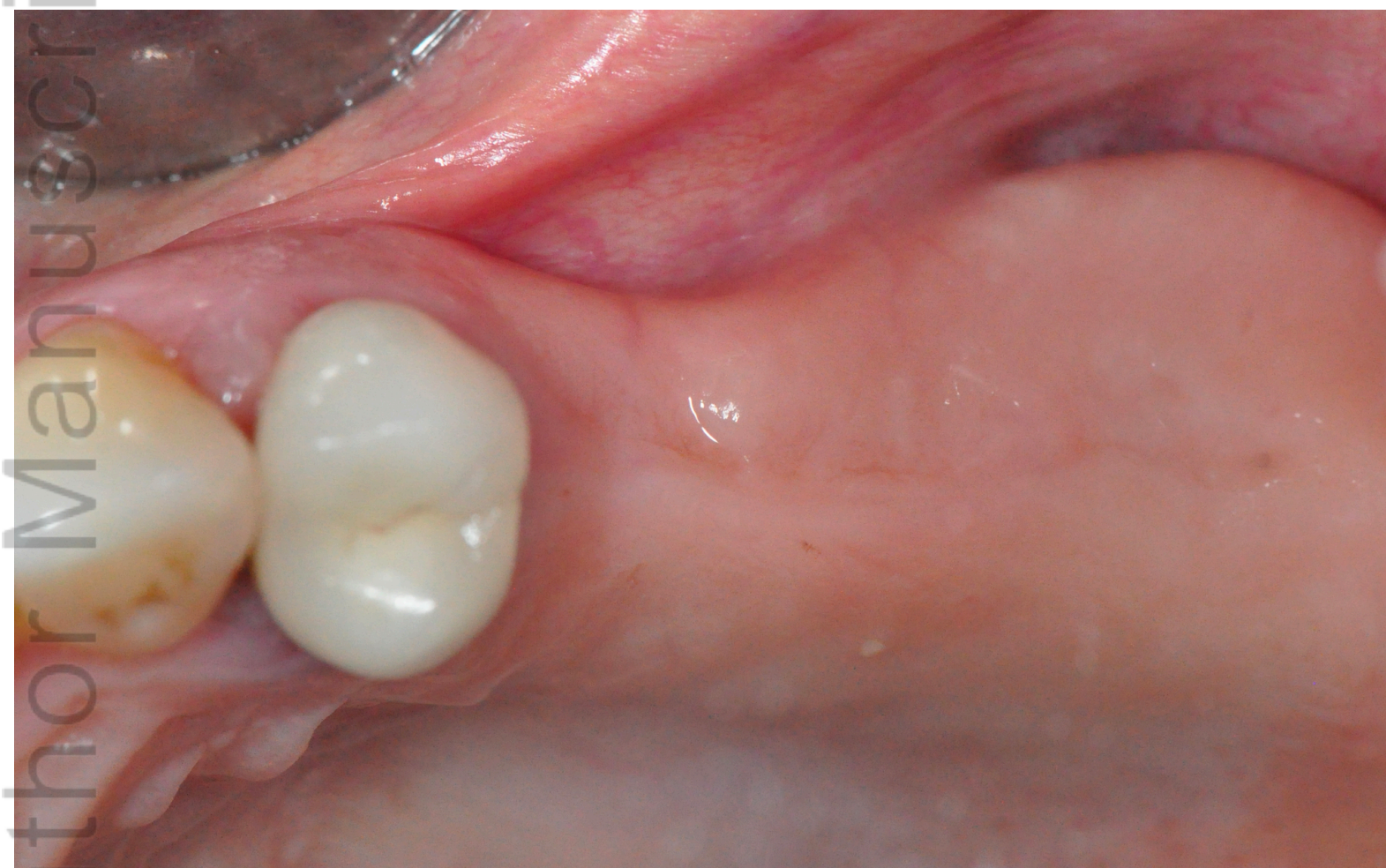Figure 3 Schematic drawing of a posterior mandibular GBR showing bone graft fixation using pins

C0: Control group

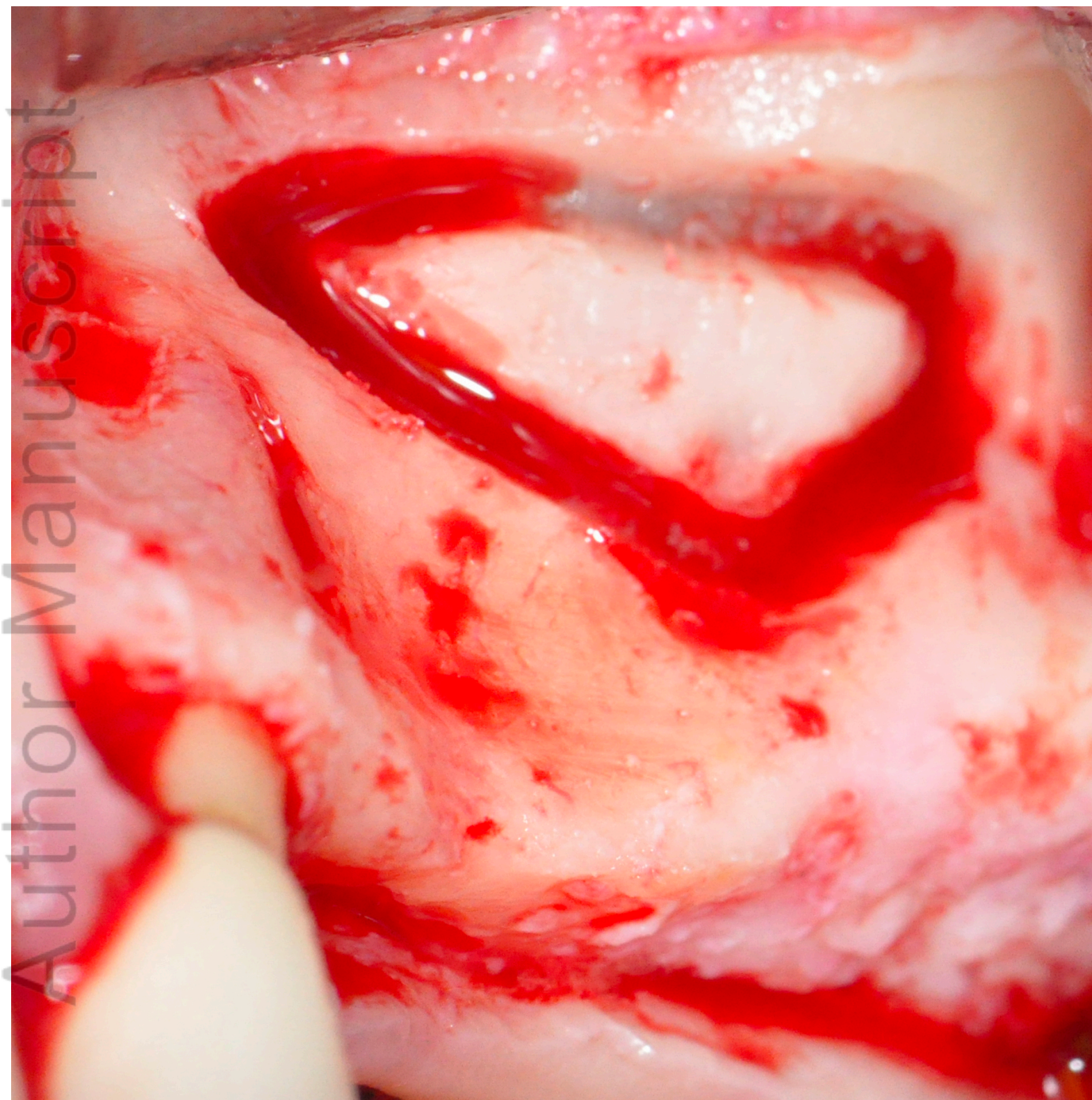
T0: Test group



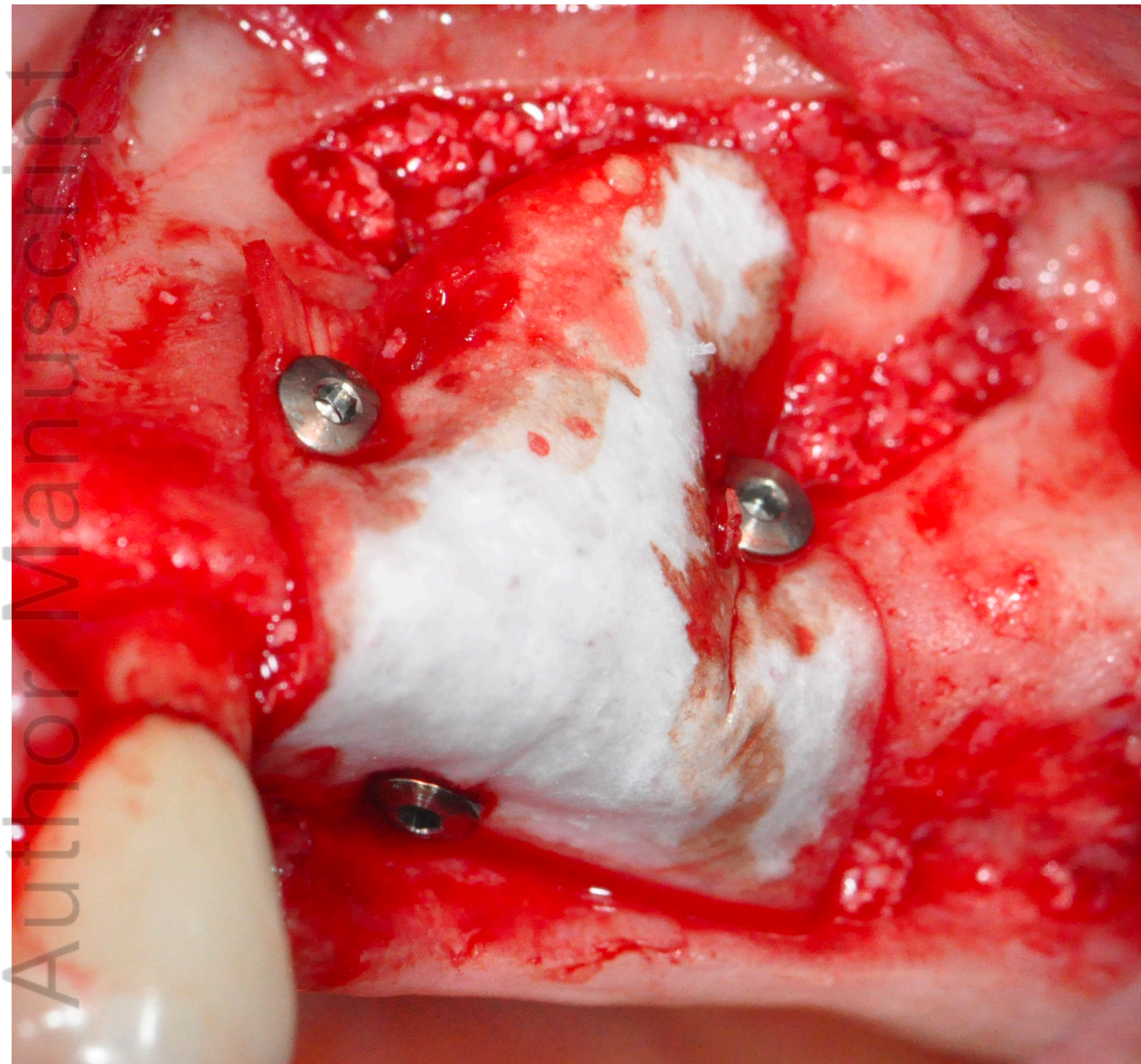
CID_13073_C0_.png



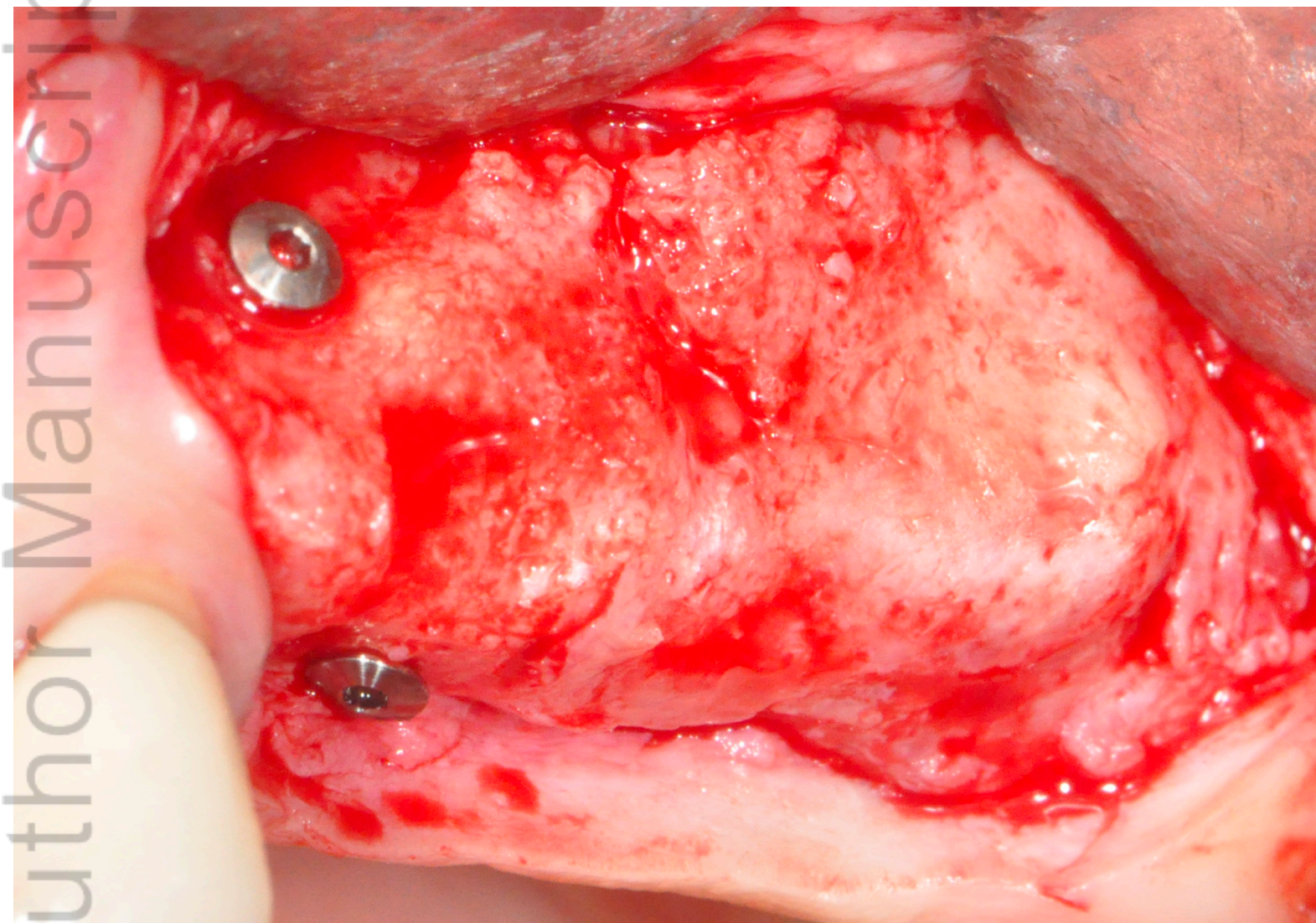
CID_13073_C1.png



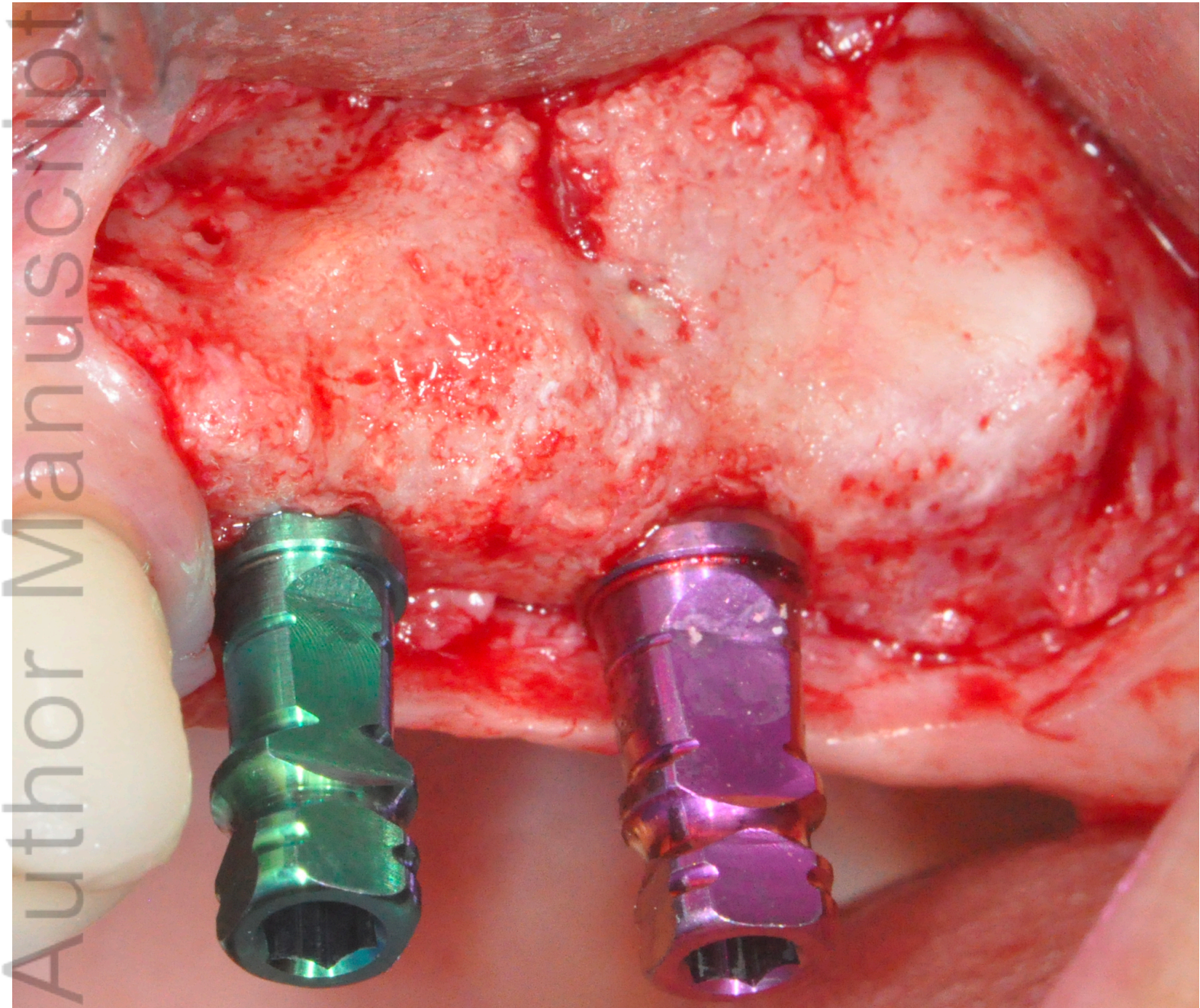
CID_13073_C2.png



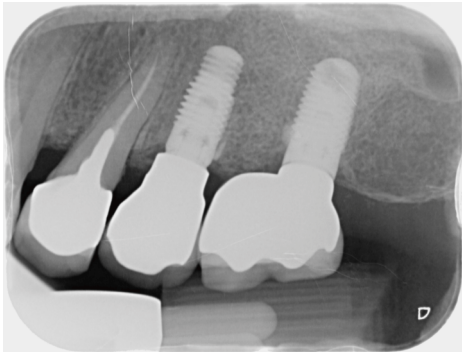
CID_13073_C3.png



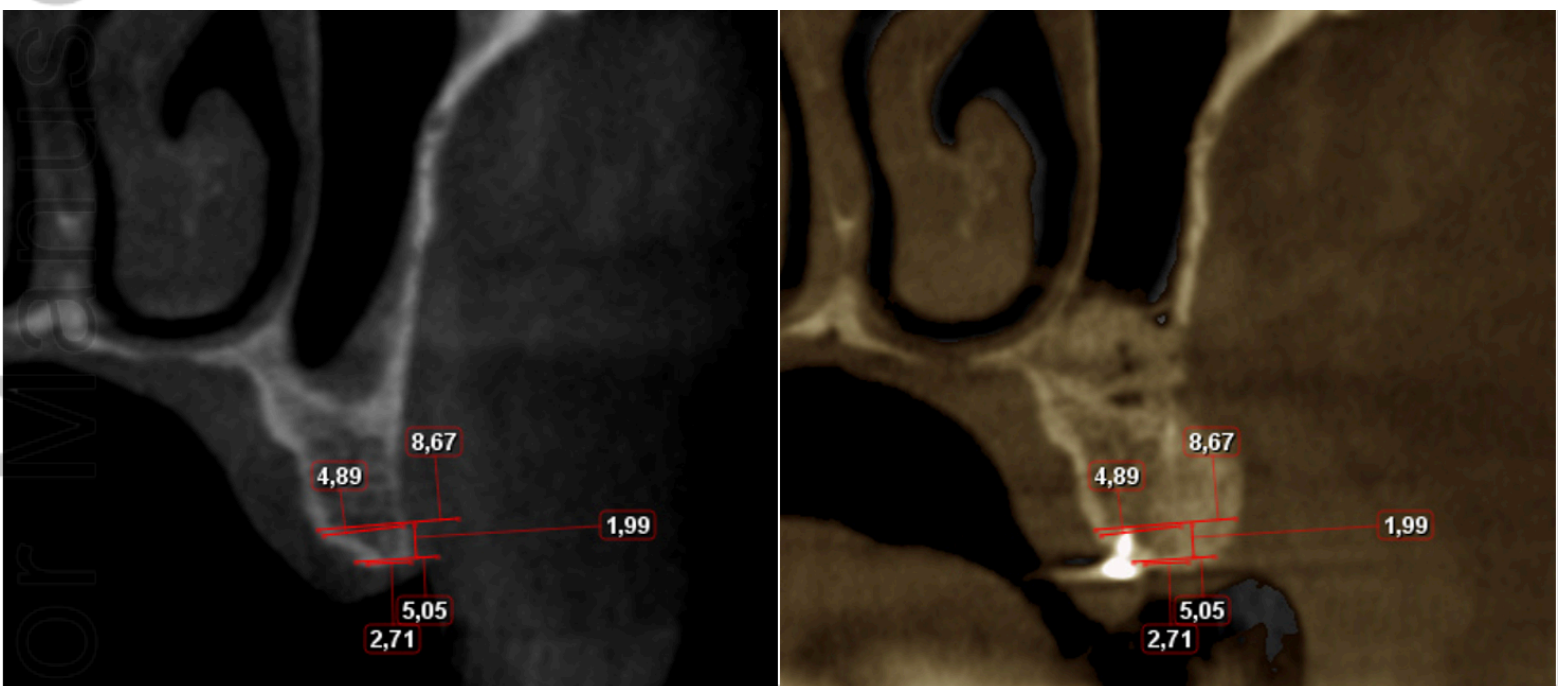
CID_13073_C4.png



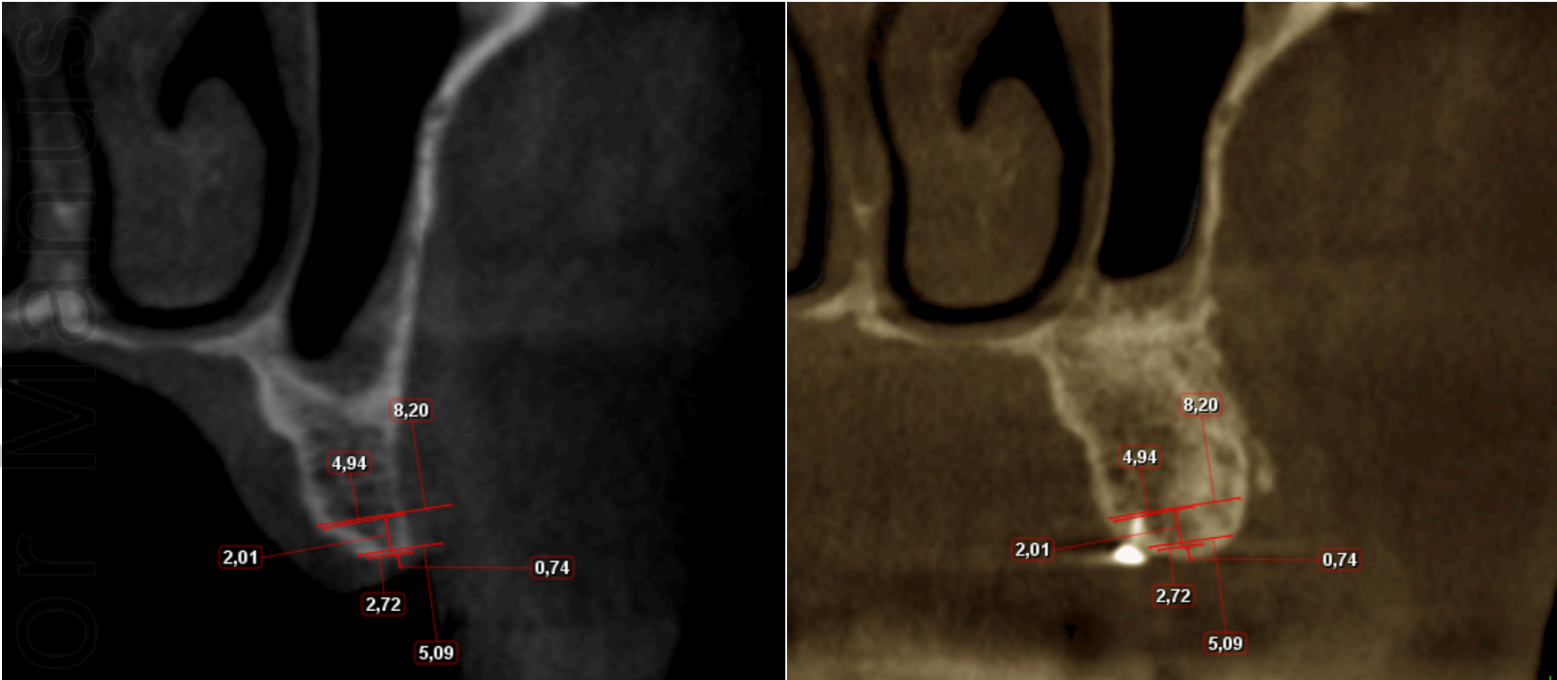
CID_13073_C5.png



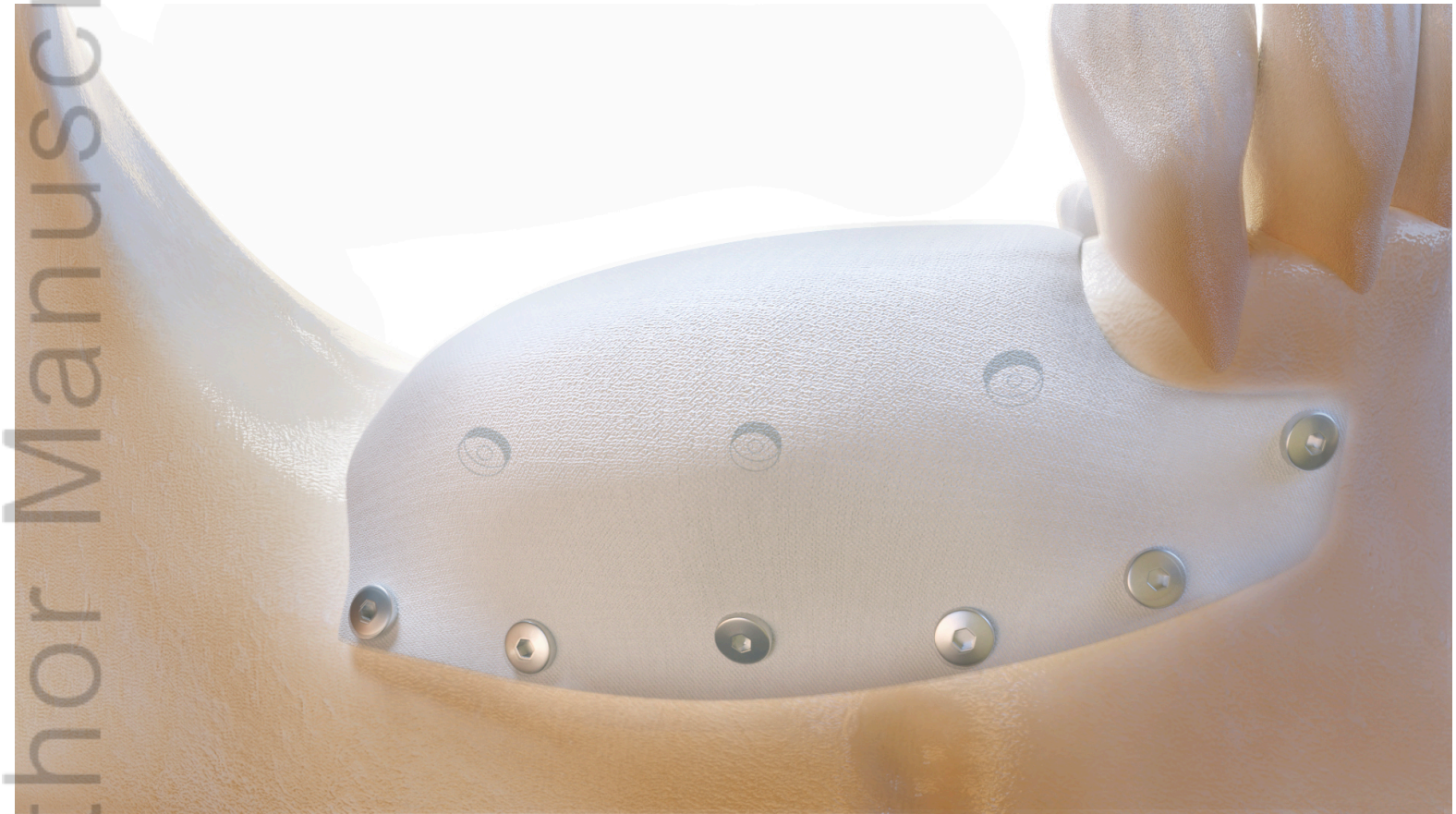
CID_13073_C6.png



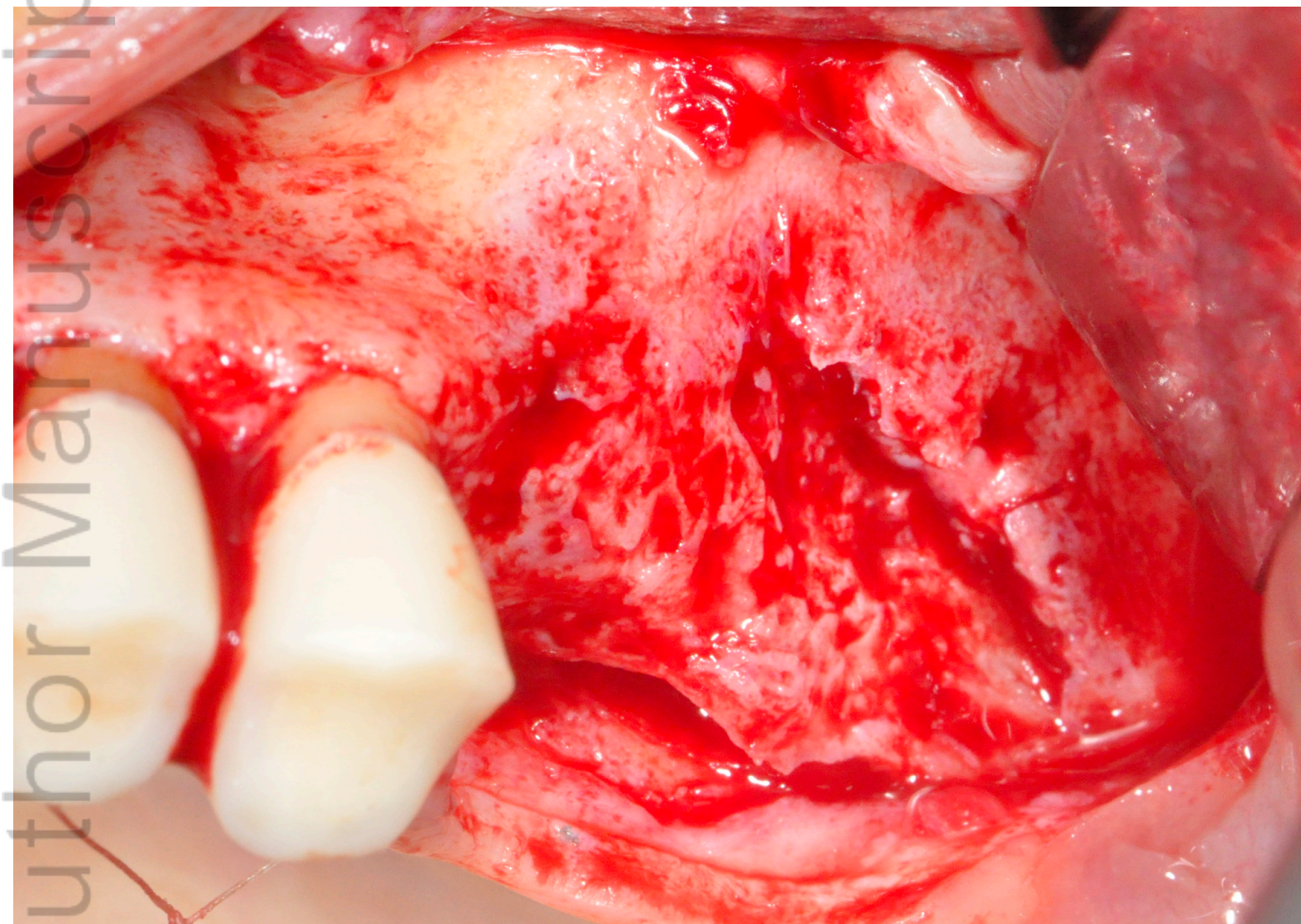
CID_13073_C7.png



CID_13073_C8.png

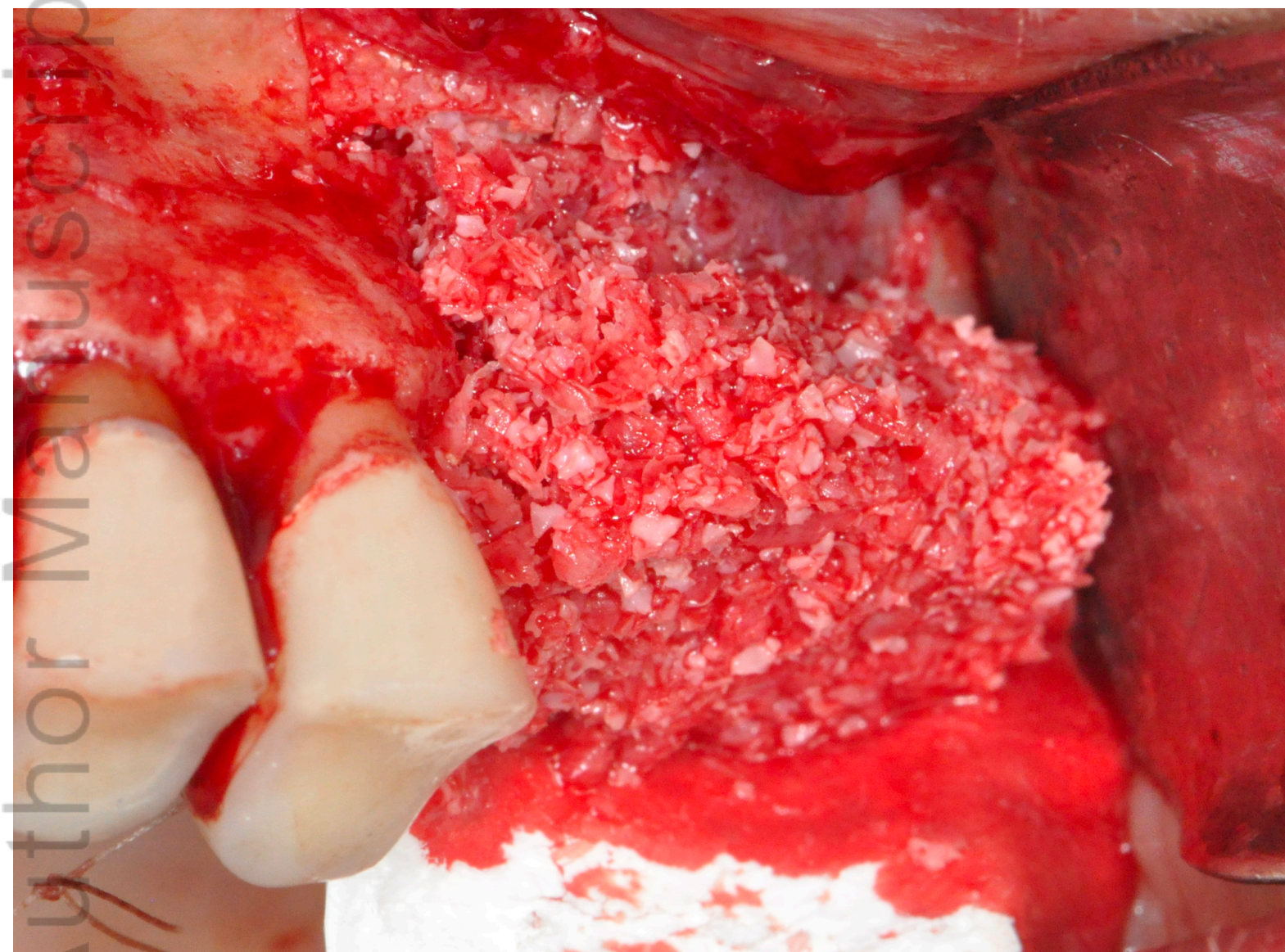


CID_13073_T0_.png

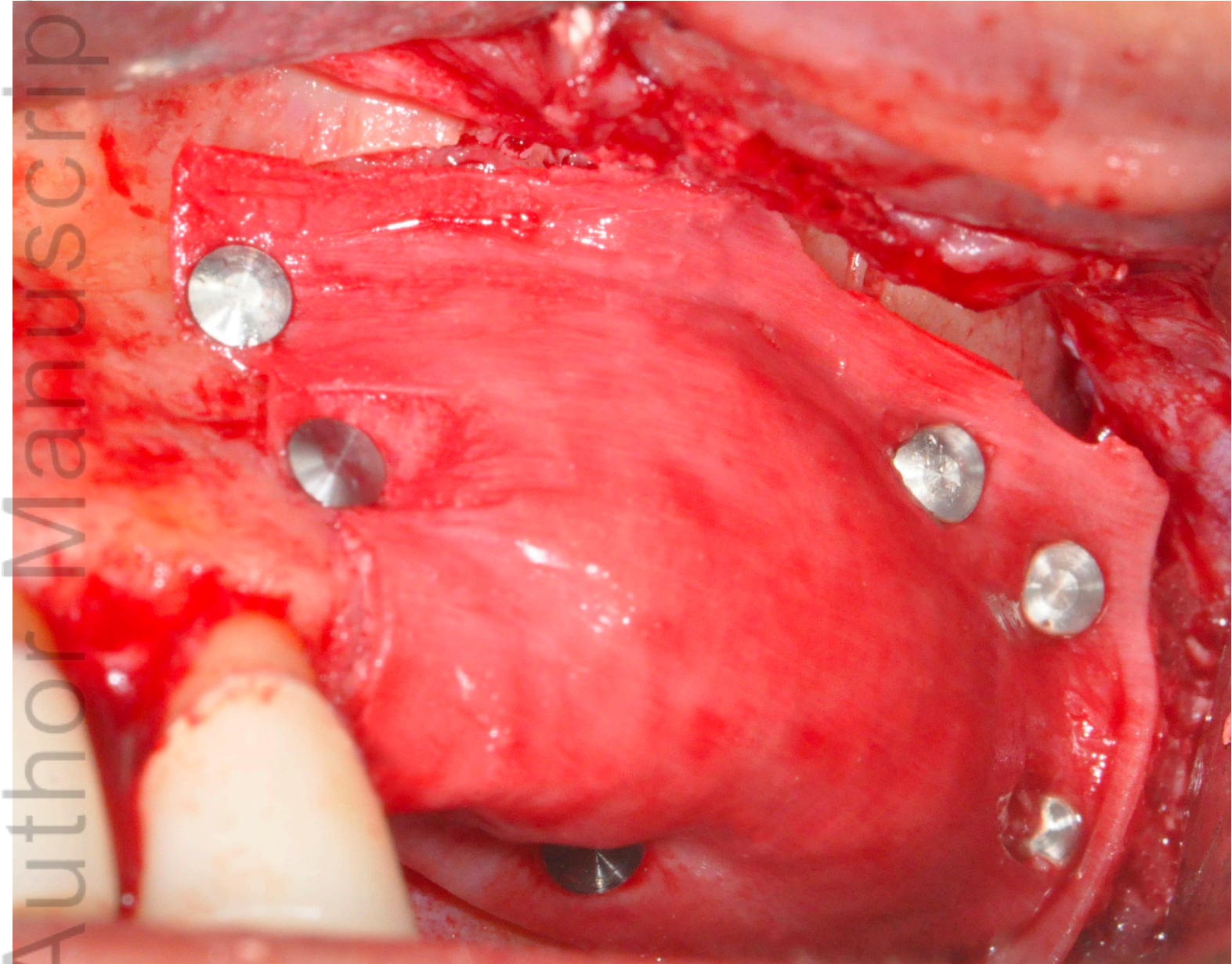


CID_13073_T1.png

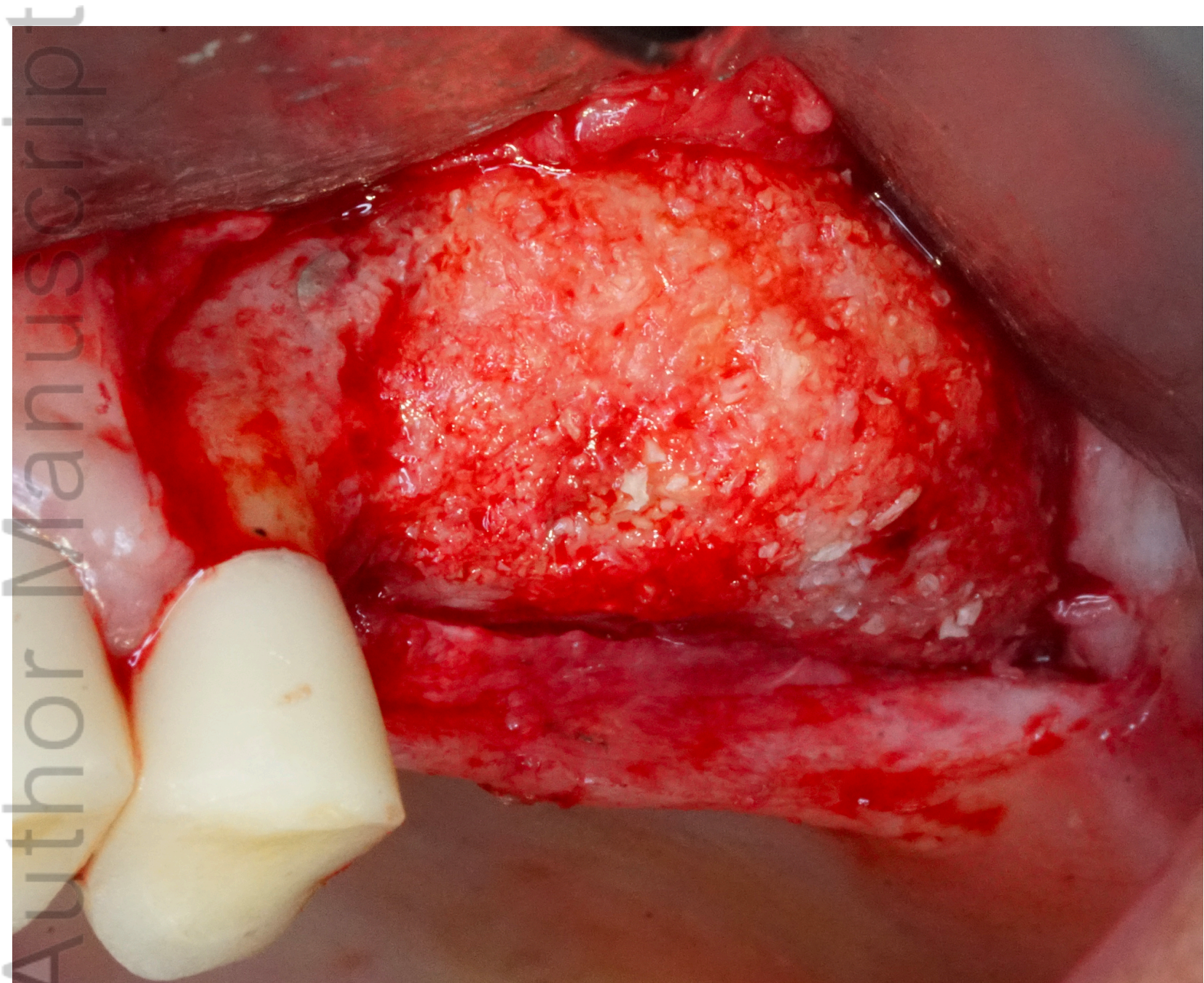Author Manuscript



CID_13073_T2.png

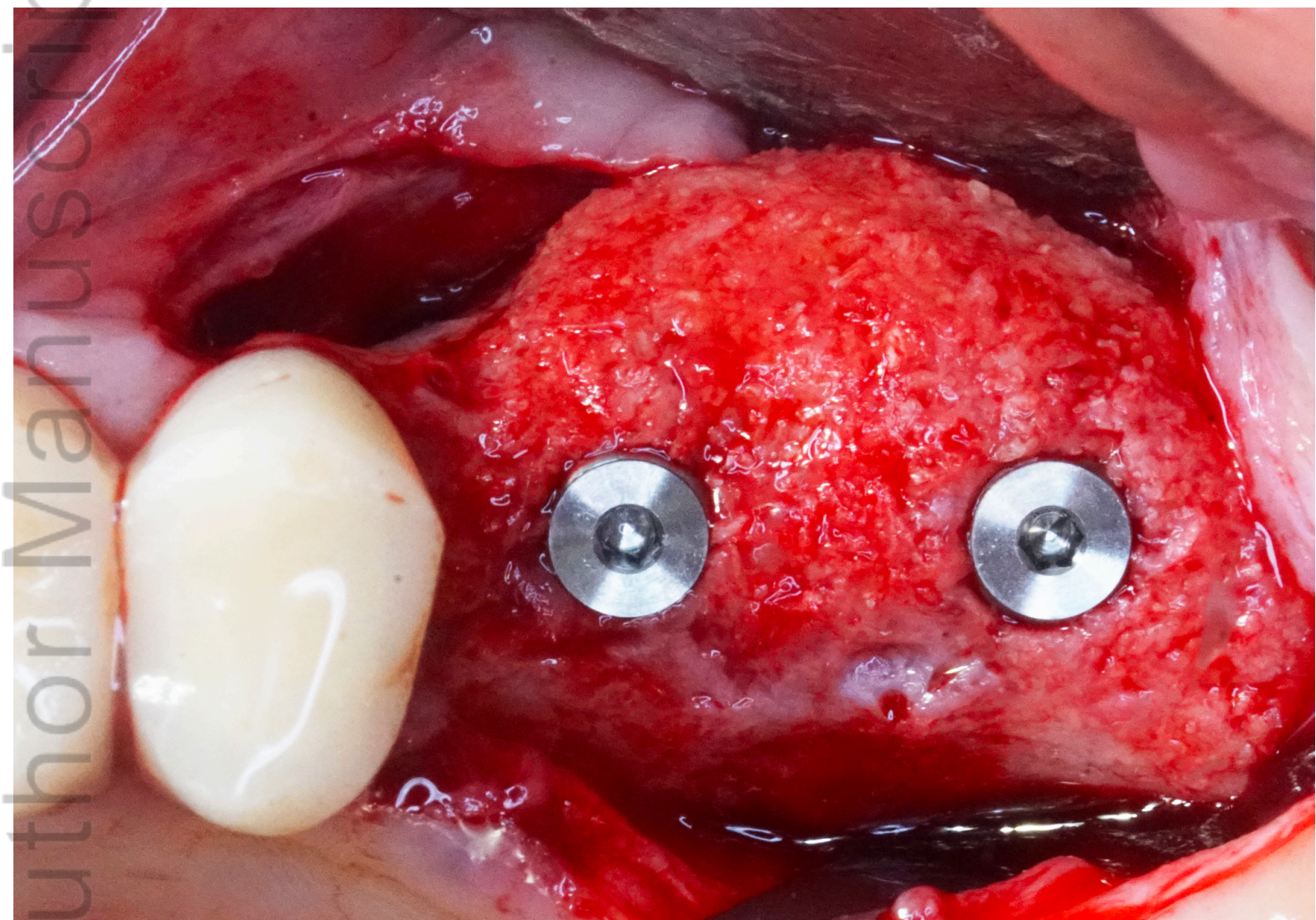


CID_13073_T3.png

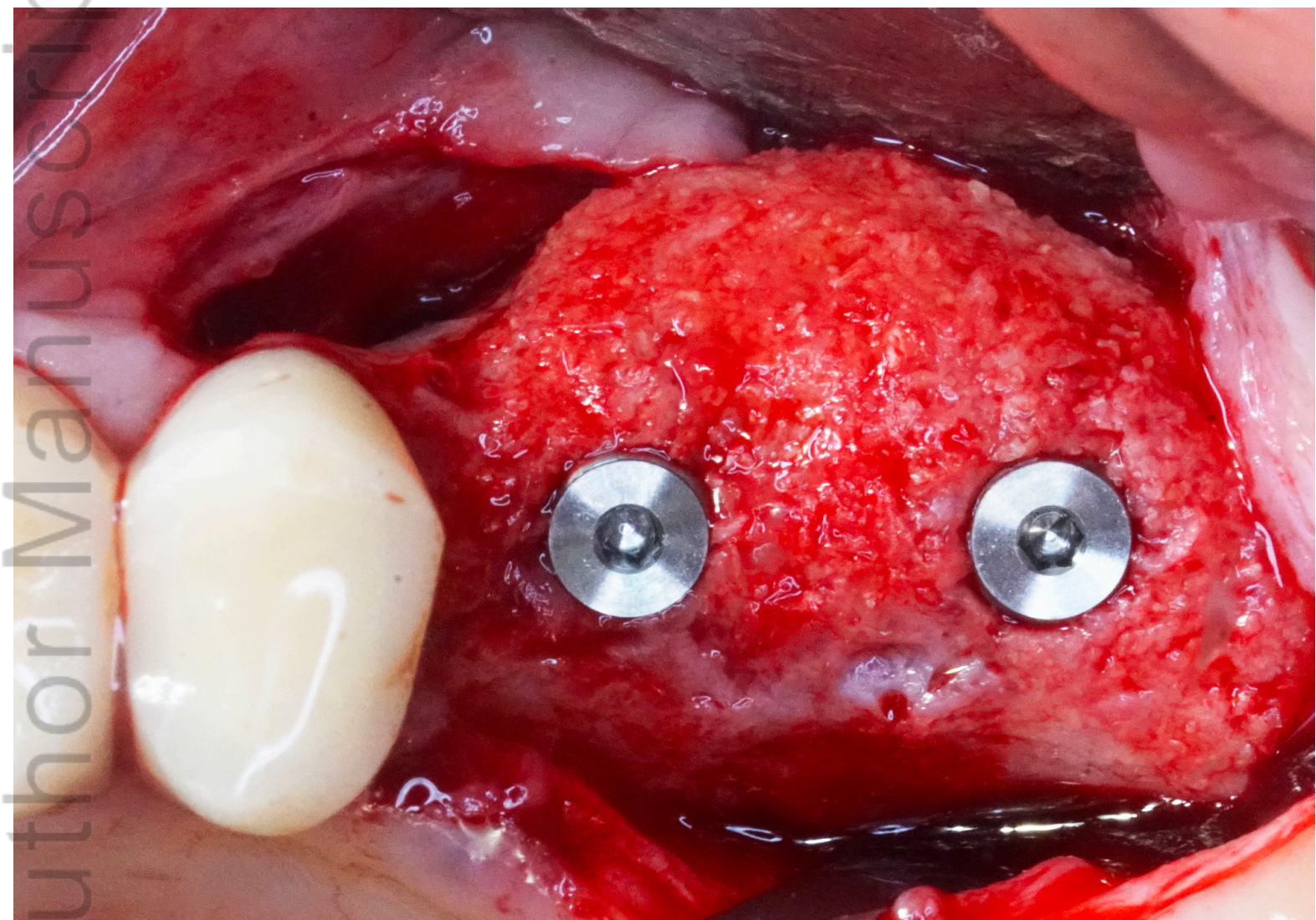


CID_13073_T4.png

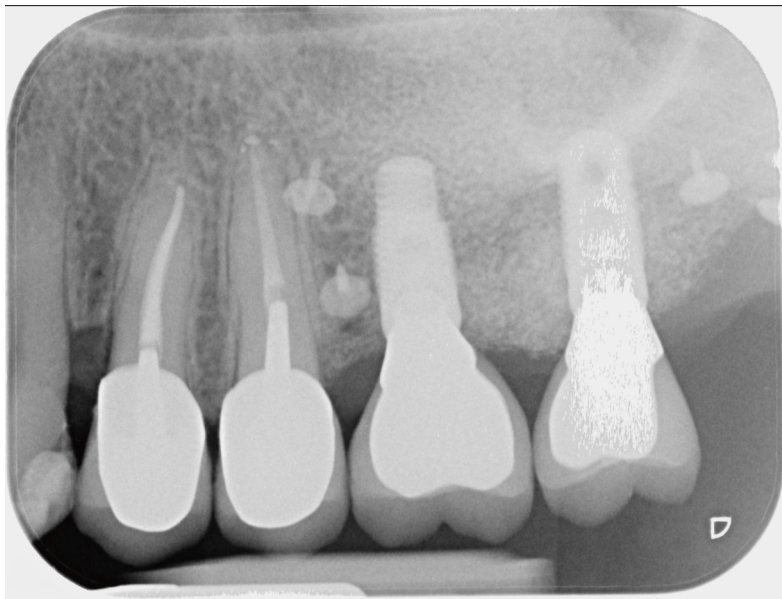
Author Manuscript



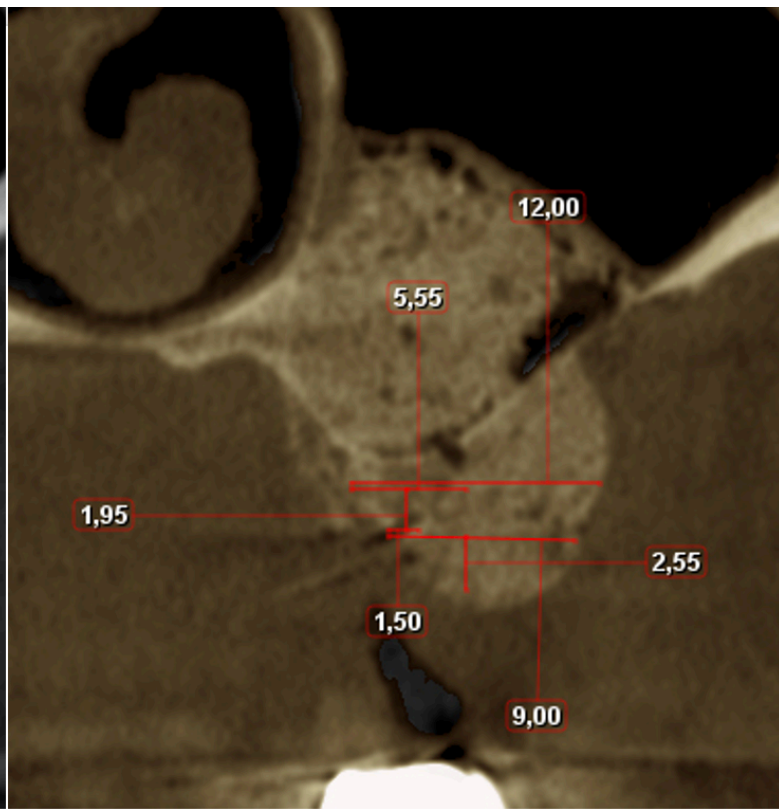
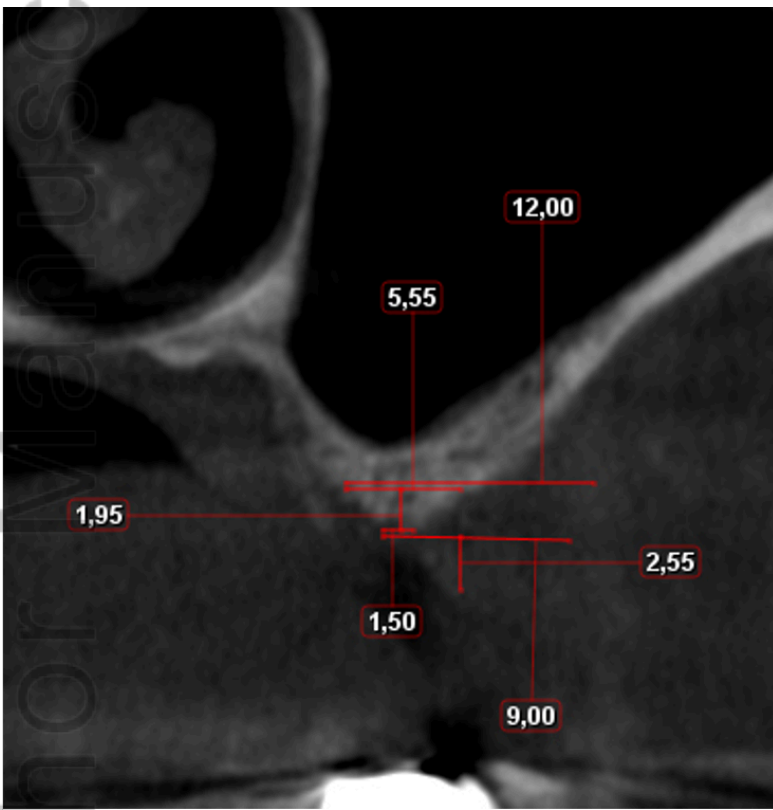CID_13073_T5_1.png



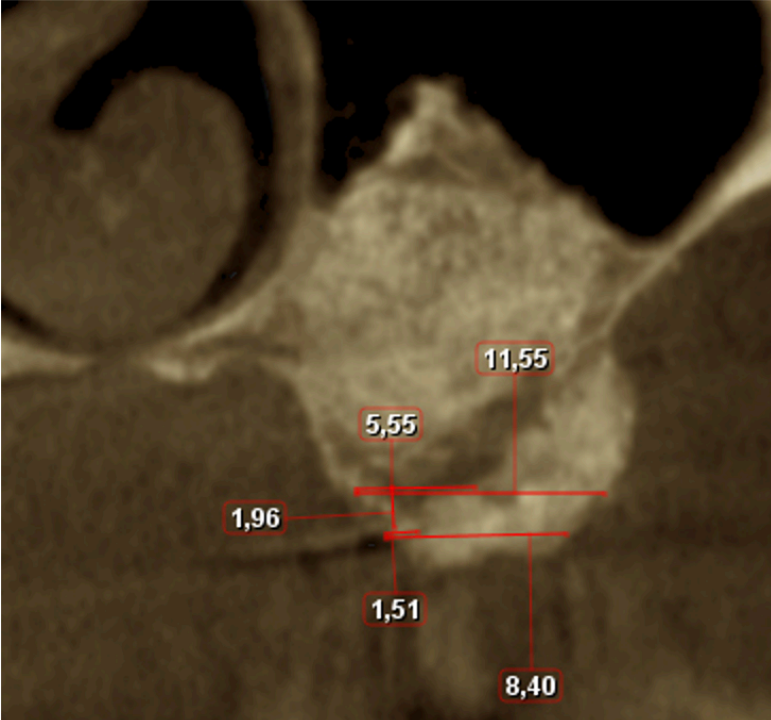
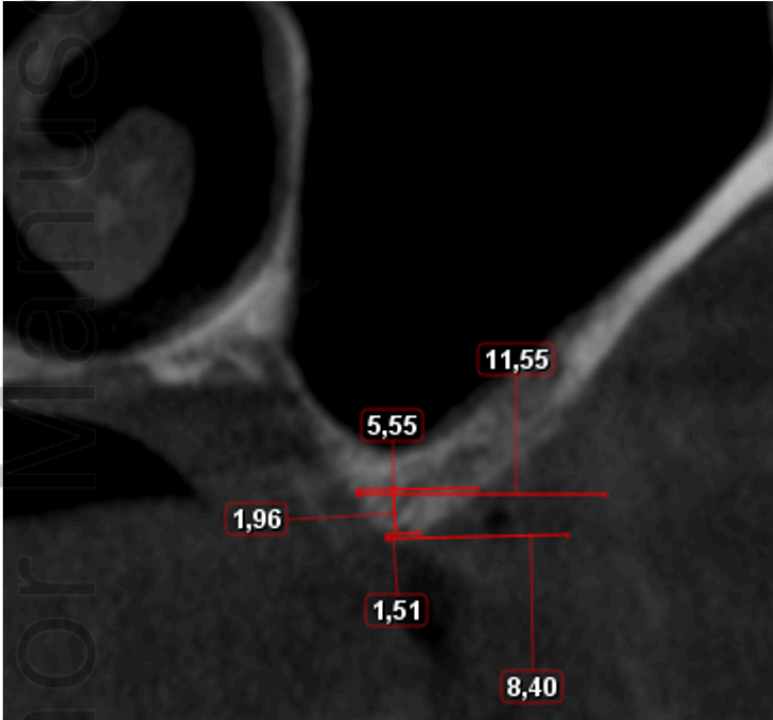
CID_13073_T5_2.png



CID_13073_T6.png



CID_13073_T7.png



CID_13073_T8.png