


## CASE REPORT

# Aspiration of an exfoliated primary molar in a child with cerebral palsy: A case report

Homa Amini<sup>1</sup>  | James R. Boynton<sup>2</sup>

<sup>1</sup> Division of Pediatric Dentistry, Ohio State University College of Dentistry, Columbus, Ohio, USA

<sup>2</sup> Department of Orthodontics and Pediatric Dentistry, University of Michigan School of Dentistry, Ann Arbor, Michigan, USA

## Correspondence

James R. Boynton, Department of Orthodontics and Pediatric Dentistry, University of Michigan School of Dentistry, Ann Arbor, MI 48109-1078, USA.  
Email: [jboynton@umich.edu](mailto:jboynton@umich.edu)

[Correction added on 24 December 2021, after first online publication: The first author's name has been corrected in the How to Cite section].

## Abstract

Foreign body aspiration is a concern in children which may occur with anything introduced to the oral cavity and can result in significant morbidity and mortality. Food and foreign objects are the most commonly aspirated objects in young children. Aspiration of a normally exfoliated primary tooth is thought to be extremely rare, if not unheard-of. The purpose of this case report is to describe the events occurring to a 10-year-old child with a cerebral palsy presenting with signs and symptoms of respiratory distress due to aspiration of a naturally exfoliated primary molar. Recommendations are provided for delivery of appropriate anticipatory guidance, management of exfoliating primary teeth, and safe clinical practice.

## KEYWORDS

cerebral palsy, primary tooth, respiratory aspiration

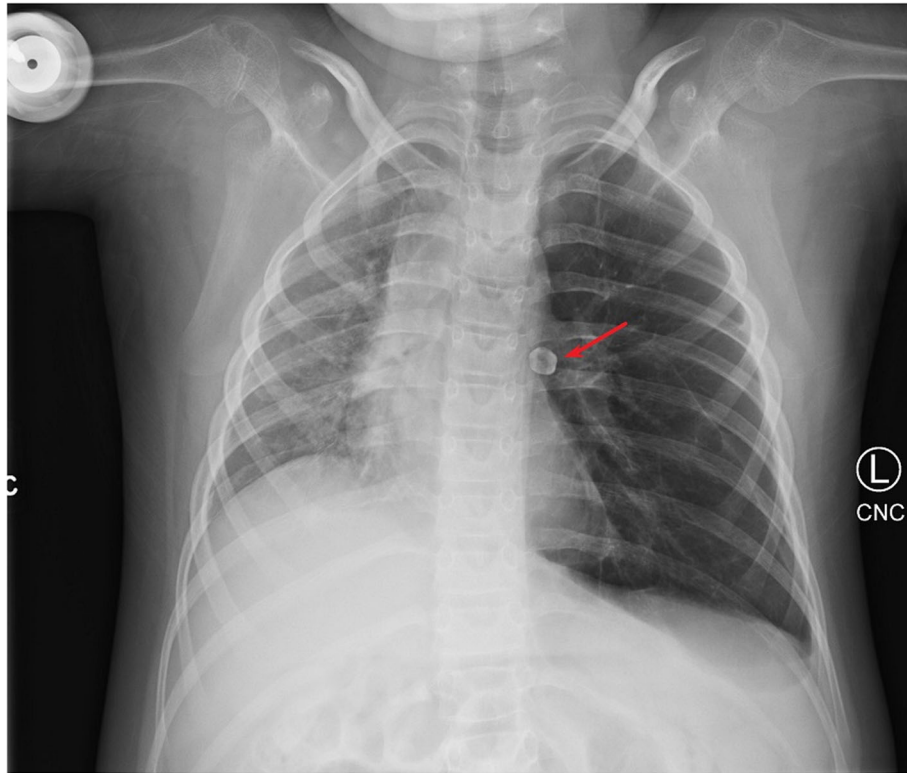
## 1 | INTRODUCTION

Aspiration of a foreign body is a critical health event in which a foreign object is passed through the vocal cords and lodged within the respiratory tree. Consequences of foreign body aspiration include acute respiratory compromise, pneumonia, and can lead to death.<sup>1</sup> Aspiration is a particular concern in children; a review of 722 pediatric foreign body aspiration events found that small food items were most commonly aspirated, and marbles, buttons, paper, pebbles, pins/screws/needles, and plastic were among the objects more frequently aspirated.<sup>2</sup> Teeth, when lost from periodontal support, have the potential to be aspirated. Most aspirated teeth are lost due to trauma.<sup>3,4</sup> Exfoliating primary teeth have the potential to be aspirated, especially in at-risk children with dysfunctional airway protective reflexes. The risk of aspiration of an exfoliated tooth is thought to be extremely low and many dentists are unaware of a case where a normally exfoliated

primary tooth is aspirated. The purpose of this case report is to describe the events occurring to a child with cerebral palsy who aspirated a naturally exfoliated primary molar and present recommendations to the dental team to support children with special healthcare needs at risk of aspiration.

## 2 | DESCRIPTION OF CASE

A 10-year-old boy with a complex past medical history including prematurity, spastic quadriplegic cerebral palsy, neuromuscular respiratory weakness, global developmental disability, and gastrostomy tube dependence was evaluated by his physician via telemedicine due to history of cough and wheezing for 3 days. Mother had administered albuterol at home without change in symptoms. Mother also reported that positioning child upright did not improve the congestion and there was significant drainage



**FIGURE 1** Chest x-ray revealing aspirated tooth within the left lung hilum

and mucous in the back of patient's throat, leading to vomiting once daily. A chest x-ray was ordered.

The x-ray was taken the next day which revealed hyperinflated left lung, decreased right lung volume with diffuse opacity, streaky right lower lobe opacities, and no pleural effusion or pneumothorax (Figure 1). Heart size was within normal limits, and there was a lobular, 11 mm radiodensity within the left hilum, not seen on prior radiographic examinations. The heart was shifted rightward. The impression was probable obstructing foreign body in the left mainstem bronchus with associated air trapping and hyperinflation of the left lung, and decreased volume with diffuse atelectasis in the right lung. Mother was advised to bring the child to the emergency room immediately.

The patient presented to the emergency department hemodynamically stable and saturating well on room air with intermittent tachypnea. Bilateral wheezing and decreased breath sounds over left lung were noted. He was evaluated by otorhinolaryngology and transported to the operating room for direct laryngoscopy, bronchoscopy, and airway foreign body removal under general anesthesia. An alligator optical forceps was passed through the bronchoscope and used to grasp and remove the object from the left mainstem bronchus. The removed object was identified as the left maxillary first primary molar. The patient was admitted for initiation of antibiotics for post-obstructive purulent bronchitis seen in left bronchus and

overnight observation. A post-op chest x-ray revealed successful removal of foreign body with decompression of left lung (Figure 2). The patient was discharged the next day.

The child presented for a dental examination approximately three months following removal of the tooth. The child was in the late mixed dentition with five primary teeth present—second primary molars and the upper left primary canine. Light plaque with minimal supragingival calculus accumulation was noted. The child had mild gingivitis and no dental restorations, caries or other oral pathology was noted.

### 3 | DISCUSSION

Primary teeth may be aspirated following trauma from accidents,<sup>5</sup> accidental loss during surgery,<sup>6</sup> or after tooth extraction.<sup>7</sup> Aspiration of a normally exfoliated primary tooth is extremely rare with only two suspected cases described in the literature. The first, a case report from 1997, describes a 9-year, 11-month-old boy with a history of cerebral palsy, seizure disorder, asthma, scoliosis, and was status post tracheostomy. The parent reported the child had lost a tooth approximately 1 month prior to symptom development that was never found. The child developed a low-grade fever with increased breathing difficulty not responsive to home chest physiotherapy and nebulized

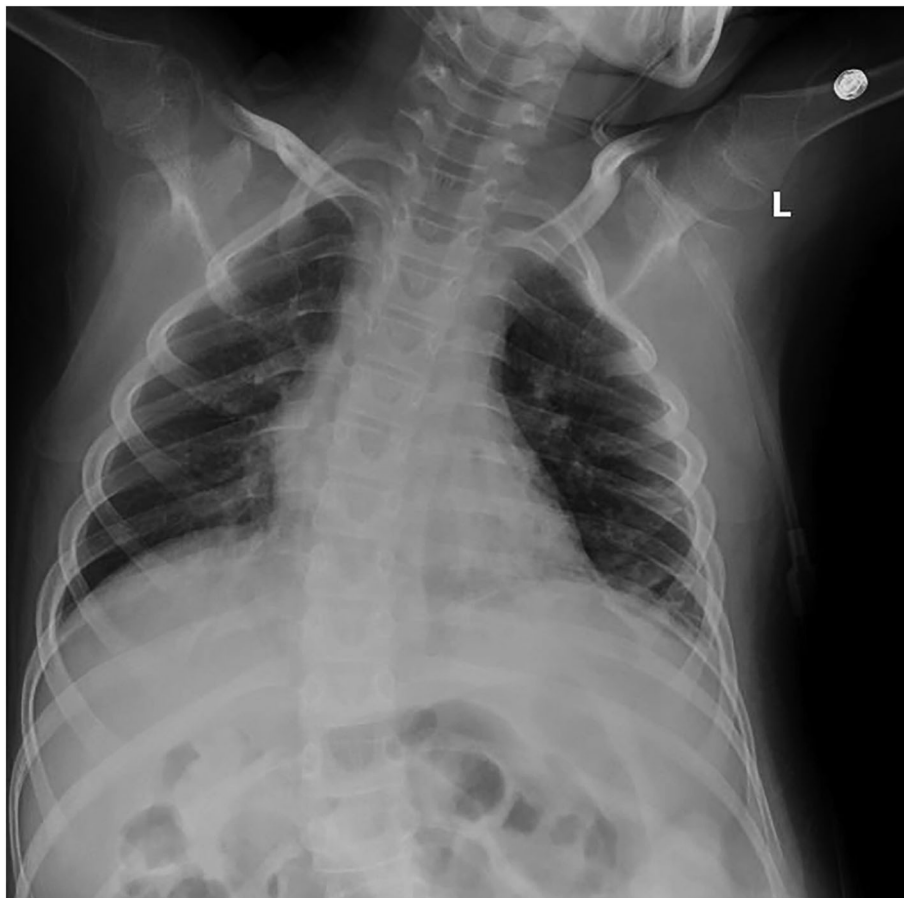


FIGURE 2 Chest x-ray showing no evidence of foreign body

albuterol treatment. The patient underwent bronchoscopy under general anesthesia and an exfoliated upper left primary canine was removed.<sup>8</sup> The second suspected case, reported in 2018, was a 9-year-old girl with a history of Lennox-Gasteau syndrome who was admitted with pneumonia. The cause was found to be from foreign body aspiration of a “tooth-like” material suspected to be from the maxillary left first primary molar.<sup>9</sup> The present case, a 10-year-old child with a history of anoxic encephalopathy, involved aspiration of an upper left primary molar. To our knowledge, these are the only three cases described of aspiration of a normally exfoliating primary tooth. Although aspiration of a foreign body is relatively common in children, responsible for more than 17,000 emergency department visits in the year 2001,<sup>10</sup> aspiration of an exfoliated primary tooth is particularly rare. Similarities in the three cases can describe the child at-risk of aspiration of an exfoliating tooth—a child aged 9 to 10 years with a history of brain injury/disease. Also of note is that all three cases involve exfoliated maxillary primary teeth. The path into the posterior pharynx is more direct from the maxillary arch, compared with mandibular teeth which may be more impeded by the tongue.

Up to 85% of children with cerebral palsy have oropharyngeal dysphagia, which is positively associated with the severity of gross motor impairment.<sup>12</sup> Oropharyngeal dysphagia in those with cerebral palsy is more severe in early childhood.<sup>11</sup> Children with cerebral palsy with severe gross motor dysfunction have reduced lip closure, inadequate bolus formation, delayed trigger of pharyngeal swallow, reduced larynx elevation, delayed pharyngeal time, and more aspiration than children with moderate or mild cerebral palsy.<sup>13</sup> Oral and pharyngeal dysfunction in cerebral palsy increases vulnerability to respiratory morbidity from direct aspiration of secretions and food; gastrostomy with tube feeds decreases this risk.<sup>14</sup> Feeds through the gastrostomy tube will prevent aspiration by bypass of the oral cavity, but would not prevent aspiration of oral secretions or any other free body in the oral cavity. The outcome of the present case report is likely related to these factors in children with cerebral palsy.

Aspiration of a foreign body is a concern during dental care. The most common symptoms of aspiration are coughing, choking, acute dyspnea, and sudden onset of wheezing.<sup>15</sup> Aspiration may also be asymptomatic—a recent literature review of aspirated foreign bodies

in the dental environment found half of the patients who had aspirated a foreign object had no immediate symptoms.<sup>16</sup> Specific to children, cases have been reported involving aspirated endodontic files,<sup>17</sup> stainless steel crowns,<sup>18</sup> gauze pressure-packs following extraction<sup>19</sup> and rubber tubing from a Molt Mouth Prop.<sup>20</sup> Data provided by two insurance companies covering 24,651 general dentists in France revealed 44 items aspirated during dental care over a 10-year period,<sup>21</sup> showing that aspiration is a rare yet severe complication in dental practice.

Developing a culture of safety is critical in dentistry and implementing patient safety measures are important to avoid adverse events. Dentists have an important role to play in the prevention of aspirated primary teeth. Recommendations to providers include the following:

1. Appropriate anticipatory guidance with caregivers: establishment of the dental home is critical for children with special healthcare needs. Caregivers of children at risk of aspiration of exfoliating primary teeth should be informed of the need to periodically monitor the child's dentition. Providers should describe the current state of the dentition and expected exfoliation times. Caregivers should be encouraged to monitor their child's dentition periodically during home oral hygiene and evaluate for lost teeth. In the event a primary tooth exfoliates, the parent should make every effort to locate the primary tooth. If the tooth could not be located and respiratory symptoms develop, the possibility of aspiration should be considered.
2. Primary teeth exhibiting mobility secondary to exfoliation should be left to exfoliate naturally unless extraction presents fewer risks to the child. Situations where extraction of mobile primary teeth near exfoliation may be appropriate are when the airway can be securely protected during extraction. If a provider extracts a mobile primary tooth, the provider should be confident that the risk of aspiration is lower during extraction than it would have been for exfoliation. There are many more reports of aspiration of extracted teeth than those naturally exfoliated; dentists should only extract mobile primary teeth if there is confidence that the airway is protected.
3. Dentists have a responsibility to protect the airway during dental care to prevent aspiration of any foreign body. In the event any item (a tooth or any other dental material) is lost, the first requirement is to ensure the airway is patent and the patient is stable and provide emergency support if necessary. If the item is not located, immediate referral is indicated for imaging and assessment.

## CONFLICT OF INTEREST

The authors have no conflict of interests to declare.

## ETHICS STATEMENT

Consent for publication of this case report was obtained from patient's legal guardian in accordance with the Nationwide Children's Hospital policy for Authorization for Public Disclosure of Underage Patient Information.

## ORCID

Homa Amini  <https://orcid.org/0000-0003-0609-352X>

## REFERENCES

1. Mohan P. Aspiration in Infants and Children. *Pediatr Rev* 2002;23:330–331.
2. Gregori D, Salerni L, Scarinzi C et al. Foreign bodies in the upper airways causing complications and requiring hospitalization in children aged 0–14 years: results from the ESFBI study. *Eur Arch Otorhinolaryngol*. 2008;265:971–978.
3. Jillela S, Subrahmanyam R. Inhaled tooth in the bronchus: importance of early intervention. *Br J Anaesth*. 2015;115:318–319.
4. Yurdakul AS, Kanbay A, Kurul C, Yorgancilar D, Demircan S, Ekim N. An occult foreign body aspiration with bronchial anomaly mimicking asthma and pneumonia. *Dent Traumatol*. 2007;23:368–370.
5. Holan G, Ram D. Aspiration of an avulsed primary incisor: a case report. *Int J Pediatr Dent*. 2000;10:150–152.
6. Alabidi A. Aspiration of an incisor tooth after adenotonsillectomy in a 10-year-old Saudi boy. *E Mediterr Health J*. 2008;14:228–230.
7. Birrer RB, Garven BA. Tooth aspiration in a six-year-old boy. *Am J Emerg Med*. 2001;19:598–600.
8. Steelman R, Millman E, Steiner M, Gustafson R. Aspiration of a primary tooth in a patient with a tracheostomy. *Spec Care Dent*. 1997;17:97–99.
9. Park M, Lee KO, Lee JH. Pneumonia due to tooth-like foreign body aspiration in a child with seizure disorder. *J Korean Dis Oral Health*. 2018;14:26–30.
10. Centers for Disease Control and Prevention. Nonfatal choking-related episodes among children—United States, 2001. *MMWR Morb Mortal Wkly Rep* 2002;51:945.
11. Benfer KA, Weir KA, Bell KL, Ware RS, Davies PSW, Boyd RN. Oropharyngeal dysphagia and gross motor skills in children with cerebral palsy. *Pediatr*. 2013;131:e1553–e1562.
12. Benfer KA, Weir KA, Bell KL, Ware RS, Davies PSW, Boyd RN. Oropharyngeal dysphagia and cerebral palsy. *Pediatr* 2017;140:e20170731.
13. Kim JS, Han ZA, Song DH, Oh HM, Chung ME. Characteristics of dysphagia in children with cerebral palsy, related to gross motor function. *Am J Phys Med Rehabil*. 2013;92:912–919.
14. Sullivan PB, Morrice JS, Vernon-Roberts A, Grant H, Eltumi M, Thomas AG. Does gastrostomy tube feeding in children with cerebral palsy increase the risk of respiratory morbidity? *Arch Dis Child*. 2006;91:478–482.
15. Passali D, Lauriello M, Bellussi L, Passali GC, Passali FM, Gregori D. Foreign body inhalation in children: an update. *Acta Otorhinolaryngol Ital*. 2010;30:27–32.

16. Hou R, Zhou H, Hu K, et al. Thorough documentation of the accidental aspiration and ingestion of foreign objects during dental procedure is necessary: review and analysis of 617 cases. *Head Face Med.* 2016;12:23.
17. Mahesh R, Prasad V, Menon PA. A case of accidental aspiration of an endodontic instrument by a child treated under conscious sedation. *Eur J Dent.* 2013;7:225–228.
18. Adewumi A, Kays DW. Stainless steel crown aspiration during sedation in pediatric dentistry. *Pediatr Dent.* 2008;30:59–62.
19. Villasenor A. Aspiration of gauze pressure-pack following a dental extraction: a case report. *Pediatr Dent.* 1999;21:135–136.
20. Wandera A, Conry JP. Aspiration and ingestion of a foreign body during dental examination by a patient with spastic quadriparesis: case report. *Pediatr Dent.* 1993;15:362–363.
21. Susini G, Pommel L, Camps J. Accidental ingestion and aspiration of root canal instruments and other dental foreign bodies in a French population. *Int Endod J.* 2007;40:585–589.

**How to cite this article:** Amini H, Boynton JR. Aspiration of an exfoliated primary molar in a child with cerebral palsy: A case report. *Spec Care Dentist.* 2022;42:416–420. <https://doi.org/10.1111/scd.12686>