

CASE REPORT

Gingival recessions caused by Herpes Simplex Virus in a patient with COVID-19 infection

Debora Franceschi¹  | Riccardo Di Gianfilippo² | Ida Rubino¹ | Lapo Serni¹ | Giovan Paolo Pini Prato³

¹Department of Experimental and Clinical Medicine, University of Florence, Florence, Italy

²Department of Periodontics and Oral Medicine, The University of Michigan School of Dentistry, Ann Arbor, Michigan, USA

³Tuscany Academy of Dental Research (ATRO), Florence, Italy

Correspondence

Debora Franceschi, Department of Experimental and Clinical Medicine, Via Ponte di mezzo 48, Florence, Italy.
Email: debora.franceschi@unifi.it

Funding information

No funding was available for the study.

Abstract

Herpes Simplex Virus type 1 (HSV-1) is a very common infection often localized in the mucocutaneous junction of the lip. Rarely, it could be detected also in periodontal tissues, associated with an elevated risk of periodontal disease progression and gingival recessions. Recently, HSV-1 and numerous co-infections have been reported in literature associated with the Coronavirus and subsequent COVID-19 disease. This report illustrates a case of HSV-1 in a patient with Covid-19 infection, showing the presence of ulcers and vesicles on the gingival margin of maxillary teeth associated with soreness and pain. The histology highlighted the presence of intraepithelial cell ballooning, confirming the diagnosis of HSV-1 infection.

KEYWORDS

Covid-19, gingival recession, Herpes Simplex Virus, Sars-CoV-2

1 | INTRODUCTION

Herpes Simplex Virus type 1 (HSV-1) is a nuclear replicating enveloped virus responsible for both primary and recurrent infections of the oral mucosa. Primary herpetic gingivostomatitis is widespread in children and young adults without significant morbidity, with 70%–80% of children positive to serum antibodies.¹ On the other hand, HSV-1 infections can be particularly severe in immunocompromised patients with increased risk of complication due to systemic dissemination. The most common manifestation of HSV-1 infection is the “herpes labialis.” It is usually localized to the mucocutaneous junction of the lips, while the tongue and the masticatory mucosa of gingiva and palate are less frequently affected. HSV-1 may be accompanied by fever, malaise, and cervical

lymphadenopathy, which may last for many months. The lesions consist of multiple vesicles that rupture, rapidly giving rise to ulcers.² Once the virus enters the skin or the mucosa, it replicates in the epithelial cells of the spinous and granular layer and induces a local inflammatory response with death of the infected epithelial cells. HSV-1 can be isolated also in monocytes and macrophages.³ After the primary infection, HSV-1 moves through sensory nerve pathways and becomes latent within the sensory nerve ganglions, although there is incomplete knowledge regarding the modalities of latency maintenance. The clinical course of HSV-1 infection is usually benign, and it ends with complete clinical resolution in about 10 days.

As regards to HSV-1 and periodontal tissues, periodontal sites with herpesvirus-infection tend to exhibit more breakdown than herpesvirus-free sites, and a herpes

This is an open access article under the terms of the [Creative Commons Attribution-NonCommercial-NoDerivs](https://creativecommons.org/licenses/by-nc-nd/4.0/) License, which permits use and distribution in any medium, provided the original work is properly cited, the use is non-commercial and no modifications or adaptations are made.

© 2022 The Authors. *Clinical Case Reports* published by John Wiley & Sons Ltd.

active infection is associated with an elevated risk of progressive periodontal disease.⁴ It is still unclear if antiviral immune mediators exert a protective or a destructive role in pathogenesis of periodontal disease. Slots⁵ reported that some immune mechanisms that are active against viruses may diminish antibacterial immune responses, and vice versa. Pini Prato et al.⁶ reported on the possible of viral etiology of gingival recessions when herpetic ulcers are located to the gingival margin. Other herpes viruses like Epstein–Barr virus and Cytomegalovirus were associated with severe types of oral disease, including increased gingival inflammation and periodontal attachment loss,⁷ periodontal abscesses,⁸ acute necrotizing ulcerative gingivitis,⁹ and oral ulcers.¹⁰

More recently, the severe acute respiratory syndrome coronavirus 2 (SARS-CoV-2) gained high scientific attention due to the global pandemic of coronavirus disease 2019 (COVID-19) that affects all age groups with severe socio-economic impact on society.^{11,12} The role of SARS-CoV-2 with other co-infections or diseases are under intense investigation. Some systematic reviews reported the association between oral lesions and SARS-CoV-2.^{13–16} In particular, some authors reported on the reactivation of latent herpes infections in patients with COVID-19.^{17,18} Research in oral medicine and periodontology still has to dive into the clinical implications of the reactivation of HSV-1 in patients with COVID-19. Therefore, the aim of this report was to present a case of severe gingival recessions caused by the reactivation of HSV-1 in a patient with COVID-19.

2 | CASE REPORT

2.1 | First examination

In January 2021, a 39-year-old woman presented in a private periodontal office (Florence 50,121, Italy) complaining of severe pain referred from the gingival margin of maxillary teeth. The medical history was reviewed and was found negative for any significant disease or condition, except for history of smoking. She used to smoke about 15 cigarettes per day and she quit since 2020. At the clinical evaluation, the patient showed poor plaque control, nicotine spots, old dental fillings, and multiple gingival recessions in the upper right quadrant of the maxillary arch (Figure 1A). The clinical aspect of soft tissues was good except for a localized inflamed area in correspondence of the upper left central incisor (Figure 1B). The patient reported that a soreness was perceived from the gingival margin of upper teeth, it started the day before and it was becoming stronger. She also reported that the gingival recessions present in the maxillary arch occurred

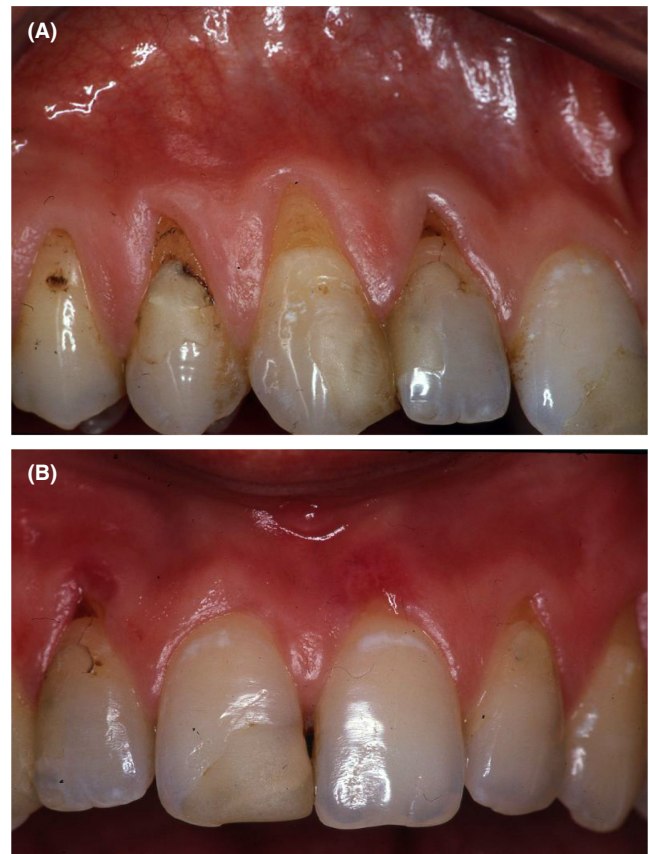

FIGURE 1 (A, B). (A) Time 0: Presence of deep gingival recessions in correspondence of the upper left first premolar, second premolar, canine and lateral incisor associated with nicotine spots and old dental filling. (B) small, inflamed area on gingival margin of the upper left central incisor

in the same way 3 years before, together with a fast onset of pain and burning sensation. The previous episode was characterized by the rapid progression of ulcerative lesions, which destroyed the soft marginal tissue rapidly in approximately 3 days. As reported by the patient, after <2 weeks from the onset of the pain, all the symptoms spontaneously disappeared but deep residual recessions were present. In the lower right quadrant of the mandibular arch, she had two implant supported crowns, apparently healthy with no sign of inflammation or marginal recessions. On the light of the pattern of progression of the gingival lesions as reported in the anamnesis, and on the undefined diagnosis, the patient was asked to come back for a re-evaluation the following day.

2.2 | Second examination

The following day, the patient presented with ulcerative inflammatory lesions located at the gingival margin of the upper right second premolar, canine, lateral incisor and upper left central incisor, together with severe pain,

burning sensation, and mild adenopathy (Figure 2A,B,C). The pain also affected slightly the right lower arch but the aspect of soft tissues around teeth and implants were healthy. The patient referred that home oral hygiene was not possible because of the acute pain from the gingival lesions. Because the signs and symptoms did not allow for a specific diagnosis, neither mechanical periodontal therapy nor chemical antibiotic therapy were initiated. An analgesic medication (ibuprofen 600 mg) was prescribed for pain control, and the patient was invited for one additional examination the following day.

2.3 | Third examination

On third day, the patient showed systemic fatigue and discomfort. Severe ulcerative lesions were present on the gingival margins of the upper right first premolar, second premolar, canine, lateral incisor, and upper left first molar (Figure 3A,B,C). The phenotypic features of gingival tissue worsened since the previous day with deepening of previous gingival recessions. These lesions were source of acute pain. Based on the previous literature by Pini Prato et al.⁶ on the possible role of HSV-1 as etiology of gingival recessions, the same periodontist (GPP) finalized a clinical suspected diagnosis of HSV-1 infection. The patient was provided with dedicated antiviral therapy (acyclovir 800 mg, 3/day for 7 days), referred to the Center of Oral Pathology of the University of Florence for microbiological culture of the ulcerative lesion.

2.4 | Fourth examination

Seven days after the beginning of the antiviral therapy, and 9 days after first examination, the patient was screened

again and reported significant improvement with reduction of all oral symptoms. The ulcerations of the gingival margin significantly regressed, together with a significant reduction of self-reported pain and burning sensation. Laboratory culture analyzed the fluid from the vesicular lesions and confirmed the presence of HSV-1 (Figure 4). Due to the persistent systemic symptomatology, it was suggested to make the molecular test to detect the presence of SARS-COV-2, which resulted positive. The patient did not show relevant symptoms during the following weeks and was followed by the general practitioner. Doctors and staff of the periodontal practice who have been in contact with the patient were screened for SARS-COV-2 and were all found negative.

2.5 | Fifth examination

Twenty-three days after the diagnosis of COVID-19 and herpes simplex infections, the patient fully recovered from COVID-19, was considered noninfective, and presented for periodontal examination. Gingival tissues displayed healthy appearance of the gingival margins, keratinized tissue, and alveolar mucosa (Figure 5B,C). Gingival recessions did not progress since last examination. Plaque control improved as the patient resumed oral hygiene maneuvers after relief from the gingival pain.

2.6 | Follow-up

The patient was visited monthly for clinical examination, professional plaque control, and oral hygiene instructions.^{19,20} Clinical peri-implant parameters^{21,22} in the lower arch were checked and recorded. In September 2021, a gingival augmentation was performed to increase

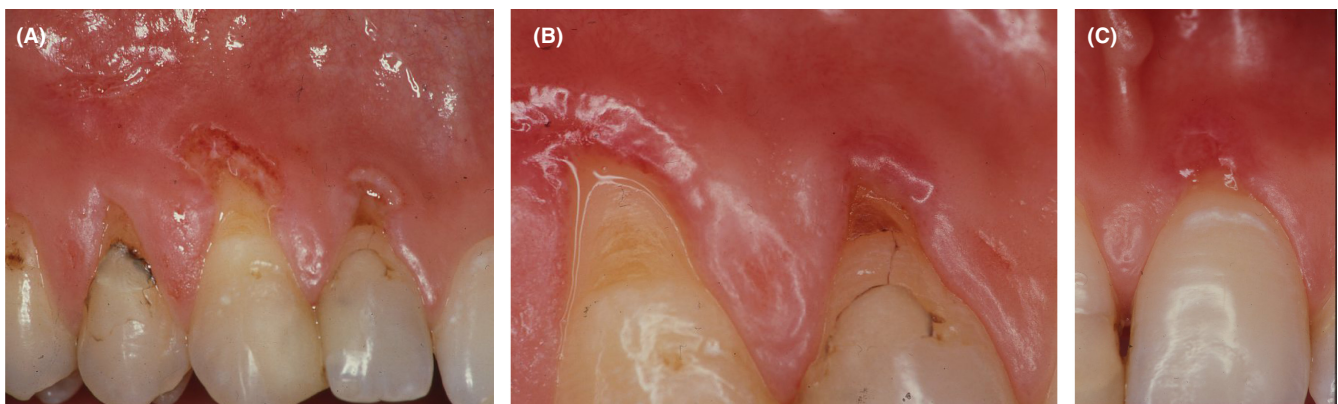


FIGURE 2 (A, B, C). (A) Presence of severe ulcerative-vesiculous lesions in correspondence of the upper left first premolar, canine, and lateral incisor 1 day after Time 0. (B) high magnification of the lesions on the canine and lateral incisor. (C) high magnification of the lesions on the upper left central incisor

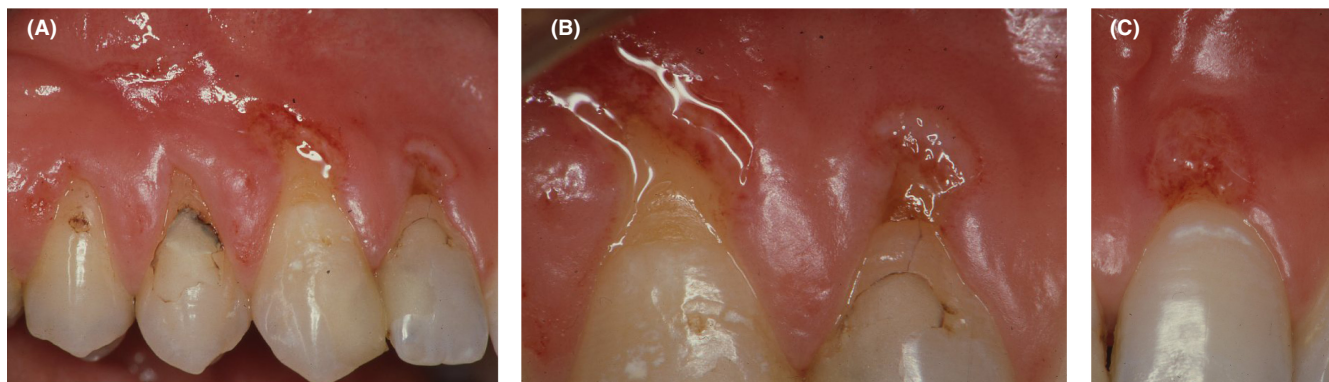


FIGURE 3 (A, B, C). (A) Lesions on premolars, canine and lateral incisor 2 days after Time 0. (B) high magnification of the lesions on the canine and lateral incisor. (C) high magnification of the lesions on the upper left central incisor

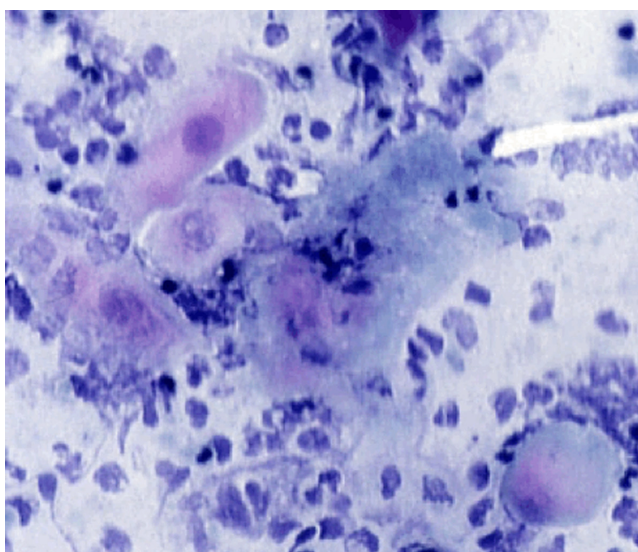


FIGURE 4 Microscopic view of the material harvested from the vesicles. The Papanicolaou stain method highlighted intraepithelial cell ballooning, inflammatory cells, virus-infected epithelial cells, and acantholytic epithelial cells (Tzanck cells)

the width of keratinized tissue and facilitate plaque control (Figure 6).

The patient signed a written informed consent with agreement to use his data for the case report, in accordance with the Helsinki declaration of 1975, as revised in 2013.

3 | DISCUSSIONS

The present report is the first evidence of gingival recessions induced by HSV-1 in a patient with COVID-19. This case offers the opportunity for interesting considerations about diagnosis and therapy after reactivation of gingival herpes in a patient positive to COVID-19.

First, the present report confirmed the possible viral etiology of gingival recessions.⁶ Microbiological analysis supported the presence of HSV-1 in the ulcerative lesions of the gingival margin, and clinical examination confirmed that the initial cleft that led to recession defects originated from the ulcerative lesions. The sole antiviral therapy fully reversed the signs of disease and allowed re-establishment of a healthy gingival appearance.

It was of interest that the patient had a similar burst of gingival lesions a few years before, as she reported. However, the previous operator did not suspect HSV-1 in the differential diagnosis. The patient was not referred for viral test and no antiviral therapy was prescribed. The patient was prescribed with antibiotics therapy, antibacterial rinses, and was provided with periodontal nonsurgical therapy. As result, the treatment was unsuccessful to induce any improvement and the gingival margin healed with severe gingival recessions.

In 2021, the patient had a new episode of oral ulcerations and presented to our periodontal practice. She was examined by the periodontist GPP, who previously encountered and published a similar case featured by severe herpetic lesions on the gingival margin. Despite the fast onset and progression of the previously reported case, timely antiviral therapy led to resolution of the infection and prevented the onset of severe recessions, without any need of mechanical periodontal therapy or antibiotics.⁶

The novelty of the present case, when compared to the previous report of herpes-induced gingival recession, stays in the concomitant COVID-19 infection. Suspect of coronavirus infection originated from the systemic symptoms that the patient reported during the examinations. Tiredness, fatigue, and mild cough were interpreted as an incipient clinical manifestation of COVID-19.²³ In addition, by early 2021, medical literature produced the early documentation of reactivation of latent herpes viruses in COVID-affected patients.^{17,18}

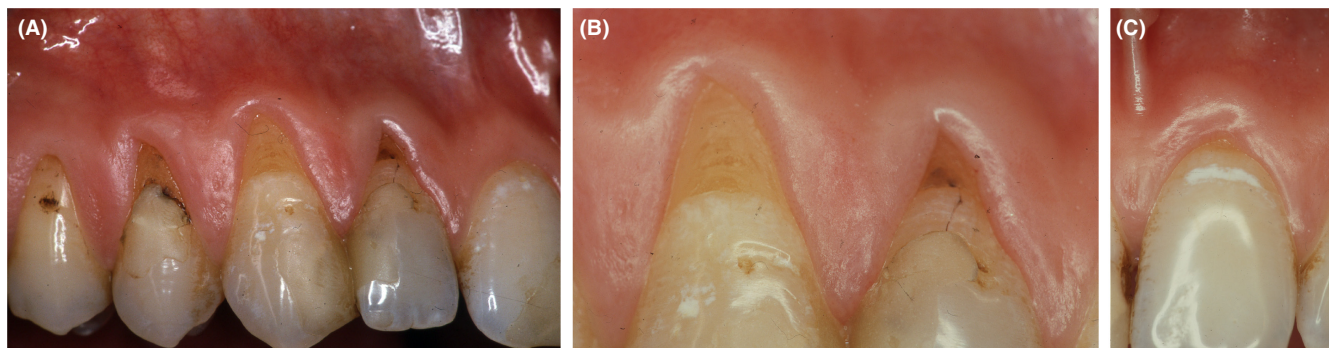


FIGURE 5 (A, B, C). (A) Healing of the marginal tissue after 23 days from Time 0, showing the maintenance of the amount of keratinized tissue, in the area previously involved by the infection. (B) high magnification of the gingival margin of the canine and lateral incisor. (C) high magnification of the gingival margin of the upper left central incisor

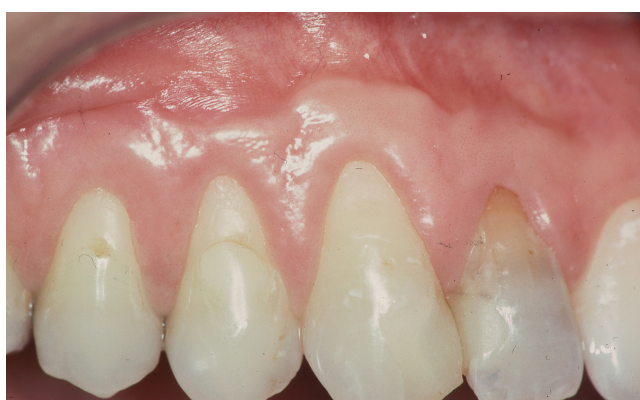

FIGURE 6 Six-month follow-up after free gingival graft performed on the upper right canine

It is interesting to notice how the gingival ulcers healed within 1 week, while the recovery after COVID-19 lasted for 3 weeks since initial diagnosis.

In conclusions, the presented case report documented that:

1. Herpes Simplex Virus 1 (HSV-1) can induce ulcerative lesions of the gingival margin leading to deep gingival recessions.
2. Contrarily to gingival recessions induced by periodontitis or mechanical trauma, gingival recessions induced by HSV-1 have fast onset/progression and viral etiopathogenesis.
3. Antibiotics and mechanical periodontal therapy are ineffective for treatment of herpes-induced gingival recessions, while the sole timely administration of antiviral therapy was followed by disease remission.
4. Mild systemic symptoms associated with herpes reactivation should raise the suspect of existing SARS-CoV-2 infection, and dedicated screening is highly recommended.

AUTHOR CONTRIBUTION

Debora Franceschi: Conceptualization, Writing original draft. Riccardo Di Gianfilippo: Conceptualization, Writing original draft. Ida Rubino: Conceptualization and supervision. Serni Lapo: Writing reviewing and Validation. Giovan Paolo Pini Prato: Supervision, Writing reviewing and Validation.

ACKNOWLEDGEMENTS

None.

CONFLICT OF INTEREST

The authors have stated explicitly that there are no conflicts of interest in connection with this article.

CONSENT

The study was conducted according to the guidelines of the Declaration of Helsinki. Ethical review and approval were waived for this study because the patient signed a written informed consent with agreement to use his data for the case report (Checklist Standards and Guideline CA-RE).

DATA AVAILABILITY STATEMENT

The data that support the findings of this study are available from the corresponding author upon reasonable request.

ORCID

Debora Franceschi  <https://orcid.org/0000-0002-9575-749X>

REFERENCES

1. Whitley RJ, Roizman B. Herpes simplex virus infections. *Lancet*. 2001;357:1513-1518.
2. Epstein JB, Scully C. Herpes simplex virus in immunocompromised patients: growing evidence of drug resistance. *Oral Surg Oral Med Oral Pathol*. 1991;72:47-50.

3. Banks T, Rouse BT. Herpesviruses—Immune escape artists? *Clin Infect Dis.* 1992;14:933-941.
4. Slots J. Herpesviruses in periodontal diseases. *Periodontology 2000.* 2005;38:33-62.
5. Slots J. Herpesviral-bacterial interactions in periodontal diseases. *Periodontology 2000.* 2010;52:117-140.
6. Pini Prato GP, Rotundo R, Magnani C, Ficarra G. Viral etiology of gingival recession. *A case report J Periodontol.* 2002;73:110-114.
7. Ling LJ, Ho CC, Wu CY, Chen YT, Hung SL. Association between human herpesviruses and the severity of periodontitis. *J Periodontol.* 2004;75:1479-1485.
8. Saygun I, Yapar M, O' zdemir A, Kubar A, Slots J. Human cytomegalovirus and Epstein–Barr virus type 1 in periodontal abscesses. *Oral Microbiol Immunol.* 2004;19:83-87.
9. Contreras A, Falkler WA Jr, Enwonwu CO, et al. Human herpesviridae in acute necrotizing ulcerative gingivitis in children in Nigeria. *Oral Microbiol Immunol.* 1997;12:259-265.
10. Syrjänen S, Leimola-Virtanen R, Schmidt-Westhausen A, Reichart PA. Oral ulcers in AIDS patients frequently associated with cytomegalovirus (CMV) and Epstein–Barr virus (EBV) infections. *J Oral Pathol Med.* 1999;28:204-209.
11. Hatmi ZN. A systematic review of systematic reviews on the COVID-19 pandemic. *SN Compr Clin Med.* 2021;26:1-18. doi:10.1007/s42399-021-00749-y
12. Suthar S, Das S, Nagpure A, et al. Epidemiology and diagnosis, environmental resources quality and socio-economic perspectives for COVID-19 pandemic. *J Environ Manage.* 2021;280:111700. doi:10.1016/j.jenvman.2020.111700
13. Aragonese J, Suárez A, Algar J, Rodriguez C, Lopez-Valverde N, Aragonese JM. Oral manifestation of COVID-19: updated systematic review with meta-analysis. *Front Med.* 2021;8:1-12.
14. Amorim Dos Santos J, Normando AGC, Carvalho da Silva RL, et al. Oral manifestations in patients with COVID-19: a living systematic review. *J Dent Res.* 2021;100(2):141-154.
15. Erbaş GS, Botsali A, Erden N, et al. COVID-19-related oral mucosa lesions among confirmed SARS-CoV-2 patients: a systematic review. *Int J Dermatol.* 2022;61(1):20-32.
16. La Rosa GRM, Libra M, De Pasquale R, Ferlito S, Pedullà E. Association of viral infections with oral cavity lesions: role of SARS-CoV-2 infection. *Front Med.* 2021;14:7-571214.
17. Xu R, Zhou Y, Cai L, et al. Co-reactivation of the human herpesvirus alpha subfamily (herpes simplex virus-1 and varicella zoster virus) in a critically ill patient with COVID-19. *Br J Dermatol.* 2020;183:1145-1147.
18. Giacobbe DR, Di Bella S, Dettori S, et al. Reactivation of Herpes Simplex Virus Type 1 (HSV-1) detected on bronchoalveolar lavage fluid (BALF) samples in critically ill COVID-19 patients undergoing invasive mechanical ventilation: preliminary results from two Italian centers. *Microorganisms.* 2022;10(2):362.
19. Nieri M, Giani M, Pagliaro U, Picciullo A, Franceschi D, Rotundo R. Efficacy and preference of manual toothbrushes: a randomised, single blind, controlled trial. *Eur J Oral Implant.* 2013;6:181-188.
20. Nieri M, Giuntini V, Pagliaro U, Giani M, Franchi L, Franceschi D. Efficacy of a U-shaped automatic electric toothbrush in dental plaque removal: a cross-over randomized controlled trial. *Int J Env Res Pub Health.* 2020;17:4649.
21. Di Gianfilippo R, Askar H, Henderson J, Franceschi D, Wang HL, Wang CW. Intra- and inter-examiner repeatability of diagnostic peri-implant clinical measurement: a pilot study. *J Oral Implantology.* 2021. Online ahead of print .
22. Cucchi A, Vignudelli E, Franceschi D, et al. Vertical and horizontal ridge augmentation using customized CAD/CAM titanium mesh with versus without resorbable membranes. A randomized clinical trial. *Clin Oral Implants Res.* 2021;32(12):1411-1424. doi:10.1111/clr.13841
23. Huang C, Wang Y, Li X, et al. Clinical features of patients infected with 2019 novel coronavirus in Wuhan, China. *Lancet.* 2020;395:497-506.

How to cite this article: Franceschi D, Di Gianfilippo R, Rubino I, Serni L, Pini Prato GP. Gingival recessions caused by Herpes Simplex Virus in a patient with COVID-19 infection. *Clin Case Rep.* 2022;10:e06056. doi: [10.1002/ccr3.6056](https://doi.org/10.1002/ccr3.6056)