








ORIGINAL ARTICLE

Comparative analysis of two biomaterials mixed with autogenous bone graft for vertical ridge augmentation: A histomorphometric study in humans

Pier Gallo DDS, PhD¹  | David Díaz-Báez DDS, MS² | Sandra Perdomo DDS, PhD² | Antonio Carlos Aloise DDS, MS, PhD¹  | Mustafa Tattan DDS³  | Muhammad H. A. Saleh BDS, MSD⁴  | André Antonio Pelegrine DDS, MS, PhD¹  | Andrea Ravidà DDS, MS⁴  | Hom-Lay Wang DDS, MS, PhD⁴ 

¹Department of Implant Dentistry, Faculdade São Leopoldo Mandic, Instituto de Pesquisas São Leopoldo Mandic, Campinas, Brazil

²Researcher of Oral Basic Research Unit -UIBO, School of Dentistry, El Bosque University, Bogotá, Colombia

³Department of Periodontics, College of Dentistry, University of Iowa, Iowa City, Iowa, USA

⁴Department of Periodontics and Oral Medicine, University of Michigan, School of Dentistry, Ann Arbor, Michigan, USA

Correspondence

Hom-Lay Wang, Department of Periodontics and Oral Medicine, University of Michigan School of Dentistry, 1011 North University Avenue, Ann Arbor, Michigan 48109-1078, USA.

Email: homlay@umich.edu

Funding information

Coordenação de Aperfeiçoamento de Pessoal de Nível Superior, Grant/Award Number: 001

Abstract

Background: The vertical increase of the alveolar ridge dimension using allograft or xenograft mixed with autogenous bone graft and covered by a nonabsorbable high-density polytetrafluoroethylene (d-PTFE) membrane is well documented in the literature.

Purpose: The aim of this study was to assess vital mineralized tissue formation in vertical ridge augmentation (VRA) procedures using autogenous bone chips mixed either with an allograft or a xenograft.

Methods: This prospective clinical trial recruited 16 partially edentulous patients to undergo vertical ridge augmentation in one or more sites, making up a total of 24 samples for histological evaluation. Patients were sequentially stratified into Group A (treated with a freeze-dried bone allograft [FDBA] mixed with autogenous bone) or to Group B (treated with a bovine xenograft mixed with autogenous bone). Histological samples were analyzed according to the biomaterial used for VRA. Histological samples were obtained on the same day of membrane removal and implant placement.

Results: Thirty-three implants were placed in 16 sites of regenerated bone via VRA, 13 patients with ridge augmentation in the posterior mandible, and 3 patients with VRA in the anterior maxilla. Group A (FDBA + autogenous) and Group B (xenograft + autogenous) showed a percent vital mineralized tissue (VMT) area of 67.64 ± 16.84 and 60.93 ± 18.25 , respectively. A significant difference between the two biomaterials was not observed.

Conclusion: When mixed with autogenous bone, either allografts or xenografts may provide a successful augmentation. Either mixture could serve as reliable alternative in VRA for obtaining a high percentage of VMT.

This is an open access article under the terms of the [Creative Commons Attribution-NonCommercial-NoDerivs](https://creativecommons.org/licenses/by-nc-nd/4.0/) License, which permits use and distribution in any medium, provided the original work is properly cited, the use is non-commercial and no modifications or adaptations are made.

© 2022 The Authors. *Clinical Implant Dentistry and Related Research* published by Wiley Periodicals LLC.

KEYWORDS

alveolar bone grafting, bone augmentation, bone substitutes, dental implants, guided bone regeneration

What is known

Vertical ridge augmentation is a very challenging surgical procedure. So far, the procedure is typically executed using either autogenous bone solely or autogenous bone mixed with a xenograft.

What this study adds

This prospective clinical trial assessed the vital mineralized tissue formation following vertical ridge augmentation using autogenous bone chips mixed either with an allograft (freeze-dried bone allograft) or a xenograft (bovine). This study provides evidence either mixture could serve as reliable alternative in VRA for obtaining a high percentage of VMT.

1 | INTRODUCTION

Following tooth loss, and resultant disuse atrophy, a significant process of alveolar ridge remodeling ensues that can preclude dental implant placement.^{1,2} Alveolar ridge augmentation via guided bone regeneration (GBR) has gained popularity in regaining these lost dimensions to enable dental implant placement when the ridge alterations preclude successful implant therapy. While horizontal ridge augmentation can be predictable, vertical ridge augmentation remains a challenge and has been associated with a high degree of technique sensitivity and requires a steep learning curve.^{3,4} Despite failures due to soft tissue dehiscence, graft shrinkage, and/or poor blood supply among other reasons,³ significant degree of bone formation has been clinically demonstrated on numerous occasions in the literature.⁴⁻⁷

One of the key elements of GBR is the scaffold that promotes blood clot stability and provides mesenchymal stem cells with a bed that is conducive to adequate bone formation.⁸ Just as bone grafts have served as well-established scaffolds in guided tissue regeneration (GTR) around teeth,^{9,10} they have provided the same role in GBR.³ The choice of bone grafting material used, based on features such as osteoconductive capacity, particle size, and resorption rate should not be a cursory process. Clinical and histological evidence has supported the efficacy of particular biomaterials for this purpose, including autogenous bone chips, allografts and xenografts. In order to harness the most favorable qualities of each biomaterial, combinations of these biomaterials have also been proposed.^{6,11-14} For example, in a histological investigation, wherein bone biopsies were obtained approximately 6–9 months following vertical ridge augmentation using a combination of autogenous bone and bovine bone particles, 35.9% of new bone formation with residual xenograft particles was observed. In this case, combining the slow resorption rate of bovine bone particles with the osteogenic capacity of autogenous bone provided a longer duration scaffold with great regenerative potential. In a prospective case series of 20 vertical bone reconstruction cases using the same bone grafting material combination with a

dense polytetrafluoroethylene membrane, samples were obtained from eight cases for histological analysis. The mean vital bone content observed, corresponding to a mean healing duration of 8.24 months was 36.6%.⁶

The primary aim of this investigation was to histomorphometrically evaluate vital mineralized tissue formation at severe ridge defects treated with VRA utilizing autogenous bone chips combined with freeze-dried bone allograft (FDBA) versus autogenous bone chips combined with bovine bone particles. Secondary study outcomes included nonvital mineralized tissue and nonmineralized tissue formation.

2 | MATERIALS AND METHODS

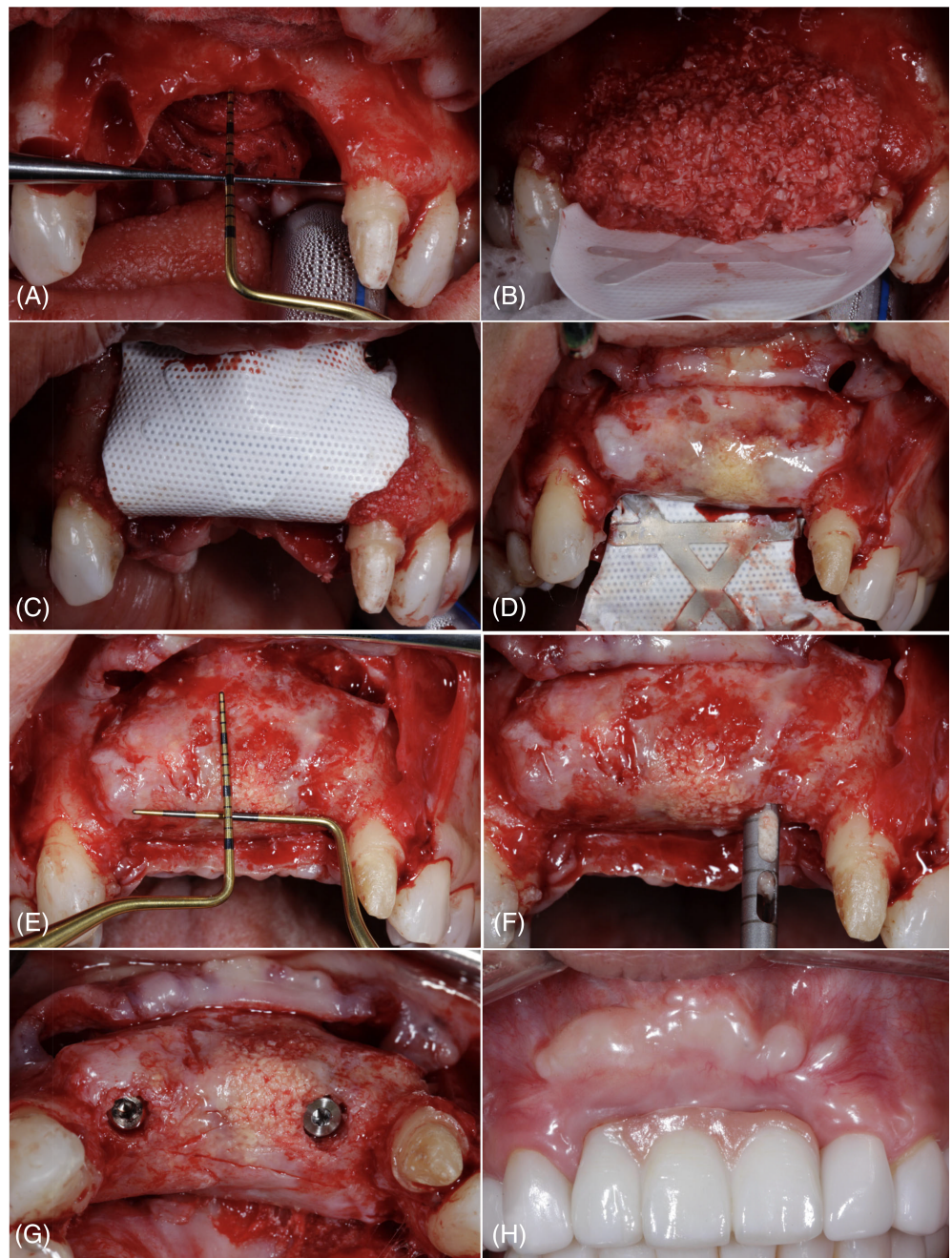
2.1 | Study design

The study protocol was approved by the Institutional review board (IRB) (2.270.655; Campinas, SP, Brazil). Written informed consent was obtained from all patients. In this prospective study, 24 samples for histology were harvested from 16 partial edentulous patients undergoing vertical guided ridge augmentation (VGRA) from January 2016 to November 2018 and who attended a private practice in Bogota, Colombia. The study groups were distinguished based on the type of bone graft used. Selection of the graft was made by decision of the patient, having as options bone of human origin, or animal. All patients were treated in the same private practice.

2.2 | Group allocation

Selected cases were not randomized for vertical augmentation. Patients were assigned to either group based on the preference (in some instances beliefs) of which bone graft substitute to be used. All VBA procedures were performed by the same experienced practitioner (P.G.). Implant

FIGURE 1 (A) The defect immediately after full mucoperiosteal flap elevation, (B) titanium-reinforced d-PTFE membrane, fixed on the palate, and placement of a xenograft + autogenous graft mixture in a 1:1 ratio, (C) A titanium-reinforced nonresorbable membrane d-PTFE covering all the particles of the graft, fixed in vestibular with two mini screws, (D) removal of the membrane after 9 months. (E) Clinical situation after the membrane removal, showing vertical augmentation. (F) A bone biopsy is taken from the site a trephine bur for the histological and histomorphometric evaluation. (G) Placement of a dental implant in the same place where the biopsy was harvested. (H) Case after placement of the final restoration



placement and subsequent prosthetic treatments were performed by author PG. Consolidated Standards of Reporting Trials (CONSORT) guidelines were followed during the preparation of the manuscript.

2.3 | Eligibility criteria

To be considered eligible, patients should have (1) Of ≥ 18 years old at the time of surgical intervention. (2) Systemically healthy or controlled, (3) demonstrated good oral hygiene and compliance, (4) demonstrated periodontal health at the time of intervention, (5) nonsmokers and (6) have severe vertical ridge defects (≥ 5 mm in

height)¹ as measured intraoperatively using a periodontal probe, and (7) require implant placement following VRA.

2.4 | Sample size calculation

The mean percentage of vital mineralized tissue was the primary variable of interest. The sample size was calculated with an assumed power of 80% (using $\alpha = 0.05$) to detect a minimal mean percentage and standard deviation of 27.30 ± 5.55 and 38.44 ± 12.34 for allograft and xenograft, respectively. A sample size of 12 samples per group was obtained.

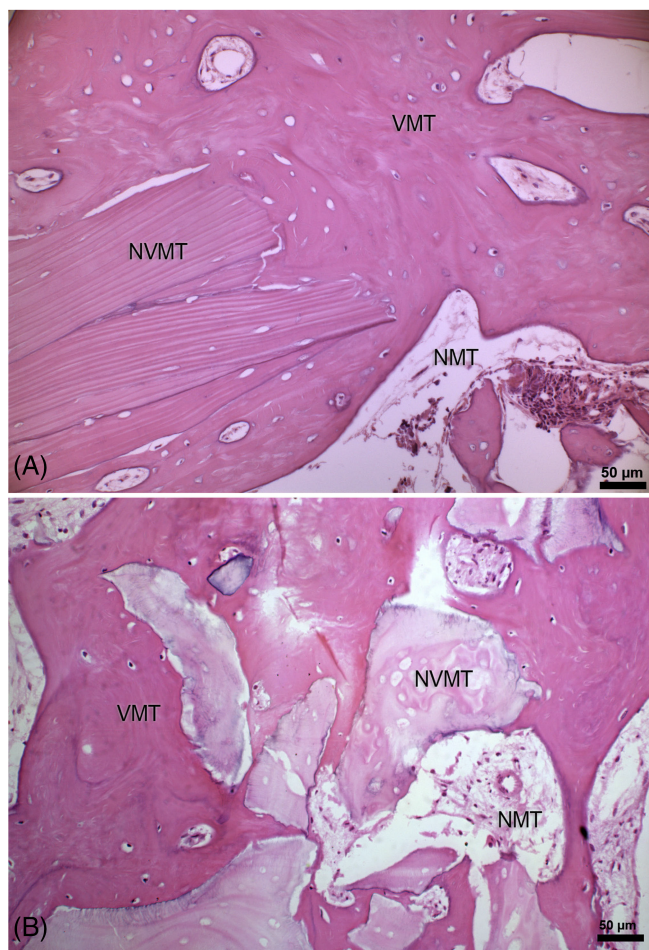


FIGURE 2 Photomicrographs of histologic slides from the Group A = allograft + autogenous bone graft (A) and Group B = xenograft + autogenous bone graft, stained with HE; 200 \times magnification. VMT, vital mineralized tissue; NVMT, nonvital mineralized tissue; NMT, nonmineralized tissue

2.5 | Surgical intervention

All surgical interventions were performed by a single, experienced surgeon (P.G.). Anesthesia in the surgical site was achieved via local infiltration with 2% lidocaine with epinephrine 1:80 000 (Roxicaine[®], Ropsohn, Bogota, Colombia). A full-thickness crestal incision in keratinized mucosa was made, followed by vertical releasing incisions, which number depended on the surgery location. In cases where the anterior maxilla was affected, two vertical incisions were made at least two teeth from the surgical site. In cases where the posterior mandible was affected, only a mesial single vertical incision was made at least one tooth from the defect (buccal and lingual only); distal vertical incisions were avoided. Full-thickness reflection of the flap was achieved using a periosteal elevator in combination with saline-moistened gauze to reveal the local anatomic structures (Figure 1A).

Advancement of the facial/buccal flap was achieved via periosteal horizontal releasing incisions that did not invade the underlying connective tissue. Due to no potential for the palatal flap to be coronally advanced, in maxillary cases, the crestal incision was positioned

slightly toward the adjacent vestibule. In patients with a mandibular defect, the mental nerve was protected by only making periosteal incisions at a 10-mm distance from the mental foramen. Following this, the subperiosteal bundles were released from the elastic fibers using a specialized periosteal elevator (Buser Periosteal Elevator, Salvin Dental Specialties, Inc., Charlotte, NC, USA). Similarly, the lingual flap was gently separated from the surface fibers of the mylohyoid muscle to achieve tension-free closure.

The defect was measured with a periodontal probe at the most apical point of the defect creating a 90° angle with another horizontally positioned periodontal probe 2 mm apical to the cemental-enamel junction of bounding teeth. The recipient bone bed was prepared with multiple cortical perforations using a spade marking drill (MIS Implants Technologies, Fair Lawn, NJ, USA). Subsequently, a nonresorbable titanium-reinforced membrane (Cytoplast; Osteogenics Biomedical, Lubbock, TX, USA) was adapted and fixed to the lingual aspect of the defect with at least two mini-screws (Profix[®]; Osteogenics Biomedical). All defects were grafted with a 1:1 ratio of autogenous bone chips harvested from the same surgical site using a specialized instrument (Bone Scraper, Salvin Dental Specialties, Inc., Charlotte, NC, USA) mixed with a commercially available hard tissue grafting material. In cases of the upper jaw where the required 50% autologous bone could not be obtained, a second surgical approach was performed in the posterior mandible, exactly in the external oblique line to harvest autogenous bone chips. Some defects were grafted with autogenous bone combined with a combination of FDBA cortical and cancellous Chips of 0.60–1.25 mm particle size (MinerOss; Biohorizons, Birmingham, AL, USA) (Study Group A), and others with autogenous bone mixed with a Porcine xenograft 0.25–1.0 mm particle size (Zcore; Osteogenics Biomedical) (Study Group B) (Figure 1B).

The membrane was folded over the bone graft and fixed at the buccal aspect using ≥ 2 mini screws to immobilize the graft (Figure 1C). Tenting screws were not used because the bone filling and the titanium-reinforced membrane prevent vertical collapse of the defect and, according to the authors, make the use of these screws of little use. Tension-free flap closure was achieved by first horizontal mattress sutures, to ensure close contact between the inner connective tissue portions of the flaps, followed by multiple single interrupted sutures (Cytoplast C-0518; Osteogenics Biomedical).

All patients were medicated with amoxicillin and clavulanate potassium (875 mg/125 mg; Clavulin[®]; GlaxoSmithKline, Brentford, UK) twice a day for 7 days, as well as Nimesulid (100 mg; Scaflam[®], Eurofarma, São Paulo, Brazil) twice a day for 5 days. Patients were also instructed to rinse twice a day with a 0.12% chlorhexidine solution (Clorhexol[®]; Farpag Farmaceutics, Bogota, Colombia). All sutures were removed before Day 21 postoperatively. Subsequent postoperative visits were scheduled at 8-day intervals in the first 2 months to evaluate the course of healing. Following the second month, re-evaluation visits were scheduled monthly.

At the time of membrane removal, bone biopsies were obtained using a trephine bur (diameter = 2.0 mm and length = 10 mm) at the time of membrane removal and implant placement (Figure 1D–F). Since the defects were vertical in nature, biopsies were taken from the future implant sites without concerns of involving native bone in the biopsies, except for the apical most portions. At the time of bone biopsy harvest,

TABLE 1 Comparison of demographic and clinical characteristics among the intervention groups

	Group A		Group B		p value
	Allograft + Autogenous		Xenograft + Autogenous		
Median age (RIQ)	52.0	(50.5–55.5)	32.0	(31–41.5)	0.006
Sex n (%)					
Female	10	83.33%	7	58.33%	0.371
Male	2	16.67%	5	41.67%	
Near of the wall n (%)					
No	8	66.67%	5	41.67%	0.219
Yes	4	33.33%	7	58.33%	
Jaw n (%)					
Mandible	11	91.67%	9	75.00%	0.590
Maxilla	1	8.33%	3	25.00%	
Area n (%)					
Anterior	1	8.33%	3	25.00%	0.590
Posterior	11	91.67%	9	75.00%	
Type of membrane (%)					
Cytoplast BL-250	1	8.33%	0	0.00%	0.250
Cytoplast PL-250	0	0.00%	1	8.33%	
Cytoplast XL-250	11	91.67%	11	91.67%	
Median measure of the vertical defect (mm) (RIQ)	4.5	(4.0–5.0)	5.0	(4.0–6.75)	0.378
Median membrane Healing Month (RIQ)	15.5	(11.0–23.0)	11.0	(9.0–15.5)	0.068
Median membrane Healing Week (RIQ)	62.0	(44.0–92.0)	44.0	(36.0–62.0)	0.068
Median N° Implants (RIQ)	2.0	(2.0–2.0)	2.0	(2.0–2.0)	0.713

Note: Analysis performed by χ^2 test, Fisher's exact test/Mann-Whitney U test.

Abbreviations: VMT, vital mineralized tissue; NMT, nonmineralized tissue; NVMT, nonvital mineralized tissue.

samples were fixed in 10% formaldehyde solution (Merck, Darmstadt, Germany) to be processed at a later time. All patients received dental implants, which were functionally loaded with implant-support fixed dental prostheses according to the case (Figure 1G,H).

2.6 | Histological preparation and histomorphometric analysis

The obtained biopsies underwent decalcification in 10% ethylenediaminetetraacetic acid for 36 h and were then processed following a conventional histology method for hard tissue. Subsequently, the samples were embedded in paraffin, and 7- μ m sections were prepared. The entire area of the trephine biopsy specimen above the native bone of the vertical augmentation was defined as the “region of interest” and evaluated via histomorphometry.

Following staining with hematoxylin and eosin (HE) stain, six areas of each fragment were analyzed in the histological slides, namely,

upper left, lower left, upper center, lower center, upper right, and lower right. A mean percentage per histology slide was calculated. Digital images were captured using a monochromatic charge-coupled-device digital camera (AxioCam HRm; Zeiss, Oberkochen, Germany) coupled with an optical microscope (Imager M2; Zeiss) at 20 \times magnification. Digital images were merged to create a single image for each histological section using the GNU image-manipulation software. One blinded, trained investigator (S.P.), who was calibrated (with an intra-class correlation coefficient [ICC] of 0.81 [95% CI: 0.78–0.85]) and blinded to the study protocol, evaluated the images. If there was disagreement, the specimen was reevaluated to reach a consensus. The examiners traced formation of new bone on all images using specialized, commercially available software (ImageJ ProPlus 4.5, National Institutes of Health, Bethesda, MD, USA). The following histomorphometric parameters were considered: (i) vital mineralized tissue (VMT), (ii) nonvital mineralized tissue (NVMT), and (iii) nonmineralized tissue (NMT) (Figure 2). All results were noted in square micrometers and stated as a percentage of the total area.

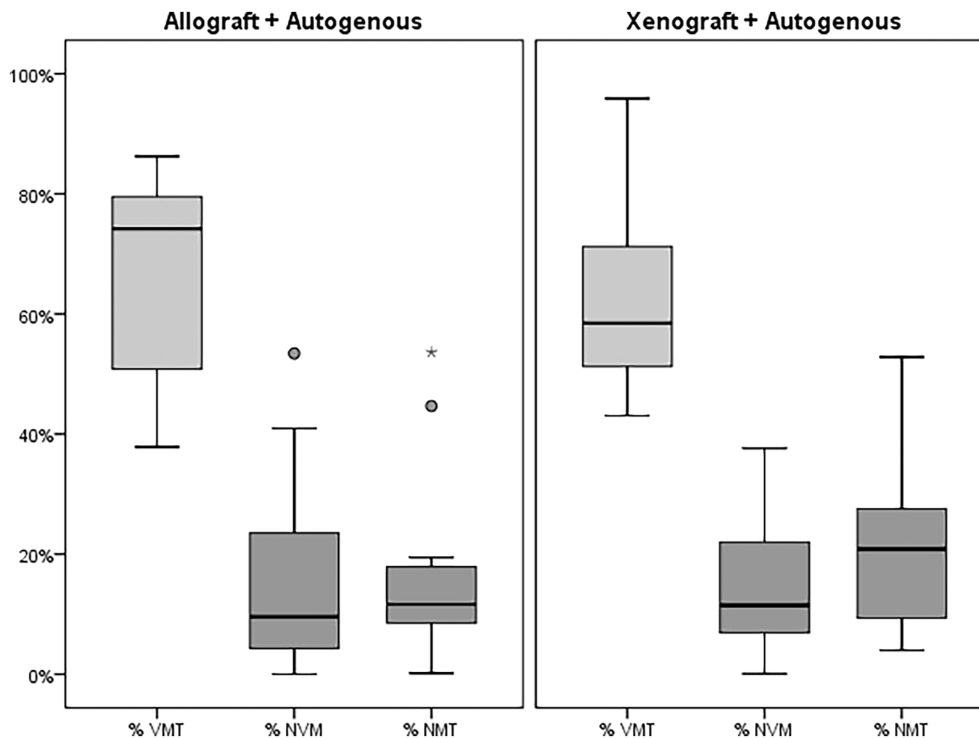


FIGURE 3 Comparison of vital mineralized tissue (VMT), nonvital mineralized tissue (NVMT), nonmineralized tissue (NMT) between groups

2.7 | Statistical analysis

The data analysis was carried out by two blind investigators (D.D.B. and S.P.) where comparison groups were coded prior to the data analysis phase of the investigation. The values of NVMT, VMT, and NMT are expressed as percentages of the areas evaluated. The Mann-Whitney U test was used to compare groups of nonparametric variables such as age, vertical defect (in mm), and membrane healing time. The Chi-squared and Fisher's exact tests were used to compare demographic and clinical characteristics. A multivariate covariance analysis (MANCOVA) obtained with the Roy's Largest Root was used to determine the differences between the intervention groups in relation to vital, nonvital, and nonmineralized mineralized tissue. The age and weeks of scarring of the membrane were entered into the MANCOVA model as covariates. A matrix that presents the effect of the independent variables and their interaction with the dependent variables in the MANCOVA model was also included. The results were considered statistically significant if $p < 0.05$. All analyses were performed using commercially available software (IBM Corp. Released 2020. IBM SPSS Statistics for Macintosh, Version 27.0. Armonk, NY: IBM Corp).

3 | RESULTS

3.1 | Sample characteristics

A total of 16 patients (11 female and 5 male) with a mean age of 45.4 ± 11.8 years old (range: 29–62 years old) participated in this study, making up a total of 12 sites participating in each group. Thirteen of these patients exhibited ridge defects in the posterior mandibular region and

3 in the anterior maxillary region. Each of these defects spanned ≥ 2 missing tooth sites, measured with a periodontal probe. There was no difference in the mean height of vertical defect in both groups (4.5 ± 0.5 mm vs. 5.0 ± 1.4 mm for Groups A and B, respectively), ($p = 0.378$). The groups were comparable in relation to the main clinical variables and sex ($p > 0.05$) (Table 1). Only the age variable was different between groups with Group A having older patients than Group B.

3.2 | Wound healing and clinical outcomes

A significant vertical bone gain was achieved for all cases at the time of membrane removal, enabling implant placement without the need for additional bone grafting. There were no membrane exposures in these cases. Below the membrane, graft particles could be seen in the coronal-most portion of the augmented alveolar ridge. There was a significant difference in healing time between both groups, with Group A having a mean healing time of 15.5 months and Group B having a mean healing time of 11.0 months ($p = 0.06$). A 100% implant survival rate was demonstrated in both Groups A and B, and all implants were restored with fixed dental prostheses.

3.3 | Histological and histomorphometric outcomes

In terms of VMT, Group A and Group B demonstrated percentages of $67.6\% \pm 16.8\%$ and $60.9\% \pm 18.3\%$, respectively. As for NVMT, the percentages for Group A and Group B were $15.7\% \pm 16.9\%$ and $14.0\% \pm 12.1\%$, respectively. Finally, the percentage of NMT

TABLE 2 Histomorphometric analysis between the intervention groups

	Group A		Group B		p value
	Allograft + Autogenous		Xenograft + Autogenous		
	Mean	SD	Mean	SD	
% VMT	67.64	16.84	60.93	18.25	0.359
% NVMT	15.72	16.92	13.99	12.10	0.775
% NMT	16.60	16.21	25.07	19.14	0.254

Note: Analysis performed by U-mann Whitney test.

Abbreviations: VMT, vital mineralized tissue; NMT, nonmineralized tissue; NVMT, nonvital mineralized tissue.

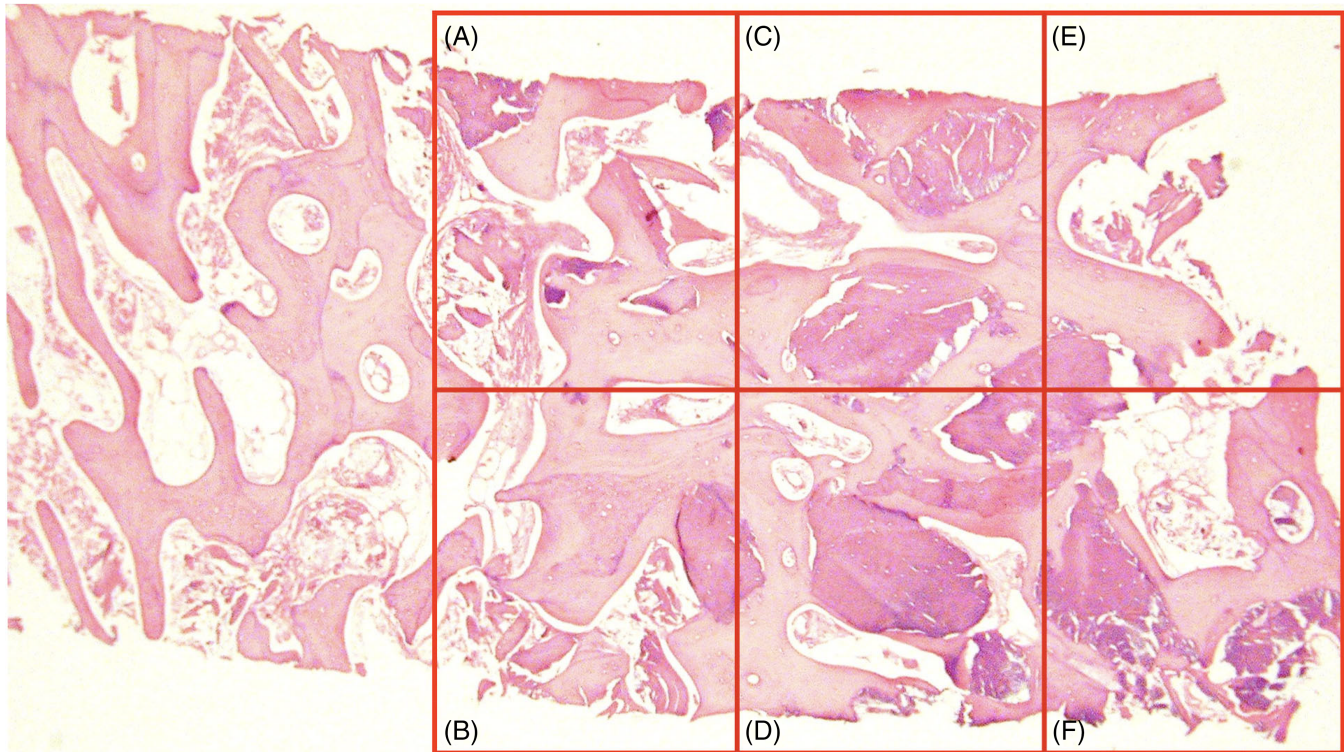


FIGURE 4 Fragment were analyzed in the histological slides, (A) upper left, (B) lower left, (C) upper center, (D) lower center, (E) upper right and (F) lower right

exhibited in Group A and Group B was $16.6\% \pm 16.2\%$ and $25.1\% \pm 19.1\%$, respectively. In the bivariate analysis, no significant differences were detected between the two study groups with respect to percent VMT ($p = 0.359$), NVMT ($p = 0.775$), and NMT ($p = 0.254$) (Figure 3, Table 2). The histological analysis of the fragment is analyzed in Figure 4. Moreover, in the multivariate analysis adjusted for age and healing duration, no statistically significant differences were detected between the groups in terms of percent VMT ($p = 0.195$), NVMT ($p = 0.968$), and NMT ($p = 0.165$). However, a variation with respect to the estimated percentage averages of VMT and NMT between the bivariate analysis and adjusted model was found (Table 3).

4 | DISCUSSION

The results of this prospective clinical, histological, and histomorphometric study have demonstrated that VRA using autogenous bone mixed with either xenograft of porcine origin or allograft yields successful results. All defects of both groups were filled with newly formed bone and recovered to the original form. No differences were found in the VMT between both groups (67.6 ± 16.8 compared to 60.9 ± 18.25 for Groups A and B, respectively [$p = 0.359$]). The same was found for NVMT and NMT.

VRA is one of the most sensitive and complex GBR methods. The predictability of this procedure is dependent to a high extent on the

TABLE 3 Histomorphometric analysis between the intervention groups adjusted to covariate age and Membrane Healing Week

Multivariate contrasts						
Effect	Value	F	Gl of the hypothesis	Gl of error	p value	
Intersection	23 036.55	138 219.29	3.00	18.00	0.000	
Age	0.87	5.23	3.00	18.00	0.009	
Membrane Healing Week	0.27	1.59	3.00	18.00	0.227	
Group	0.08	0.50	3.00	18.00	0.689	
Intersubject effects						
Origin	Dependent variable	Sum of squares	gl	Quadratic mean	F	p value
Corrected model	% VMT	2613.11	3	871.04	3.92	0.024
	% NVMT	169.80	3	56.60	0.25	0.863
	% NMT	3285.79	3	1095.26	5.39	0.007
Intersection	% VMT	13.20	1	13.20	0.06	0.810
	% NVMT	4.01	1	4.01	0.02	0.896
	% NMT	3542.27	1	3542.27	17.43	0.000
Age	% VMT	2331.17	1	2331.17	10.50	0.004
	% NVMT	20.56	1	20.56	0.09	0.768
	% NMT	2790.50	1	2790.50	13.73	0.001
Membrane Healing Week	% VMT	267.30	1	267.30	1.20	0.286
	% NVMT	151.63	1	151.63	0.66	0.427
	% NMT	818.39	1	818.39	4.03	0.059
Group	% VMT	232.15	1	232.15	1.05	0.319
	% NVMT	11.45	1	11.45	0.05	0.826
	% NMT	139.71	1	139.71	0.69	0.417
Error	% VMT	4440.32	20	222.02		
	% NVMT	4606.70	20	230.33		
	% NMT	4065.14	20	203.26		
Total	% VMT	106237.63	24			
	% NVMT	10074.61	24			
	% NMT	17772.10	24			
Total corrected	% VMT	7053.43	23			
	% NVMT	4776.50	23			
	% NMT	7350.93	23			
Estimates						
	Group A		Group B		p value	
	Allograft + Autogenous		Xenograft + Autogenous			
	Mean	SE	Mean	SE		
% VMT	60.35	4.91	68.22	4.91	0.319	
% NVMT	15.73	5.00	13.98	5.00	0.826	
% NMT	23.89	4.69	17.78	4.69	0.417	

Note: Analysis performed by MANCOVA.

Abbreviations: VMT, vital mineralized tissue; NMT, nonmineralized tissue; NVMT, nonvital mineralized tissue.

operator surgical skill and experience. Adept knowledge of case selection and of anatomic limitations are keys for success.^{15,16} Bone grafts have two main functions in GBR procedures. The first is mechanical, where it helps maintaining the space required for GBR, stabilizes the blood clot, and stabilizes the membrane. The second is that it provides

biological benefits in terms of being possessing osteogenic, osteoinductive, or osteoconductive effects.¹⁷ It is not the mechanical function of the bone grafts that usually interests clinicians, but the biological. Although autogenous bone is considered by many the “gold standard” for bone reconstruction, they are associated with high

levels of postoperative morbidity, especially in situations that necessitate considerable harvesting from the donor area.¹⁸ Hence, for grafting procedures that require substantial grafting like VRA, adjunct biomaterials may have become necessary.¹⁹

The effect of having autogenous bone as one of the two components of the bone grafting mixture is evident in the present study. A recently published systematic review and network meta-analysis assessed the VMT formation in 33 randomized controlled trials for alveolar ridge preservation.²⁰ Included studies utilized different types of grafting materials including allografts, xenografts, and alloplasts; with or without biologics. With all biopsies being obtained in roughly the same temporal window, none of the eight grafting materials compared was found to produce a significant effect on the percentage of VMT. In fact, all grafting materials statistically reduced the quantity of VMT in the histomorphometric analysis compared to controls (unassisted socket healing). The systematic review concluded that there is no available grafting material able to improve the percentage of VMT after tooth extraction. More interestingly, the mean VMT formation ranged from 21% to 54% depending on the type/combination of bone graft used. In the present study, both Groups A and B demonstrated a higher percentage of VMT with $67.6\% \pm 16.8\%$ and $60.9\% \pm 18.3\%$, respectively. This may elucidate and/or verify the concept discussed in other studies, that mixing autogenous bone with another slow resorbing graft does not only maintain the autogenous graft dimensions, but also provides an opportunity for more vital bone to be formed.²¹ The findings of the present study seem to be more in line with those reported in a systematic review by Troeltzsch et al., in which the degree of bone formation (VMT) was $56.6\% \pm 24.0\%$ for an autogenous graft mixed with other grafting materials.²²

It has been repeatedly advocated that a composite graft made up of autogenous bone chips and a slow-degrading biomaterial (usually xenograft) in a 1:1 ratio is particularly beneficial for challenging horizontal augmentations and VRA due to the extensive space required for mesenchymal host cells to regenerate, with several demonstrating successful clinical outcomes of regeneration and histological bone formation.^{19,23,24} Ideally, the autogenous bone chips would enhance the regeneration outcome by intrinsic osteogenic progenitor cells and proteins within the augmented space.^{25,26} In addition to limited supply, so to speak, autogenous bone resorbs faster. Supplementing autogenous bone with slow-degrading biomaterials will slow the overall resorption rate and would require less bone harvesting.^{27,28}

However, a preclinical study that compared deproteinized bovine bone mineral (DBBM) to a mixture of DBBM and autogenous bone demonstrated that the expected increase in VMT with the addition of autogenous bone chips only occurs in the early healing stages (3 weeks), where VMT was found to be similar in later healing phases (12 weeks).²⁹ These findings were substantiated by a more recent clinical trial which showed no additional clinical and/or histological benefit from increasing the volume of autogenous bone in the autogenous-DBBM mixture during ridge augmentation procedures.³⁰ This controversy highlights the need for further investigation, particularly for VRA and more challenging defects.

In the present study, allograft and xenograft showed a similar capacity to form a large percentage of VMT when combined with autogenous bone. Also, no significant differences were found between the groups for VMT ($p = 0.319$), NVMT ($p = 0.826$), and NMT ($p = 0.417$), once the covariate was adjusted. It has been previously demonstrated that the same bone substitute may result in different volumes of VMT³¹ if the preparation process is different.

The present study has limitations. Since the presented patient pool was one that attended the author's private practice, many of them had particular choices of the type of bone graft used based on their personal preference, though this was without any interference or recommendation from the author. Consequently, this analysis was based on a sample of voluntary response. The size and height of the defect, as well as the proximity of the neighboring osseous walls where the biopsy was taken, could have influenced the rate of new bone formation. For this reason, the results found in this study cannot represent the entire population treated with these procedures.

The healing time in this study was also considerably longer than similar studies and may have been one of the reasons for the increased volume of VMT. It is important to notice that the histologic biopsies were obtained at the time of implant placement, which was decided more by the defect size the healing pattern rather than the type of bone used, which resulted in unbalanced mean healing times in both groups. Similar studies have demonstrated that a significant amount of fibrovascular tissue may be found in histological sections between native bone and residual graft at roughly 12 weeks post-surgery; this bone though might have a potential to partly turn into VMT over time.^{32,33}

Our current understanding of the crestal behavior after VRA is founded on few radiographic retrospective studies. One study evaluating machined (turned) surface implants followed for a mean follow-up of 15 years concluded that these implants seemed to have relatively stable crestal bone.³⁴ Aside from that, the amount of mineralized bone found after VRA and its influence on osseointegration and implant survival remains unknown. The current study did not find significant differences when either allografts or xenografts were used, it may be suggested that the use of a nonresorbable membrane autogenous bone, or biologics may play a more significant role in the outcome than the bone filler.³⁵ Clinical trials are required to assess the effectiveness of the amount of mineralized bone and its relationship to long-term implant survival.

5 | CONCLUSION

Given the limitations of this prospective clinical trial, our study showed that allografts and xenografts mixed with autogenous bone had similar behavior in terms of the amount of vital mineralized tissue when used for VRA. Both biomaterials mixed with autogenous bone could be an excellent alternative for bone filling in VRA to obtain vital mineralized bone.

AUTHOR CONTRIBUTIONS

Pier Gallo and André Antonio Pelegrine contributed to the conception and design of the work. Pier Gallo and Sandra Perdomo, Antonio Carlos Aloise collected and analyzed the data; Muhammad H. A. Saleh, Mustafa Tattan, Andrea Ravidà contributed to manuscript preparation. Hom-Lay Wang, Andrea Ravidà, and Pier Gallo made critical changes and gave final approval to the manuscript. All authors gave their final approval and agreed to be accountable for all aspects of the work.

FUNDING INFORMATION

This study was supported in part by the Coordenação de Aperfeiçoamento de Pessoal de Nível Superior – Brazil (finance code 001).

CONFLICT OF INTEREST

The authors have no conflicts of interest to disclose.

DATA AVAILABILITY STATEMENT

The data that support the findings of this study are available from the corresponding author upon request.

ORCID

Pier Gallo  <https://orcid.org/0000-0002-3193-1700>

Antonio Carlos Aloise  <https://orcid.org/0000-0002-9318-7956>

Mustafa Tattan  <https://orcid.org/0000-0001-7498-8064>

Muhammad H. A. Saleh  <https://orcid.org/0000-0001-5067-7317>

André Antonio Pelegrine  <https://orcid.org/0000-0001-7935-1062>

Andrea Ravidà  <https://orcid.org/0000-0002-3029-8130>

Hom-Lay Wang  <https://orcid.org/0000-0003-4238-1799>

REFERENCES

- Couso-Queiruga E, Stuhr S, Tattan M, Chambrone L, Avila-Ortiz G. Post-extraction dimensional changes: a systematic review and meta-analysis. *J Clin Periodontol*. 2021;48:126-144.
- Araujo MG, Lindhe J. Dimensional ridge alterations following tooth extraction. An experimental study in the dog. *J Clin Periodontol*. 2005; 32:212-218.
- Rocchietta I, Ferrantino L, Simion M. Vertical ridge augmentation in the esthetic zone. *Periodontol 2000*. 2000;2018(77):241-255.
- Rocchietta I, Fontana F, Simion M. Clinical outcomes of vertical bone augmentation to enable dental implant placement: a systematic review. *J Clin Periodontol*. 2008;35:203-215.
- Urban IA. Papilla reconstruction in conjunction with vertical augmentation in single tooth defects. In: Urban IA, ed. *Vertical and Horizontal Ridge Augmentation: New Perspectives*. Quintessence Publishing Co.; 2017.
- Urban IA, Lozada JL, Jovanovic SA, Nagursky H, Nagy K. Vertical ridge augmentation with titanium-reinforced, dense-PTFE membranes and a combination of particulated autogenous bone and anorganic bovine bone-derived mineral: a prospective case series in 19 patients. *Int J Oral Maxillofac Implants*. 2014;29:185-193.
- Tinti C, Parma-Benfenati S. Vertical ridge augmentation: surgical protocol and retrospective evaluation of 48 consecutively inserted implants. *Int J Periodontics Restorative Dent*. 1998;18:434-443.
- Wang HL, Boyapati L. "PASS" principles for predictable bone regeneration. *Implant Dent*. 2006;15:8-17.
- Reynolds MA, Kao RT, Camargo PM, et al. Periodontal regeneration - intrabony defects: a consensus report from the AAP regeneration workshop. *J Periodontol*. 2015;86:S105-S107.
- Tattan M. Surgical regenerative therapy. In: Suárez López del Amo F, ed. *Periodontics: the Complete Summary*. Quintessence Publishing Co; 2021:118-131.
- Misch CE, Dietsch F. Bone-grafting materials in implant dentistry. *Implant Dent*. 1993;2:158-167.
- Tidwell JK, Blijdorp PA, Stoelinga PJ, Brouns JB, Hinderks F. Composite grafting of the maxillary sinus for placement of endosteal implants. A preliminary report of 48 patients. *Int J Oral Maxillofac Surg*. 1992; 21:204-209.
- Yildirim M, Spiekermann H, Handt S, Edelhoff D. Maxillary sinus augmentation with the xenograft bio-Oss and autogenous intraoral bone for qualitative improvement of the implant site: a histologic and histomorphometric clinical study in humans. *Int J Oral Maxillofac Implants*. 2001;16:23-33.
- Simion M, Fontana F, Rasperini G, Maiorana C. Vertical ridge augmentation by expanded-polytetrafluoroethylene membrane and a combination of intraoral autogenous bone graft and deproteinized anorganic bovine bone (bio Oss). *Clin Oral Implants Res*. 2007;18:620-629.
- Mendoza-Azpur G, Gallo P, Mayta-Tovalino F, Alva R, Valdivia E. A case series of vertical ridge augmentation using a nonresorbable membrane: a multicenter study. *Int J Periodontics Restorative Dent*. 2018;38:811-816.
- Urban IA, Monje A, Lozada J, Wang HL. Principles for vertical ridge augmentation in the atrophic posterior mandible: a technical review. *Int J Periodontics Restorative Dent*. 2017;37:639-645.
- Simion M, Jovanovic SA, Trisi P, Scarano A, Piattelli A. Vertical ridge augmentation around dental implants using a membrane technique and autogenous bone or allografts in humans. *Int J Periodontics Restorative Dent*. 1998;18:8-23.
- Jensen SS, Terheyden H. Bone augmentation procedures in localized defects in the alveolar ridge: clinical results with different bone grafts and bone-substitute materials. *Int J Oral Maxillofac Implants*. 2009;24-(Suppl):218-236.
- Urban IA, Saleh MHA, Ravidà A, Forster A, Wang HL, Barath Z. Vertical bone augmentation utilizing a titanium-reinforced PTFE mesh: a multi-variate analysis of influencing factors. *Clin Oral Implants Res*. 2021;32:828-839.
- Canellas J, Ritto FG, Figueredo C, et al. Histomorphometric evaluation of different grafting materials used for alveolar ridge preservation: a systematic review and network meta-analysis. *Int J Oral Maxillofac Surg*. 2020;49:797-810.
- Avila-Ortiz G, Elangovan S, Kramer KW, Blanchette D, Dawson DV. Effect of alveolar ridge preservation after tooth extraction: a systematic review and meta-analysis. *J Dent Res*. 2014;93:950-958.
- Troeltzsch M, Troeltzsch M, Kauffmann P, et al. Clinical efficacy of grafting materials in alveolar ridge augmentation: a systematic review. *J Craniomaxillofac Surg*. 2016;44:1618-1629.
- Meloni SM, Jovanovic SA, Urban I, Baldoni E, Pisano M, Tallarico M. Horizontal ridge augmentation using GBR with a native collagen membrane and 1:1 ratio of particulate xenograft and autologous bone: a 3-year after final loading prospective clinical study. *Clin Implant Dent Relat Res*. 2019;21:669-677.
- Urban IA, Nagursky H, Lozada JL, Nagy K. Horizontal ridge augmentation with a collagen membrane and a combination of particulated autogenous bone and anorganic bovine bone-derived mineral: a prospective case series in 25 patients. *Int J Periodontics Restorative Dent*. 2013;33:299-307.
- Nasr HF, Aichelmann-Reidy ME, Yukna RA. Bone and bone substitutes. *Periodontol 2000*. 2000;1999(19):74-86.
- Song YW, Jung HJ, An YZ, Jung UW, Lee JS. Addition of autogenous bone chips to deproteinized bovine bone mineral does not have additional benefit in lateral ridge augmentation-a preclinical in vivo experimental study. *Clin Oral Implants Res*. 2021;32:1105-1114.
- Maiorana C, Beretta M, Salina S, Santoro F. Reduction of autogenous bone graft resorption by means of bio-Oss coverage:

- a prospective study. *Int J Periodontics Restorative Dent*. 2005;25:19-25.
28. Wen SC, Fu JH, Wang HL. Effect of deproteinized bovine bone mineral at implant dehiscence defects grafted by the Sandwich bone augmentation technique. *Int J Periodontics Restorative Dent*. 2018;38:79-85.
 29. Janner SFM, Bosshardt DD, Cochran DL, et al. The influence of collagen membrane and autogenous bone chips on bone augmentation in the anterior maxilla: a preclinical study. *Clin Oral Implants Res*. 2017;28:1368-1380.
 30. Aludden H, Mordenfeld A, Cederlund A, et al. Radiographic changes in height and volume after lateral GBR procedures with different ratios of deproteinized bovine bone mineral and autogenous bone at different time points. An experimental study. *Clin Oral Implants Res*. 2021;32:167-179.
 31. Cook DC, Mealey BL. Histologic comparison of healing following tooth extraction with ridge preservation using two different xenograft protocols. *J Periodontol*. 2013;84:585-594.
 32. Araujo MG, Liljenberg B, Lindhe J. Dynamics of bio-Oss collagen incorporation in fresh extraction wounds: an experimental study in the dog. *Clin Oral Implants Res*. 2010;21:55-64.
 33. Song YW, Rafikov K, Paeng KW, et al. Dimensional changes of the maxillary sinus augmented with a collagenated synthetic bone block or synthetic bone particulates: a pre-clinical study in rabbits. *J Clin Periodontol*. 2020;47:1416-1426.
 34. Simion M, Ferrantino L, Idotta E, Zarone F. Turned implants in vertical augmented bone: a retrospective study with 13 to 21 years follow-up. *Int J Periodontics Restorative Dent*. 2016;36:309-317.
 35. Urban IA, Tattan M, Ravida A, Saleh MH, Tavelli L, Avila-Ortiz G. Simultaneous alveolar ridge augmentation and periodontal regenerative therapy leveraging recombinant human platelet-derived growth factor-BB (rhPDGF-BB): A case report. *Int J Periodontics Restorative Dent*. 2022 Jun 30. doi:10.11607/prd.6055. Epub ahead of print. PMID: 35771596.

How to cite this article: Gallo P, Díaz-Báez D, Perdomo S, et al. Comparative analysis of two biomaterials mixed with autogenous bone graft for vertical ridge augmentation: A histomorphometric study in humans. *Clin Implant Dent Relat Res*. 2022;24(5):709-719. doi:10.1111/cid.13124