






Comparing Survival Outcomes of Patients With LI-RADS-M Hepatocellular Carcinomas and Intrahepatic Cholangiocarcinomas

Andrea S. Kierans, MD,¹  Kyle J. Lafata, PhD,^{2,3,4} Daniel R. Ludwig, MD,⁵ Lauren M. B. Burke, MD,⁶ Victoria Chernyak, MD, MS,⁷  Kathryn J. Fowler, MD,⁸ Tyler J. Fraum, MD,⁵ Katrina A. McGinty, MD,⁶ Matthew D. F. McInnes, MD, PhD,⁹ Mishal Mendiratta-Lala, MD,¹⁰ Guilherme Moura Cunha, MD,¹¹  Brian C. Allen, MD,¹²  Elizabeth M. Hecht, MD,¹  Tracy A. Jaffe, MD,² Kevin R. Kalisz, MD,² Damithri S. Ranathunga, MD,¹² Benjamin Wildman-Tobriner, MD,² Diana M. Cardona, MD,² Anum Aslam, MD,¹⁰ Sonia Gaur, MD,¹⁰ and Mustafa R. Bashir, MD^{2,6,13*}

Background: There is a sparsity of data evaluating outcomes of patients with Liver Imaging Reporting and Data System (LI-RADS) (LR)-M lesions.

Purpose: To compare overall survival (OS) and progression free survival (PFS) between hepatocellular carcinoma (HCC) and intrahepatic cholangiocarcinoma (iCCA) meeting LR-M criteria and to evaluate factors associated with prognosis.

Study Type: Retrospective.

Subjects: Patients at risk for HCC with at least one LR-M lesion with histologic diagnosis, from 8 academic centers, yielding 120 patients with 120 LR-M lesions (84 men [mean age 62 years] and 36 women [mean age 66 years]).

Field Strength/Sequence: A 1.5 and 3.0 T/3D T₁-weighted gradient echo, T₂-weighted fast spin-echo.

Assessment: The imaging categorization of each lesion as LR-M was made clinically by a single radiologist at each site and patient outcome measures were collected.

Statistical Tests: OS, PFS, and potential independent predictors were evaluated by Kaplan–Meier method, log-rank test, and Cox proportional hazard model. A *P* value of <0.05 was considered significant.

Results: A total of 120 patients with 120 LR-M lesions were included; on histology 65 were HCC and 55 were iCCA. There was similar median OS for patients with LR-M HCC compared to patients with iCCA (738 days vs. 769 days, *P* = 0.576). There were no significant differences between patients with HCC and iCCA in terms of sex (47:18 vs. 37:18, *P* = 0.549), age (63.0 ± 8.4 vs. 63.4 ± 7.8, *P* = 0.847), etiology of liver disease (*P* = 0.202), presence of cirrhosis (100% vs. 100%, *P* = 1.000), tumor size (4.73 ± 3.28 vs. 4.75 ± 2.58, *P* = 0.980), method of lesion histologic diagnosis (*P* = 0.646), and proportion of patients who underwent locoregional therapy (60.0% vs. 38.2%, *P* = 0.100) or surgery (134.8 ± 165.5 vs. 142.5 ± 205.6, *P* = 0.913). Using multivariable analysis, nonsurgical compared to surgical management (HR, 4.58), larger tumor size (HR, 1.19), and higher MELD score (HR, 1.12) were independently associated with worse OS.

View this article online at [wileyonlinelibrary.com](https://onlinelibrary.wiley.com/doi/10.1002/jmri.28218). DOI: 10.1002/jmri.28218

Received Jan 14, 2022, Accepted for publication Apr 21, 2022.

*Address reprint requests to: M.R.B., Department of Radiology Duke University, Box 3808 Durham, NC 27710, USA. E-mail: mustafa.bashir@duke.edu

From the ¹Department of Radiology, Weill Cornell Medical College, New York, NY, USA; ²Department of Radiology, Duke University, Durham, NC, USA; ³Department of Radiation Oncology, Duke University, Durham, NC, USA; ⁴Department of Electrical and Computer Engineering, Duke University, Durham, NC, USA; ⁵Mallinckrodt Institute of Radiology, Washington University School of Medicine, St. Louis, MO, USA; ⁶Department of Radiology, University of North Carolina, Chapel Hill, NC, USA; ⁷Department of Radiology, Beth Israel Deaconess Medical Center and Montefiore Medical Center, New York, NY, USA; ⁸Department of Radiology, University California San Diego, San Diego, CA, USA; ⁹Department of Radiology, the Ottawa Hospital Research Institute Clinical Epidemiology Program, University of Ottawa, Ottawa, Canada; ¹⁰Department of Radiology, University of Michigan, Ann Arbor, MI, USA; ¹¹Department of Radiology, University of Washington, St. Louis, MO, USA; ¹²Department of Radiology, University of Ottawa, Ottawa, Canada; and ¹³Department of Radiology, Center for Advanced Magnetic Resonance Development, Duke University, Durham, NC, USA

[Correction added on 10 June 2022, after the first online publication: misspelled author name Anum Aslum has been corrected to Anum Aslam.]

Additional supporting information may be found in the online version of this article

Data Conclusion: There was similar OS in patients with LR-M HCC and LR-M iCCA, suggesting that LR-M imaging features may more closely reflect patient outcomes than histology.

Evidence Level: 3

Technical Efficacy: Stage 5

J. MAGN. RESON. IMAGING 2023;57:308–317.

The Liver Imaging Reporting and Data System (LI-RADS) was initially introduced in 2011 and incorporated into the American Association for the Study of Liver Disease (AASLD) hepatocellular carcinoma (HCC) clinical practice guideline in 2018.¹ LI-RADS categorizes lesions on an ordinal scale to relay the likelihood of HCC in at risk patients. It also provides a unique category (LR-M) for lesions that are definitely or probably malignant, but are not specific for HCC.¹ LR-M lesions are those with at least one targetoid feature, which includes rim arterial phase hyperenhancement, nonperipheral washout, delayed central enhancement, and targetoid diffusion restriction or transitional/hepatobiliary phase appearance. The LR-M category can also be assigned to lesions not meeting LR-5 or LR-Tumor-in-Vein (TIV) criteria and with any of the following nontargetoid features including infiltrative appearance, marked diffusion restriction, or necrosis/severe ischemia.¹ Prior meta-analyses have demonstrated that 26%–48% of LR-M lesions are HCC while 32%–59% are intrahepatic cholangiocarcinoma (iCCA).^{2,3}

There is a sparsity of published data evaluating outcomes of patients with LR-M lesions. The current literature has focused on outcomes after surgical resection, with one prior study demonstrating an overall survival (OS) and recurrence free survival (RFS) of 37.5 and 16.5 months, respectively, for patients after resection of a LR-M lesion.⁴ However, many iCCAs are unresectable due to advanced disease at the time of diagnosis, and therefore, studies of patients with resected lesions may be biased toward less aggressive iCCAs than those encountered in clinical practice.⁵ Furthermore, while it is well established that the prognosis for iCCA is dismal, there are few studies that evaluate outcomes of iCCAs in patients with cirrhosis.^{6–8}

Even less is known about outcomes in patients with HCCs meeting LR-M criteria. A few prior studies have demonstrated more aggressive biologic behavior in HCCs with rim arterial phase rim hyper-enhancement thought to be due to the presence of microvascular invasion, early lymph node metastases, and rapid growth.^{4,9,10} Furthermore, patients with LR-M HCCs have been demonstrated to have worse prognosis than those with HCCs meeting criteria for LR-5 and LR-4 after surgical resection in a prior study involving a small cohort of LR-M HCCs.¹⁰ This suggests prognostic heterogeneity in HCCs that may be more accurately captured by imaging features than standard histologic assessment. Given these findings, we hypothesize that the biologic behavior and resultant outcomes of LR-M

HCCs are similar to LR-M iCCAs. Knowledge of the outcomes of these lesions may be useful for determining optimal management.

Therefore, the aim of our study is to compare the OS and PFS between HCC and iCCA meeting LR M criteria and to evaluate factors associated with prognosis.

Material and Methods

Patients

This multicenter retrospective Health Insurance Portability and Accountability Act–compliant study was approved by the institutional review boards at all institutions with waiver of informed consent.

The institutional databases from eight academic centers were searched to identify patients ≥ 18 years-old who 1) met criteria for application of LI-RADS¹; 2) had at least one LR-M lesion on dynamic contrast-enhanced CT or MRI; and 3) had histologic diagnosis of the LR-M lesion through biopsy, resection, or explant. Exclusion criteria were as follows: 1) the presence of LR-4, LR-5, LR-TIV or other malignancy within 5 years prior to baseline imaging, as this could confound outcome measures; 2) locoregional or systemic treatment of the LR-M lesion prior to the baseline imaging study; and 3) absence of at least one of the following tumor markers within 4 weeks of baseline imaging (alpha fetoprotein, carbohydrate antigen 19–9, or carcinoembryonic antigen). Patients were further excluded for 1) LR-M lesions that were not HCC or iCCA on histology (including exclusion of combined cHCC-CCA) and 2) without imaging or clinical follow-up after the baseline CT or MRI examination. Patients who had no available imaging after the baseline study to evaluate for the presence of progression were not included in the PFS analysis; however, those with clinical follow-up were still included in the final cohort for OS analysis. The eight institutions that contributed data included Montefiore Medical Center ($n = 6$), University of Ottawa ($n = 6$), University of California San Diego ($n = 8$), Weill Cornell Medical Center ($n = 11$), University of North Carolina ($n = 19$), Duke University Medical Center ($n = 23$), Washington University School of Medicine ($n = 23$), and University of Michigan ($n = 24$). The final cohort included 120 lesions in 120 patients (84 men [mean age 62 years; range, 31–87 years] and 36 women [mean age 66 years; range, 52–82 years]). Patient selection is summarized in Fig. 1.

The categorization of each lesion as LR-M was made by a single radiologist at each respective site, with 2–30 years of

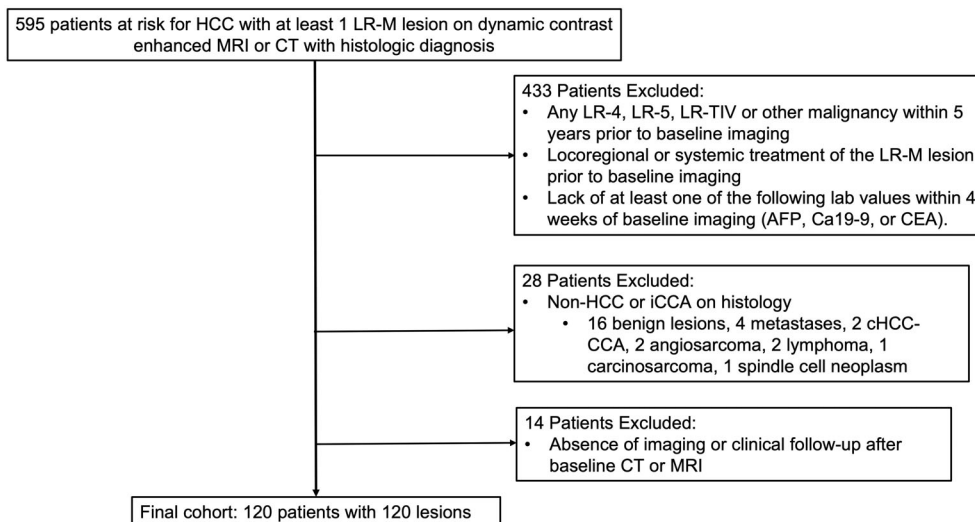


FIGURE 1: Study flowchart. LR = LI-RADS; TIV = tumor in vein; HCC = hepatocellular carcinoma; iCCA = intrahepatic cholangiocarcinoma.

postabdominal imaging fellowship experience at the time of clinical interpretation of imaging, using v2018 LR-M criteria.¹ The following data were gathered from the electronic medical records; patient demographics, lesion histology, method of histologic diagnosis (biopsy, resection, explant), initial lesion treatment (including locoregional and/or systemic therapy), surgical resection or liver transplantation, time from lesion diagnosis to treatment initiation or surgery, presence of radiologic progression as per the modified Response Evaluation Criteria in Solid Tumors (mRECIST) on follow-up imaging, time from diagnosis to radiologic progression, time from diagnosis to death or last living follow-up, and cause of death.

End points

The primary end point was OS, defined as the time from imaging diagnosis of LR-M lesion to death, where all deaths were counted as events. Disease-specific survival was also evaluated, where only deaths attributable to tumor progression were considered events. Patients known to be alive or with unknown status at the end of the study period were censored at the last date of living clinical or radiologic follow-up before January 03, 2022. The secondary end point was progression free survival (PFS), defined as the time from diagnosis of LR-M lesion to radiologic progression as defined by mRECIST. Patients without radiologic progression during the study period were censored at the last available contrast-enhanced CT, MRI, or PET/CT examination before January 03, 2022.

As per mRECIST, complete response was defined as the absence of enhancing tumor in all target lesions; partial response (PR) and progressive disease (PD) was greater than a 30% decrease or greater than 20% increase, respectively, in the sum of the longest diameters of the enhancing lesions; and stable disease as neither PR or PD.¹¹ mRECIST category

was determined by a single radiologist at each respective site based on lesion size and description from the clinically rendered reports on follow-up imaging compared to the baseline imaging. The development of a new LR-4, LR-5, LR-TIV, or LR-M lesion in a patient was considered progression.^{12,13}

Imaging

All patients underwent MRI (*n* = 110) or CT (*n* = 10) with a dynamic contrast enhanced liver protocol per LI-RADS 2018 technical requirements (Supplemental Material S1). MRI examinations were performed with 1.5 T (*n* = 82) or 3.0 T (*n* = 28) systems. Ninety-seven MR examinations were performed with an extracellular contrast agent (gadobenate dimeglumine, *n* = 63; gadoterate meglumine, *n* = 16; gadobutrol, *n* = 14; gadopentetate dimeglumine, *n* = 1; or unknown agent, *n* = 1) and 13 examinations were performed with a hepatobiliary agent (gadoxetate disodium). Hepatobiliary phase imaging was not performed for any examinations utilizing gadobenate dimeglumine.

Statistical Analysis

To compare features between patients with HCC and iCCA, we used two-sample t-tests for continuous variables and chi-square tests for categorical variables. Median follow-up times were calculated based on the reverse Kaplan–Meier method. Cox proportional hazard models with backward selection were utilized for univariable and multivariable analyses of factors related to OS and PFS of LR-M lesions. Potential factors included histologic type of tumor (HCC vs. iCCA), surgical vs. nonsurgical treatment, patient age, tumor size, and Model for End-Stage Liver Disease score (MELD) score at the time of LR-M classification. Variables with *P* < 0.10 at univariable analyses were included in the multivariable analysis. OS and PFS were estimated by using Kaplan–Meier survival curves

and the log-rank test used to compare OS and PFS between LR-M HCC and iCCA and between lesions who underwent surgical and nonsurgical management. For comparisons, a P value of <0.05 was considered significant.

Results

Study Sample

The clinical and treatment characteristics of the patient cohort are summarized in Table 1. The study cohort consisted of 65 patients with HCC and 55 patients with iCCA. There was no significant difference in the prevalence of hepatitis C (50.7% vs. 34.5%, $P = 0.202$) or hepatitis B (7.7% vs. 5.5%, $P = 0.202$) between the two groups. There was no significant difference between patients with HCC and iCCA in terms of sex (47:18 vs. 37:18, $P = 0.549$), age (63.0 ± 8.4 vs. 63.4 ± 7.8 , $P = 0.847$), etiology of liver disease ($P = 0.202$), presence of cirrhosis (100% vs. 100%, $P = 1.000$), tumor size (4.73 ± 3.28 vs. 4.75 ± 2.58 , $P = 0.980$), method of lesion histologic diagnosis ($P = 0.646$), and proportion of patients who underwent locoregional therapy (60.0% vs. 38.2%, $P = 0.100$). HCCs were diagnosed by biopsy ($n = 51$), resection ($n = 12$), or explant ($n = 2$). iCCAs were diagnosed by either biopsy ($n = 43$), resection ($n = 8$), explant ($n = 1$), bile duct brushing ($n = 2$), or cytology of ascites ($n = 1$).

There was no significant difference in proportion of patients who underwent surgery of the baseline lesion between the two groups (23.1 vs. 23.6, $P = 0.948$). Interval from diagnosis to surgery also did not significantly differ between the two groups (134.8 ± 165.5 vs. 142.5 ± 205.6 days, $P = 0.95$). Significantly fewer patients with HCC underwent systemic therapy than those with iCCA (12% vs. 19%), and there was a longer interval between diagnosis and initiation of systemic therapy for those with HCC compared to those with iCCA (350.3 ± 379.7 days vs. 115.1 ± 90.5 days). Extrahepatic metastases, based on imaging findings in all cases, were present on baseline imaging in 2/65 (3%) patients with HCC and 16/55 (29%) patients with iCCA.

Overall Survival

There was no significant difference in median follow-up between HCC and iCCA (1087 days vs. 744 days, $P = 0.220$) (Table 2). The median OS was similar for patients with HCC compared to patients with iCCA (738 days vs. 769 days, $P = 0.576$) (Figs. 2 and 3). Disease-specific survival was also similar for patients with HCC compared to iCCA (1585 vs. 1060 days, $P = 0.349$). For the 34 patients with HCC who died, the cause of death was tumor progression (with or without hepatic failure) in 58.8% (20/34), hepatic failure without tumor progression in 17.6% (6/34), and other causes in 23.5% (8/34) patients (unknown cause [$n = 3$], sepsis [$n = 2$], hemorrhagic shock [$n = 2$], and

pulmonary embolism [$n = 1$]). For the 29 patients with iCCA who died, the cause of death was tumor progression (with or without hepatic failure) in 69% (20/29), hepatic failure without tumor progression in 10.3% (3/29), and other causes in 20.7% (6/29) (unknown cause [$n = 2$], gastrointestinal bleed [$n = 2$], arrhythmia [$n = 1$], and renal failure [$n = 1$]).

Table 3 summarizes the results of univariable and multivariable analyses for potential factors associated with OS. At univariable analysis, nonsurgical compared to surgical management (HR 4.23), larger tumor size (1.12), and higher MELD score (HR 1.12) were significantly associated with shorter OS. Similarly, at multivariable analysis, nonsurgical compared to surgical management (HR, 4.58), larger tumor size (HR, 1.19), and higher MELD score (HR, 1.12) showed significant independent associations with OS. Median OS of patients who underwent nonsurgical compared to surgical management of the LR-M lesion is presented in the Supplementary Material S1.

Progression Free Survival

The median PFS for patients with HCC was 533 days and for iCCA was 310 days (Fig. 4). Table 3 summarizes the results of univariable and multivariable analyses for the factors affecting PFS. Using multivariable analysis, nonsurgical compared to surgical management (HR, 2.15) and higher MELD score (HR, 1.05) showed an independent association with worse PFS. Median PFS of patients who underwent surgery vs. nonsurgical management of the LR-M lesion is presented in the Supplementary Material S1.

Of the 53 patients with HCC and imaging follow-up, disease progression occurred in 54.7% (29/53), which was confirmed with biopsy ($n = 2$) or imaging as per mRECIST ($n = 27$). Disease progression occurred as: progression of the baseline lesion alone in 17.2% (5/29) patients, new disease elsewhere in the liver alone in 34.5% (10/29) patients, both progression of baseline lesion and new disease elsewhere in the liver in 10.3% (3/29) patients, and extrahepatic metastases with or without intrahepatic tumor progression in 37.9% (11/29) patients. Of the 10 patients with new intrahepatic lesions elsewhere in the liver, the new lesions were categorized as LR-M in 30% (3/10) patients, LR-5 in 40% (4/10) patients, and LR-4 in 30% (3/10) patients. Of the 11 patients with extrahepatic metastases, the location of extrahepatic metastases was lymph node metastases alone in 45.5% (5/11) patients and combinations of lymph node, bone, and lung metastases in the remaining 54.5% (6/11) patients.

Of the 44 patients with iCCA and follow-up imaging, disease progression occurred in 72.7% (32/44) patients, which were diagnosed on imaging in all cases. Disease progression occurred as: progression of the baseline lesion alone in 15.6% (5/32) patients, new disease elsewhere in the liver alone in 25% (8/32) patients, progression of baseline lesion and new disease elsewhere in the liver in 6.3% (2/32)

TABLE 1. Demographics and Treatment of Patients With LR-M HCC and iCCA

Variable	HCC (<i>n</i> = 65)	iCCA (<i>n</i> = 55)	<i>P</i> value
Mean age (years)			
All patients	63.0 ± 8.4	63.4 ± 7.8	<i>P</i> = 0.847
Men	61.7 ± 8.2	62.6 ± 8.5	<i>P</i> = 0.630
Woman	66.7 ± 7.8	65.0 ± 6.2	<i>P</i> = 0.468
M:F ratio	47:18	37:18	<i>P</i> = 0.549
Tumor size ± SD (cm)	4.73 ± 3.28	4.75 ± 2.58	<i>P</i> = 0.980
Cirrhosis	65/65 (100%)	55/55 (100%)	<i>P</i> = 1.000
Etiology of liver disease			<i>P</i> = 0.202
Hepatitis C	33/65 (50.8%)	19/55 (34.5%)	
Hepatitis B	5/65 (7.7%)	3/55 (5.5%)	
Alcohol	4/65 (6.2%)	7/55 (12.7%)	
Nonalcoholic steatohepatitis	12/65 (18.5%)	18/55 (32.7%)	
Other	11/65 (16.9%)	8/55 (14.5%)	
Modality of initial diagnosis			<i>P</i> = 0.646
Biopsy	51/65 (78.4%)	43/55 (78.1%)	
Surgical specimen	12/65 (18.5%)	8/55 (14.5%)	
Explant	1/65 (1.5%)	1/55 (1.8%)	
Other	1/65 (1.5%)	3/55 (5.5%)	
Surgical procedures	15/65 (23.1%)	13/55 (23.6)	<i>P</i> = 0.948
Liver transplantation	3/15 (20.0%)	2/13 (15.4%)	
Resection	12/15 (80.0%)	11/13 (84.6%)	
Interval between diagnosis and surgery (days)	134.8 ± 165.5	142.5 ± 205.6	<i>P</i> = 0.913
Initial locoregional therapy of baseline lesion	39/65 (60.0%)	21/55 (38.2%)	<i>P</i> = 0.100
TACE	14/39 (35.9%)	2/21 (9.5%)	
Microwave ablation	6/39 (15.3%)	5/21 (23.8%)	
RF ablation	2/39 (5.1%)	1/21 (4.8%)	
Cryoablation	0/39 (0%)	1/21 (4.8%)	
Radioembolization	9/39 (23.1%)	6/21 (28.6%)	
Bland embolization	4/39 (10.3%)	2/21 (9.5%)	
SBRT	4/39 (10.3%)	4/21 (19.0%)	
Underwent LRT of initial lesion > 1x	13/65 (20.0%)	5/55 (9.1%)	<i>P</i> = 0.095
Interval between diagnosis and first LRT (days)	108.1 ± 89.0	84.4 ± 64.9	<i>P</i> = 0.290
Underwent systemic therapy	12 (18.5%)	19 (34.5%)	<i>P</i> = 0.045
Interval between diagnosis and systemic therapy (days)	350.3 ± 379.7	115.1 ± 90.5	<i>P</i> = 0.014

HCC = hepatocellular carcinoma; iCCA = intrahepatic cholangiocarcinoma; TACE = trans-arterial chemoembolization; RF = radiofrequency; SBRT = stereotactic body radiation therapy; LRT = locoregional therapy.

TABLE 2. Outcomes of Patients With LR-M HCC and iCCA

Variable	HCC (n = 65)	iCCA (n = 55)	P Value
Median follow-up period (to death or censorship) (days)	1087	744	0.220
Median OS (days)	738	769	0.576
Median DSS (days)	1585	1060	0.349
Median PFS (days)	533	310	0.038
Overall Survival			0.960
Deceased	34/65 (52.3%)	29/55 (52.7%)	
Alive/censored	31/65 (47.7%)	26/55 (47.3%)	
Cause of death			0.400
Cancer progression with or without hepatic failure or other cause	20/34 (58.8%)	20/29 (69.0%)	
Hepatic failure or other cause without cancer progression	14/34 (41.2%)	9/29 (31.0%)	
Progression free survival as per mRECIST			0.280
Complete response	20/65 (30.8%)	8/55 (14.5%)	
Partial response or stable disease	3/65 (4.6%)	2/55 (3.6%)	
Stable disease	1/65 (1.5%)	2/55 (3.6%)	
Progressive disease	29/65 (44.6%)	32/55 (58.2%)	
Insufficient follow-up to establish RECIST category	12/65 (18.5%)	11/55 (20.0%)	
Location of progressive disease			0.23
Hepatic progression only (progression of baseline lesion and/or progression elsewhere in the liver)	18/29 (62.1%)	15/32 (46.9%)	
Extrahepatic metastases with or without hepatic progression	11/29 (37.9%)	17/32 (53.1%)	

OS = overall survival; DSS = disease-specific survival; PFS = progression-free survival; mRECIST = modified response evaluation criteria in solid tumors.

patients, and extrahepatic metastases with or without hepatic tumor progression in 53.1% (17/32) patients. Of the 8 patients with new intrahepatic lesions, these lesions were categorized as LR-M in 37.5% (3/8) patients, LR-5 in 37.5% (3/8) patients, and LR-4 in 25% (2/8) patients. Of the 17 patients with extrahepatic metastases, the location of extrahepatic metastases was lymph node metastases alone in 11.8% (2/17) patients, peritoneal metastases with or without metastases elsewhere in 35.3% (6/17) patients, and a combination of lung, lymph node, pulmonary, and osseous metastases in the remaining 52.9% (9/17) patients.

Discussion

Based on a few prior studies demonstrating aggressive behavior in LR-M HCCs,^{10,14} we hypothesized that patients with LR-M HCCs would have similar outcomes to those with

LR-M iCCAs. Our results demonstrated no significant difference in median OS in patients with LR-M HCC compared to iCCA. Furthermore, we found that nonsurgical compared to surgical management, larger tumor size at the time of diagnosis, and higher MELD score were independently associated with shorter OS for LR-M lesions. While PFS was significantly longer for patients with HCC than iCCA, tumor histology (HCC vs. iCCA) was not independently associated with PFS at multivariable analysis.

The prognosis of intrahepatic cholangiocarcinoma is known to be dismal due to advanced stage at the time of diagnosis and close proximity of tumors to central hepatic structures.¹⁵ As a result, patients with iCCA are reported to have a median OS of only 12–59 months.^{5,8,16–18} However, reports of iCCA outcomes in cirrhosis are conflicting,^{6,19–21} with some demonstrating worse prognosis in cirrhotic than noncirrhotic patients and others without survival differences.²² The median OS for cirrhotic patients with LR-M

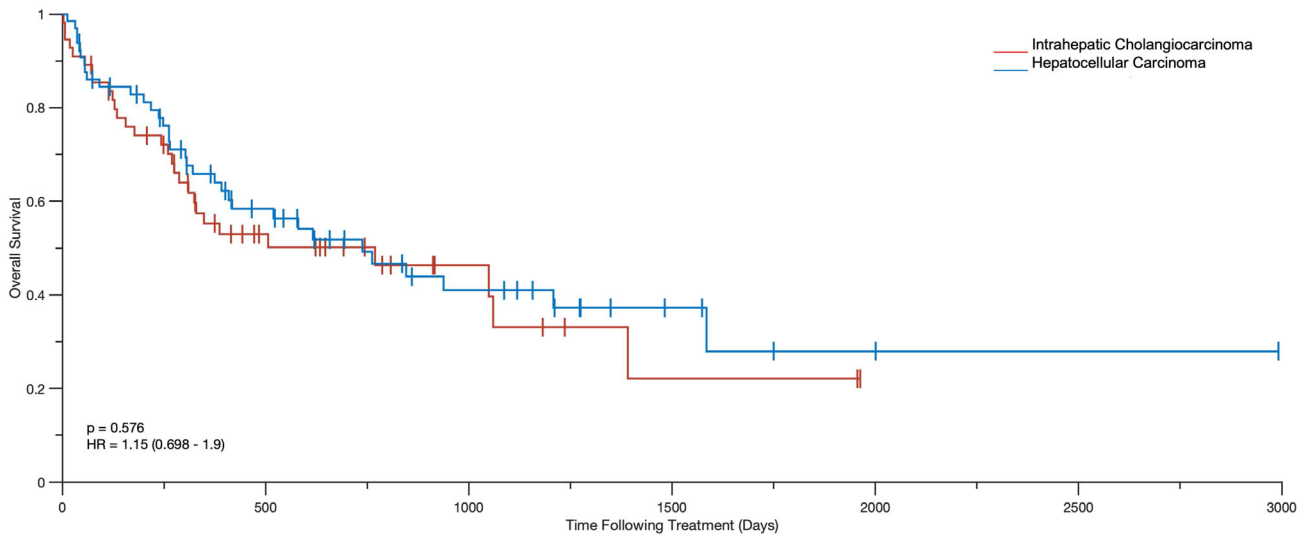


FIGURE 2: Kaplan–Meier curves demonstrating overall survival in patients with LR-M hepatocellular carcinoma compared to LR-M intrahepatic cholangiocarcinoma.

iCCA in our cohort was 26 months, which is comparable to survival reported in noncirrhotic patients.^{5,6,16} iCCA has been shown to develop in the background of cirrhosis in 10%–36% of patients,^{23–25} hypothesized to be due to the presence of common precursors cells that proliferate into predominantly bile duct cells²⁴ leading to iCCA.

Little is known about prognosis in patients with LR-M HCCs as prior studies involved up to only seven LR-M HCCs, making it difficult to draw meaningful conclusions.^{4,10} The median OS of patients with LR-M HCCs in our study was approximately 25 months. The literature demonstrates a wide range of median survival times for patients

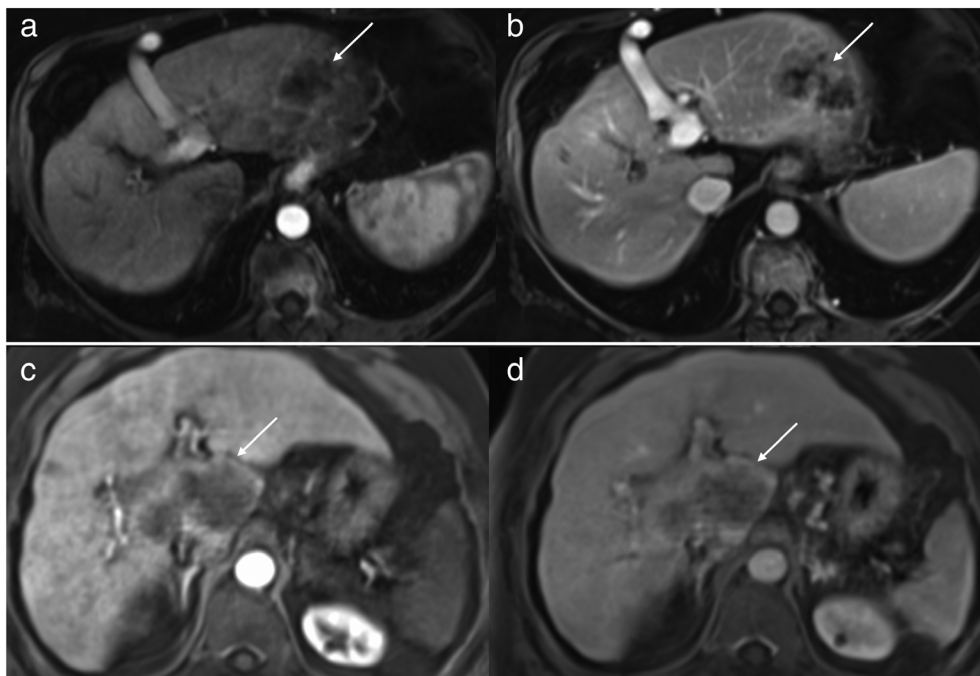


FIGURE 3: LR-M hepatocellular carcinoma and LR-M intrahepatic cholangiocarcinoma. Arterial (a) and portal venous (b) phase T1-weighted fat suppressed 3D GRE images after the administration of gadobenate dimeglumine in a 60-year-old female with hepatitis C cirrhosis demonstrates a 6.0 cm observation (arrows) in segment 2 with arterial-phase rim hyperenhancement persisting in the portal venous phase, categorized as LR-M. At biopsy, this lesion was hepatocellular carcinoma. Arterial (c) and portal venous (d) phase images after the administration of gadobenate dimeglumine in a 72-year-old male with nonalcoholic steatohepatitis (NASH) cirrhosis demonstrates an 8.5 cm observation (arrows) in segments 8, 4a, and 1 with arterial-phase rim hyperenhancement persisting in the portal venous phase, categorized as LR-M. At biopsy, this lesion was intrahepatic cholangiocarcinoma. The patient with LR-M HCC died 90 days after diagnosis and the patient with LR-M iCCA died 72 days after diagnosis due to tumor progression.

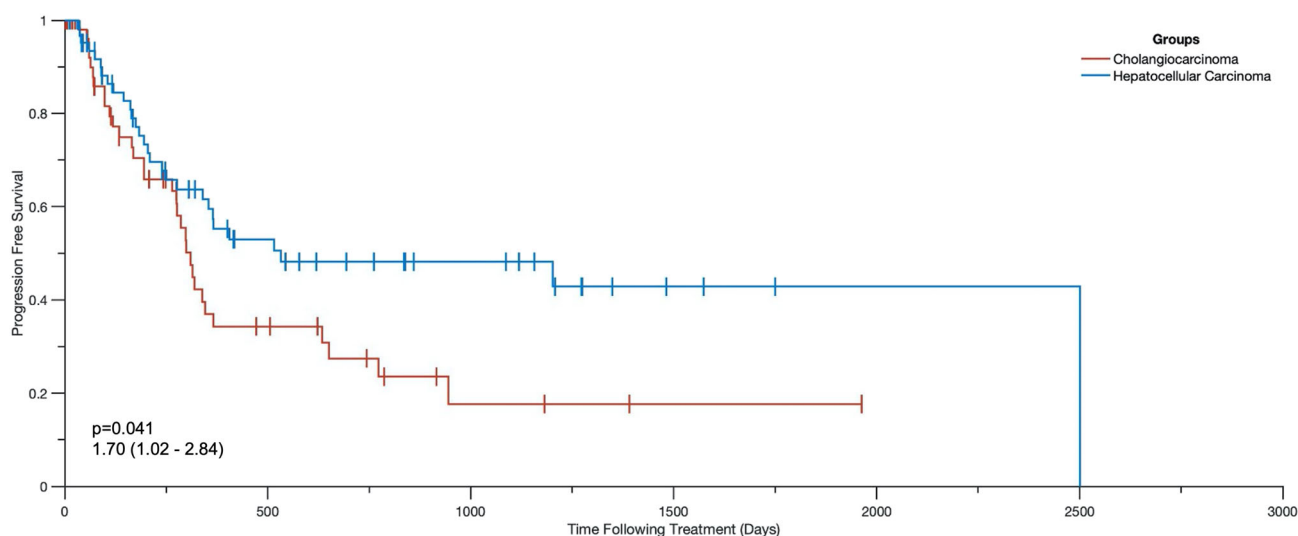
TABLE 3. Univariable and Multivariable Analysis of Factor Affecting Overall Survival and Progression Free Survival in Patient With LR-M HCC and LR-M iCCA

Variable	Overall Survival		Progression Free Survival	
	Univariable Analysis	Multivariable Analysis	Univariable Analysis	Multivariable Analysis
Nonsurgical vs. surgical Management	4.23 (1.92, 9.35) <i>P</i> = 0.0004	4.58 (1.88, 11.17) <i>P</i> < 0.0001	2.40 (1.24, 4.62) <i>P</i> = 0.0093	2.15 (1.10, 4.19) <i>P</i> = 0.024
Age	0.99 (0.96, 1.03) <i>P</i> = 0.910	NA	0.99 (0.96, 1.03) <i>P</i> = 0.780	NA
Histology (iCCA compared to HCC)	1.15 (0.70, 1.89) <i>P</i> = 0.576	NA	1.70 (1.02, 2.84) <i>P</i> = 0.041	NA
MELD score	1.12 (1.08, 1.16) <i>P</i> < 0.0001	1.12 (1.07, 1.15) <i>P</i> < 0.0001	1.06 (1.02, 1.11) <i>P</i> = 0.0078	1.05 (1.00, 1.10) <i>P</i> = 0.032
Tumor size	1.12 (10.6, 1.18) <i>P</i> < 0.0001	1.19 (1.11, 1.29) <i>P</i> < 0.0001	1.05 (0.97, 1.14) <i>P</i> = 0.213	NA

Data are hazard ratios. Numbers in parentheses are 95% confidence intervals. HCC = hepatocellular carcinoma; iCCA = intrahepatic cholangiocarcinoma; MELD = Model for End-Stage Liver Disease.

with HCC ranging from 8 to 95 months that varies according to stage, etiology of HCC, region, and varying clinical practices over time.^{26–28} We demonstrated similar OS and similar disease-specific survival in patients with LR-M HCC compared to iCCA. This suggests that LR-M imaging appearance may be representative of tumor behavior and patient prognosis, regardless of histology. Furthermore, only 5% of patients with LR-M HCC in our cohort underwent liver transplant, suggesting in part, that advanced disease stage at diagnosis may have precluded transplant candidacy.

As might be expected, larger tumor size was independently associated with worse OS for all LR-M lesions, independent of histology. Tumor size has been shown to be associated with worse prognosis for both HCCs and iCCAs in prior investigations.^{29,30} Similarly, MELD score was independently associated with OS and PFS in our investigation, with prior studies also demonstrating functional impairment of the underlying liver having a significant impact on prognosis, regardless of the tumor stage.³¹ It is likely that for patients with resectable lesions or multifocal tumors that are treatable

**FIGURE 4: Kaplan–Meier curves demonstrating progression-free survival in patients with LR-M hepatocellular carcinoma compared to LR-M intrahepatic cholangiocarcinoma.**

with locoregional modalities, the presence of liver decompensation complicates these treatments, in turn affecting survival.

Surgical management was independently associated with prognosis and was more strongly associated with OS and PFS than was histology. The significant differences in median OS and PFS between patients with LR-M lesions who underwent surgery vs. nonsurgical management also persisted in subgroup analyses of patients with LR-M HCC and LR-M iCCA. The ability to undergo surgical resection of the primary LR-M lesion may at least in part be a surrogate for early (and therefore resectable) disease stage at presentation, and surgical candidacy may be more indicative of prognosis than lesion histology. Given the similar behaviors and prognoses of LR-M iCCA and HCC, a unified clinical approach in the management of these lesions may be beneficial, although further prospective studies to investigate optimal treatment paradigms for LR-M HCCs and iCCAs are needed.

Limitations

Given the inherent infrequency of LR-M observations in clinical practice, we had a modest patient cohort size, and therefore our study may have been under-powered to detect a difference in OS. However, we included patients with LR-M observations from eight academic medical centers (seven of which are liver transplant centers) to maximize our study cohort numbers. We did not 1:1 match HCC and iCCAs according to prognostic factors such as tumor size, patient age, or MELD score. Matching would likely have limited the number of eligible patients further given the size of our cohort, and we therefore chose to instead attempt to account for differences with multivariable analyses. The diagnosis of LR-M for every lesion was confirmed by a single radiologist at each respective institution, based on the clinical report, which may not account for interreader variability in LR-M category assignment. However, we chose to include lesions categorized as LR-M in real life clinical practice, as opposed expert research reads. There were insufficient follow-up studies to establish an mRECIST category to determine PFS for 23 patients, an inherent limitation of retrospective outcome studies. However, patients without imaging follow-up but with clinical follow-up were still included for the evaluation of OS and those without either imaging or clinical follow-up were excluded. The presence of disease progression was diagnosed on imaging in the majority of cases without histological proof. However, this reflects standard clinical practice where hepatic and extrahepatic metastases are often diagnosed and treated based on imaging without the need for biopsy. Lastly, we did not evaluate detailed morphologic and immunohistochemical tumor characteristics. Therefore, we could not assess the pathogenetic mechanism of the prognosis of LR-M HCCs and iCCAs; further studies assessing progenitor cell markers in LR-M lesions are needed.

Conclusion

This study found similar OS in patients with LR-M HCC and LR-M iCCA, suggesting that LR-M imaging appearance may more closely reflect patient outcomes than histology.

References

1. American College of Radiology. CT/MRI LI-RADS version 2018. Accessed April 8 2021. Available from: <https://www.acr.org/-/media/ACR/Files/RADS/LI-RADS/LI-RADS-2018-Core.pdf>
2. Kim DH, Choi SH, Park SH, et al. Liver imaging reporting and data system category M: A systematic review and meta-analysis. *Liver Int* 2020; 40(6):1477-1487.
3. van der Pol CB, Lim CS, Sirlin CB, et al. Accuracy of the liver imaging reporting and data system in computed tomography and magnetic resonance image analysis of hepatocellular carcinoma or overall malignancy—a systematic review. *Gastroenterology* 2019;156(4): 976-986.
4. Choi SH, Lee SS, Park SH, et al. LI-RADS classification and prognosis of primary liver cancers at gadoteric acid-enhanced MRI. *Radiology* 2019; 290(2):388-397.
5. Dhanasekaran R, Hemming AW, Zendejas I, et al. Treatment outcomes and prognostic factors of intrahepatic cholangiocarcinoma. *Oncol Rep* 2013;29(4):1259-1267.
6. Li YY, Li H, Lv P, et al. Prognostic value of cirrhosis for intrahepatic cholangiocarcinoma after surgical treatment. *J Gastrointest Surg* 2011; 15(4):608-613.
7. Hyder O, Marques H, Pulitano C, et al. A nomogram to predict long-term survival after resection for intrahepatic cholangiocarcinoma: An eastern and Western experience. *JAMA Surg* 2014;149(5):432-438.
8. Li SQ, Liang LJ, Hua YP, et al. Long-term outcome and prognostic factors of intrahepatic cholangiocarcinoma. *Chin Med J (Engl)* 2009; 122(19):2286-2291.
9. Kierans AS, Leonardou P, Hayashi P, et al. MRI findings of rapidly progressive hepatocellular carcinoma. *Magn Reson Imaging* 2010;28(6): 790-796.
10. An C, Kim DW, Park YN, Chung YE, Rhee H, Kim MJ. Single hepatocellular carcinoma: Preoperative MR imaging to predict early recurrence after curative resection. *Radiology* 2015;276(2):433-443.
11. Lencioni R, Llovet JM. Modified RECIST (mRECIST) assessment for hepatocellular carcinoma. *Semin Liver Dis* 2010;30(1):52-60.
12. Pinyol R, Montal R, Bassaganyas L, et al. Molecular predictors of prevention of recurrence in HCC with sorafenib as adjuvant treatment and prognostic factors in the phase 3 STORM trial. *Gut* 2019;68(6):1065-1075.
13. Takahashi K, Obeid J, Burmeister CS, et al. Intrahepatic cholangiocarcinoma in the liver explant after liver transplantation: Histological differentiation and prognosis. *Ann Transplant* 2016;21: 208-215.
14. Choi SY, Kim SH, Park CK, et al. Imaging features of gadoteric acid-enhanced and diffusion-weighted MR imaging for identifying cytokeratin 19-positive hepatocellular carcinoma: A retrospective observational study. *Radiology* 2018;286(3):897-908.
15. Poultsides GA, Zhu AX, Choti MA, Pawlik TM. Intrahepatic cholangiocarcinoma. *Surg Clin North Am* 2010;90(4):817-837.
16. Weber SM, Jarnagin WR, Klimstra D, DeMatteo RP, Fong Y, Blumgart LH. Intrahepatic cholangiocarcinoma: Resectability, recurrence pattern, and outcomes. *J Am Coll Surg* 2001;193(4):384-391.
17. Ohtsuka M, Ito H, Kimura F, et al. Extended hepatic resection and outcomes in intrahepatic cholangiocarcinoma. *J Hepatobiliary Pancreat Surg* 2003;10(4):259-264.
18. Guglielmi A, Ruzzenente A, Campagnaro T, et al. Intrahepatic cholangiocarcinoma: Prognostic factors after surgical resection. *World J Surg* 2009;33(6):1247-1254.

19. Luo X, Yuan L, Wang Y, Ge R, Sun Y, Wei G. Survival outcomes and prognostic factors of surgical therapy for all potentially resectable intrahepatic cholangiocarcinoma: A large single-center cohort study. *J Gastrointest Surg* 2014;18(3):562-572.
20. Jesper D, Heyn SG, Schellhaas B, et al. Effects of liver cirrhosis and patient condition on clinical outcomes in intrahepatic cholangiocarcinoma: A retrospective analysis of 156 cases in a single center. *Eur J Gastroenterol Hepatol* 2018;30(5):552-556.
21. Tyson GL, El-Serag HB. Risk factors for cholangiocarcinoma. *Hepatology* 2011;54(1):173-184.
22. Tovoli F, Guerra P, Iavarone M, et al. Surveillance for hepatocellular carcinoma also improves survival of incidentally detected intrahepatic cholangiocarcinoma arisen in liver cirrhosis. *Liver Cancer* 2020;9(6): 744-755.
23. Chang KY, Chang JY, Yen Y. Increasing incidence of intrahepatic cholangiocarcinoma and its relationship to chronic viral hepatitis. *J Natl Compr Canc Netw* 2009;7(4):423-427.
24. Yamamoto S, Kubo S, Hai S, et al. Hepatitis C virus infection as a likely etiology of intrahepatic cholangiocarcinoma. *Cancer Sci* 2004;95(7): 592-595.
25. Kobayashi M, Ikeda K, Saitoh S, et al. Incidence of primary cholangiocellular carcinoma of the liver in Japanese patients with hepatitis C virus-related cirrhosis. *Cancer* 2000;88(11):2471-2477.
26. Wang C-Y, Li S. Clinical characteristics and prognosis of 2887 patients with hepatocellular carcinoma: A single center 14 years experience from China. *Medicine* 2019;98(4):e14070.
27. Kudo M. Surveillance, diagnosis, and treatment outcomes of hepatocellular carcinoma in Japan: 2021 update. *Liver Cancer* 2021;10(3): 167-180.
28. Brar G, Greten TF, Graubard BI, et al. Hepatocellular carcinoma survival by etiology: A SEER-Medicare database analysis. *Hepatol Commun* 2020;4(10):1541-1551.
29. Kong J, Cao Y, Chai J, et al. Effect of tumor size on long-term survival after resection for solitary intrahepatic cholangiocarcinoma. *Front Oncol* 2020;10:559911.
30. Sakamoto Y, Kokudo N, Matsuyama Y, et al. Proposal of a new staging system for intrahepatic cholangiocarcinoma: Analysis of surgical patients from a nationwide survey of the liver cancer study Group of Japan. *Cancer* 2016;122(1):61-70.
31. Bruix J, Sherman M. Management of hepatocellular carcinoma. *Hepatology* 2005;42(5):1208-1236.