

## PERSPECTIVE

# Osseous topography in biologically driven flap design in minimally invasive regenerative therapy: A classification proposal

**Diego Velasquez-Plata**<sup>1,2</sup><sup>1</sup>Private Practice, Fenton, Michigan, USA<sup>2</sup>Department of Periodontics and Oral Medicine, University of Michigan School of Dentistry, Ann Arbor, Michigan, USA**Correspondence**Diego Velasquez-Plata, 415 N. Alloy Drive, Fenton, MI 48430, USA.  
Email: [dvelasq@umich.edu](mailto:dvelasq@umich.edu)**Abstract**

Minimally invasive periodontal regenerative surgical procedures are a paradigm shift that demands a unique approach encompassing specialized armamentarium, magnification tools, knowledge of handling properties of biomaterials, and specific flap designs. Biologically driven flap design is dictated by optimal soft and hard tissue handling, flap perfusion, and wound stability, all in the pursuit of primary intention healing. The unique architecture of the infrabony defect is a determining factor on incision tracing, boundaries of flap extension, and biomaterial selection. The purpose of this article is to propose a flap design classification based on the osseous topography of infrabony defects during biologically driven minimally invasive surgical periodontal regenerative therapy.

**KEYWORDS**

biocompatible materials, guided tissue regeneration, regeneration

**INTRODUCTION**

In an editorial published in the *British Journal of Surgery* in 1990, Fitzpatrick and Wickham<sup>1</sup> concluded that changes occurring in the operating theatres across surgical specialties had one common denominator: ensuring that trauma of surgical access was reduced to a minimum while still achieving the intended therapeutic aims. The field of regenerative periodontal therapy has not been excluded from these revolutionary surgical changes. Since Harrel and Rees<sup>2</sup> illustrated the concept of minimally invasive surgical (MIS) procedures for periodontal regeneration in 1995, different flap designs and suture techniques have been introduced with the purpose of minimizing surgical access, diminishing tissue trauma, enhancing wound closure, providing stability and protection to the blood clot, and avoiding soft tissue recession while facilitating visual and mechanical access to infrabony defects. The MIS technique was subsequently illustrated in several other publications.<sup>3–5</sup>

Flap design has played an important role in the development and application of MIS principles. Takei et al.<sup>6</sup>

introduced a papilla preservation technique to protect the interproximal space hosting the infrabony defect by avoiding incisions directly on the col area, thus facilitating primary closure and protecting grafting material placed in the interproximal spaces. The palatal approach proposed by this technique was modified 10 years later when Cortellini et al.<sup>7</sup> described both the modified papilla preservation technique and a few years later, the simplified papilla preservation flap.<sup>8</sup> These novel techniques provided surgical access from the buccal aspect instead. This surgical modality required a well-defined protocol for incision extension and location, soft tissue manipulation, suturing, and wound closure. It is important to recall that non-absorbable and resorbable barriers were being utilized as the standard of care at that time, and due to their size and nature, incision and flap extension had to be more extensive.

The evolution of the MIS approach has witnessed the incorporation of the minimally invasive surgical technique (MIST), which limits mesio-distal flap extension and coronal-apical reflection while minimizing trauma and maximizing tissue stability.<sup>9</sup> In an effort to further maximize

This is an open access article under the terms of the [Creative Commons Attribution](https://creativecommons.org/licenses/by/4.0/) License, which permits use, distribution and reproduction in any medium, provided the original work is properly cited.

© 2022 The Authors. *Clinical Advances in Periodontics* published by Wiley Periodicals LLC on behalf of American Academy of Periodontology.

wound stability and blood clot protection, a modified MIST (M-MIST) technique was described and illustrated with clinical cases followed up for 12 months.<sup>10</sup> Utilization of enamel matrix derivatives (EMDs) was recommended when performing periodontal regenerative therapy utilizing both the MIST and M-MIST techniques.

A novel technique has been introduced, the entire papilla preservation technique, to treat isolated interproximal infrabony defects. This technique utilizes a tunnel approach with a vertical incision fully elevating a mucoperiosteal flap to access the infrabony defect.<sup>11</sup>

Flap design continued its evolution defined by increased knowledge and experience pertaining to biologic guiding principles such as wound stability, blood clot protection, and introduction of biomaterials that were more compatible with minimally invasive procedures. The incorporation of magnification tools such as the operating microscope (OM) allowed for optimal visual access and illumination, two fundamental requirements when executing surgical therapy in narrow, deep, and constrained spaces.

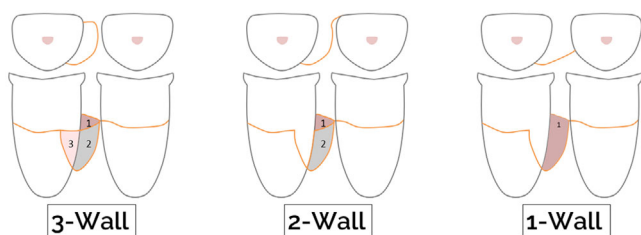
The understanding of the architectural topography of infrabony defects has played a defining role in determining flap design and wound management. The purpose of this article is to propose a flap design classification based on the osseous topography of infrabony defects during biologically driven MIS regenerative therapy.

## INFRABONY DEFECTS

An infrabony defect is a periodontal lesion in which the base of the defect is located apical to the alveolar crest.<sup>12</sup> Goldman and Cohen<sup>13</sup> proposed a classification based on osseous morphology and dependent on the location and number of osseous walls defining the osseous defect. According to the number of walls remaining, a defect would be classified as a 3 wall, 2 wall, or 1 wall. A combination of these categories was recognized as feasible depending on the apico-coronal features of each individual lesion. Therefore, it was possible to have a 3 wall–2 wall–1 wall or a 2 wall–1 wall osseous defect (Figure 1).

The topography of the osseous lesion can be determined by three methods.

1. Bone sounding performed with a periodontal probe allows determination of the presence and height of the remaining osseous walls.



**FIGURE 1** Infrabony defect classification: 3 walls, 2 walls, and 1 wall. Combinations of these defects are clinically feasible

2. Radiographic evaluation utilizing conventional two-dimensional images is most reliable in determining horizontal osseous dimensions when visualizing interproximal spaces. Evidence to justify the use of cross-sectional images (i.e., cone-beam computed tomography scans) is limited, and its utilization is not yet recommended for this purpose.<sup>14</sup>
3. Surgical exploration allows for the most definitive anatomical description and helps determine the type of treatment to be performed.

Infrabony defect morphology influences periodontal regenerative surgical outcomes. Baseline defect depth (>4 mm), narrower angles (<37°), and an increased number of walls (three walls) have a positive influence on bone gain and clinical attachment gain.<sup>15</sup> Understanding the anatomy of the defect is of paramount importance for anticipating the potential regenerative result of the infrabony defect as well as in executing appropriate flap designs that allow optimal access, visualization, and utilization of biomaterials as indicated.

## MINIMALLY INVASIVE SURGICAL PROCEDURES

Incision tracing protocols have been aimed at the preservation of interproximal tissues by protecting the papillary-col complex. The papilla preservation techniques applied palatally<sup>6,16</sup> or buccally,<sup>7,8,10,17–19</sup> are part of these efforts. Novel remote access techniques employing horizontal<sup>20</sup> or vertical incisions<sup>11</sup> have been recently added to this body of work. The common denominator remains blood clot protection, space maintenance, optimization of wound closure, and facilitation of first intention wound healing by enhancing flap perfusion.

Patient-reported outcomes seem to favor the less invasive nature of these procedures by reporting lower pain during the first postoperative days when comparing single versus double flap approach procedures.<sup>21</sup> However, according to Clementini et al.,<sup>22</sup> a juxtaposition of MIS procedures and traditional regenerative surgical therapy cannot be established due to the paucity of studies targeting this type of comparison.

Horizontal and vertical extension of the designed flap boundaries will be determined by achieving optimal visual access allowing thorough inspection of the osseous and radicular anatomy of the infrabony defect. Establishing the osseous topography, verifying the integrity of the root surface, identifying etiologic factors, and placing biomaterials needed for regenerative purposes will be facilitated by proper access. The utilization of magnification devices with coaxial illumination, such as OMs, will refine minimally invasive efforts when approaching infrabony defects.<sup>23</sup> Awareness of macrovascular and microvascular tracks during incision tracing and flap design will translate into proper angiogenesis and wound healing.<sup>24,25</sup>

## BIOMATERIALS

A biomaterial has been defined as “any substance (other than a drug) or combination of substances, synthetic or natural in origin, which can be used for any period of time, as a whole or as a part of a system which treats, augments, or replaces any tissue, organ, or function of the body”.<sup>26</sup> When looking at biomaterials in the field of periodontics, there is evidence of periodontal regeneration in humans (restoration of lost or diminished cementum, periodontal ligament, and alveolar bone) for bone grafts such as decalcified freeze-dried bone allograft (DFDBA)<sup>27</sup> and demineralized bovine bone mineral (DBBM),<sup>28</sup> and bioactive substances and growth factors such as enamel matrix derivative (EMD),<sup>29</sup> recombinant human platelet-derived growth factor-BB (rhPDGF-BB),<sup>30</sup> and recombinant human growth differentiation factor-5 (rhGDF-5).<sup>31</sup>

Synthetic polymers and naturally derived membranes have been utilized in guided tissue regeneration procedures. Membranes must be biocompatible and must have occlusive properties and adequate mechanical properties conducive to space maintenance. Depending on their composition, these biomaterials could be biologically active, biodegradable, and tolerant to exposure. For a more detailed analysis of biomaterials, the reader is referred to Ref.<sup>32</sup>

## INFRABONY DEFECT-DRIVEN BIOLOGIC FLAP DESIGN

### Infrabony defect topography

One of the primary components of the biologically driven flap design is the anatomy of the infrabony defect. Sounding anesthetized gingival tissues with a probe allows establishing the underlying topography of the alveolar bone.

In order to develop clinical surgical guidelines on how to approach infrabony defect-driven flap design, the following infrabony defect classification is being proposed. The buccal-lingual and mesio-distal extension of the infrabony defect are the primary differentiating factors among the three different categories.

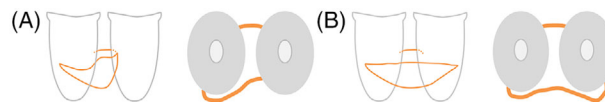
**Type I:** The osseous defect is limited to the interproximal space between teeth. It could be confined to one interproximal wall (i.e., the mesial wall of the first premolar) or could be a “crater” defect involving both interproximal walls of the teeth adjacent to each other (i.e., the mesial wall of the first premolar and the distal wall of the canine) (Figure 2).

**Type II:** The interproximal osseous defect extends mesially and/or distally and is limited to either the buccal or the lingual surfaces (Figure 3).

**Type III:** The interproximal osseous defect extends mesially and distally and affects both the buccal and lingual surfaces. Defects found on the distal or mesial aspects adjacent to an edentulous ridge and extending to the buccal



**FIGURE 2** Frontal and axial views of infrabony defect type I. (A) Defect is confined to one interproximal surface. (B) Defect (crater type) involves both interproximal surfaces



**FIGURE 3** Frontal and axial views of infrabony defect type II. (A) Defect extends beyond the interproximal aspect in only one direction (either mesial or distal) toward the buccal or lingual region. (B) Defect extends beyond the interproximal aspect in both directions (mesial and distal) toward the buccal or lingual region



**FIGURE 4** Frontal and axial views of infrabony defect type III. (A) The interproximal osseous defect extends mesially and distally and affects both the buccal and lingual surfaces. (B) Defects affecting the distal or mesial aspects adjacent to an edentulous ridge and extending to the buccal and/or lingual aspects of the affected tooth are part of this group

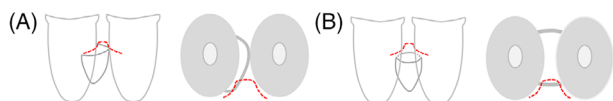
and/or lingual aspects of the affected tooth also fall into this category (Figure 4).

### Flap design

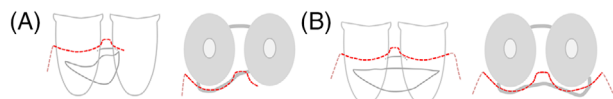
The anatomical extension of the infrabony defect will determine the placement of incisions within this minimally invasive approach. Flap elevation must allow adequate visual access to correctly identify the boundaries of the infrabony defect and facilitate mechanical instrumentation and delivery of biomaterials.

Allocation of biomaterials will be defined by the number of walls defining the infrabony defect or defects being treated. In well-contained defects, such as 3-wall defects, bioactive substances and growth factors can be utilized alone or in combination with an osseous graft. For 2-wall and 1-wall infrabony defects, and wide 3-wall infrabony defects,<sup>33</sup> combinations of osseous grafts, bioactive substances/growth factors, and membranes are to be considered as primary choices to reconstruct missing hard tissues with the intention of establishing a hemostatic condition compatible with periodontal health.

Papilla preservation incision techniques and intrasulcular incisions are preferred. Vertical incision tracing is to be avoided, and when incorporated (usually determined by the vertical dimension of the infrabony defect), the apico-coronal extension is to be minimized to protect macro- and



**FIGURE 5 (A and B)** Flap design A: papilla preservation incision techniques are the default choice when treating type I infrabony defects



**FIGURE 6 (A and B)** Flap design B: type II infrabony defects can be accessed with a combination of papilla preservation incision techniques and intrasulcular incisions

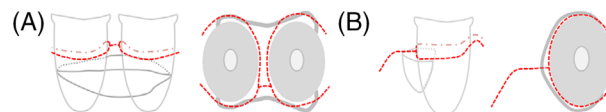
microcirculatory components. The following flap design modalities correspond to their respective infrabony defect types.

**Type A flap design:** When treating a type I infrabony defect, papilla preservation incision techniques are the default choice. Slight intrasulcular extension toward the immediately adjacent interproximal line angles as needed for osseous defect boundary identification and debridement. Vertical incisions are not needed with this type of osseous topography (Figure 5, Video 1 in online *Clinical Advances in Periodontics*).

**Type B flap design:** Type II infrabony defects can be handled with a combination of papilla preservation incision techniques and intrasulcular incisions. The extension of the intrasulcular mesial and/or distal incisions mirrors the extension and direction of the underlying infrabony defect. Vertical incisions are to be avoided. When visualization and access are compromised and a vertical incision(s) will facilitate treatment execution, its apico-coronal extension is to be as minimal as possible (Figure 6, Video 2 in online *Clinical Advances in Periodontics*).

**Type C flap design:** Incision tracing for type III infrabony defects will maintain a combination of papilla preservation incision techniques and intrasulcular incisions extending mesially, distally, buccally, and lingually matching the extension and direction defining the infrabony defect being treated. When dealing with multiple teeth, continuation of the intrasulcular incisions in the interdental space will be advised in the absence of an infrabony defect. If an infrabony defect is present, depending on its anatomy and depth, a step back incision or a papilla preservation incision technique is then considered.

When addressing an infrabony defect on the distal or mesial aspects adjacent to an edentulous ridge and extending to the buccal and/or lingual aspects of the affected tooth, intrasulcular incisions in combination with supracrestal incisions incorporating minimally extended vertical incisions are recommended to obtain visual access and facilitate therapy execution (Figure 7, Video 3 in online *Clinical Advances in Periodontics*).



**FIGURE 7** Flap design C: (A) Incision tracing for type III infrabony defects will maintain a combination of papilla preservation incision techniques and intrasulcular incisions. (B) Intrasulcular incisions in combination with supracrestal incisions incorporating minimally extended vertical incisions are recommended when addressing infrabony defects adjacent to edentulous ridges

## SUMMARY

Classification systems are valuable communication tools that help expedite the understanding of clinical scenarios and diagnostic conditions. These communication tools establish a common ground that facilitates the execution of tasks and the completion of procedures in an orderly and efficient manner.

This manuscript proposes a flap design classification based on the osseous topography of the infrabony defects during biologically driven MIS regenerative therapy. This communication tool will help guide clinicians with incision tracing, extension flap elevation, and delivery of biomaterials when addressing infrabony defects in the natural dentition.

Validation of classification systems by conducting further studies incorporating reliability tests is recommended for future research.

## CONFLICT OF INTEREST

The author declares there are no conflicts of interest.

## REFERENCES

1. Fitzpatrick JM, Wickham JE. Minimally invasive surgery. *Br J Surg*. 1990;77:721–722.
2. Harrel SK, Rees TD. Granulation tissue removal in routine and minimally invasive procedures. *Compend Contin Educ Dent*. 1995;16:960–962. 964 passim.
3. Harrel SK. A minimally invasive surgical approach for periodontal bone grafting. *Int J Periodontics Restorative Dent*. 1998;18:161–169.
4. Harrel SK. A minimally invasive surgical approach for periodontal regeneration: surgical technique and observations. *J Periodontol*. 1999;70:1547–1557.
5. Harrel SK, Nunn ME, Belling CM. Long-term results of a minimally invasive surgical approach for bone grafting. *J Periodontol*. 1999;70:1558–1563.
6. Takei HH, Han TJ, Carranza FA Jr, Kenney EB, Lekovic V. Flap technique for periodontal bone implants. Papilla preservation technique. *J Periodontol*. 1985;56:204–210.
7. Cortellini P, Prato GP, Tonetti MS. The modified papilla preservation technique. A new surgical approach for interproximal regenerative procedures. *J Periodontol*. 1995;66:261–266.
8. Cortellini P, Prato GP, Tonetti MS. The simplified papilla preservation flap. A novel surgical approach for the management of soft tissues in regenerative procedures. *Int J Periodontics Restorative Dent*. 1999;19:589–599.
9. Cortellini P, Tonetti MS. A minimally invasive surgical technique with an enamel matrix derivative in the regenerative treatment of intra-bony defects: a novel approach to limit morbidity. *J Clin Periodontol*. 2007;34:87–93.



10. Cortellini P, Tonetti MS. Improved wound stability with a modified minimally invasive surgical technique in the regenerative treatment of isolated interdental intrabony defects. *J Clin Periodontol*. 2009;36:157–163.
11. Aslan S, Buduneli N, Cortellini P. Entire papilla preservation technique: a novel surgical approach for regenerative treatment of deep and wide intrabony defects. *Int J Periodontics Restorative Dent*. 2017;37:227–233.
12. Prichard J. A technique for treating intrabony pockets based on alveolar process morphology. *Dent Clin North Am*. 1960;4:85–105.
13. Goldman HM, Cohen DW. The intrabony pocket: classification and treatment. *J Periodontol*. 1958;29:272–291.
14. Kim DM, Bassir SH. When is cone-beam computed tomography imaging appropriate for diagnostic inquiry in the management of inflammatory periodontitis? An American Academy of Periodontology best evidence review. *J Periodontol*. 2017;88:978–998.
15. Nibali L, Sultan D, Arena C, Pelekos G, Lin GH, Tonetti M. Periodontal infrabony defects: systematic review of healing by defect morphology following regenerative surgery. *J Clin Periodontol*. 2021;48:100–113.
16. Murphy KG. Interproximal tissue maintenance in GTR procedures: description of a surgical technique and 1-year reentry results. *Int J Periodontics Restorative Dent*. 1996;16:463–477.
17. Trombelli L, Farina R, Franceschetti G, Calura G. Single-flap approach with buccal access in periodontal reconstructive procedures. *J Periodontol*. 2009;80:353–360.
18. Bianchi AE, Bassetti A. Flap design for guided tissue regeneration surgery in the esthetic zone: the “whale’s tail” technique. *Int J Periodontics Restorative Dent*. 2009;29:153–159.
19. Ribeiro FV, Nociti Júnior FH, Sallum EA, Sallum AW, Casati MZ. Use of enamel matrix protein derivative with minimally invasive surgical approach in intra-bony periodontal defects: clinical and patient-centered outcomes. *Braz Dent J*. 2010;21:60–67.
20. Moreno Rodriguez JA, Caffesse RG. Non incised papillae surgical approach (NIPSA) in periodontal regeneration: preliminary results of a case series. *Int J Periodontics Restorative Dent*. 2018;38(suppl):s105–s111.
21. Schincaglia GP, Hebert E, Farina R, Simonelli A, Trombelli L. Single versus double flap approach in periodontal regenerative treatment. *J Clin Periodontol*. 2015;42:557–566.
22. Clementini M, Ambrosi A, Ciccirelli V, De Risi V, de Sanctis M. Clinical performance of minimally invasive periodontal surgery in the treatment of infrabony defects: systematic review and meta-analysis. *J Clin Periodontol*. 2019;46:1236–1253.
23. Cortellini P, Tonetti MS. Microsurgical approach to periodontal regeneration. Initial evaluation in a case cohort. *J Periodontol*. 2001;72:559–569.
24. Mikecs B, Vág J, Gerber G, Molnár B, Feigl G, Shahbazi A. Revisiting the vascularity of the keratinized gingiva in the maxillary esthetic zone. *BMC Oral Health*. 2021;21:160.
25. Fazekas R, Molnár E, Lohinai Z, et al. Functional characterization of collaterals in the human gingiva by laser speckle contrast imaging. *Microcirculation*. 2018;25:e12446.
26. National Institutes of Health Consensus. Development conference statement on the clinical applications of biomaterials. November 1–3, 1982. *Artif Organs*. 1983;7:260–265.
27. Bowers GM, Chadroff B, Carnevale R, et al. Histologic evaluation of new attachment apparatus formation in humans. Part III. *J Periodontol*. 1989;60:683–693.
28. Mellonig JT. Human histologic evaluation of a bovine-derived bone xenograft in the treatment of periodontal osseous defects. *Int J Periodontics Restorative Dent*. 2000;20:19–29.
29. Yukna RA, Mellonig JT. Histologic evaluation of periodontal healing in humans following regenerative therapy with enamel matrix derivative. A 10-case series. *J Periodontol*. 2000;71:752–759.
30. Nevins M, Camelo M, Nevins ML, Schenk RK, Lynch SE. Periodontal regeneration in humans using recombinant human platelet-derived growth factor-BB (rhPDGF-BB) and allogenic bone. *J Periodontol*. 2003;74:1282–1292.
31. Stavropoulos A, Windisch P, Gera I, Capsius B, Sculean A, Wikesjö UM. A phase IIa randomized controlled clinical and histological pilot study evaluating rhGDF-5/ $\beta$ -TCP for periodontal regeneration. *J Clin Periodontol*. 2011;38:1044–1054.
32. Sanz M, Dahlin C, Apatzidou D, et al. Biomaterials and regenerative technologies used in bone regeneration in the craniomaxillofacial region: consensus report of group 2 of the 15th European Workshop on Periodontology on Bone Regeneration. *J Clin Periodontol*. 2019;46(suppl 21):82–91.
33. Stavropoulos A, Wikesjö UM. Influence of defect dimensions on periodontal wound healing/regeneration in intrabony defects following implantation of a bovine bone biomaterial and provisions for guided tissue regeneration: an experimental study in the dog. *J Clin Periodontol*. 2010;37:534–543.

## SUPPORTING INFORMATION

Additional supporting information can be found online in the Supporting Information section at the end of this article.

**How to cite this article:** Velasquez-Plata D. Osseous topography in biologically driven flap design in minimally invasive regenerative therapy: A classification proposal. *Clin Adv Periodontics*. 2022;12:251–255. <https://doi.org/10.1002/cap.10209>